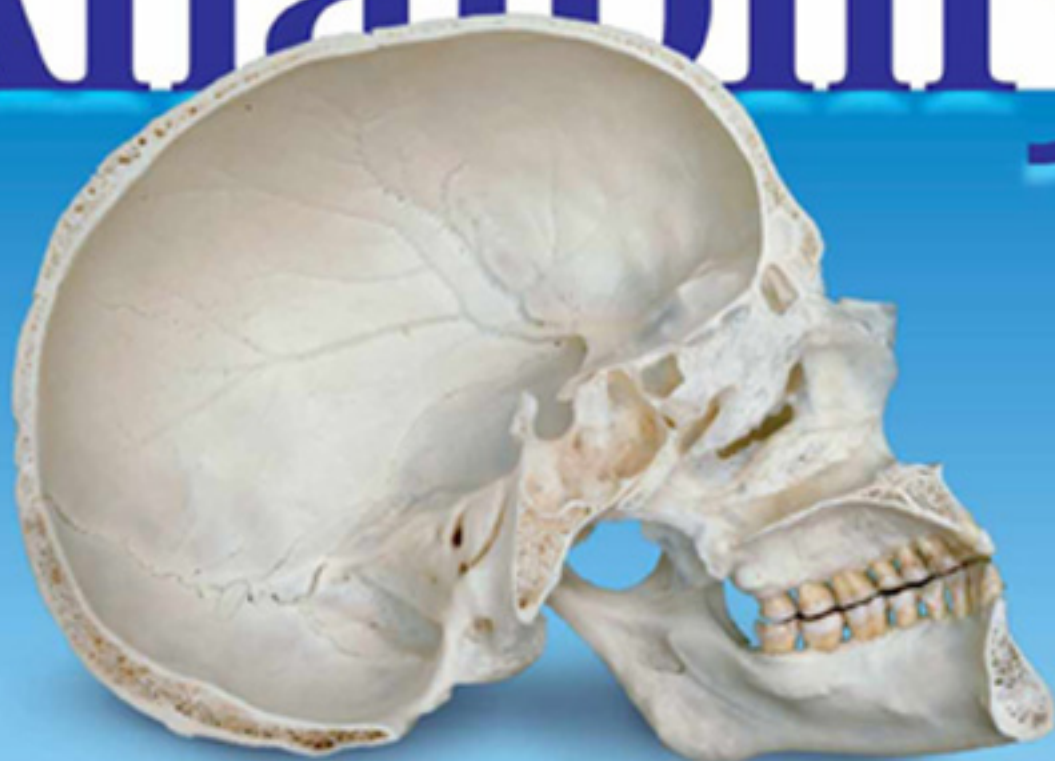

7th Edition

Rohen ■ Yokochi ■ Lütjen-Drecoll

Color Atlas of Anatomy



A Photographic Study
of the Human Body



Wolters Kluwer | Lippincott Williams & Wilkins
Health

thePoint

This page intentionally left blank.

Johannes W. Rohen
Chihiro Yokochi
Elke Lütjen-Drecoll

Color Atlas of Anatomy



A Photographic Study
of the Human Body

Seventh Edition



Coeditons in 20 Languages

Johannes W. Rohen
Chihiro Yokochi
Elke Lütjen-Drecoll

Color Atlas of Anatomy

A Photographic Study
of the Human Body

Seventh Edition

With 1211 Figures,
1117 in Color,
and 94 Radiographs, CT and MRI Scans

 Wolters Kluwer | Lippincott Williams & Wilkins
Health
Philadelphia • Baltimore • New York • London
Buenos Aires • Hong Kong • Sydney • Tokyo

 **Schattauer**

Prof. Dr. med. Dr. med. h.c. Johannes W. Rohen
Anatomisches Institut II der Universität Erlangen-Nürnberg
Universitätsstraße 19, 91054 Erlangen, Germany

Chihiro Yokochi, M.D.
Professor emeritus, Department of Anatomy
Kanagawa Dental College, Yokosuka, Kanagawa, Japan
Correspondence to:
Prof. Chihiro Yokochi, c/o Igaku-Shoin Ltd., 1-28-23 Hongo,
Bunkyo-ku Tokyo 113-8719, Japan

Prof. Dr. med. Elke Lütjen-Drecoll
Anatomisches Institut II der Universität Erlangen-Nürnberg
Universitätsstraße 19, 91054 Erlangen, Germany

With Collaboration of
Kyung W. Chung, Ph.D.
David Ross Boyd Professor & Vice Chairman
Samuel Roberts Noble Foundation Presidential Professor
Director, Advanced Human Anatomy
University of Oklahoma, College of Medicine
Department of Cell Biology

Copyright ©
Fourth Edition, 1998
Fifth Edition, 2002
Sixth Edition, 2006
Seventh Edition, 2011 by
Schattauer GmbH,
Hölderlinstraße 3, 70174 Stuttgart, Germany; <http://www.schattauer.de>, and
Lippincott Williams & Wilkins, a Wolters Kluwer business

351 West Camden Street 530 Walnut Street
Baltimore, MD 21201 Philadelphia, PA 19106

All rights reserved. This book is protected by copyright. No part of this book may be reproduced or transmitted in any form or by any means, including as photocopies or scanned-in or other electronic copies, or utilized by any information storage and retrieval system without written permission from the copyright owner, except for brief quotations embodied in critical articles and reviews. Materials appearing in this book prepared by individuals as part of their official duties as U.S. government employees are not covered by the above-mentioned copyright. To request permission, please contact Lippincott Williams & Wilkins at 530 Walnut Street, Philadelphia, PA 19106, via email at permissions@lww.com, or via website at lww.com (products and services).

9 8 7 6 5 4 3 2 1

Library of Congress Cataloging-in-Publication data has been applied for and is available upon request.

DISCLAIMER

Care has been taken to confirm the accuracy of the information present and to describe generally accepted practices. However, the authors, editors, and publisher are not responsible for errors or omissions or for any consequences from application of the information in this book and make no warranty, expressed or implied, with respect to the currency, completeness, or accuracy of the contents of the publication. Application of this information in a particular situation remains the professional responsibility of the practitioner; the clinical treatments described and recommended may not be considered absolute and universal recommendations.

The authors, editors, and publisher have exerted every effort to ensure that drug selection and dosage set forth in this text are in accordance with the current recommendations and practice at the time of publication. However, in view of ongoing research, changes in government regulations, and the constant flow of information relating to drug therapy and drug reactions, the reader is urged to check the package insert for each drug for any change in indications and dosage and for added warnings and precautions. This is particularly important when the recommended agent is a new or infrequently employed drug.

Some drugs and medical devices presented in this publication have Food and Drug Administration (FDA) clearance for limited use in restricted research settings. It is the responsibility of the health care provider to ascertain the FDA status of each drug or device planned for use in their clinical practice.

To purchase additional copies of this book, call our customer service department at (800) 638-3030 or fax orders to (301) 223-2320. International customers should call (301) 223-2300.

Visit Lippincott Williams & Wilkins on the Internet: <http://www.lww.com>. Lippincott Williams & Wilkins customer service representatives are available from 8:30 am to 6:00 pm, EST.

ISBN: 9781582558561

Preface to the Seventh Edition

This new edition was revised and structured anew in different ways. Each chapter is provided with an introductory front page to give an overview of the topics of the chapter and short descriptions. The whole introductory chapter "General Anatomy" was newly arranged and supported with introductory texts, thus facilitating students to better understand the complicated "world" of gross anatomy. The large chapter 2 "Head and Neck" was split into 5 sub-chapters with an introductory page each. Furthermore, the drawings were revised and improved in many chapters and depicted more consistently. In most of the chapters new photographs taken from newly dissected specimens were incorporated.

The general structure and arrangement of the Atlas were maintained. The chapters of regional anatomy are consequently placed behind the systematic descriptions of the anatomical structures so that students can study – e.g. before dissecting an extremity – the systematic anatomy of bones, joints, muscles, nerves and vessels. For studying the photographs of the specimens the use of a magnifier might be helpful. The enormous plasticity of the photos is surprising, especially at higher magnifications.

In many places new MRI and CT scans were added to give consideration to the new imaging techniques which become more and more important for the student in preclinics. We would like to express our sincere thanks to Prof. Heuck, Munich, who provided us with the MRI scans.

We would like to express our great gratitude to all coworkers who helped to make the *Color Atlas of Anatomy* a success. We are particularly indebted to those who dissected new specimens with great skill and knowledge, particularly to Jeff Bryant (member of our staff) and Dr. Martin Rexer (now Klinikum Fürth, Germany), who prepared most of the new specimens of the fifth, sixth and seventh edition. We would also like to thank Dr. K. Okamoto (now Nagasaki, Japan), who dissected many excellent specimens of the fourth edition, also included in the fifth edition. Furthermore, we are greatly indebted to Prof. W. Neuhuber and his coworkers for their great efforts in supporting our work.

The specimens of the previous editions also depicted in this volume were dissected with great skill and enthusiasm by Prof. Dr. S. Nagashima (now Nagasaki, Japan), Dr. Mutsuko Takahashi (now Tokyo, Japan), Dr. Gabriele Lindner-Funk (Erlangen, Germany), Dr. P. Landgraf (Erlangen, Germany), and Miss Rachel M. McDonnell (now Dallas, Texas, USA).

We are greatly indebted to Prof. Kyung Won Chung, Ph.D., Director of Medical Gross Anatomy, University of Oklahoma, USA, Dept. of Cell Biology, for his careful corrections of the proofs of the new edition.

In the underlying seventh edition photographs of the surface anatomy of the human body were included again. We omitted marks and indications in order not to affect the quality of the pictures.

Despite numerous additions and amendments the size of the volume did not increase so that students both in preclinics and in clinics are offered an atlas easy to handle and cope with.

While preparing this new edition, the authors were reminded of how precisely, beautifully, and admirably the human body is constructed. If this book helps the student or medial doctor to appreciate the overwhelming beauty of the anatomical architecture of tissues and organs in the human, then it greatly fulfils its task. Deep interest and admiration of the anatomical structures may create the "love for man", which alone can be considered of primary importance for daily medical work.

We would like to express our great gratitude to all coworkers for their skilled work. Without their help the improvements of the *Color Atlas of Anatomy* would not have been possible. We would also like to express our sincere thanks to those at Schattauer GmbH, Stuttgart, Germany, Lippincott, Williams & Wilkins, Baltimore, Maryland, USA, and Igaku-Shoin, Tokyo, Japan, who always listened to our suggestions and invested again a great deal of their effort into improving this book.

Acknowledgements

We would also like to express our many thanks to Prof. W. Bautz (Radiologisches Institut, University Erlangen-Nürnberg, Germany) and Prof. A. Heuck (Radiologisches Zentrum, München-Pasing, Germany), who provided the newly included excellent CT and MRI scans.

We are also greatly indebted to Mr. Hans Sommer (SOMSO Co., Coburg, Germany), who kindly provided a number of excellent bone specimens.

Finally, we would like to express our great gratitude to our photographer, Mr. Marco Gößwein, who contributed the very excellent macrophotos. Excellent and untiring work was done by our secretaries, Mrs. Lisa Köhler and Elisabeth Wascher, and as well by our artists, Mr. Jörg Pekarsky and Mrs. Annette Gack, who not only performed excellent new drawings but revised effectively the layout of the new edition.

Last but not least, we would like to express our sincere thanks to all scientists, students, and other coworkers, particularly to the ones at the publishing companies themselves.

Erlangen, Germany; Spring 2010

J. W. Rohen
C. Yokochi
E. Lütjen-Drecoll

Preface to the First Edition

Today there exist any number of good anatomic atlases. Consequently, the advent of a new work requires justification. We found three main reasons to undertake the publication of such a book.

First of all, most of the previous atlases contain mainly schematic or semischematic drawings which often reflect reality only in a limited way; the third dimension, i.e., the spatial effect, is lacking. In contrast, the photo of the actual anatomic specimen has the advantage of conveying the reality of the object with its proportions and spatial dimensions in a more exact and realistic manner than the "idealized", colored "nice" drawings of most previous atlases. Furthermore, the photo of the human specimen corresponds to the student's observations and needs in the dissection courses. Thus he has the advantage of immediate orientation by photographic specimens while working with the cadaver.

Secondly, some of the existing atlases are classified by systemic rather than regional aspects. As a result, the student needs several books each supplying the necessary facts for a certain region of the body. The present atlas, however, tries to portray macroscopic anatomy with regard to the regional and stratigraphic aspects of the object itself as realistically as possible. Hence it is an immediate help during the dissection courses in the study of medical and dental anatomy.

Another intention of the authors was to limit the subject to the essential and to offer it didactically in a way that is self-explanatory. To all regions of the body we added schematic drawings of the main tributaries of nerves and vessels, of the course and mechanism of the muscles, of the nomenclature of the various regions, etc. This will enhance the understanding of the details seen in the photographs. The complicated architecture of the

skull bones, for example, was not presented in a descriptive way, but rather through a series of figures revealing the mosaic of bones by adding one bone to another, so that ultimately the composition of skull bones can be more easily understood.

Finally, the authors also considered the present situation in medical education. On one hand there is a universal lack of cadavers in many departments of anatomy, while on the other hand there has been a considerable increase in the number of students almost everywhere. As a consequence, students do not have access to sufficient illustrative material for their anatomic studies. Of course, photos can never replace the immediate observation, but we think the use of a macroscopic photo instead of a painted, mostly idealized picture is more appropriate and is an improvement in anatomic study over drawings alone.

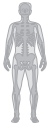The majority of the specimens depicted in the atlas were prepared by the authors either in the Dept. of Anatomy in Erlangen, Germany, or in the Dept. of Anatomy, Kanagawa Dental College, Yokosuka, Japan. The specimens of the chapter on the neck and those of the spinal cord demonstrating the dorsal branches of the spinal nerves were prepared by Dr. K. Schmidt with great skill and enthusiasm. The specimens of the ligaments of the vertebral column were prepared by Dr. Th. Mokuschi, and a great number of specimens in the chapter of the upper and lower limb was very carefully prepared by Dr. S. Nagashima, Kurume, Japan.

Once again, our warmest thanks go out to all of our coworkers for their unselfish, devoted and highly qualified work.

Erlangen, Germany; Spring 1983

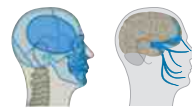J.W. Rohen
C. Yokochi

Contents



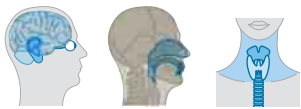1 General Anatomy 1

Architectural Principles of the Human Body _____	1
Position of the Inner Organs, Palpable Points, and Regional Lines _____	2
Planes and Directions of the Body _____	4
Osteology _____	6
Skeleton of the Human Body _____	6
Bone Structure _____	8
Ossification of the Bones _____	9
Arthrology _____	10
Types of Joints _____	10
Architecture of the Joint _____	12
Myology _____	13
Shapes of Muscles _____	13
Structure of the Muscular System _____	14
Comparative Imaging of Skeletal and Muscular Structures in MRI and X-Ray _____	15
Organization of the Circulatory System _____	16
Organization of the Lymphatic System _____	17
Organization of the Nervous System _____	18



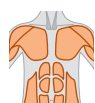
2 Head and Neck 19

2.1 Skull and Muscles of the Head _____	19
Bones of the Skull _____	20
Disarticulated Skull I _____	24
Sphenoidal and Occipital Bones _____	24
Temporal Bone _____	26
Frontal Bone _____	28
Calvaria _____	29
Base of the Skull _____	30
Skull of the Newborn _____	35
Median Sections through the Skull _____	36
Disarticulated Skull II _____	38
Ethmoidal Bone _____	38
Ethmoidal and Palatine Bones _____	39
Palatine Bone and Maxilla _____	40
Sphenoidal, Ethmoidal, and Palatine Bones _____	43
Maxilla, Zygomatic Bone, and Bony Palate _____	45
Pterygopalatine Fossa and Orbit _____	46
Orbit, and Nasal and Lacrimal Bones _____	47
Bones of the Nasal Cavity _____	48
Septum and Cartilages of the Nose _____	49
Maxilla and Mandible with Teeth _____	50
Deciduous and Permanent Teeth _____	51
Mandible and Dental Arch _____	52
Ligaments of the Temporomandibular Joint _____	53
Temporomandibular Joint _____	54
Temporomandibular Joint and Masticatory Muscles _____	55
Masticatory Muscles _____	56
Temporalis and Masseter Muscles _____	56
Pterygoid Muscles _____	57
Facial Muscles _____	58
Supra- and Infrahyoid Muscles _____	60
Section through the Cavities of the Head _____	62
Maxillary Artery _____	63
2.2 Cranial Nerves _____	64
Brain and Cranial Nerves _____	64
Trigeminal Nerve _____	68
Facial Nerve _____	70
Connection with the Brain Stem _____	71
Nerves of the Orbit _____	72
Base of the Skull with Cranial Nerves _____	74
Regions of the Head _____	76
Lateral Region _____	76
Retromandibular Region _____	80
Para- and Retropharyngeal Regions _____	83



2 Head and Neck

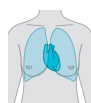2.3 Brain and Sensory Organs _____	84	2.4 Oral and Nasal Cavities _____	143
Position of Brain and Great Sensory Organs _____	84	Position of Oral and Nasal Cavities _____	143
Scalp and Meninges _____	85	Nasal Cavity _____	144
Meninges _____	86	Paranasal Sinuses _____	144
Dura Mater and Dural Venous Sinuses _____	86	Nerves and Arteries _____	146
Dura Mater _____	88	Sections through the Nasal and Oral Cavities _____	148
Pia Mater and Arachnoid _____	89	Oral Cavity _____	150
Brain _____	90	Muscles _____	150
Median Sections _____	90	Submandibular Triangle _____	152
Arteries and Veins _____	92	Salivary Glands _____	153
Arteries _____	93		
Arteries and the Arterial Circle of Willis _____	98	2.5 Neck and Organs of the Neck _____	154
Cerebrum _____	99	Organization and Regions of the Neck _____	154
Cerebellum _____	102	Muscles of the Neck _____	156
Dissections _____	104	Larynx _____	158
Limbic System _____	107	Cartilages and Hyoid Bone _____	158
Hypothalamus _____	108	Muscles _____	160
Subcortical Nuclei _____	109	Vocal Ligament _____	161
Ventricular System _____	112	Nerves _____	162
Brain Stem _____	114	Larynx and Oral Cavity _____	163
Coronal and Cross Sections _____	116	Pharynx _____	164
Horizontal Sections _____	118	Muscles _____	166
Auditory and Vestibular Apparatus _____	122	Vessels of the Head and Neck _____	168
Temporal Bone _____	125	Arteries _____	168
Middle Ear _____	126	Arteries and Veins _____	170
Auditory Ossicles _____	128	Veins _____	171
Internal Ear _____	129	Lymph Vessels and Nodes _____	172
Auditory Pathway and Areas _____	131	Regions of the Neck _____	174
Visual Apparatus and Orbit _____	132	Anterior Region _____	174
Eyeball _____	133	Lateral Region _____	178
Vessels of the Eye _____	134	Cervical and Brachial Plexuses _____	186
Extra-ocular Muscles _____	135		
Visual Pathway and Areas _____	137		
Layers of the Orbit _____	140		
Lacrimal Apparatus and Lids _____	142		



3 Trunk

187

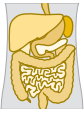Segmental Structure of the Trunk _____	187
Skeleton _____	188
Vertebrae _____	190
Vertebral Column and Thorax _____	192
Vertebral Joints _____	195
Costovertebral Joints and Intercostal Muscles _____	196
Costovertebral Joints _____	197
Ligaments _____	198
Joints Connecting to the Head _____	200
Vertebral Column of the Neck _____	203
Surface Anatomy of the Anterior Body _____	204
Female _____	204
Male _____	205
Thoracic Wall _____	206
Thoracic and Abdominal Walls _____	209
Vessels and Nerves _____	214
Inguinal Region _____	217
Male _____	217
Female _____	220
Back _____	221
Muscles _____	221
Nerves _____	226
Vertebral Canal and Spinal Cord _____	230
Nuchal Region _____	234



4 Thoracic Organs

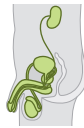243

Position of the Thoracic Organs _____	243
Respiratory System _____	246
Bronchial Tree _____	246
Projections of Lungs and Pleura _____	248
Lungs _____	249
Bronchopulmonary Segments _____	250
Heart _____	252
Myocardium _____	257
Valves _____	258
Function _____	260
Conducting System _____	261
Arteries and Veins _____	262
Regional Anatomy of the Thoracic Organs _____	264
Thymus _____	266
Heart _____	268
Pericardium _____	272
Epicardium _____	273
Posterior Mediastinum _____	274
Mediastinal Organs _____	274
Posterior and Superior Mediastinum _____	281
Mediastinal Organs _____	281
Diaphragm _____	282
Coronal Sections through the Thorax _____	284
Horizontal Sections through the Thorax _____	286
Fetal Circulatory System _____	288
Mammary Gland _____	290



5 Abdominal Organs 291

Position of the Abdominal Organs _____	291
Anterior Abdominal Wall _____	293
Stomach _____	294
Pancreas and Bile Ducts _____	296
Liver _____	298
Spleen _____	300
Upper Abdominal Organs _____	301
Vessels of the Abdominal Organs _____	302
Superior Mesenteric Vessels _____	302
Portal Circulation _____	303
Superior Mesenteric Artery _____	304
Inferior Mesenteric Artery _____	305
Dissection of the Abdominal Organs _____	306
Mesenteric Arteries _____	308
Mesentery _____	310
Upper Abdominal Organs _____	311
Posterior Abdominal Wall _____	316
Pancreas and Bile Ducts _____	316
Duodenum, Pancreas, and Spleen _____	317
Root of the Mesentery and Peritoneal Recesses _____	318
Horizontal Sections through the Abdominal Cavity _____	320
Midsagittal Sections through the Abdominal Cavity _____	322



6 Retroperitoneal Organs 323

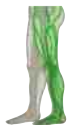Position of the Urinary Organs _____	323
Sections through the Retroperitoneal Region _____	325
Kidney _____	326
Arteries _____	328
Arteries and Veins _____	329
Retroperitoneal Region _____	330
Urinary System _____	330
Lymph Vessels and Nodes _____	332
Vessels and Nerves _____	333
Autonomic Nervous System _____	334
Male Urogenital System _____	336
Male Genital Organs (isolated) _____	337
Male External Genital Organs _____	340
Penis _____	342
Male Internal Genital Organs _____	343
Testis and Epididymis _____	343
Accessory Glands _____	344
Pelvic Cavity in the Male _____	345
Coronal Sections _____	345
Vessels of the Pelvic Organs _____	346
Abdominal Aorta _____	348
Vessels and Nerves of the Pelvic Organs _____	349
Urogenital and Pelvic Diaphragms in the Male _____	350
Female Urogenital System _____	354
Female Genital Organs (isolated) _____	356
Female Internal Genital Organs _____	358
Uterus and Related Organs _____	359
Arteries and Lymph Vessels _____	360
Female External Genital Organs _____	361
Urogenital Diaphragm and External Genital Organs in the Female _____	363
Pelvic Cavity in the Female _____	366
Coronal and Horizontal Sections _____	367



7 Upper Limb

368

Skeleton of the Shoulder Girdle and Thorax _____	368
Scapula _____	371
Skeleton of the Shoulder Girdle and Humerus _____	372
Humerus _____	373
Skeleton of the Forearm _____	374
Skeleton of the Forearm and Hand _____	375
Skeleton of the Hand _____	376
Joints and Ligaments of the Shoulder _____	378
Ligaments of the Elbow Joint _____	379
Ligaments of the Hand and Wrist _____	380
Muscles of the Shoulder and Arm _____	382
Dorsal Muscles _____	382
Pectoral Muscles _____	384
Muscles of the Arm _____	386
Muscles of the Forearm and Hand _____	388
Flexor Muscles _____	388
Extensor Muscles _____	392
Muscles of the Hand _____	394
Arteries _____	396
Veins _____	398
Nerves _____	399
Surface Anatomy of the Upper Limb _____	401
Posterior and Lateral Aspects _____	401
Anterior Aspect _____	402
Neck and Shoulder _____	403
Shoulder _____	404
Posterior Region _____	404
Anterior Region _____	406
Shoulder and Arm _____	408
Axillary Region _____	410
Brachial Plexus _____	413
Arm _____	414
Cubital Region _____	416
Forearm and Hand _____	420
Posterior Region _____	420
Anterior Region _____	422
Hand _____	424
Posterior Region _____	424
Anterior Region _____	426
Sections through the Upper Limb _____	430

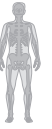

8 Lower Limb

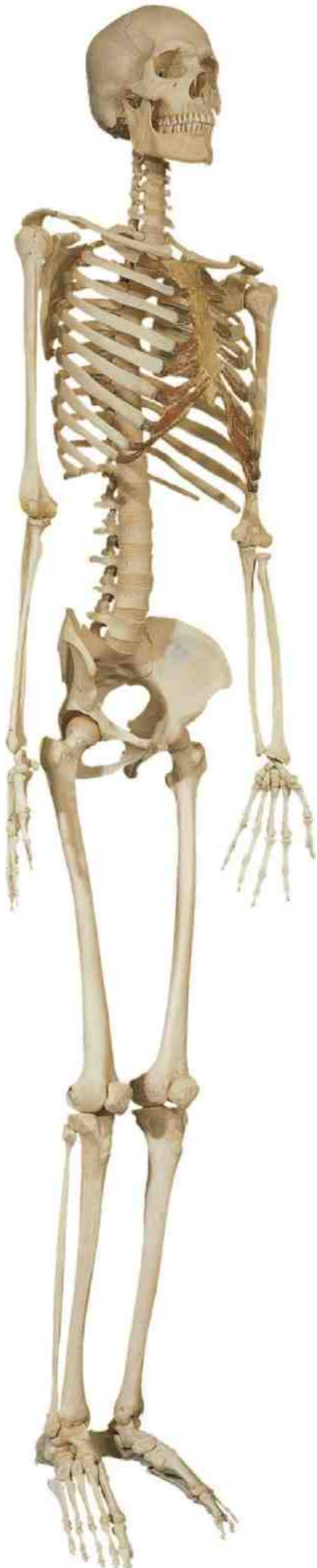432

Skeleton of the Pelvic Girdle and Lower Limb _____	432
Bones of the Pelvis _____	433
Skeleton of the Pelvis _____	435
Bones of the Hip Joint _____	438
Femur _____	439
Skeleton of the Leg _____	440
Bones of the Knee Joint _____	441
Skeleton of the Foot _____	442
Ligaments of the Pelvis and Hip Joint _____	444
Knee Joint _____	446
Ligaments of the Knee Joint _____	447
Joints of the Ankle _____	449
Ligaments of the Foot _____	450
Muscles of the Thigh _____	452
Adductor Muscles _____	452
Gluteal Muscles _____	454
Flexor Muscles _____	455
Muscles of the Leg _____	457
Flexor Muscles _____	457
Muscles of the Leg and Foot _____	458
Deep Flexor Muscles _____	460
Extensor Muscles _____	462
Muscles of the Foot _____	463
Arteries _____	466
Veins _____	468
Nerves _____	470
Lumbosacral Plexus _____	471
Lumbar Part of the Vertebral Canal and Spinal Cord _____	472
Spinal Cord with Intercostal Nerves _____	474
Spinal Cord and Lumbar Plexus _____	475
Surface Anatomy of the Lower Limb _____	476
Posterior Aspect _____	476
Anterior Aspect _____	477
Thigh _____	478
Anterior Region _____	478
Gluteal Region _____	482
Thigh _____	484
Posterior Region _____	484
Knee and Popliteal Fossa _____	486
Crural Region _____	489
Crural Region and Foot _____	492
Coronal Sections through the Foot _____	495
Sections through the Lower Limb _____	496
Foot _____	498
Posterior Region _____	498
Anterior Region _____	500

This page intentionally left blank.

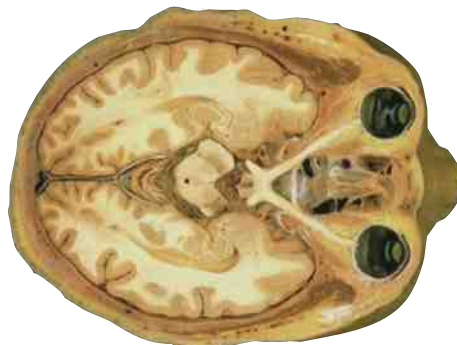


1 General Anatomy



Three general principles are recognizable in the architecture of the human organism:

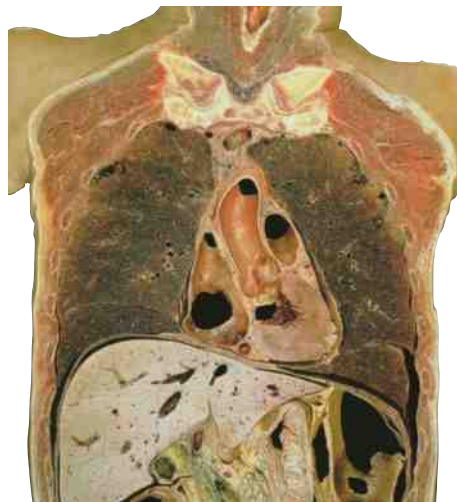
1. **The principle of polarity:** Polarity is reflected mainly in the formal and functional contrast between the head (predominantly spherical form) and the extremities (radially arranged skeletal elements). In the phylogenetic development of the upright position of the human body, polarity developed also among the extremities: The lower extremities provide the basis for locomotion whereas the upper extremities are not needed anymore for locomotion, so they can be used for gesture, manual and artistic activities.
2. **The principle of segmentation:** This principle dominates in the trunk. The anatomical structures (vertebrae, pairs of ribs, muscles, and nerves) are arranged segmentally and replicate rhythmically in a similar way.
3. **The principle of bilateral symmetry:** Both sides of the body are separated by a midsagittal plane and resemble each other like image and mirror-image.



Horizontal section through the head at the level of the eyes.

There are also different principles in the architecture and function of the inner organs:

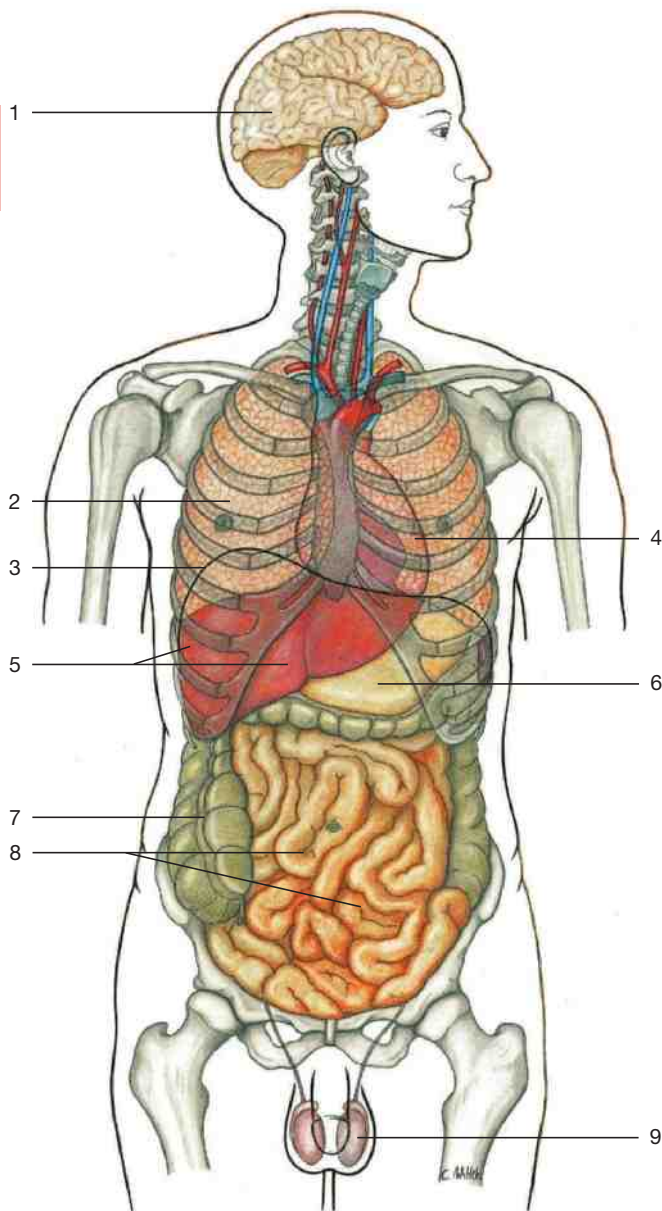
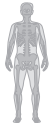The **skull** contains the brain and the sensory organs. They are arranged like mirror and mirror-image and are the basis of our consciousness.



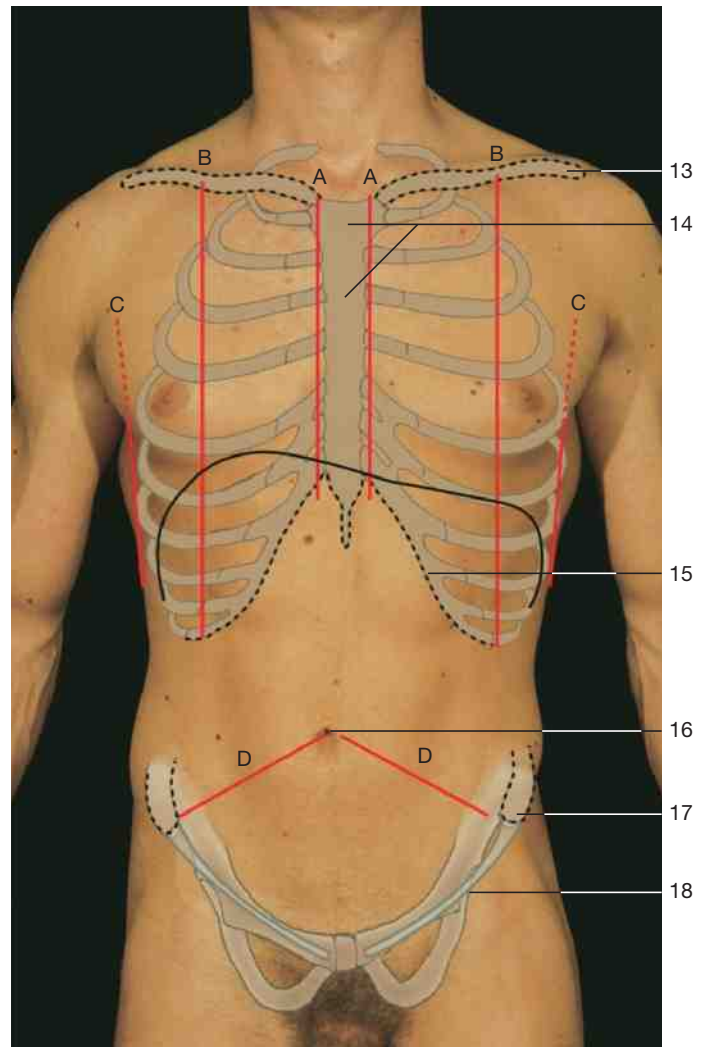
Coronal section through the thoracic and abdominal cavity.

The **thorax** contains the organs of the rhythmic system (heart, lung), which are only to some extent bilaterally organized. The consciousness (feeling, etc.) is located in-between.

In the **abdominal cavity**, the most important abdominal organs (intestinal tract, liver, pancreas) are arranged unpaired. Their functions remain subconscious.



Position of the inner organs of the human body (anterior aspect). The main cavities of the body and their contents.



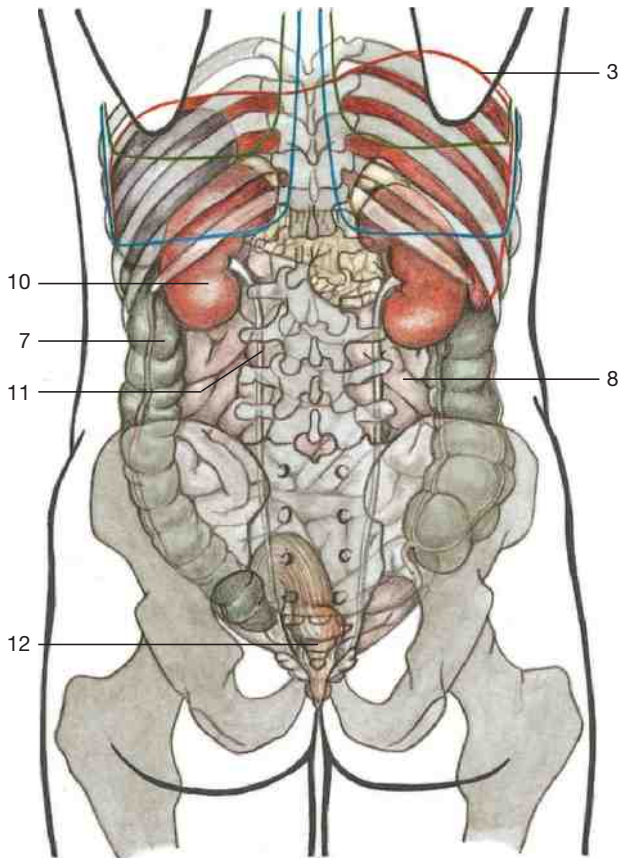
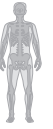Regional lines and palpable points at the ventral side of the human body.

Regional lines

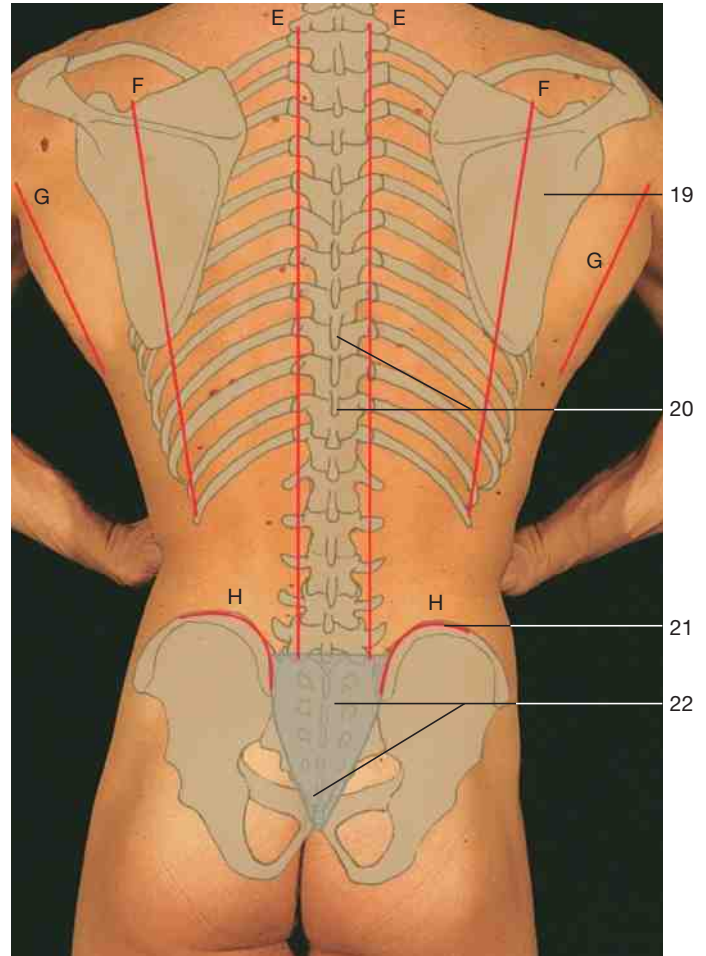
- A = parasternal line
- B = midclavicular line
- C = anterior axillary line
- D = umbilical-pelvic line

The bones of the skeletal system are palpable through the skin at different points. This enables physicians to localize the inner organs. On the **ventral side**, the clavicle, sternum, ribs, and intercostal spaces are palpable. Furthermore, the anterior iliac spine and the symphysis can be

localized. For better orientation, several **lines of orientation** are used, e.g., the parasternal line, the midclavicular line, the anterior axillary line, the umbilical-pelvic line. By means of these lines, the heart and the position of the vermiform process can be localized.



Position of the inner organs of the human body (posterior aspect).



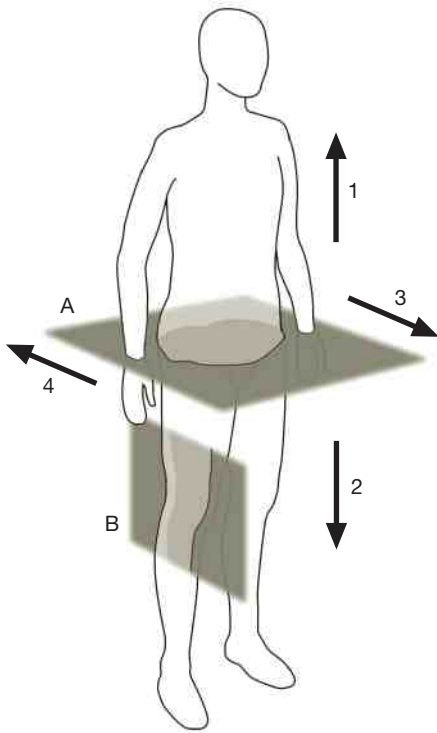
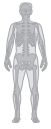Regional lines and palpable points at the dorsal side of the human body.

Regional lines

- E = paravertebral line
- F = scapular line
- G = posterior axillary line
- H = iliac crest

- 1 Brain
- 2 Lung
- 3 Diaphragm
- 4 Heart
- 5 Liver
- 6 Stomach
- 7 Colon
- 8 Small intestine
- 9 Testis
- 10 Kidney
- 11 Ureter
- 12 Anal canal
- 13 Clavicle
- 14 Manubrium sterni
- 15 Costal arch
- 16 Umbilicus
- 17 Anterior superior iliac spine
- 18 Inguinal ligament
- 19 Scapular spine
- 20 Spinous processes
- 21 Iliac crest
- 22 Coccyx and sacrum

At the **dorsal side** of the body, the posterior spines of the vertebral column, the ribs, the scapula, the sacrum, and the iliac crest are palpable. **Lines of orientation** are the paravertebral line, the scapular line, the posterior axillary line, and the iliac crest.

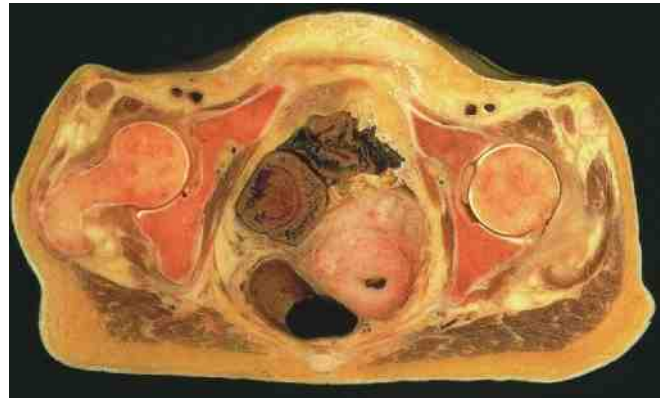

Planes of the body:

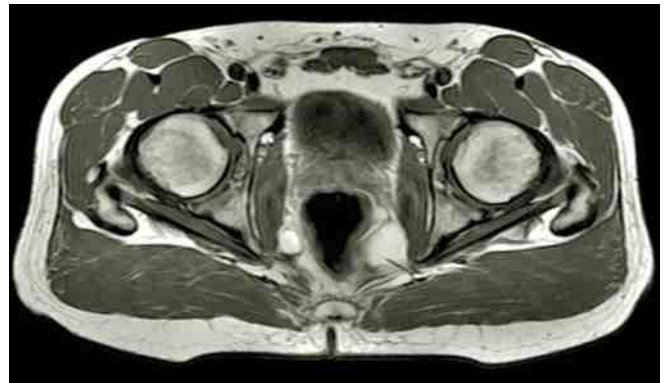A = horizontal or axial or transverse plane
B = sagittal plane (at the level of the knee joint)

Directions:

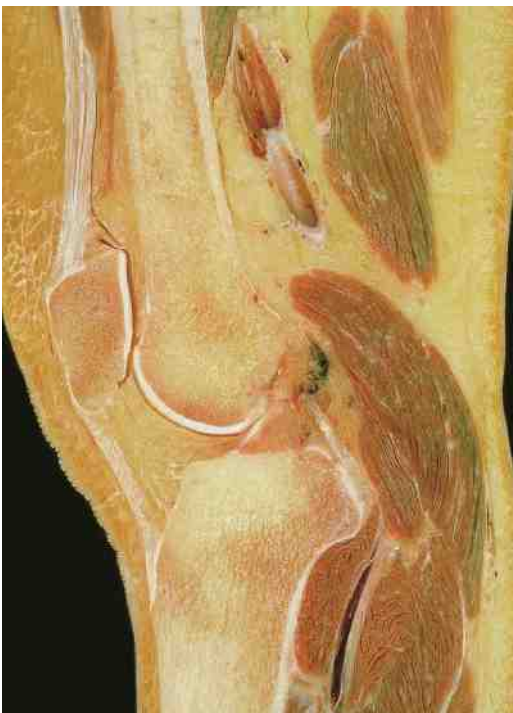1 = cranial 3 = anterior (ventral)
2 = caudal 4 = posterior (dorsal)



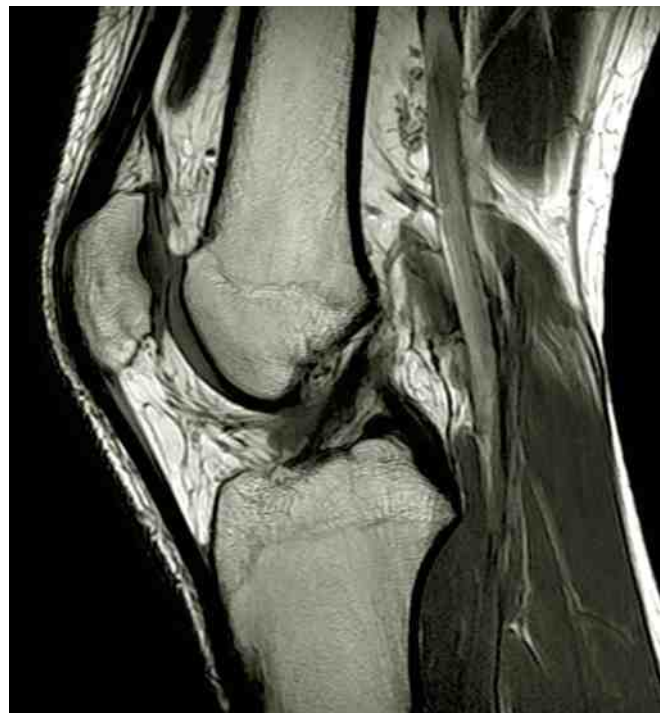Horizontal section through the pelvic cavity and the hip joints.



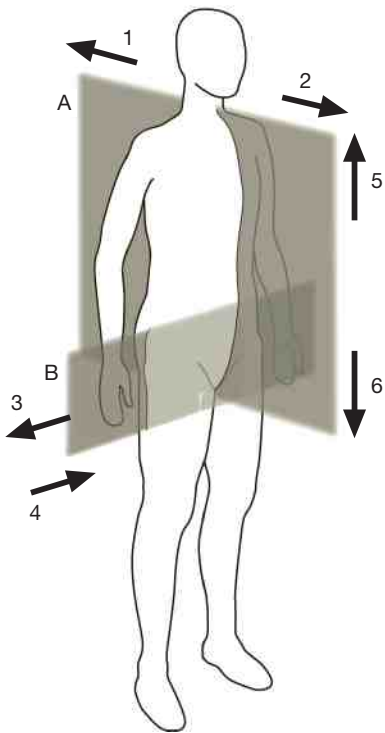
MRI scan through the pelvic cavity and the hip joints (horizontal or axial or transverse plane).



Sagittal section through the knee joint.



MRI scan through the knee joint (sagittal plane).



Planes of the body:

A = midsagittal or median plane

B = frontal or coronal plane (through the pelvic cavity)

Directions:

1 = posterior (dorsal)

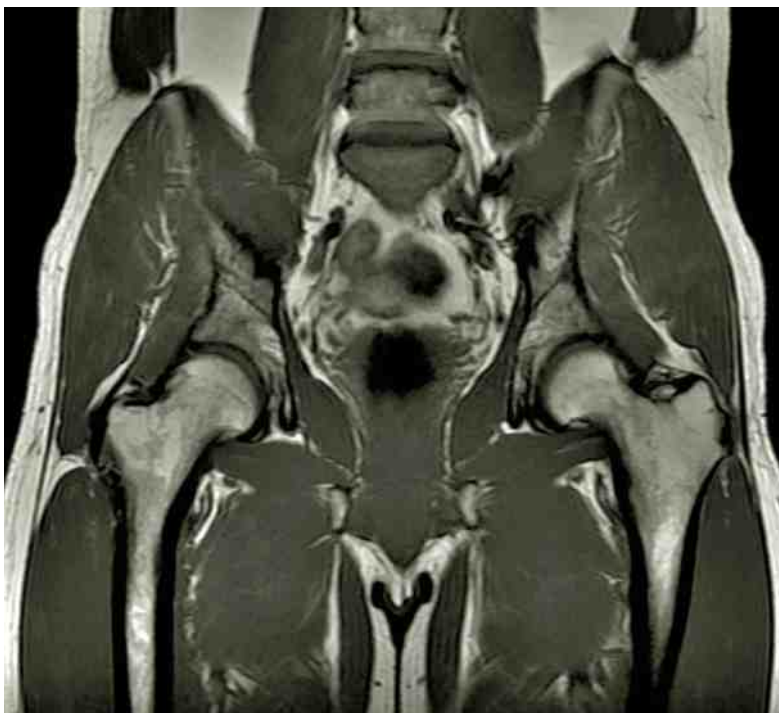4 = medial

2 = anterior (ventral)

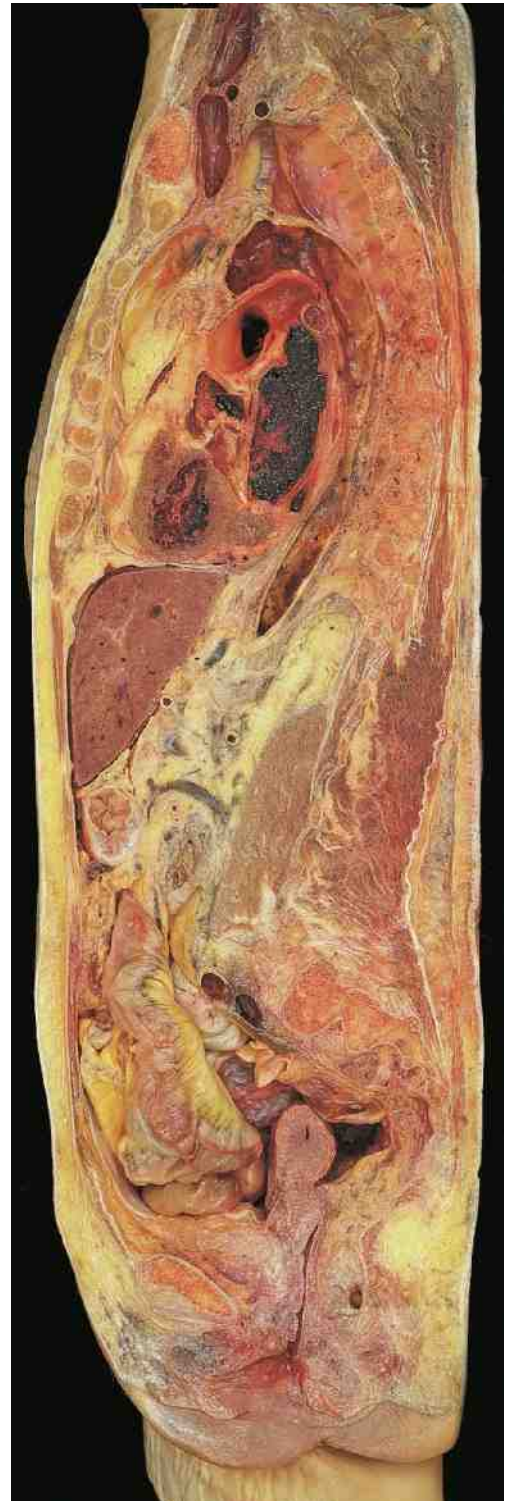
5 = cranial

3 = lateral

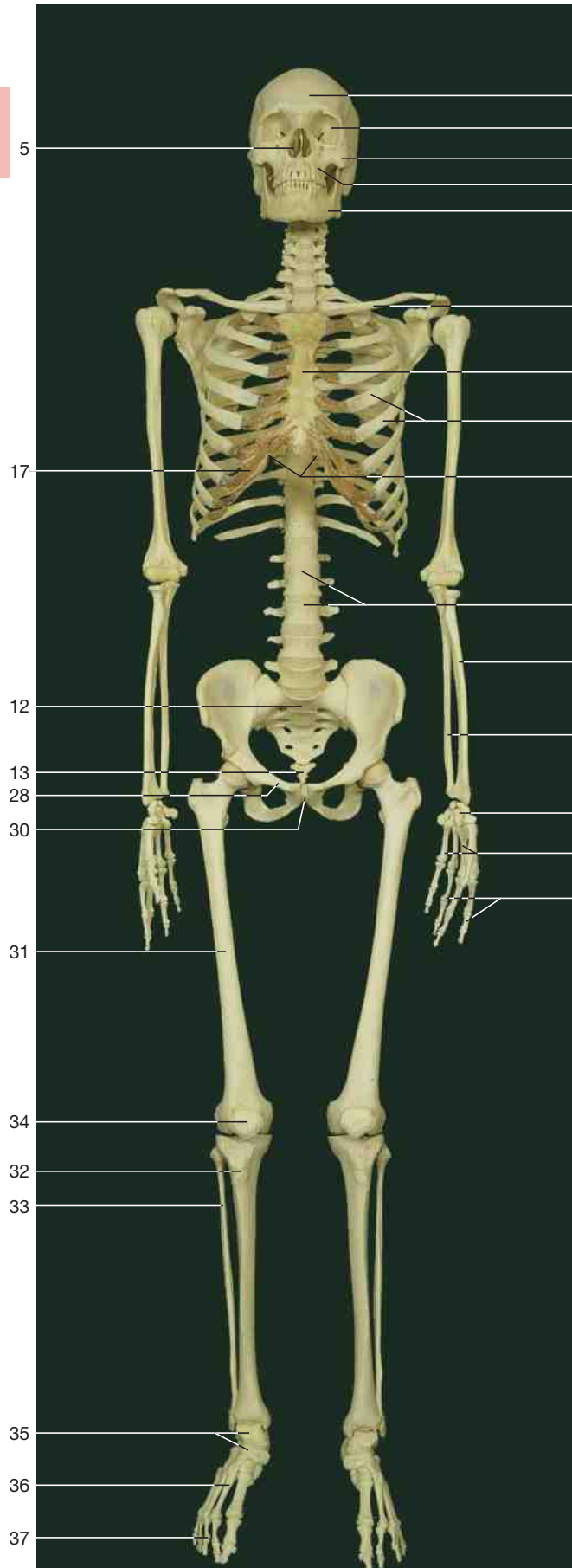
6 = caudal



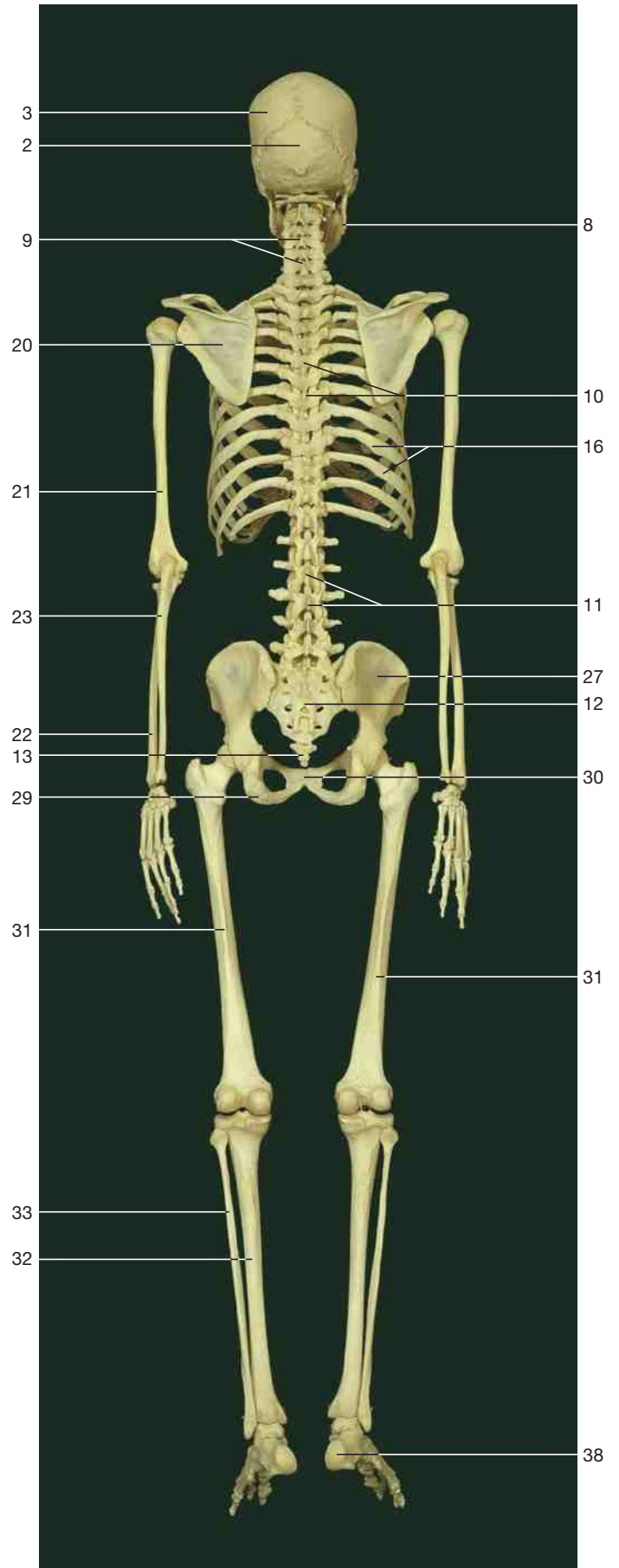
MRI scan through the pelvic cavity and the hip joints (frontal or coronal plane).



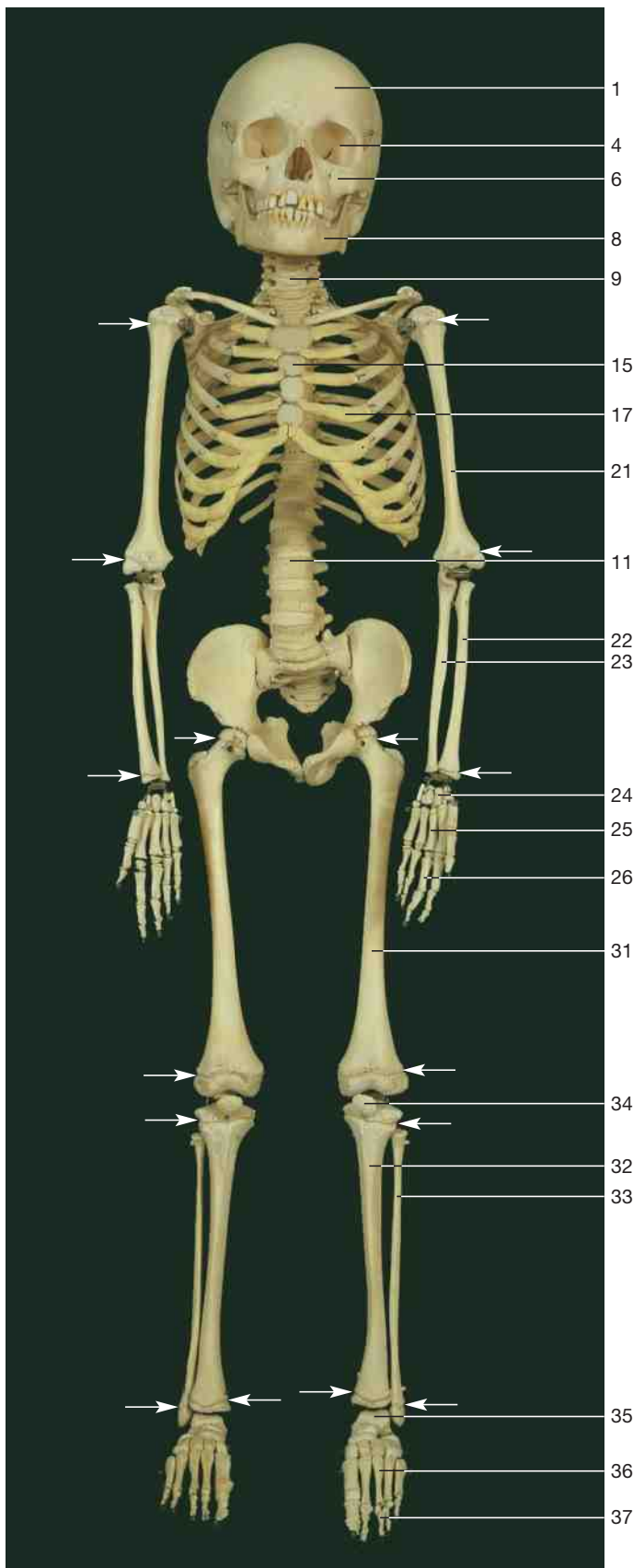
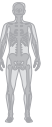Median section through the trunk of a female.



Skeleton of a female adult (anterior aspect).



Skeleton of a female adult (posterior aspect).

**Axial skeleton****Head**

- 1 Frontal bone
- 2 Occipital bone
- 3 Parietal bone
- 4 Orbit
- 5 Nasal cavity
- 6 Maxilla
- 7 Zygomatic bone
- 8 Mandible

Trunk and thorax**Vertebral column**

- 9 Cervical vertebrae
- 10 Thoracic vertebrae
- 11 Lumbar vertebrae
- 12 Sacrum
- 13 Coccyx
- 14 Intervertebral discs

Thorax

- 15 Sternum
- 16 Ribs
- 17 Costal cartilage
- 18 Infrasternal angle

Appendicular skeleton**Upper limb and shoulder girdle**

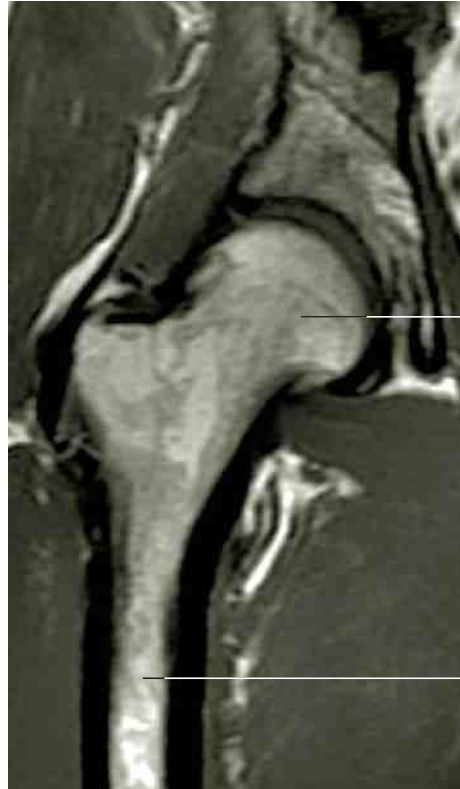
- 19 Clavicle
- 20 Scapula
- 21 Humerus
- 22 Radius
- 23 Ulna
- 24 Carpals bones
- 25 Metacarpal bones
- 26 Phalanges of the hand

Lower limb and pelvis

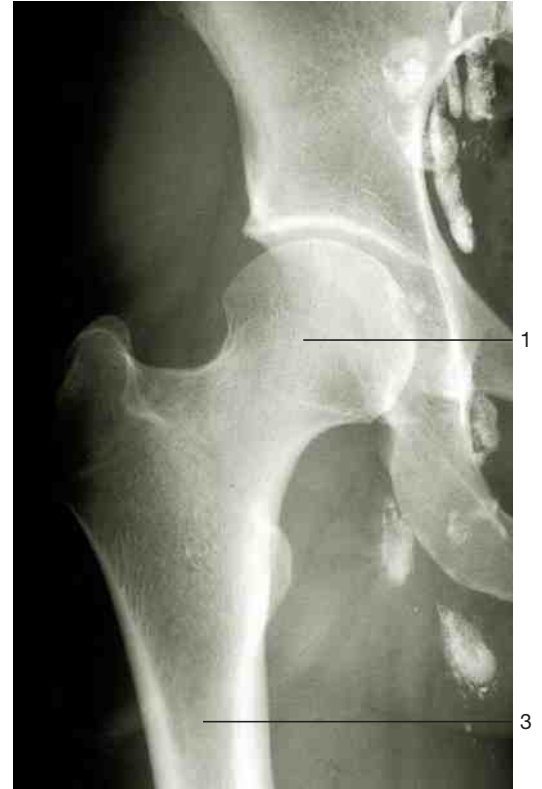- 27 Ilium
- 28 Pubis
- 29 Ischium
- 30 Symphysis pubis
- 31 Femur
- 32 Tibia
- 33 Fibula
- 34 Patella
- 35 Tarsal bones
- 36 Metatarsal bones
- 37 Phalanges of the foot
- 38 Calcaneus

Skeleton of a 5-year-old child (anterior aspect).

The zones of the cartilaginous growth plates are seen (arrows). In contrast to the adult, the ribs show a predominantly horizontal position.



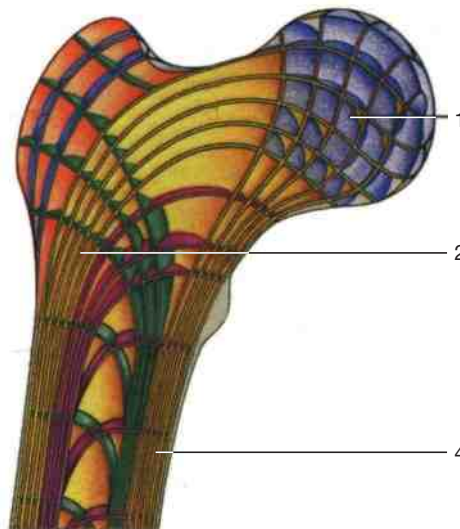
MRI scan of the right femur and the hip joint (coronal section) (from Heuck et al., MRT-Atlas, 2009).



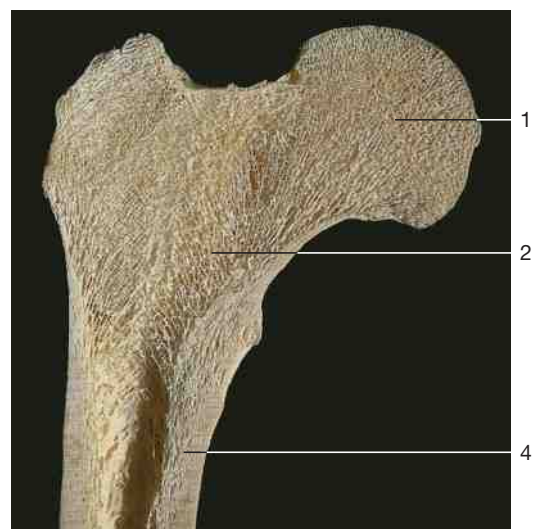
X-ray of the right femur and the hip joint (a.-p. direction).

◁ **Femur of the adult.** Coronal section of the proximal and distal epiphyses displaying the spongy bone and the medullary cavity.

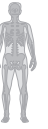- 1 Head of the femur
- 2 Spongy bone
- 3 Diaphysis of the femur
- 4 Compact bone
- 5 Articular cartilage



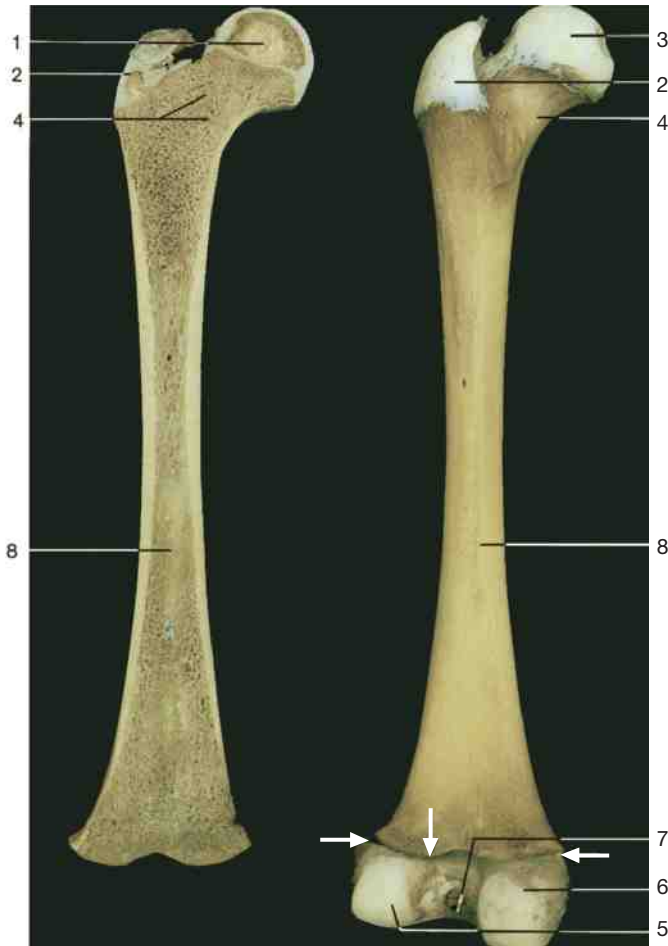
Three-dimensional representation on the trajectorial lines of the femoral head (according to B. Kummer).



Coronal section through the proximal end of the adult femur showing the characteristic structure of the spongy bone.

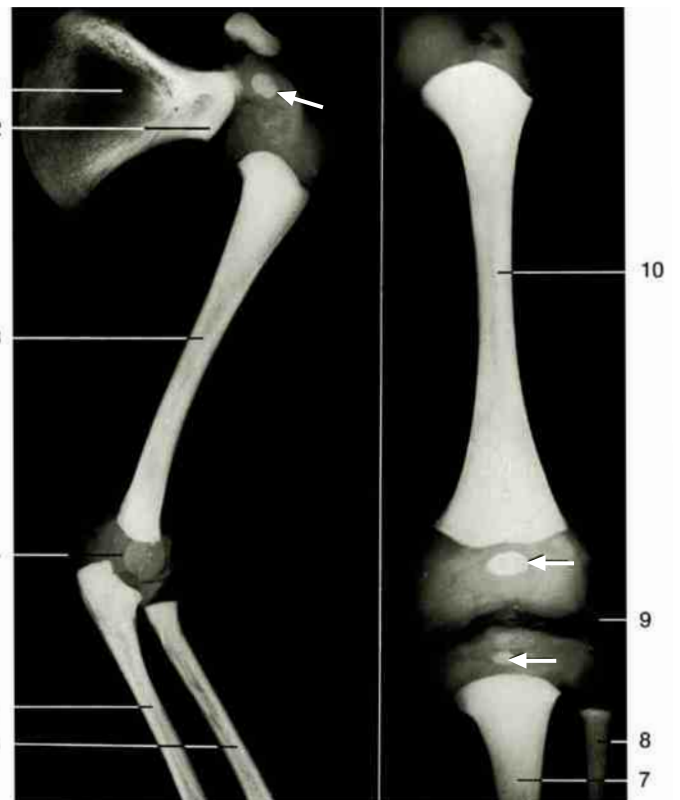


The **ossification of the bones** of the limbs starts within the ossification centers of the primary cartilagenous bones. Here, the medullary cavity develops. The ossification process of limb bones is not finished at birth.



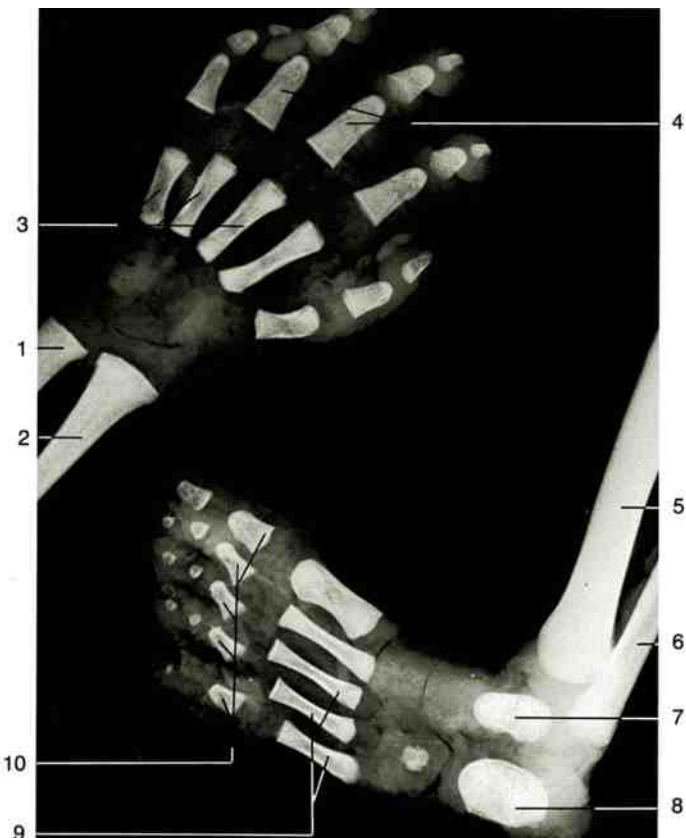
- 1 Ossification center in the head of the femur
- 2 Greater trochanter
- 3 Head of the femur
- 4 Neck of the femur
- 5 Lateral condyle
- 6 Medial condyle
- 7 Intercondylar notch
- 8 Diaphysis

Ossification of the femur (left: coronal section, right: posterior view of the femur). Arrows: distal epiphysis.



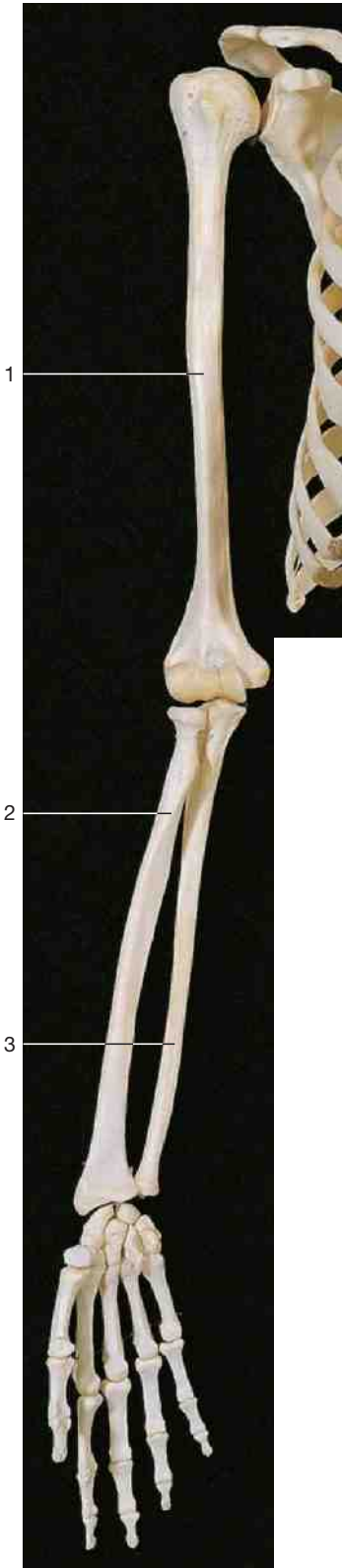X-ray of the upper and lower limb of a newborn child (left: upper limb, right: lower limb). Arrows: ossification centers.

- 1 Scapula
- 2 Shoulder joint
- 3 Humerus
- 4 Elbow joint
- 5 Ulna
- 6 Radius
- 7 Tibia
- 8 Fibula
- 9 Knee joint
- 10 Femur

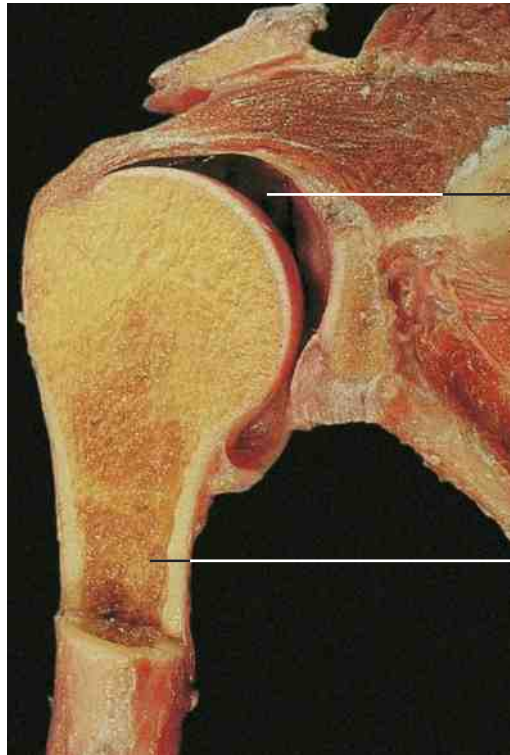


- 1 Ulna
- 2 Radius
- 3 Metacarpals
- 4 Phalanges
- 5 Tibia
- 6 Fibula
- 7 Talus
- 8 Calcaneus
- 9 Metatarsals
- 10 Phalanges

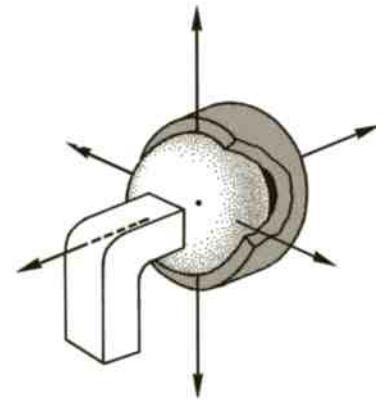
X-ray of hand and foot of a newborn.



Skeleton of the right arm and shoulder girdle (anterior aspect).

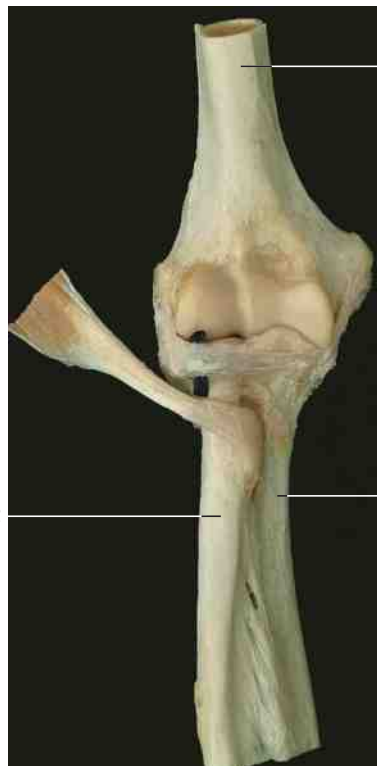

Shoulder joint as an example of a multiaxial ball-and-socket joint (coronal section).

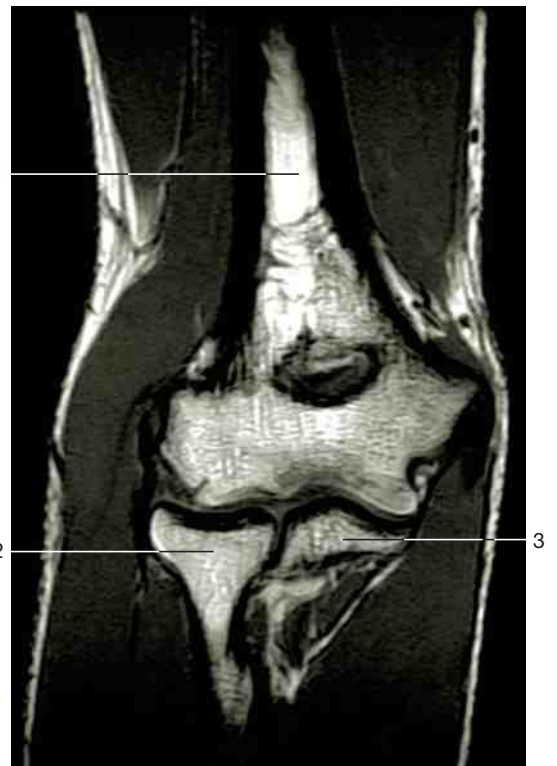

Ball-and-socket joint with its different axes (schematic drawing). Arrows: axes of movement.

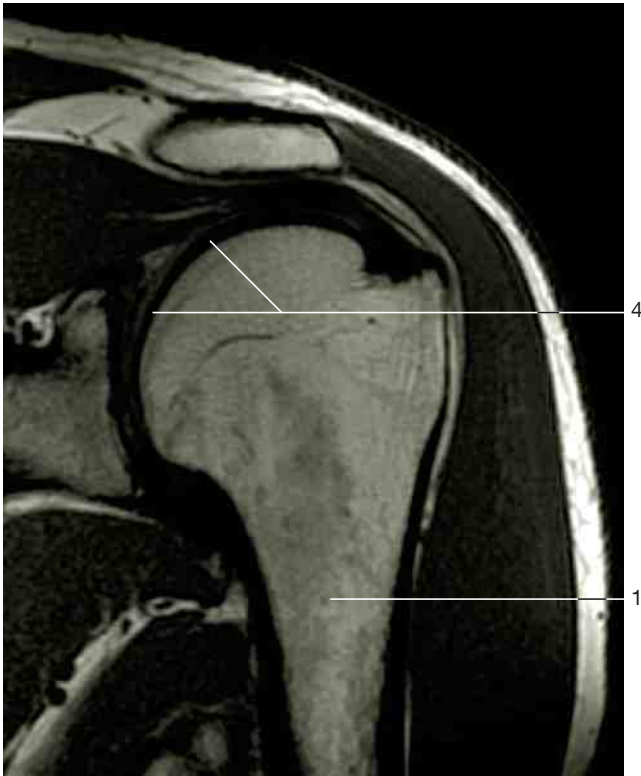
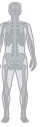- 1 Humerus
- 2 Radius
- 3 Ulna
- 4 Articular cavity (shoulder joint)
- 5 Metacarpophalangeal joint
- 6 Joints of fingers



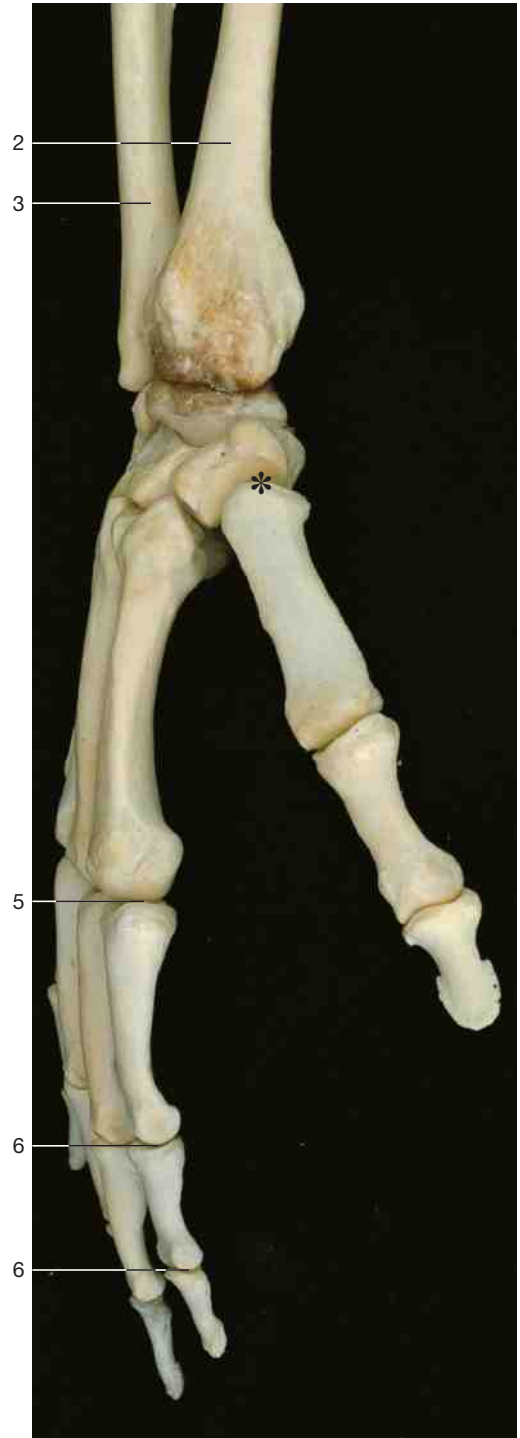Elbow joint with ligaments as an example of a hinge joint (monaxial humero-ulnar joint) in combination with a pivot joint (monaxial radio-ulnar joint), which allows rotation.



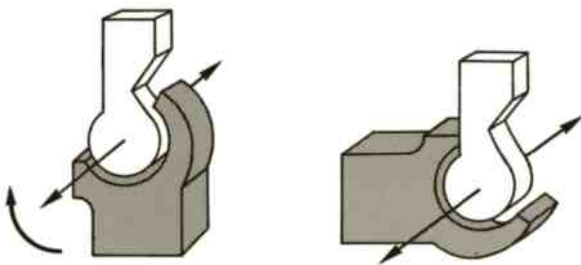
Coronal section of the elbow joint (MRI scan, courtesy of Prof. Heuck, Munich). The possibilities of movement are shown in the schematic drawings on p. 11.



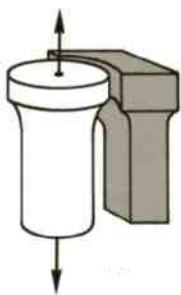Coronal section of the shoulder joint
(MRI scan, from Heuck et al., MRT-Atlas, 2009).



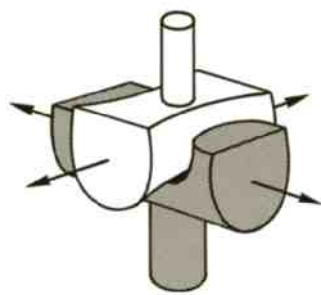
Skeleton of right wrist and hand (medial aspect).
The metacarpophalangeal joints are biaxial, as is the carpometacarpal joint of the thumb (* in the figure). The joints of the fingers, however, are monaxial.



Hinge joint
(e.g. humero-ulnar joint). Left: extension, right: flexion.
Arrows: axes of movement.

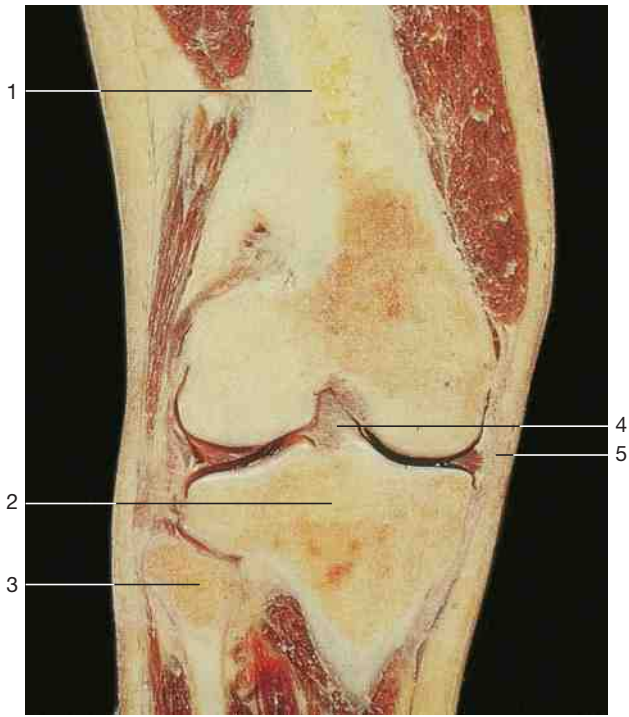


Pivot joint
(e.g. radio-ulnar joint).

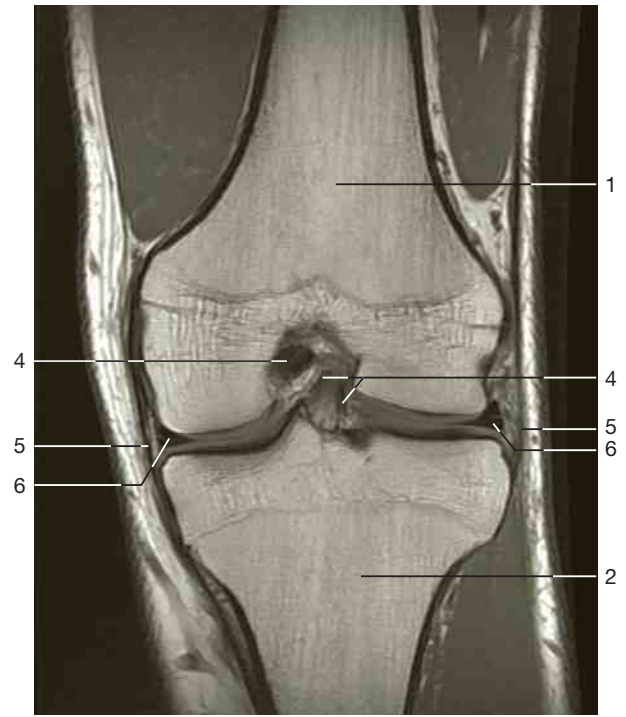


Saddle joint
(e.g. carpometacarpal joint of the thumb).

Joints exhibit a variety of functions. In general, mobility becomes reduced in the direction from proximal to distal. The hip joint, e.g., is multiaxial; the knee joint is biaxial, and the joints of toes and fingers are monaxial.

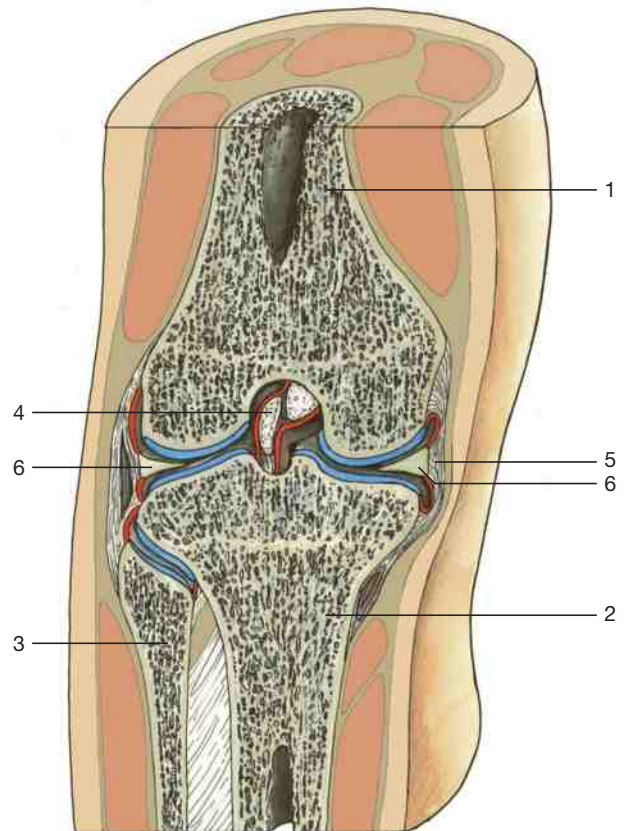


Coronal section through the knee joint (anterior aspect of the right joint in extension).



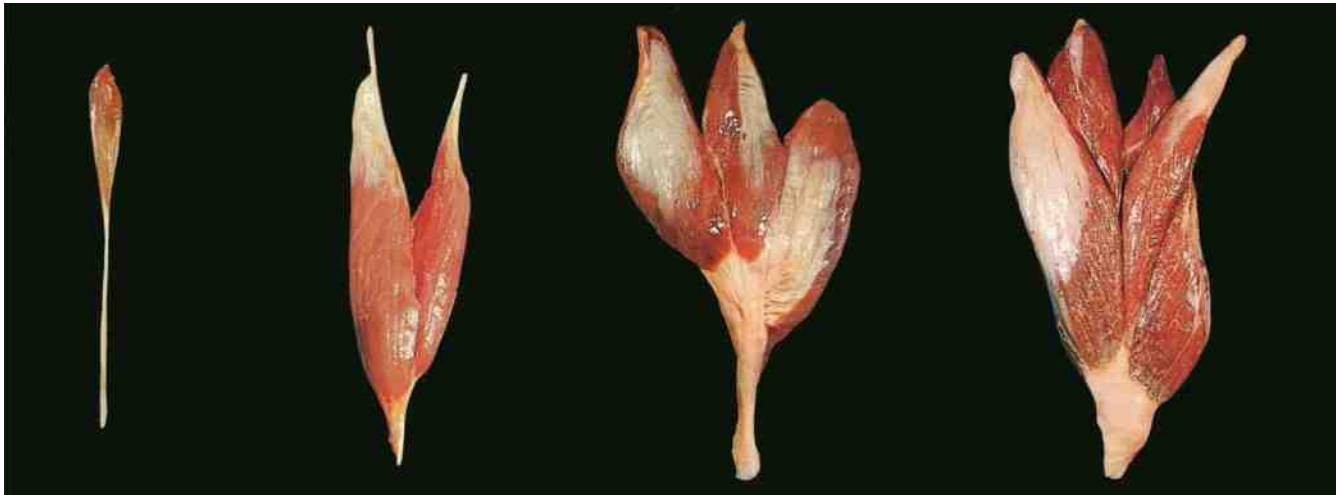MRI scan of the knee joint (coronal plane) (from Heuck et al., MRT-Atlas, 2009).

- 1 Femur
- 2 Tibia
- 3 Fibula
- 4 Cruciate ligaments
- 5 Collateral ligaments
- 6 Meniscus



Schematic drawing of the knee joint as an example of a synovial joint, characterized by a joint cavity enclosed by a joint capsule (red) containing synovial fluid. Blue = articular cartilage.

Joints are places of articulation allowing movements between bones. Synovial joints are characterized by a joint cavity enclosed by a joint capsule containing synovial fluid, which is produced by the articular capsule. The kind of movements depends not only on form and structure of the articulating bones but also on ligaments incorporated into the articular capsule. In some synovial joints, fibrocartilagenous articular discs develop, when the articulating surfaces of the bones are incongruous.

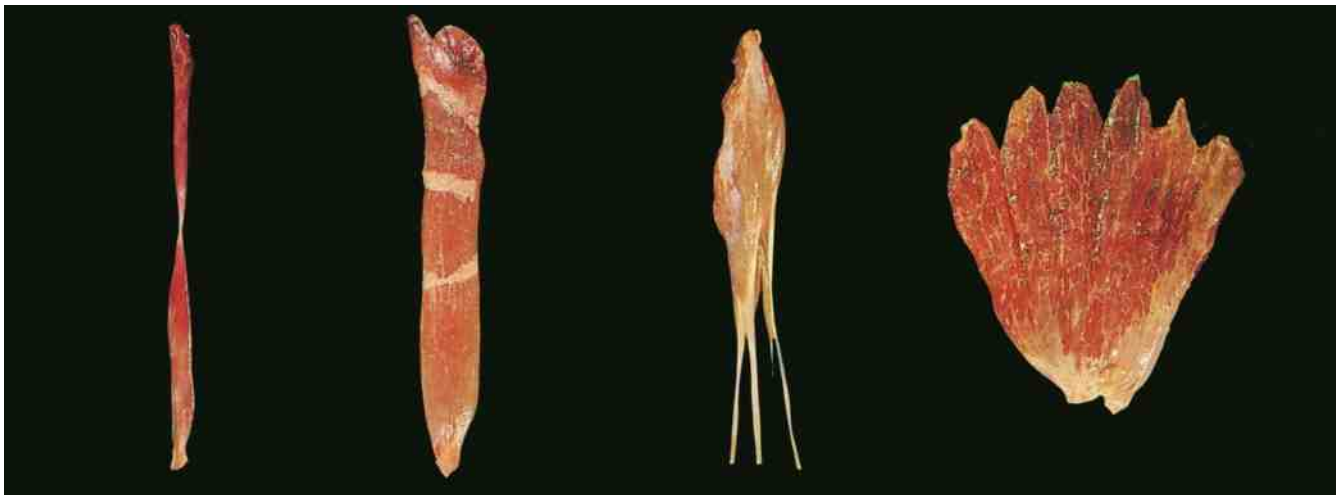

Fusiform
(palmaris longus)

Bicipital
(biceps brachii)

Tripital (triceps surae,
gastrocnemius, and soleus)

Quadricipital
(quadriceps femoris)



Digastric
(omohyoideus)

Multiventral
(rectus abdominis)

Multicaudal
(flexor digitorum prof.)

Serrated
(serratus anterior)



Bipennate
(tibialis anterior)

Unipennate
(semimembranosus)

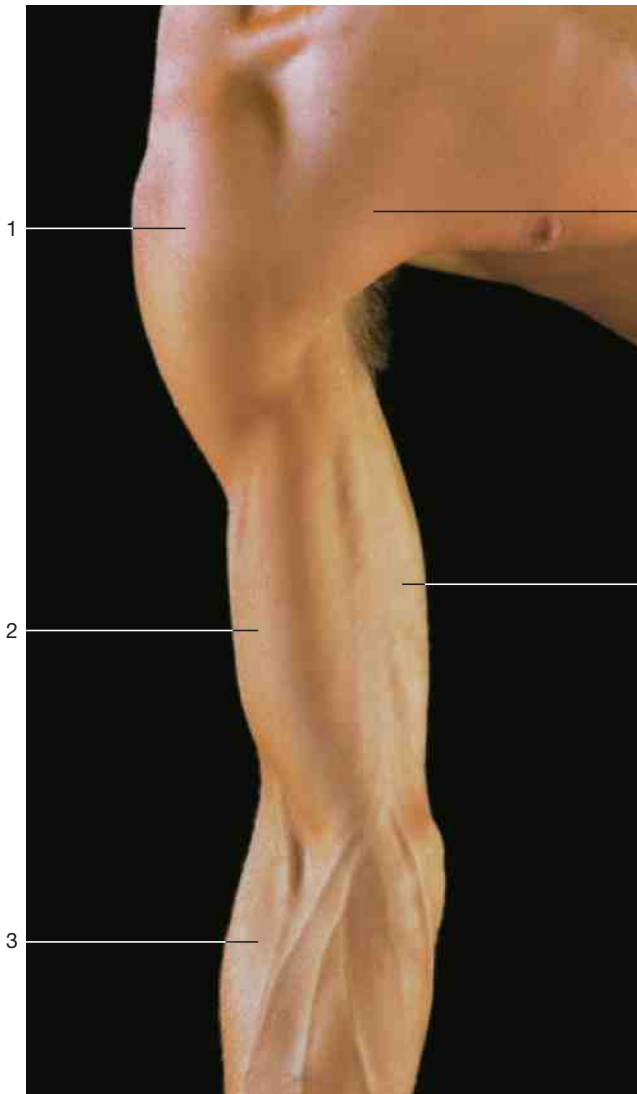
Semitendinous
(semitendinosus)

Broad, flat muscle
(latissimus dorsi)

Ring-like
(sphincter ani externus)

The human body possesses a **great variety of muscles**. The architecture of the muscles depends on the functional systems in which they are involved, i.e., the kind of move-

ments, the form of the joints with their specific ligaments, etc. The movements themselves vary to a great extent individually.



Ventral aspect of the right arm. The biceps muscle appears slightly contracted. In the area of the elbow joint, several subcutaneous veins can be recognized.

- 1 Deltoid muscle
- 2 Biceps brachii muscle
- 3 Brachioradialis muscle
- 4 Humerus
- 5 Triceps brachii muscle
- 6 Elbow joint
- 7 Brachialis muscle
- 8 Pectoralis major muscle
- 9 Radius
- 10 Ulna

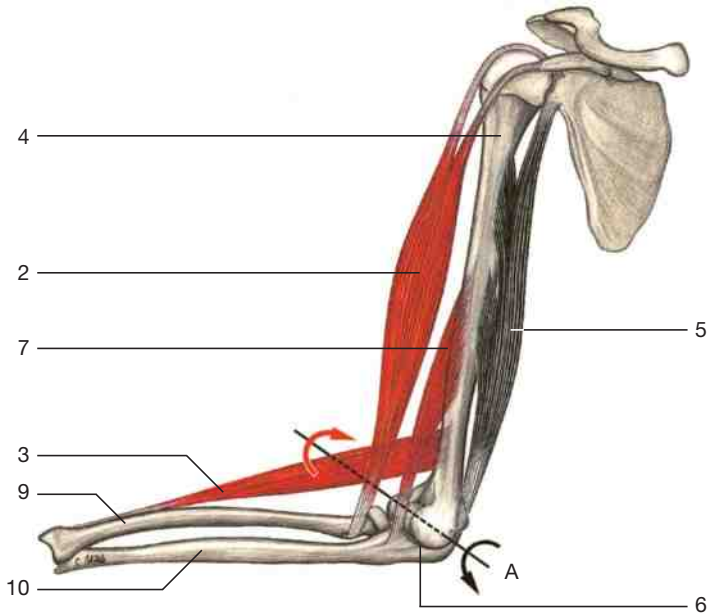
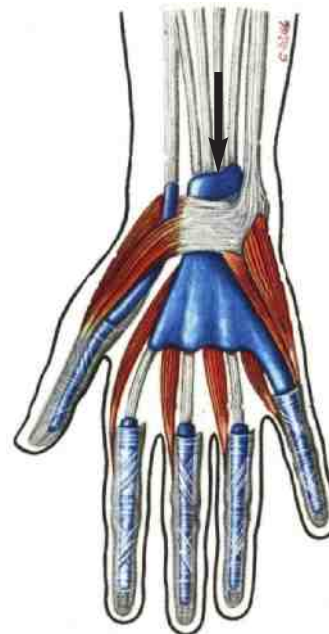


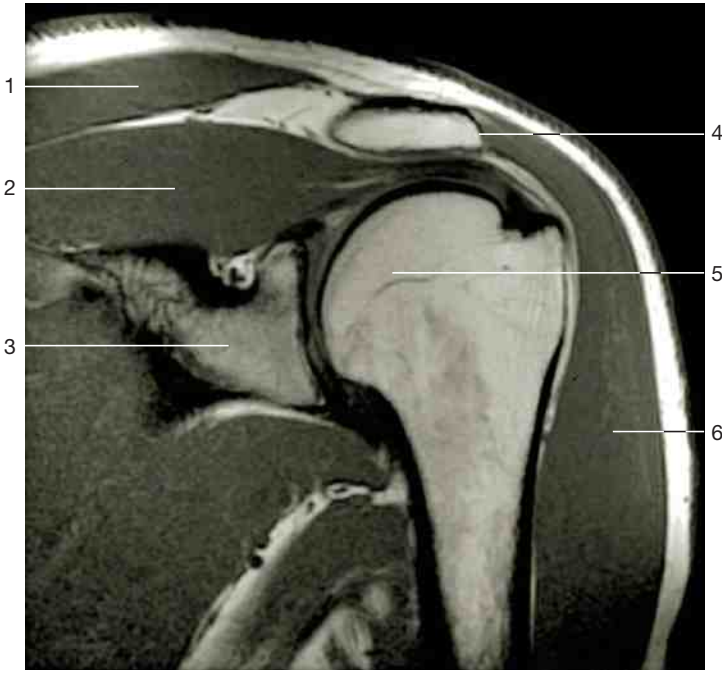
Diagram illustrating the position of the flexor and extensor muscles of the arm and their effect on the elbow joint. A = axis of humero-ulnar joint; arrows = direction of movements; red = flexion; black = extension.



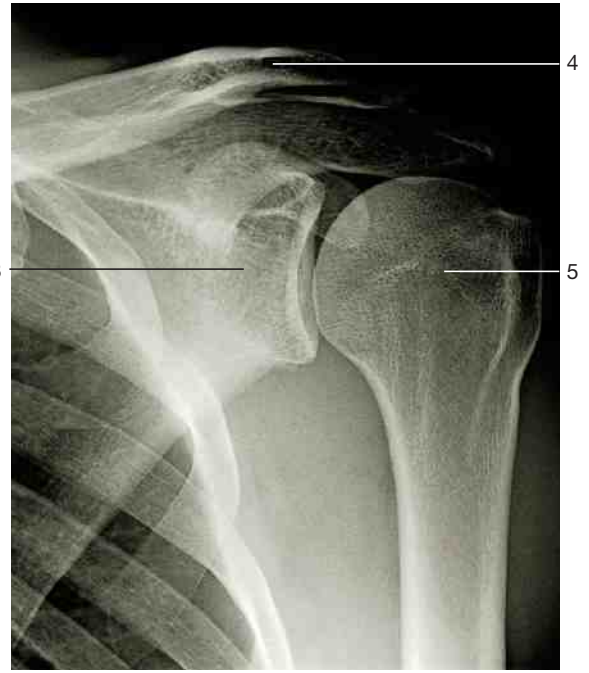Synovial sheaths of flexor tendons (palmar aspect of right hand, semischematic drawing). The **flexor retinaculum** protects the flexor tendons passing through the carpal tunnel (arrow).

Joints are moved by muscles. The highly differentiated movements are coordinated by special groups of muscles (**synergists**). Their counterparts are called **antagonists**. Movements can only be carried out harmoniously if the contraction of the synergists are supported by a corresponding dilatation of the antagonists. This interaction is

controlled by the nervous system. In order to carry out certain directions of movements, often the tendons of muscles have to be directed by ligaments. At those places, the tendons often develop synovial sheaths, e.g., at the wrist joint or at the fingers.

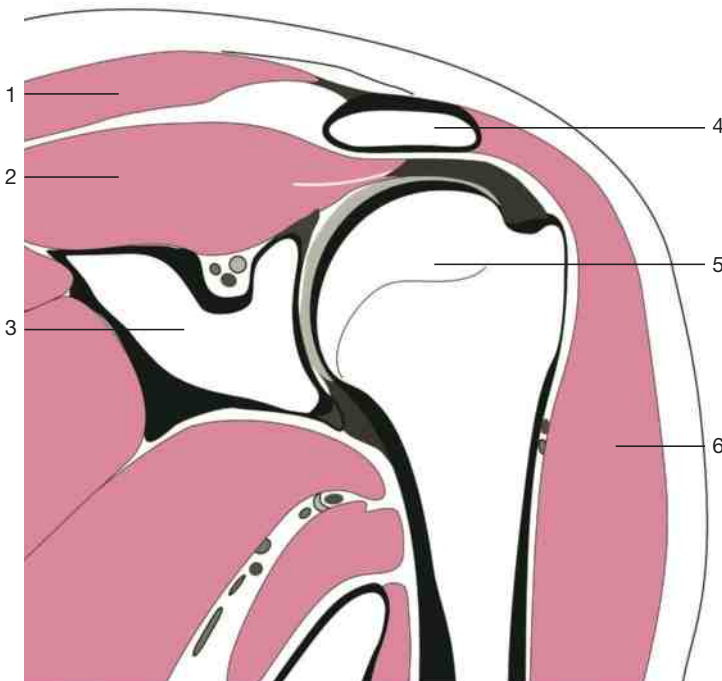


Shoulder joint (MRI scan, coronal section) (from Heuck et al., MRT-Atlas, 2009).

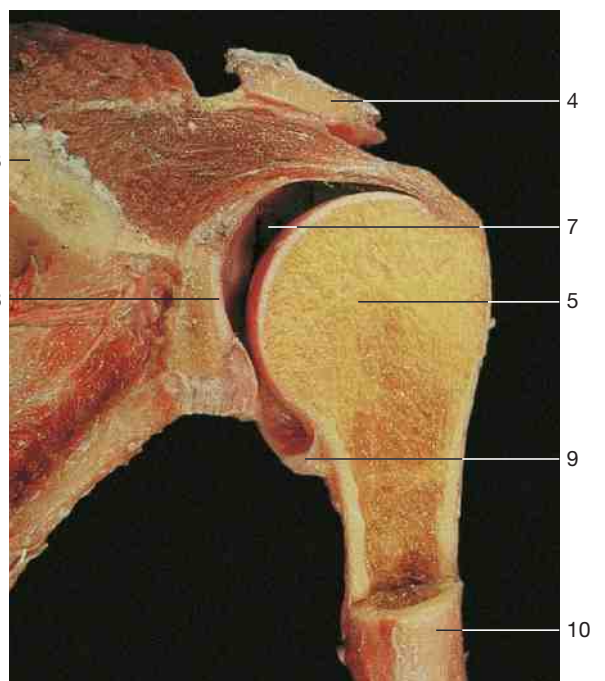


Shoulder joint (X-ray, a.-p. direction) (courtesy of Dr. Holik, Spardorf).

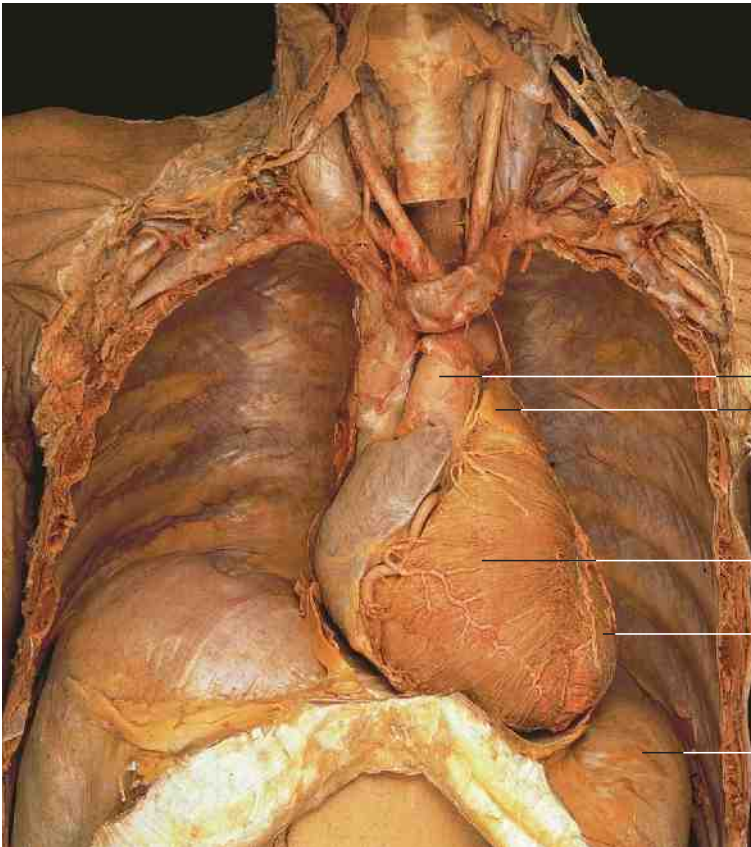
- | | |
|------------------------|----------------------------|
| 1 Trapezius muscle | 6 Deltoid muscle |
| 2 Supraspinatus muscle | 7 Cavity of shoulder joint |
| 3 Scapula | 8 Articular cartilage |
| 4 Acromion | 9 Articular cavity |
| 5 Head of humerus | 10 Humerus |



Shoulder joint (schematic drawing of the MRI scan above) (from Heuck et al., MRT-Atlas, 2009).

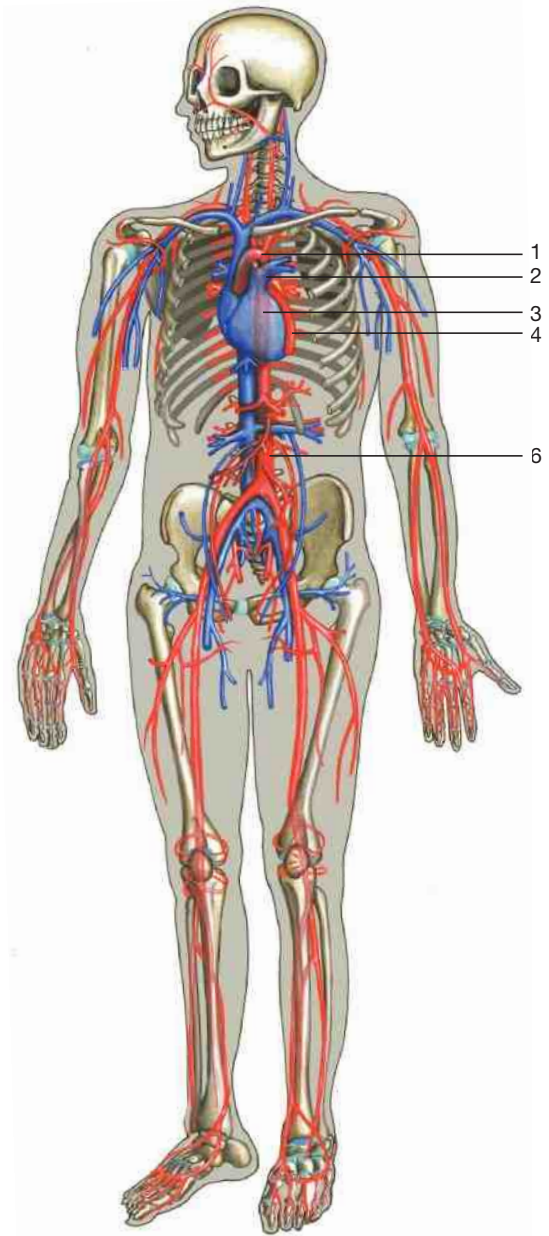


Frontal section of the shoulder joint (compare with the two pictures above).

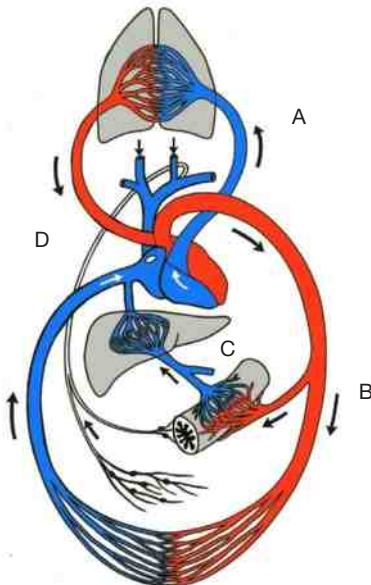


Heart and related vessels in situ (anterior aspect). Anterior thoracic wall, pericardium, and epicardium have been removed. The trachea is divided.

- | | |
|--------------------|-------------------|
| 1 Aorta | 4 Left heart |
| 2 Pulmonary artery | 5 Diaphragm |
| 3 Right heart | 6 Abdominal aorta |



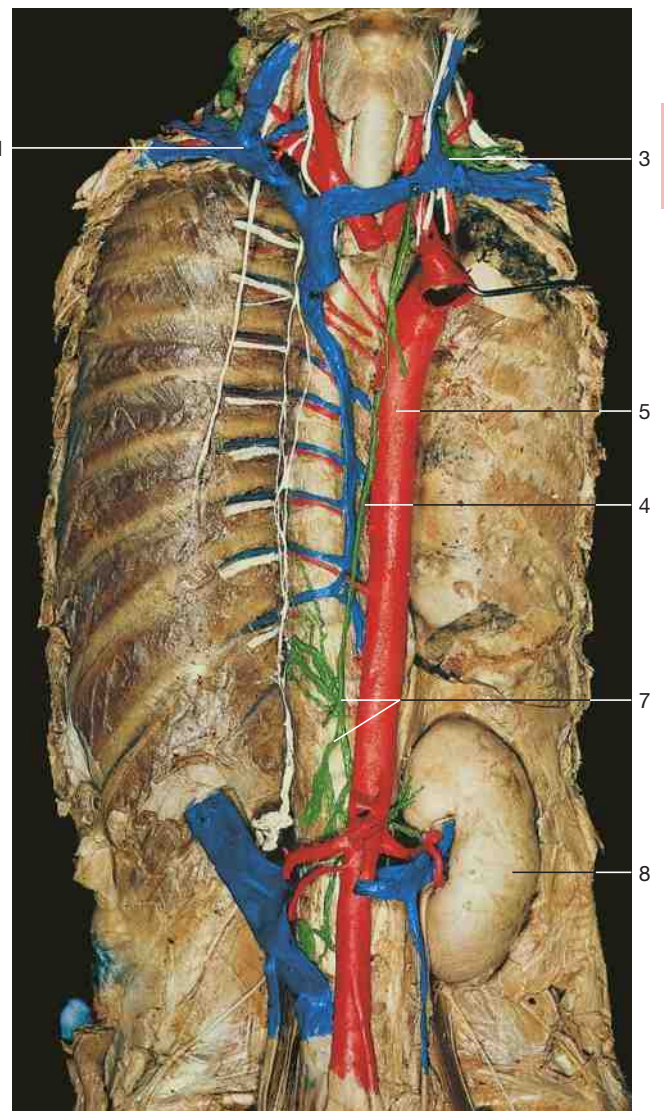
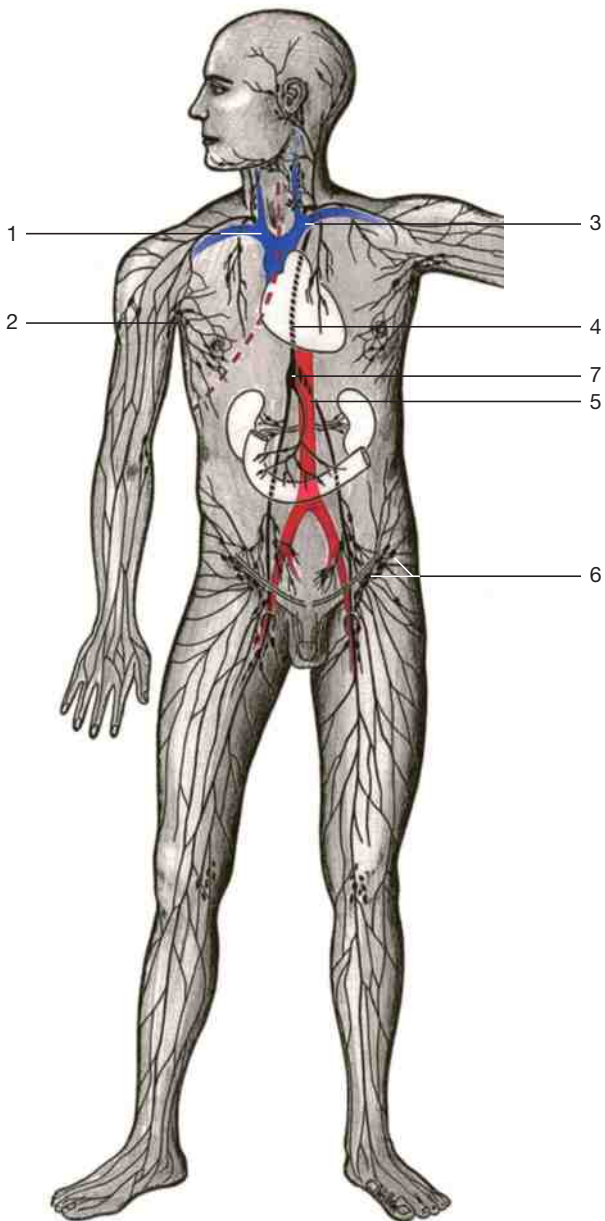
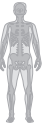Organization of the circulatory system with the heart in the center. Red = arteries; blue = veins (from Lütjen-Drecoll, Rohen, Innenansichten des menschlichen Körpers, 2010).



Organization of the circulatory systems in the human body. The center of this system represents the heart. Red = arteries; blue = veins (from Lütjen-Drecoll, Rohen, Innenansichten des menschlichen Körpers, 2010).

- | | |
|---------------------------|---------------------------|
| A = pulmonary circulation | C = portal circulation |
| B = systemic circulation | D = lymphatic circulation |

The center of the circulatory system is the heart, which is situated in the thoracic cavity and in contact with the diaphragm. In the right ventricle, the venous blood is collected and pumped through the pulmonary artery and into the lung where the blood is oxygenated. The veins of the lung transport the blood to the left ventricle, where it is pumped through the aorta and its branches (arteries) in the human body. Arteries and veins mostly run parallel. The venous blood from the intestine reaches the liver via the portal vein.



Major lymph vessels of the trunk (green). Blue = veins, red = arteries, white = nerves.

Organization of the lymphatic system.

Course of the main lymphatic vessels and lymph nodes in the body. Dotted red line = border between lymphatic vessels draining toward the right and the left venous angles.

- 1 Right venous angle
- 2 Axillary lymph nodes
- 3 Left venous angle
- 4 Thoracic duct
- 5 Aorta
- 6 Inguinal lymph nodes
- 7 Cisterna chyli
- 8 Left kidney

Lymphatic vessels originate in the tissue spaces (lymph capillaries) and unite to form larger vessels (lymphatics). These resemble veins but have a much thinner wall, more valves, and are interrupted by lymph nodes at various intervals. Large groups of lymph nodes are located in the inguinal and axillary regions, deep to the mandible and

sternocleidomastoid muscle, and within the root of the mesentery of the intestine. The lymphatic vessels of the right half of the head and neck, the right thorax, and the right upper limb drain toward the right venous angle; those of the rest of the body, toward the left venous angle.

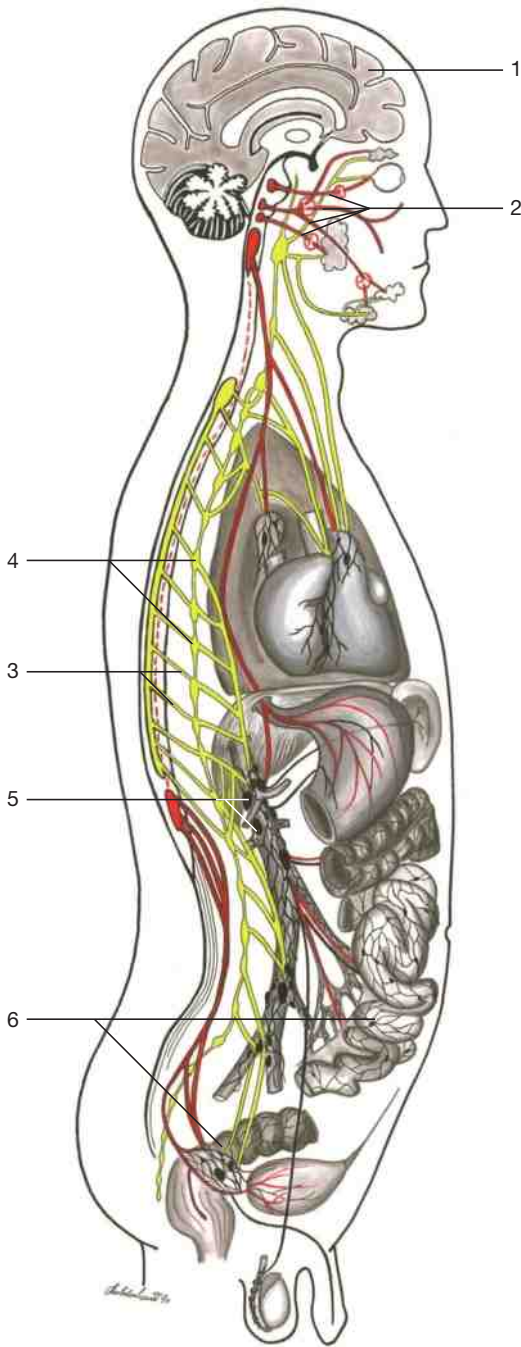
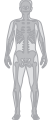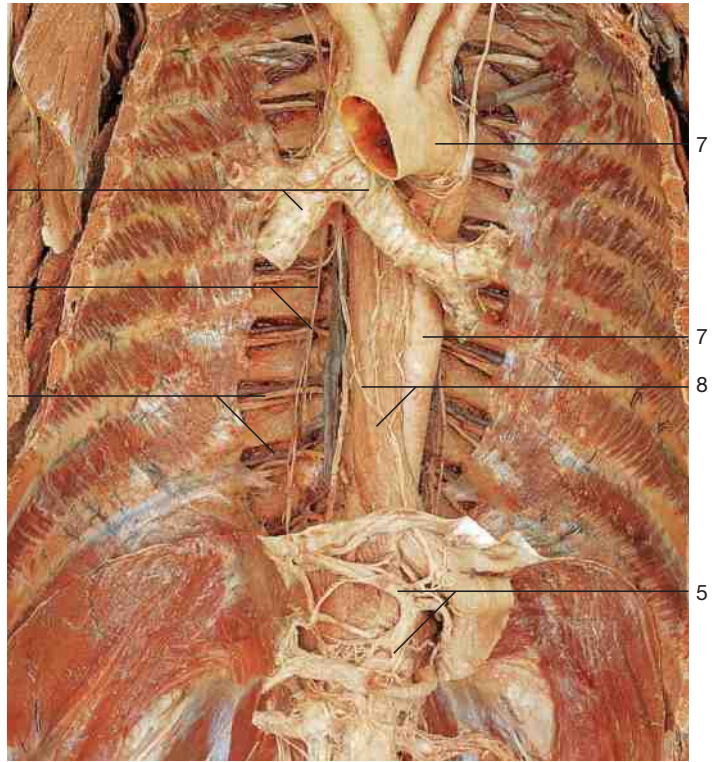


Diagram illustrating the **localization of the three functional portions of the nervous system** (brain, spinal cord and autonomic nervous system). Yellow = sympathetic system; red = parasympathetic system.

The nervous system can be divided into three functionally distinct parts:

1. The cranial part, which comprises the great sensory organs and the brain.
2. The spinal cord, which shows a segmental structure and serves predominantly as a reflex organ.
3. The autonomic nervous system, which controls the involuntary functions (subconscious control) of organs and tissues. The autonomic part of the nervous system forms many delicate plexuses near or within the organs.

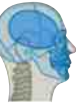

Posterior part of the trunk. The solar plexus with its connection to the vagus nerve and the sympathetic trunk has been dissected.

- | | |
|---------------------|--|
| 1 Cerebrum | 6 Nervous plexus of the autonomic system |
| 2 Cranial nerves | 7 Aorta |
| 3 Spinal nerves | 8 Vagus nerve and esophagus |
| 4 Sympathetic trunk | 9 Bifurcation of trachea |
| 5 Solar plexus | |

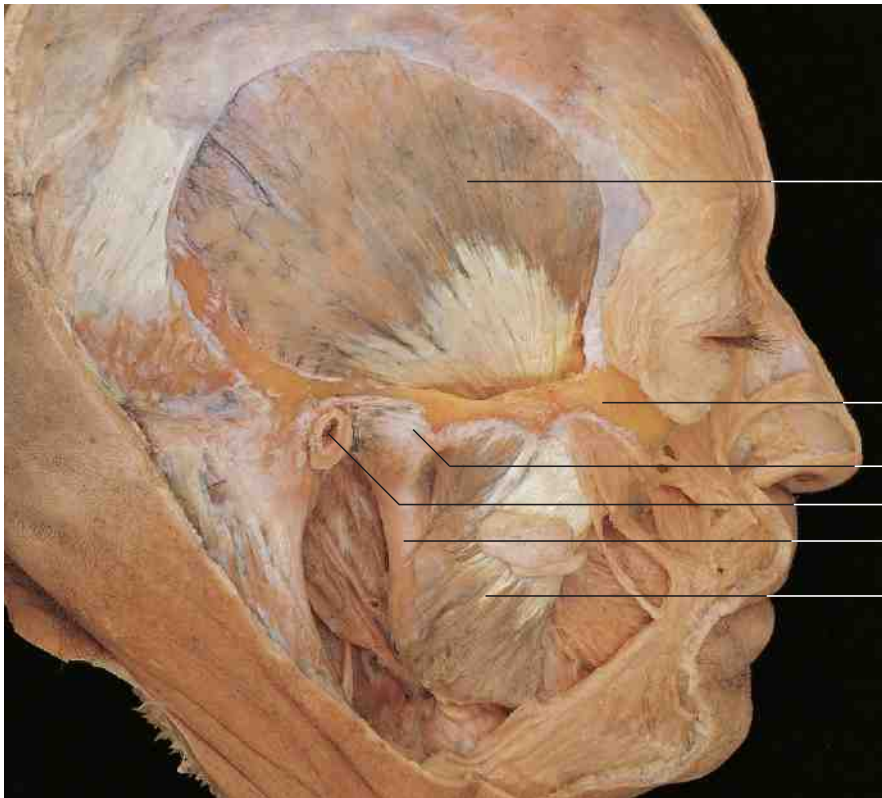
At certain places these plexuses contain aggregations of nerve cells (prevertebral and intramural ganglia).

The spinal nerves leave the spinal cord at regular intervals. The ventral rami of the spinal nerves form the cervical and brachial plexus, which innervates the upper extremity, and the ventral rami of the lumbar and sacral spinal nerves form the lumbosacral plexus, which innervates the pelvis and genital organs and the lower extremity.



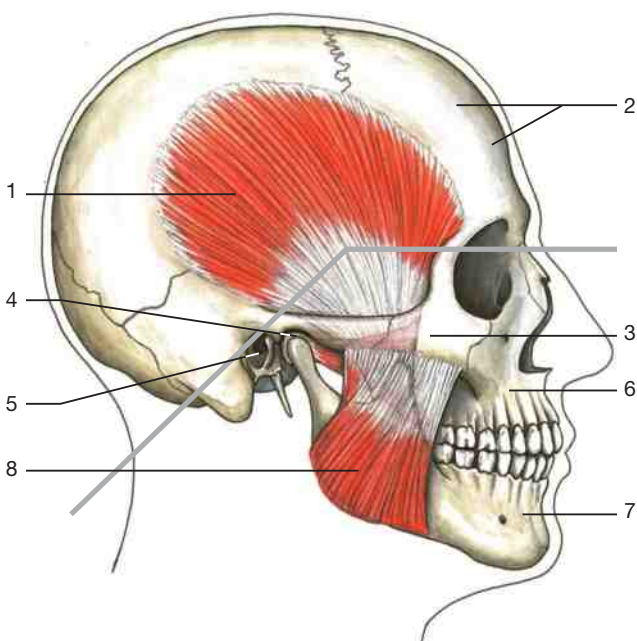
2 Head and Neck

2.1 Skull and Muscles of the Head



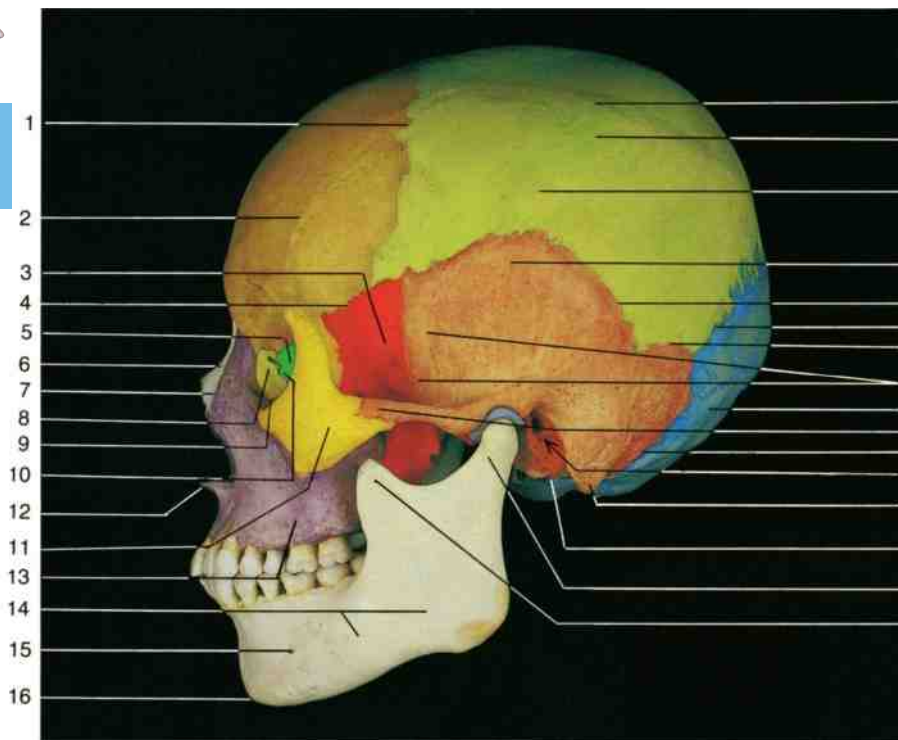
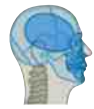The head contains the brain and the great sensory organs (neurocranium). Anteriorly, the facial bones, the facial muscles, and the muscles of mastication have been developed (viscerocranium). The base of the skull is slightly bent so that the structures of the viscerocranium become located underneath the neurocranium, a specificity of the human head. Therefore mimic movements are possible in the human face.

Muscles of mastication and facial muscles (lateral aspect).
The auricle has been removed.



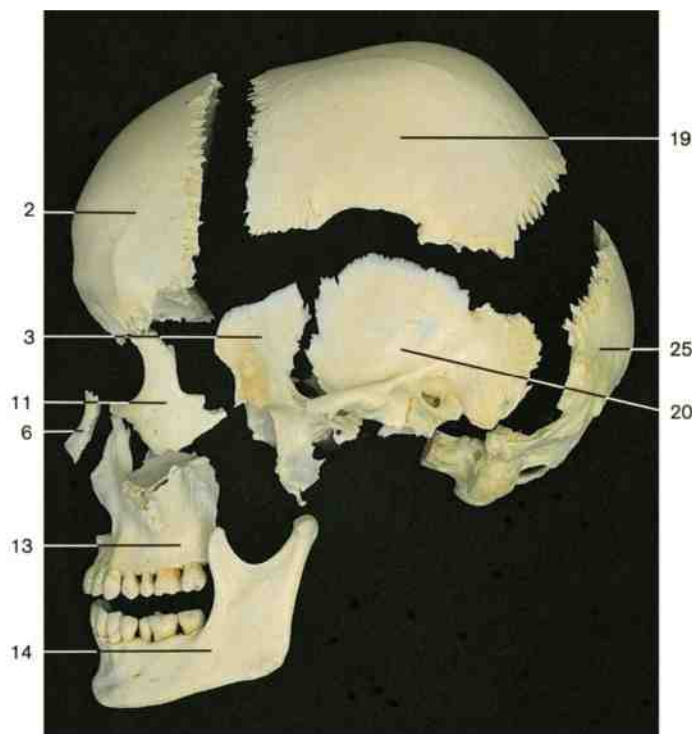
- 1 Temporalis muscle
- 2 Frontal bone
- 3 Zygomatic bone
- 4 Temporomandibular joint
- 5 External acoustic meatus
- 6 Maxilla
- 7 Mandible
- 8 Masseter muscle

Lateral aspect of the skull with muscles of mastication
(temporalis and masseter muscles = red).
The base of the skull is bent (grey line).



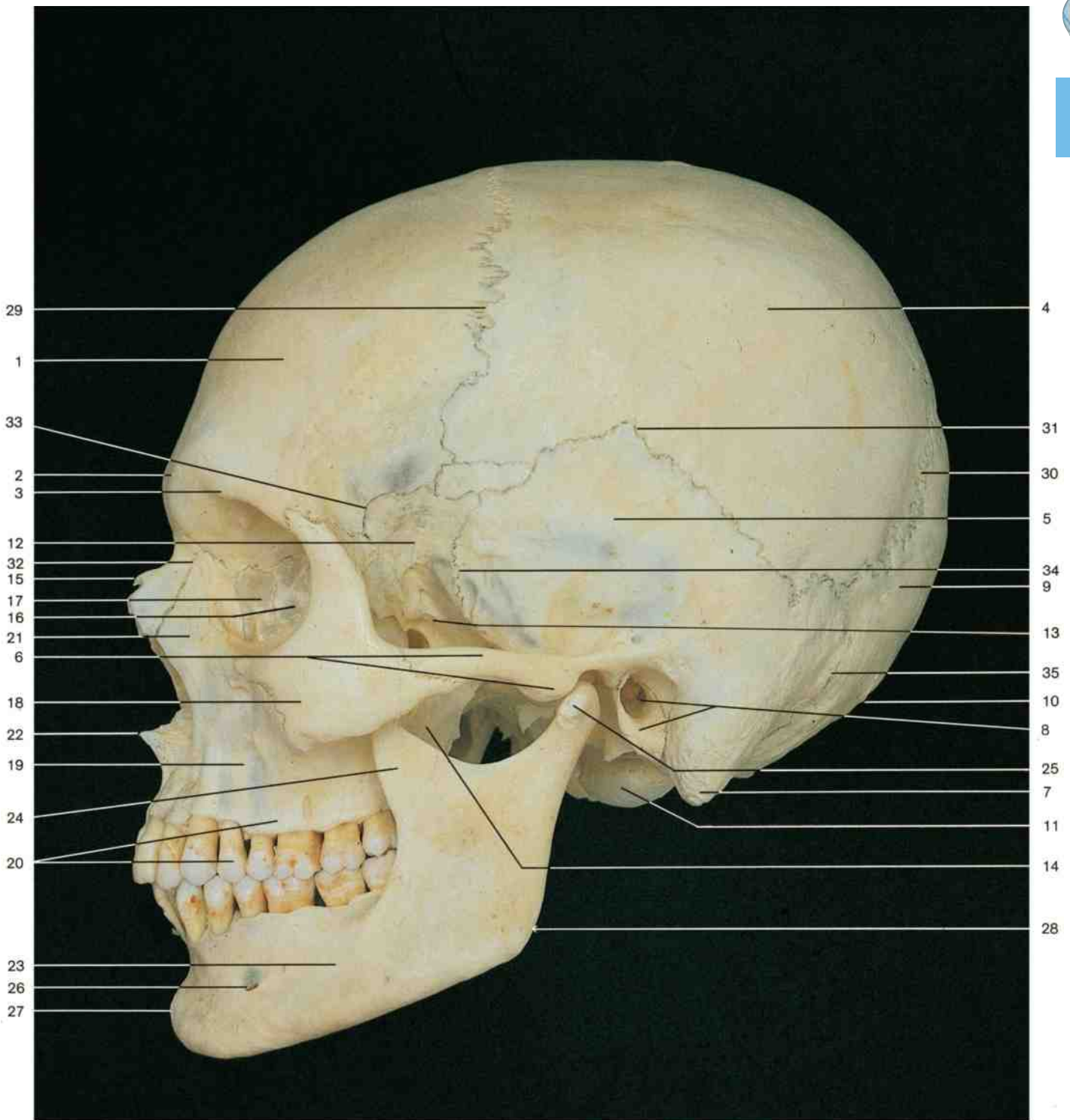
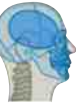- 1 Coronal suture
- 2 Frontal bone
- 3 Sphenoidal bone
- 4 Sphenofrontal suture
- 5 Ethmoidal bone
- 6 Nasal bone
- 7 Nasomaxillary suture
- 8 Lacrimal bone
- 9 Lacrimomaxillary suture
- 10 Ethmoidolacrimal suture
- 11 Zygomatic bone
- 12 Anterior nasal spine
- 13 Maxilla
- 14 Mandible
- 15 Mental foramen
- 16 Mental protuberance
- 17 Superior temporal line
- 18 Inferior temporal line
- 19 Parietal bone
- 20 Temporal bone
- 21 Squamous suture
- 22 Lambdoid suture
- 23 Temporal fossa
- 24 Parietomastoid suture
- 25 Occipital bone
- 26 Zygomatic arch
- 27 Occipitomastoid suture
- 28 External acoustic meatus
- 29 Mastoid process
- 30 Tympanic portion of temporal bone
- 31 Condylar process of mandible
- 32 Coronoid process of mandible

General architecture of the skull (lateral aspect). The different bones are indicated in color (numbers cf. table).



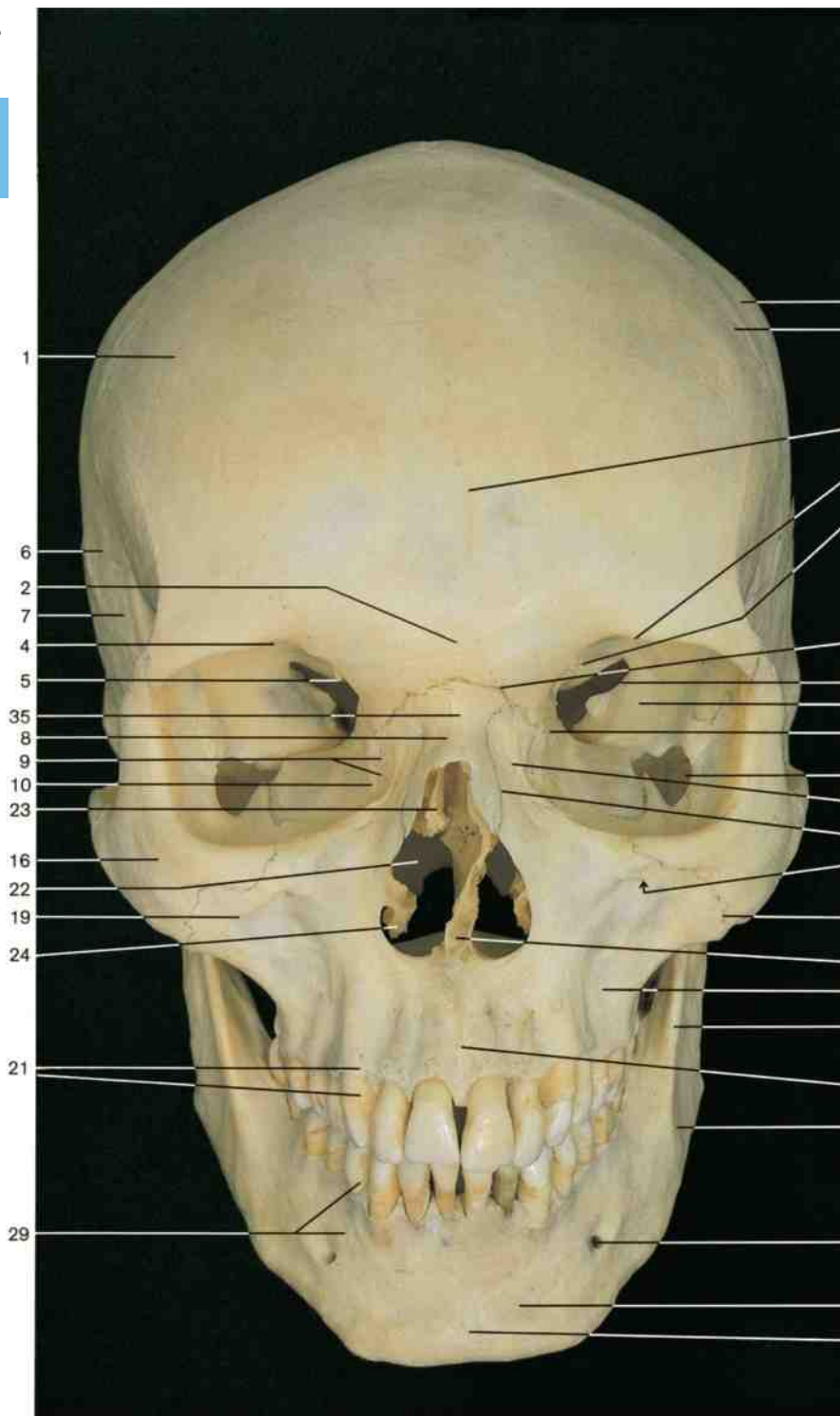
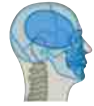2 Frontal bone (orange) 19 Parietal bone (light yellow) 3 Greater wing of sphenoidal bone (red) 25 Squama of occipital bone (blue) 20 Squama of temporal bone (brown)	Cranial bones
5 Ethmoidal bone (dark green) 3 Sphenoidal bone (red) Temporal bone excluding squama (brown) 30 Tympanic portion of temporal bone (dark brown) Occipital bone excluding squama (blue)	Base of skull
6 Nasal bone (white) 8 Lacrimal bone (light yellow) Inferior nasal concha Vomer 11 Zygomatic bone (dark yellow) Palatine bone 13 Maxilla (violet) 14 Mandible (white)	Facial bones
Malleus } within petrous portion of Incus } temporal bone Stapes }	Auditory ossicles
Hyoid	

Lateral aspect of the disarticulated skull (palatine bone, lacrimal bone, ethmoidal bone, and vomer are not depicted).



Lateral aspect of the skull.

- | | | |
|---|--|---------------------------|
| 1 Frontal bone | 12 Sphenoidal bone (greater wing) | 25 Condylar process |
| 2 Glabella | 13 Infratemporal crest of sphenoid | 26 Mental foramen |
| 3 Supraorbital margin | 14 Pterygoid process (lateral pterygoid plate) | 27 Mental protuberance |
| 4 Parietal bone | 15 Nasal bone | 28 Angle of the mandible |
| 5 Temporal bone (squamous part) | 16 Ethmoidal bone (orbital part) | |
| 6 Zygomatic process (articular tubercle) | 17 Lacrimal bone | Sutures |
| 7 Mastoid process | 18 Zygomatic bone | 29 Coronal suture |
| 8 Tympanic part (tympanic plate) and external acoustic meatus | 19 Maxilla (body) | 30 Lambdoid suture |
| 9 Occipital bone (squamous part) | 20 Alveolar process and teeth | 31 Squamous suture |
| 10 External occipital protuberance | 21 Frontal process | 32 Nasomaxillary suture |
| 11 Occipital condyle | 22 Anterior nasal spine | 33 Frontosphenoid suture |
| | 23 Mandible (body) | 34 Sphenosquamosal suture |
| | 24 Coronoid process | 35 Occipitomastoid suture |



Anterior aspect of the skull.

- 1 Frontal bone
- 2 Glabella
- 3 Supra-orbital margin
- 4 Supra-orbital notch
- 5 Trochlear spine
- 6 Parietal bone
- 7 Temporal bone
- 8 Nasal bone

Orbit

- 9 Lacrimal bone
- 10 Posterior lacrimal crest
- 11 Ethmoidal bone

Sphenoidal bone

- 12 Greater wing of sphenoidal bone
- 13 Lesser wing of sphenoidal bone
- 14 Superior orbital fissure
- 15 Inferior orbital fissure
- 16 Zygomatic bone

Maxilla

- 17 Frontal process
- 18 Infra-orbital foramen
- 19 Zygomatic process
- 20 Body of maxilla
- 21 Alveolar process with teeth

Nasal cavity

- 22 Anterior nasal aperture
- 23 Middle nasal concha
- 24 Inferior nasal concha
- 25 Nasal septum, vomer

Mandible

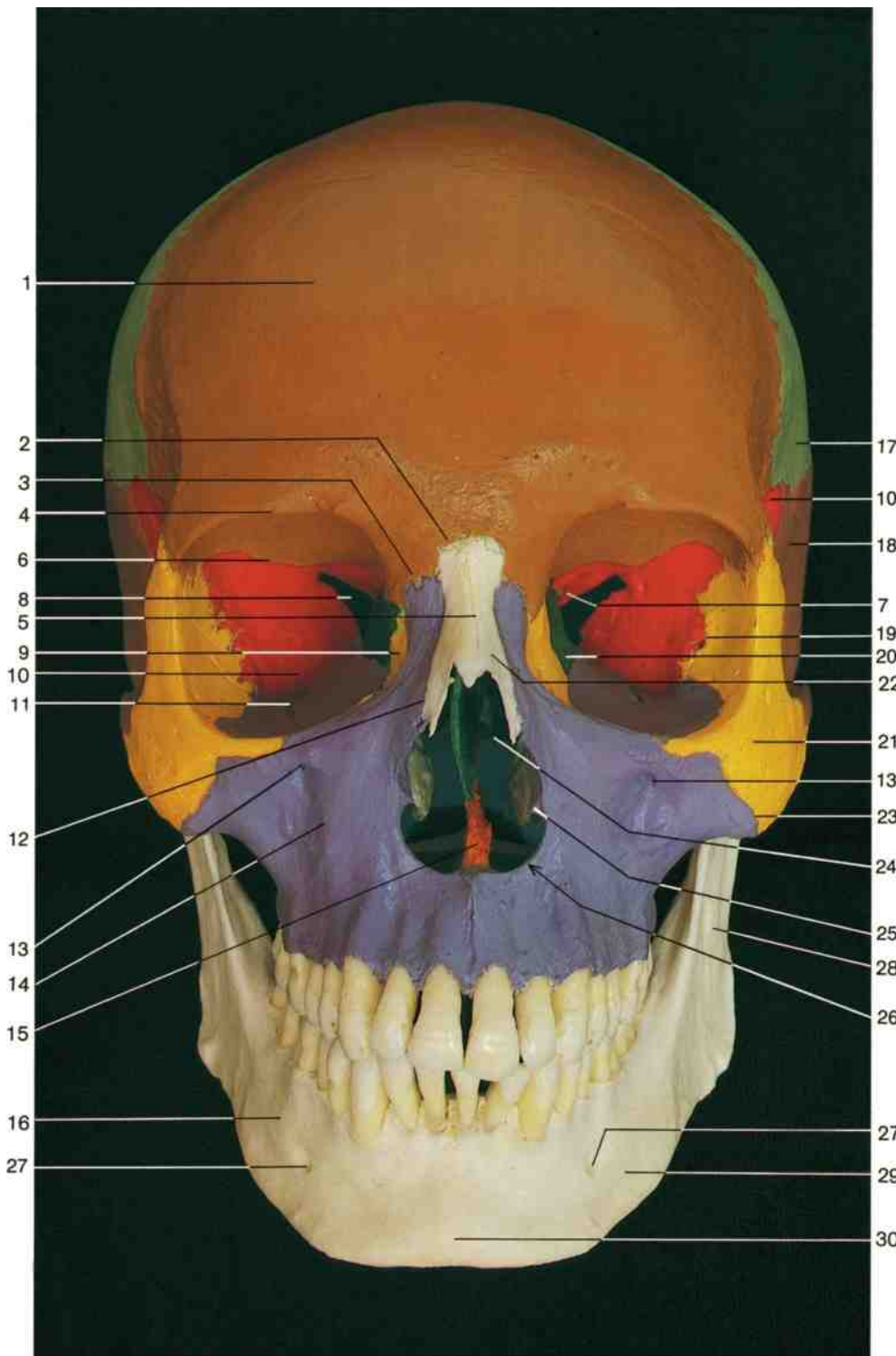
- 26 Body of mandible
- 27 Ramus of mandible
- 28 Mental foramen
- 29 Alveolar part with teeth
- 30 Base of mandible
- 31 Mental protuberance

Sutures

- 32 Frontal suture
- 33 Coronal suture
- 34 Frontonasal suture
- 35 Internasal suture
- 36 Nasomaxillary suture
- 37 Zygomaticomaxillary suture
- 38 Intermaxillary suture

The skull comprises a mosaic of numerous complicated bones that form the cranial cavity protecting the brain (**neurocranium**) and several cavities such as the nasal and oral cavities in the facial region. The neurocranium consists of large bony plates that develop directly from the surrounding sheets of connective tissue (**desmocranium**).

The bones of the skull base are formed out of cartilaginous tissue (**chondrocranium**), which ossifies secondarily. The **visceral skeleton**, which in fish gives rise to the gills, has in higher vertebrates been transformed into the bones of the masticatory and auditory apparatus (maxilla, mandible, auditory ossicles, and hyoid bone).



- 1 Frontal bone
- 2 Frontonasal suture
- 3 Frontomaxillary suture
- 4 Supra-orbital margin
- 5 Internasal suture
- 6 Sphenofrontal suture
- 7 Optic canal in lesser wing of sphenoidal bone
- 8 Superior orbital fissure
- 9 Lacrimal bone
- 10 Sphenoidal bone (greater wing)
- 11 Inferior orbital fissure
- 12 Nasomaxillary suture
- 13 Infra-orbital foramen
- 14 Maxilla
- 15 Vomer
- 16 Body of mandible
- 17 Parietal bone
- 18 Temporal bone
- 19 Sphenozygomatic suture
- 20 Ethmoidal bone
- 21 Zygomatic bone
- 22 Nasal bone
- 23 Zygomaticomaxillary suture
- 24 Middle nasal concha
- 25 Inferior nasal concha
- 26 Anterior nasal aperture
- 27 Mental foramen
- 28 Ramus of mandible
- 29 Base of mandible
- 30 Mental protuberance

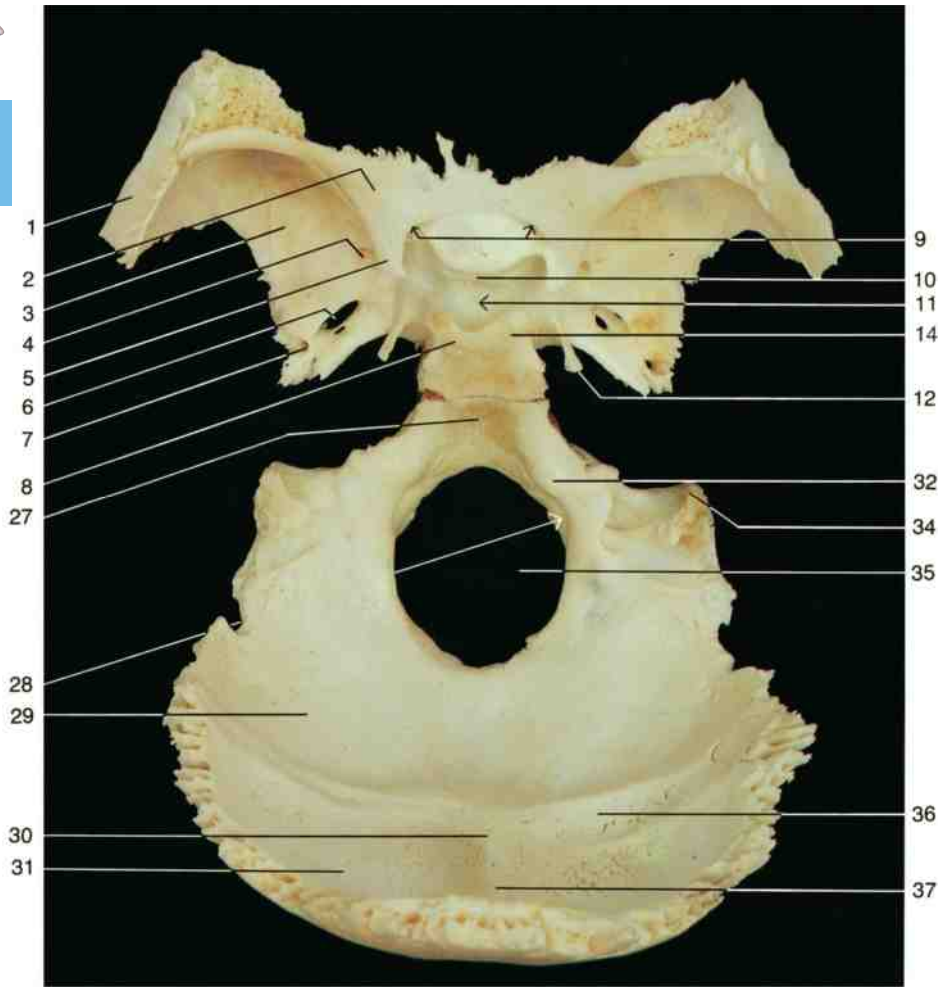
Bones

Brown	= frontal bone
Light green	= parietal bone
Dark brown	= temporal bone
Red	= sphenoidal bone
Yellow	= zygomatic bone
Dark green	= ethmoidal bone
Yellow	= lacrimal bone
Orange	= vomer
Violet	= maxilla
White	= nasal bone
White	= mandible

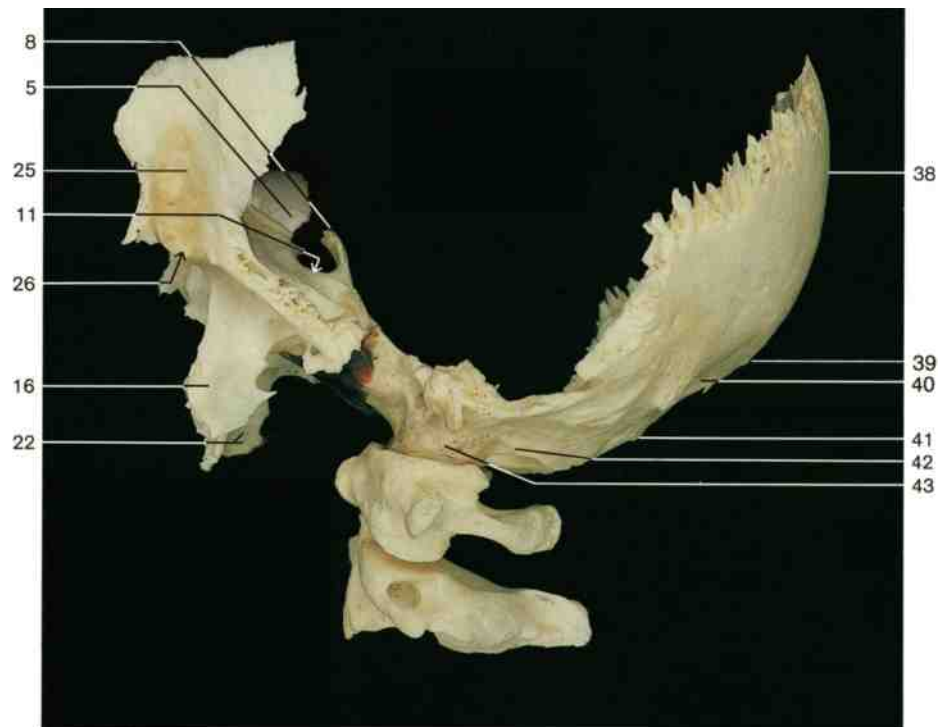Anterior aspect of the skull (individual bones indicated by color).

The following series of figures are arranged so that the mosaic-like pattern of the skull becomes understandable. It starts with the bones of the **skull base** (sphenoidal and occipital bones) to which the other bones are added step by

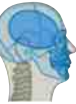step. The facial skeleton is built up by the ethmoidal bone to which the palatine bone and maxilla are attached laterally; the small nasal and lacrimal bones fill the remaining spaces. Cartilages remain only in the external part of the nose.



Sphenoidal and occipital bone (from above).



Sphenoidal and occipital bone in connection with the atlas and axis (1st and 2nd cervical vertebrae) (left lateral view).

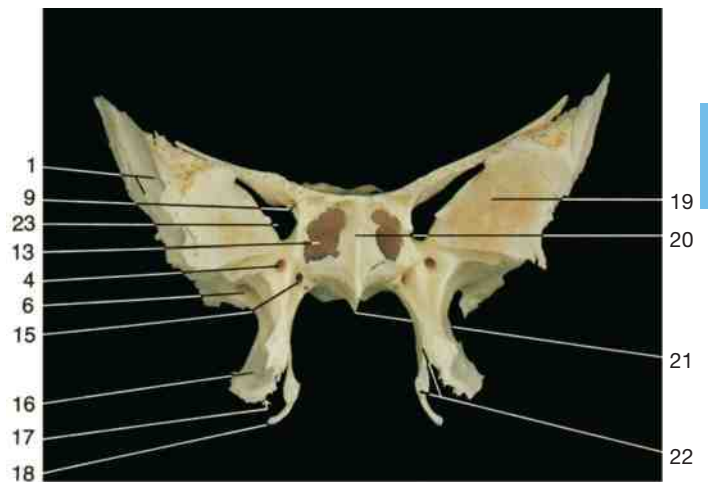


Sphenoidal bone

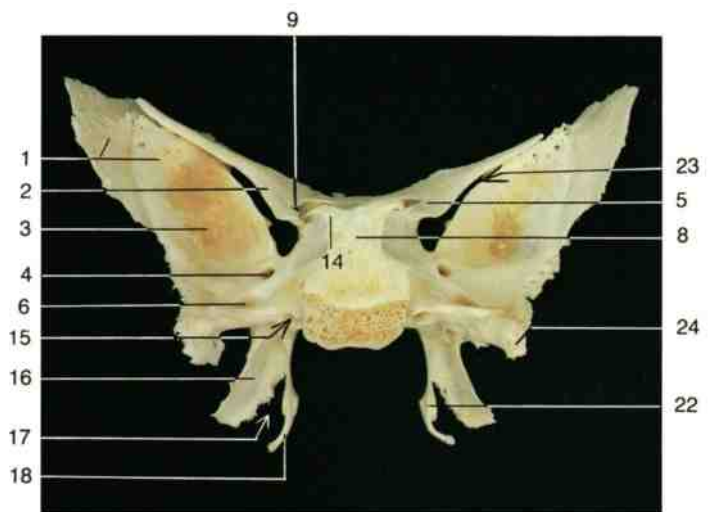
- 1 Greater wing
- 2 Lesser wing
- 3 Cerebral or superior surface of greater wing
- 4 Foramen rotundum
- 5 Anterior clinoid process
- 6 Foramen ovale
- 7 Foramen spinosum
- 8 Dorsum sellae
- 9 Optic canal
- 10 Chiasmatic groove (sulcus chiasmatis)
- 11 Hypophysial fossa (sella turcica)
- 12 Lingula
- 13 Opening of sphenoidal sinus
- 14 Posterior clinoid process
- 15 Pterygoid canal
- 16 Lateral pterygoid plate of pterygoid process
- 17 Pterygoid notch
- 18 Pterygoid hamulus
- 19 Orbital surface of greater wing
- 20 Sphenoidal crest
- 21 Sphenoidal rostrum
- 22 Medial pterygoid plate
- 23 Superior orbital fissure
- 24 Spine of sphenoid
- 25 Temporal surface of greater wing
- 26 Infratemporal crest

Occipital bone

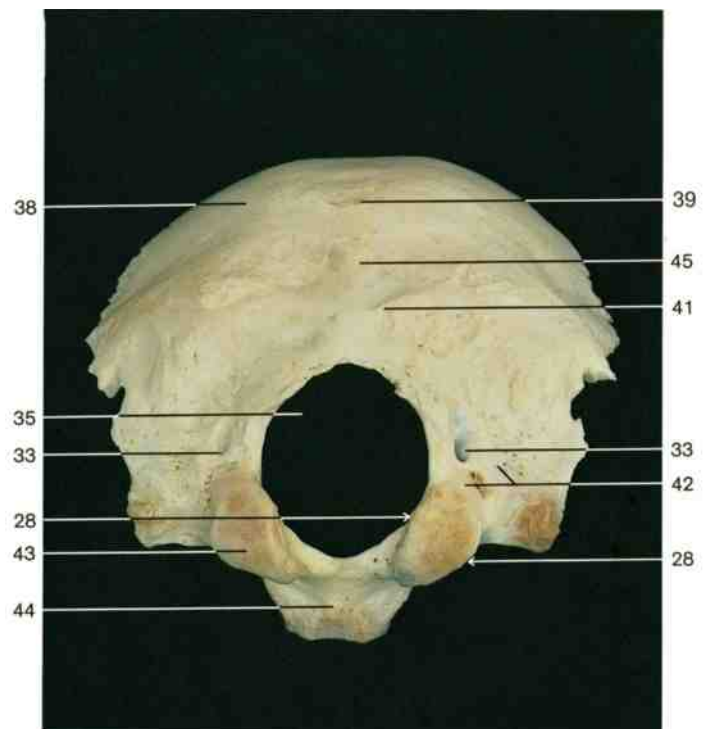
- 27 Clivus with basilar part of occipital bone
- 28 Hypoglossal canal
- 29 Fossa for cerebellar hemisphere
- 30 Internal occipital protuberance
- 31 Fossa for cerebral hemisphere
- 32 Jugular tubercle
- 33 Condylar canal
- 34 Jugular process
- 35 Foramen magnum
- 36 Groove for transverse sinus
- 37 Groove for superior sagittal sinus
- 38 Squamous part of the occipital bone
- 39 External occipital protuberance
- 40 Superior nuchal line
- 41 Inferior nuchal line
- 42 Condylar fossa
- 43 Condyle
- 44 Pharyngeal tubercle
- 45 External occipital crest



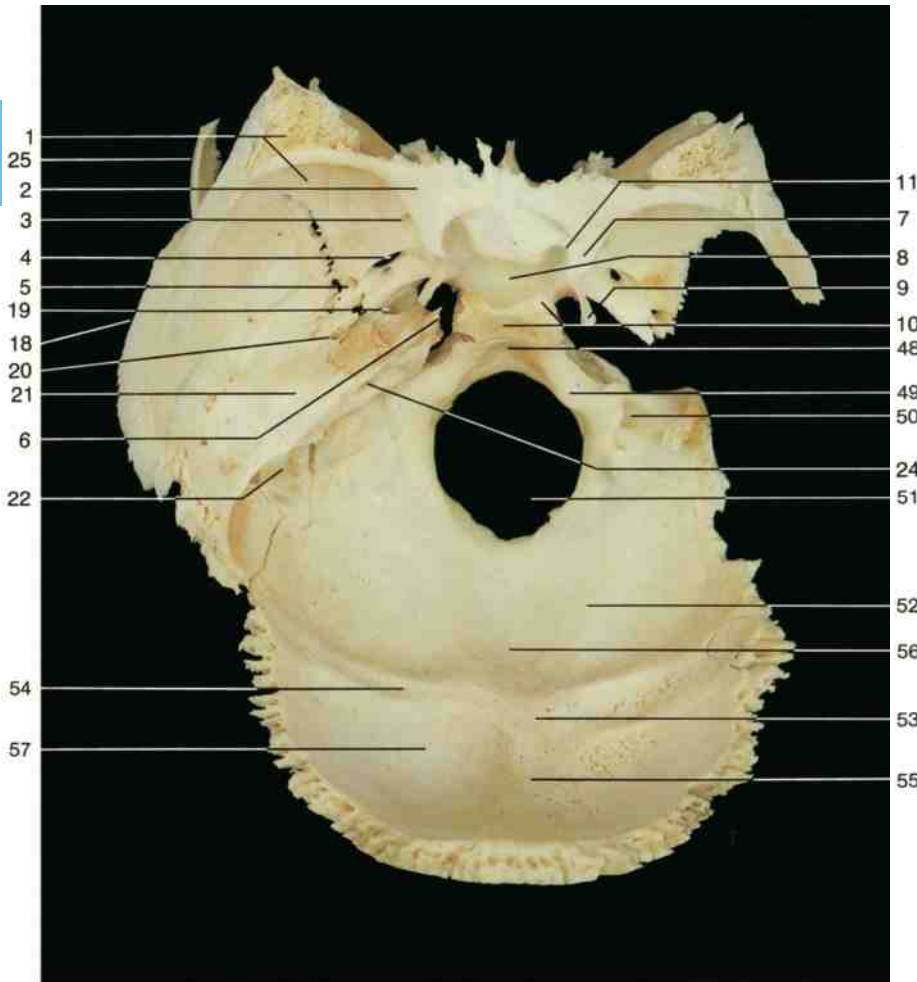
Sphenoidal bone (anterior aspect).



Sphenoidal bone (posterior aspect).



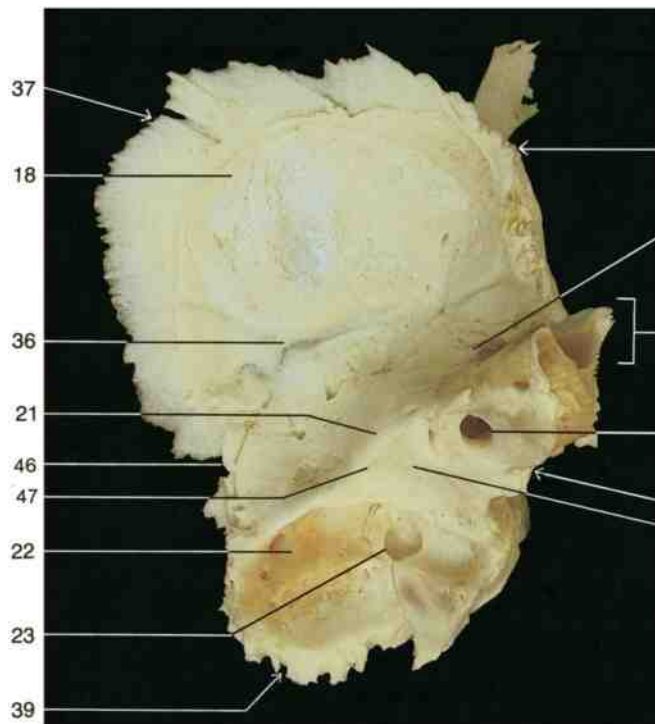
Occipital bone (from below).



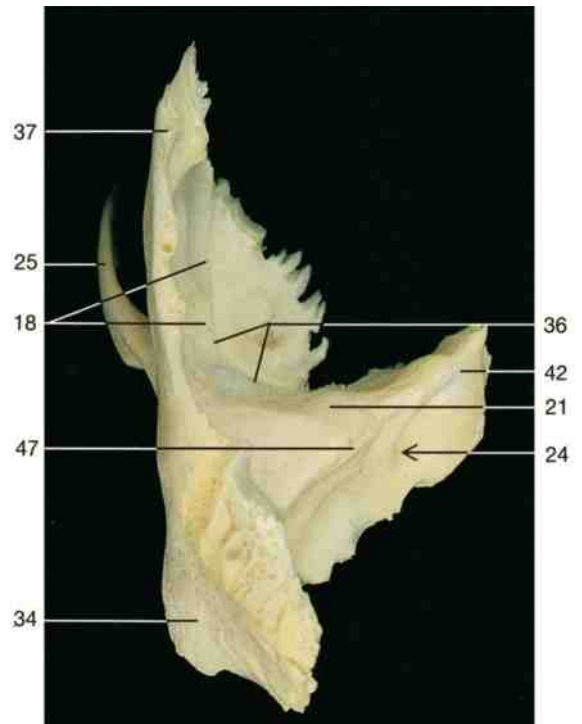
Sphenoidal bone

- 1 Greater wing
- 2 Lesser wing
- 3 Foramen rotundum
- 4 Foramen ovale
- 5 Foramen spinosum
- 6 Foramen lacerum
- 7 Anterior clinoid process
- 8 Hypophysial fossa (sella turcica)
- 9 Lingula
- 10 Dorsum sellae and posterior clinoid process
- 11 Optic canal
- 12 Sphenoidal rostrum
- 13 Medial pterygoid plate
- 14 Lateral pterygoid plate
- 15 Pterygoid hamulus
- 16 Infratemporal crest
- 17 Body of the sphenoidal bone

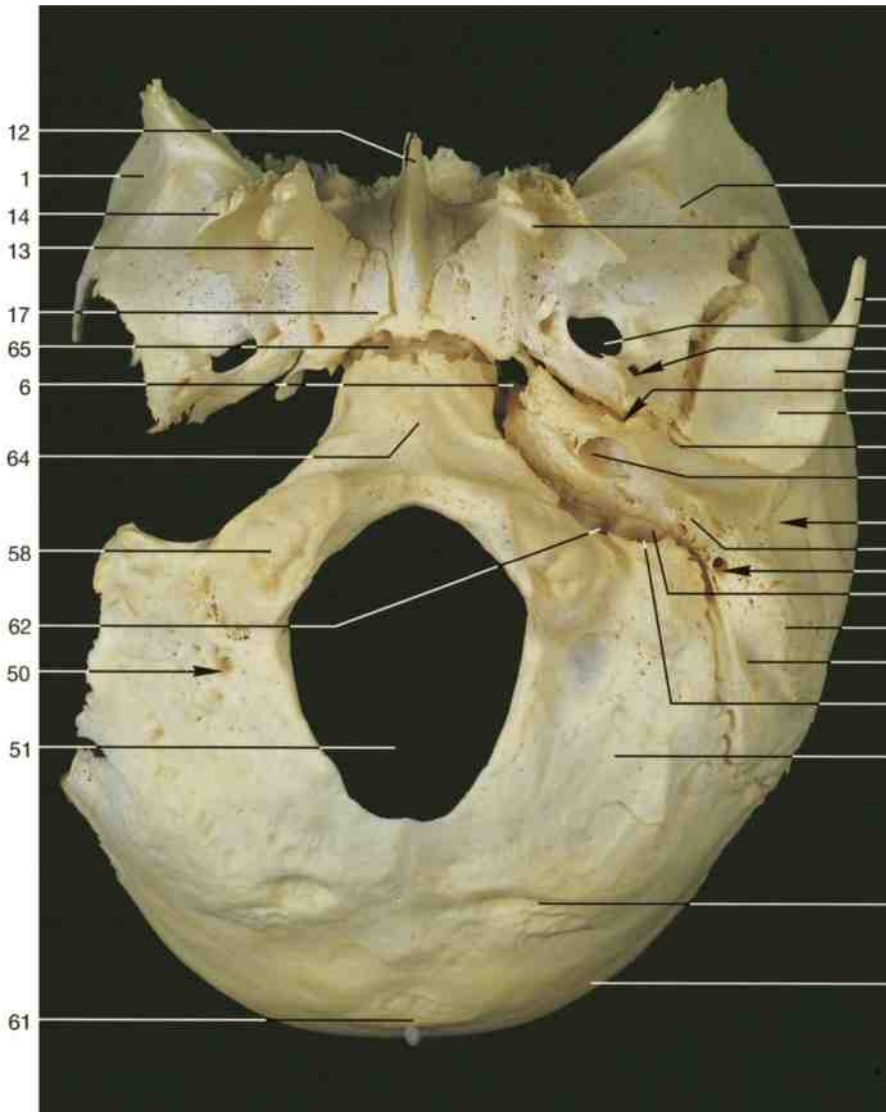
Sphenoidal, occipital, and left temporal bone (from above). Internal aspect of the base of the skull. The left temporal bone has been added to the preceding figure.



Left temporal bone (medial aspect).



Left temporal bone (from above).




Sphenoidal, occipital, and left temporal bone. Base of the skull (external aspect).

Temporal bone

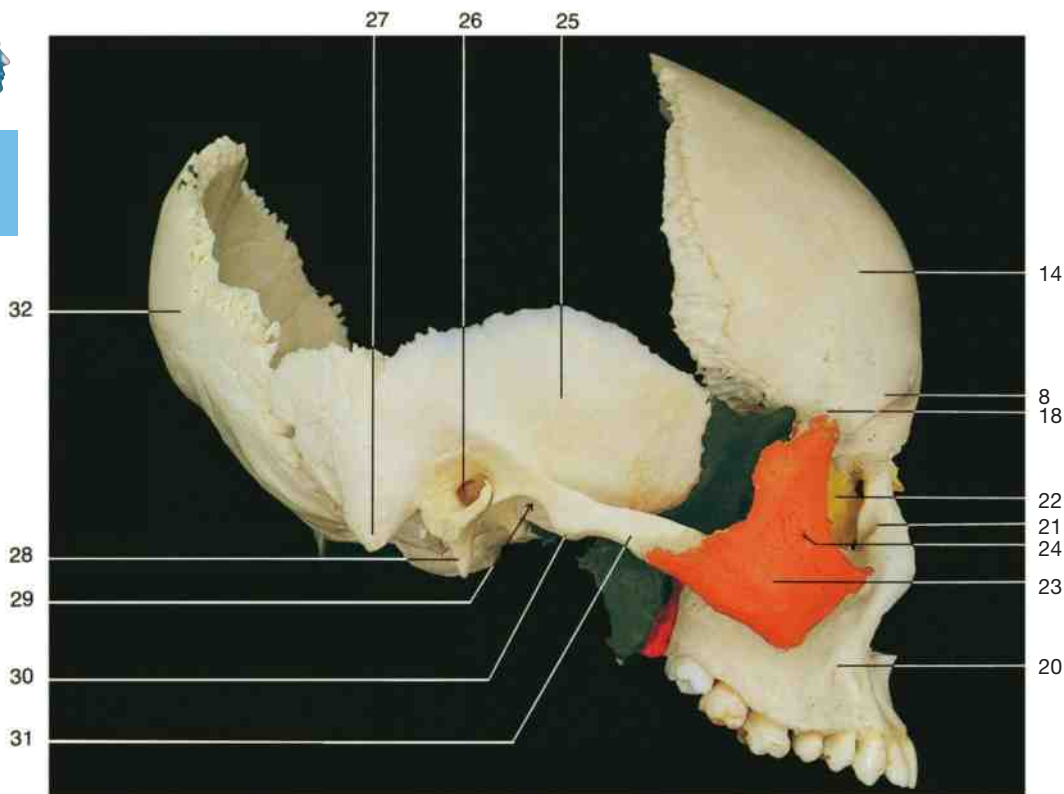
- 18 Squamous part
- 19 Carotid canal
- 20 Hiatus of facial canal
(for the greater petrosal nerve)
- 21 Arcuate eminence
- 22 Groove for the sigmoid sinus
- 23 Mastoid foramen
- 24 Internal acoustic meatus
- 25 Zygomatic process
- 26 Mandibular fossa
- 27 Petrotympenic fissure
- 4 28 Canalis musculotubarius
(bony part of auditory tube)
- 5 29 External acoustic meatus
- 45 30 Styloid process (remnant only)
- 28 31 Stylomastoid foramen
- 26 32 Mastoid canaliculus
- 27 33 Jugular fossa
- 19 34 Mastoid process
- 29 35 Mastoid notch
- 30 36 Groove for middle
meningeal vessels
- 31 37 Parietal margin
- 32 38 Sphenoidal margin
- 34 39 Occipital margin
- 35 40 Cochlear canaliculus
- 33 41 Aqueduct of the vestibule
- 59 42 Apex of the petrous part
- 63 43 Tympanic part
- 44 44 Trigeminal impression
- 45 45 Articular tubercle
- 46 46 Parietal notch
- 47 47 Groove for the superior
petrosal sinus

Occipital bone

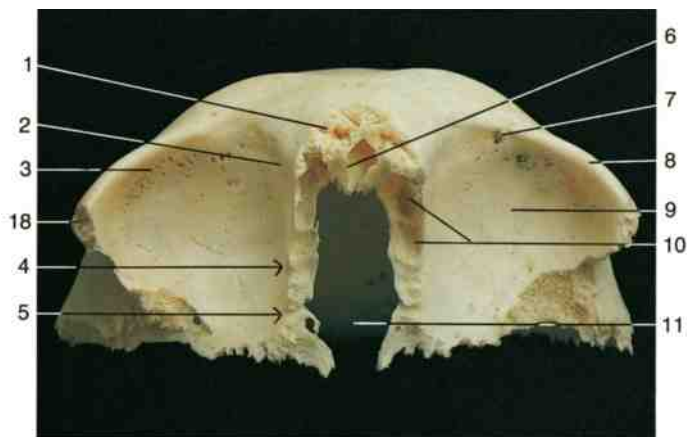
- 48 Clivus
- 49 Jugular tubercle
- 50 Condylar canal
- 51 Foramen magnum
- 52 Lower part of squamous
occipital bone
(cerebellar fossa)
- 53 Internal occipital protuberance
- 54 Groove for the transverse sinus
- 55 Groove for the superior sagittal sinus
- 56 Internal occipital crest
- 57 Upper part of squamous occipital
bone (cerebral fossa)
- 58 Condyle
- 59 Nuchal plane
- 60 Superior nuchal line
- 61 External occipital protuberance
- 62 Jugular foramen
- 63 Inferior nuchal line
- 64 Pharyngeal tubercle
- 65 Spheno-occipital synchondrosis



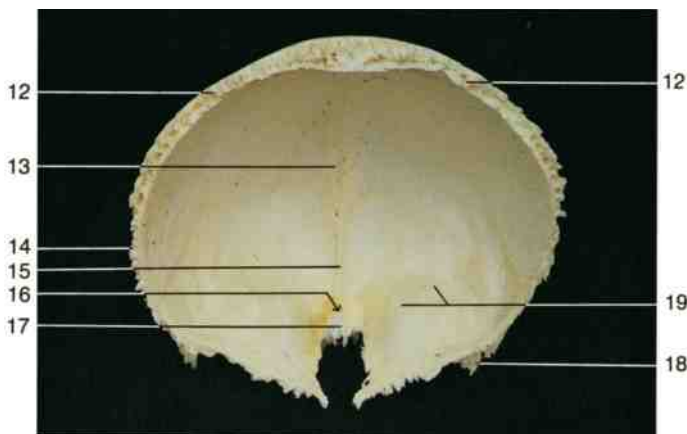
Left temporal bone (lateral aspect).



Part of a disarticulated skull (right lateral aspect). The frontal bone and the maxilla are connected with the temporal bone by the zygomatic bone (orange). Sphenoidal bone (black), palatine bone (red), lacrimal bone (yellow).



Frontal bone (inferior aspect). The ethmoidal foveolae cover the ethmoidal cavities of the ethmoidal bone.



Frontal bone (posterior aspect).

Frontal bone

- 1 Nasal margin
- 2 Trochlear fossa
- 3 Fossa for lacrimal gland
- 4 Anterior ethmoidal foramen
- 5 Posterior ethmoidal foramen
- 6 Nasal spine
- 7 Supra-orbital notch
- 8 Supra-orbital margin
- 9 Orbital plate
- 10 Roofs of the ethmoidal air cells
- 11 Ethmoidal notch
- 12 Parietal margin
- 13 Groove for superior sagittal sinus
- 14 Squamous part of frontal bone
- 15 Frontal crest
- 16 Foramen cecum
- 17 Nasal spine
- 18 Zygomatic process of frontal bone
- 19 Jugal foramen

Facial bones

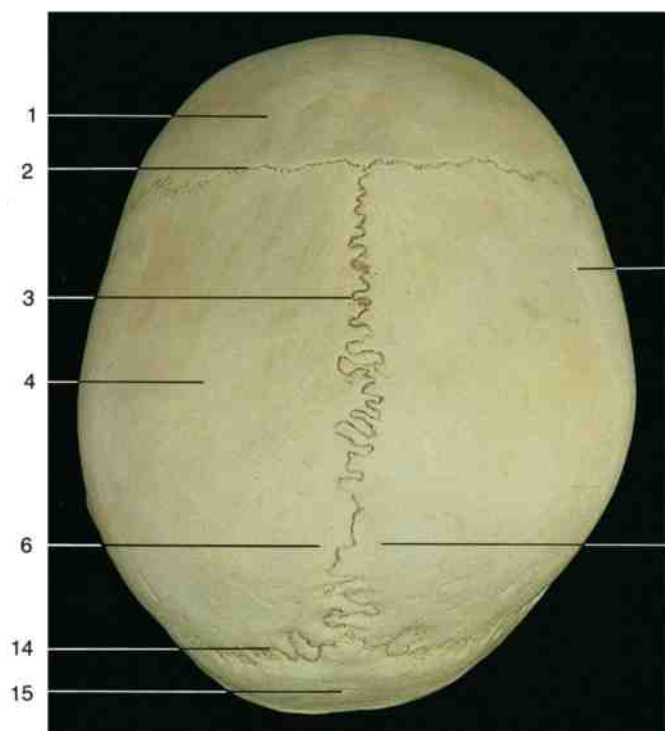
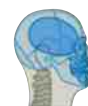- 20 Maxilla
- 21 Frontal process of maxilla
- 22 Lacrimal bone (yellow)
- 23 Zygomatic bone (orange)
- 24 Zygomaticofacial foramen

Temporal bone

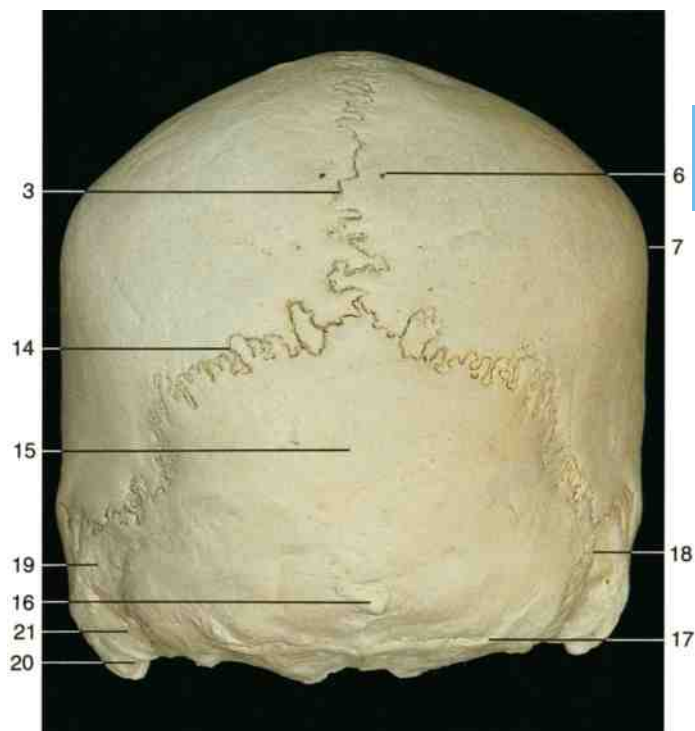- 25 Squamous part of temporal bone
- 26 External acoustic meatus
- 27 Mastoid process
- 28 Styloid process
- 29 Mandibular fossa
- 30 Articular tubercle
- 31 Zygomatic process

Occipital bone

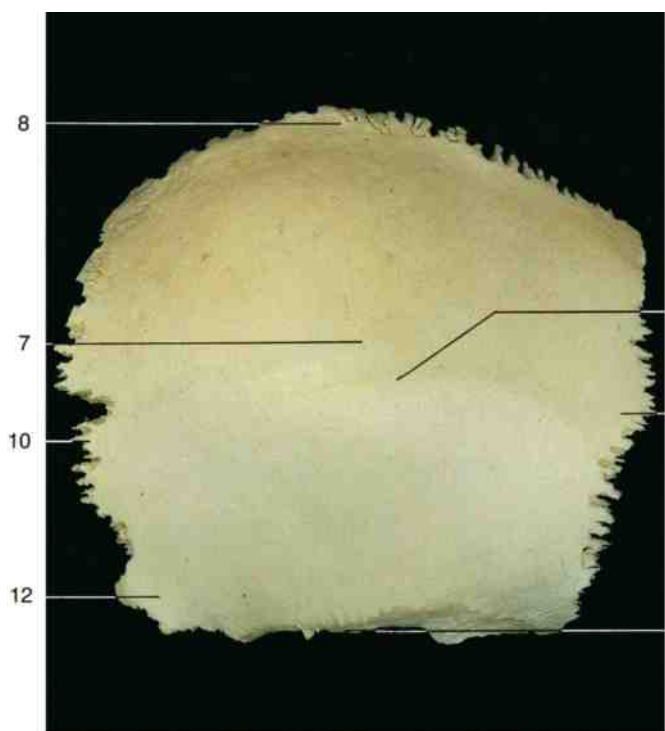
- 32 Squamous part of occipital bone



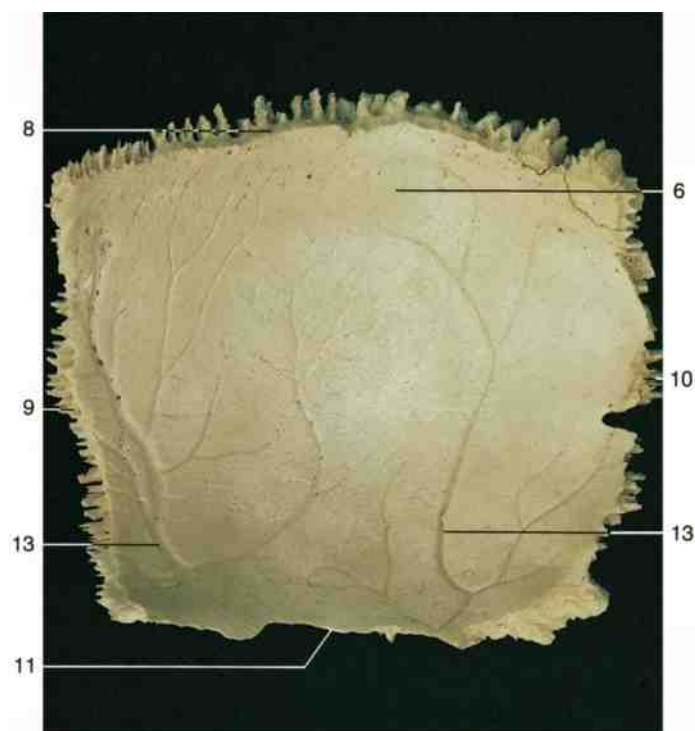
Calvaria (superior aspect).



Calvaria (posterior aspect).



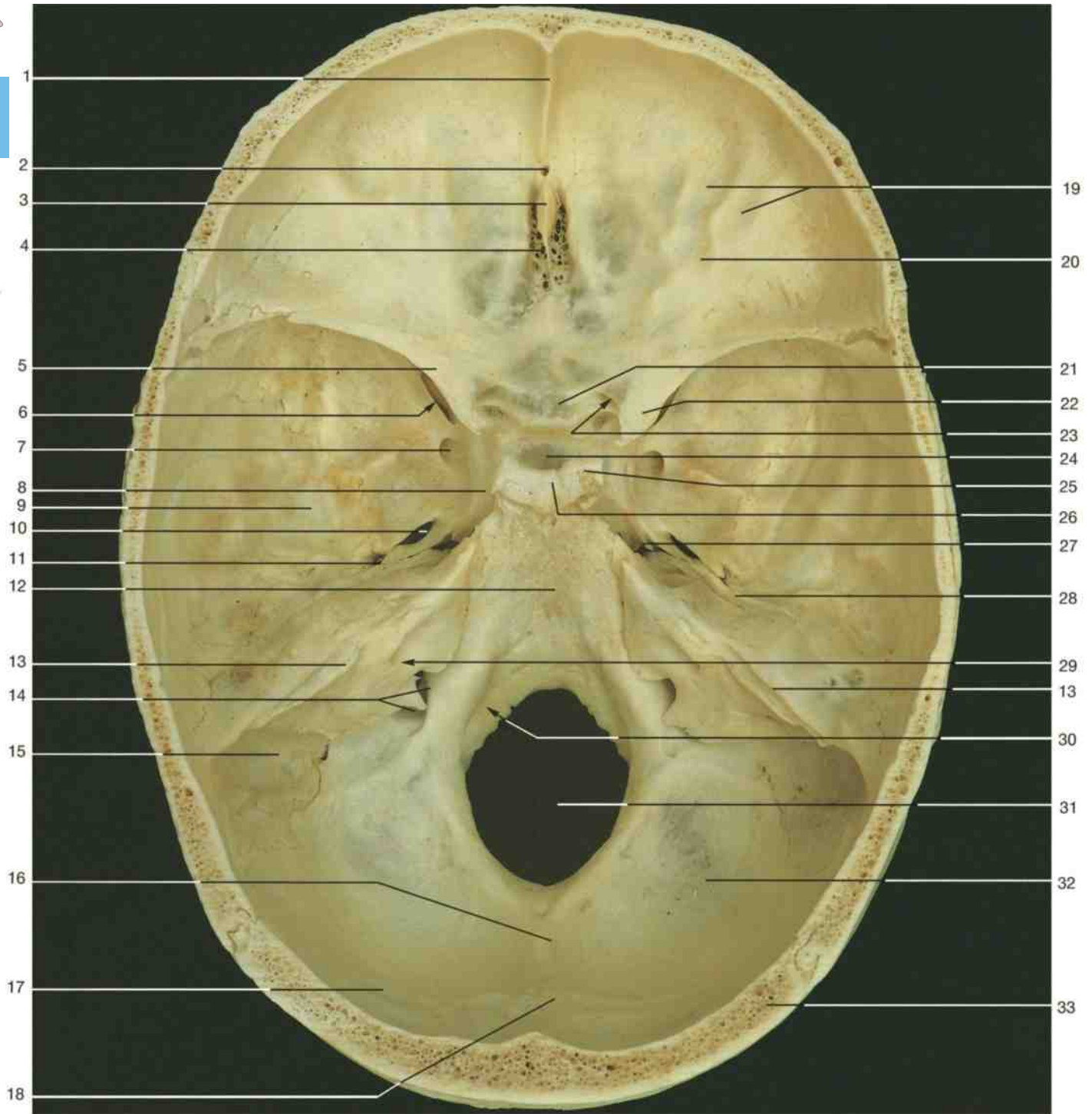
Left parietal bone (external aspect).



Left parietal bone (internal aspect).

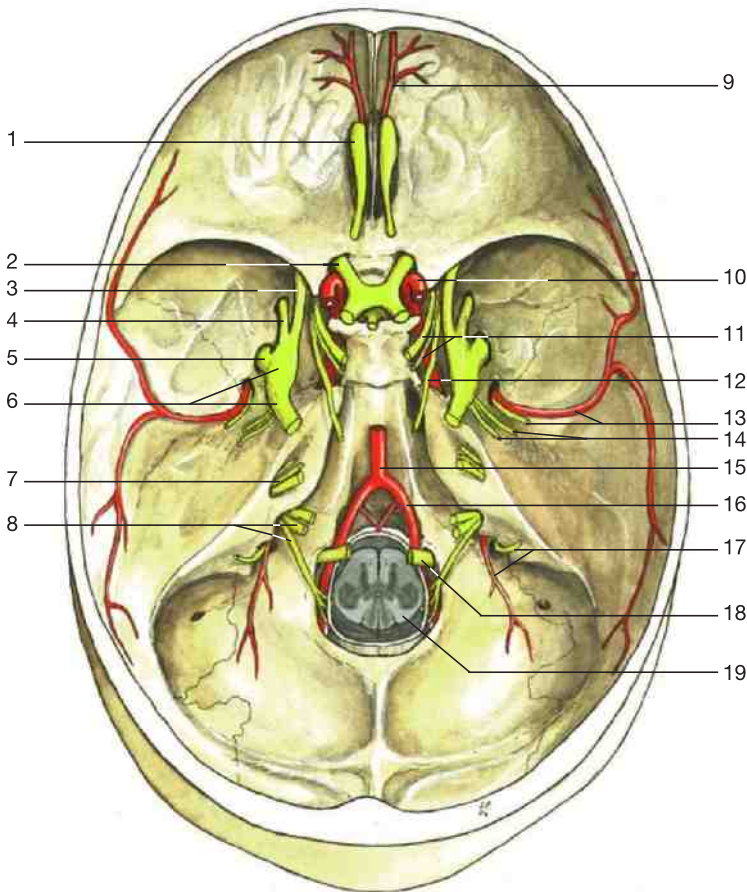
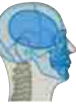- | | |
|------------------------------|---------------------------------------|
| 1 Frontal bone | 8 Sagittal margin |
| 2 Coronal suture | 9 Occipital margin |
| 3 Sagittal suture | 10 Frontal margin |
| 4 Parietal bone | 11 Squamous margin |
| 5 Superior temporal line | 12 Sphenoidal angle |
| 6 Parietal foramen | 13 Groove for middle meningeal artery |
| 7 Parietal tuber or eminence | 14 Lambdoid suture |

- | |
|------------------------------------|
| 15 Occipital bone |
| 16 External occipital protuberance |
| 17 Inferior nuchal line |
| 18 Occipitomastoid suture |
| 19 Temporal bone |
| 20 Mastoid process |
| 21 Mastoid notch |



Base of the skull, calvaria removed (internal aspect).

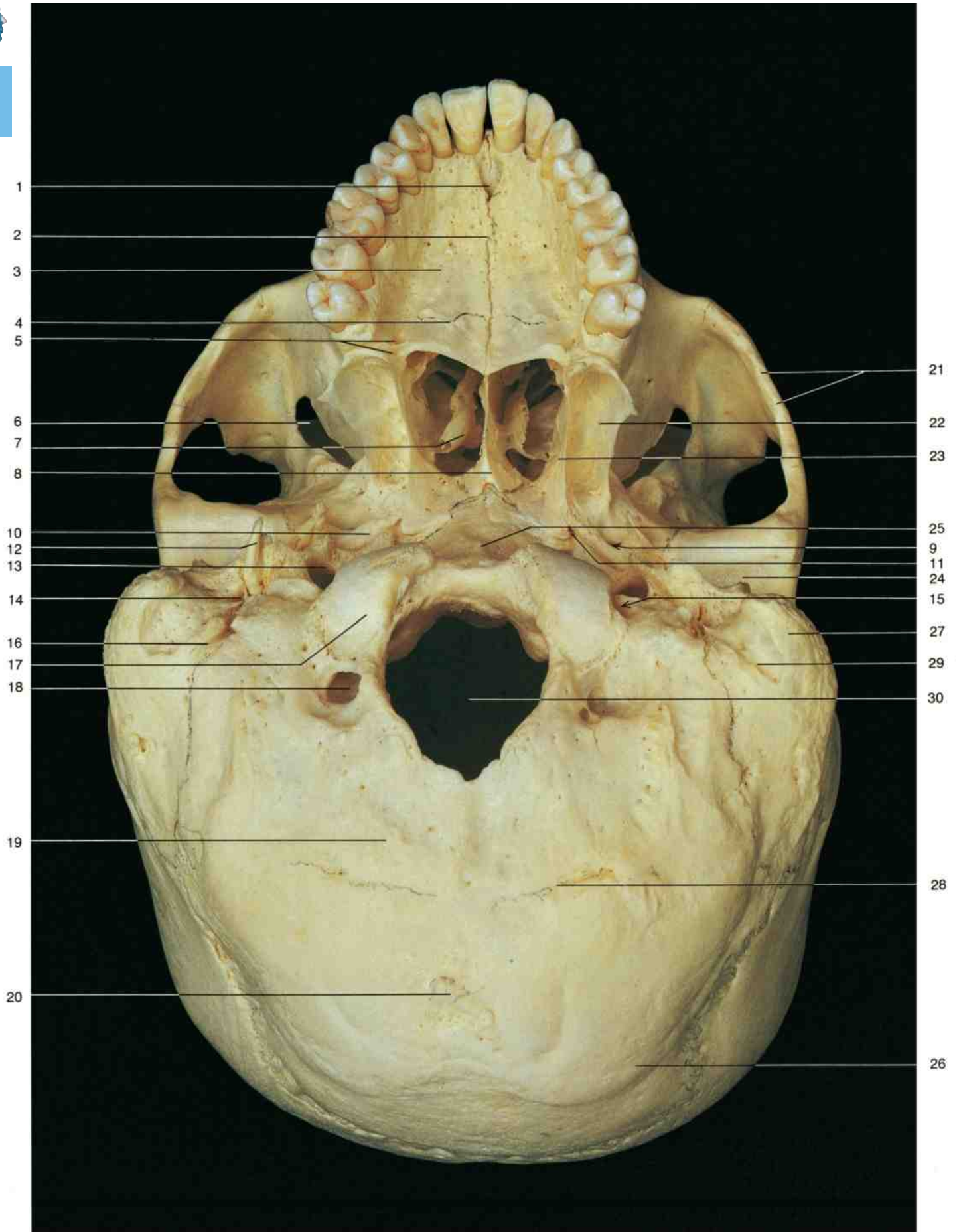
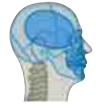- | | | |
|--------------------------------------|---------------------------------------|--------------------------------------|
| 1 Frontal crest | 12 Clivus | 23 Optic canal |
| 2 Foramen cecum | 13 Groove for superior petrosal sinus | 24 Sella turcica (hypophysial fossa) |
| 3 Crista galli | 14 Jugular foramen | 25 Posterior clinoid process |
| 4 Cribriform plate of ethmoidal bone | 15 Groove for sigmoid sinus | 26 Dorsum sellae |
| 5 Lesser wing of sphenoidal bone | 16 Internal occipital crest | 27 Foramen lacerum |
| 6 Superior orbital fissure | 17 Groove for transverse sinus | 28 Groove for greater petrosal nerve |
| 7 Foramen rotundum | 18 Internal occipital protuberance | 29 Internal acoustic meatus |
| 8 Carotid sulcus | 19 Digitate impressions | 30 Hypoglossal canal |
| 9 Middle cranial fossa | 20 Anterior cranial fossa | 31 Foramen magnum |
| 10 Foramen ovale | 21 Chiasmatic sulcus | 32 Posterior cranial fossa |
| 11 Foramen spinosum | 22 Anterior clinoid process | 33 Diploë |



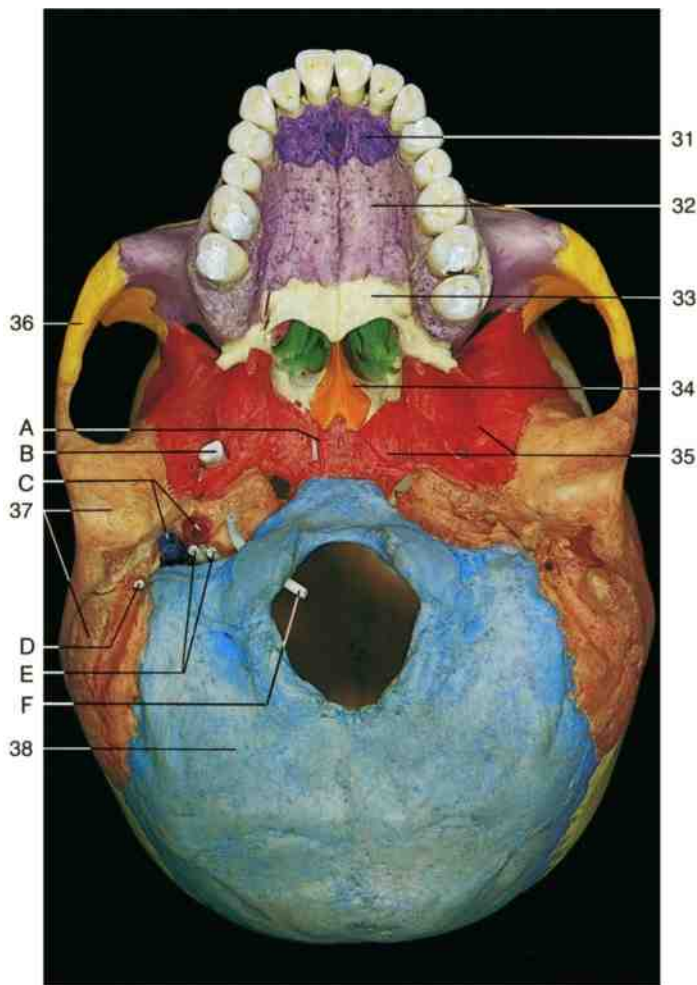
- 1 Olfactory bulb
- 2 Optic nerve (n. II)
- 3 Ophthalmic nerve (n. V₁)
- 4 Maxillary nerve (n. V₂)
- 5 Mandibular nerve (n. V₃)
- 6 Trigeminal nerve (n. V) with trigeminal ganglion
- 7 Facial nerve (n. VII) and vestibulocochlear nerve (n. VIII)
- 8 Glossopharyngeal nerve (n. IX), vagus nerve (n. X) and accessory nerve (n. XI)
- 9 Anterior meningeal artery
- 10 Internal carotid artery
- 11 Oculomotor nerve (n. III) and trochlear nerve (n. IV)
- 12 Abducent nerve (n. VI)
- 13 Middle meningeal artery and meningeal branch of mandibular nerve
- 14 Greater and lesser petrosal nerves
- 15 Basilar artery
- 16 Vertebral artery
- 17 Posterior meningeal artery and recurrent meningeal nerve
- 18 Hypoglossal nerve (n. XII)
- 19 Medulla oblongata

Base of the skull with cranial nerves and meningeal arteries (internal aspect, schematic drawing).

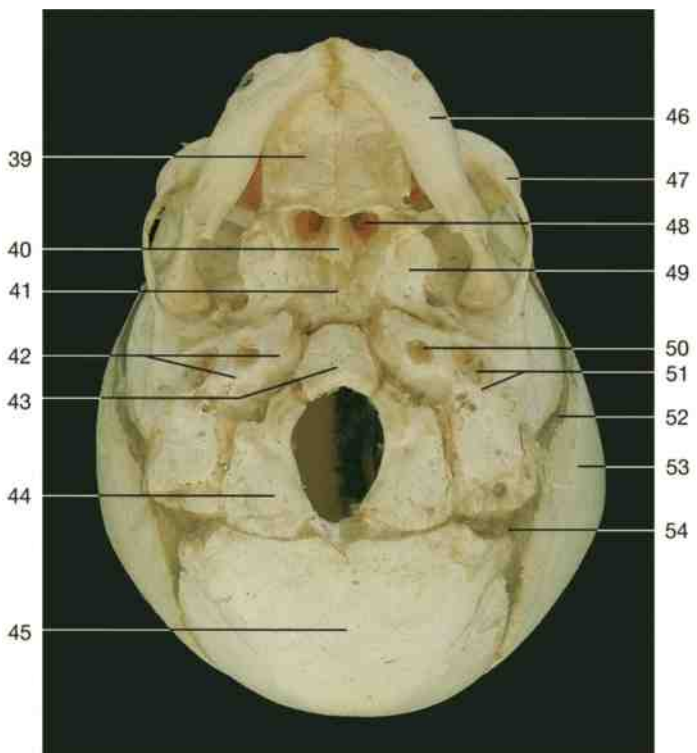
	Cranial nerves and vessels	Related foramina	Related regions
Anterior cranial fossa	Olfactory nerves (n. I), Anterior ethmoidal artery, vein, and nerve, Anterior meningeal artery	Lamina cribrosa	Nasal cavity
Middle cranial fossa	Optic nerve (n. II), Ophthalmic artery	Optic canal	Orbit
	Oculomotor nerve (n. III), Trochlear nerve (n. IV), Abducent nerve (n. VI), Ophthalmic nerve (n. V ₁), Superior ophthalmic vein	Superior orbital fissure	Orbit
	Maxillary nerve (n. V ₂)	Foramen rotundum	Pterygopalatine fossa
	Mandibular nerve (n. V ₃)	Foramen ovale	Infratemporal fossa
	Middle meningeal artery, Meningeal branch of mandibular nerve (n. V ₃)	Foramen spinosum	Infratemporal fossa
	Internal carotid artery	Carotid canal	Cavernous sinus, Base of skull
Posterior cranial fossa	Facial nerve (n. VII), Vestibulocochlear nerve (n. VIII), Artery and vein of the labyrinth	Internal acoustic meatus, Stylomastoid foramen, Facial canal	Inner ear, Face
	Glossopharyngeal nerve (n. IX), Vagus nerve (n. X), Accessory nerve (n. XI), Internal jugular vein, Posterior meningeal artery	Jugular foramen	Parapharyngeal region
	Hypoglossal nerve (n. XII)	Hypoglossal canal	Tongue
	Accessory nerve (n. XI, spinal root), Vertebral arteries, Anterior and posterior spinal arteries, Medulla oblongata	Foramen magnum	Base of skull



Base of the skull (inferior aspect).



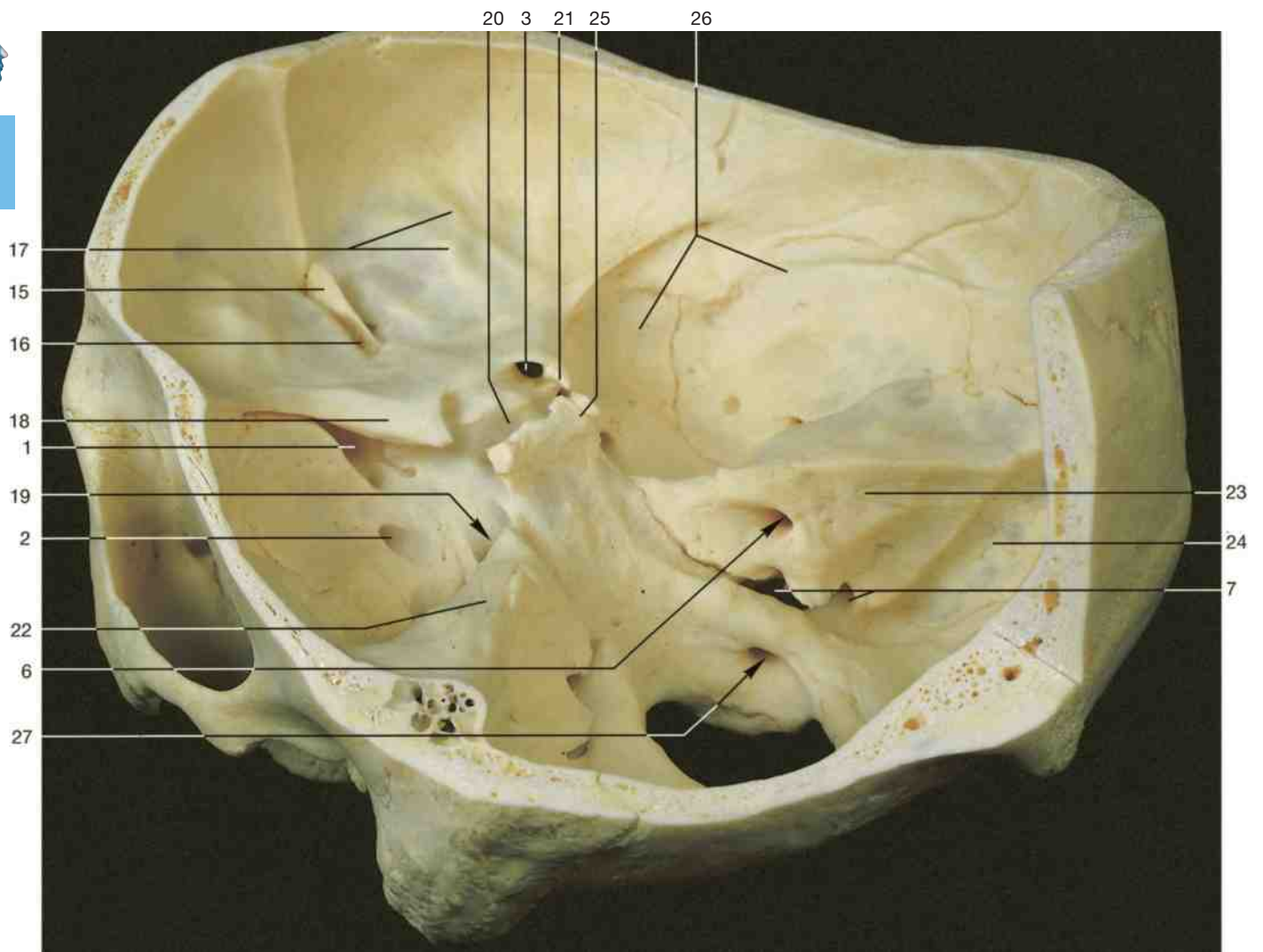
Base of the skull (from below). The individual bones are indicated by different colors.



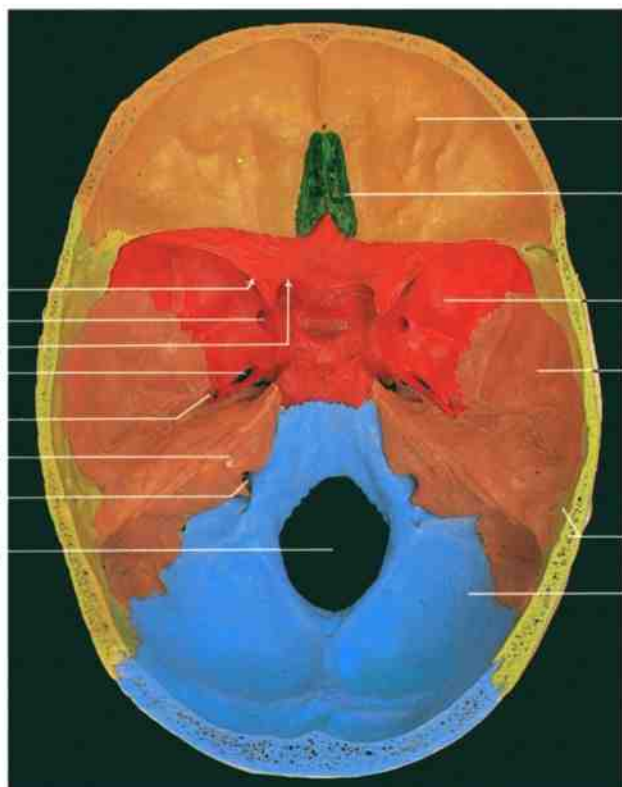
Skull of the newborn (inferior aspect).

- A = pterygoid canal
- B = foramen ovale
- C = internal carotid artery within **carotid canal** and internal jugular vein within the venous part of jugular foramen
- D = stylomastoid foramen (facial nerve)
- E = jugular foramen (glossopharyngeal, vagus and accessory nerves)
- F = hypoglossal canal (hypoglossal nerve)

- 1 Incisive canal
- 2 Median palatine suture
- 3 Palatine process of maxilla
- 4 Palatomaxillary suture
- 5 Greater and lesser palatine foramina
- 6 Inferior orbital fissure
- 7 Middle concha (process of ethmoidal bone)
- 8 Vomer
- 9 Foramen ovale
- 10 Groove for auditory tube
- 11 Pterygoid canal
- 12 Styloid process
- 13 Carotid canal
- 14 Stylomastoid foramen
- 15 Jugular foramen
- 16 Groove for occipital artery
- 17 Occipital condyle
- 18 Condylar canal
- 19 Nuchal plane
- 20 External occipital protuberance
- 21 Zygomatic arch
- 22 Lateral pterygoid plate
- 23 Medial pterygoid plate
- 24 Mandibular fossa
- 25 Pharyngeal tubercle
- 26 Superior nuchal line
- 27 Mastoid process
- 28 Inferior nuchal line
- 29 Mastoid notch
- 30 Foramen magnum
- 31 Incisive bone or premaxilla (dark violet)
- 32 Maxilla (violet)
- 33 Palatine bone (white)
- 34 Vomer (orange)
- 35 Sphenoidal bone (red)
- 36 Zygomatic bone (yellow)
- 37 Temporal bone (brown)
- 38 Occipital bone (blue)
- 39 Palatine process of maxilla
- 40 Vomer
- 41 Sphenoidal bone
- 42 Petrous part of temporal bone
- 43 Basilar part
- 44 Lateral part
- 45 Squamous part
- 46 Mandible
- 47 Zygomatic arch
- 48 Choana
- 49 Pterygoid process of sphenoidal bone
- 50 Carotid canal
- 51 External acoustic meatus (tympenic anulus)
- 52 Sphenoidal fontanelle
- 53 Parietal bone
- 54 Mastoid fontanelle



Base of the skull (internal aspect, oblique lateral view from left side).



Canals, fissures, and foramina of the base of the skull

- 1 Superior orbital fissure
- 2 Foramen rotundum
- 3 Optic canal
- 4 Foramen ovale
- 5 Foramen spinosum
- 6 Internal acoustic meatus
- 7 Jugular foramen
- 8 Foramen magnum

Bones

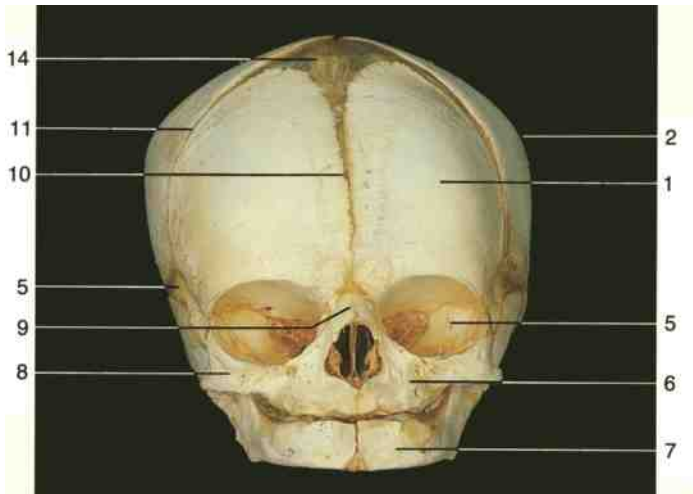
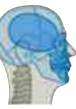- 9 Frontal bone (orange)
- 10 Ethmoidal bone (dark green)
- 11 Sphenoidal bone (red)
- 12 Temporal bone (brown)
- 13 Parietal bone (yellow)
- 14 Occipital bone (blue)

Details of bones

- 15 Crista galli
- 16 Cribriform plate

- 17 Digitate impressions (frontal bone)
- 18 Lesser wing of sphenoidal bone
- 19 Foramen lacerum
- 20 Hypophysial fossa (sella turcica)
- 21 Anterior clinoid process
- 22 Trigeminal impression
- 23 Petrous part of temporal bone
- 24 Groove for sigmoid sinus
- 25 Dorsum sellae (posterior clinoid process)
- 26 Greater wing of sphenoidal bone, groove for middle meningeal artery
- 27 Hypoglossal canal

Base of the skull (internal aspect, superior view). Individual bones indicated by color.



Skull of the newborn (anterior aspect).

Cranial skeleton

- 1 Frontal tuber or eminence
- 2 Parietal tuber or eminence
- 3 Occipital tuber or eminence
- 4 Squamous part of temporal bone
- 5 Greater wing of sphenoidal bone

Facial skeleton

- 6 Maxilla
- 7 Mandible
- 8 Zygomatic bone
- 9 Nasal bone


Sutures and fontanelles

- 10 Frontal suture
- 11 Coronal suture
- 12 Sagittal suture
- 13 Lambdoid suture
- 14 Anterior fontanelle
- 15 Posterior fontanelle
- 16 Sphenoidal (anterolateral) fontanelle
- 17 Mastoid (posterolateral) fontanelle

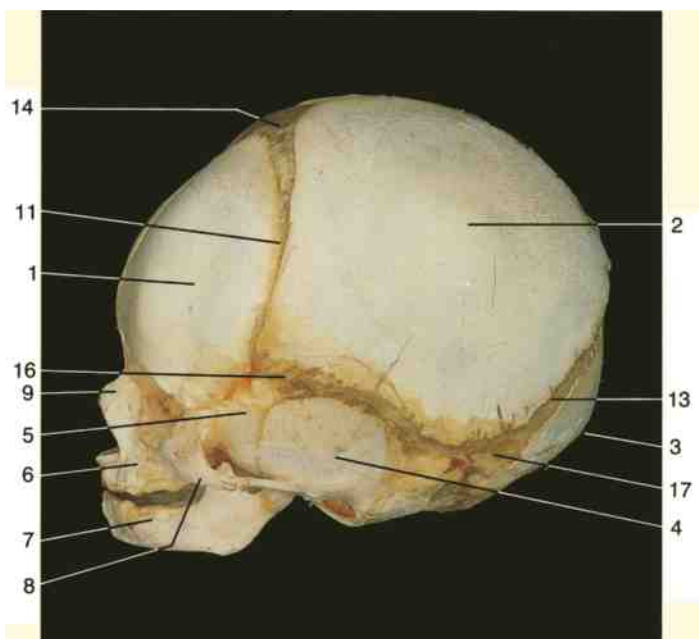
Base of the skull

- 18 Frontal bone
- 19 Ethmoidal bone
- 20 Sphenoidal bone
- 21 Hypophysial fossa (sella turcica)
- 22 Dorsum sellae
- 23 Temporal bone
- 24 Mastoid (posterolateral) fontanelle
- 25 Occipital bone

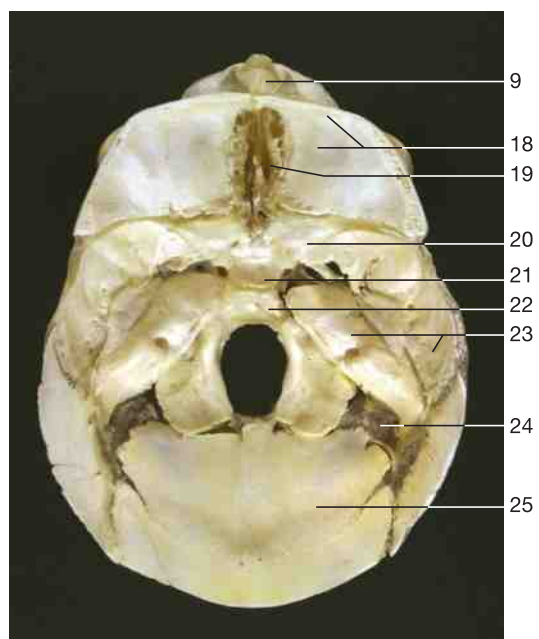
In the newborn, the facial skeleton, in contrast to the cranial skeleton, appears relatively small. There are no teeth presenting. The bones of the cranium are separated by wide fontanelles.



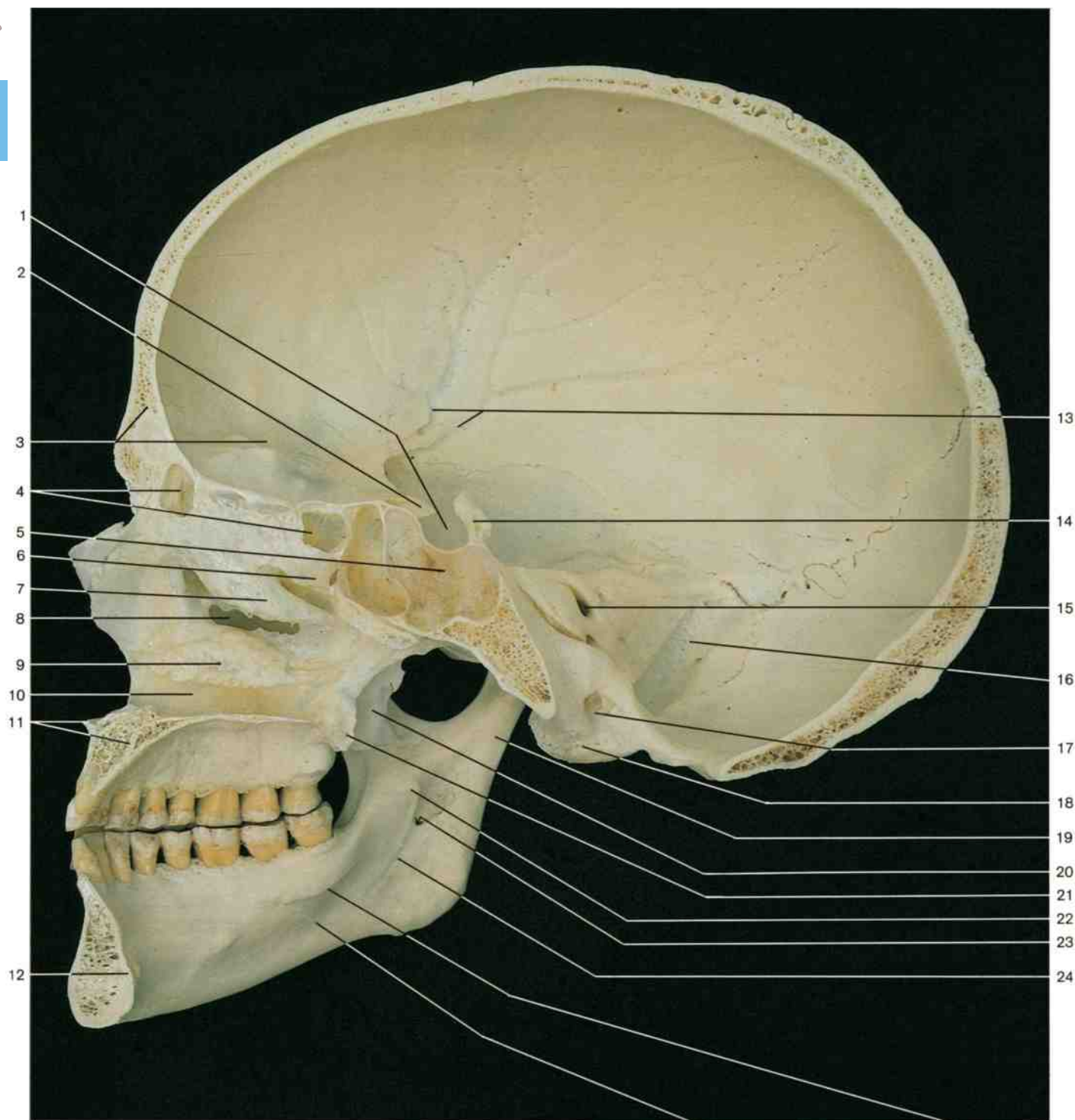
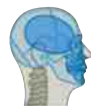Skull of the newborn (superior aspect). Calvaria.



Skull of the newborn (lateral aspect).

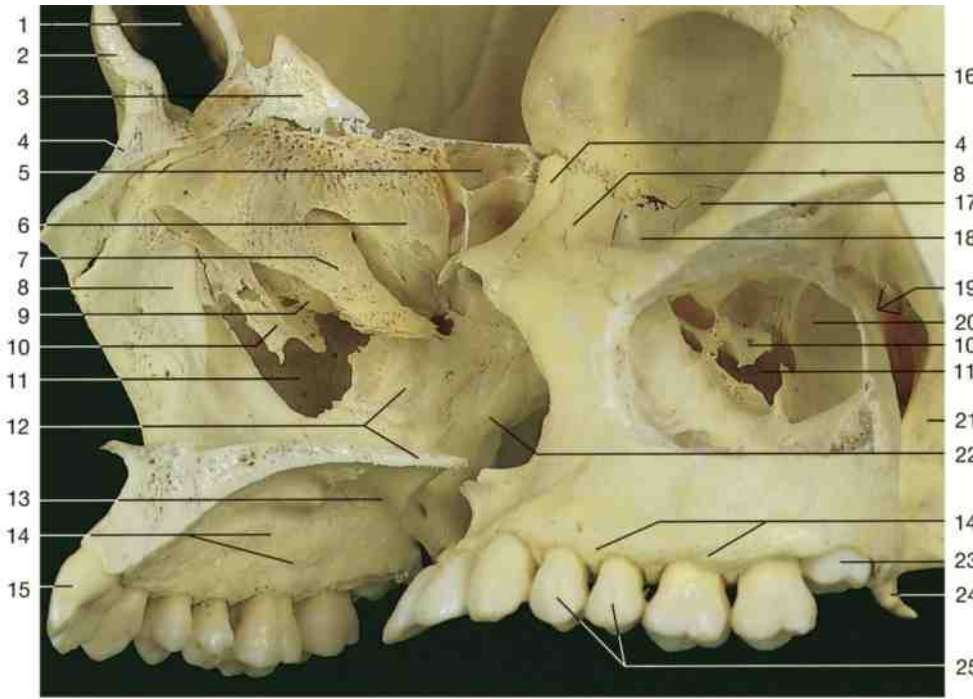


Base of the skull of the newborn (internal aspect).



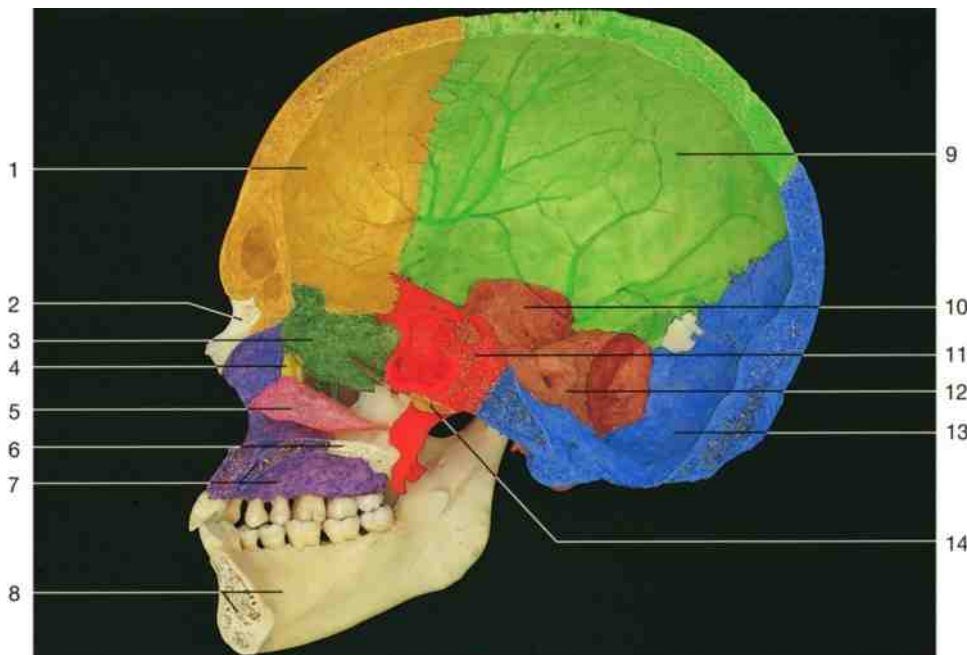
Median section through the skull, right half (internal aspect).

- | | | |
|---------------------------------------|-----------------------------|------------------------|
| 1 Hypophysial fossa (sella turcica) | 14 Dorsum sellae | |
| 2 Anterior clinoid process | 15 Internal acoustic meatus | |
| 3 Frontal bone | 16 Groove for sigmoid sinus | |
| 4 Ethmoidal air cells | 17 Hypoglossal canal | |
| 5 Sphenoidal sinus | 18 Occipital condyle | |
| 6 Superior concha | 19 Condylar process | |
| 7 Middle concha | 20 Lateral pterygoid plate | |
| 8 Maxillary hiatus | 21 Medial pterygoid plate | } of pterygoid process |
| 9 Inferior concha | 22 Lingula of mandible | |
| 10 Inferior meatus | 23 Mandibular foramen | |
| 11 Anterior nasal spine and maxilla | 24 Mylohyoid groove | |
| 12 Mental spine or genial tubercle | 25 Mylohyoid line | |
| 13 Groove for middle meningeal artery | 26 Submandibular fovea | |



- 1 Frontal sinus
- 2 Frontal bone
- 3 Crista galli
- 4 Nasal bone
- 5 Sphenoidal sinus
- 6 Superior concha } of ethmoidal
- 7 Middle concha } bone
- 8 Frontal process of maxilla
- 9 Ethmoidal bulla
- 10 Uncinate process
- 11 Maxillary hiatus
- 12 Palatine bone
- 13 Greater palatine foramen
- 14 Alveolar process of maxilla
- 15 Central incisor
- 16 Zygomatic bone
- 17 Ethmoidal bone
- 18 Lacrimal bone
- 19 Pterygopalatine fossa
- 20 Maxillary sinus
- 21 Lateral pterygoid plate
- 22 Medial pterygoid plate
- 23 Third molar tooth
- 24 Pterygoid hamulus
- 25 Two premolar teeth

Facial part of the skull (viscerocranium), divided in two halves (lateral and medial aspect). Right inferior concha has been removed to show the maxillary hiatus. Left maxillary sinus opened.




- Bones** (indicated by colors)
- 1 Frontal bone (yellow)
 - 2 Nasal bone (white)
 - 3 Ethmoidal bone (dark green)
 - 4 Lacrimal bone (yellow)
 - 5 Inferior nasal concha (pink)
 - 6 Palatine bone (white)
 - 7 Maxilla (violet)
 - 8 Mandible (white)
 - 9 Parietal bone (light green)
 - 10 Temporal bone (brown)
 - 11 Sphenoidal bone (red)
 - 12 Petrous part of temporal bone (brown)
 - 13 Occipital bone (blue)
 - 14 Ala of vomer (light brown)

Median section through the skull. The nasal septum has been removed. Bones indicated by colors.

Because of the upright posture that the human developed in the course of evolution, the cranial cavity greatly increased in size, whereas the facial skeleton decreased. As a result, the base of the skull developed an angulation of

about 120° between the clivus and the cribriform plate (see drawing on page 19). The hypophysial fossa containing the pituitary gland lies at the angle formed between these two planes.



Ethmoidal bone

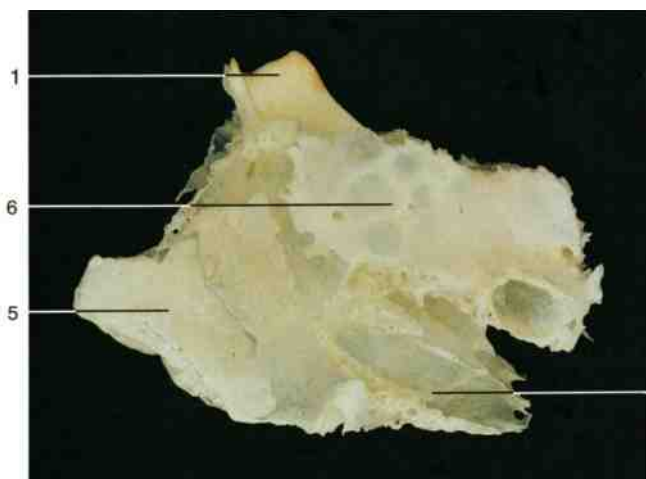
- 1 Crista galli
- 2 Cribriform plate
- 3 Ethmoidal air cells
- 4 Middle concha
- 5 Perpendicular plate (part of nasal septum)
- 6 Orbital plate

Sphenoidal bone

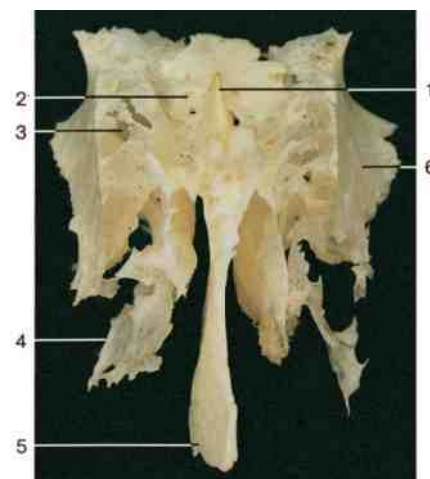
- 7 Lesser wing
- 8 Greater wing
- 9 Anterior clinoid process
- 10 Posterior clinoid process
- 11 Foramen ovale
- 12 Foramen spinosum
- 13 Lingula of the sphenoidal bone
- 14 Clivus
- 15 Optic canal
- 16 Tuberculum sellae
- 17 Foramen rotundum (right side)
- 18 Hypophysial fossa (sella turcica)
- 19 Dorsum sellae
- 20 Carotid sulcus
- 21 Spheno-occipital synchondrosis
- 22 Lateral pterygoid plate
- 23 Greater wing of sphenoidal bone (orbital surface)
- 24 Greater wing of sphenoidal bone (maxillary surface)
- 25 Foramen rotundum (left side)
- 26 Superior orbital fissure
- 27 Infratemporal crest of the greater wing

Part of the disarticulated base of the skull.

Ethmoidal, sphenoidal, and occipital bones (from above).
Green = sphenoidal bone; yellow = ethmoidal bone.



Ethmoidal bone (lateral aspect), posterior portion to the right.



Ethmoidal bone (anterior aspect).



Occipital bone

- 28 Jugular tubercle
- 29 Jugular process
- 30 Mastoid margin
- 31 Posterior cranial fossa
- 32 Lambdoid margin
- 33 Intrajugular process
- 34 Condylar canal
- 35 Lateral part of occipital bone
- 36 Hypoglossal canal
- 37 Foramen magnum
- 38 Internal occipital crest
- 39 Squamous part of occipital bone
- 40 Internal occipital protuberance

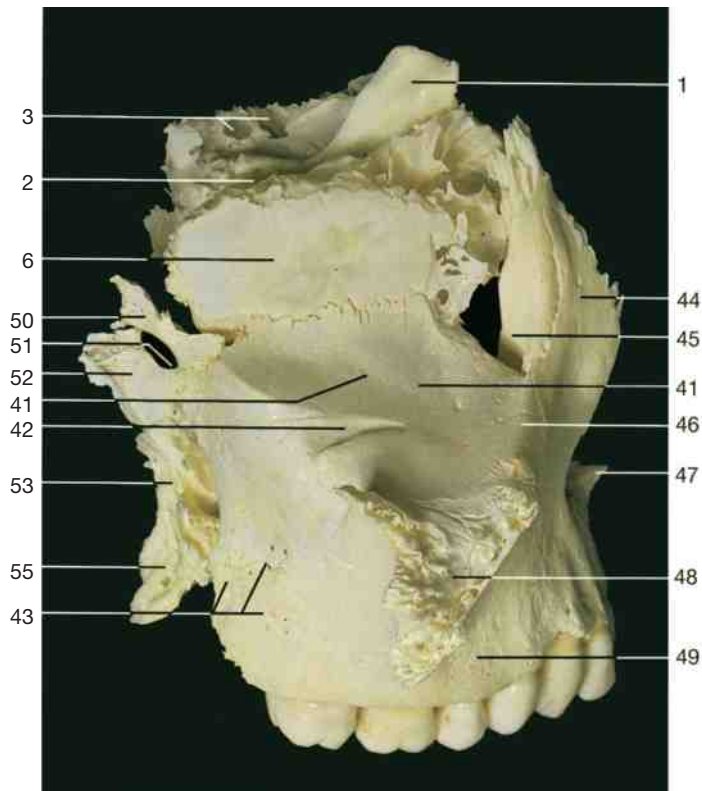
Maxilla

- 41 Orbital surface
- 42 Infra-orbital groove
- 43 Maxillary tuberosity with foramina
- 44 Frontal process
- 45 Nasolacrimal groove
- 46 Infra-orbital margin
- 47 Anterior nasal spine
- 48 Zygomatic process
- 49 Alveolar process

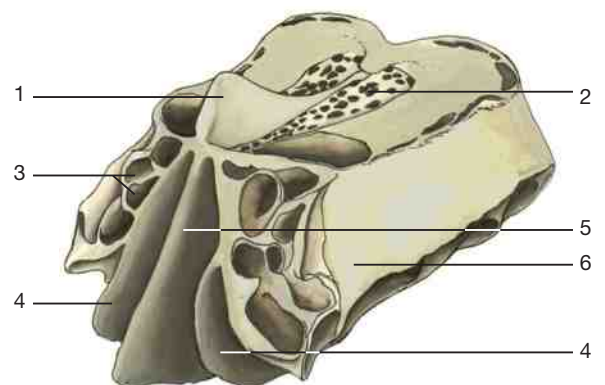
Palatine bone

- 50 Orbital process
- 51 Sphenopalatine notch
- 52 Sphenoidal process
- 53 Perpendicular plate
- 54 Horizontal plate
- 55 Pyramidal process

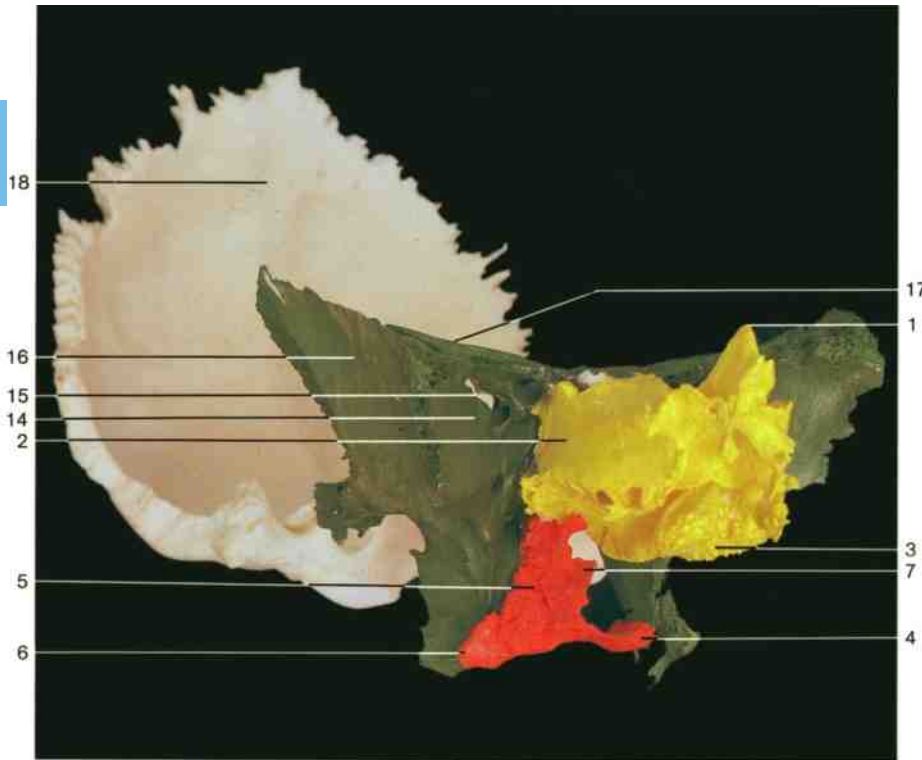
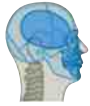Disarticulated base of the skull (anterior aspect). Green = sphenoidal bone; yellow = ethmoidal bone; red = palatine bone.



Right maxilla, ethmoidal, and palatine bone (lateral aspect).



Ethmoidal bone (oblique anterior aspect). (Schematic drawing.)



Ethmoidal bone

- 1 Crista galli
- 2 Orbital plate
- 3 Middle concha

Palatine bone

- 4 Horizontal plate of palatine bone
- 5 Greater palatine canal
- 6 Pyramidal process
- 7 Maxillary process
- 8 Orbital process
- 9 Sphenopalatine notch
- 10 Perpendicular plate of palatine bone
- 11 Conchal crest
- 12 Nasal crest
- 13 Sphenoidal process

Sphenoidal bone

- 14 Greater wing
- 15 Superior orbital fissure
- 16 Greater wing (orbital surface)
- 17 Lesser wing

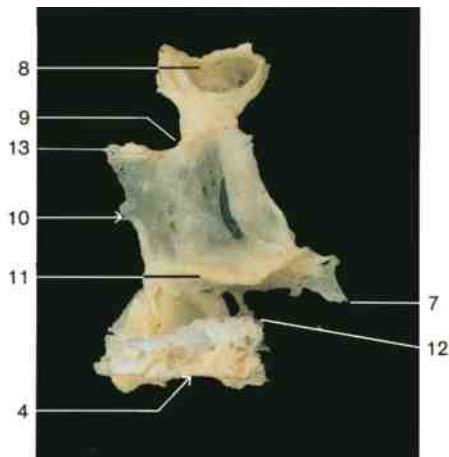
Occipital bone

- 18 Squamous part of occipital bone

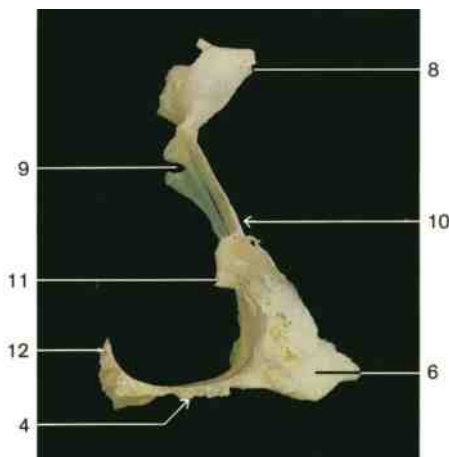
Maxilla

- 19 Maxillary tuberosity
- 20 Frontal process
- 21 Orbital surface
- 22 Infra-orbital margin
- 23 Infra-orbital groove
- 24 Zygomatic process
- 25 Alveolar process

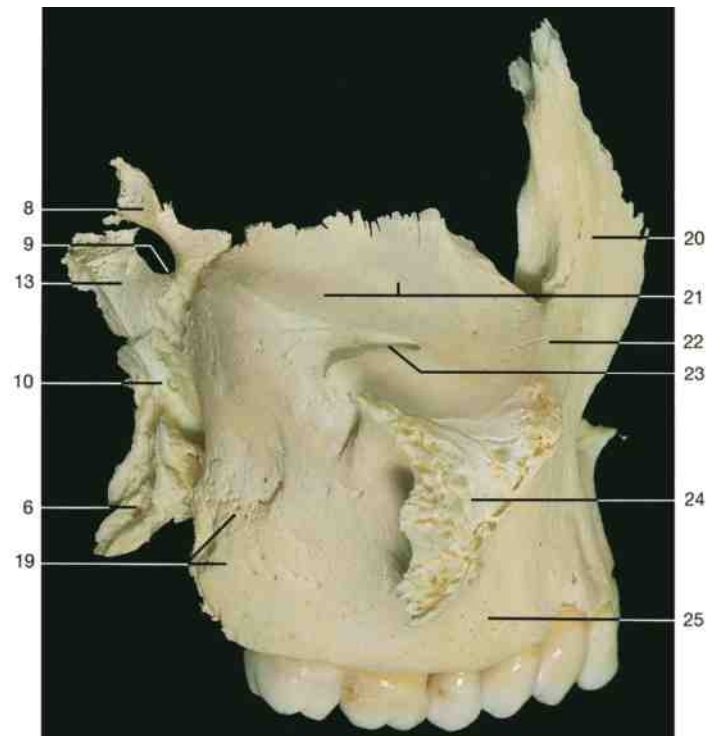
Part of a disarticulated skull base, similar to the preceding figures, but with palatine bone. Green = sphenoidal bone; yellow = ethmoidal bone; red = palatine bone.



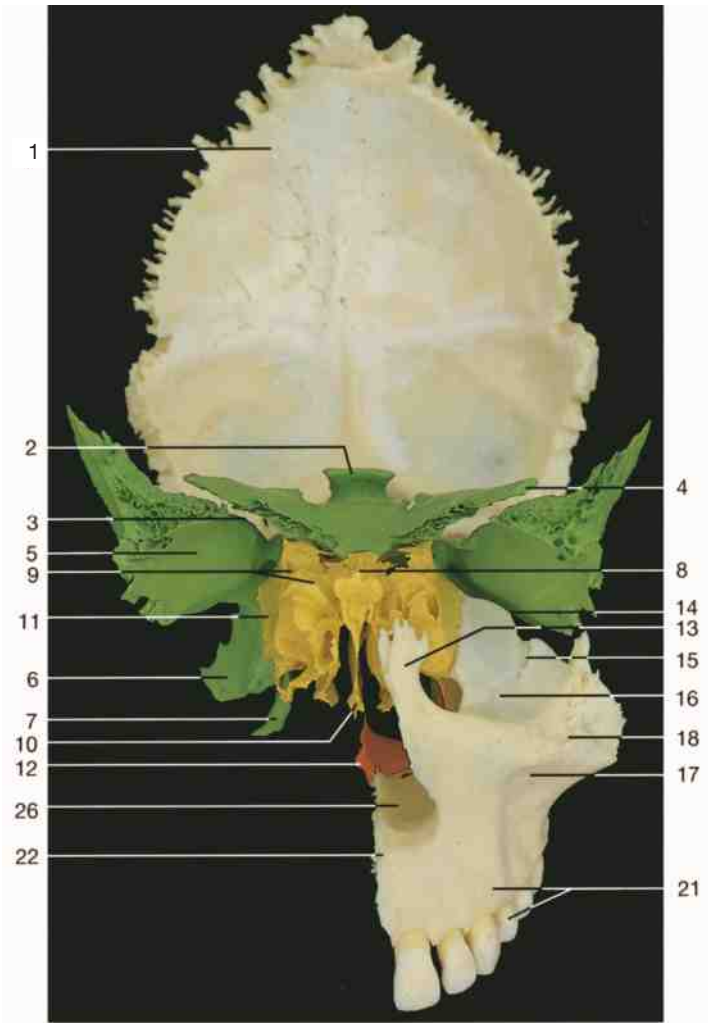
Left palatine bone (medial aspect, posterior aspect to the left).



Left palatine bone (anterior aspect).



Right maxilla and right palatine bone (lateral aspect).



Occipital bone

- 1 Squamous part

Sphenoidal bone

- 2 Dorsum sellae
- 3 Superior orbital fissure
- 4 Lesser wing
- 5 Greater wing (orbital surface)
- 6 Lateral pterygoid plate
- 7 Medial pterygoid plate

Ethmoidal bone

- 8 Crista galli
- 9 Ethmoidal air cells
- 10 Perpendicular plate
- 11 Orbital plate

Palatine bone

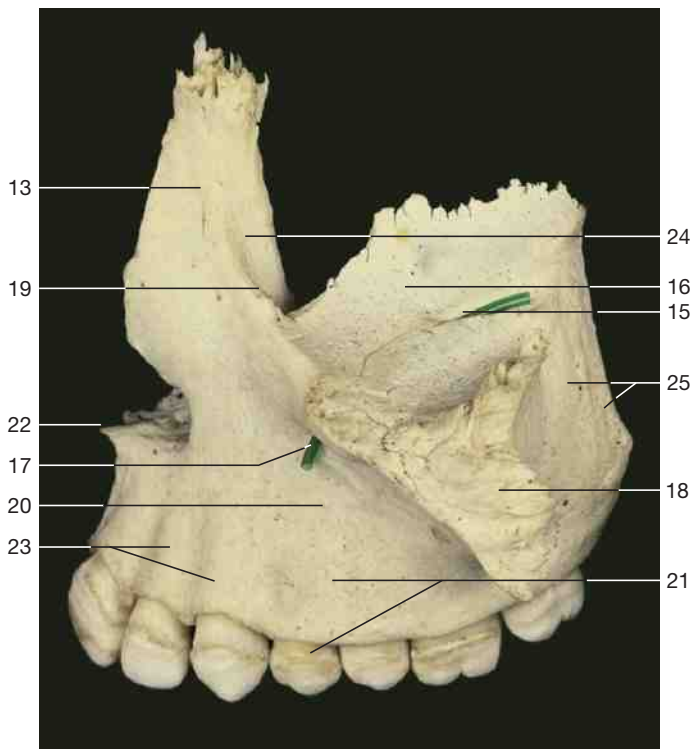
- 12 Horizontal plate (nasal crest)

Maxilla

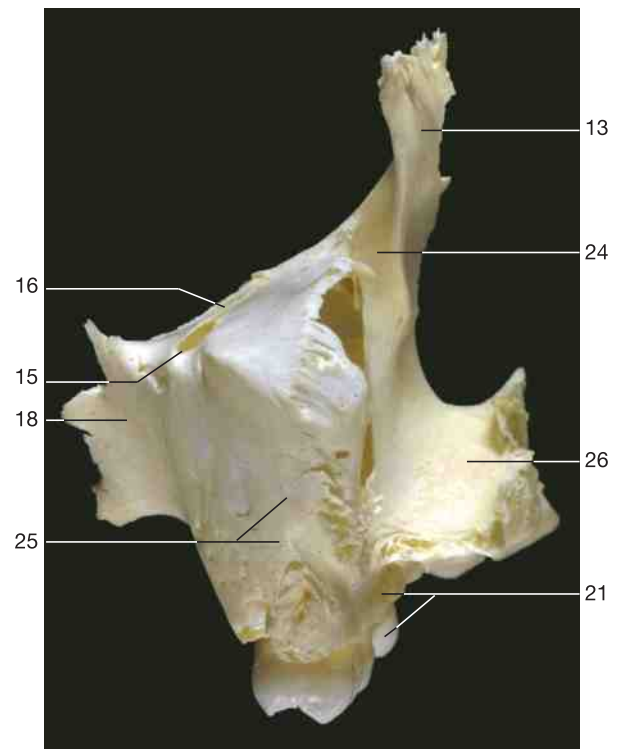
- 13 Frontal process
- 14 Inferior orbital fissure
- 15 Infra-orbital groove
- 16 Orbital surface
- 17 Infra-orbital foramen
- 18 Zygomatic process
- 19 Anterior lacrimal crest
- 20 Canine fossa
- 21 Alveolar process with teeth
- 22 Anterior nasal spine
- 23 Juga alveolaria (elevations formed by roots of teeth)
- 24 Lacrimal groove
- 25 Maxillary tuberosity with alveolar foramina
- 26 Palatine process of maxilla

Part of a disarticulated skull.

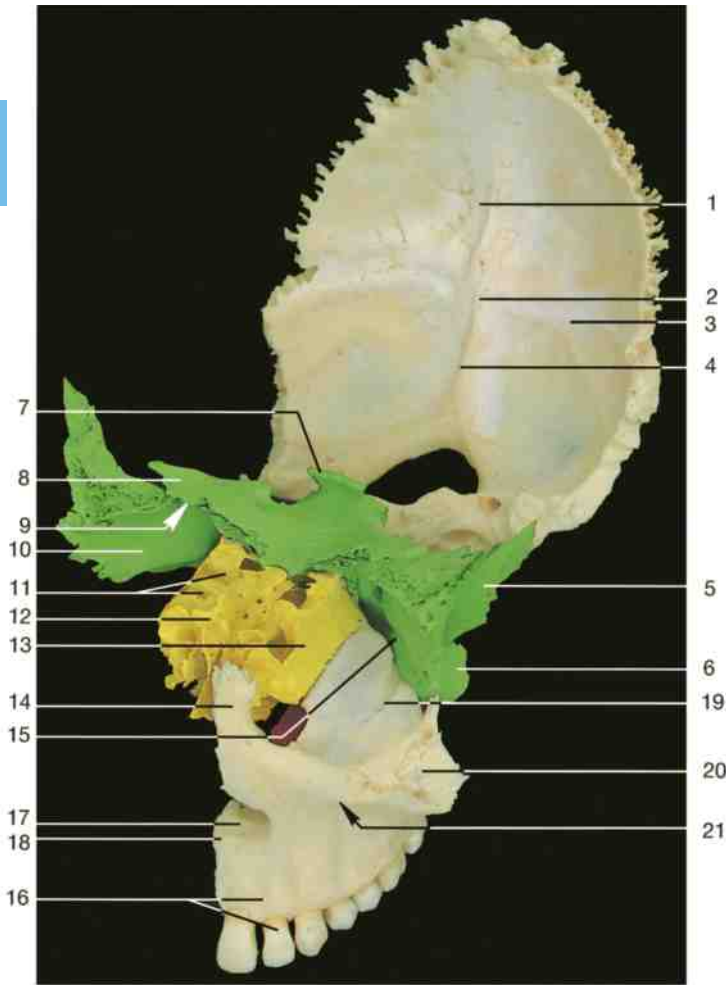
The left maxilla is added to the preceding specimen.



Left maxilla (lateral aspect). Probe = infra-orbital canal.



Left maxilla (posterior aspect).



Part of a disarticulated base of skull. The mosaic of the facial bones [sphenoidal bone (green), ethmoidal bone (yellow), and palatine bone (red)] is seen from the antero-lateral aspect.

Occipital bone

- 1 Groove for superior sagittal sinus
- 2 Internal occipital protuberance
- 3 Groove for transverse sinus
- 4 Internal occipital crest

Sphenoidal bone

- 5 Greater wing (temporal surface)
- 6 Lateral pterygoid plate
- 7 Dorsum sellae
- 8 Lesser wing
- 9 Superior orbital fissure
- 10 Greater wing (orbital surface)

Ethmoidal bone

- 11 Ethmoidal air cells
- 12 Crista galli
- 13 Orbital plate

Maxilla

- 14 Frontal process
- 15 Inferior orbital fissure
- 16 Alveolar process with teeth
- 17 Palatine process
- 18 Anterior nasal spine
- 19 Infra-orbital groove
- 20 Zygomatic process
- 21 Location of infra-orbital foramen
- 22 Middle nasal meatus
- 23 Inferior nasal meatus
- 24 Maxillary hiatus (leading to maxillary sinus)
- 25 Third molar
- 26 Lacrimal groove
- 27 Conchal crest
- 28 Body of maxilla (nasal surface)
- 29 Nasal crest
- 30 Incisive canal

Palatine bone

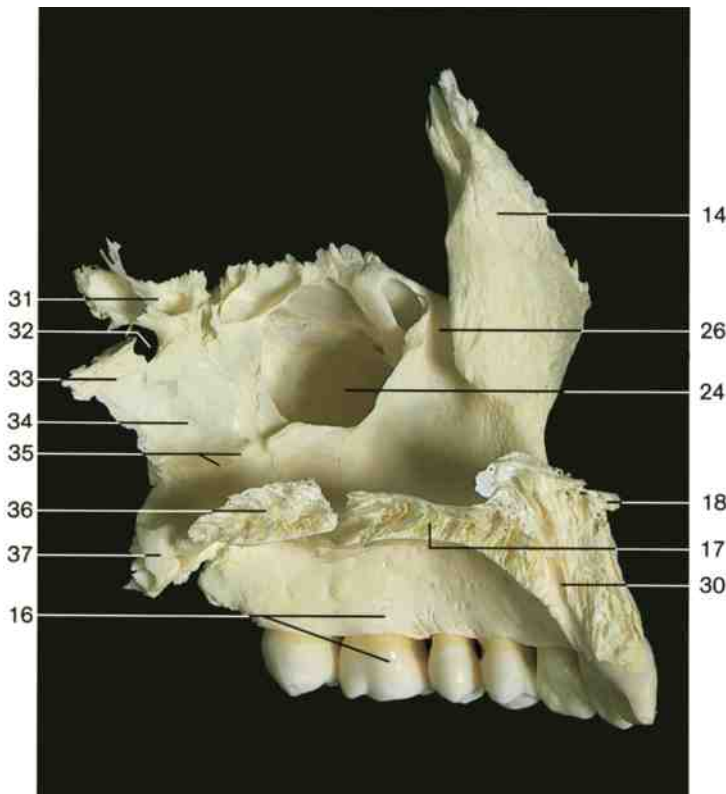
- 31 Orbital process
- 32 Sphenopalatine notch
- 33 Sphenoidal process
- 34 Perpendicular plate
- 35 Conchal crest
- 36 Horizontal plate
- 37 Pyramidal process

Frontal bone

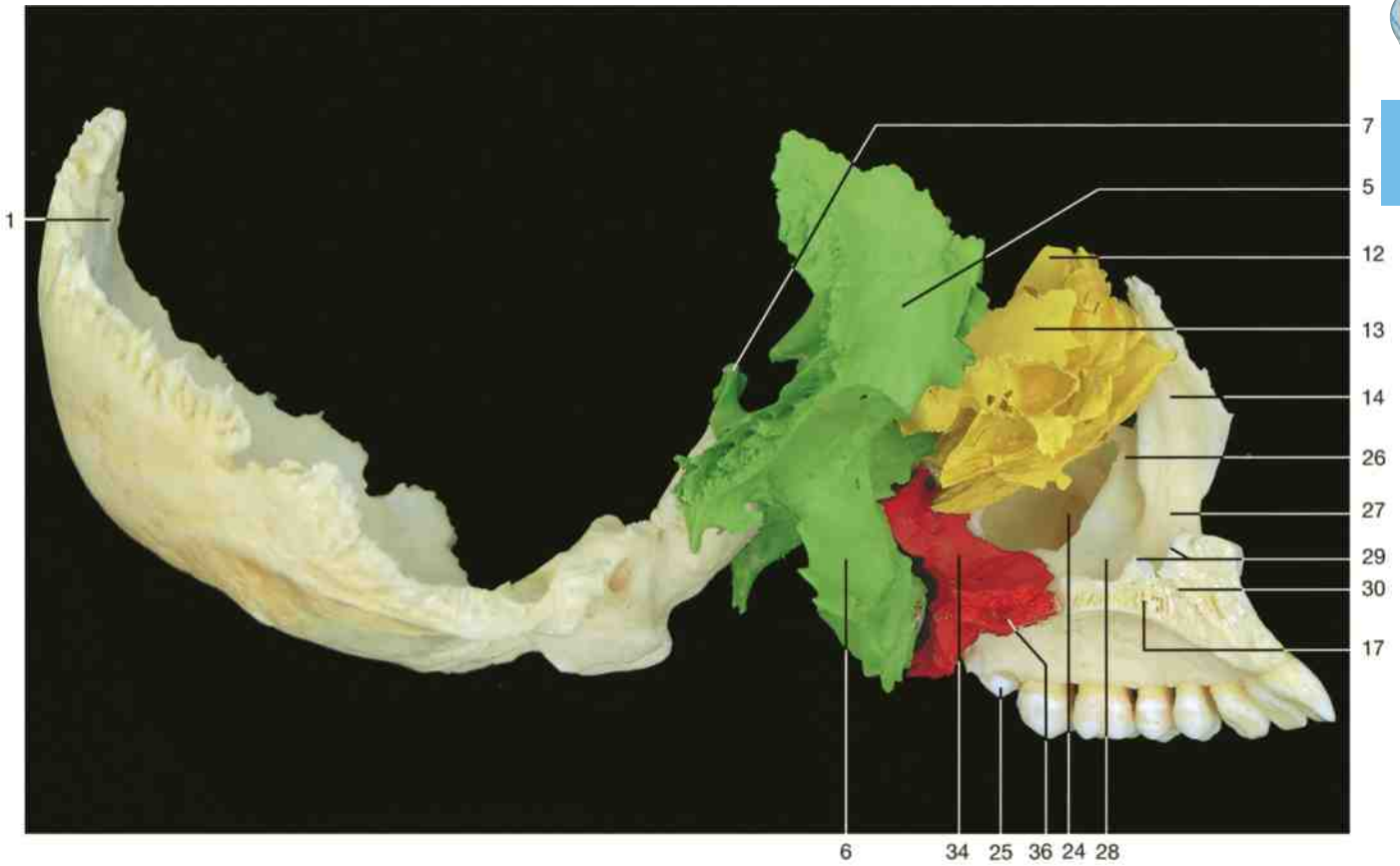
- 38 Squamous part
- 39 Supra-orbital foramen
- 40 Frontal notch
- 41 Frontal spine

Inferior nasal concha

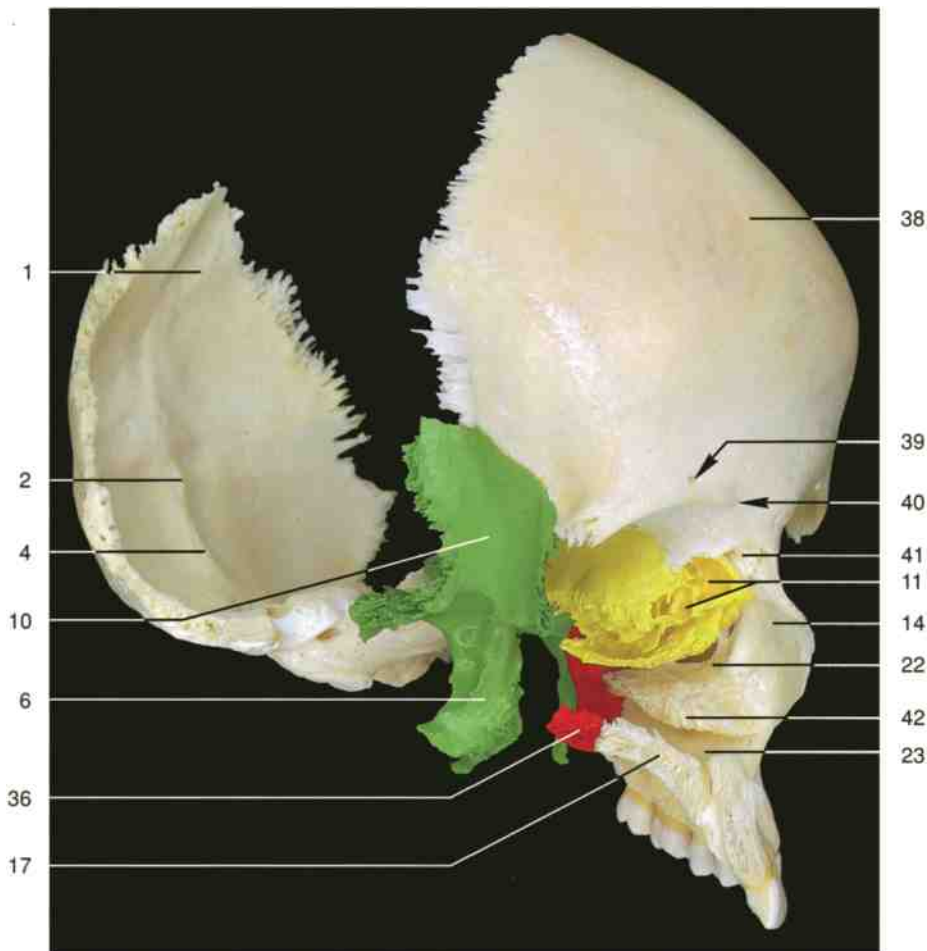
- 42 Inferior nasal concha with maxillary process



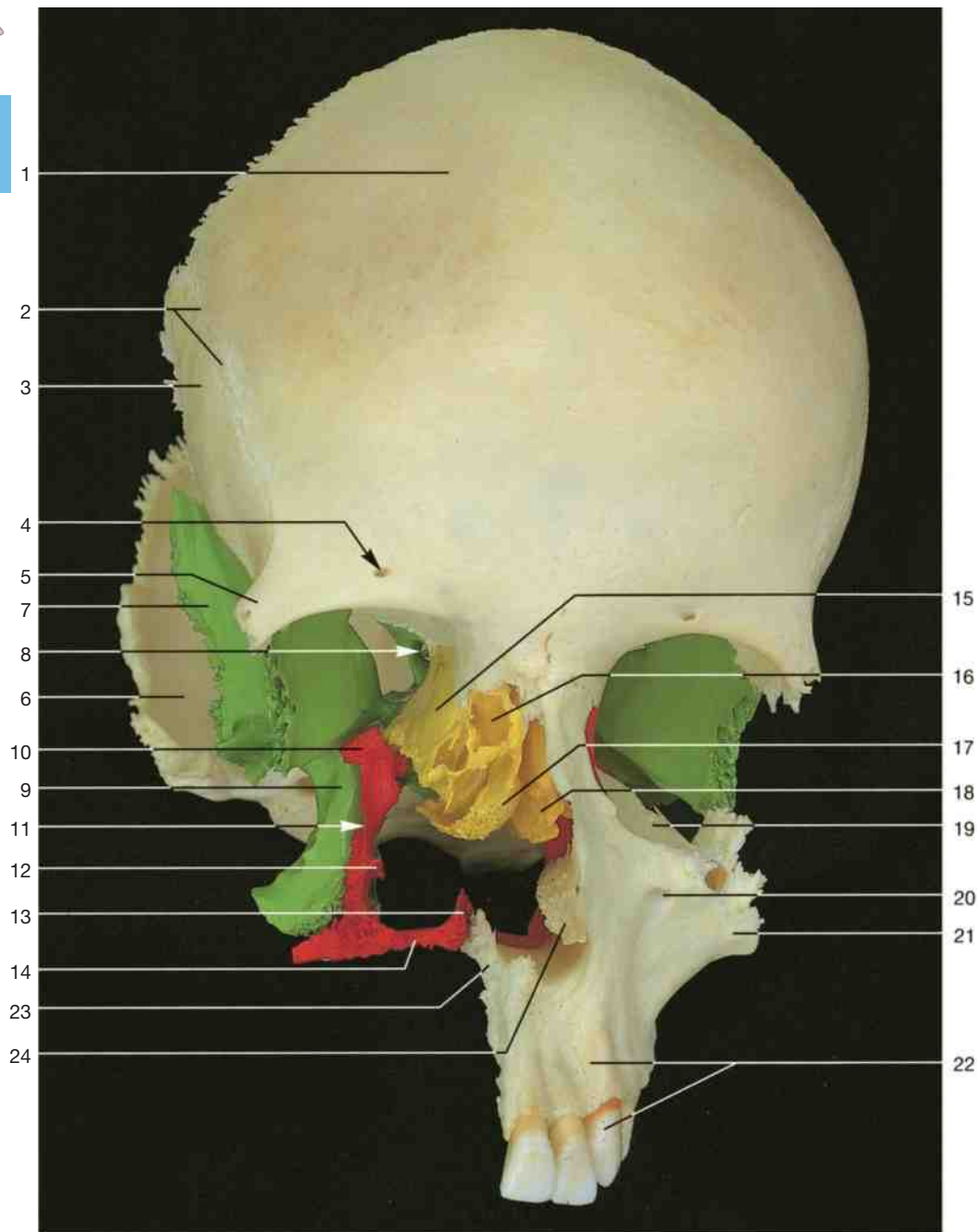
Left maxilla and palatine bone (medial aspect).



Part of a disarticulated base of skull (medial aspect). Green = sphenoidal bone; yellow = ethmoidal bone; red = palatine bone; natural colored = left maxilla.



Part of a disarticulated base of skull. The same specimen as shown above but with frontal bone (oblique-lateral aspect).



Part of a disarticulated skull showing the connection of the palatine bone (red) and the maxilla with ethmoidal bone (yellow) and sphenoidal bone (green) (anterior aspect).

Frontal bone

- 1 Squamous part
- 2 Inferior temporal line
- 3 Temporal surface
- 4 Supra-orbital foramen
- 5 Zygomatic process

Occipital bone

- 6 Squamous part

Sphenoidal bone

- 7 Greater wing (temporal surface)
- 8 Optic canal within the lesser wing
- 9 Lateral pterygoid plate

Palatine bone

- 10 Orbital process
- 11 Perpendicular plate
- 12 Conchal crest
- 13 Nasal crest
- 14 Horizontal plate

Ethmoidal bone

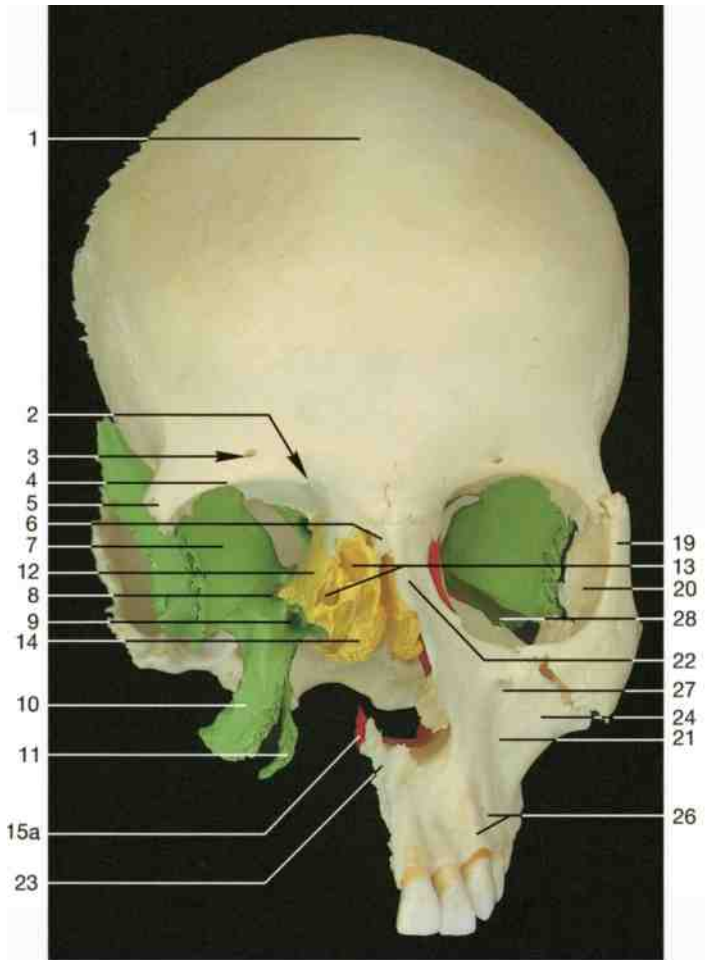
- 15 Orbital plate
- 16 Ethmoidal air cell
- 17 Middle concha
- 18 Perpendicular plate (part of bony nasal septum)

Maxilla

- 19 Infra-orbital groove
- 20 Infra-orbital foramen
- 21 Zygomatic process
- 22 Alveolar process with teeth
- 23 Palatine process

Left inferior nasal concha

- 24 Anterior part of inferior concha



Anterior view of a disarticulated skull showing the connection of the maxilla with the frontal and zygomatic bones. Yellow = ethmoidal bone; red = palatine bone; green = sphenoidal bone.

Frontal bone

- 1 Squamous part
- 2 Frontal notch
- 3 Supra-orbital foramen
- 4 Supra-orbital margin
- 5 Zygomatic process
- 6 Frontal spine

Sphenoidal bone

- 7 Greater wing (orbital surface)
- 8 Foramen rotundum
- 9 Pterygoid or Vidian canal
- 10 Lateral pterygoid plate
- 11 Medial pterygoid plate

Ethmoidal bone

- 12 Orbital plate
- 13 Ethmoidal air cells
- 14 Middle concha

Palatine bone

- 15 Horizontal plate
- 15a Nasal crest
- 16 Pyramidal process
- 17 Lesser palatine foramen
- 18 Greater palatine foramen

Zygomatic bone

- 19 Frontal process
- 20 Orbital surface

Maxilla

- 21 Canine fossa
- 22 Frontal process
- 23 Palatine process
- 24 Zygomatic process
- 25 Alveolar process and teeth
- 26 Juga alveolaria
- 27 Infra-orbital foramen
- 28 Infra-orbital groove
- 29 Anterior nasal aperture
- 30 Anterior nasal spine

Incisive bone

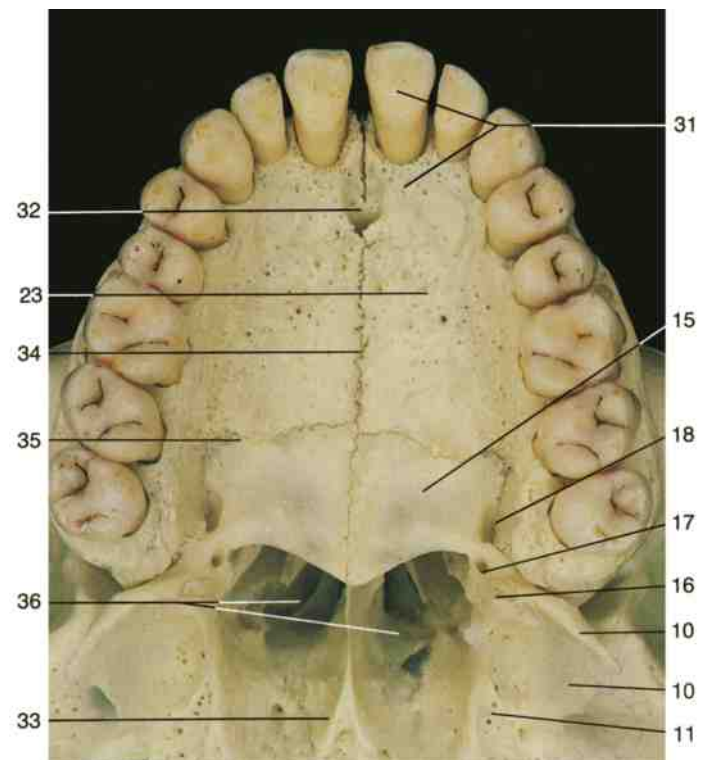
- 31 Central incisor and incisive bone or premaxilla
- 32 Incisive fossa

Vomer

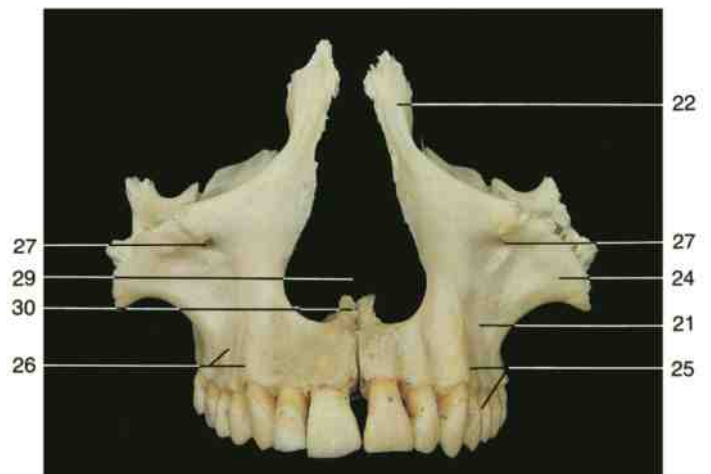
- 33 Ala of the vomer

Sutures and choanae

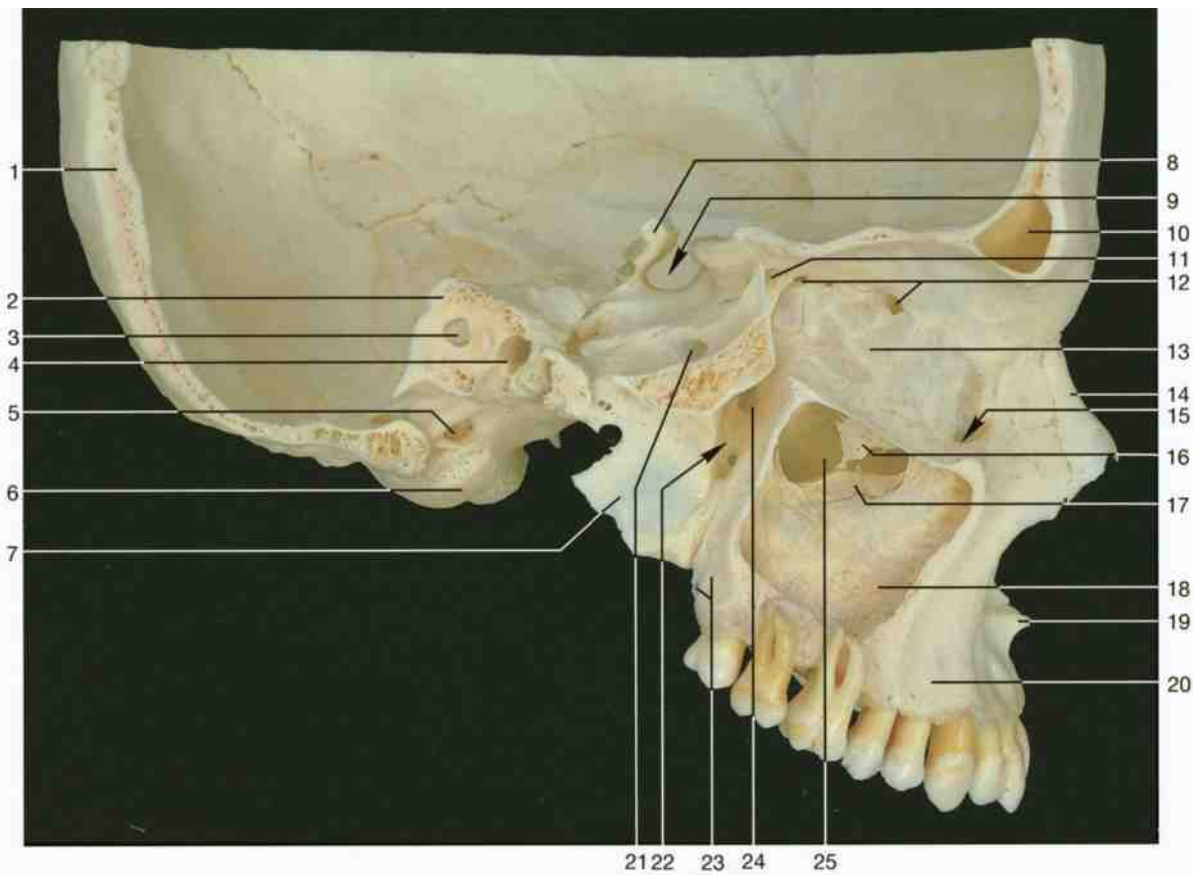
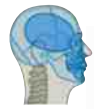- 34 Median palatine suture
- 35 Transverse palatine suture
- 36 Choanae



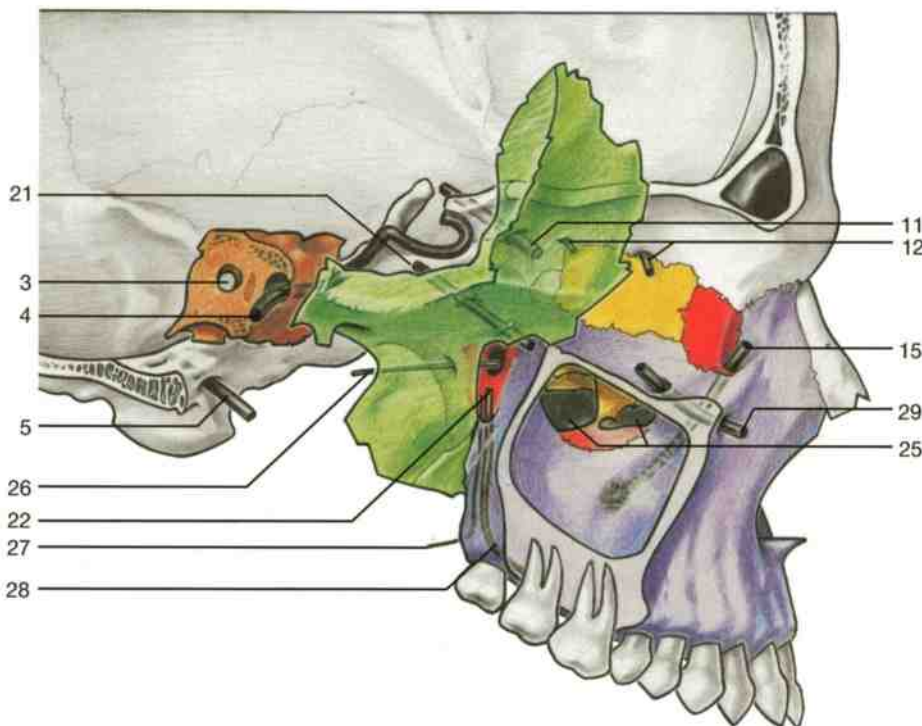
Bony palate and teeth of the maxillae (from below).



Anterior view of both maxillae forming the anterior bony aperture of the nose.

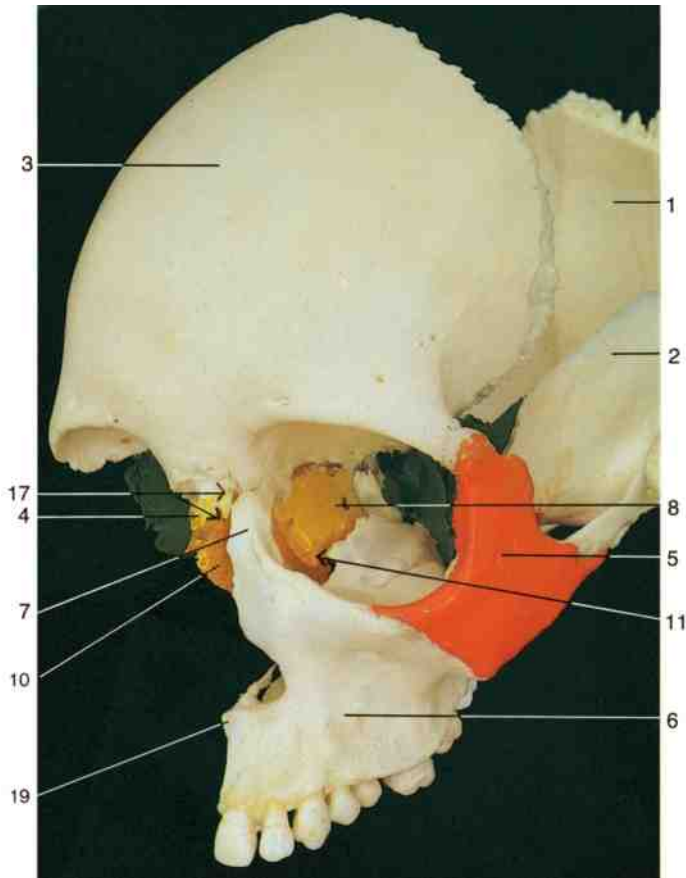


Paramedian section through the skull, right side (lateral aspect). Frontal and maxillary sinuses are opened.



- 1 Occipital bone
- 2 Temporal bone (petrous part)
- 3 Internal acoustic meatus
- 4 Carotid canal
- 5 Hypoglossal canal
- 6 Occipital condyle
- 7 Lateral plate of pterygoid process
- 8 Dorsum of sella turcica
- 9 Sella turcica
- 10 Frontal sinus
- 11 Optic canal
- 12 Posterior and anterior ethmoidal foramina
- 13 Orbital plate of ethmoidal bone
- 14 Nasal bone
- 15 Nasolacrimal canal
- 16 Uncinate process
- 17 Inferior nasal concha (maxillary process)
- 18 Maxillary sinus
- 19 Anterior nasal spine
- 20 Alveolar process of maxilla
- 21 Foramen rotundum
- 22 Pterygopalatine fossa
- 23 Tuberosity of maxilla with alveolar foramina
- 24 Sphenopalatine foramen
- 25 Maxillary hiatus
- 26 Pterygoid or Vidian canal
- 27 Lesser palatine canal
- 28 Greater palatine canal
- 29 Infra-orbital canal

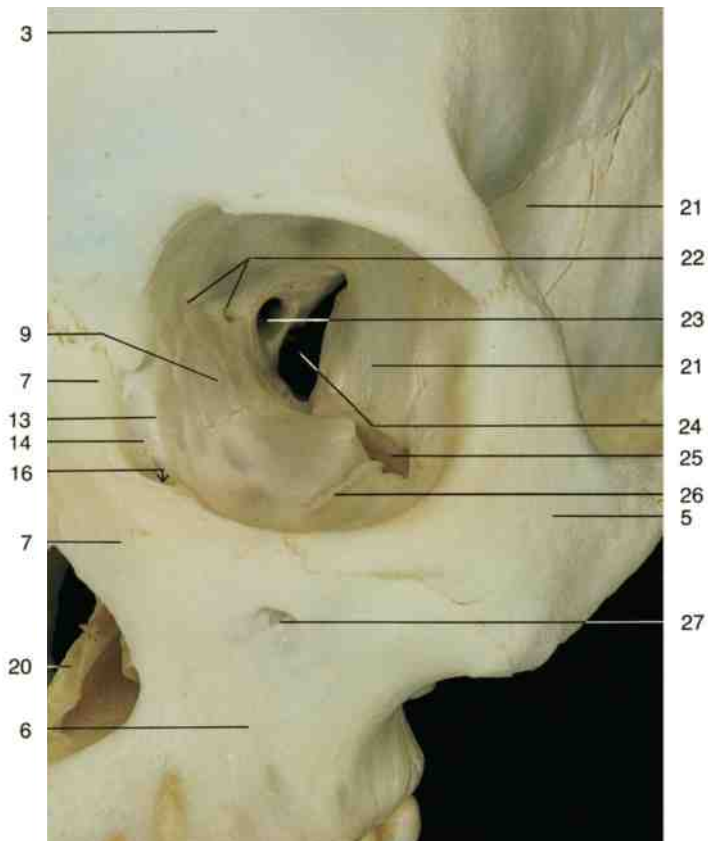
Illustration of canals and foramina connected with the right orbit and pterygopalatine fossa (compare the above figure). The greater wing of sphenoidal bone (green) is shown as being transparent. Brown = temporal bone; yellow = ethmoidal bone; red = lacrimal bone; light red = inferior nasal concha; violet = maxilla; red = palatine bone.



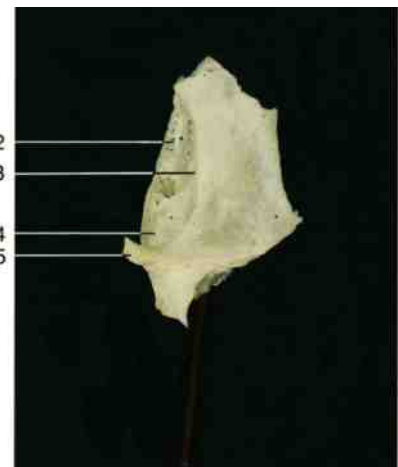
- 1 Occipital bone
- 2 Temporal bone
- 3 Frontal bone
- 4 Nasal spine of frontal bone
- 5 Zygomatic bone
- 6 Maxilla
- 7 Frontal process of maxilla
- 8 Ethmoidal bone
- 9 Orbital plate of ethmoidal bone
- 10 Perpendicular plate of ethmoidal bone
- 11 Site of lacrimal bone
- 12 Lacrimal groove of lacrimal bone
- 13 Posterior lacrimal crest
- 14 Fossa for lacrimal sac
- 15 Lacrimal hamulus
- 16 Nasolacrimal canal
- 17 Site of nasal bone
- 18 Nasal foramina of nasal bone
- 19 Anterior nasal spine of maxilla
- 20 Vomer
- 21 Greater wing of sphenoidal bone
- 22 Anterior and posterior ethmoidal foramina
- 23 Optic canal
- 24 Superior orbital fissure
- 25 Inferior orbital fissure
- 26 Infra-orbital groove
- 27 Infra-orbital foramen

Anterior part of a disarticulated skull.

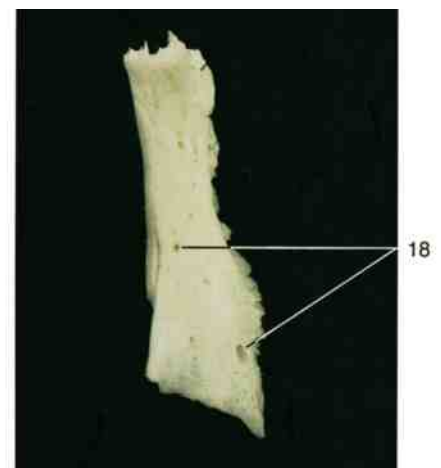
Orange = zygomatic bone; yellow = ethmoidal bone; dark green = sphenoidal bone. The arrows indicate the locations of the lacrimal bone (11) and the nasal bone (17).



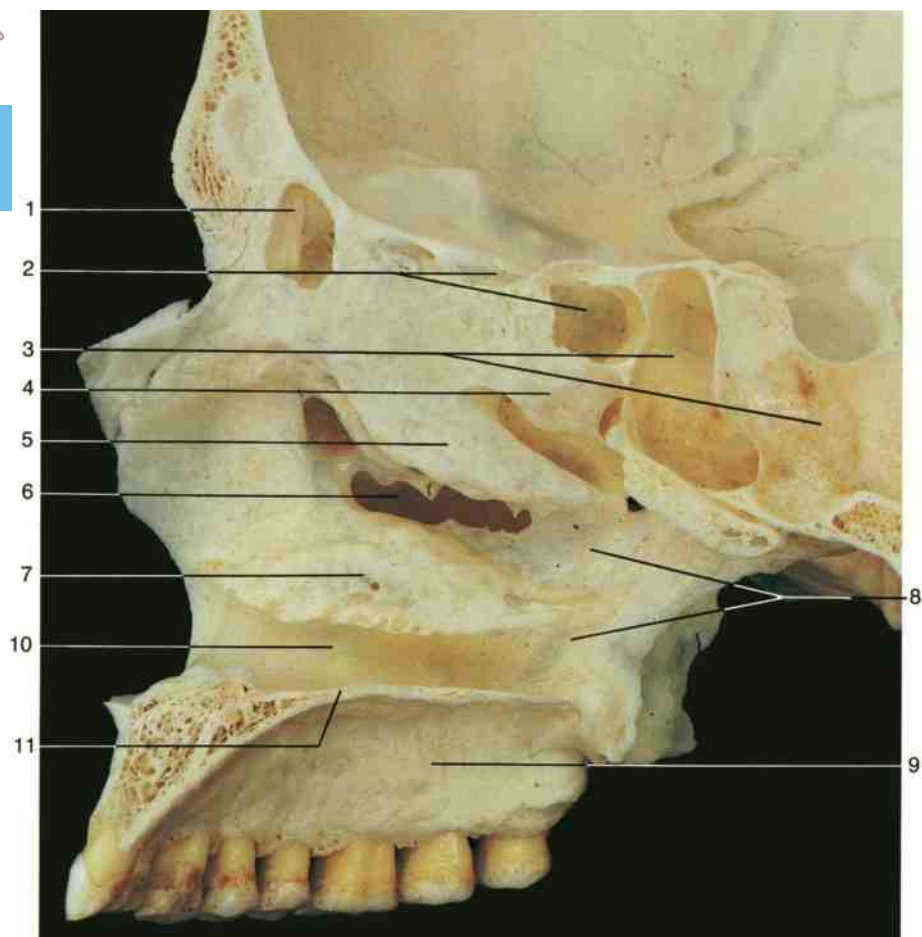
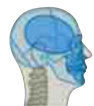Left orbit (anterior aspect).



Left lacrimal bone (anterior aspect).



Left nasal bone (anterior aspect).



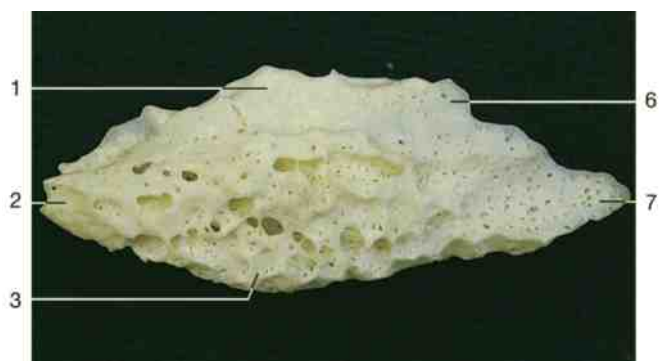
- 1 Frontal sinus
- 2 Ethmoidal air cells
- 3 Sphenoidal sinus
- 4 Superior nasal concha
- 5 Middle nasal concha
- 6 Maxillary hiatus
- 7 Inferior nasal concha
- 8 Palatine bone
- 9 Maxilla
- 10 Inferior meatus
- 11 Palatine process of the maxilla



To page 49:

- Blue = occipital bone
- Light green = parietal bone
- Yellow = frontal bone
- Dark brown = temporal bone
- Red = sphenoidal bone
- Dark green = ethmoidal bone
- Light blue = nasal bone
- Pink = inferior concha
- Orange = vomer
- Violet = maxilla
- White = palatine bone
- White = mandible

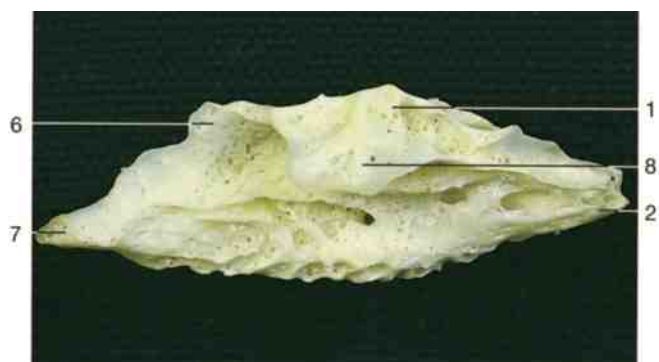
Lateral wall of the nasal cavity. Median section through the skull.



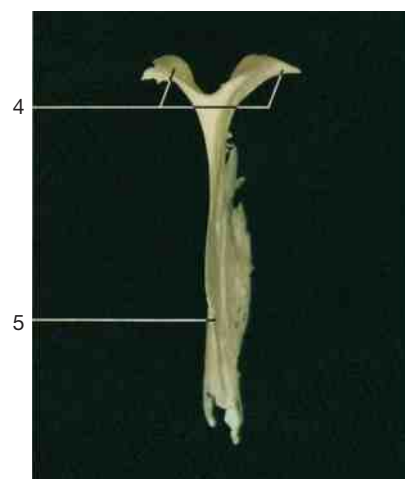
Right inferior nasal concha (medial aspect). Anterior part to the left.

Inferior concha and vomer

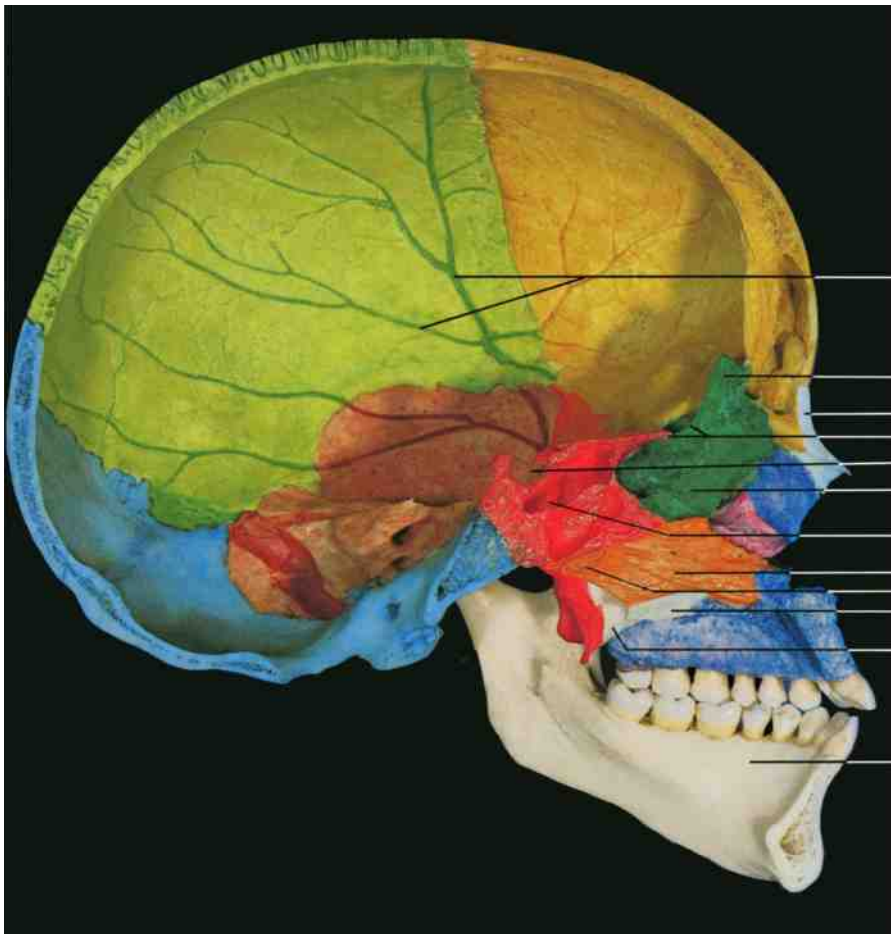
- 1 Ethmoidal process
- 2 Anterior part of concha
- 3 Inferior border
- 4 Ala of vomer
- 5 Posterior border of nasal septum
- 6 Lacrimal process
- 7 Posterior part of concha
- 8 Maxillary process



Right inferior nasal concha (lateral aspect). Anterior part to the right.



Vomer (posterior aspect).

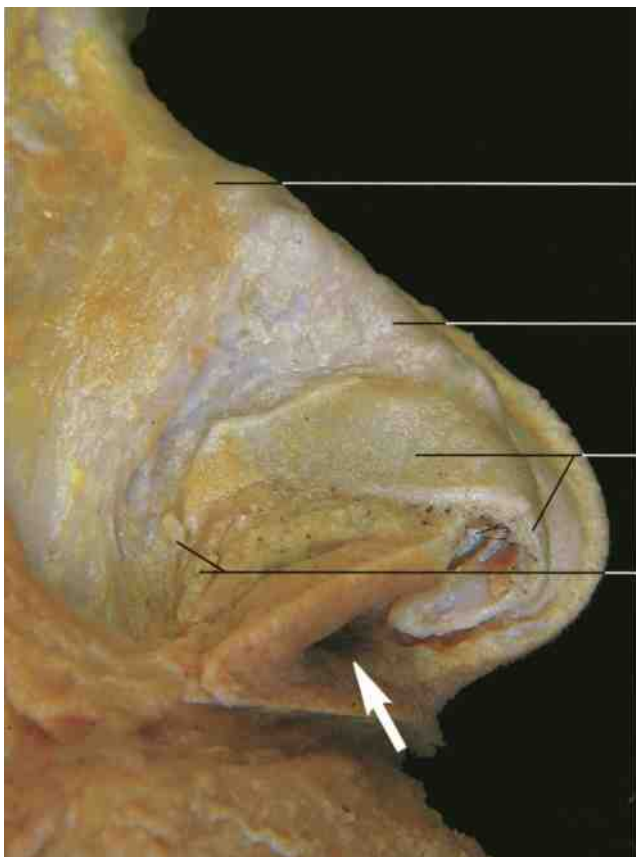


- 1 Crista galli
- 2 Cribriform plate of ethmoidal bone
- 3 Perpendicular plate of ethmoidal bone
- 4 Vomer
- 5 Ala of the vomer
- 6 Palatine bone (perpendicular process)
- 7 Palatine bone (horizontal plate)
- 8 Mandible
- 9 Nasal bone
- 10 Sphenoidal sinus
- 11 Hypophysial fossa (sella turcica)
- 12 Grooves for the middle meningeal artery

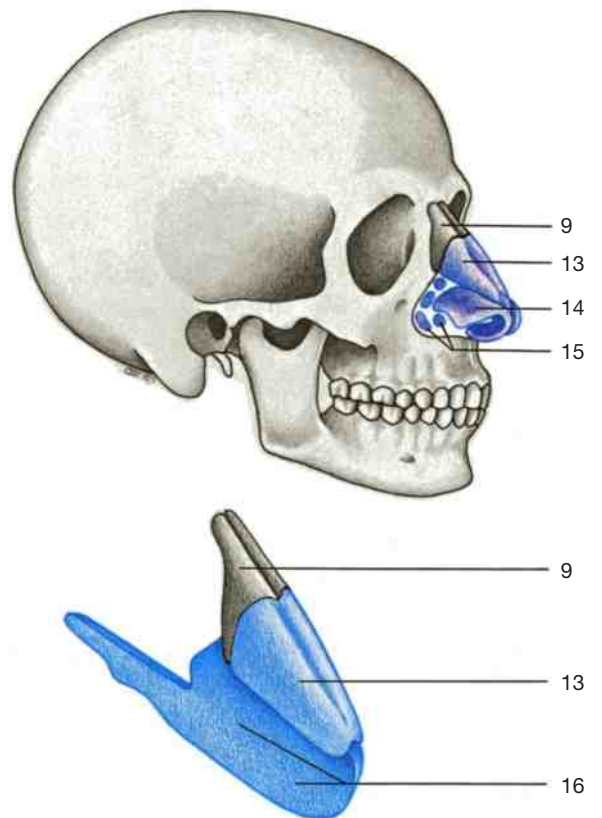
Cartilages of the nose

- 13 Lateral nasal cartilage
- 14 Greater alar cartilage
- 15 Lesser alar cartilages
- 16 Septal cartilage
- 17 Location of nasal bone

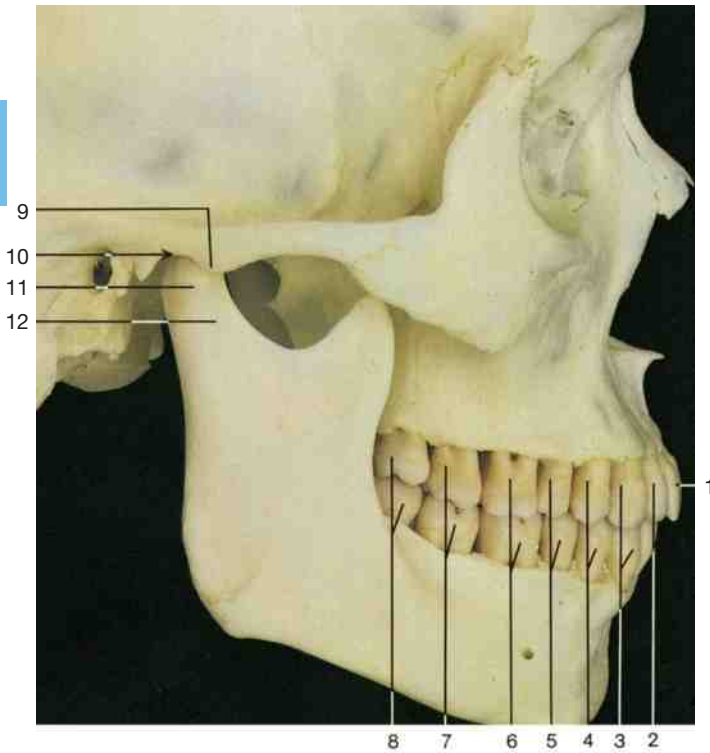
Paramedian sagittal section through the skull including the nasal septum.



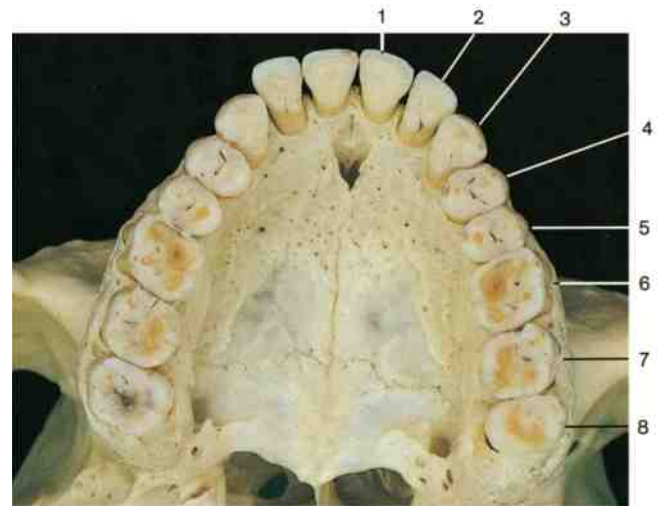
Cartilages of the nose (right anterior aspect). Arrow = nostril, framed by nasal wing.



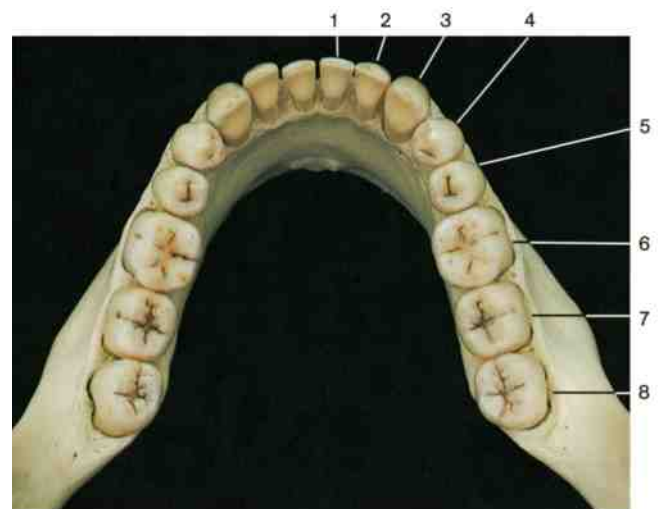
Cartilages of the nose (schematic diagram of the external nose).



Normal position of teeth. Dentition in centric occlusion (lateral view).

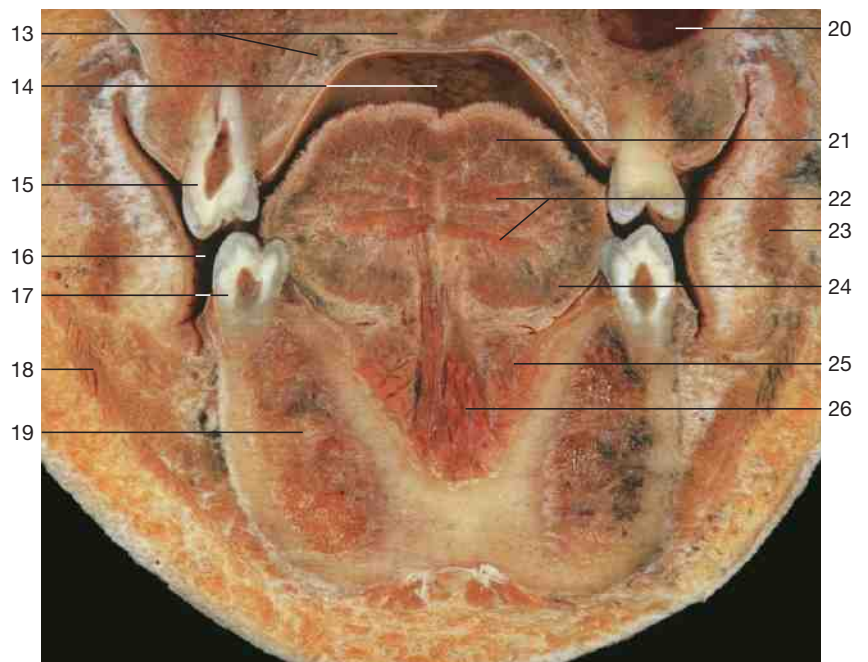

Upper teeth of the adult (inferior aspect).

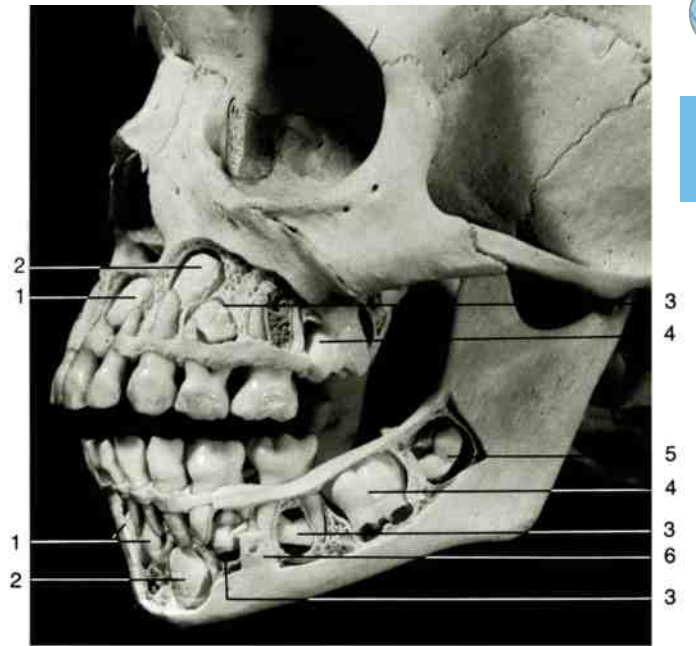
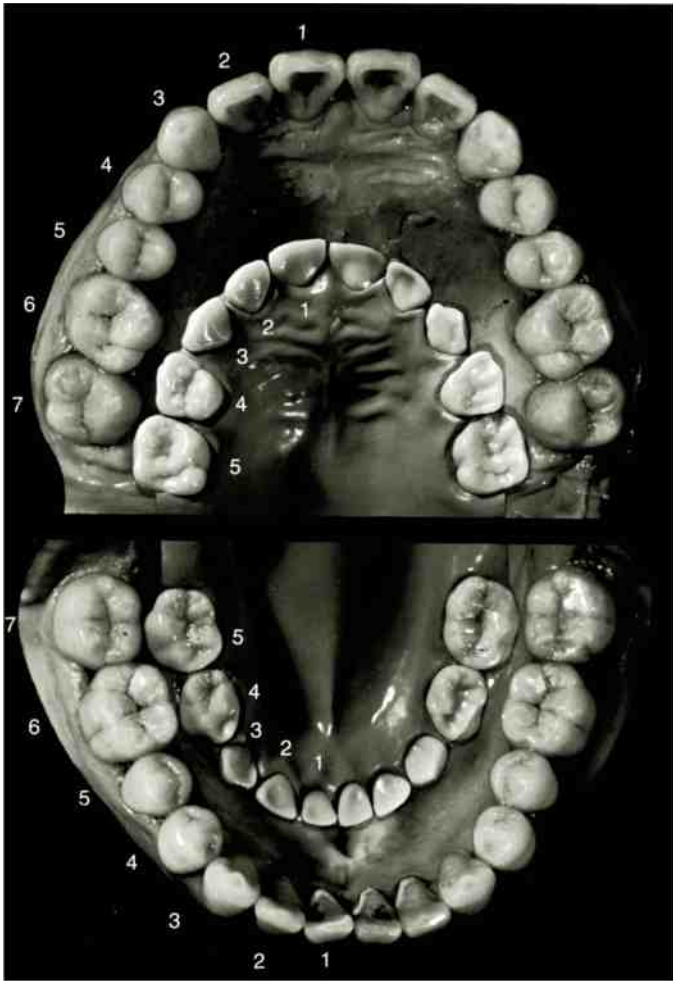


Lower teeth of the adult (superior aspect).

- 1 Central incisor
- 2 Lateral incisor
- 3 Canines
- 4 First premolars or bicuspid
- 5 Second premolars or bicuspid
- 6 First molars
- 7 Second molars
- 8 Third molars
- 9 Articular tubercle
- 10 Mandibular fossa
- 11 Head of mandible
- 12 Condylar process
- 13 Hard palate and palatine glands
- 14 Oral cavity
- 15 Upper molar
- 16 Oral vestibule
- 17 Lower molar
- 18 Platysma muscle
- 19 Mandible
- 20 Maxillary sinus
- 21 Superior longitudinal muscle of tongue
- 22 Transverse muscle of tongue
- 23 Buccinator muscle
- 24 Inferior longitudinal muscle of tongue
- 25 Sublingual gland
- 26 Genioglossus muscle



Coronal section through the oral cavity.

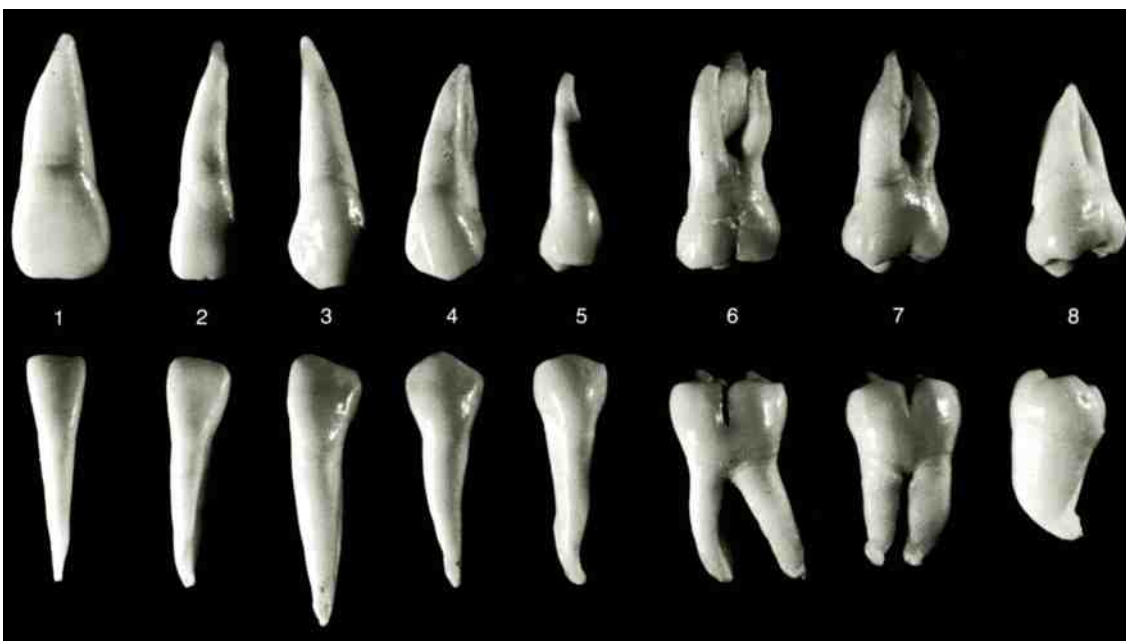


Deciduous teeth in child's skull. The developing crowns of the permanent teeth are displayed in their crypts in the maxilla and mandible.

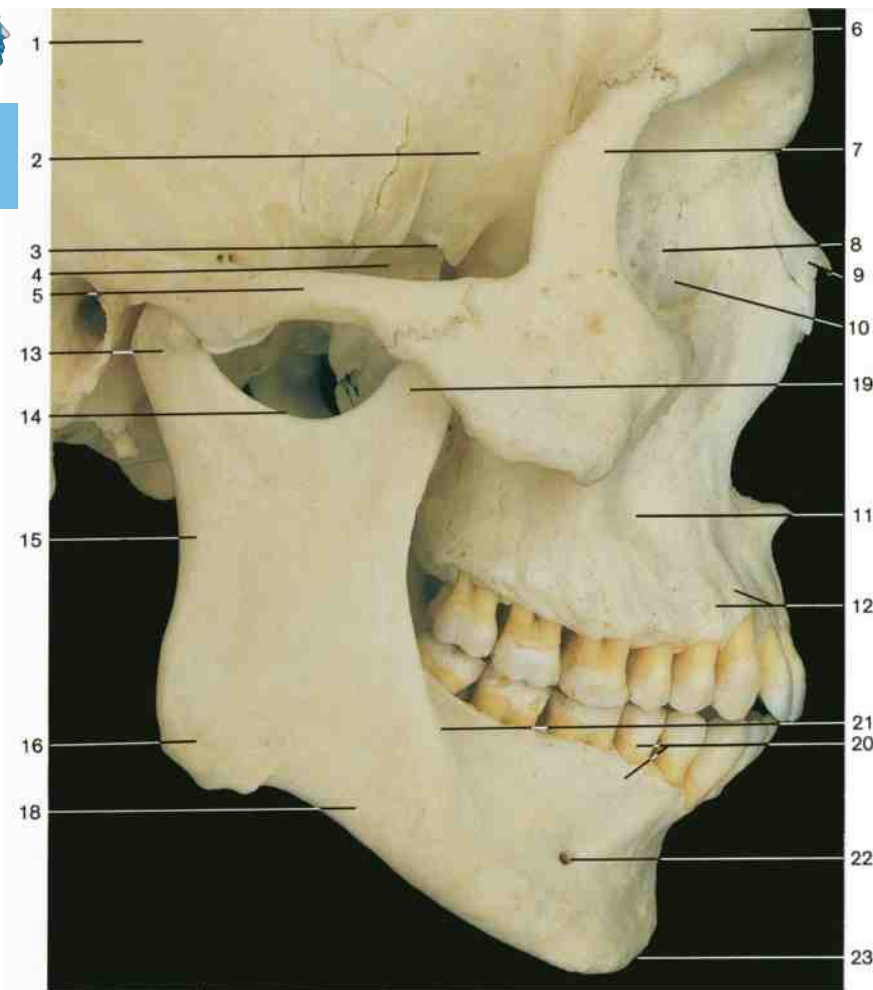
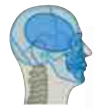- 1 Permanent incisors
- 2 Permanent cuspid (canine)
- 3 Premolars
- 4 First permanent molar
- 5 Second permanent molar
- 6 Mental foramen

Comparison of the deciduous and permanent teeth.

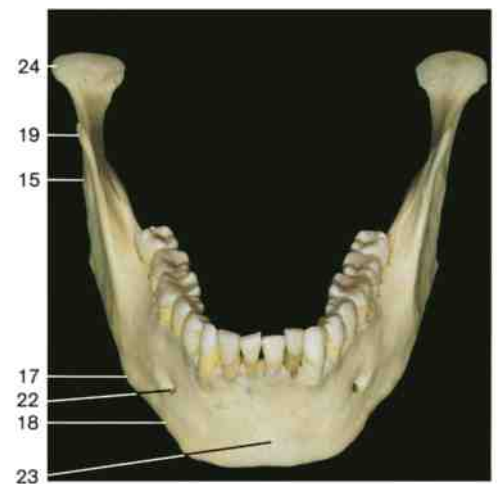
Notice that the breadth of the alveolar arch of the child's mandible and maxilla holding the deciduous teeth is nearly the same as the comparable portion in the jaws of the adult. Note the emergence of the third molars. The numbers of the teeth correspond to the numbers in the figure below.



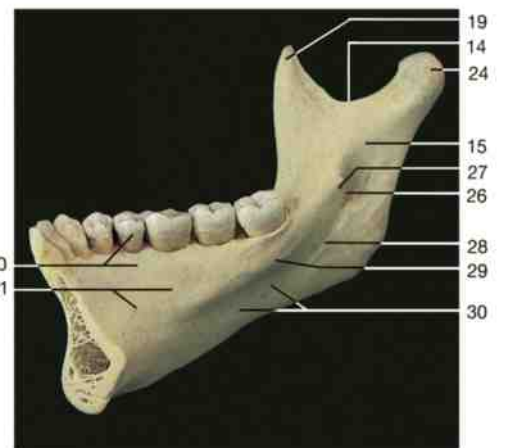
Isolated teeth of the alveolar part of the maxilla (top row) and the mandible (lower row), labial surface of the teeth.



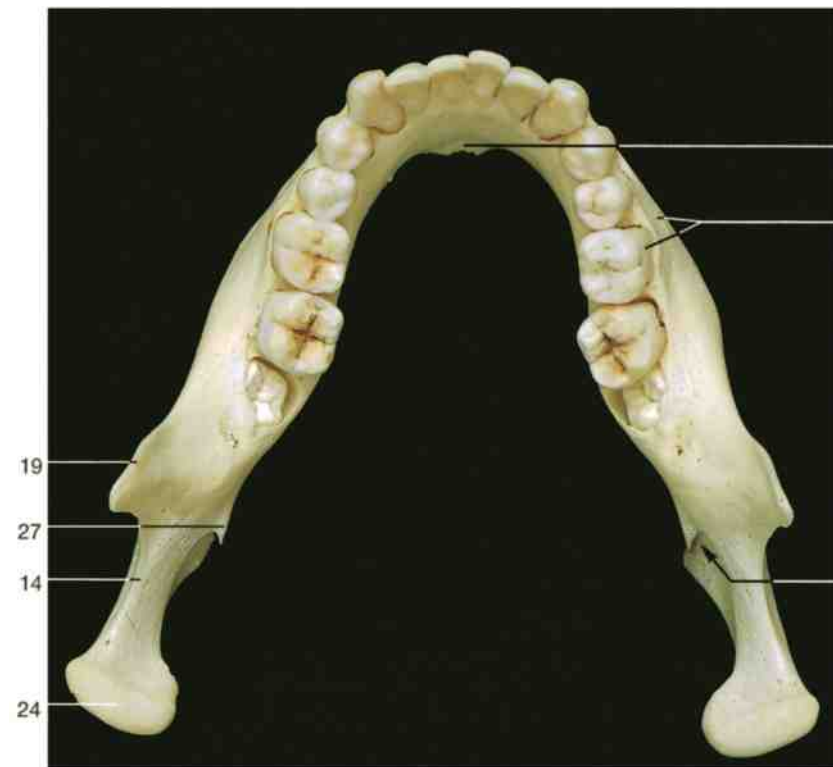Lateral aspect of the facial bones. Mandible and teeth in the position of occlusion. Upper and lower jaw occluded.



Mandible of the adult (anterior aspect).



Right half of mandible (medial aspect).

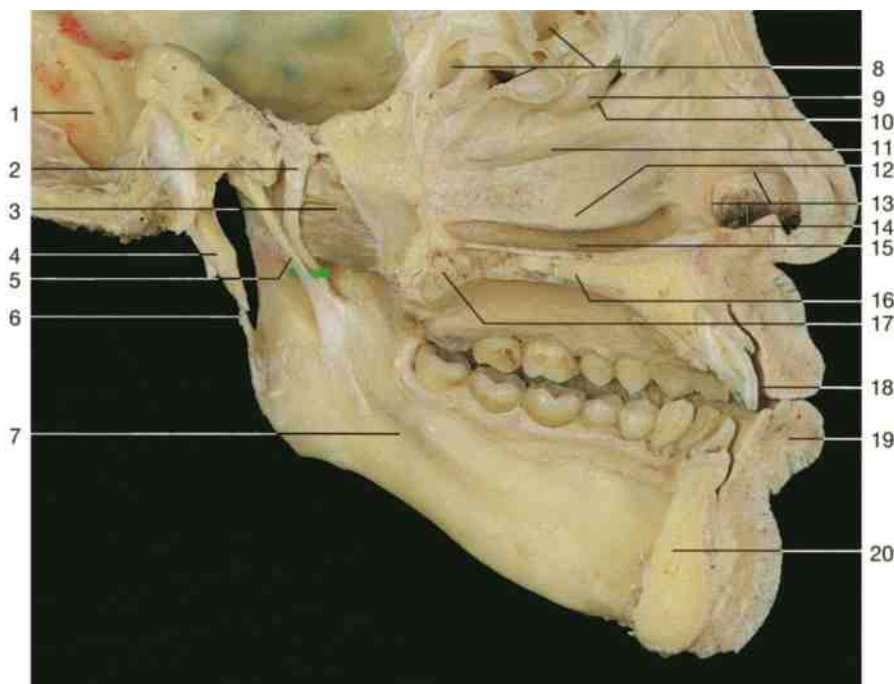
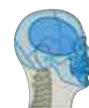

Mandible of the adult (superior aspect).

- 1 Temporal bone
- 2 Temporal fossa (greater wing of sphenoidal bone)
- 3 Infratemporal crest
- 4 Infratemporal fossa
- 5 Zygomatic arch
- 6 Frontal bone
- 7 Zygomatic bone (frontal process)
- 8 Lacrimal bone
- 9 Nasal bone
- 10 Lacrimal groove
- 11 Maxilla (canine fossa)
- 12 Alveolar process of maxilla

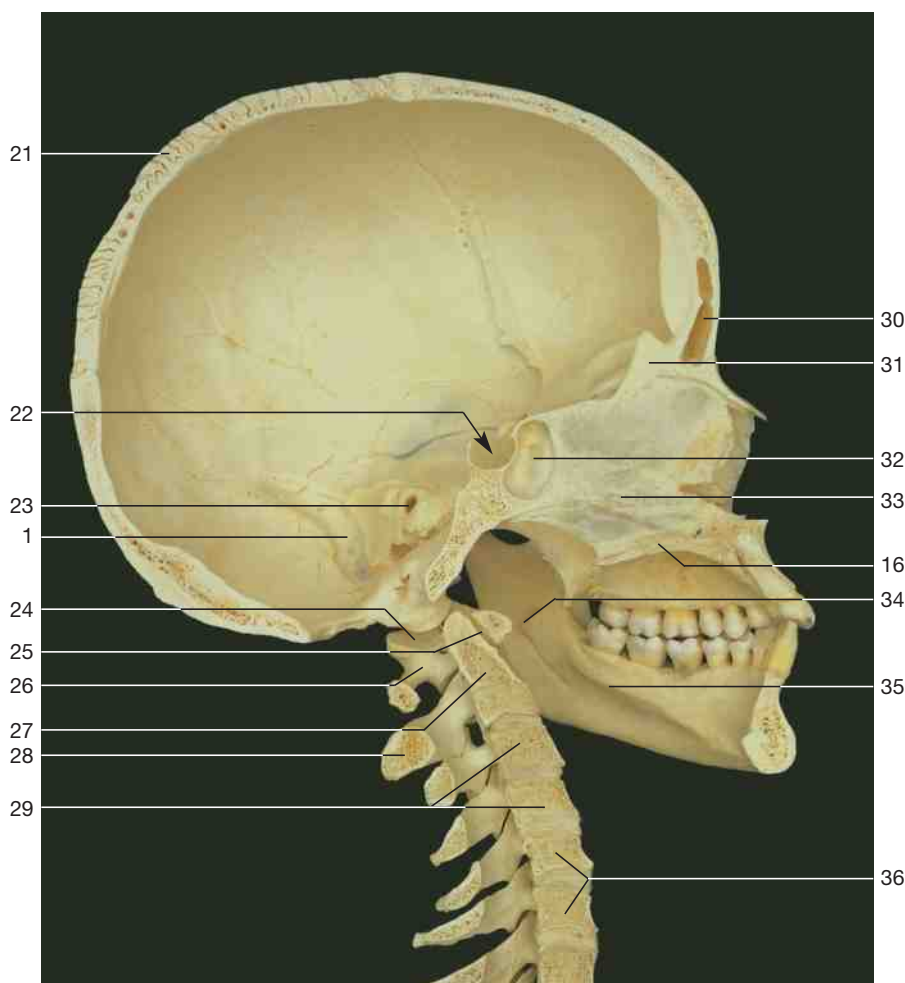
Mandible

- 13 Condylar process
- 14 Mandibular notch
- 15 Ramus of the mandible
- 16 Masseteric tuberosity
- 17 Angle of the mandible
- 18 Body of the mandible
- 19 Coronoid process
- 20 Alveolar process including teeth
- 21 Oblique line
- 22 Mental foramen
- 23 Mental protuberance
- 24 Head of the mandible
- 25 Genial tubercle or mental spine
- 26 Mandibular foramen (entrance to mandibular canal)
- 27 Lingula
- 28 Mylohyoid sulcus
- 29 Mylohyoid line
- 30 Submandibular fossa
- 31 Sublingual fossa

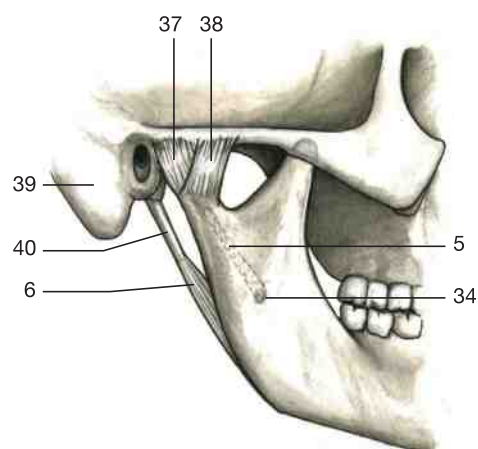


Ligaments of temporomandibular joint. Left half of the head (medial aspect).


- 1 Groove for sigmoid sinus
- 2 Mandibular nerve
- 3 Lateral pterygoid muscle
- 4 Styloid process
- 5 Sphenomandibular ligament
- 6 Styломandibular ligament
- 7 Mylohyoid groove
- 8 Ethmoidal air cells
- 9 Ethmoidal bulla
- 10 Hiatus semilunaris
- 11 Middle meatus
- 12 Inferior nasal concha
- 13 Limen nasi
- 14 Vestibule with hairs
- 15 Inferior meatus
- 16 Hard palate
- 17 Soft palate
- 18 Vestibule of oral cavity
- 19 Lower lip
- 20 Mandible
- 21 Calvaria with diploe
- 22 Sella turcica
- 23 Internal acoustic meatus
- 24 Atlanto-occipital articulation
- 25 Median atlanto-axial articulation
- 26 Atlas (C₁)
- 27 Dens of axis (C₂)
- 28 Spinous process of axis (C₂)
- 29 Cervical vertebrae (C₃, C₄)
- 30 Frontal sinus
- 31 Crista galli
- 32 Sphenoidal sinus
- 33 Nasal septum
- 34 Mandibular foramen
- 35 Mylohyoid line
- 36 Bodies of cervical vertebrae (C₅, C₆)
- 37 Articular capsule
- 38 Lateral ligament
- 39 Mastoid process
- 40 Styloid process



Head and cervical vertebral column (median section through skull and cervical vertebrae, medial aspect).

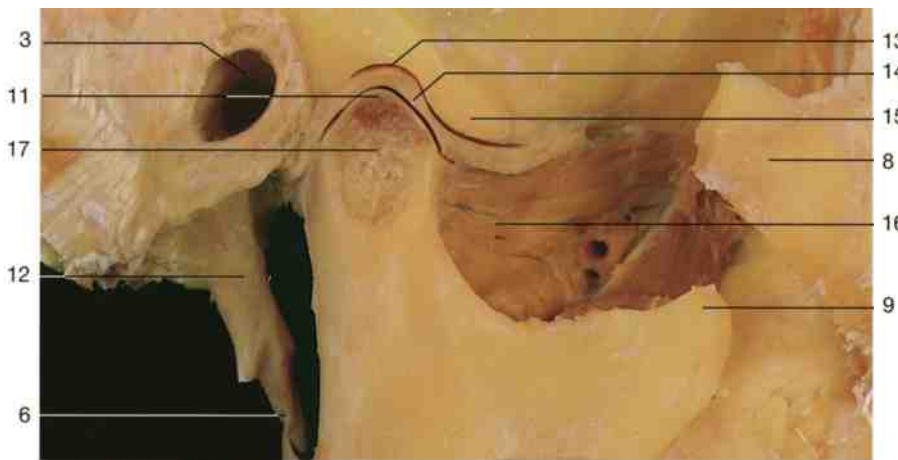


Ligaments related to the temporomandibular joint (schematic drawing).

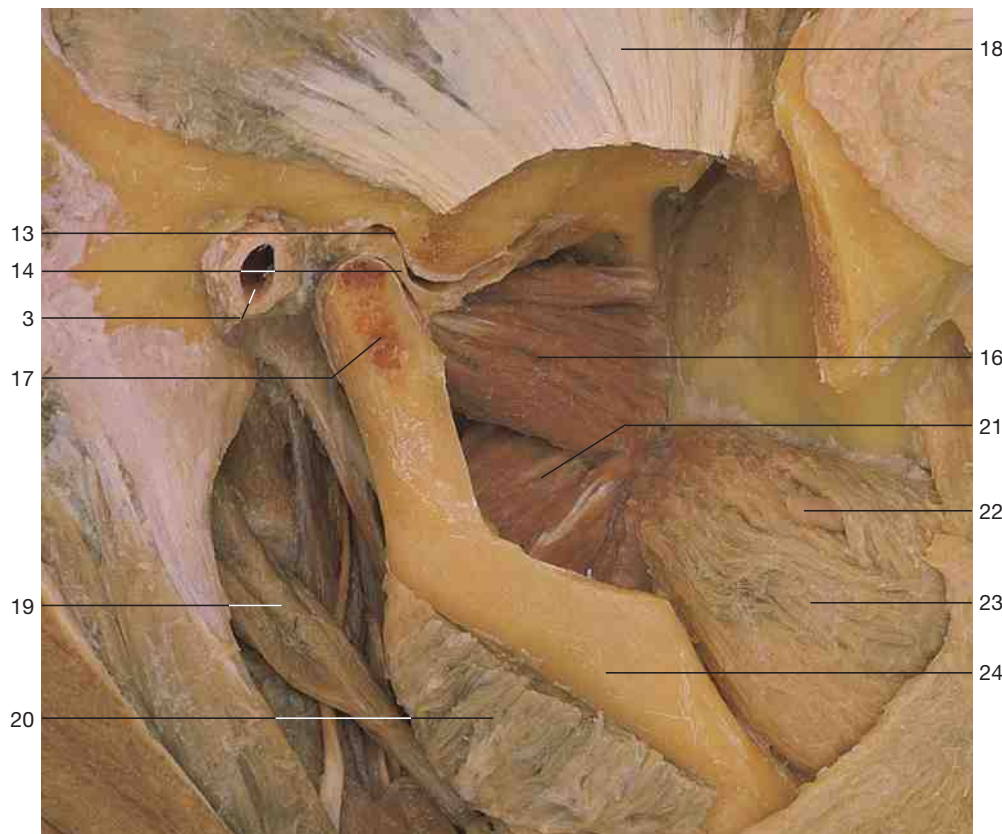


- 1 Zygomatic arch
- 2 Articular capsule
- 3 External acoustic meatus
- 4 Lateral ligament
- 5 Mandibular notch
- 6 Stylo-mandibular ligament
- 7 Ramus of the mandible
- 8 Zygomatic bone
- 9 Coronoid process
- 10 Maxilla
- 11 Articular cartilage of condylar process
- 12 Styloid process
- 13 Mandibular fossa
- 14 Articular disc
- 15 Articular tubercle
- 16 Lateral pterygoid muscle
- 17 Condylar process of mandible
- 18 Temporalis muscle
- 19 Digastric muscle, posterior belly
- 20 Masseter muscle
- 21 Medial pterygoid muscle
- 22 Parotid duct
- 23 Buccinator muscle
- 24 Mandible

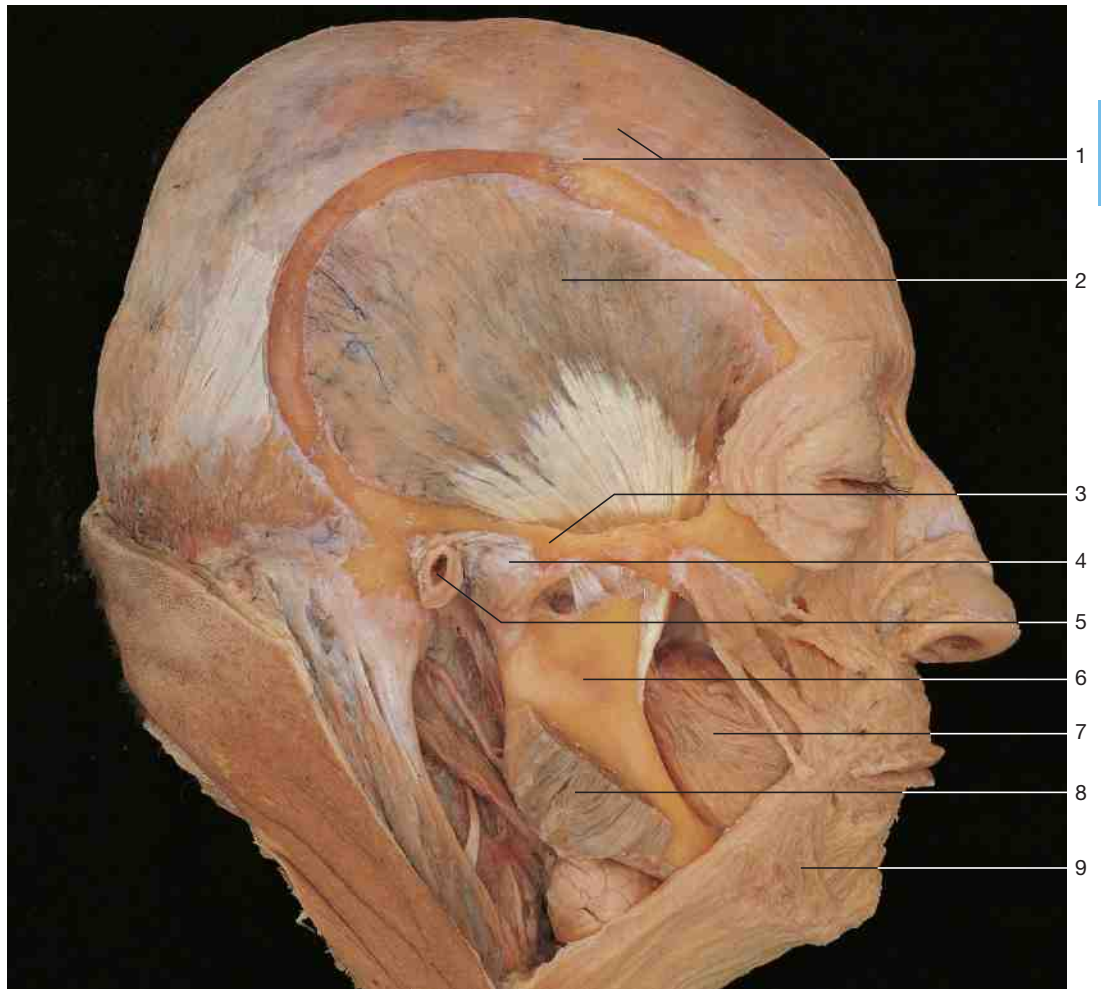
Temporomandibular joint with ligaments.



Temporomandibular joint, sagittal section.

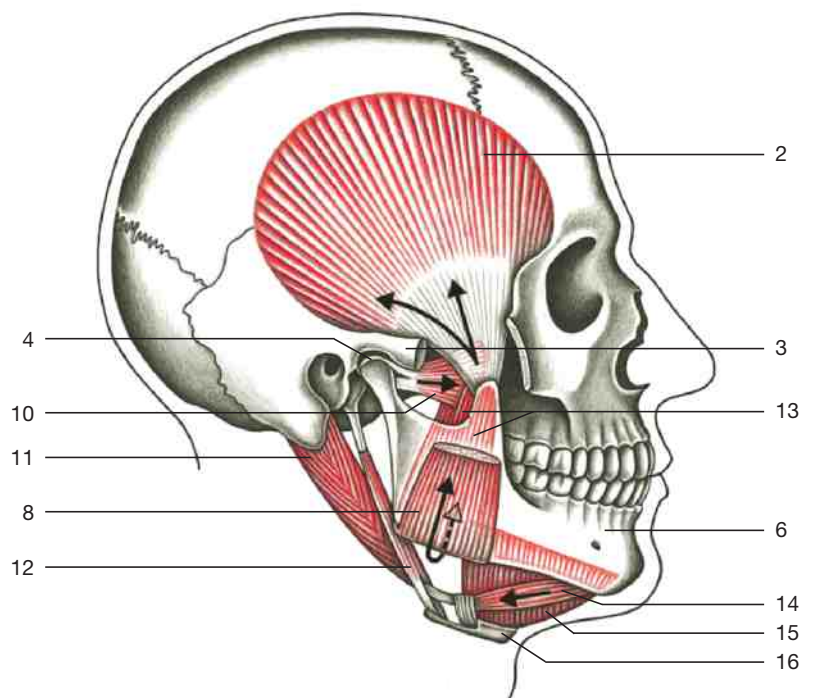


Temporomandibular joint. Dissection of the articular disc and the related muscles (lateral aspect).

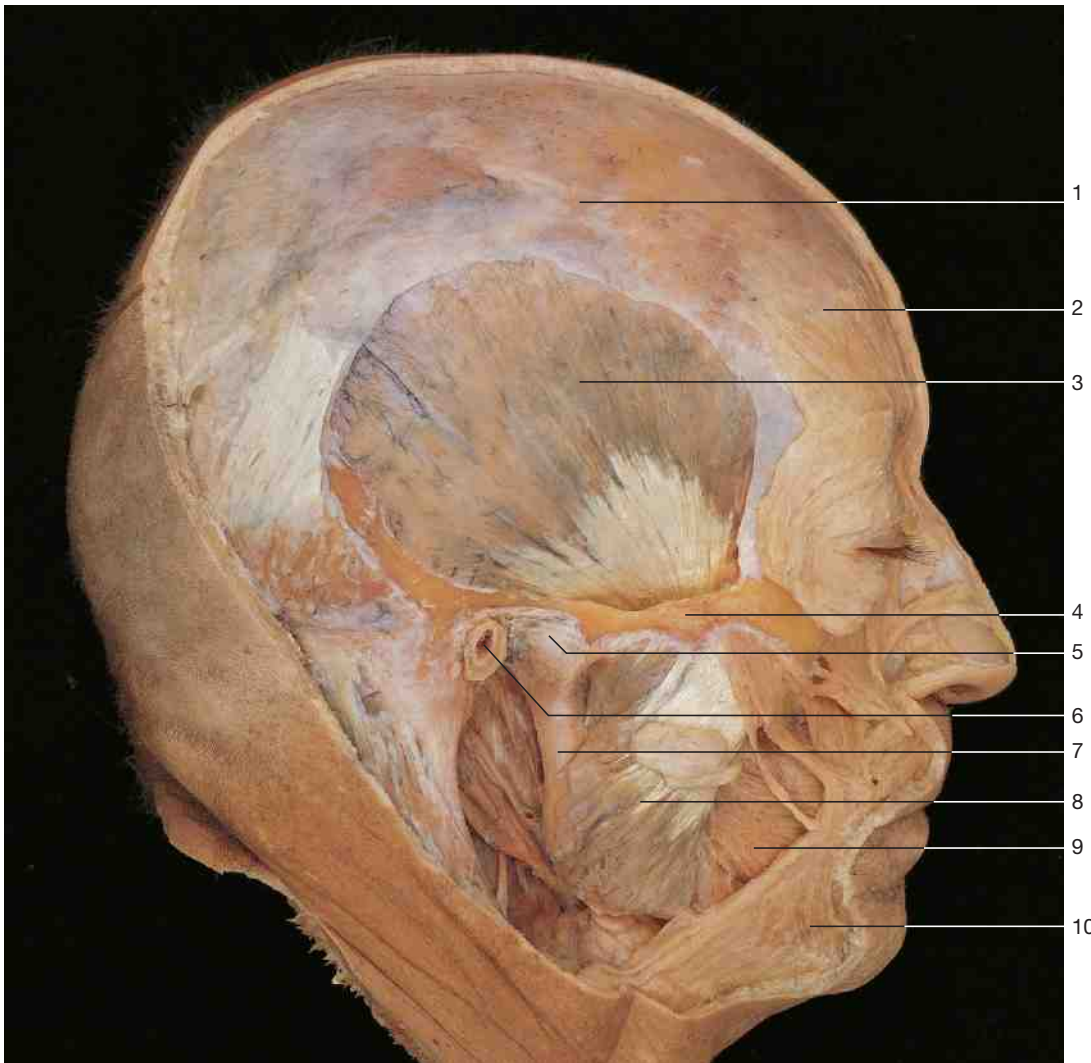
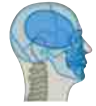

Muscles of mastication and temporomandibular joint. Masseter muscle partly removed.

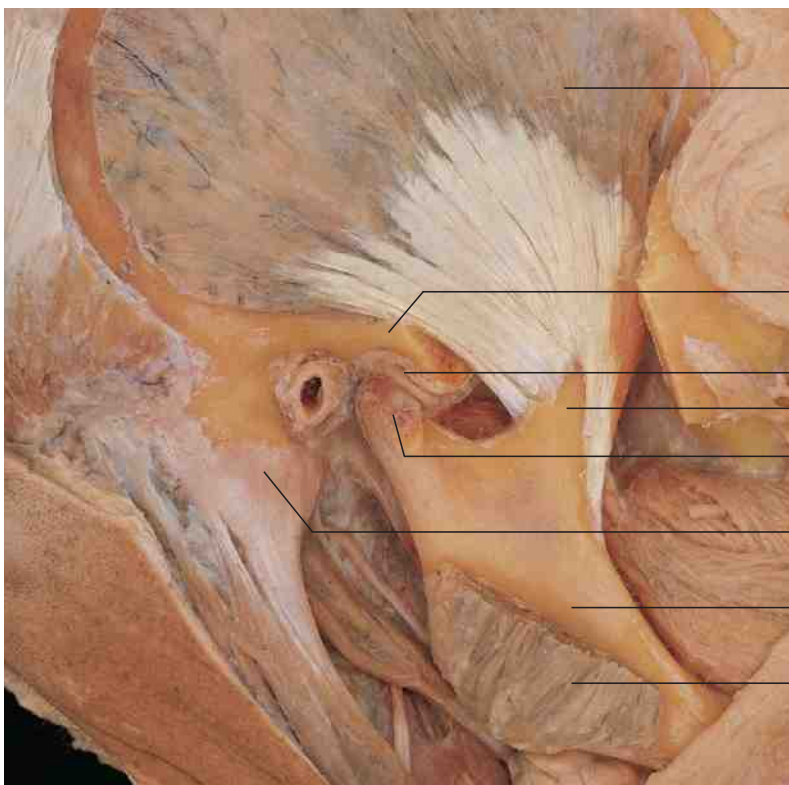
- 1 Galea aponeurotica
- 2 Temporalis muscle
- 3 Zygomatic arch
- 4 Temporomandibular joint
- 5 External acoustic meatus
- 6 Mandible
- 7 Buccinator muscle
- 8 Masseter muscle (cut)
- 9 Platysma muscle
- 10 Lateral pterygoid muscle
- 11 Posterior belly of digastric muscle
- 12 Stylohyoid muscle
- 13 Medial pterygoid muscle
- 14 Anterior belly of digastric muscle
- 15 Mylohyoid muscle
- 16 Hyoid bone



Effect of the masticatory muscles on the temporomandibular joint (arrows).

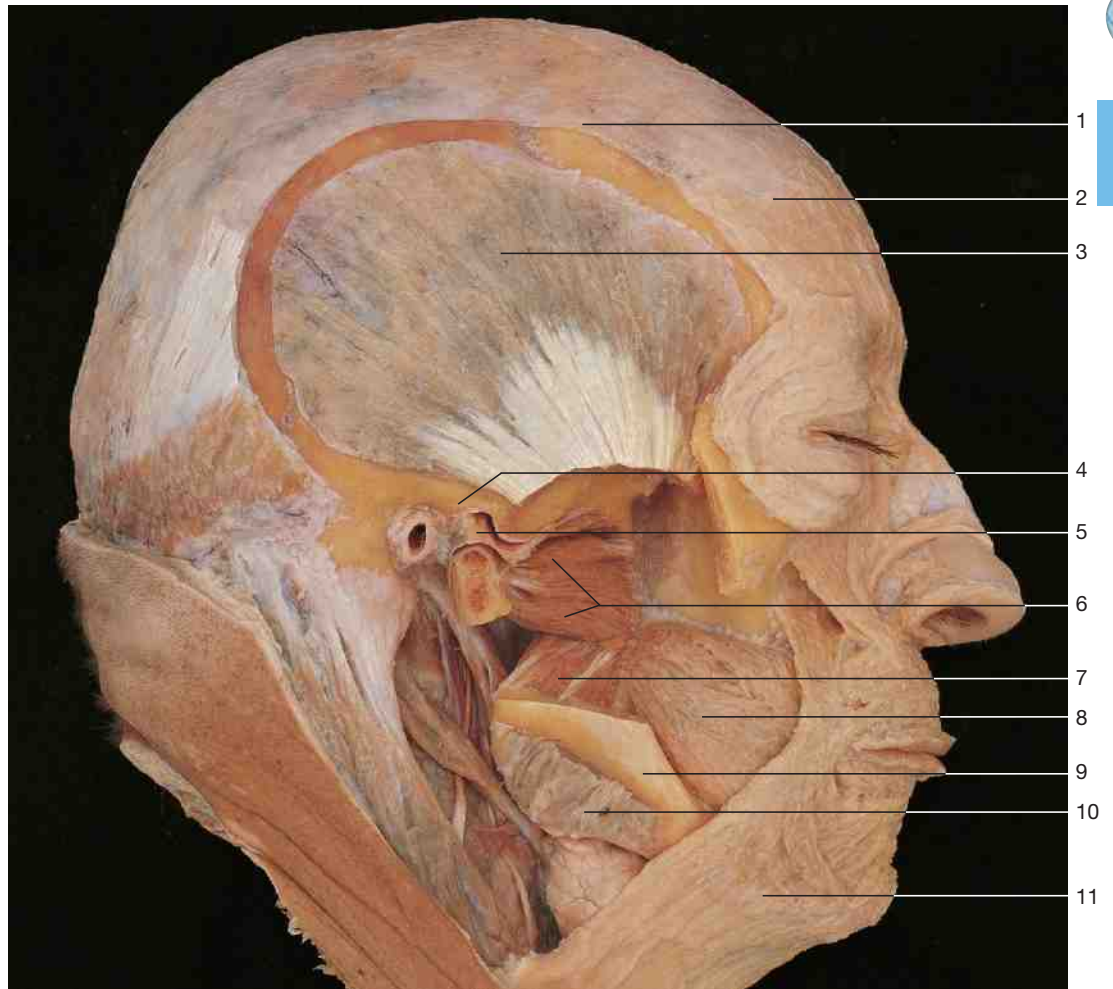


Muscles of mastication. The temporomandibular joint and the masseter and temporalis muscles are shown.



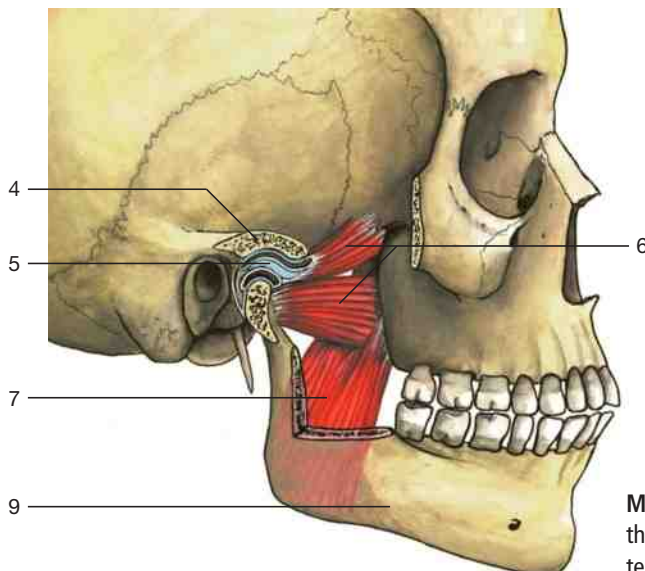
- 1 Galea aponeurotica
- 2 Frontal belly of occipitofrontalis muscle
- 3 Temporalis muscle
- 4 Zygomatic arch
- 5 Temporomandibular joint
- 6 External acoustic meatus
- 7 Mandible
- 8 Masseter muscle
- 9 Buccinator muscle
- 10 Platysma muscle
- 11 Articular disc of temporomandibular joint
- 12 Coronoid process of mandible
- 13 Condylar process of mandible
- 14 Mastoid process

Temporalis muscle with insertion at the mandible and the temporomandibular joint. Zygomatic arch and masseter muscle have been partly removed.

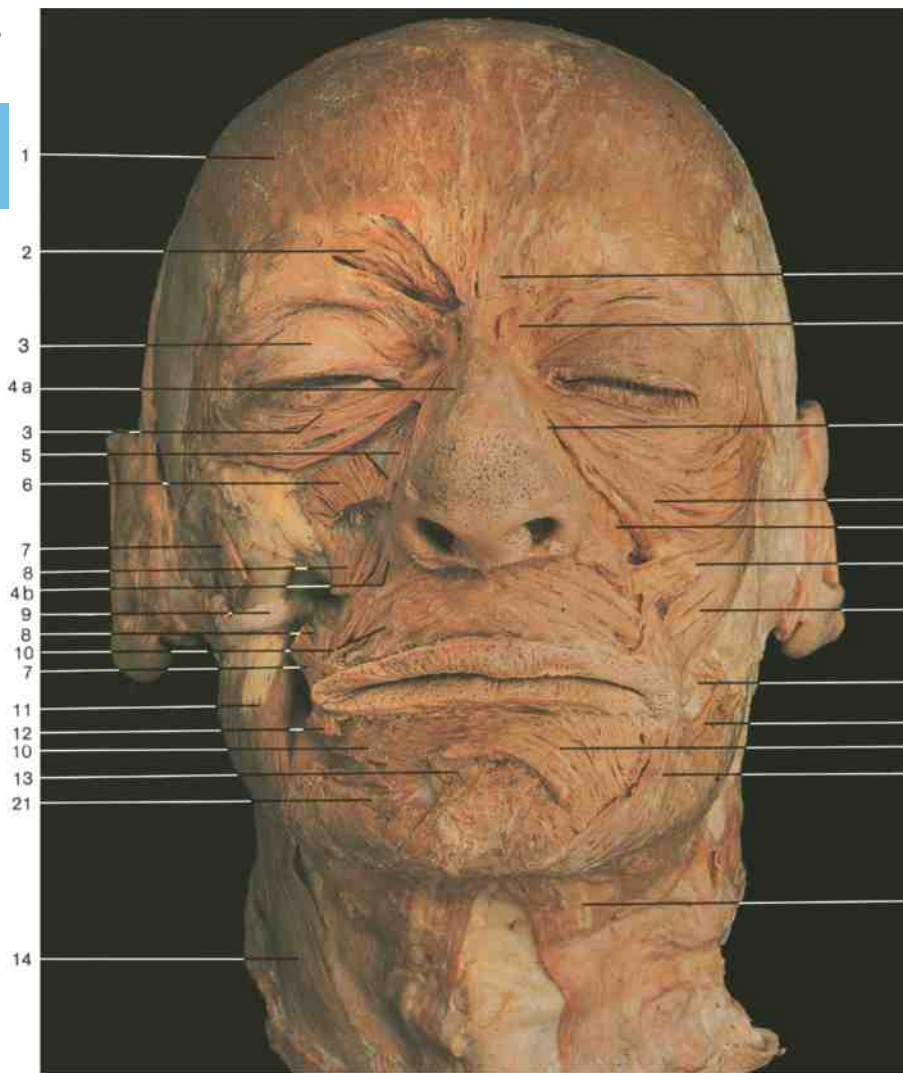


Muscles of mastication. The zygomatic arch and part of the mandible have been removed to reveal the medial and lateral pterygoid muscles.

- | | |
|---|---------------------------|
| 1 Galea aponeurotica | 7 Medial pterygoid muscle |
| 2 Frontal belly of occipitofrontalis muscle | 8 Buccinator muscle |
| 3 Temporalis muscle | 9 Mandible |
| 4 Zygomatic arch | 10 Masseter muscle |
| 5 Articular disc of temporomandibular joint | 11 Platysma muscle |
| 6 Lateral pterygoid muscle | |

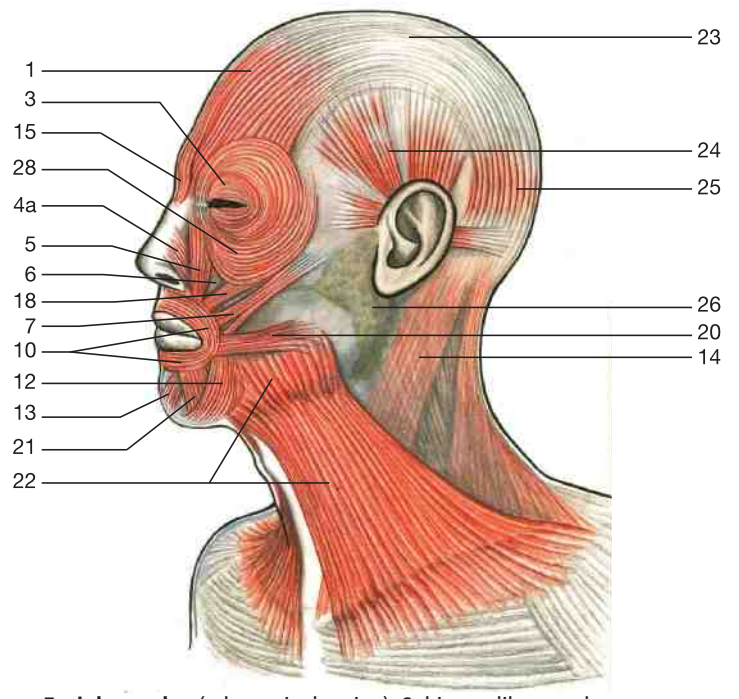
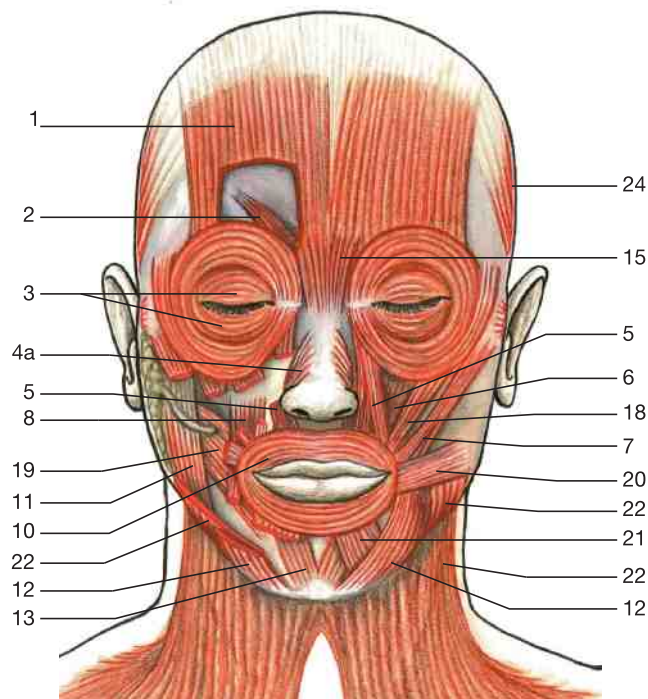


Medial and lateral pterygoid muscles and their connections with the articular disc of the temporomandibular joint (schematic drawing).



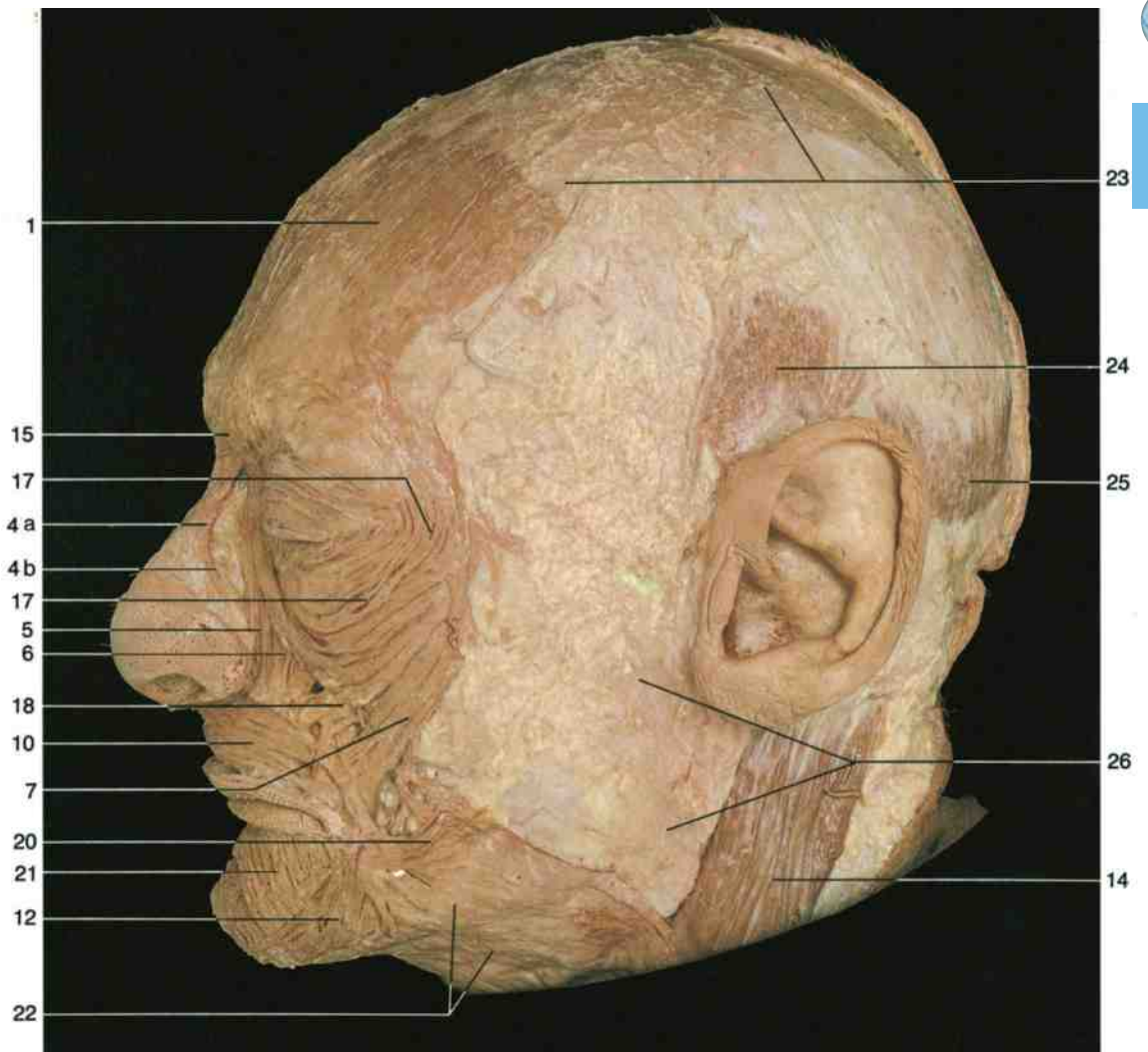
- 1 Frontal belly of occipitofrontalis muscle
- 2 Corrugator supercilii muscle
- 3 Palpebral part of orbicularis oculi muscle
- 4a Transverse part of nasalis muscle
- 4b Alar part of nasalis muscle
- 5 Levator labii superioris alaeque nasi muscle
- 6 Levator labii superioris muscle
- 7 Zygomaticus major muscle
- 8 Levator anguli oris muscle
- 9 Parotid duct
- 10 Orbicularis oris muscle
- 11 Masseter muscle
- 12 Depressor anguli oris muscle
- 13 Mentalis muscle
- 14 Sternocleidomastoid muscle
- 15 Procerus muscle
- 16 Depressor supercilii muscle
- 17 Orbital part of orbicularis oculi muscle
- 18 Zygomaticus minor muscle
- 19 Buccinator muscle
- 20 Risorius muscle
- 21 Depressor labii inferioris muscle
- 22 Platysma muscle
- 23 Galea aponeurotica
- 24 Temporoparietalis muscle
- 25 Occipital belly of occipitofrontalis muscle
- 26 Parotid gland with fascia
- 27 Temporal fascia
- 28 Orbicularis oculi muscle
- 29 Parotid duct and masseter muscle

Facial muscles (anterior aspect). Left side: superficial layer, right side: deeper layer.

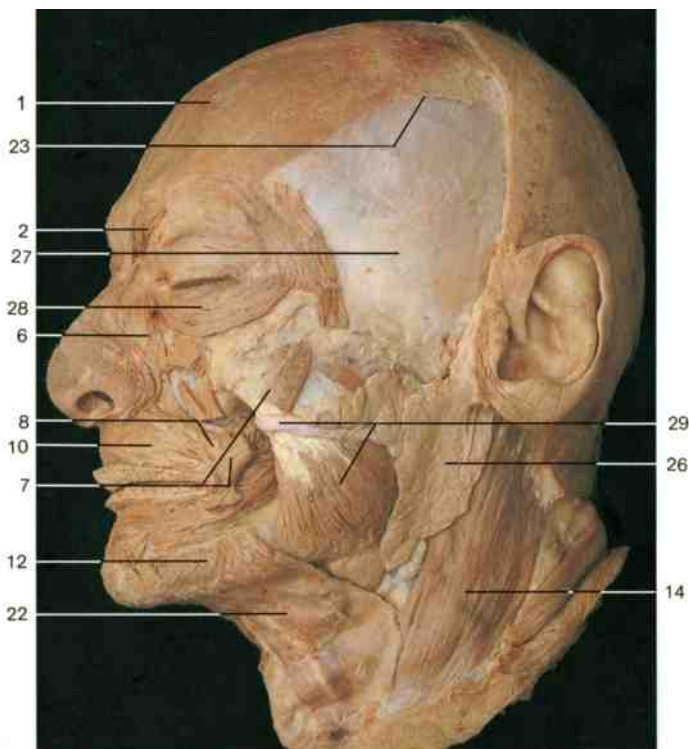


Facial muscles (schematic drawing). Left side: superficial layer, right side: deeper layer.

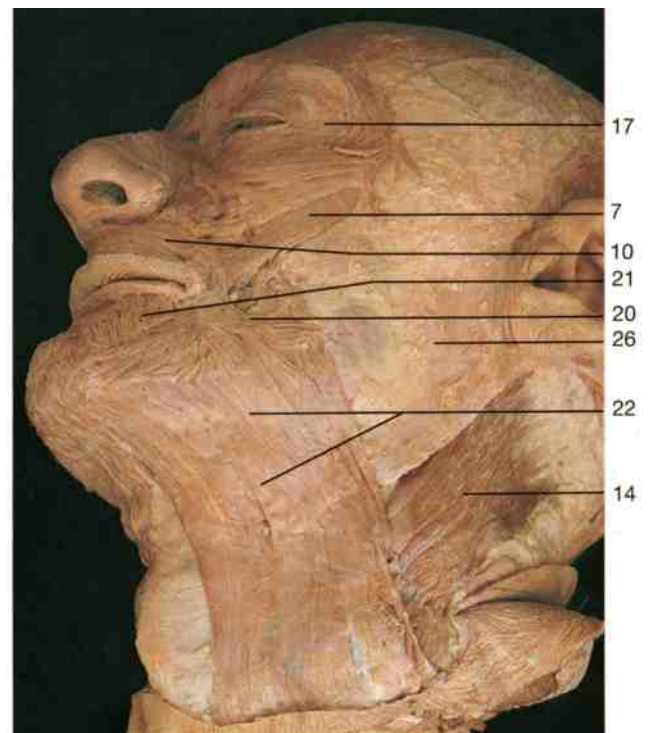
Facial muscles (schematic drawing). Sphincter-like muscles surround the orifices of the head. Radially arranged muscles work as their antagonists.



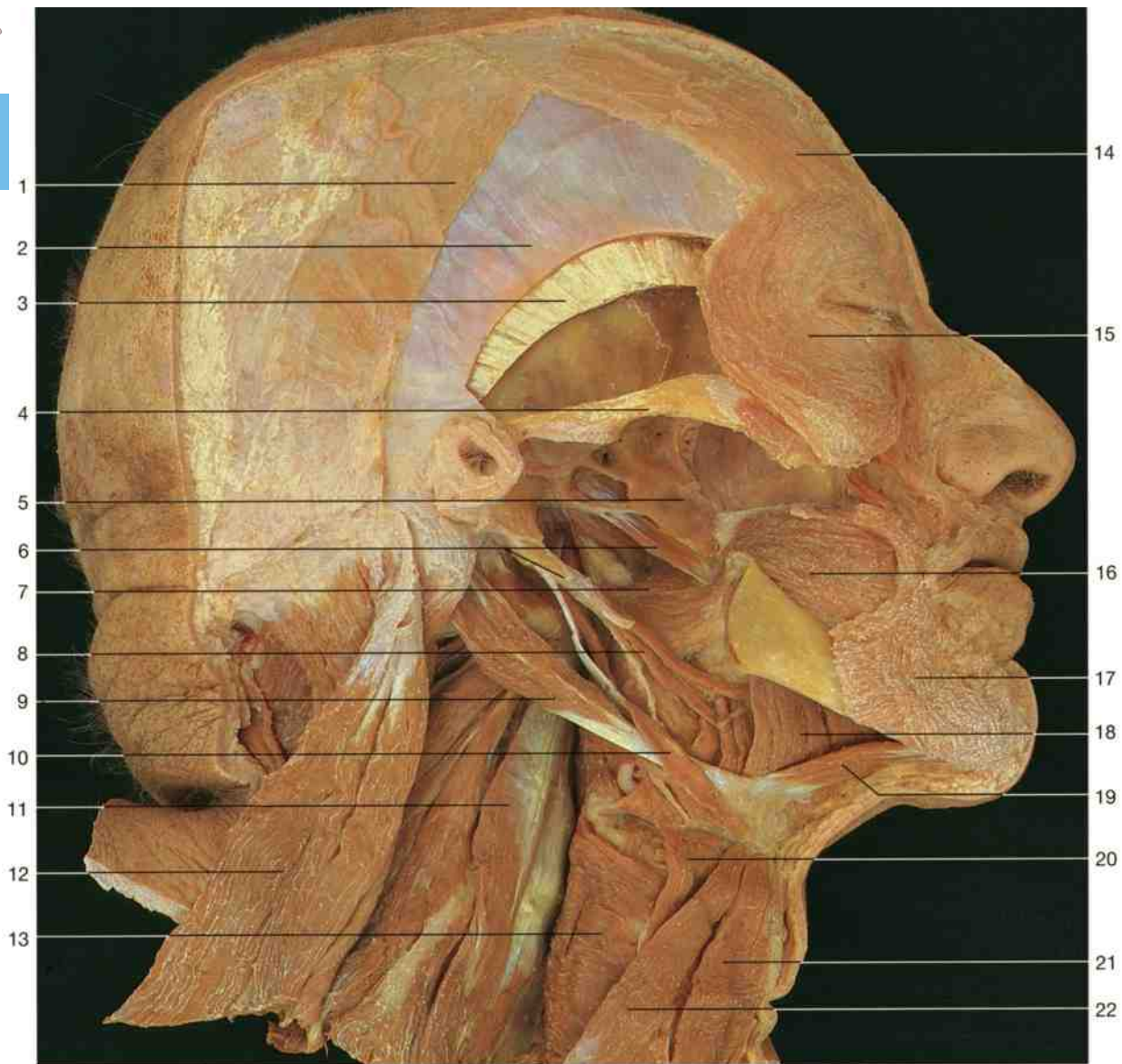
Facial muscles (lateral aspect).



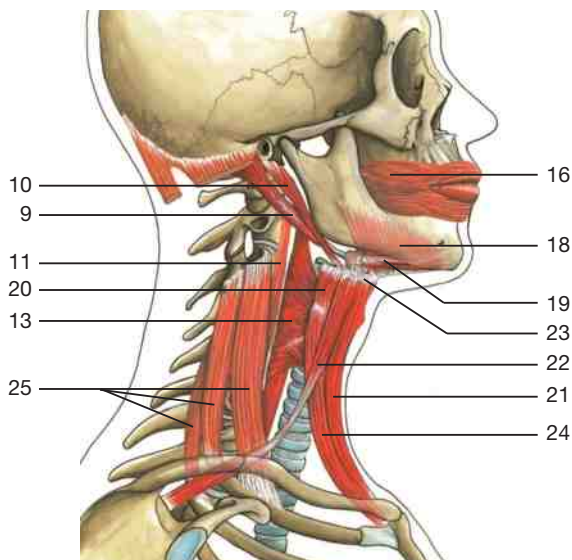
Facial muscles and parotid gland (lateral aspect).



Platysma muscle (oblique lateral aspect). Superficial lamina of cervical fascia partly removed.

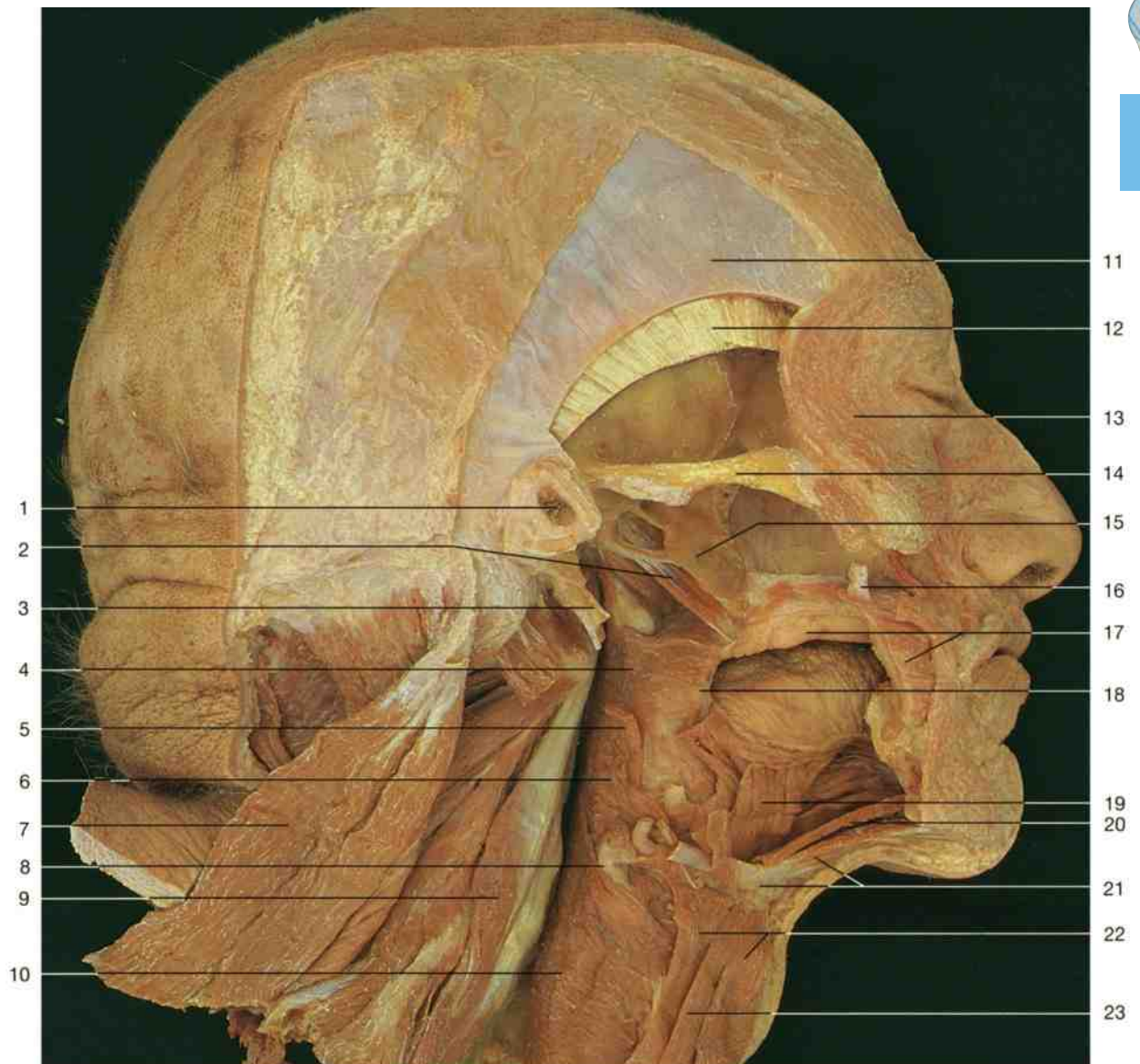
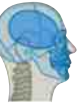

Supra- and infrahyoid muscles and pharynx (lateral aspect). Ramus of mandible, pterygoid muscles, and insertion of temporalis muscle removed.



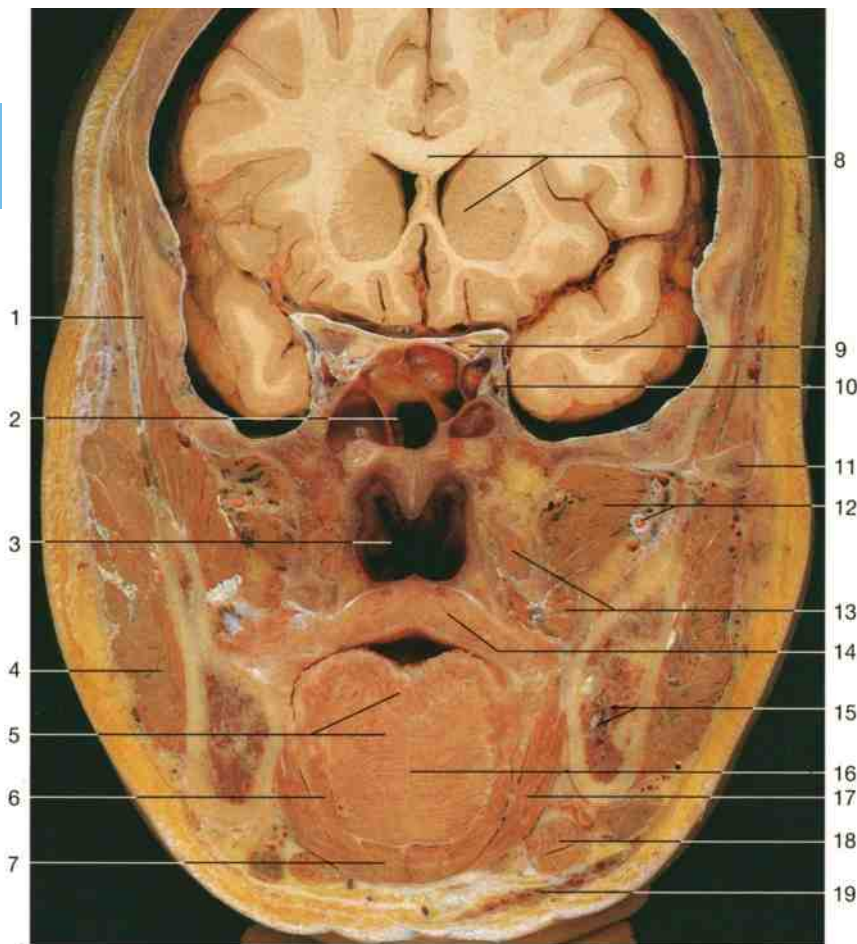
Supra- and infrahyoid muscles (schematic drawing).

- 1 Galea aponeurotica
- 2 Temporal fascia
- 3 Tendon of temporalis muscle
- 4 Zygomatic arch
- 5 Lateral pterygoid plate
- 6 Tensor veli palatini muscle (styloid process)
- 7 Superior constrictor muscle of pharynx
- 8 Styloglossus muscle
- 9 Posterior belly of digastric muscle
- 10 Stylohyoid muscle
- 11 Longus capitis muscle
- 12 Sternocleidomastoid muscle (reflected)
- 13 Inferior constrictor of pharynx
- 14 Frontal belly of occipitofrontalis muscle
- 15 Orbital part of orbicularis oculi muscle
- 16 Buccinator muscle
- 17 Depressor anguli oris muscle
- 18 Mylohyoid muscle
- 19 Anterior belly of digastric muscle
- 20 Thyrohyoid muscle
- 21 Sternohyoid muscle
- 22 Omohyoid muscle
- 23 Hyoid bone
- 24 Sternothyroid muscle
- 25 Scalenus muscles



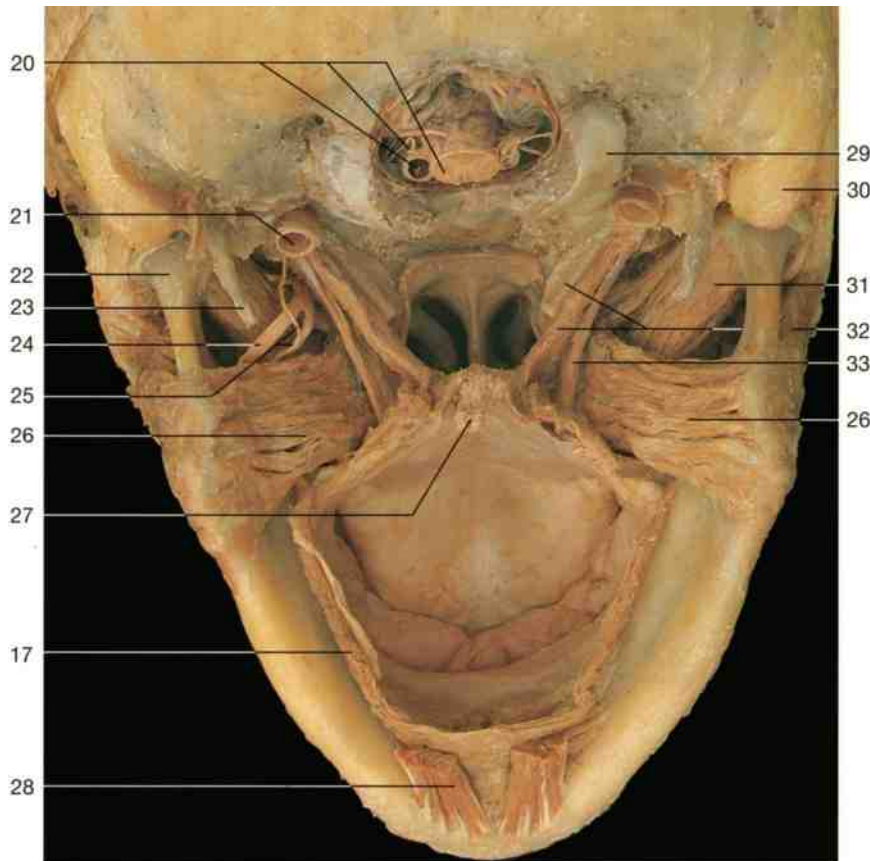
Supra- and infrahyoid muscles and pharynx (lateral aspect). Buccinator muscle removed; oral cavity opened.

- 1 External acoustic meatus
- 2 Tensor veli palatini muscle
- 3 Styloid process
- 4 Superior constrictor muscle of pharynx
- 5 Stylopharyngeus muscle (divided)
- 6 Middle constrictor muscle of pharynx
- 7 Sternocleidomastoid muscle
- 8 Greater horn of hyoid bone
- 9 Longus capitis muscle
- 10 Inferior constrictor muscle of pharynx
- 11 Temporal fascia
- 12 Tendon of temporalis muscle
- 13 Orbicularis oculi muscle
- 14 Zygomatic arch
- 15 Lateral pterygoid plate
- 16 Parotid duct
- 17 Gingiva of upper jaw (without teeth),
buccinator muscle (divided)
- 18 Pterygomandibular raphe
- 19 Hyoglossus muscle
- 20 Mylohyoid muscle
- 21 Anterior belly of digastric muscle (hyoid bone)
- 22 Sternohyoid and thyrohyoid muscles
- 23 Omohyoid muscle

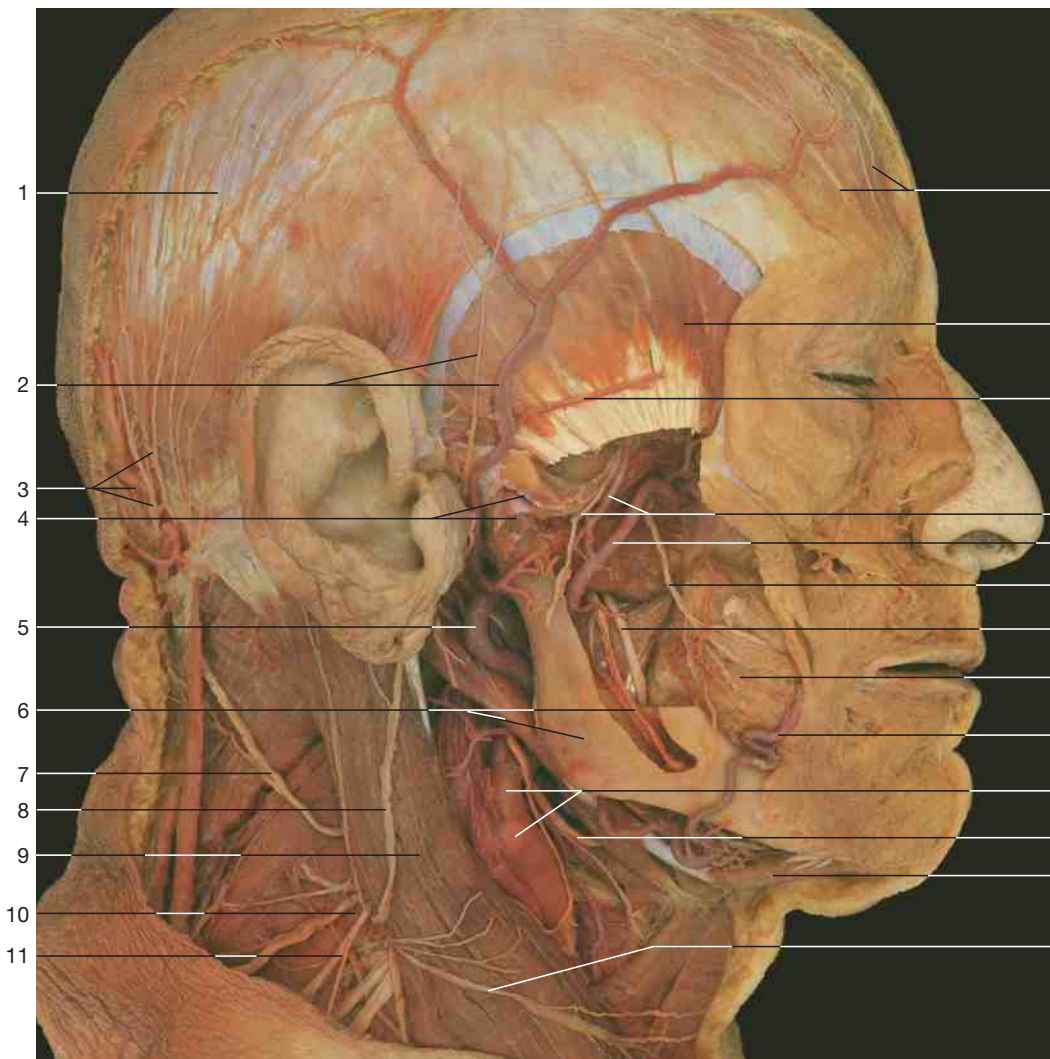
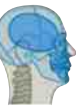

Coronal section through cranial, nasal, and oral cavities at the level of sphenoidal sinus.

- 1 Temporalis muscle
- 2 Sphenoidal sinus
- 3 Nasopharynx
- 4 Masseter muscle
- 5 Superior longitudinal, transverse and vertical muscles of tongue
- 6 Hyoglossus muscle
- 7 Geniohyoid muscle
- 8 Corpus callosum (caudate nucleus)
- 9 Optic nerve
- 10 Cavernous sinus
- 11 Zygomatic arch
- 12 Cross section of lateral pterygoid muscle and maxillary artery
- 13 Section of medial pterygoid muscle
- 14 Soft palate
- 15 Mandible and inferior alveolar nerve
- 16 Septum of the tongue
- 17 Mylohyoid muscle
- 18 Submandibular gland
- 19 Platysma muscle
- 20 Foramen magnum, vertebral artery and spinal cord
- 21 Internal carotid artery
- 22 Head of mandible
- 23 Styloid process
- 24 Inferior alveolar nerve
- 25 Lingual nerve and chorda tympani nerve
- 26 Medial pterygoid muscle
- 27 Uvula
- 28 Anterior belly of digastric muscle (cut)
- 29 Condyle of occipital bone
- 30 Mastoid process
- 31 Lateral pterygoid muscle
- 32 Auditory tube and levator veli palatini muscle
- 33 Tensor veli palatini muscle

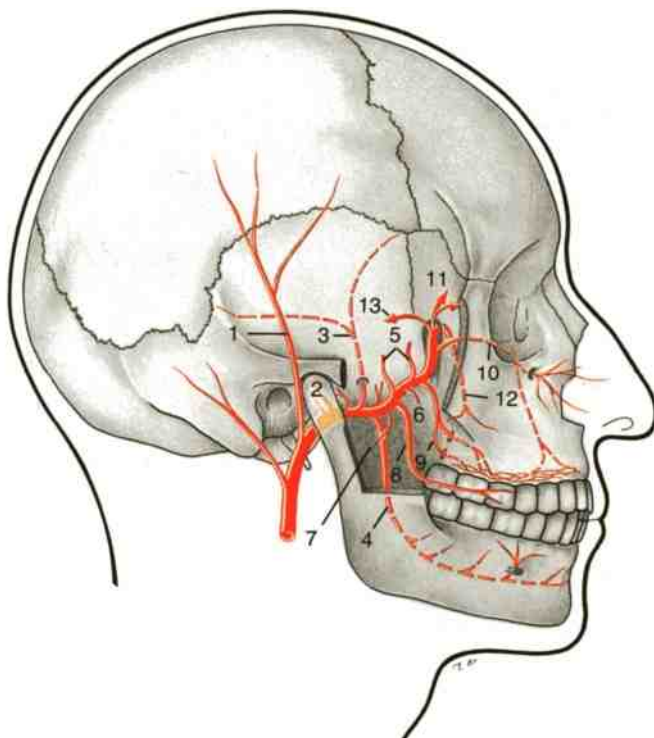


Pterygoid and palatine muscles (posterior aspect).



- 1 Galea aponeurotica
- 2 Superficial temporal artery and auriculo-temporal nerve
- 3 Occipital artery and greater occipital nerve (C₂)
- 4 Temporomandibular joint (opened)
- 5 External carotid artery
- 6 Mandible and inferior mandibular artery and nerve
- 7 Accessory nerve (Var.)
- 8 Great auricular nerve
- 9 Sternocleidomastoid muscle
- 10 Punctum nervosum
- 11 Supraclavicular nerves
- 12 Supra-orbital nerves
- 13 Temporalis muscle
- 14 Transverse facial artery
- 15 Masseteric nerve and deep temporal branch of maxillary artery
- 16 Maxillary artery
- 17 Buccal nerve
- 18 Lingual nerve
- 19 Buccinator muscle
- 20 Facial artery
- 21 External carotid artery and sinus caroticus
- 22 Hypoglossal nerve
- 23 Digastric muscle
- 24 Transverse cervical nerves

Dissection of maxillary artery (lateral aspect). Ramus mandibulae partly removed and canalis mandibulae opened.



Main branches of maxillary artery (schematic drawing).

- 1 Superficial temporal artery

Branches of the first part

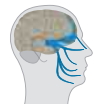- 2 Deep auricular artery and anterior tympanic artery
- 3 Middle meningeal artery
- 4 Inferior alveolar artery

Branches of the second part

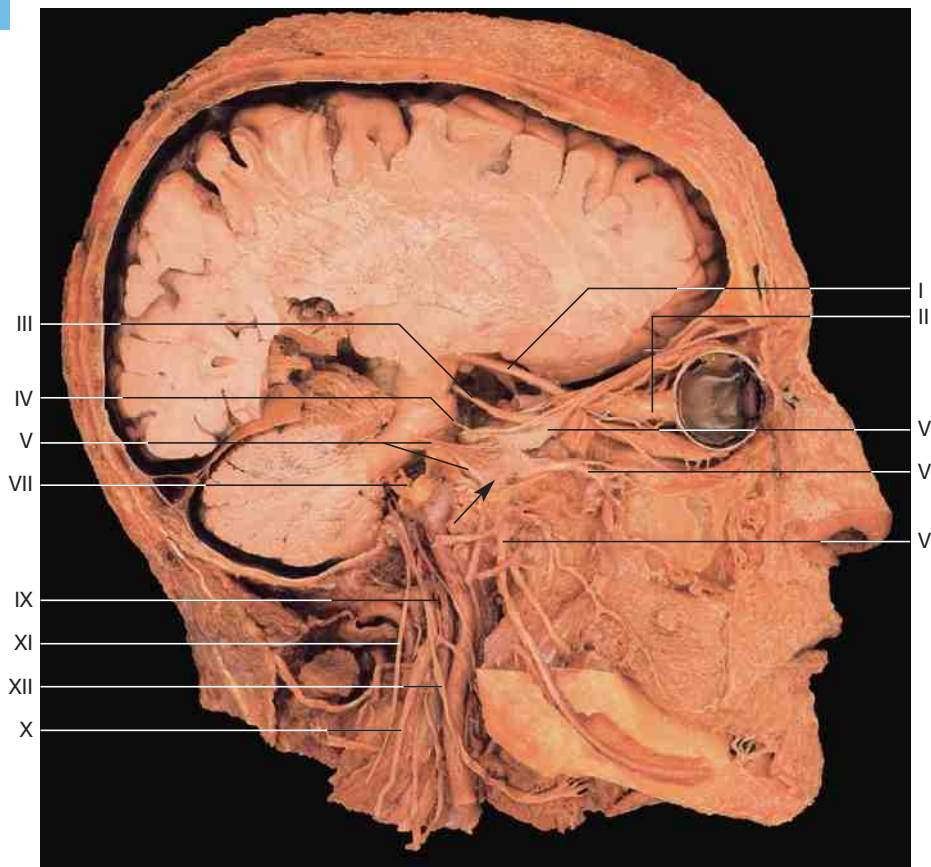
- 5 Deep temporal branches
- 6 Pterygoid branches
- 7 Masseteric artery
- 8 Buccal artery

Branches of the third part

- 9 Posterior superior alveolar artery
- 10 Infra-orbital artery
- 11 Sphenopalatine artery and branches to the nasal cavity
- 12 Descending palatine artery
- 13 Artery of the pterygoid canal



2.2 Cranial Nerves

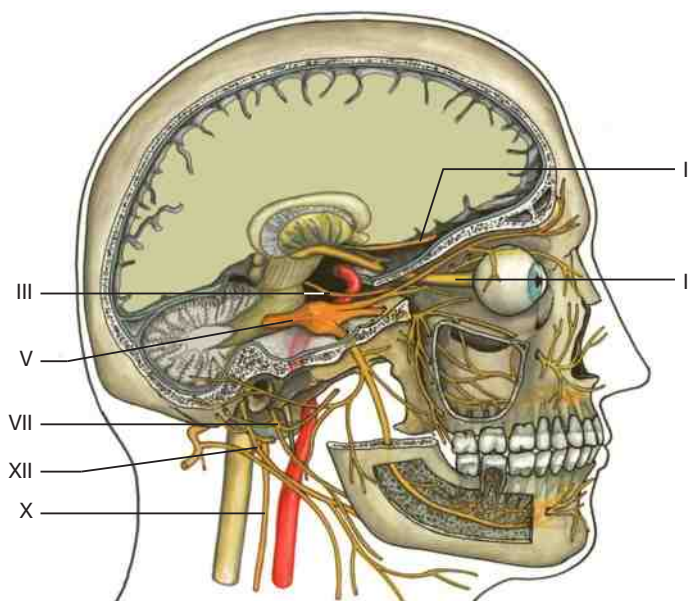


Dissection of the cranial nerves (indicated by I–XII) (lateral aspect). Brain, brain stem, and cerebellum have been partly removed (from Lütjen-Drecolt, Rohen, *Innenansichten des menschlichen Körpers*, 2010).

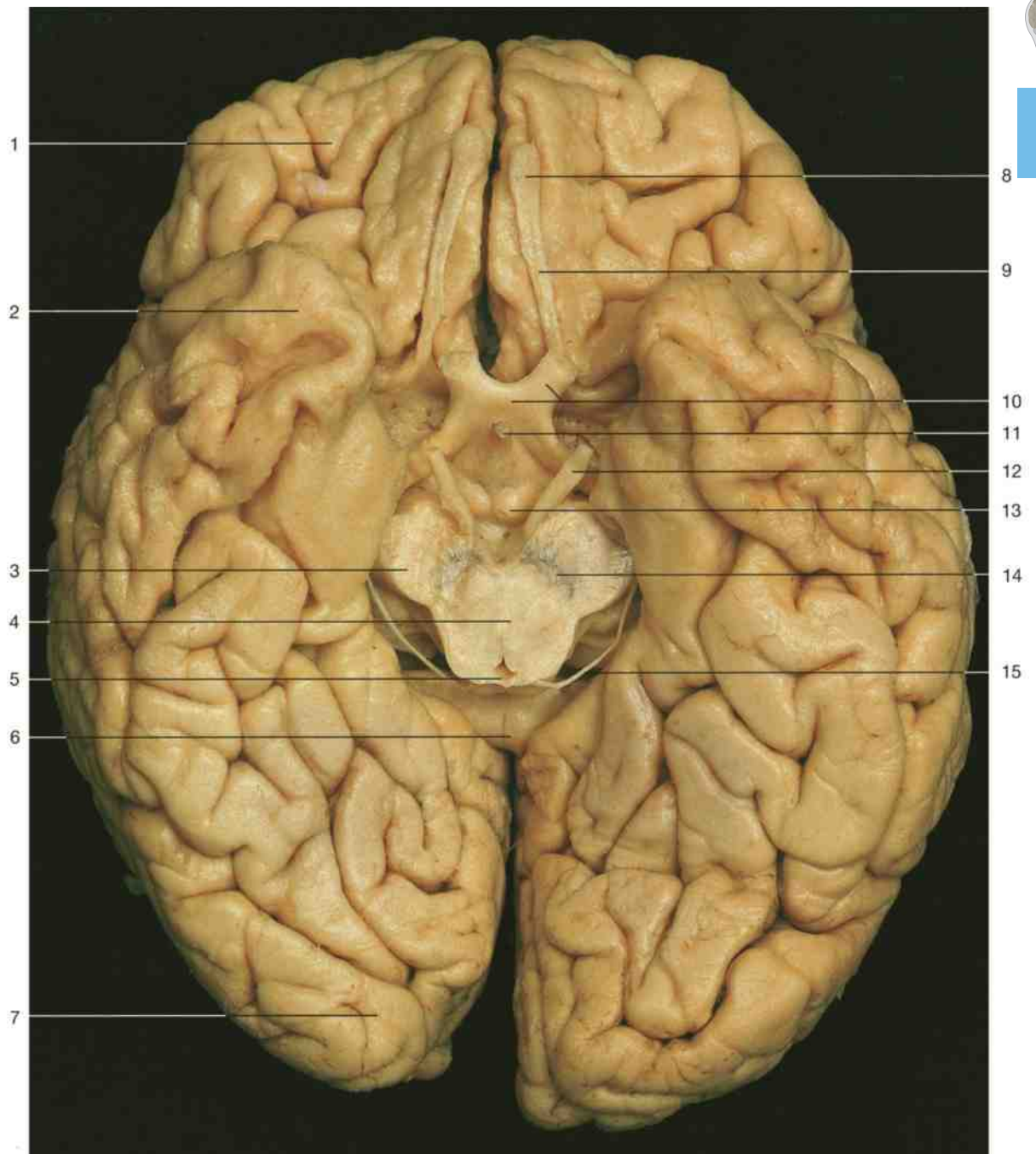
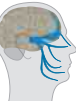The twelve cranial nerves emerge from the brain stem and penetrate the skull at different places. The olfactory nerves (n. I) pass the lamina cribrosa innervating the upper part of the nasal mucous membrane. The optic nerve (n. II) is related to the eye. The external ocular muscles are innervated by the oculomotor, trochlear, and abducent nerves (n. III, n. IV, and n. VI). Facial skin and masticatory muscles are innervated by the trigeminal nerve (n. V) while the facial nerve (n. VII) innervates mainly the mimic musculature. The stato-acoustic organ is related to the vestibulocochlear nerve (n. VIII). The vagus nerve (n. X) is one of the longest cranial nerves, running through the lateral neck region to reach the thoracic and abdominal cavities. It belongs to the parasympathetic part of the autonomic nervous system. The glossopharyngeal (n. IX), accessory (n. XI), and hypoglossal (n. XII) nerves innervate the muscles of the neck, the tongue, and the pharynx. During human evolution, they were incorporated secondarily into the brain cavity.

Cranial nerves

- I = Olfactory nerves
- II = Optic nerve
- III = Oculomotor nerve
- IV = Trochlear nerve
- V = Trigeminal nerve
- VI = Abducent nerve
- VII = Facial nerve
- VIII = Vestibulocochlear nerve
- IX = Glossopharyngeal nerve
- X = Vagus nerve
- XI = Accessory nerve
- XII = Hypoglossal nerve

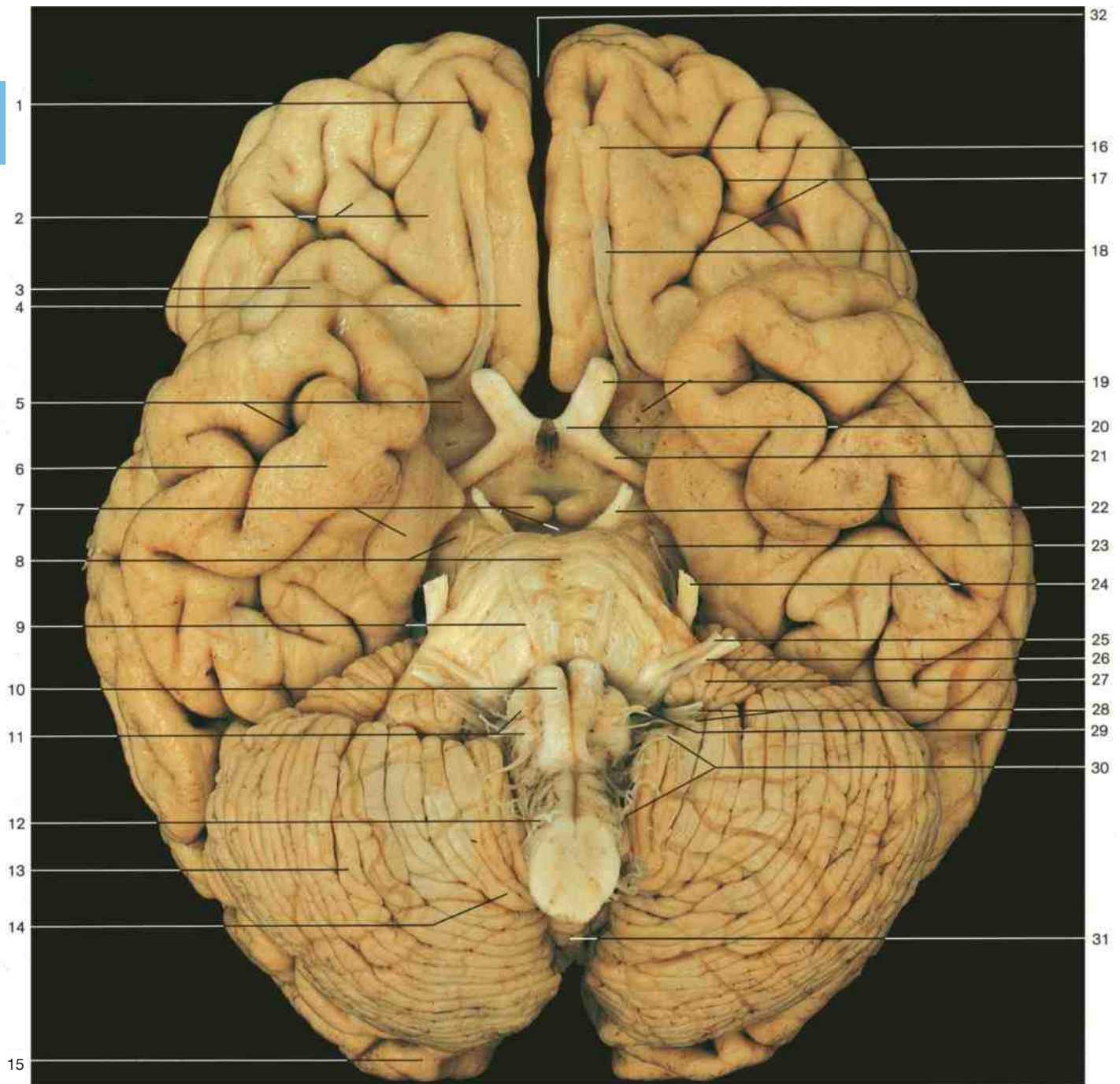
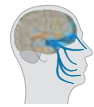

Schematic drawing of the cranial nerves (indicated by I–XII) (lateral aspect).



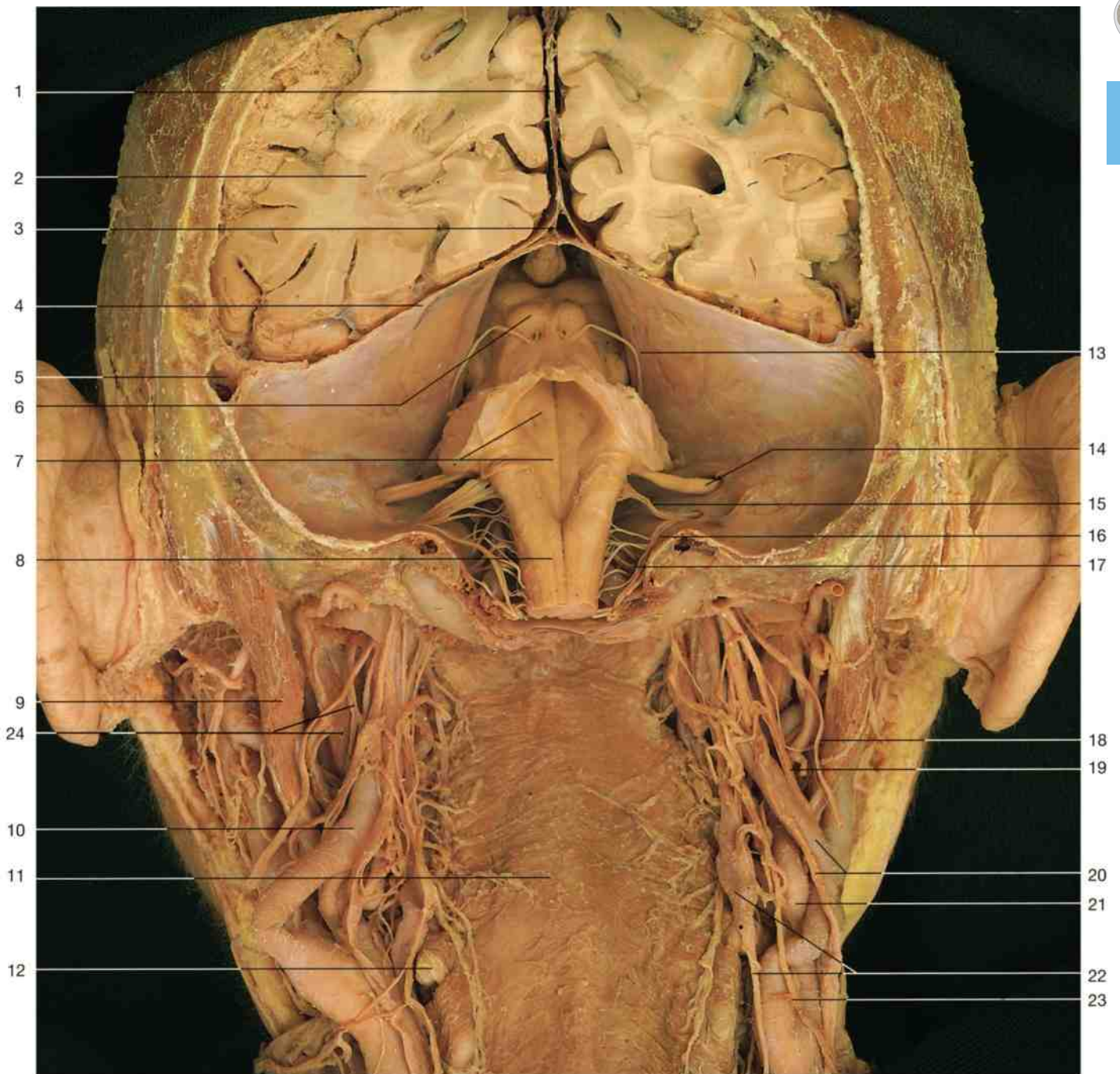
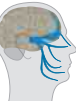Inferior aspect of the brain with cranial nerves. Midbrain divided.

- | | |
|-------------------------------|----------------------------------|
| 1 Frontal lobe | 9 Olfactory tract |
| 2 Temporal lobe | 10 Optic nerve and optic chiasma |
| 3 Pedunculus cerebri | 11 Infundibulum |
| 4 Midbrain (divided) | 12 Oculomotor nerve (n. III) |
| 5 Cerebral aqueduct | 13 Mamillary body |
| 6 Splenium of corpus callosum | 14 Substantia nigra |
| 7 Occipital lobe | 15 Trochlear nerve (n. IV) |
| 8 Olfactory bulb | |



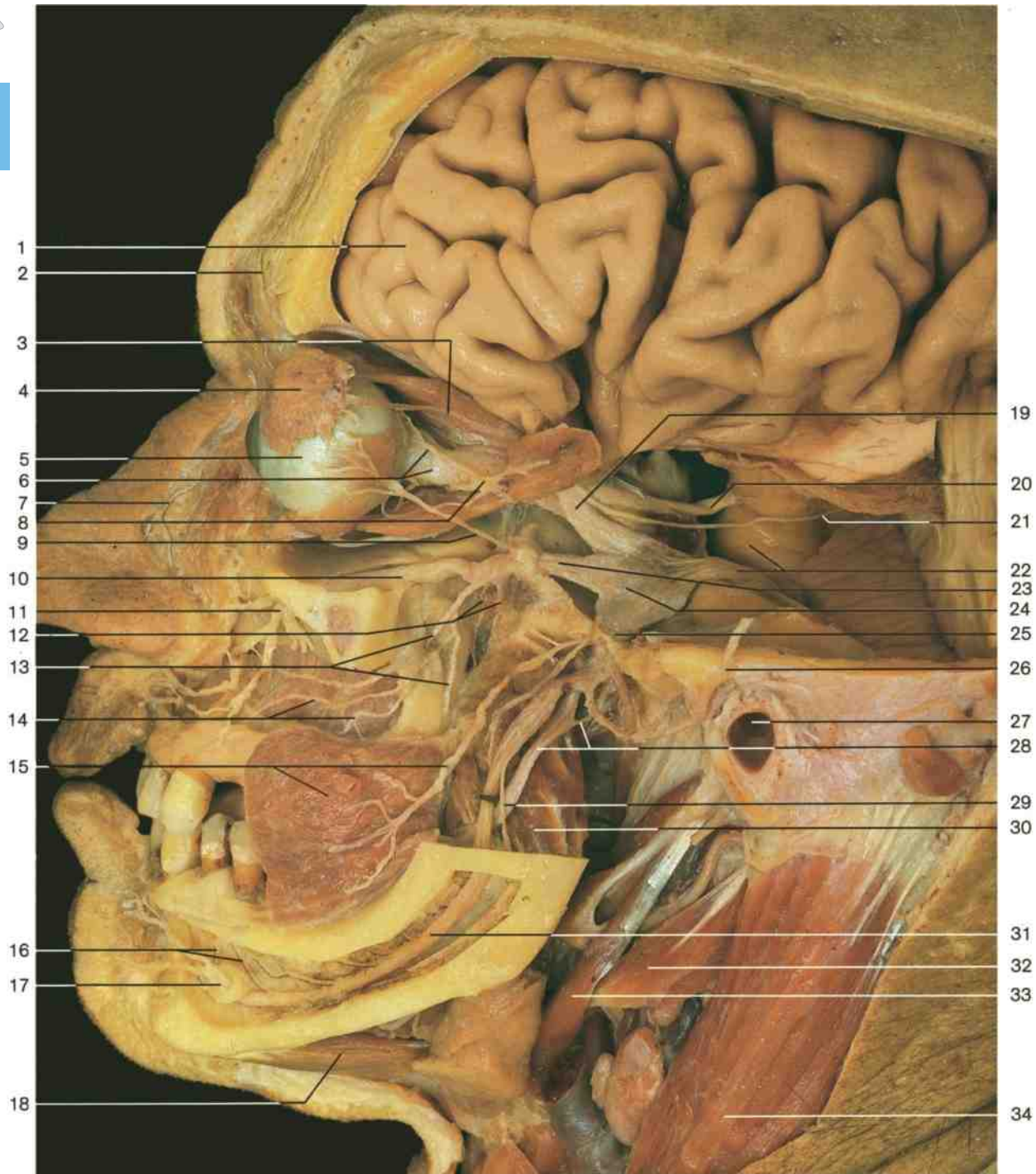
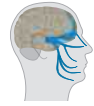Cranial nerves. Brain (inferior aspect).

- | | | |
|--|--|---|
| 1 Olfactory sulcus (termination) | 13 Cerebellum | 25 Facial nerve (n. VII) |
| 2 Orbital gyri | 14 Tonsil of cerebellum | 26 Vestibulocochlear nerve (n. VIII) |
| 3 Temporal lobe | 15 Occipital lobe (posterior pole) | 27 Flocculus of cerebellum |
| 4 Straight gyrus | 16 Olfactory bulb | 28 Glossopharyngeal nerve (n. IX)
and vagus nerve (n. X) |
| 5 Olfactory trigone and inferior temporal sulcus | 17 Orbital sulci of frontal lobe | 29 Hypoglossal nerve (n. XII) |
| 6 Medial occipitotemporal gyrus | 18 Olfactory tract | 30 Accessory nerve (n. XI) |
| 7 Parahippocampal gyrus, mamillary body, and interpeduncular fossa | 19 Optic nerve (n. II) and anterior perforated substance | 31 Vermis of cerebellum |
| 8 Pons and cerebral peduncle | 20 Optic chiasma | 32 Longitudinal fissure |
| 9 Abducent nerve (n. VI) | 21 Optic tract | |
| 10 Pyramid | 22 Oculomotor nerve (n. III) | |
| 11 Inferior olive | 23 Trochlear nerve (n. IV) | |
| 12 Cervical spinal nerves | 24 Trigeminal nerve (n. V) | |



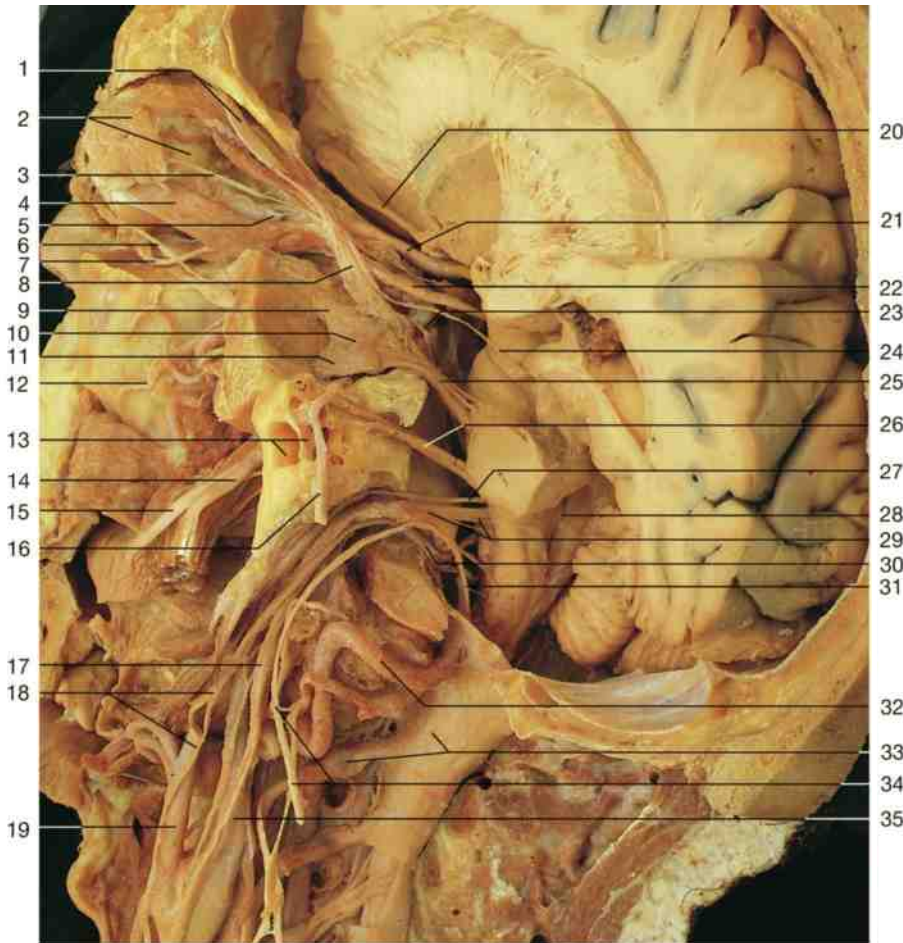
Brain stem and pharynx with cranial nerves (posterior aspect). Cranial cavity opened and cerebellum removed.

- | | | |
|---------------------------------------|--|--|
| 1 Falx cerebri | 11 Pharynx (middle constrictor muscle) | 19 Hypoglossal nerve (n. XII) |
| 2 Occipital lobe | 12 Hyoid bone (greater horn) | 20 Vagus nerve (n. X) and internal carotid artery |
| 3 Straight sinus | 13 Trochlear nerve (n. IV) | 21 External carotid artery |
| 4 Tentorium cerebelli | 14 Facial nerve (n. VII) and vestibulocochlear nerve (n. VIII) | 22 Sympathetic trunk and superior cervical ganglion |
| 5 Transverse sinus | 15 Glossopharyngeal nerve (n. IX) and vagus nerve (n. X) | 23 Ansa cervicalis (superior root of hypoglossal nerve) |
| 6 Inferior colliculus of midbrain | 16 Accessory nerve (intracranial portion) (n. XI) | 24 Glossopharyngeal nerve (n. IX) and stylopharyngeus muscle |
| 7 Rhomboid fossa | 17 Hypoglossal nerve (intracranial portion) (n. XII) | |
| 8 Medulla oblongata | 18 Accessory nerve (n. XI) | |
| 9 Posterior belly of digastric muscle | | |
| 10 Internal carotid artery | | |



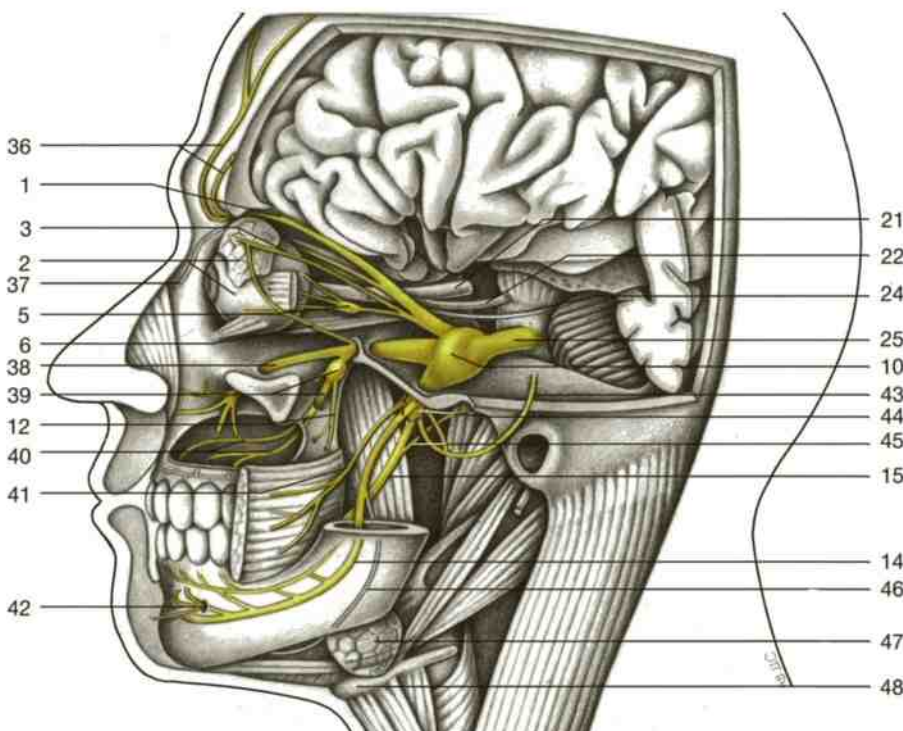
Dissection of the trigeminal nerve in its entirety. Lateral wall of cranial cavity, lateral wall of orbit, zygomatic arch, and ramus of the mandible have been removed and the mandibular canal opened.

- | | | |
|---|--|--|
| 1 Frontal lobe of cerebrum | 12 Pterygopalatine ganglion and pterygopalatine nerves | 23 Maxillary nerve (n. V ₂) |
| 2 Supra-orbital nerve | 13 Posterior superior alveolar nerves | 24 Trigeminal ganglion |
| 3 Lacrimal nerve | 14 Superior dental plexus | 25 Mandibular nerve (n. V ₃) |
| 4 Lacrimal gland | 15 Buccinator muscle and buccal nerve | 26 Auriculotemporal nerve |
| 5 Eyeball | 16 Inferior dental plexus | 27 External acoustic meatus (divided) |
| 6 Optic nerve and short ciliary nerves | 17 Mental foramen and mental nerve | 28 Lingual nerve and chorda tympani |
| 7 External nasal branch of anterior ethmoidal nerve | 18 Anterior belly of digastric muscle | 29 Mylohyoid nerve |
| 8 Ciliary ganglion | 19 Ophthalmic nerve (n. V ₁) | 30 Medial pterygoid muscle |
| 9 Zygomatic nerve | 20 Oculomotor nerve (n. III) | 31 Inferior alveolar nerve |
| 10 Infra-orbital nerve | 21 Trochlear nerve (n. IV) | 32 Posterior belly of digastric muscle |
| 11 Infra-orbital foramen and terminal branches of infra-orbital nerve | 22 Trigeminal nerve and pons | 33 Stylohyoid muscle |
| | | 34 Sternocleidomastoid muscle |

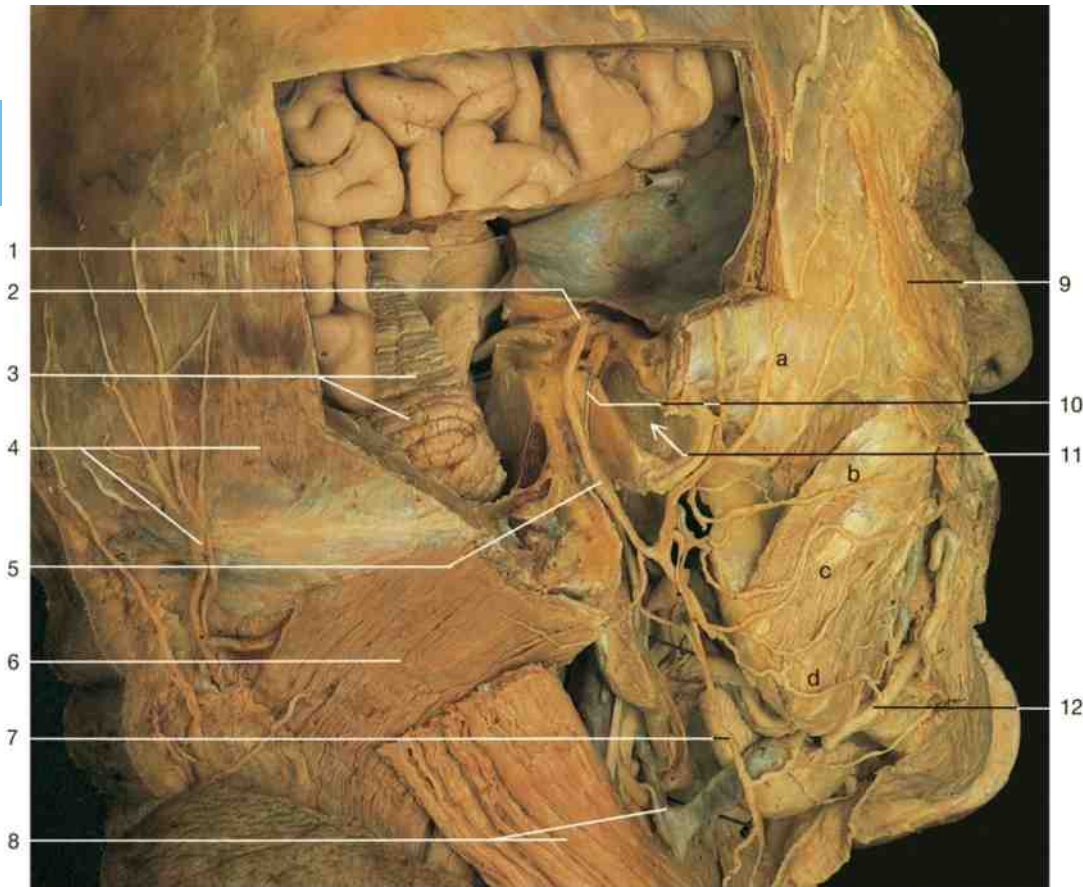


- 1 Frontal nerve
- 2 Lacrimal gland and eyeball
- 3 Lacrimal nerve
- 4 Lateral rectus muscle
- 5 Ciliary ganglion lateral to optic nerve
- 6 Zygomatic nerve
- 7 Inferior branch of oculomotor nerve
- 8 Ophthalmic nerve (n. V₁)
- 9 Maxillary nerve (n. V₂)
- 10 Trigeminal ganglion
- 11 Mandibular nerve (n. V₃)
- 12 Posterior superior alveolar nerves
- 13 Tympanic cavity, external acoustic meatus, and tympanic membrane
- 14 Inferior alveolar nerve
- 15 Lingual nerve
- 16 Facial nerve (n. VII)
- 17 Vagus nerve (n. X)
- 18 Hypoglossal nerve (n. XII) and superior root of ansa cervicalis
- 19 External carotid artery
- 20 Olfactory tract (n. I)
- 21 Optic nerve (n. II) (intracranial part)
- 22 Oculomotor nerve (n. III)
- 23 Abducent nerve (n. VI)
- 24 Trochlear nerve (n. IV)
- 25 Trigeminal nerve (n. V)
- 26 Vestibulocochlear nerve (n. VIII) and facial nerve (n. VII)
- 27 Glossopharyngeal nerve (n. IX) (leaving brain stem)
- 28 Rhomboid fossa
- 29 Vagus nerve (n. X) (leaving brain stem)
- 30 Hypoglossal nerve (n. XII) (leaving medulla oblongata)
- 31 Accessory nerve (n. XI) (ascending from foramen magnum)
- 32 Vertebral artery
- 33 Spinal ganglion and dura mater of spinal cord
- 34 Accessory nerve (n. XI)
- 35 Internal carotid artery
- 36 Lateral and medial branch of supra-orbital nerve
- 37 Infratrochlear nerve
- 38 Infra-orbital nerve
- 39 Pterygopalatine ganglion and middle superior alveolar nerve
- 40 Middle superior alveolar nerves (entering superior dental plexus)
- 41 Buccal nerve
- 42 Mental nerve and mental foramen
- 43 Auriculotemporal nerve
- 44 Otic ganglion (dotted line)
- 45 Chorda tympani
- 46 Mylohyoid nerve
- 47 Submandibular gland
- 48 Hyoid bone

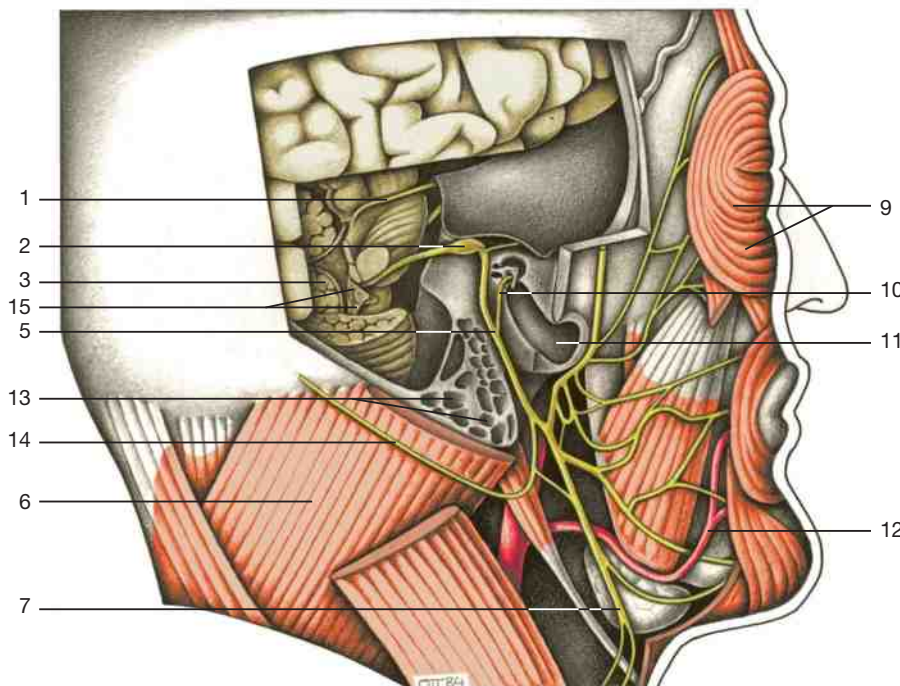
Cranial nerves in connection with the brain stem. Left side (lateral superior aspect). Left half of brain and head partly removed. Notice the location of trigeminal ganglion.



Main branches of trigeminal nerve (schematic drawing of figure on opposite page).



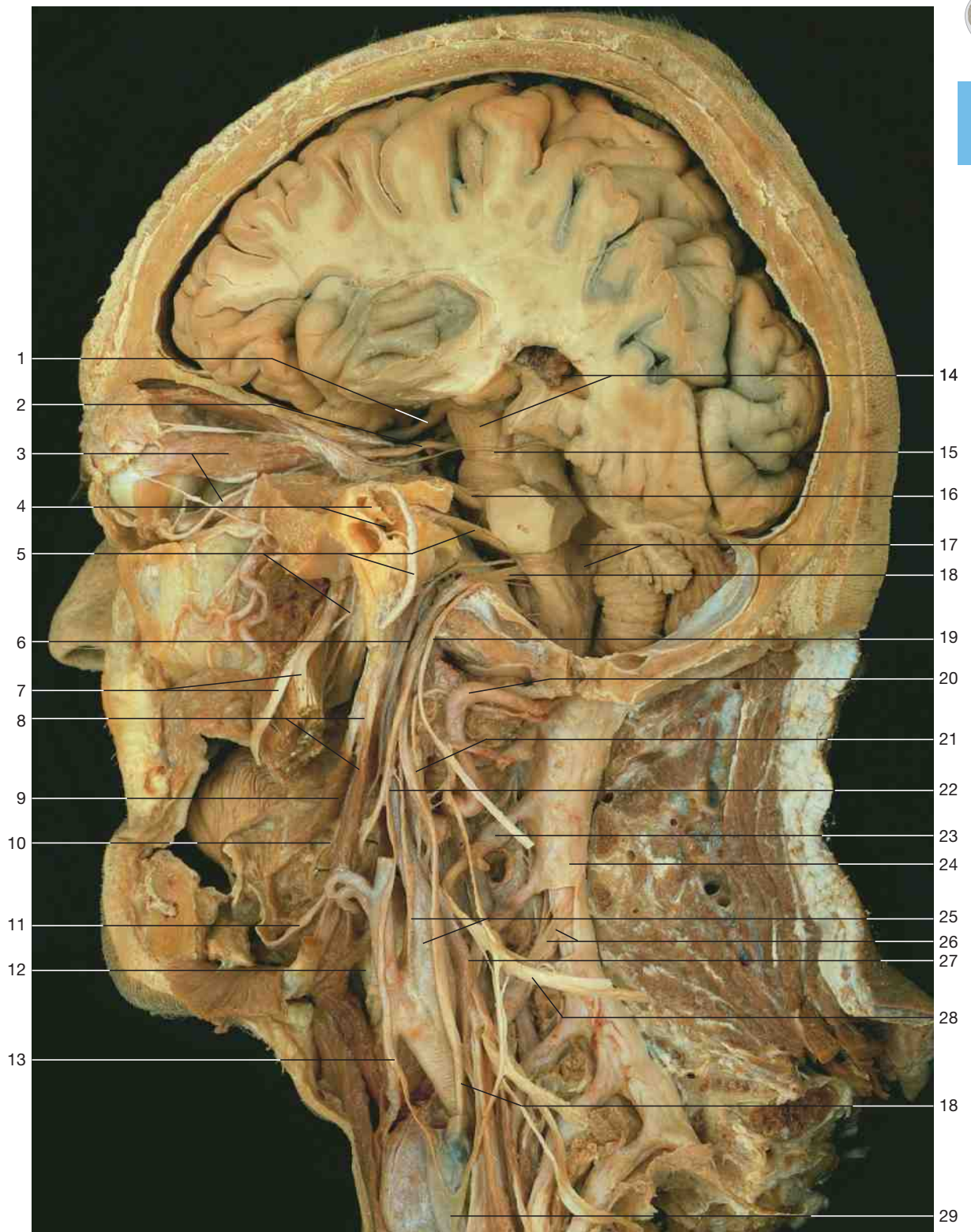
Dissection of facial nerve in its entirety. Cranial cavity fenestrated; temporal lobe partly removed. Facial canal and tympanic cavity opened, posterior wall of external acoustic meatus removed. **Branches of facial nerve:** a = temporal branch; b = zygomatic branches; c = buccal branches; d = marginal mandibular branch.



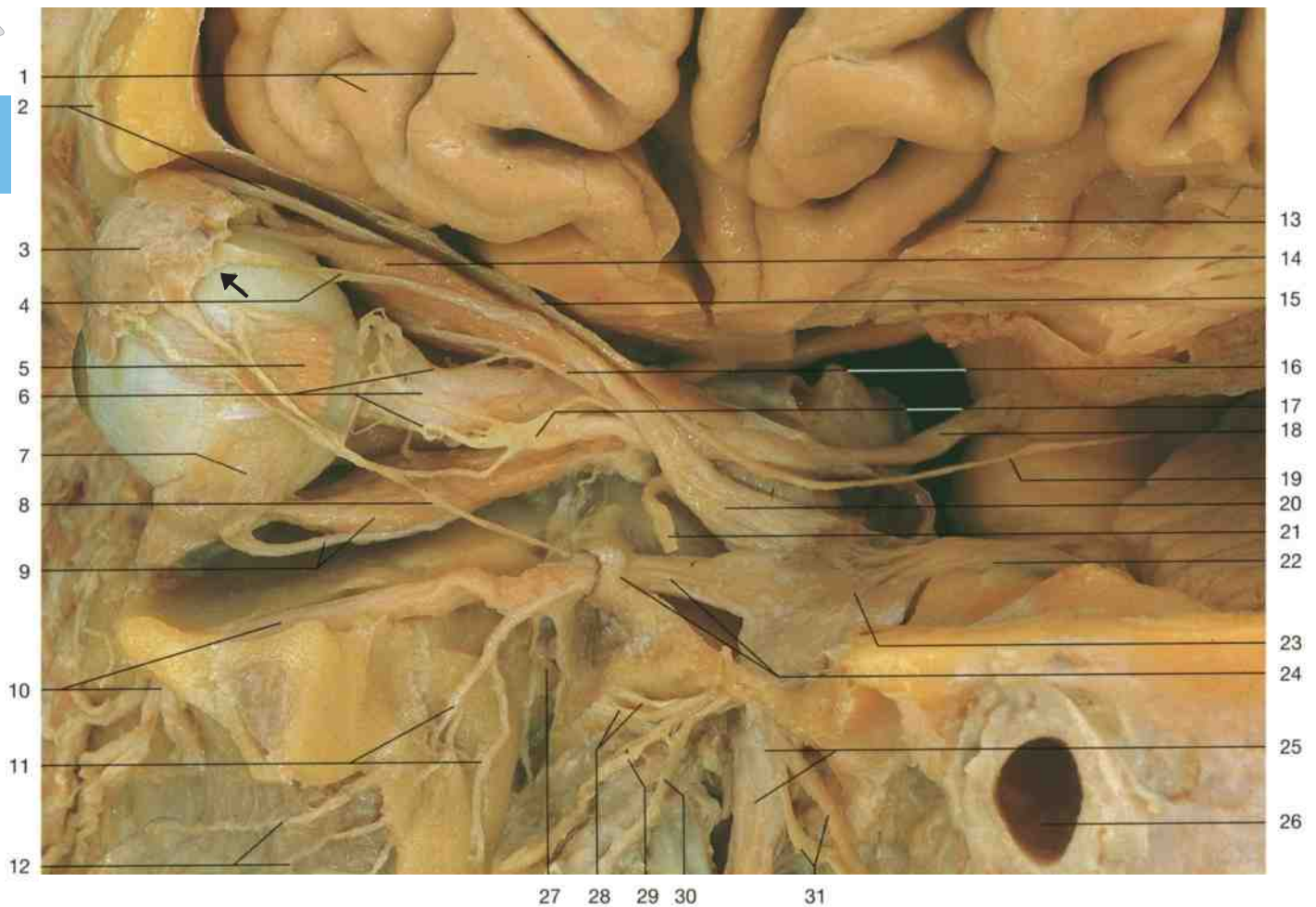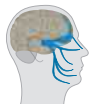- 1 Trochlear nerve
- 2 Facial nerve with geniculate ganglion
- 3 Cerebellum (right hemisphere)
- 4 Occipital belly of occipitofrontalis muscle and greater occipital nerve
- 5 Facial nerve at stylomastoid foramen
- 6 Splenius capitis muscle
- 7 Cervical branch of facial nerve
- 8 Sternocleidomastoid muscle and retromandibular vein
- 9 Orbicularis oculi muscle
- 10 Chorda tympani
- 11 External acoustic meatus
- 12 Facial artery
- 13 Mastoid air cells
- 14 Posterior auricular nerve
- 15 Nucleus and genu of facial nerve

Cranial nerves in connection with the brain stem (oblique-lateral aspect). Lateral portion of the skull, brain and facial structures, lateral wall of orbit and oral cavity have been removed. The tympanic cavity has been opened. The mandible has been divided and the muscles of mastication have been removed.

Facial nerve (schematic drawing of the dissection above).

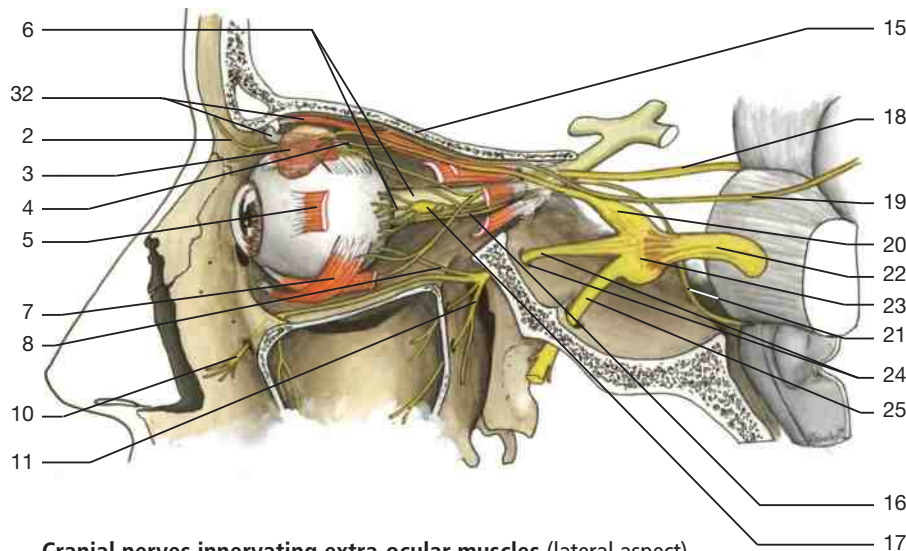


- | | | | | | |
|----|--|----|--|----|--|
| 1 | Optic tract | 11 | Lingual branch of hypoglossal nerve | 22 | Hypoglossal nerve (n. XII) |
| 2 | Oculomotor nerve (n. III) | 12 | External carotid artery | 23 | Spinal ganglion with dural sheath |
| 3 | Lateral rectus muscle and inferior branch of oculomotor nerve | 13 | Superior root of ansa cervicalis (branch of hypoglossal nerve, derived from C ₁) | 24 | Dura mater of spinal cord |
| 4 | Malleus and chorda tympani | 14 | Lateral ventricle with choroid plexus and cerebral peduncle | 25 | Internal carotid artery and carotid sinus branch of glossopharyngeal nerve |
| 5 | Chorda tympani, facial nerve (n. VII), and vestibulocochlear nerve (n. VIII) | 15 | Trochlear nerve (n. IV) | 26 | Dorsal roots of spinal nerve |
| 6 | Glossopharyngeal nerve (n. XI) | 16 | Trigeminal nerve (n. V) | 27 | Sympathetic trunk |
| 7 | Lingual nerve and inferior alveolar nerve | 17 | Fourth ventricle and rhomboid fossa | 28 | Branch of cervical plexus (ventral primary ramus of third cervical spinal nerve) |
| 8 | Styloid process and stylohyoid muscle | 18 | Vagus nerve (n. X) | 29 | Ansa cervicalis |
| 9 | Styloglossus muscle | 19 | Accessory nerve (n. XI) | | |
| 10 | Lingual branches of glossopharyngeal nerve | 20 | Vertebral artery | | |
| | | 21 | Superior cervical ganglion | | |

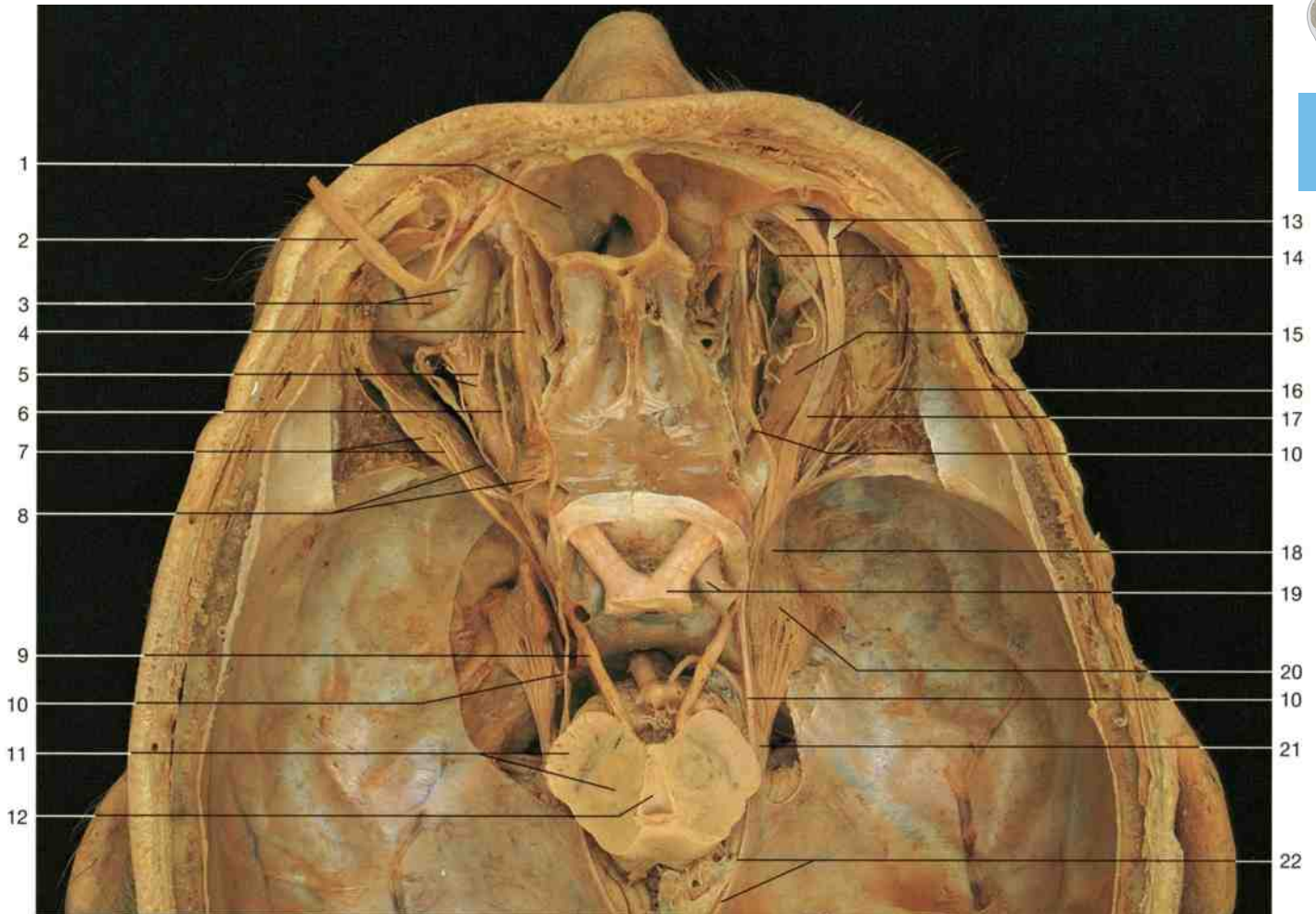


Cranial nerves of the orbit and pterygopalatine fossa. Left orbit (lateral aspect). Note the zygomaticolacrimal anastomosis (arrow).

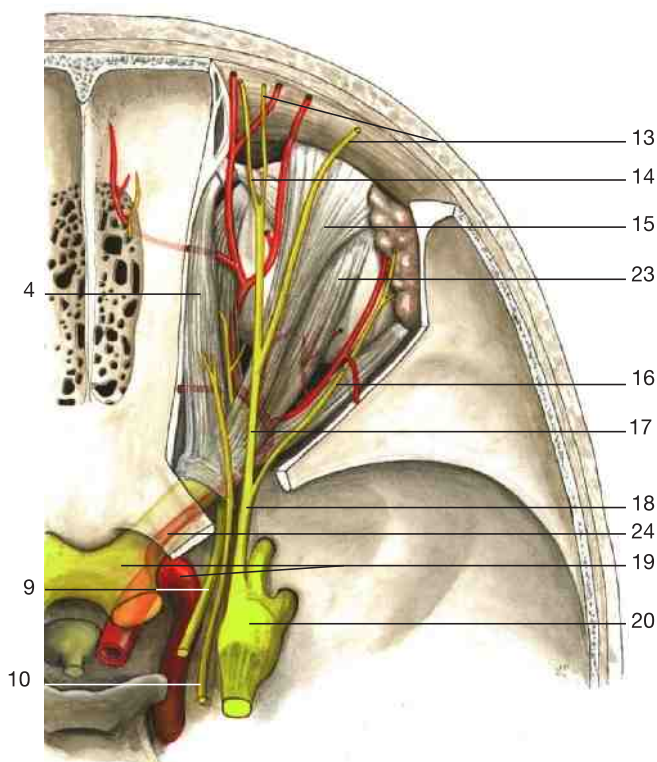
- | | | |
|-----------------------------------|--|--|
| 1 Frontal lobe | 6 Optic nerve and short ciliary nerves | 10 Infra-orbital nerve |
| 2 Supra-orbital nerve | 7 Inferior oblique muscle | 11 Posterior superior alveolar nerves |
| 3 Lacrimal gland | 8 Zygomatic nerve | 12 Branches of superior alveolar plexus adjacent to mucous membrane of maxillary sinus |
| 4 Lacrimal nerve | 9 Inferior branch of oculomotor nerve and inferior rectus muscle | 13 Central sulcus of insula |
| 5 Lateral rectus muscle (divided) | | 14 Superior rectus muscle |
| | | 15 Periorbita (roof of orbit) |
| | | 16 Nasociliary nerve |
| | | 17 Ciliary ganglion |
| | | 18 Oculomotor nerve (n. III) |
| | | 19 Trochlear nerve (n. IV) |
| | | 20 Ophthalmic nerve (n. V ₁) |
| | | 21 Abducent nerve (n. VI) (divided) |
| | | 22 Trigeminal nerve (n. V) |
| | | 23 Trigeminal ganglion |
| | | 24 Maxillary nerve (n. V ₂) and foramen rotundum |
| | | 25 Mandibular nerve (n. V ₃) |
| | | 26 External acoustic meatus |
| | | 27 Pterygopalatine nerves |
| | | 28 Deep temporal nerves |
| | | 29 Buccal nerve |
| | | 30 Masseteric nerve |
| | | 31 Auriculotemporal nerve |
| | | 32 Trochlea and superior oblique muscle |



Cranial nerves innervating extra-ocular muscles (lateral aspect). (Schematic drawing.)

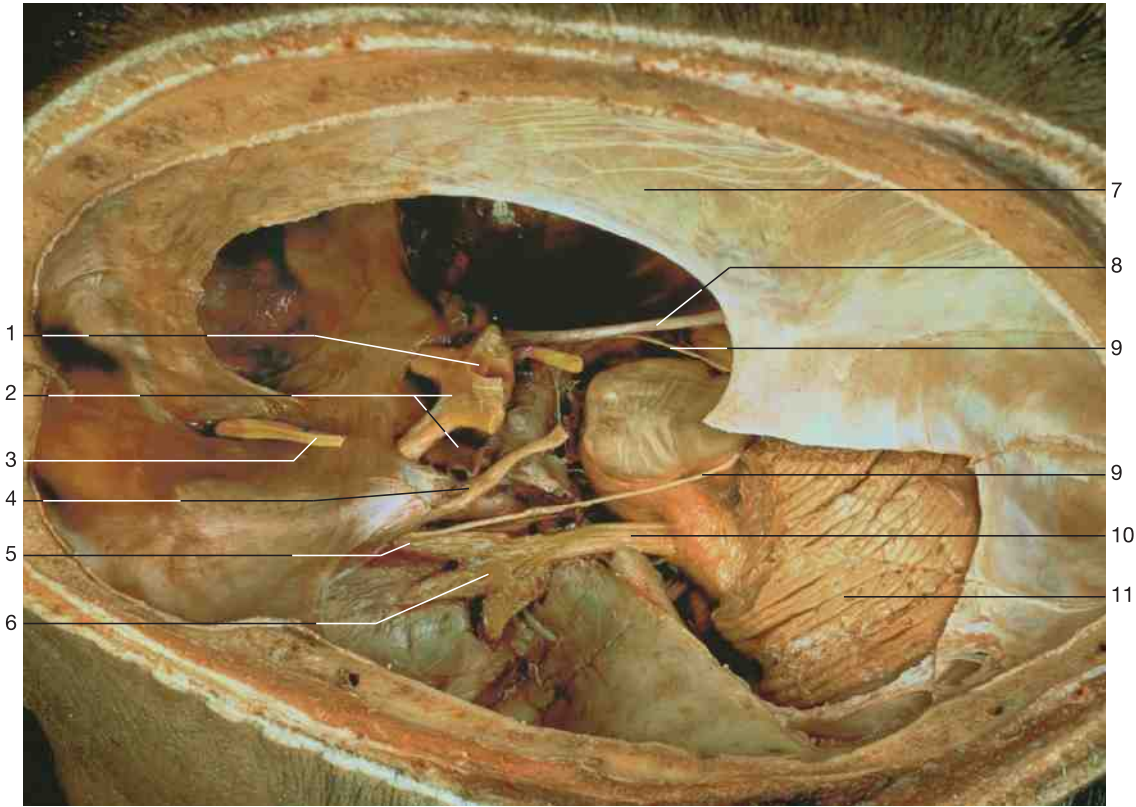
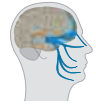
Cranial nerves of the orbit (superior aspect). Right side: superficial layer, left side: middle layer of the orbit (superior rectus muscle and frontal nerve divided and reflected). Tentorium and dura mater partly removed.

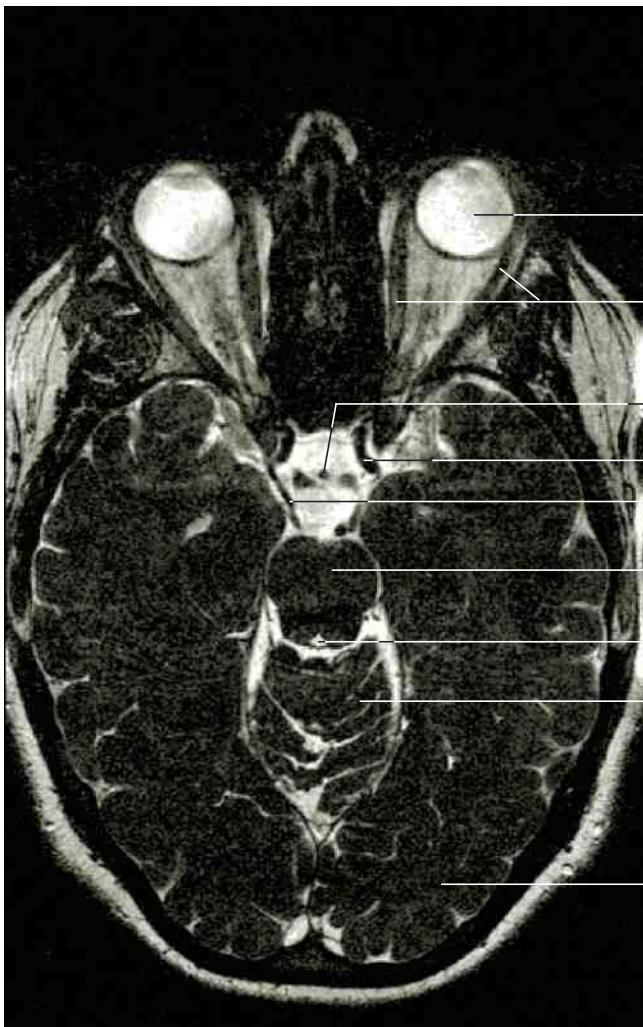


Cranial nerves within the orbit (superior aspect).

- 1 Frontal sinus (enlarged)
- 2 Frontal nerve (divided and reflected)
- 3 Superior rectus muscle (divided) and eyeball
- 4 Superior oblique muscle
- 5 Short ciliary nerves and optic nerve (n. II)
- 6 Nasociliary nerve
- 7 Abducent nerve (n. VI) and lateral rectus muscle
- 8 Ciliary ganglion and superior rectus muscle (reflected)
- 9 Oculomotor nerve (n. III)
- 10 Trochlear nerve (n. IV)
- 11 Crus cerebri and midbrain
- 12 Inferior wall of the third ventricle connected with cerebral aqueduct
- 13 Lateral and medial branches of supra-orbital nerve
- 14 Supratrochlear nerve
- 15 Superior levator palpebrae muscle
- 16 Lacrimal nerve
- 17 Frontal nerve
- 18 Ophthalmic nerve (n. V₁)
- 19 Optic chiasma and internal carotid artery
- 20 Trigeminal ganglion
- 21 Trigeminal nerve (n. V)
- 22 Tentorial notch
- 23 Superior rectus muscle
- 24 Ophthalmic artery

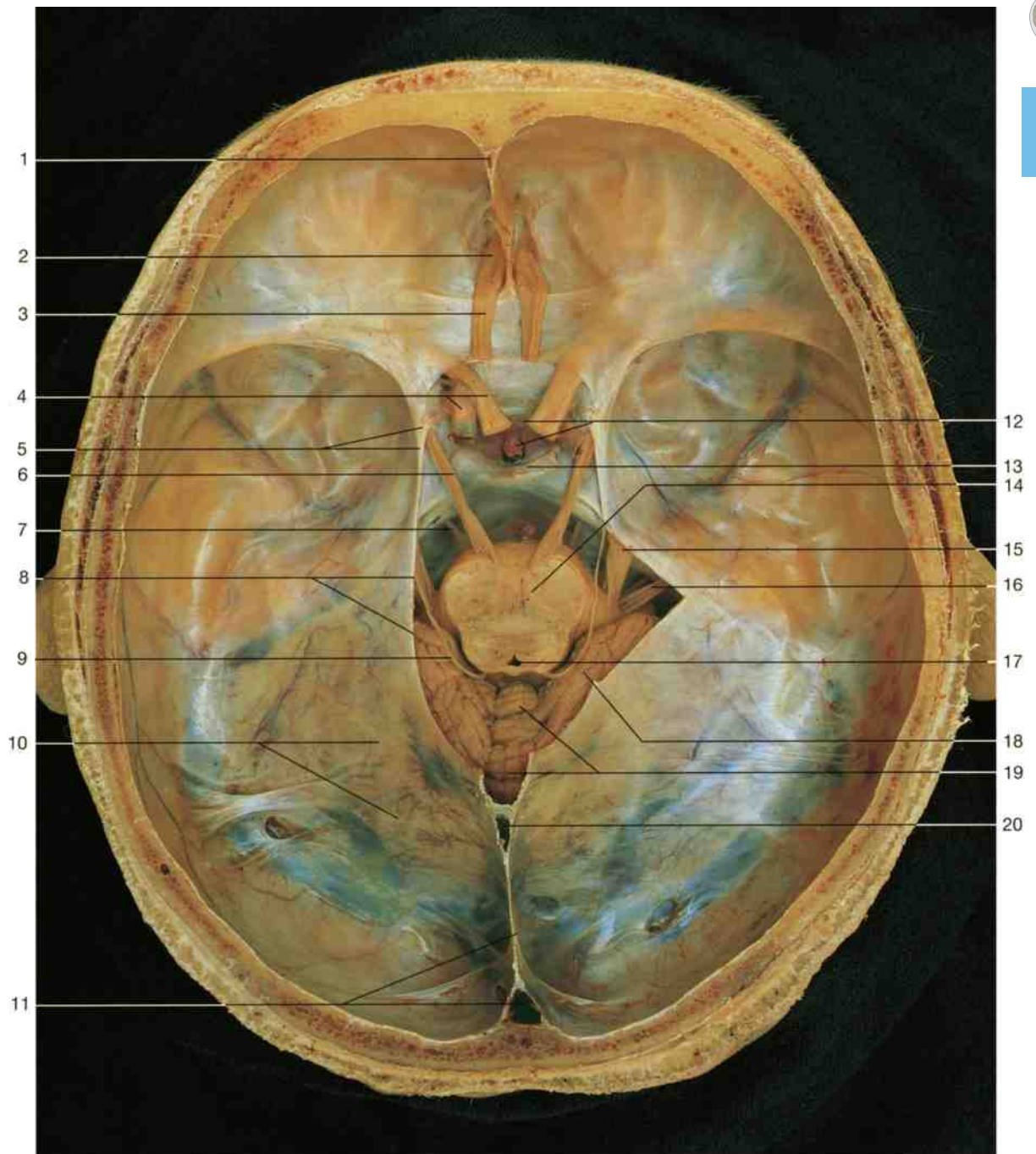


Cranial nerves at the base of the skull. The brain stem was divided and the tentorium fenestrated. Both hemispheres were removed.



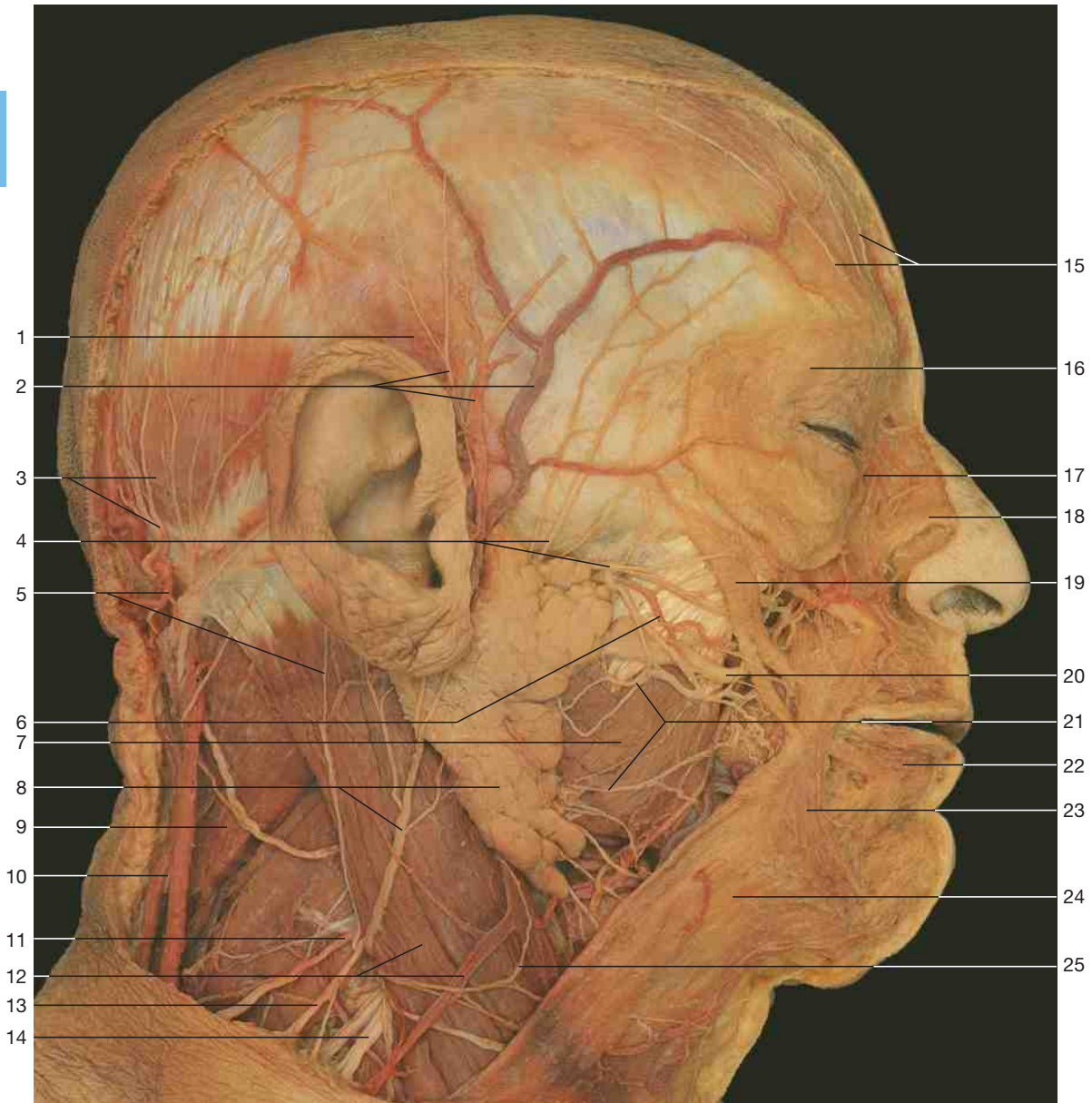
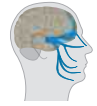- 1 Infundibulum
- 2 Optic chiasma and internal carotid artery
- 3 Olfactory tract
- 4 Oculomotor nerve (n. III)
- 5 Ophthalmic nerve (n. V1)
- 6 Trigeminal ganglion
- 7 Falx cerebri
- 8 Tentorial notch
- 9 Trochlear nerve (n. IV)
- 10 Trigeminal nerve (n. V)
- 11 Cerebellum
- 12 Eyeball
- 13 Medial and lateral rectus muscles
- 14 Internal carotid artery
- 15 Oculomotor nerve (n. III)
- 16 Midbrain
- 17 Cerebral aqueduct
- 18 Vermis of cerebellum
- 19 Occipital lobe of the cerebrum
- 20 Basilar artery

Section through the head at the level of the sella turcica demonstrating cranial nerves (MRI scan, University of Erlangen, Dpt. of Neurosurgery).

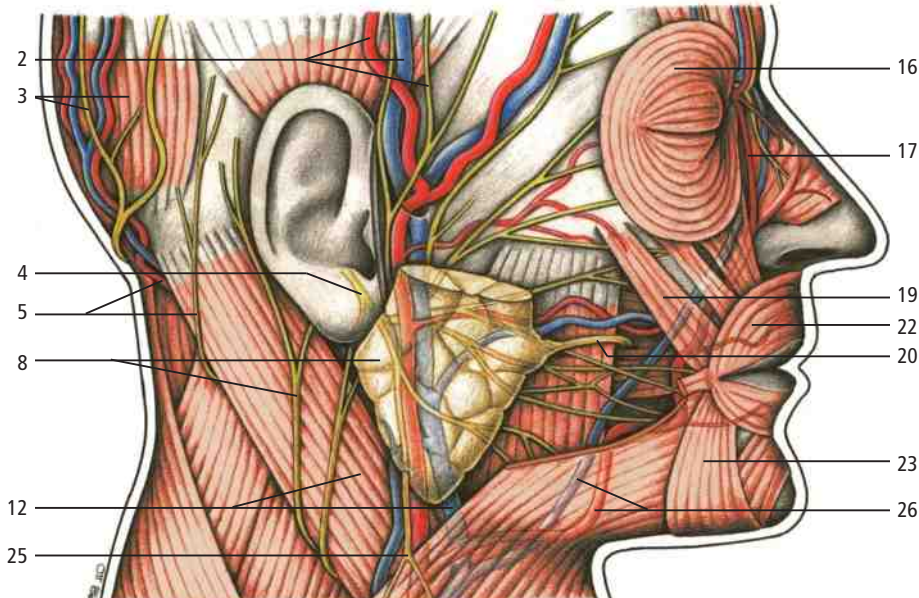


Base of the skull with cranial nerves (internal aspect). Both cerebral hemispheres and upper part of the brain stem removed. Incision on the right tentorium cerebelli to display the cranial nerves of the infratentorial space.

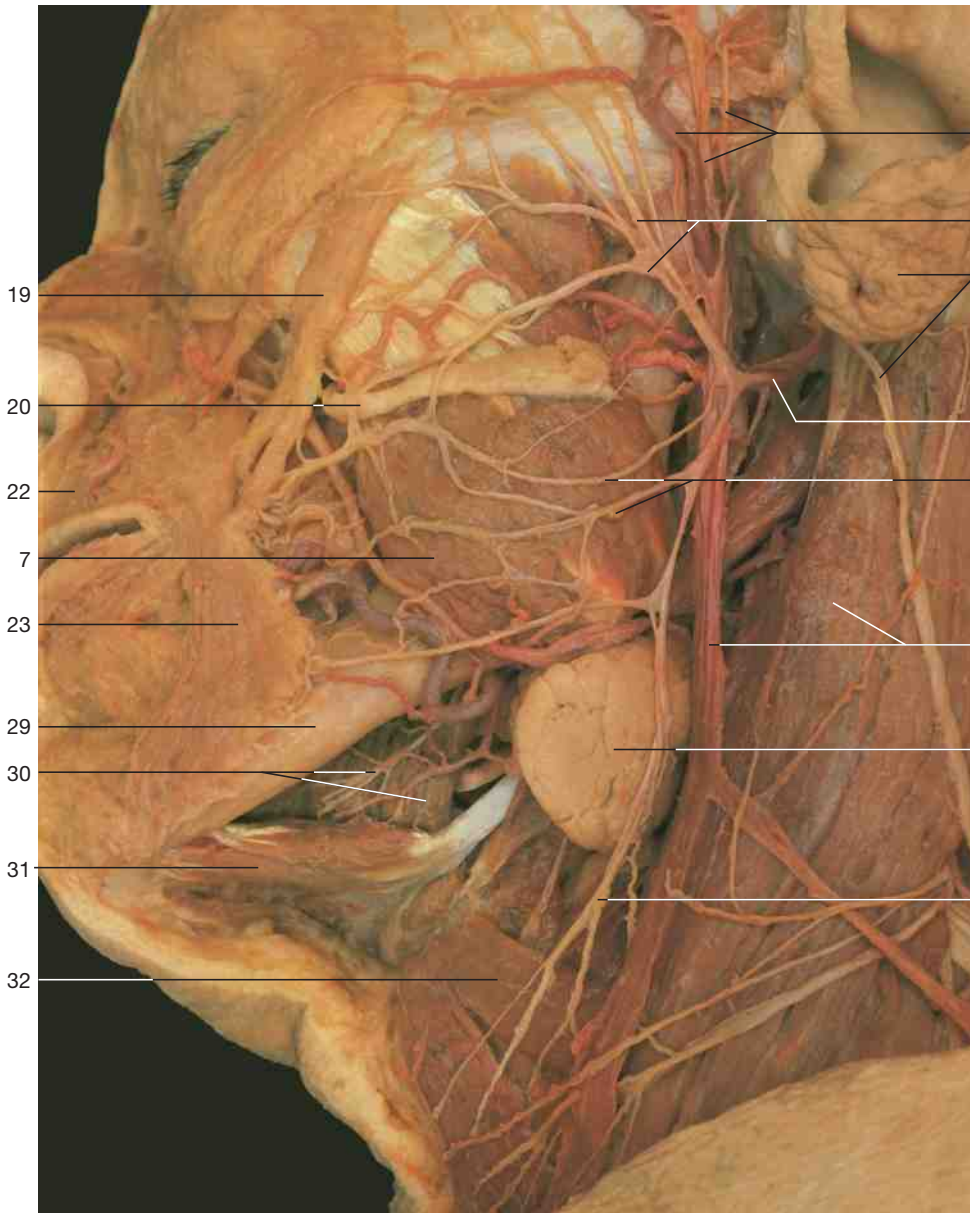
- | | |
|---|---|
| 1 Superior sagittal sinus with falx cerebri | 12 Hypophysial fossa, infundibulum, and diaphragma sellae |
| 2 Olfactory bulb | 13 Dorsum sellae |
| 3 Olfactory tract | 14 Midbrain (divided) |
| 4 Optic nerve and internal carotid artery | 15 Trigeminal nerve (n. V) |
| 5 Anterior clinoid process and anterior attachment of tentorium cerebelli | 16 Facial nerve (n. VII), nervus intermedius, and vestibulocochlear nerve (n. VIII) |
| 6 Oculomotor nerve (n. III) | 17 Cerebral aqueduct |
| 7 Abducent nerve (n. VI) | 18 Right hemisphere of cerebellum |
| 8 Tentorial notch (incisura tentorii) | 19 Vermis of cerebellum |
| 9 Trochlear nerve (n. IV) | 20 Straight sinus |
| 10 Tentorium cerebelli | |
| 11 Falx cerebri and confluence of sinuses | |



Lateral superficial aspect of the face. Peripheral distribution of facial nerve (n. VII).

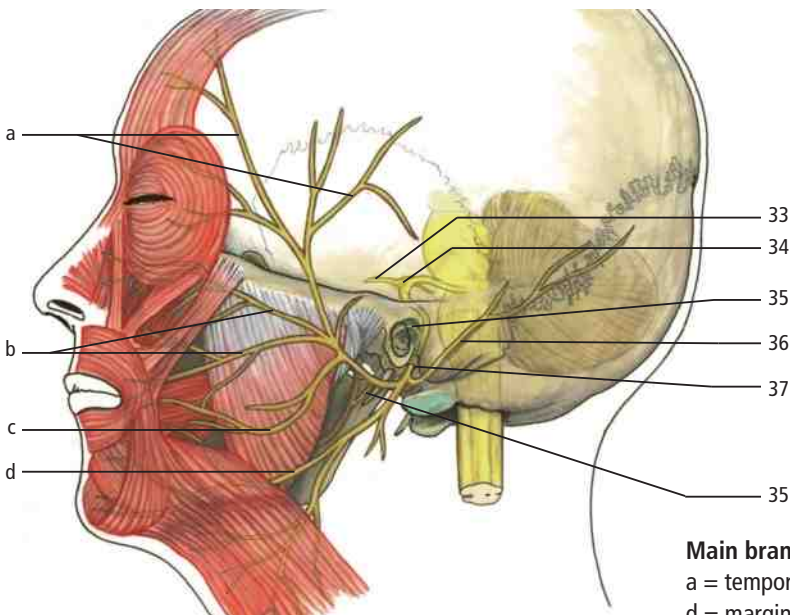


Superficial region of the face. Note the facial plexus within the parotid gland (semischematic drawing).

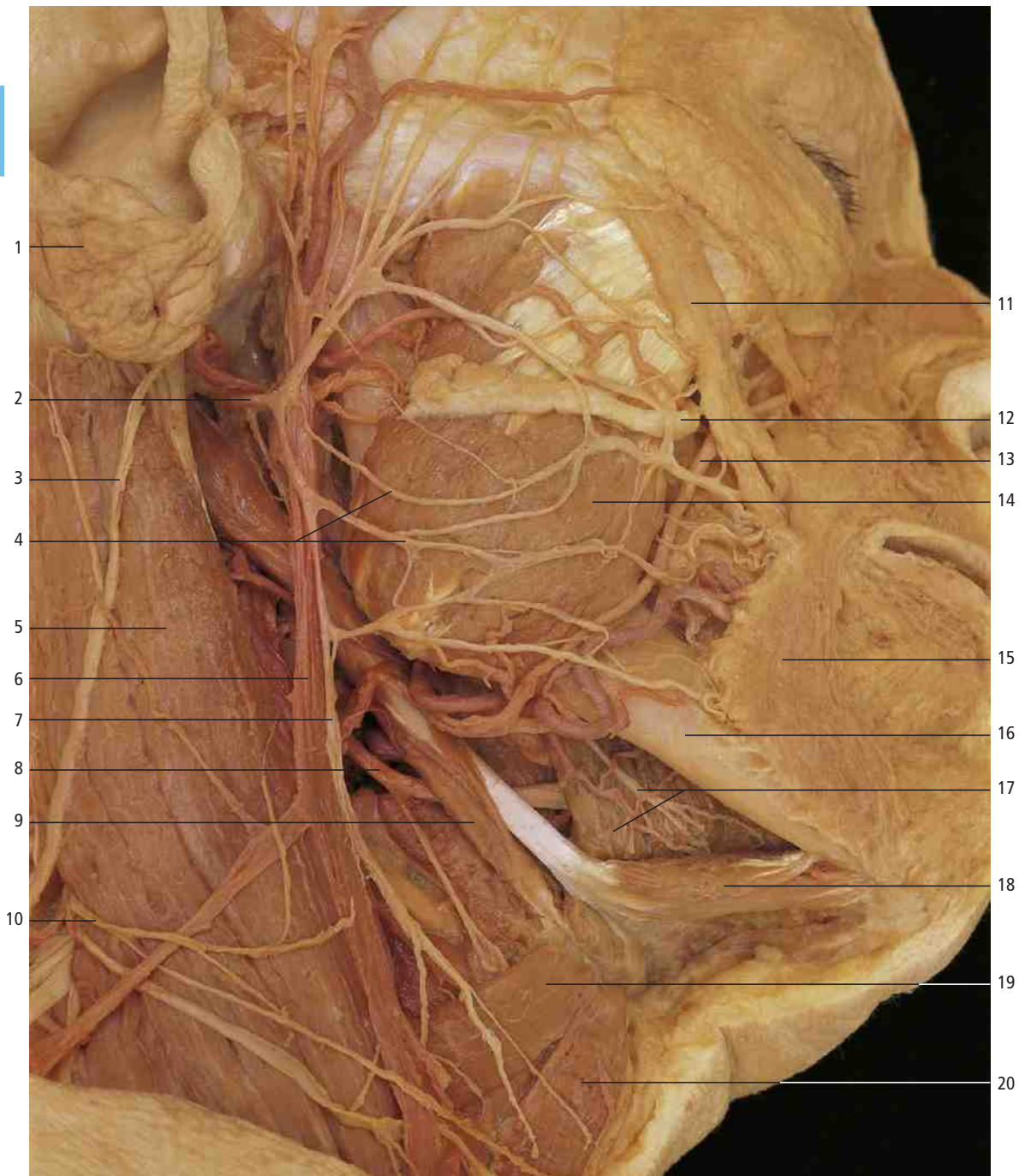


- 1 Temporoparietalis muscle
- 2 Superficial temporal artery and vein, and auriculotemporal nerve
- 3 Occipital belly of occipitofrontalis muscle and greater occipital nerve (C₂)
- 4 Facial nerve (n. VII)
- 5 Lesser occipital nerve and occipital artery
- 6 Transverse facial artery
- 7 Masseter muscle
- 8 Parotid gland and great auricular nerve
- 9 Splenius capitis muscle
- 10 Trapezius muscle
- 11 Punctum nervosum, point of distribution of cutaneous nerves of cervical plexus
- 12 Sternocleidomastoid muscle and external jugular vein
- 13 Supraclavicular nerves
- 14 Brachial plexus
- 15 Supra-orbital nerves
- 16 Orbicularis oculi muscle
- 17 Angular artery (terminal branch of facial artery)
- 18 Nasalis muscle
- 19 Zygomaticus major muscle
- 20 Parotid duct
- 21 Zygomatic and buccal branches of facial nerve
- 22 Orbicularis oris muscle
- 23 Depressor anguli oris muscle
- 24 Platysma muscle
- 25 Cervical branch of facial nerve (anastomosing with transverse cervical nerve of cervical plexus)
- 26 Facial artery and vein
- 27 Temporal branches of facial nerve
- 28 Submandibular gland
- 29 Mandible
- 30 Mylohyoid muscle and nerve
- 31 Anterior belly of digastric muscle
- 32 Omohyoid muscle
- 33 Greater petrosal nerve
- 34 Geniculate ganglion
- 35 Chorda tympani
- 36 Posterior auricular nerve
- 37 Stylomastoid foramen
- 38 Sternocleidomastoid muscle and retromandibular vein

Deep dissection of facial nerve. Retromandibular and submandibular regions of the head (lateral aspect). The parotid gland has been removed.



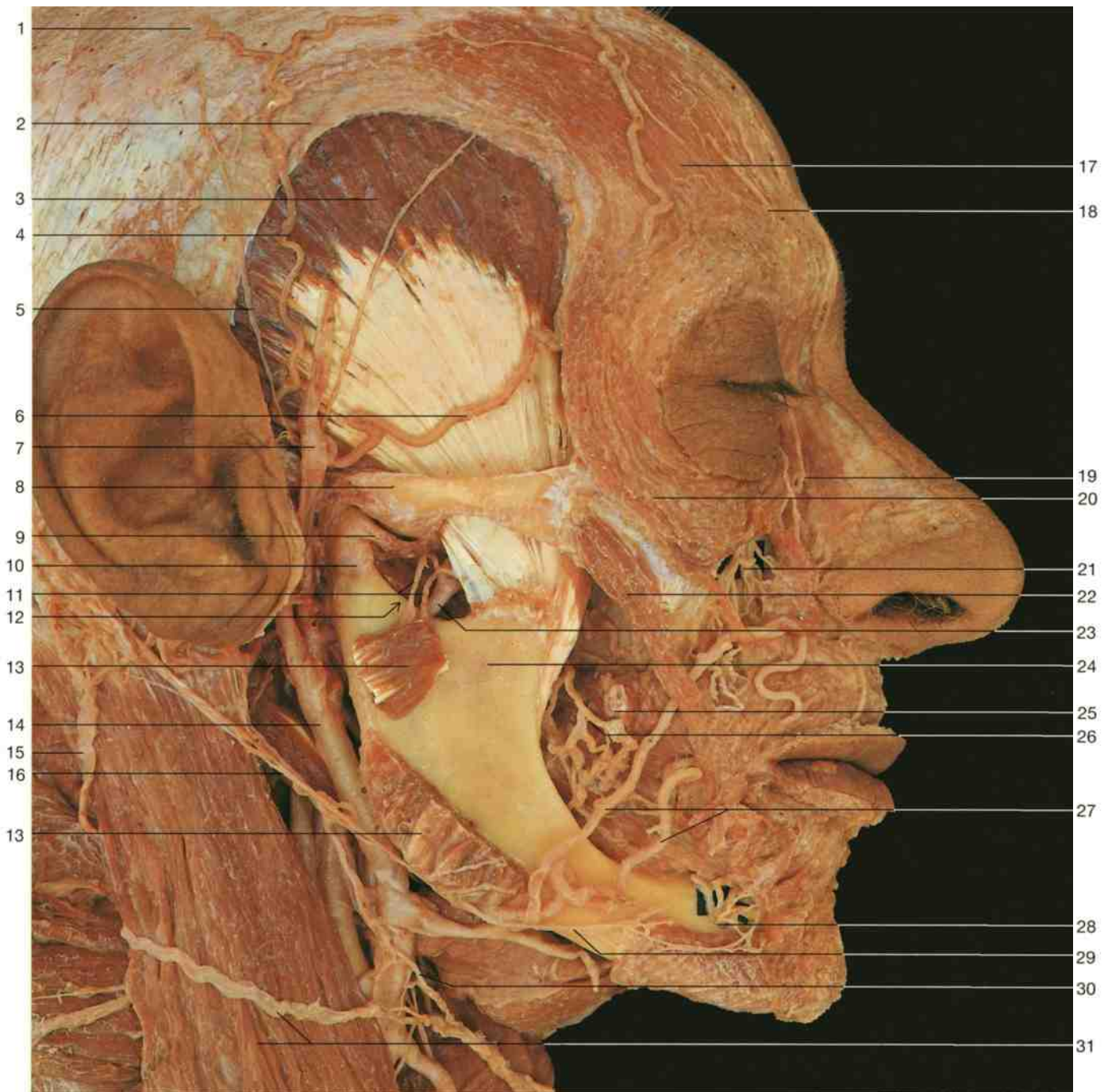
Main branches of facial nerve (schematic drawing).
a = temporal branches; b = zygomatic branches; c = buccal branches; d = marginal mandibular branch.



Deep dissection of facial nerve. Retromandibular and submandibular regions of the head (lateral aspect).

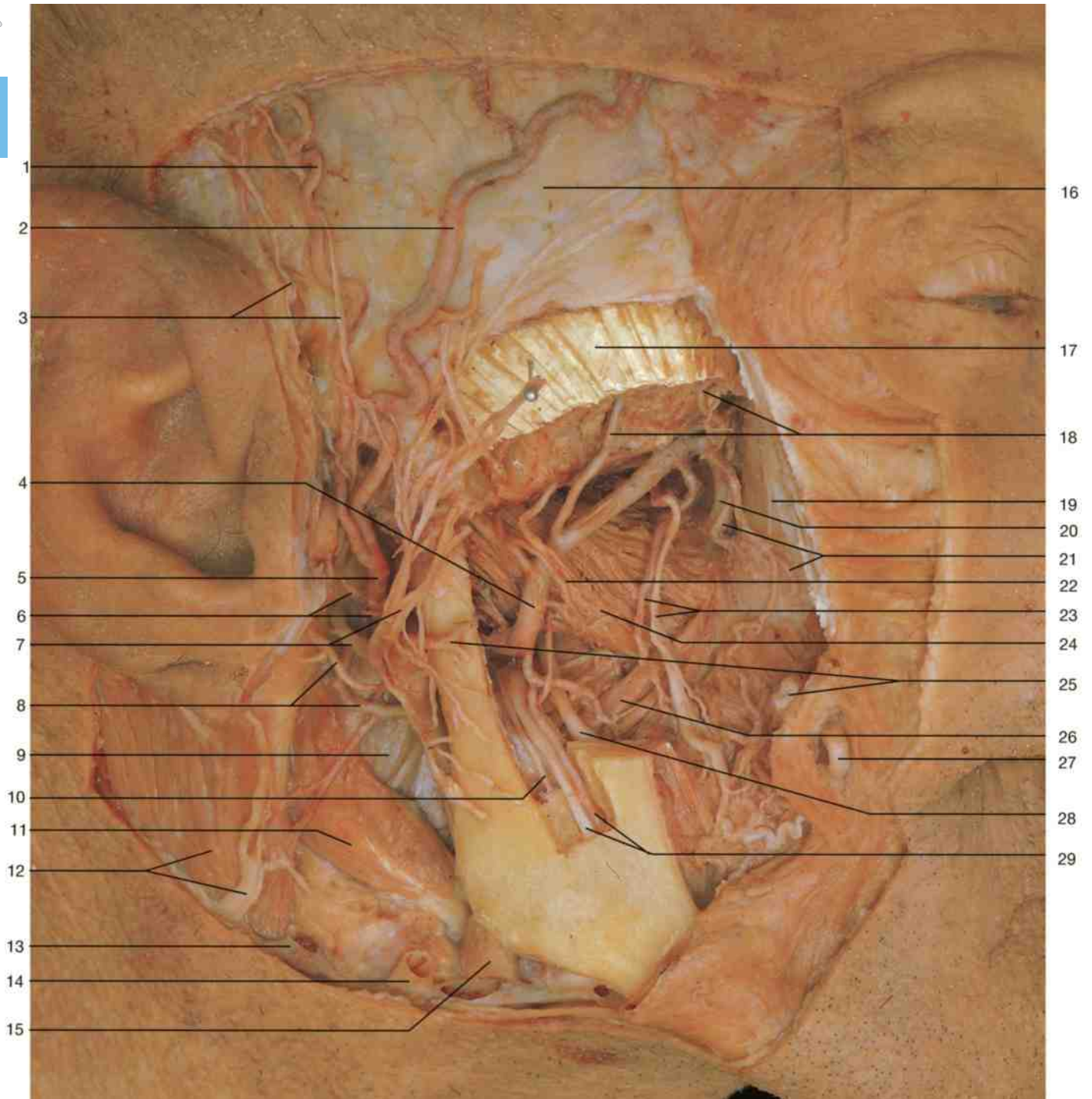
The parotid gland and the submandibular gland have been removed. The parotid plexus (4) is formed by anastomosis of the temporal, zygomatic, buccal, marginal mandibular, and cervical branches of the facial nerve, arising in the parotid gland.

- | | | |
|-----------------------------------|------------------------------|---------------------------------------|
| 1 Parotid gland | 8 Hypoglossal nerve (n. XII) | 15 Depressor anguli oris muscle |
| 2 Facial nerve (n. VII) | 9 Stylohyoid muscle | 16 Mandible |
| 3 Great auricular nerve | 10 Transverse cervical nerve | 17 Mylohyoid muscle and nerve |
| 4 Parotid plexus | 11 Zygomaticus major muscle | 18 Anterior belly of digastric muscle |
| 5 Sternocleidomastoid muscle | 12 Parotid duct | 19 Omohyoid muscle |
| 6 Retromandibular vein | 13 Facial artery | 20 Sternohyoid muscle |
| 7 Cervical branch of facial nerve | 14 Masseter muscle | |



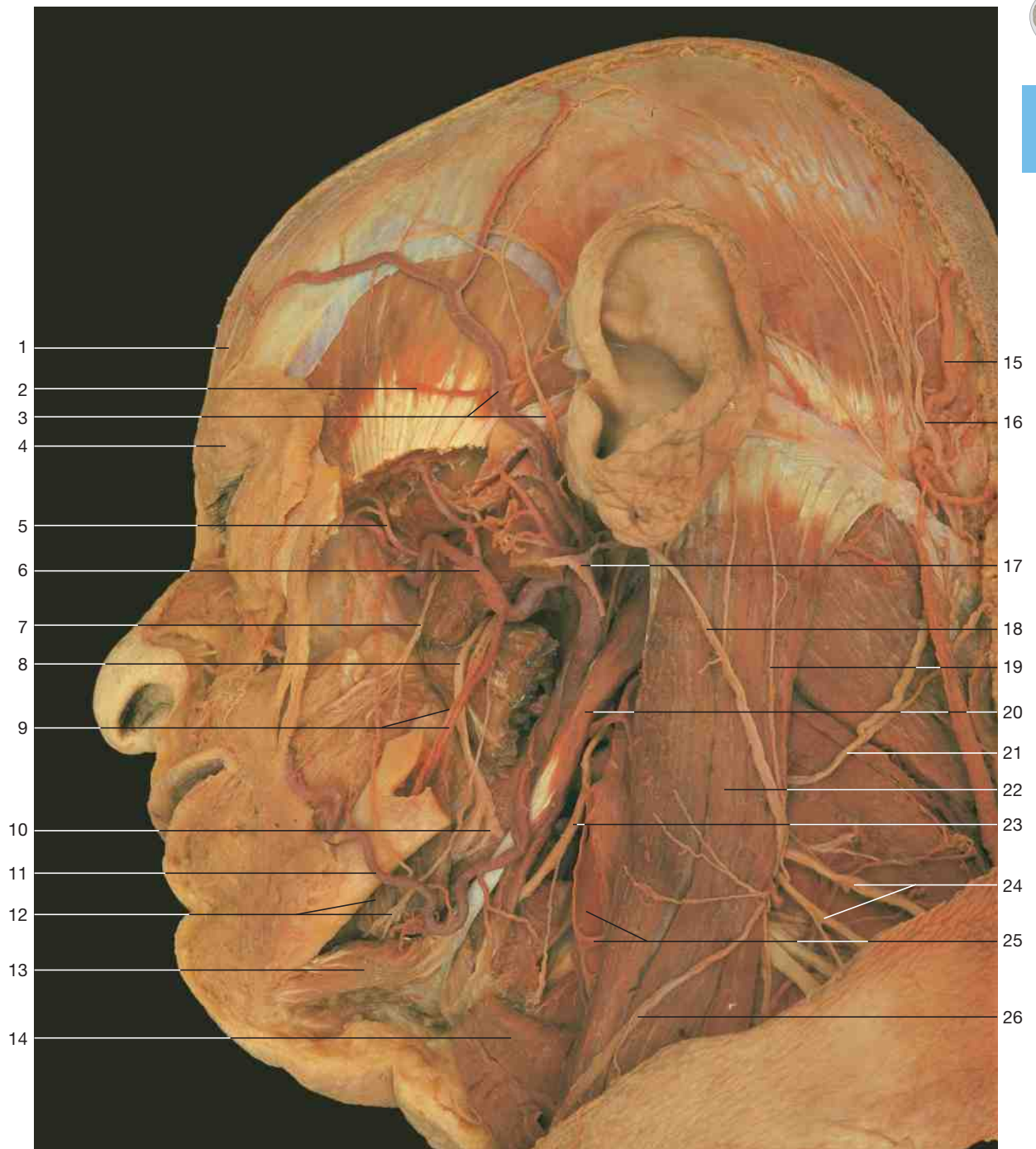
Lateral superficial aspect of the face. Masseter muscle and temporal fascia have been partly removed to display the masseteric artery and nerve.

- | | | | | | |
|---|--|----|---|----|---|
| 1 | Galea aponeurotica | 10 | Head of mandible | 22 | Zygomaticus major muscle |
| 2 | Temporal fascia | 11 | Masseteric artery and nerve | 23 | Maxillary artery |
| 3 | Temporalis muscle | 12 | Mandibular notch | 24 | Coronoid process |
| 4 | Parietal branch of superficial temporal artery | 13 | Masseter muscle (divided) | 25 | Parotid duct (divided) |
| 5 | Auriculotemporal nerve | 14 | External carotid artery | 26 | Buccal nerve |
| 6 | Frontal branch of superficial temporal artery | 15 | Great auricular nerve | 27 | Facial artery and vein |
| 7 | Superficial temporal vein | 16 | Facial nerve (reflected) | 28 | Mental nerve |
| 8 | Zygomatic arch | 17 | Frontal belly of occipitofrontalis muscle | 29 | Mandibular branch of facial nerve |
| 9 | Articular disc of temporomandibular joint | 18 | Medial branch of supra-orbital nerve | 30 | Cervical branch of facial nerve |
| | | 19 | Angular artery | 31 | Transverse cervical nerve (communicating branch with facial nerve) and sternocleidomastoid muscle |
| | | 20 | Orbicularis oculi muscle | | |
| | | 21 | Infra-orbital nerve | | |



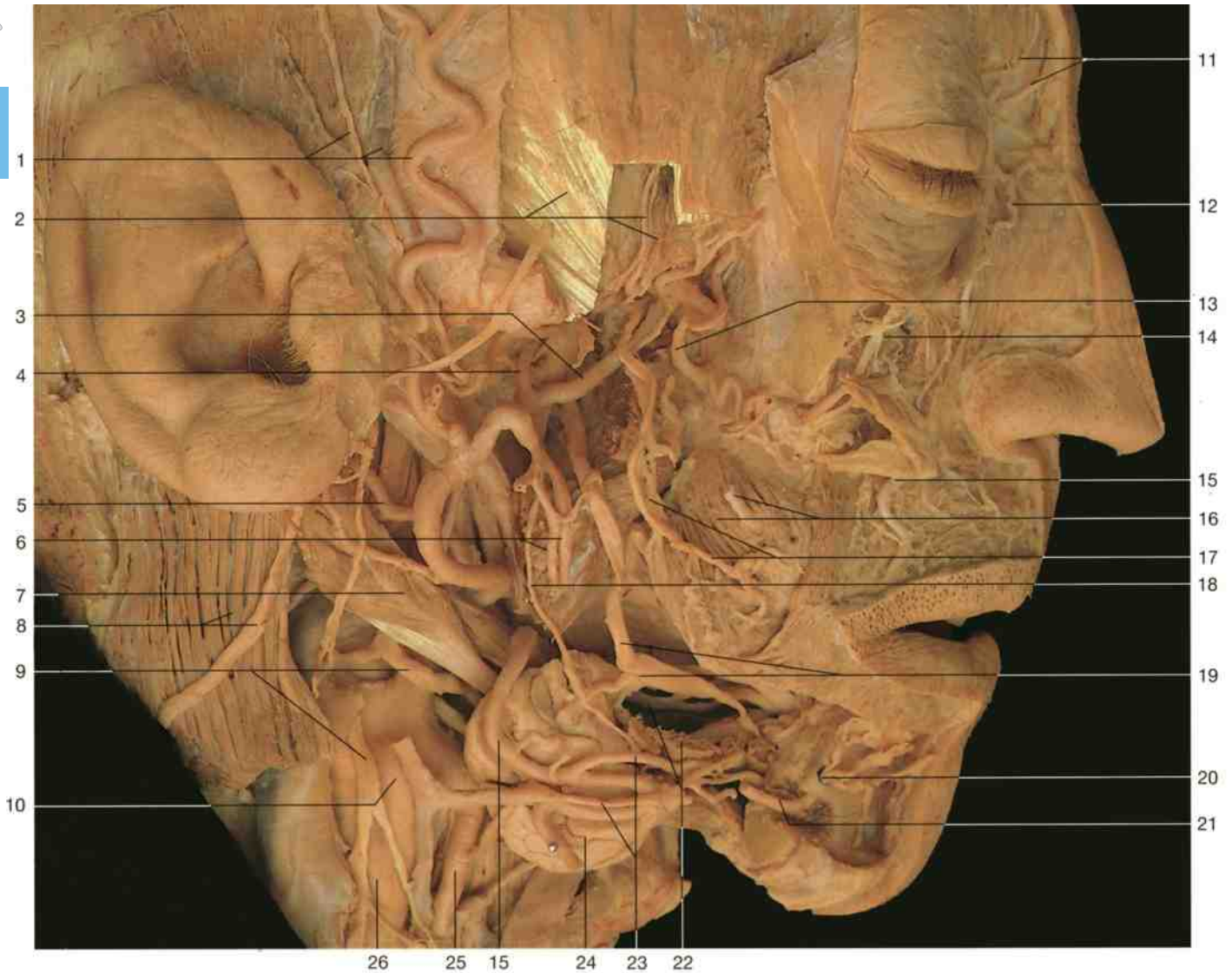
Deep dissection of facial and retromandibular regions. The coronoid process together with the insertions of temporalis muscle have been removed to display the maxillary artery. The upper part of the mandibular canal has been opened.

- | | | |
|---|---|---|
| 1 Parietal branch of the superficial temporal artery | 10 Mylohyoid nerve | 22 Masseteric artery and nerve |
| 2 Frontal branch of the superficial temporal artery | 11 Posterior belly of digastric muscle | 23 Buccal nerve and artery |
| 3 Auriculotemporal nerve | 12 Great auricular nerve and sternocleidomastoid muscle | 24 Lateral pterygoid |
| 4 Maxillary artery | 13 External jugular vein | 25 Transverse facial artery and parotid duct (divided) |
| 5 Superficial temporal artery | 14 Retromandibular vein | 26 Medial pterygoid muscle |
| 6 Communicating branches between facial and auriculotemporal nerves | 15 Submandibular gland | 27 Facial artery |
| 7 Facial nerve | 16 Temporal fascia | 28 Lingual nerve |
| 8 Posterior auricular artery and anterior auricular branch of superficial temporal artery | 17 Temporalis tendon | 29 Inferior alveolar artery and nerve (mandibular canal opened) |
| 9 Internal jugular vein | 18 Deep temporal arteries | |
| | 19 Posterior superior alveolar nerve | |
| | 20 Sphenopalatine artery | |
| | 21 Posterior superior alveolar arteries | |

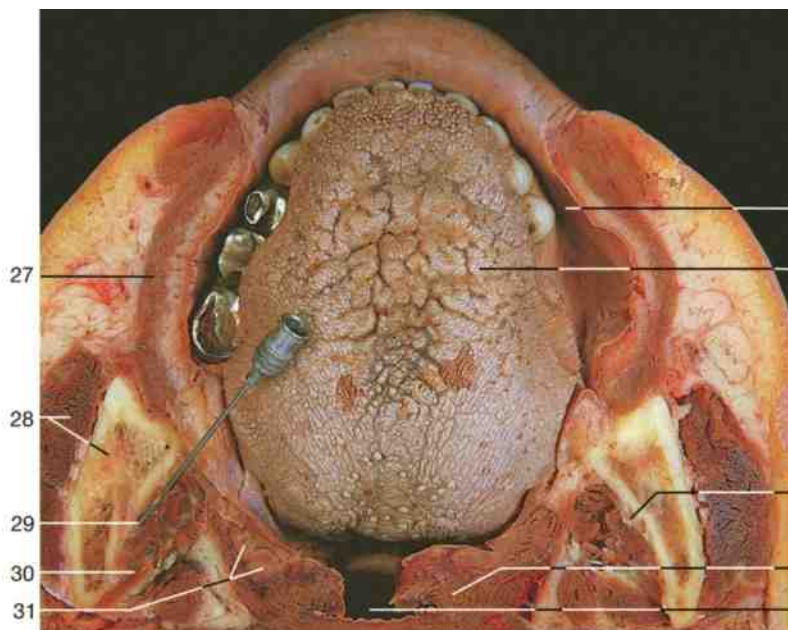


Peripharyngeal and retromandibular regions. The mandible has been partly removed (oblique lateral aspect).

- | | | | | | |
|---|--|----|---|----|---|
| 1 | Supra-orbital nerve (medial branch) | 10 | Submandibular ganglion | 20 | Posterior belly of digastric muscle |
| 2 | Temporalis muscle | 11 | Facial artery | 21 | Accessory nerve (Var.) |
| 3 | Superficial temporal artery and auriculotemporal nerve | 12 | Mylohyoid muscle and nerve | 22 | Sternocleidomastoid muscle |
| 4 | Orbicularis oculi muscle | 13 | Anterior belly of digastric muscle | 23 | Hypoglossus nerve (n. XII) |
| 5 | Anterior deep temporal artery | 14 | Omohyoid muscle | 24 | Supraclavicular nerves (lateral and intermedial branches) |
| 6 | Maxillary artery | 15 | Occipital artery | 25 | Internal jugular vein and ansa cervicalis |
| 7 | Buccal nerve | 16 | Greater occipital nerve (C ₂) | 26 | Anterior supraclavicular nerve |
| 8 | Lingual nerve | 17 | Facial nerve (cut) (n. VII) | | |
| 9 | Inferior alveolar nerve and artery | 18 | Great auricular nerve | | |
| | | 19 | Lesser occipital nerve | | |

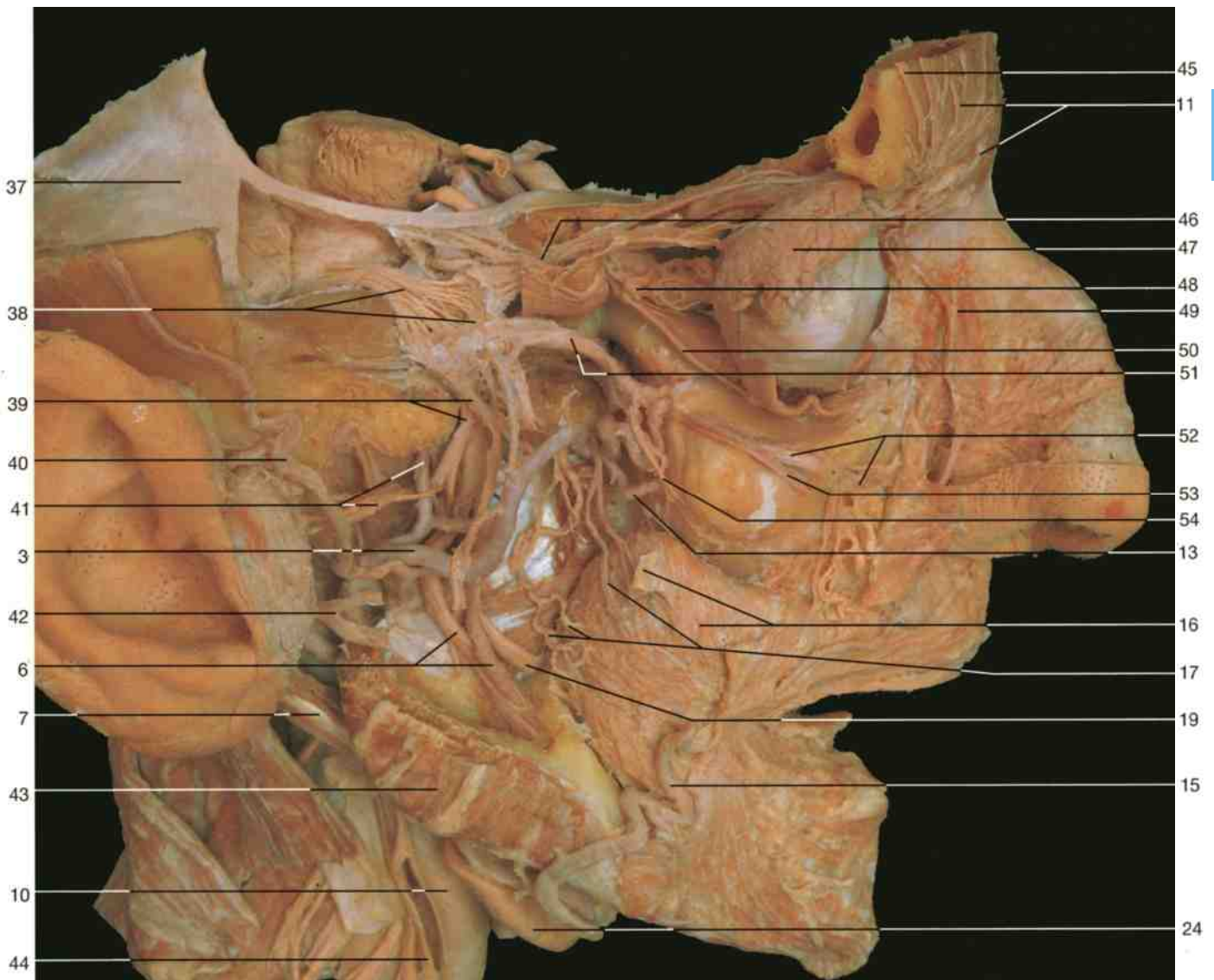


Dissection of deep facial and retromandibular regions after removal of mandible. Pterygoid muscles removed, temporalis muscle fenestrated.



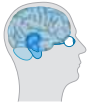- 1 Superficial temporal artery and vein and auriculotemporal nerve
- 2 Temporalis tendon, deep temporal nerves and artery
- 3 Maxillary artery
- 4 Middle meningeal artery
- 5 Occipital artery
- 6 Inferior alveolar artery and nerve
- 7 Posterior belly of digastric muscle
- 8 Great auricular nerve and sternocleidomastoid muscle
- 9 Hypoglossal nerve and superior root of ansa cervicalis
- 10 External carotid artery
- 11 Supratrochlear nerve and medial branch of supra-orbital artery
- 12 Angular artery
- 13 Posterior superior alveolar artery
- 14 Infra-orbital nerve
- 15 Facial artery
- 16 Parotid duct (divided) and buccinator muscle
- 17 Buccal artery and nerve

Transverse section through oral cavity and pharynx. The location of inferior alveolar nerve and artery is indicated by a needle.

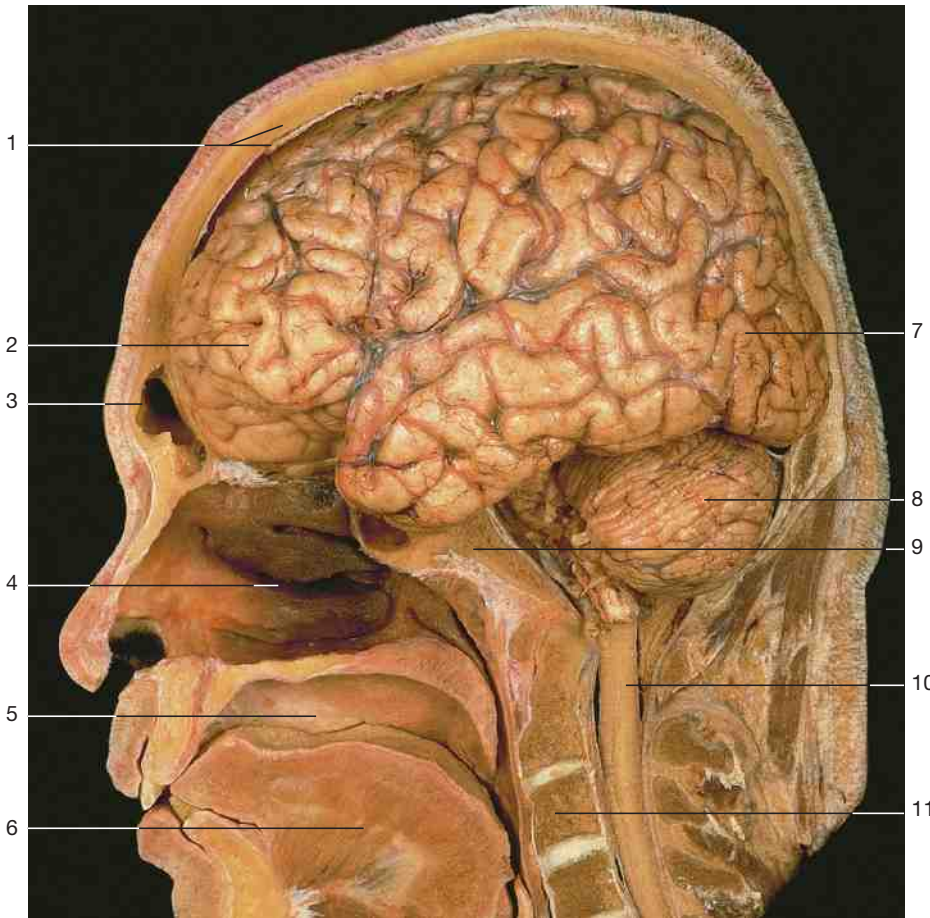


Para- and retropharyngeal regions. The mandible and the lateral wall of the orbit have been removed. The main branches of the trigeminal nerve and its ganglion are displayed.

- | | |
|---|---|
| 18 Mylohyoid nerve | 36 Pharynx |
| 19 Lingual nerve and submandibular ganglion | 37 Tentorium of cerebellum |
| 20 Mental nerve and mental foramen | 38 Trigeminal nerve and ganglion |
| 21 Inferior alveolar nerve | 39 Mandibular nerve |
| 22 Mylohyoid muscle (divided) and hypoglossal nerve | 40 Superficial temporal artery |
| 23 Submental artery and vein | 41 Auriculotemporal nerve and middle meningeal artery |
| 24 Submandibular gland | 42 Facial nerve (divided) |
| 25 Superior thyroid artery | 43 Masseter muscle |
| 26 Common carotid artery | 44 Superior root of ansa cervicalis |
| 27 Buccinator muscle | 45 Lateral branch of supra-orbital nerve |
| 28 Masseter muscle and mandible | 46 Ophthalmic nerve |
| 29 Entrance of mandibular canal | 47 Lacrimal gland |
| 30 Medial pterygoid muscle | 48 Ciliary ganglion and short ciliary nerves |
| 31 Palatine tonsil | 49 Angular artery |
| 32 Oral vestibule | 50 Inferior branch of oculomotor nerve |
| 33 Tongue | 51 Maxillary nerve |
| 34 Inferior alveolar nerve, artery, and vein | 52 Infra-orbital nerve |
| 35 Pharyngeal constrictor muscle | 53 Anterior superior alveolar nerve |
| | 54 Posterior superior alveolar nerve |

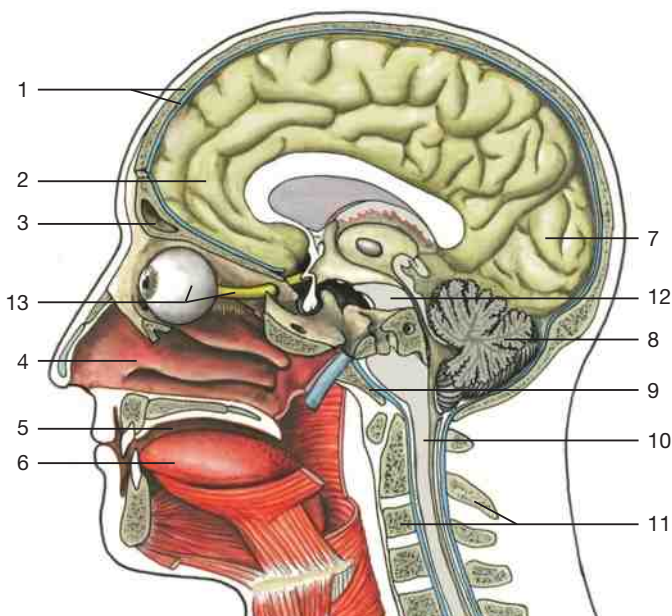


2.3 Brain and Sensory Organs



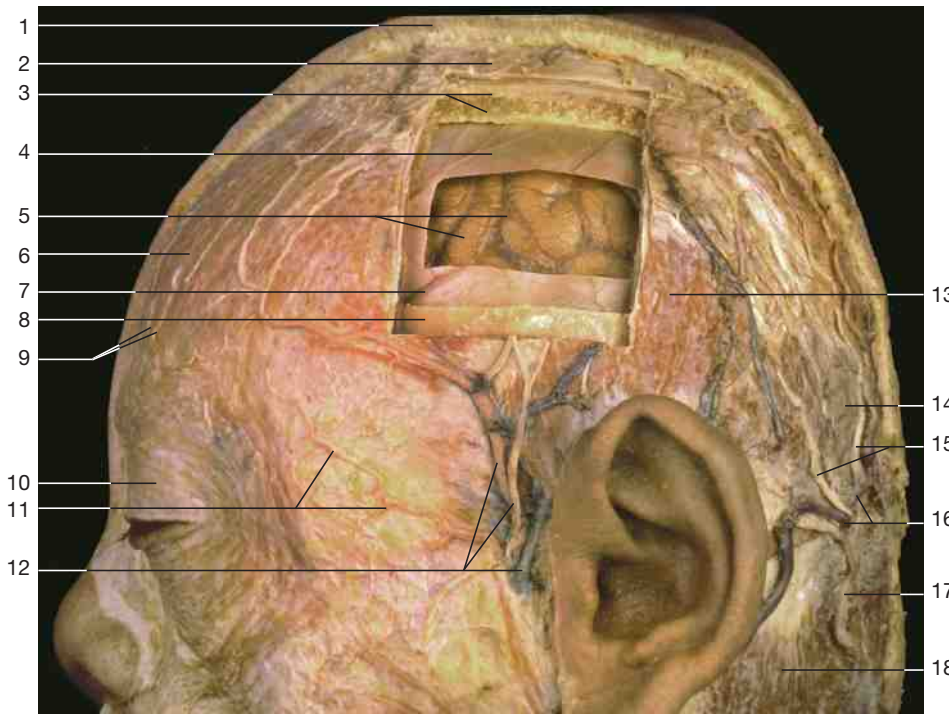
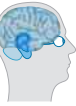The cranial cavity harbours the brain, the cerebellum, and the brain stem from where the cranial nerves emerge and exit the skull through various openings and fissures. The great sensory organs are located within the orbit (eye), the nasal cavity (olfactory system), and the petrous portion of the temporal bone (vestibulocochlear organ). The brain is wrapped by the pia mater containing the brain vessels. The dura mater is firmly attached to the skull and provides shelter and stabilization for the brain. Interposed between pia and dura mater lies the arachnoid containing the cerebrospinal fluid.

Dissection of the brain with pia mater and arachnoid in situ. The head is cut in half except for the brain, which is shown in its entirety.



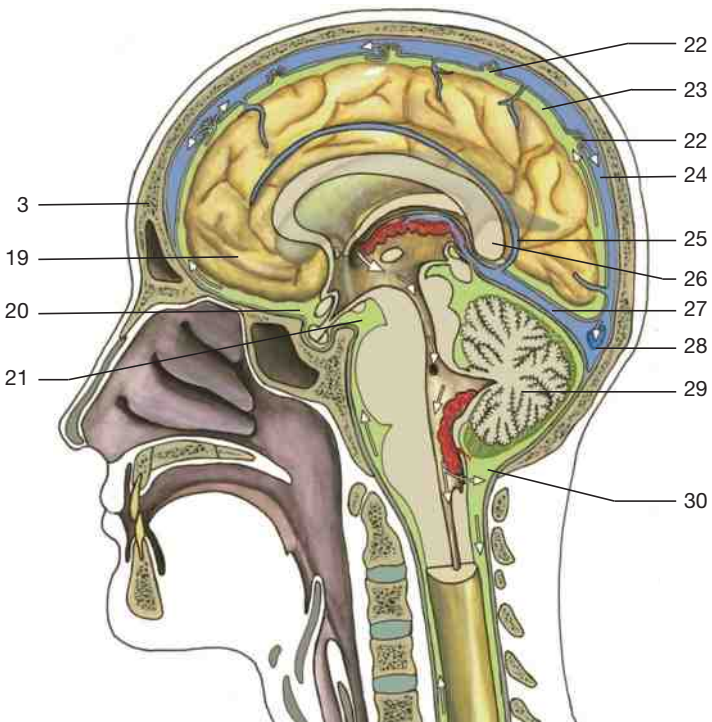
- 1 Vertex of the skull and dura mater
- 2 Frontal lobe covered by arachnoid and pia mater
- 3 Frontal sinus
- 4 Nasal cavity
- 5 Oral cavity
- 6 Tongue
- 7 Occipital lobe
- 8 Cerebellum
- 9 Base of skull
- 10 Spinal cord
- 11 Vertebral column
- 12 Brain stem
- 13 Eye and optic nerve (n. II)

Sagittal section through the head with brain and sensory organs (schematic drawing). The eye with the optic nerve is located within the orbit; the labyrinth organ, within the petrous bone.

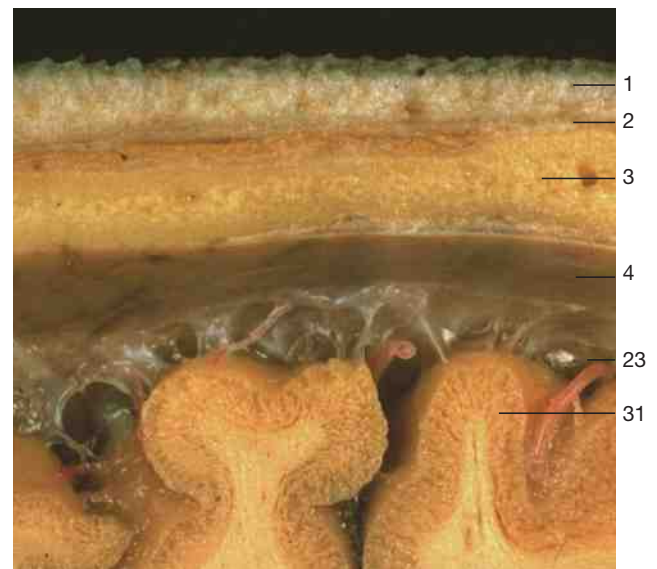


- 1 Skin
- 2 Galea aponeurotica
- 3 Skull diploe
- 4 Dura mater
- 5 Arachnoid and pia mater with cerebral vessels
- 6 Frontal belly of occipitofrontalis muscle
- 7 Branch of middle meningeal artery
- 8 Pericranium (periosteum)
- 9 Lateral and medial branches of supra-orbital nerve
- 10 Orbicularis oculi muscle
- 11 Zygomatico-orbital artery
- 12 Auriculotemporal nerve and superficial temporal artery and vein
- 13 Superior auricular muscle
- 14 Occipital belly of occipitofrontalis muscle
- 15 Occipital nerve
- 16 Occipital artery and vein
- 17 Greater occipital nerve
- 18 Sternocleidomastoid muscle
- 19 Frontal lobe
- 20 Chiasmatic cistern
- 21 Interpeduncular cistern
- 22 Arachnoid granulations
- 23 Subarachnoid space
- 24 Superior sagittal sinus
- 25 Inferior sagittal sinus
- 26 Corpus callosum
- 27 Straight sinus
- 28 Confluence of sinuses
- 29 Cerebellum
- 30 Cerebellomedullar cistern
- 31 Cerebral cortex

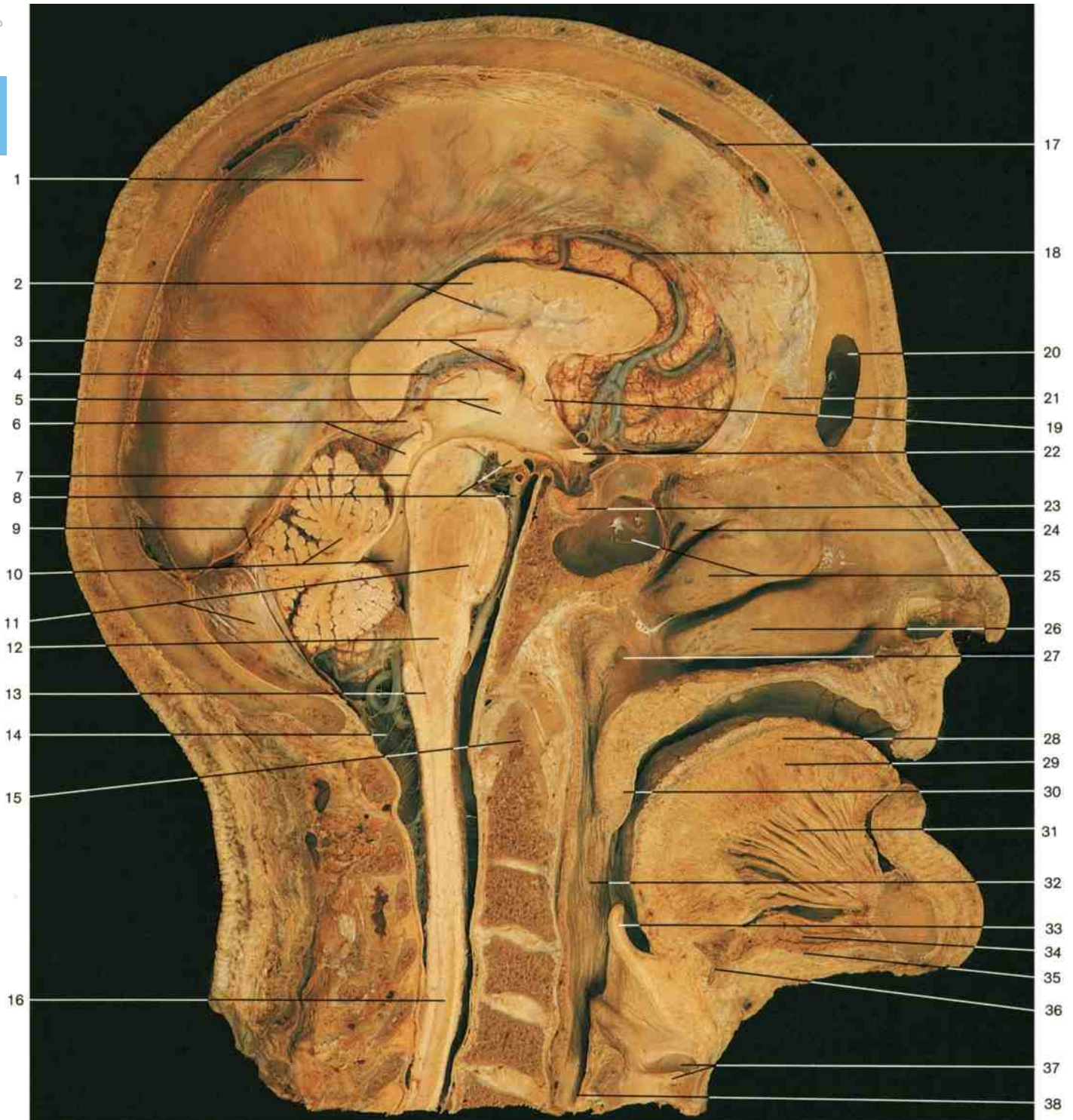
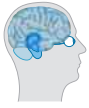Lateral aspect of the head. Scalp, vertex of the skull, and meninges are demonstrated by a series of window-like openings.



Subarachnoid cisterns of the brain (midsagittal section). Green = cisterns; blue = dural sinus and ventricles; red = choroid plexus of third and fourth ventricles; arrows = flow of cerebrospinal fluid.

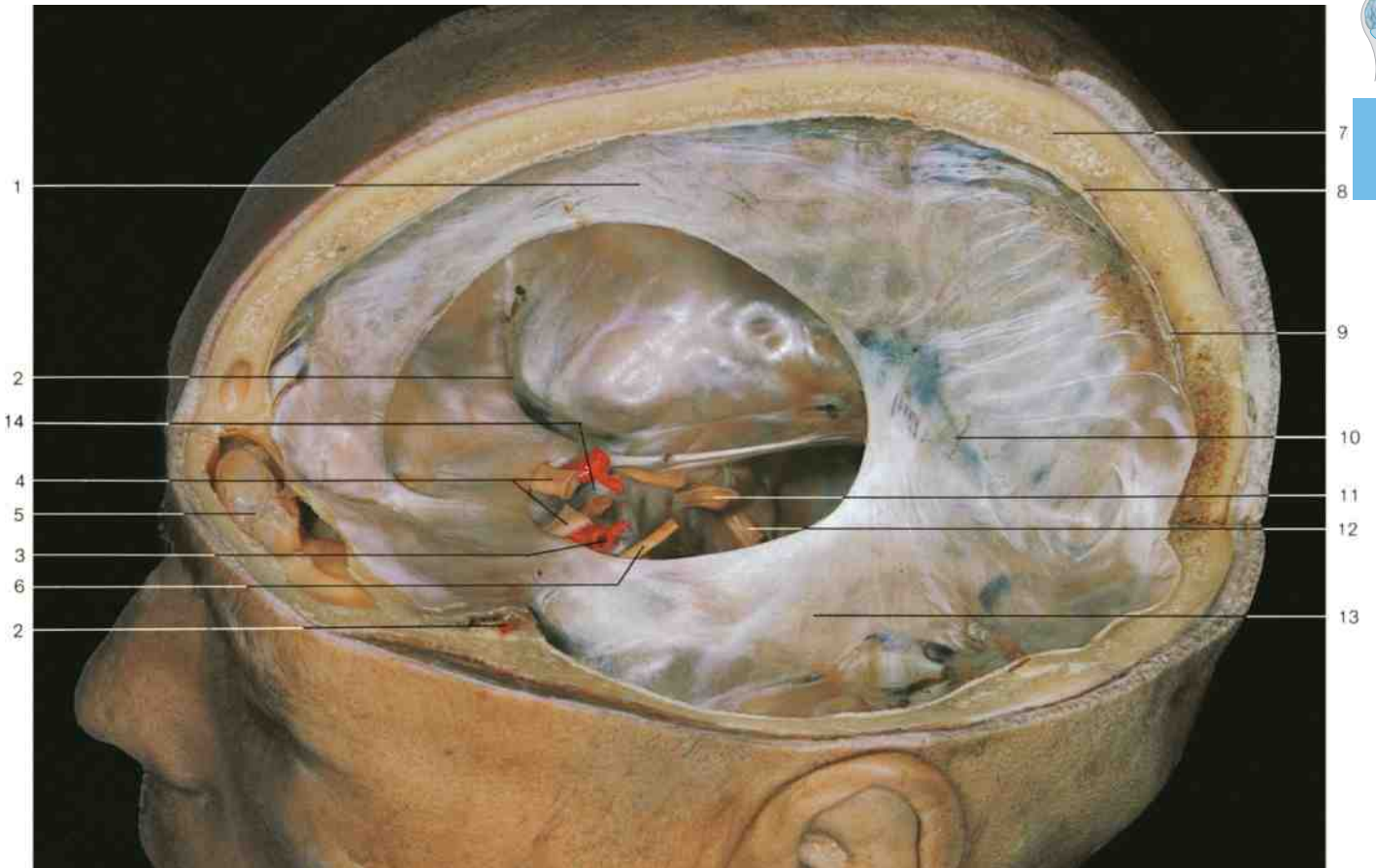


Cross section of the scalp and the meninges. The subarachnoid space (23) is shown.



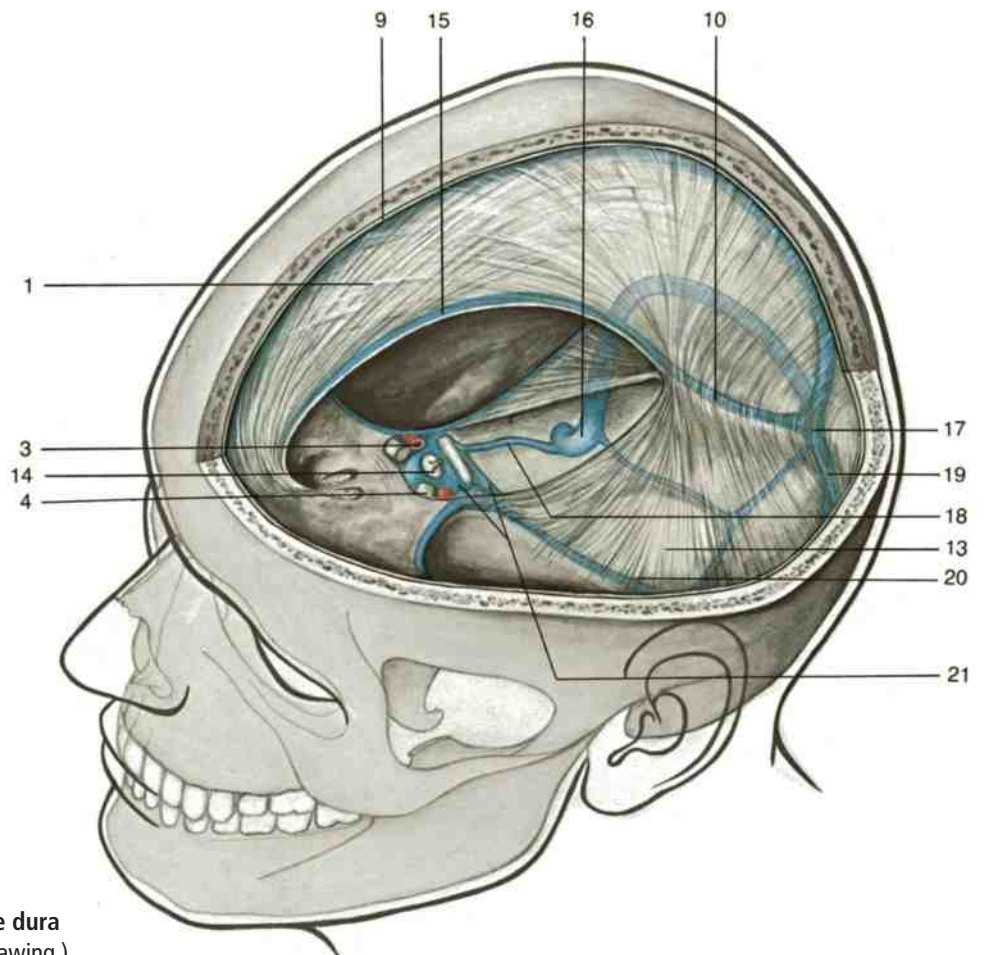
Median sagittal section through the head and neck.

- | | | |
|--|---|---|
| 1 Falx cerebri | 14 Cerebellomedullary cistern | 27 Pharyngeal opening of auditory tube |
| 2 Corpus callosum and septum pellucidum | 15 Dens of the axis (odontoid process) | 28 Superior longitudinal muscle of tongue |
| 3 Interventricular foramen and fornix | 16 Spinal cord | 29 Vertical muscle of the tongue |
| 4 Choroid plexus of third ventricle and internal cerebral vein | 17 Superior sagittal sinus | 30 Uvula |
| 5 Third ventricle and interthalamic adhesion | 18 Anterior cerebral artery | 31 Genioglossus muscle |
| 6 Pineal body and colliculi of the midbrain | 19 Anterior commissure | 32 Pharynx |
| 7 Cerebral aqueduct | 20 Frontal sinus | 33 Epiglottis |
| 8 Mamillary body and basilar artery | 21 Crista galli | 34 Geniohyoid muscle |
| 9 Straight sinus | 22 Optic chiasma | 35 Mylohyoid muscle |
| 10 Fourth ventricle and cerebellum | 23 Pituitary gland (hypophysis) | 36 Hyoid bone |
| 11 Pons and falx cerebelli | 24 Superior nasal concha | 37 Vocal fold and sinus of larynx |
| 12 Medulla oblongata | 25 Middle nasal concha and sphenoid sinus | 38 Esophagus |
| 13 Central canal | 26 Inferior nasal concha | |

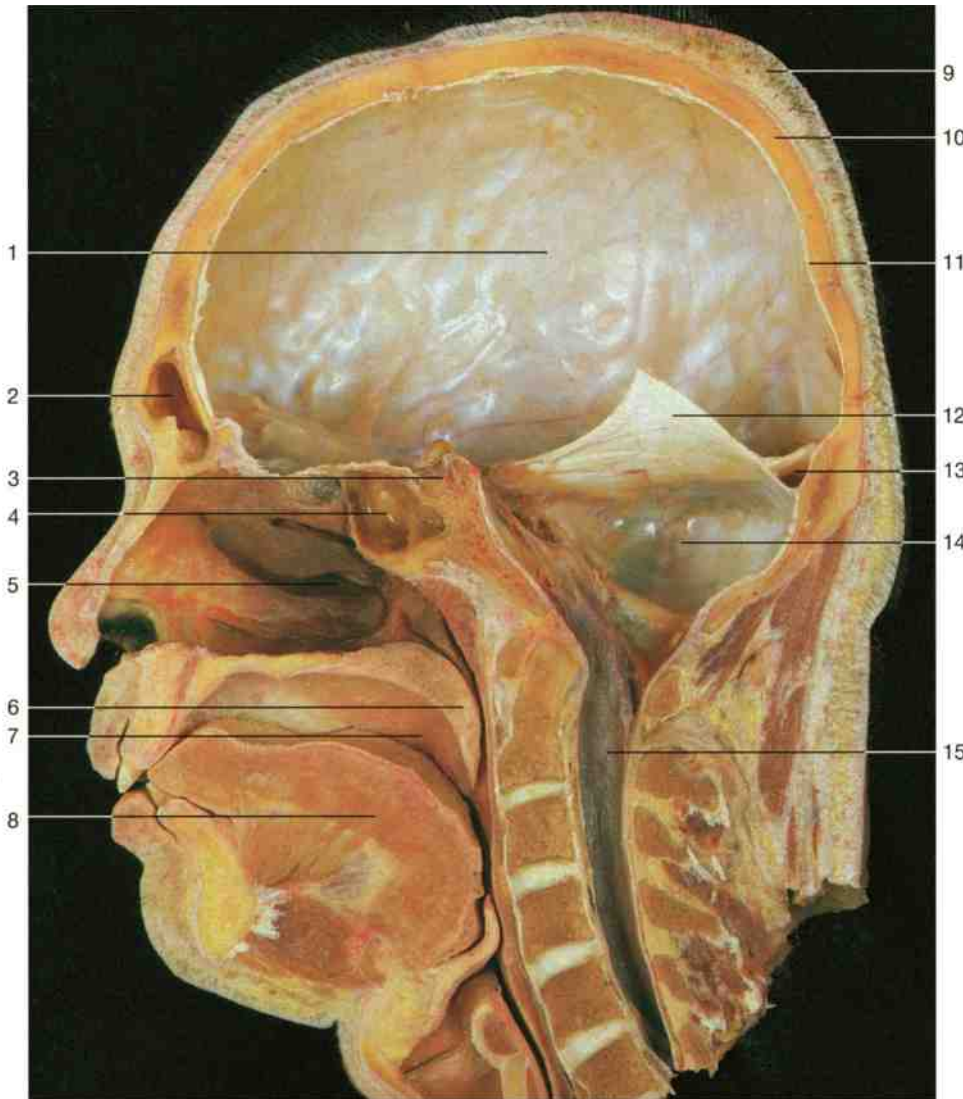
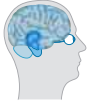

Dura mater and venous sinuses of the dura mater. The brain has been removed (oblique lateral aspect).

- 1 Falx cerebri
- 2 Position of middle meningeal artery and vein
- 3 Internal carotid artery
- 4 Optic nerve (n. II)
- 5 Frontal sinus
- 6 Oculomotor nerve (n. III)
- 7 Diploe
- 8 Dura mater
- 9 Superior sagittal sinus
- 10 Straight sinus
- 11 Trigeminal nerve (n. V)
- 12 Facial and vestibulocochlear nerve (n. VII and n. VIII)
- 13 Tentorium cerebelli
- 14 Pituitary gland (hypophysis)
- 15 Inferior sagittal sinus
- 16 Sigmoid sinus
- 17 Confluence of sinuses
- 18 Inferior petrosal sinus
- 19 Transverse sinus
- 20 Superior petrosal sinus
- 21 Cavernous and intercavernous sinuses

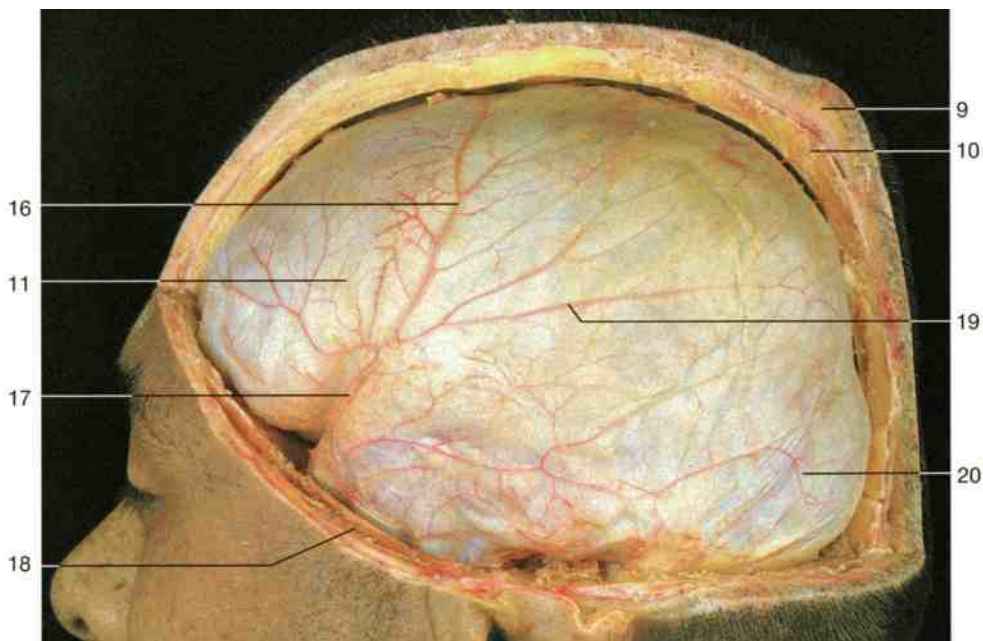


Dura mater and venous sinuses of the dura mater (left lateral aspect). (Schematic drawing.)

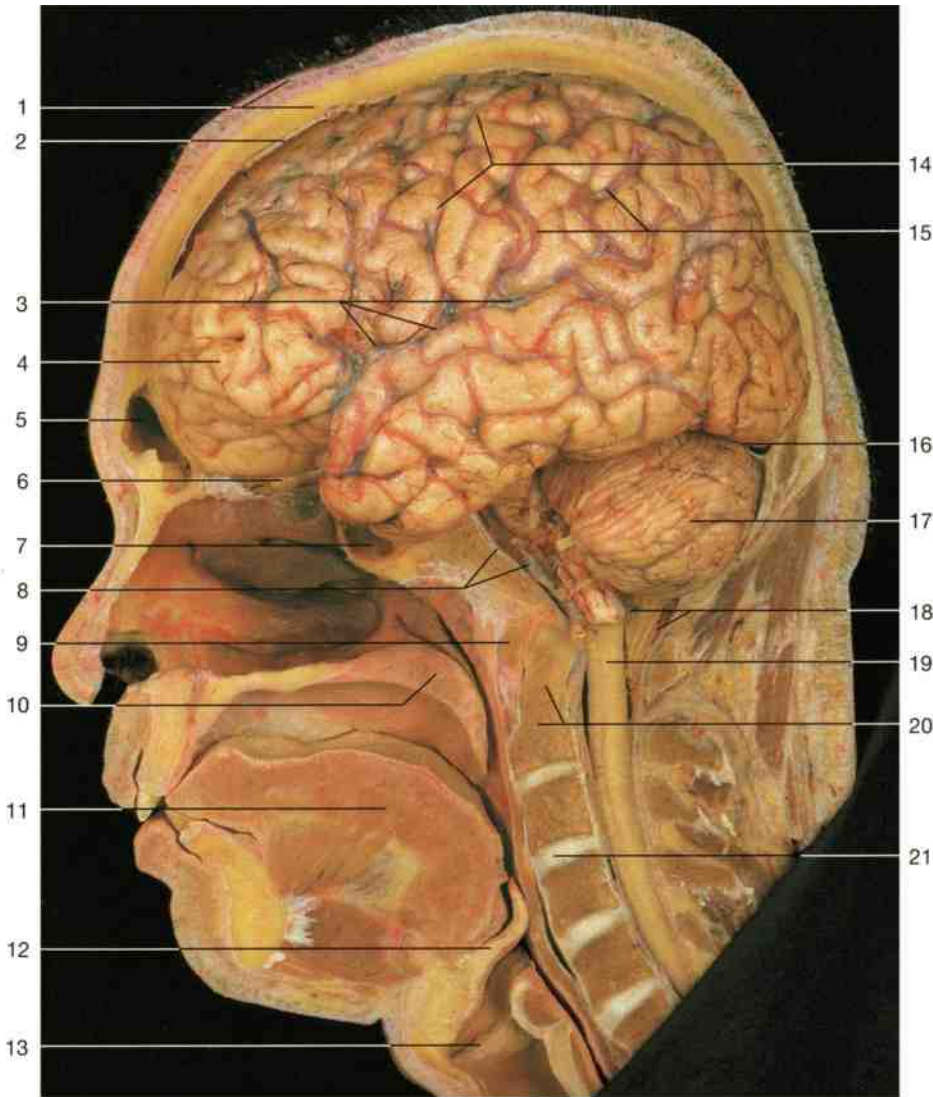


- 1 Cranial cavity with dura mater (right cerebral hemisphere has been removed)
- 2 Frontal sinus
- 3 Hypophysial fossa with pituitary gland
- 4 Sphenoidal sinus
- 5 Nasal cavity
- 6 Soft palate (uvula)
- 7 Oral cavity
- 8 Tongue
- 9 Skin
- 10 Calvaria
- 11 Dura mater
- 12 Tentorium cerebelli
- 13 Confluence of sinuses
- 14 Infratentorial space (cerebellum and part of the brain stem have been removed)
- 15 Vertebral canal
- 16 Frontal branch of middle meningeal artery and veins
- 17 Middle meningeal artery
- 18 Diploe
- 19 Parietal branch of middle meningeal artery and vein
- 20 Occipital pole of left hemisphere covered with dura mater

Median section through the head. Demonstration of dura mater covering the cranial cavity. Brain and spinal cord are removed (right half of the head, as seen from medial).

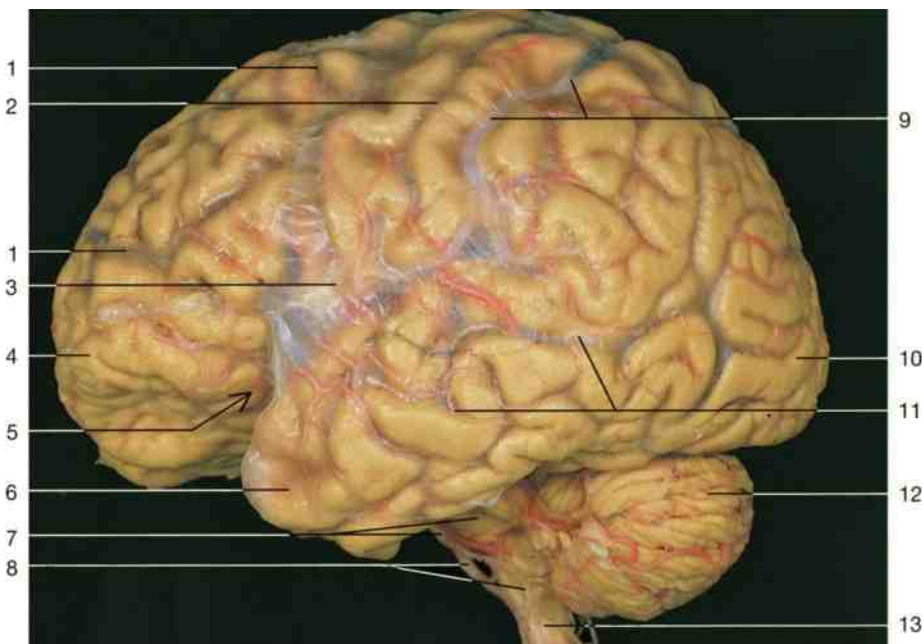


Dissection of dura mater and meningeal vessels. Left half of calvaria removed.



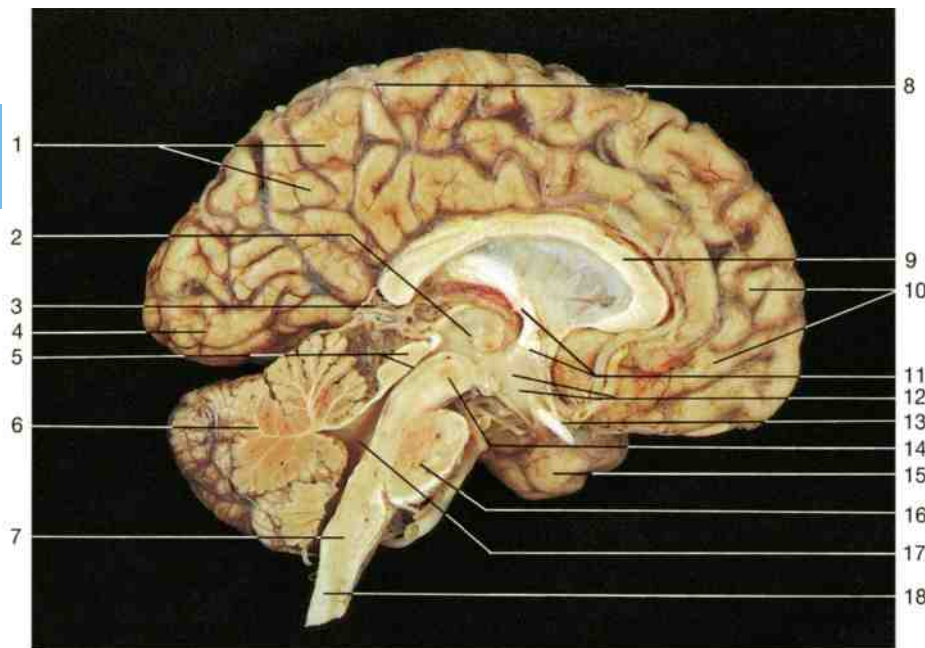
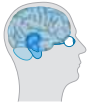- 1 Calvaria and skin of the scalp
- 2 Dura mater (divided)
- 3 Position of lateral sulcus
- 4 Frontal lobe covered by arachnoid and pia mater
- 5 Frontal sinus
- 6 Olfactory bulb
- 7 Sphenoidal sinus
- 8 Dura mater on clivus and basilar artery
- 9 Atlas (anterior arch, divided)
- 10 Soft palate
- 11 Tongue
- 12 Epiglottis
- 13 Vocal fold
- 14 Position of central sulcus
- 15 Superior cerebral veins
- 16 Tentorium (divided)
- 17 Cerebellum
- 18 Cerebellomedullary cistern
- 19 Position of foramen magnum and spinal cord
- 20 Dens of axis
- 21 Intervertebral disc

Dissection of the brain with pia mater and arachnoid in situ. The head is cut in half except for the brain, which is shown in its entirety.



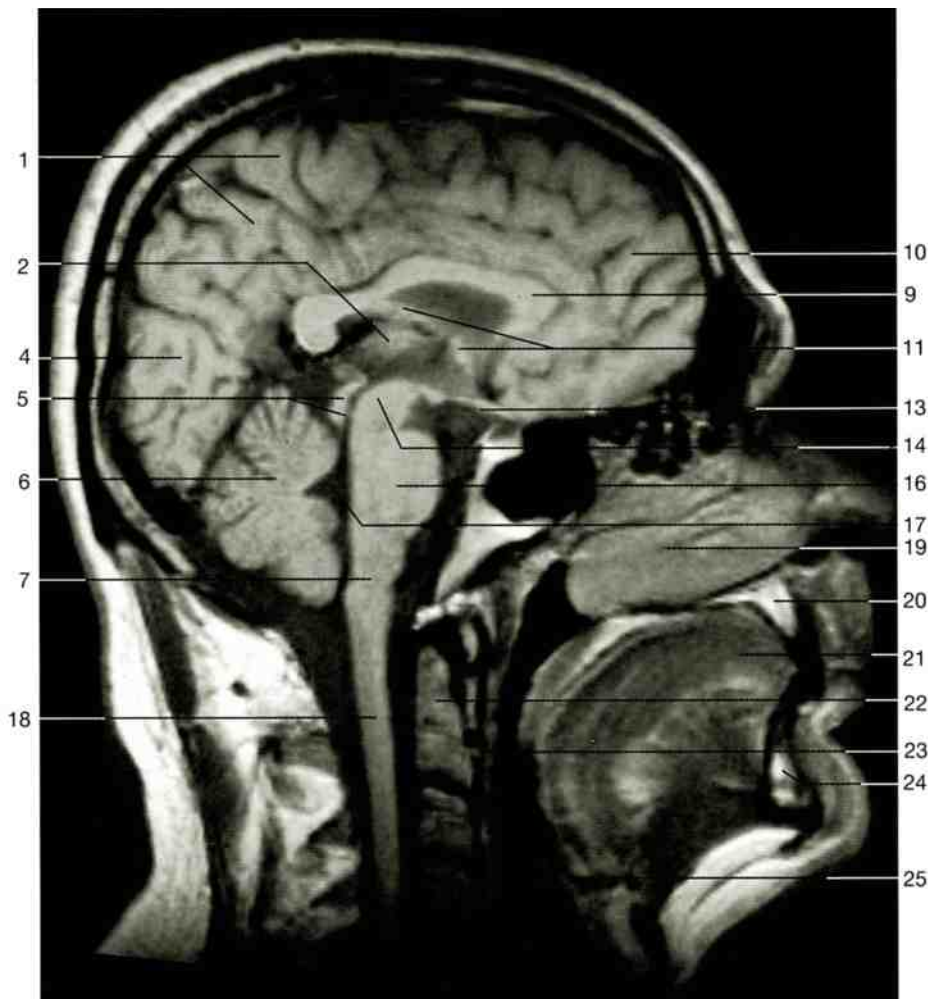
- 1 Superior cerebral veins
- 2 Position of central sulcus
- 3 Position of lateral sulcus and cistern of lateral cerebral fossa
- 4 Frontal pole
- 5 Lateral sulcus (arrow)
- 6 Temporal pole
- 7 Pons and basilar artery
- 8 Vertebral arteries
- 9 Superior anastomotic vein
- 10 Occipital pole
- 11 Inferior cerebral veins
- 12 Hemisphere of cerebellum
- 13 Medulla oblongata

Brain with pia mater and arachnoid. Frontal pole to the left (lateral aspect).

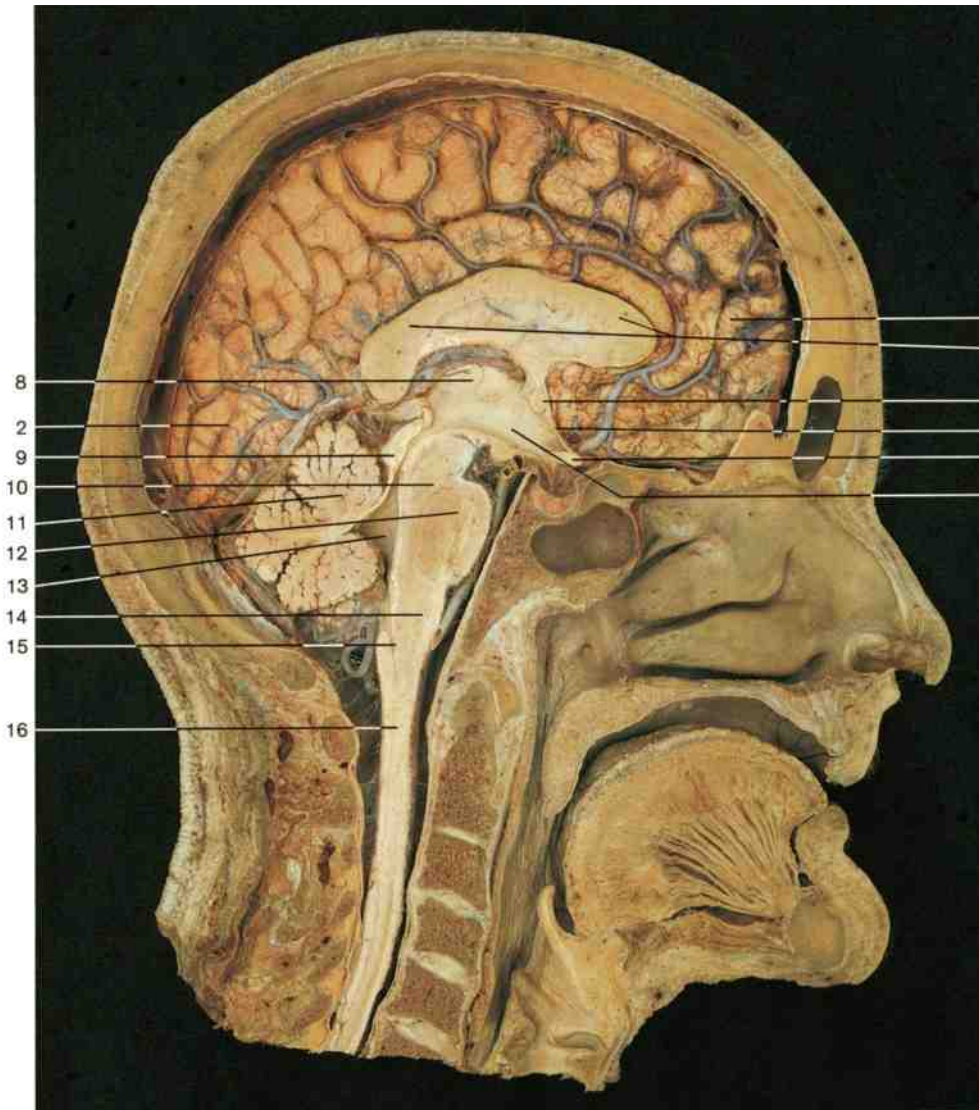
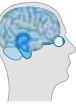

- 1 Parietal lobe
- 2 Thalamus, third ventricle, and intermediate mass
- 3 Great cerebral vein
- 4 Occipital lobe
- 5 Colliculi of the midbrain and cerebral aqueduct
- 6 Cerebellum
- 7 Medulla oblongata
- 8 Central sulcus
- 9 Corpus callosum
- 10 Frontal lobe
- 11 Fornix and anterior commissure
- 12 Hypothalamus
- 13 Optic chiasma
- 14 Midbrain
- 15 Temporal lobe
- 16 Pons
- 17 Fourth ventricle
- 18 Spinal cord
- 19 Inferior concha and nasal cavity
- 20 Alveolar process of maxilla
- 21 Tongue
- 22 Dens of axis
- 23 Oral part of pharynx
- 24 Alveolar process of mandible
- 25 Epiglottitis

Brain and brain stem, median section. Frontal pole to the right.

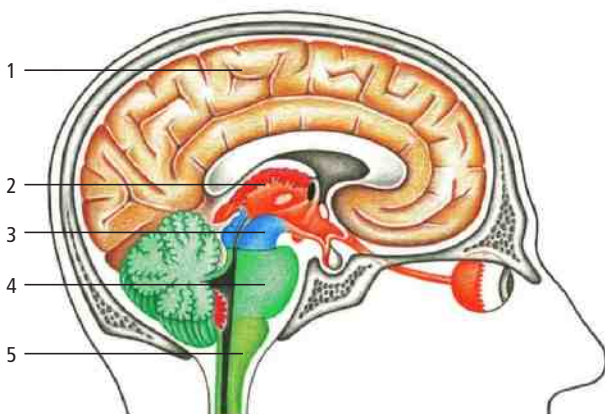


Median section through the head. (MRI scan, cf. section on opposite page.)



- 1 Frontal lobe of cerebrum
- 2 Occipital lobe of cerebrum
- 3 Corpus callosum
- 4 Anterior commissure
- 5 Lamina terminalis
- 6 Optic chiasma
- 7 Hypothalamus
- 8 Thalamus and third ventricle
- 9 Colliculi of the midbrain
- 10 Midbrain (inferior portion)
- 11 Cerebellum
- 12 Pons
- 13 Fourth ventricle
- 14 Medulla oblongata
- 15 Central canal
- 16 Spinal cord

Median section through the head. Regions of the brain. Falx cerebri removed.



Scheme of brain divisions (cf. table). (Schematic drawing.) Red = choroidal plexus.

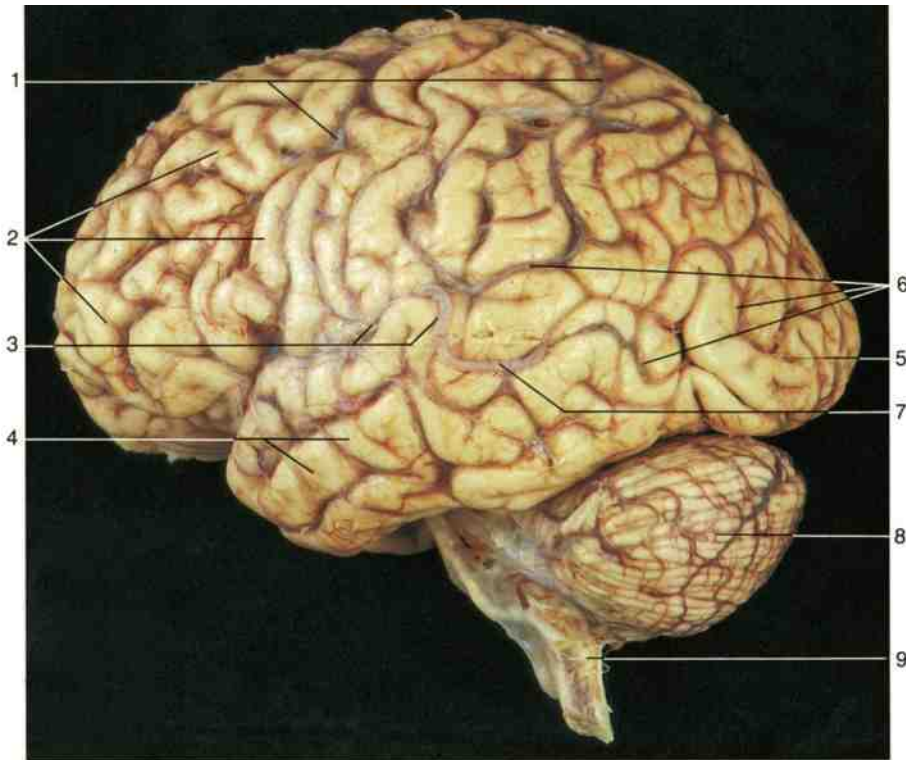
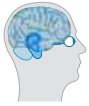- 1 Telencephalon (yellow) with lateral ventricles
- 2 Diencephalon (orange) with third ventricle, optic nerve, and retina
- 3 Mesencephalon (blue) with cerebral aqueduct
- 4 Metencephalon (green) with fourth ventricle
- 5 Myelencephalon (yellow-green)

I. Prosencephalon (forebrain)	<ul style="list-style-type: none"> 1. Telencephalon (cerebral hemispheres, striatum, etc.) 2. Diencephalon (thalamus, metathalamus, hypothalamus, etc.)
II. Mesencephalon (midbrain)	3. Mesencephalon (colliculi, cerebral peduncles, tegmentum)
III. Rhombencephalon (hindbrain)	<ul style="list-style-type: none"> 4. Metencephalon (pons, cerebellum) 5. Myelencephalon (medulla oblongata)

Main divisions of the brain

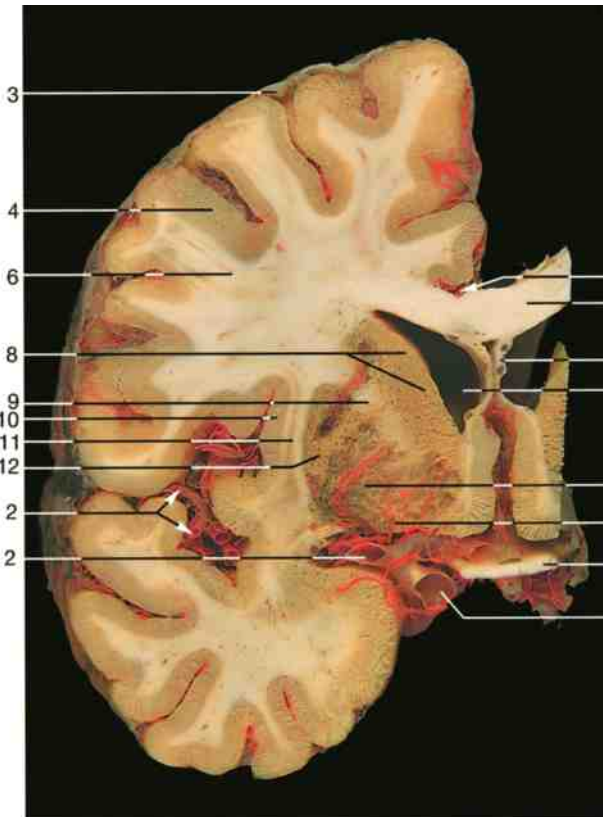
I-III = primary brain vesicles; 1-5 = secondary brain vesicles

Diencephalon, midbrain, pons, and medulla oblongata are collectively termed the **brain stem**.

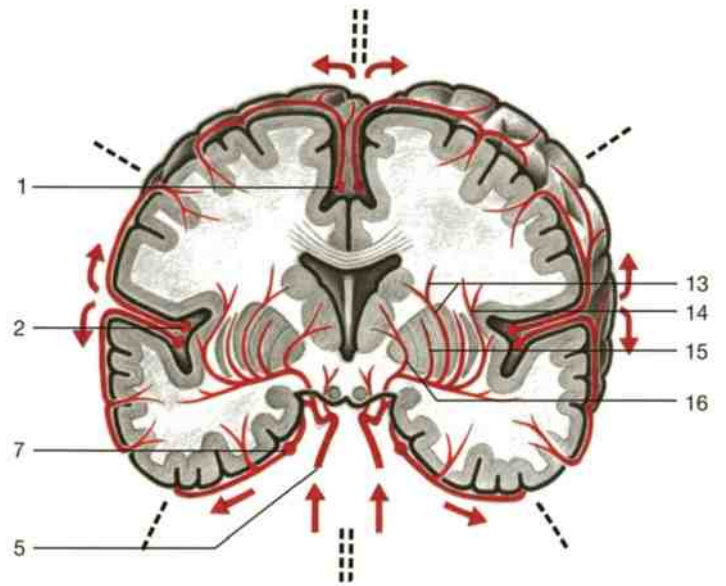


- 1 Superior cerebral veins and parietal lobe
- 2 Frontal lobe
- 3 Superficial middle cerebral vein and cistern of lateral cerebral fossa
- 4 Temporal lobe
- 5 Occipital lobe
- 6 Inferior cerebral veins and transverse occipital sulcus
- 7 Inferior anastomotic vein
- 8 Cerebellum
- 9 Medulla oblongata

Brain with pia mater. Cerebral veins (bluish). In the lateral sulcus the cistern of the lateral fossa is recognizable. Frontal lobe to the left.



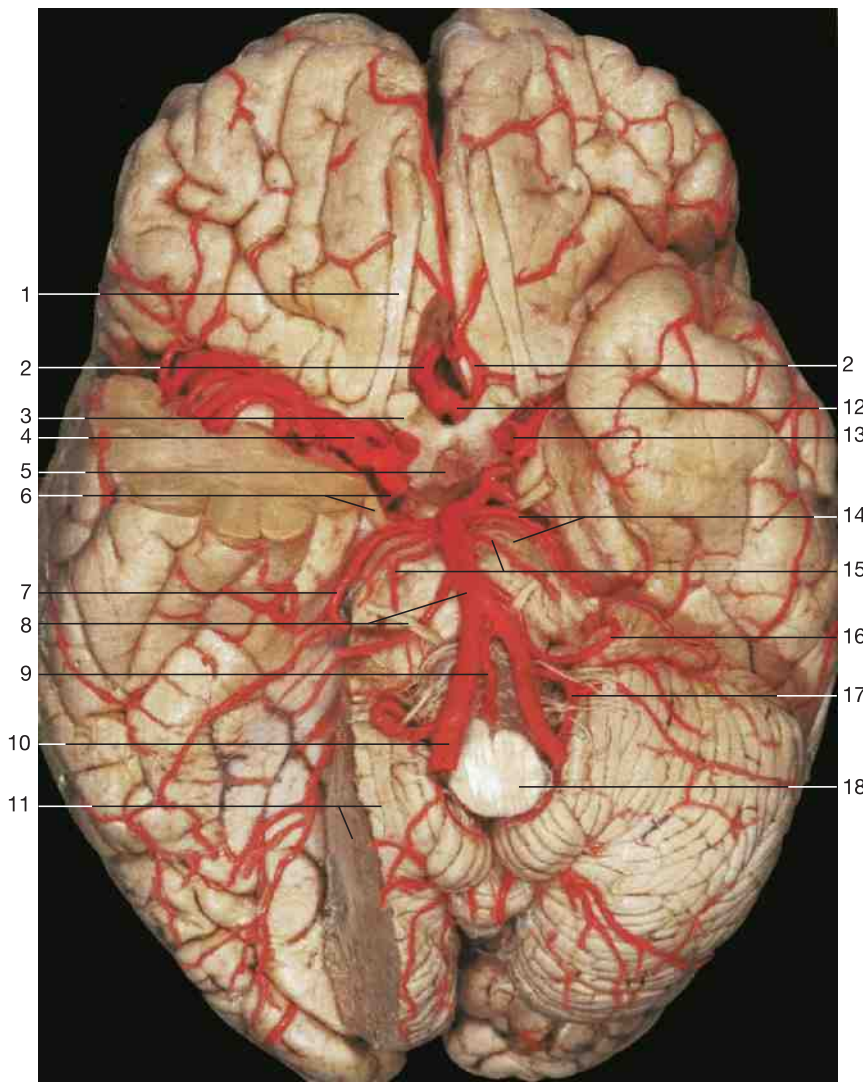
- 1 Anterior cerebral artery
- 2 Middle cerebral arteries
- 3 Arachnoid
- 4 Cortex
- 5 Internal carotid artery
- 6 Frontal lobe (white matter)
- 7 Posterior cerebral artery
- 8 Caudate nucleus
- 9 Internal capsule
- 10 Insular lobe
- 11 Claustrum
- 12 Putamen
- 13 Posterior striate branch
- 14 Insular artery



Arteries of the brain. Coronal section. Areas supplied by cortical and central arteries. Dotted lines indicate boundaries of arterial supply areas; arrows = direction of blood flow.

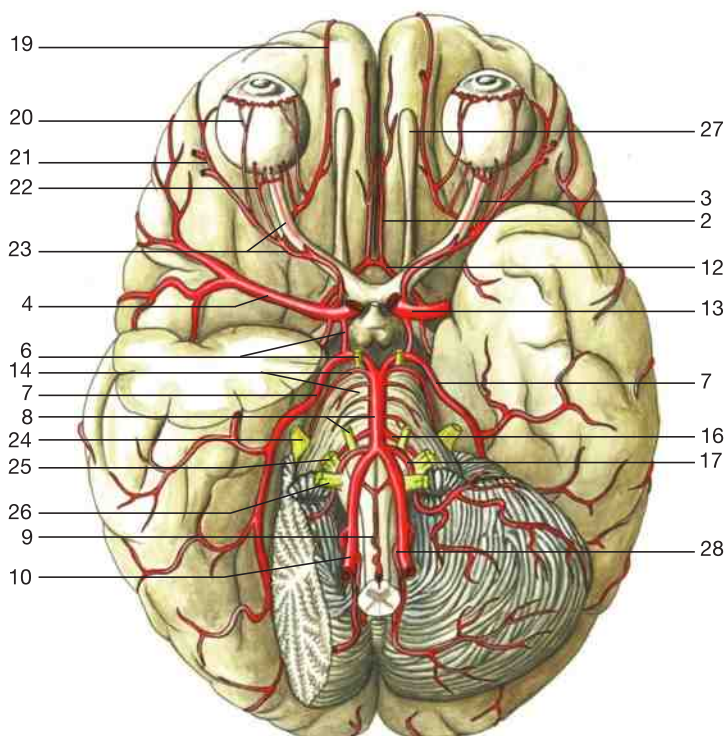
◁ **Coronal section through the right hemisphere, showing arachnoid, pia mater, and the arterial blood supply (anterior aspect).**

- 15 Pallidostriate artery
- 16 Thalamic artery
- 17 Corpus callosum
- 18 Septum pellucidum
- 19 Lateral ventricle
- 20 Optic chiasma

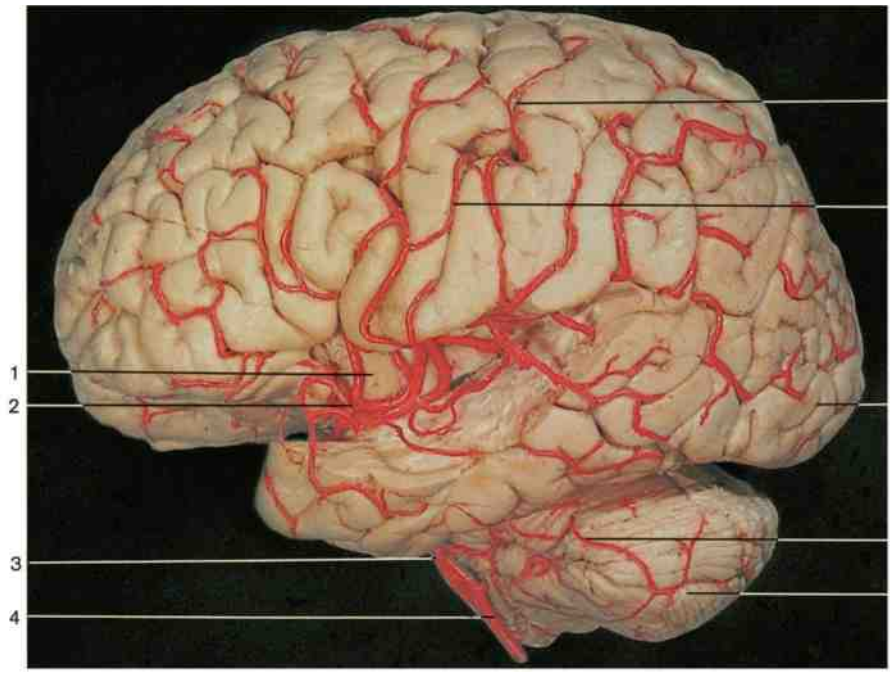


- 1 Olfactory tract
- 2 Anterior cerebral artery
- 3 Optic nerve (n. II)
- 4 Middle cerebral artery
- 5 Infundibulum
- 6 Oculomotor nerve (n. III) and posterior communicating artery
- 7 Posterior cerebral artery
- 8 Basilar artery and abducent nerve (n. VI)
- 9 Anterior spinal artery
- 10 Vertebral artery
- 11 Cerebellum
- 12 Anterior communicating artery
- 13 Internal carotid artery
- 14 Superior cerebellar artery and pons
- 15 Labyrinthine arteries
- 16 Inferior anterior cerebellar artery
- 17 Inferior posterior cerebellar artery
- 18 Medulla oblongata
- 19 Supratrochlear artery
- 20 Anterior ciliary arteries
- 21 Lacrimal artery
- 22 Posterior ciliary arteries
- 23 Ophthalmic artery with central retinal artery
- 24 Trigeminal nerve (n. V)
- 25 Facial nerve (n. VII) and vestibulocochlear nerve (n. VIII)
- 26 Glossopharyngeal nerve (n. IX), vagus nerve (n. X), and accessory nerve (n. XI)
- 27 Olfactory bulb
- 28 Posterior spinal artery

Arteries of the brain (inferior aspect, frontal pole above). Right temporal lobe and cerebellum partly removed.



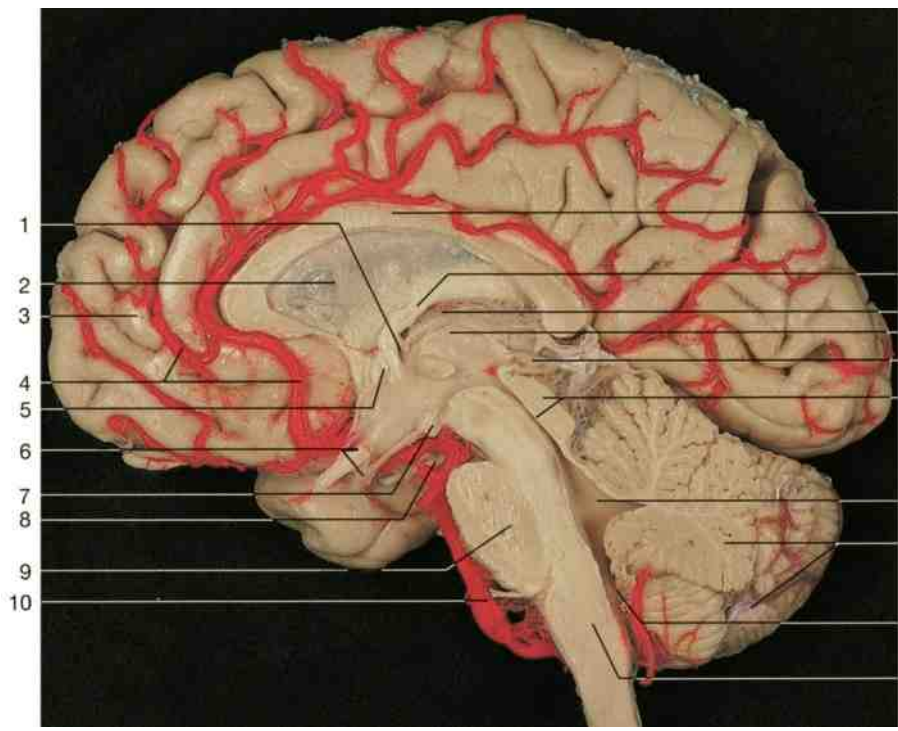
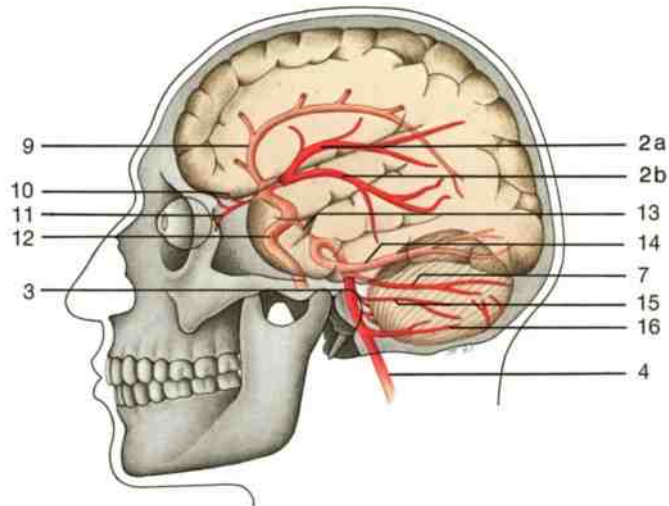
Arteries of the brain (inferior aspect). Right temporal lobe and cerebellum partly removed. Note the arterial circle of Willis around the infundibulum.



- 1 Insula
- 2 Middle cerebral artery (2 branches:
 - a Parietal branches,
 - b Temporal branches)
- 3 Basilar artery
- 4 Vertebral artery
- 5 Central sulcus
- 6 Occipital lobe
- 7 Superior cerebellar artery
- 8 Cerebellum
- 9 Anterior cerebral artery
- 10 Ethmoidal arteries
- 11 Ophthalmic artery
- 12 Internal carotid artery
- 13 Posterior communicating artery
- 14 Posterior cerebral artery
- 15 Anterior inferior cerebellar artery
- 16 Posterior inferior cerebellar artery

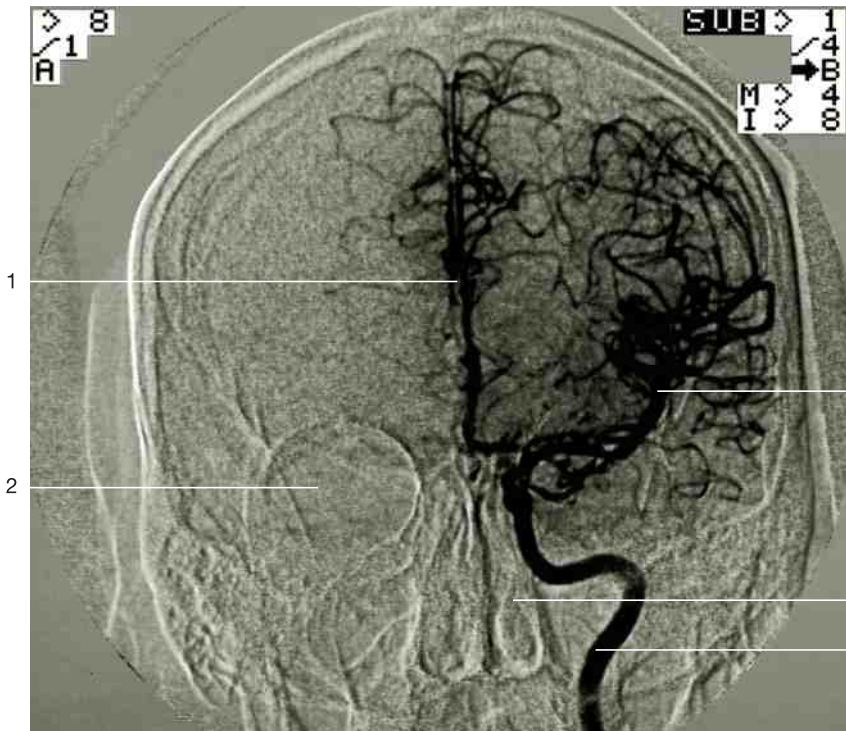
Cerebral arteries. Lateral aspect of the left hemisphere. The upper part of the temporal lobe has been removed to display the insula and cerebral arteries.

◁ **Arteries of the brain.**



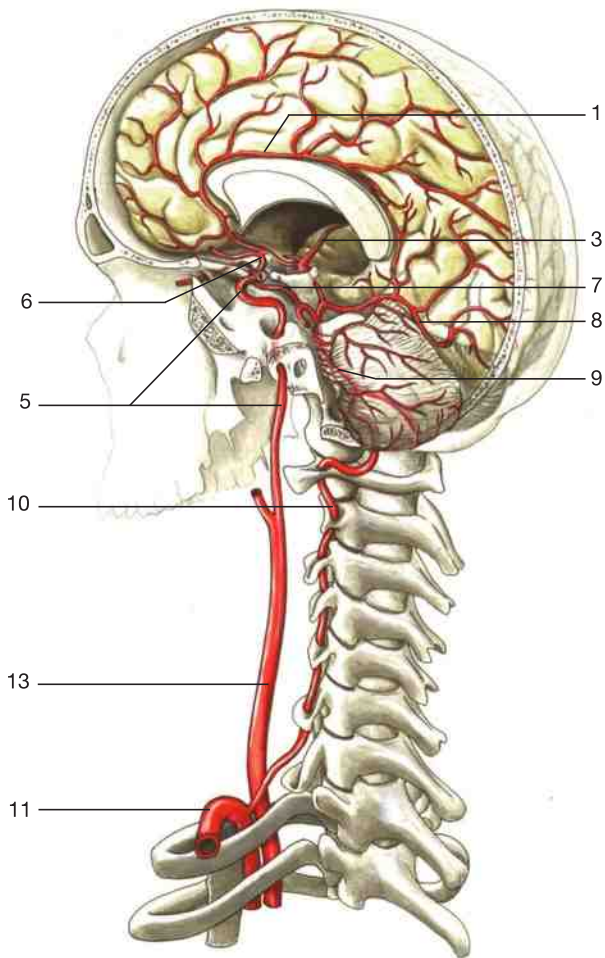
- 1 Interventricular foramen
- 2 Septum pellucidum
- 3 Frontal lobe
- 4 Anterior cerebral artery
- 5 Anterior commissure
- 6 Optic chiasma and infundibulum
- 7 Mamillary body
- 8 Oculomotor nerve (n. III)
- 9 Pons
- 10 Basilar artery
- 11 Corpus callosum
- 12 Fornix
- 13 Choroid plexus
- 14 Third ventricle
- 15 Pineal body
- 16 Tectum and cerebral aqueduct
- 17 Fourth ventricle
- 18 Cerebellum (arbor vitae, vermis)
- 19 Median aperture of Magendie
- 20 Medulla oblongata

Median section through the brain and brain stem. Cerebral arteries injected with red resin.

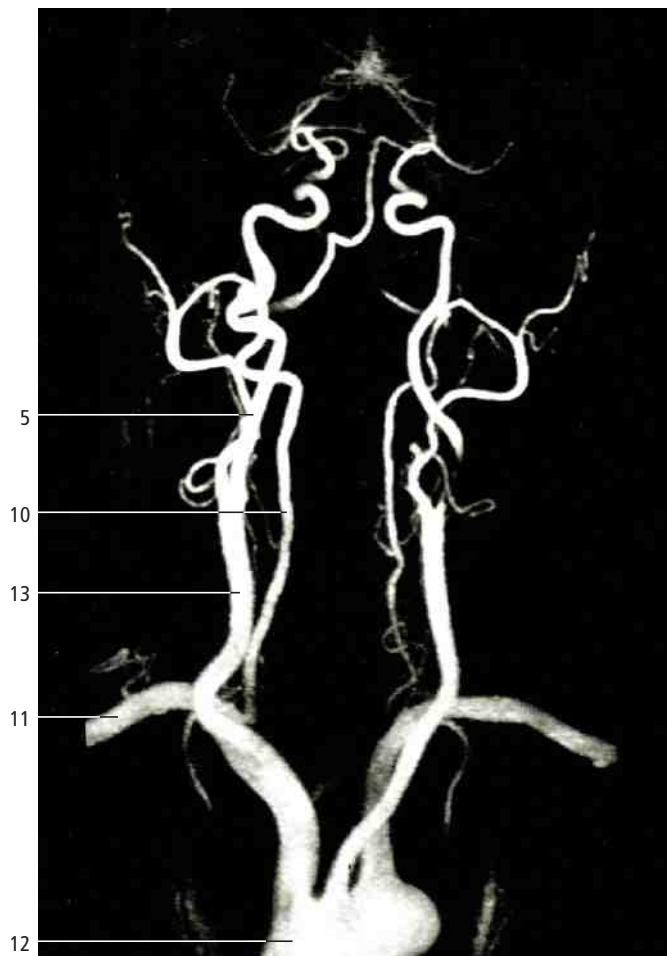


- 1 Anterior cerebral artery
- 2 Orbit
- 3 Middle cerebral artery
- 4 Nasal cavity
- 5 Internal carotid artery
- 6 Arterial circle of Willis
- 7 Posterior communicating artery
- 8 Posterior cerebral artery
- 9 Basilar artery
- 10 Vertebral artery
- 11 Subclavian artery
- 12 Aortic arch
- 13 Common carotid artery

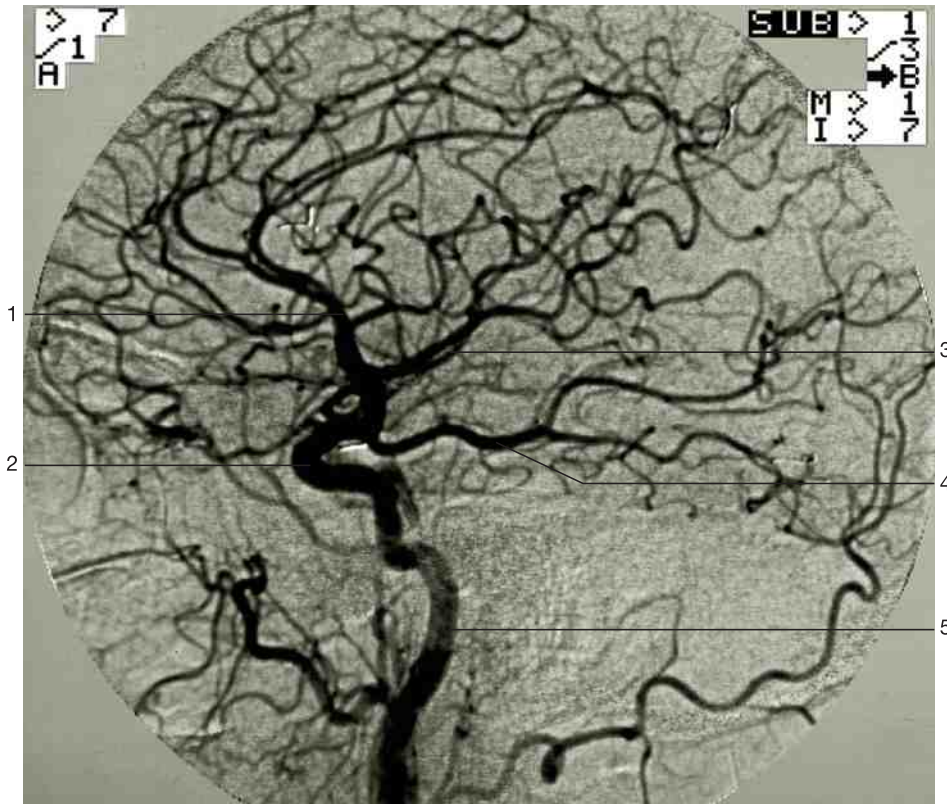
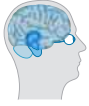Arteries of the brain. Angiogram of the internal carotid artery (anterior aspect)
(courtesy of Prof. Dr. W. Huk, University of Erlangen-Nürnberg).



Cerebral arteries (schematic drawing).
Left hemisphere and brain stem have been removed.
Note the arterial circle of Willis around the sella turcica.

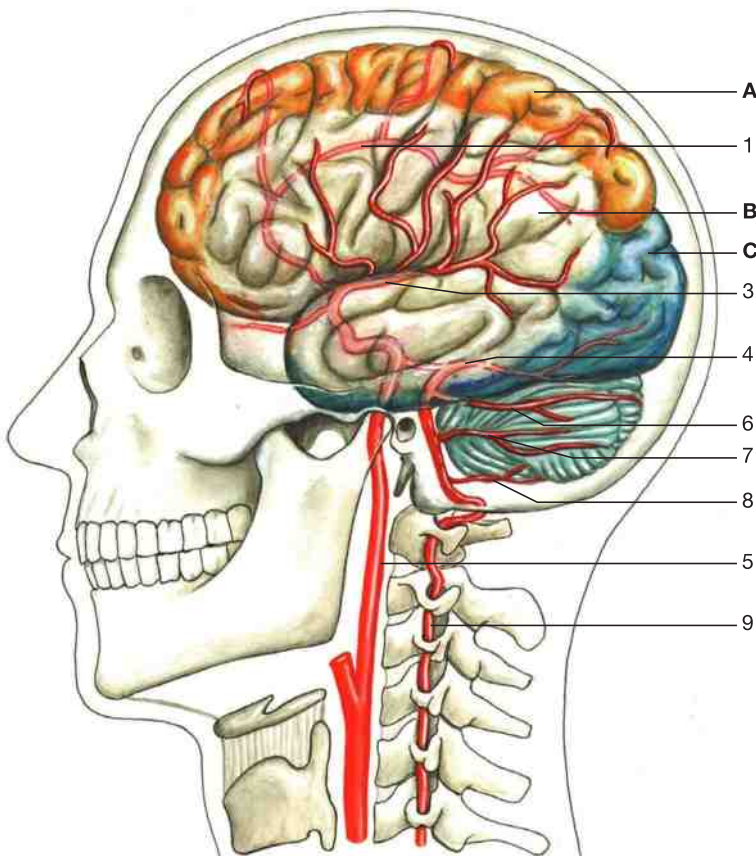


Main arteries for brain supply (MRI angiograph, anterior aspect,
courtesy of Prof. Dr. W. Bautz, University of Erlangen-Nürnberg).



- 1 Anterior cerebral artery
- 2 Loop of the internal carotid artery
- 3 Middle cerebral artery
- 4 Posterior cerebral artery
- 5 Internal carotid artery
- 6 Superior cerebellar artery
- 7 Anterior inferior cerebellar artery
- 8 Posterior inferior cerebellar artery
- 9 Vertebral artery

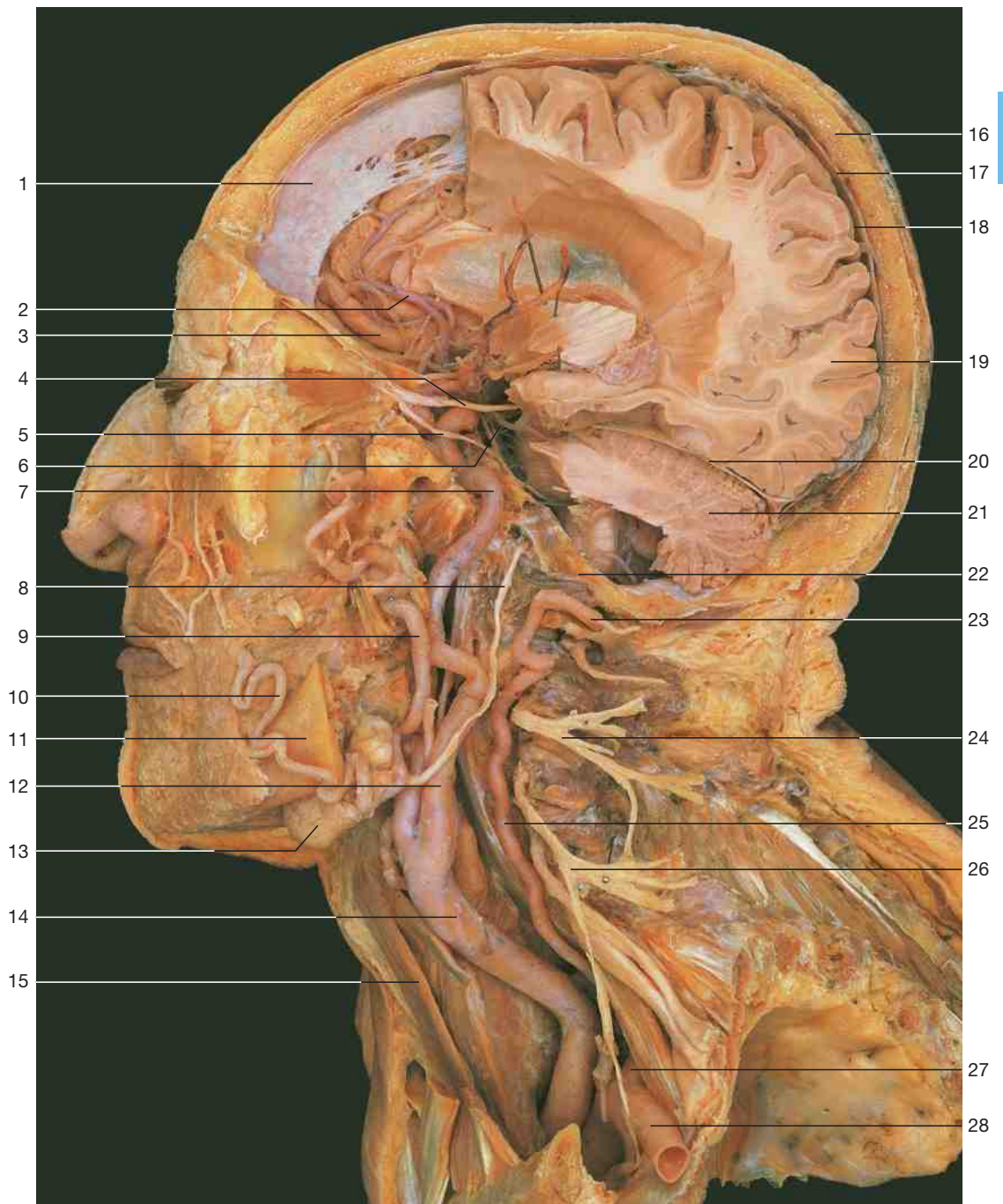
Arteries of the brain. Angiogram of the internal carotid artery (lateral aspect) (courtesy of Prof. Dr. W. Huk, University of Erlangen-Nürnberg).



Areas of blood supply of the brain
(cerebellum = light blue).

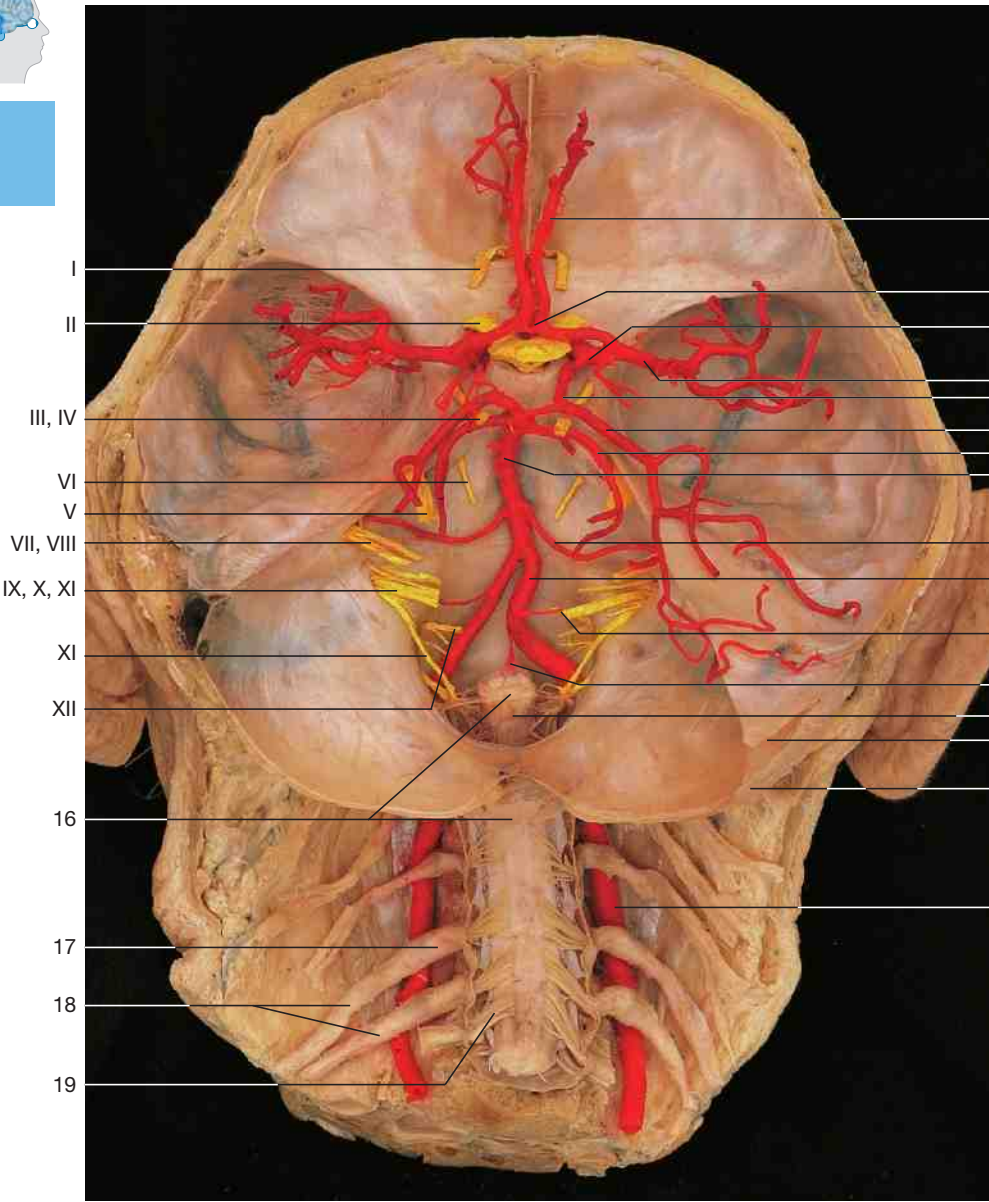
- A = anterior cerebral artery (upper and medial parts of the cortex) (orange)
- B = middle cerebral artery (lateral areas of the frontal, parietal, and temporal lobes) (white)
- C = posterior cerebral artery (occipital lobe and inferior parts of the temporal lobe) (blue)

Cerebral arteries. The areas supplied by the main arteries are indicated by different colors (lateral aspect).



Dissection of the arteries of the brain and head (lateral aspect, superficial layers of facial region and left hemisphere and cerebellum partly removed).

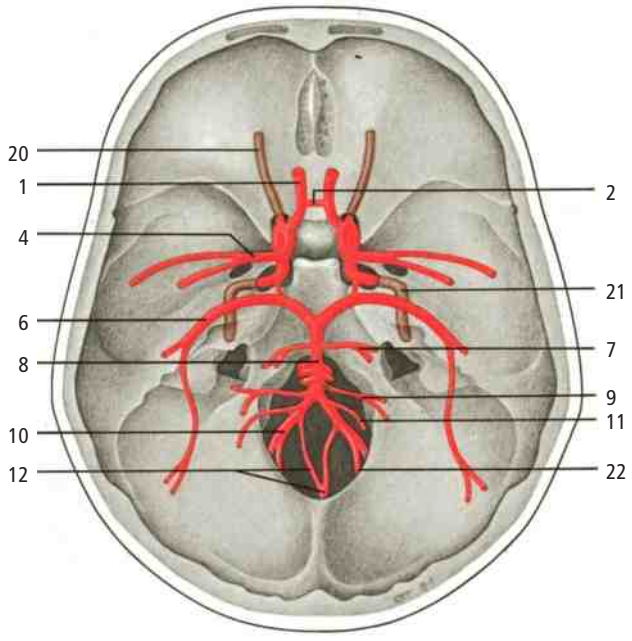
- | | |
|--|---|
| 1 Falx cerebri | 16 Calvaria |
| 2 Anterior cerebral artery | 17 Dura mater |
| 3 Frontal lobe | 18 Subarachnoidal space |
| 4 Oculomotor nerve (n. III) | 19 Occipital lobe |
| 5 Abducent nerve (n. VI) | 20 Tentorium of cerebellum |
| 6 Posterior cerebral artery | 21 Cerebellum |
| 7 Internal carotid artery, entering sinus cavernosus | 22 Base of skull |
| 8 Hypoglossus nerve (n. XII) | 23 Vertebral artery
(on the posterior arch of the atlas) |
| 9 Maxillary artery | 24 Cervical plexus |
| 10 Facial artery | 25 Vertebral artery
(removed from the cervical vertebrae) |
| 11 Mandible | 26 Brachial plexus |
| 12 External carotid artery | 27 Vertebral artery
(branching from the subclavian artery) |
| 13 Submandibular gland | 28 Subclavian artery |
| 14 Common carotid artery | |
| 15 Sternohyoid muscle | |



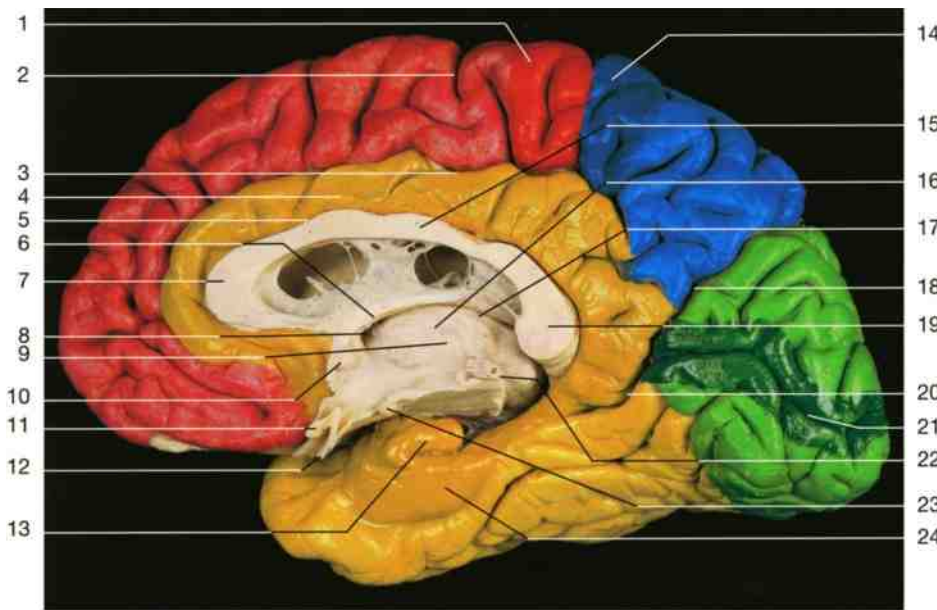
- 1 Anterior cerebral artery
- 2 Anterior communicating artery
- 3 Internal carotid artery
- 4 Medial cerebral artery
- 5 Posterior communicating artery
- 6 Posterior cerebral artery
- 7 Superior cerebellar artery
- 8 Basilar artery
- 9 Anterior inferior cerebellar artery with the artery of the labyrinth
- 10 Vertebral artery
- 11 Posterior inferior cerebellar artery
- 12 Anterior spinal artery
- 13 Pia mater of spinal cord
- 14 Tentorium cerebelli
- 15 Dura mater of the cranial cavity
- 16 Spinal cord
- 17 Spinal ganglion
- 18 Spinal nerves (C₃, C₄)
- 19 Posterior root filaments (fila radicularia post.)
- 20 Ophthalmic artery (within the orbit)
- 21 Internal carotid artery (within carotid canal)
- 22 Posterior spinal artery

- I Olfactory tract
- II Optic nerve
- III Oculomotor nerve
- IV Trochlear nerve
- V Trigeminal nerve
- VI Abducent nerve
- VII Facial nerve
- VIII Vestibulocochlear nerve
- IX Glossopharyngeal nerve
- X Vagus nerve
- XI Accessory nerve
- XII Hypoglossus nerve

Dissection of the arterial circle of the cerebrum at the base of the skull
 (from above; calvaria and brain have been removed; arteries are colored in red, cranial nerves [n. I–XII] in yellow).



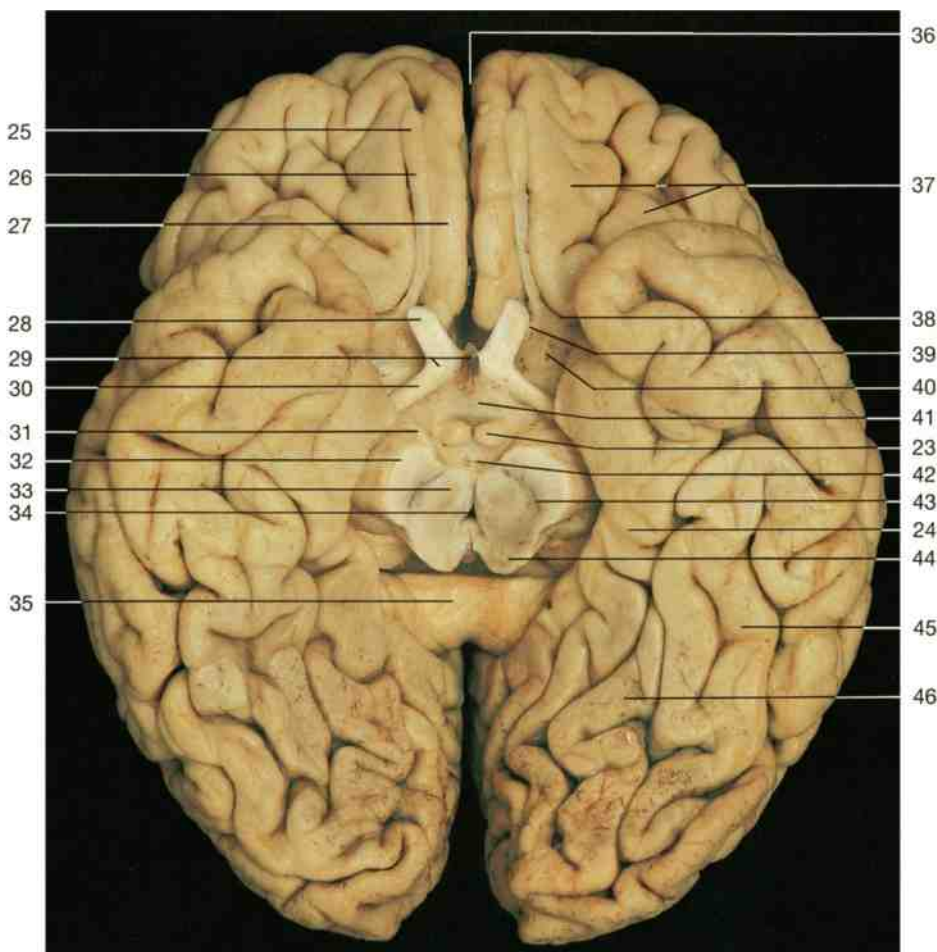
Arterial circle of Willis (superior aspect).
 (Schematic drawing.)



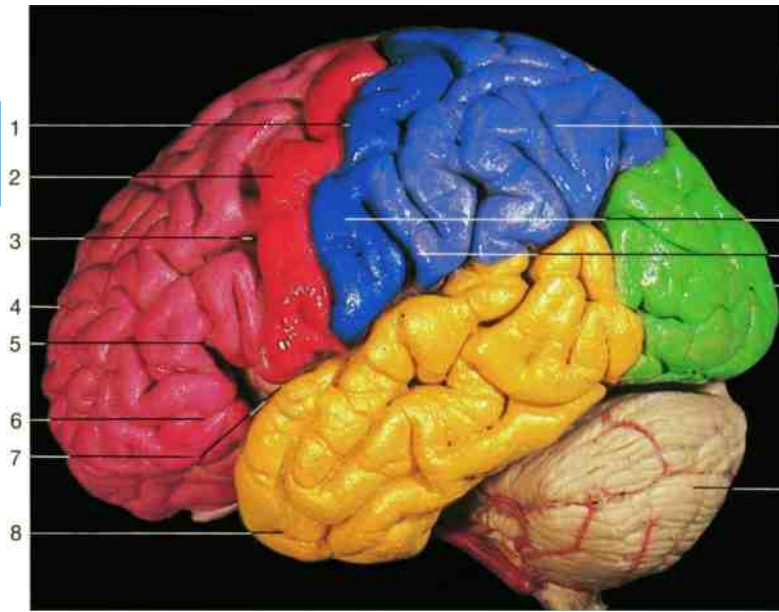
Brain, right hemisphere (medial aspect). Frontal pole to the left (midbrain divided, cerebellum and inferior part of brain stem removed).

Red	= Frontal lobe	Dark blue	= Postcentral lobe
Blue	= Parietal lobe	Dark green	= Calcarine sulcus
Green	= Occipital lobe	Dark yellow	= Limbic cortex (cingulate and parahippocampal gyri)
Yellow	= Temporal lobe		
Dark red	= Precentral lobe		

- 1 Precentral gyrus
- 2 Precentral sulcus
- 3 Cingulate sulcus
- 4 Cingulate gyrus
- 5 Sulcus of corpus callosum
- 6 Fornix
- 7 Genu of corpus callosum
- 8 Interventricular foramen
- 9 Intermediate mass
- 10 Anterior commissure
- 11 Optic chiasma
- 12 Infundibulum
- 13 Uncus hippocampi
- 14 Postcentral gyrus
- 15 Body of corpus callosum
- 16 Third ventricle and thalamus
- 17 Stria medullaris
- 18 Parieto-occipital sulcus
- 19 Splenium of corpus callosum
- 20 Communication of calcarine and parieto-occipital sulcus
- 21 Calcarine sulcus
- 22 Pineal body
- 23 Mamillary body
- 24 Parahippocampal gyrus
- 25 Olfactory bulb
- 26 Olfactory tract
- 27 Gyrus rectus
- 28 Optic nerve
- 29 Infundibulum and optic chiasma
- 30 Optic tract
- 31 Oculomotor nerve
- 32 Pedunculus cerebri
- 33 Red nucleus
- 34 Cerebral aqueduct
- 35 Corpus callosum
- 36 Longitudinal fissure
- 37 Orbital gyri
- 38 Lateral root of olfactory tract
- 39 Medial root of olfactory tract
- 40 Olfactory tubercle and anterior perforated substance
- 41 Tuber cinereum
- 42 Interpeduncular fossa
- 43 Substantia nigra
- 44 Colliculi of the midbrain
- 45 Lateral occipitotemporal gyrus
- 46 Medial occipitotemporal gyrus

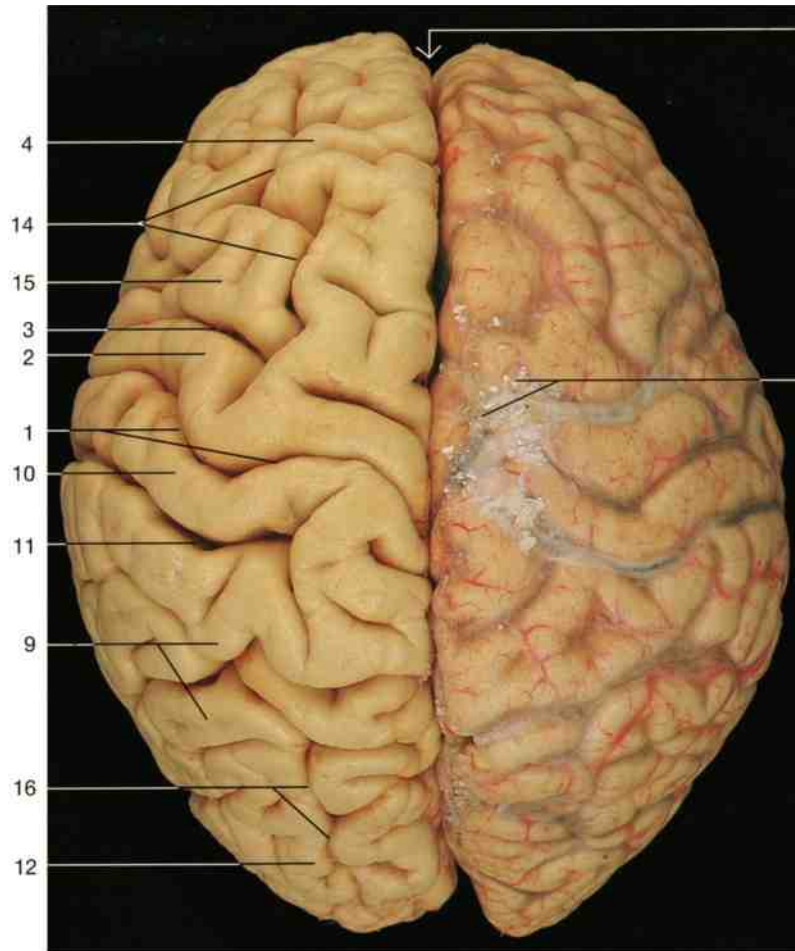


Brain (inferior aspect). Midbrain divided. Cerebellum and inferior part of brain stem removed. Frontal pole at the top.



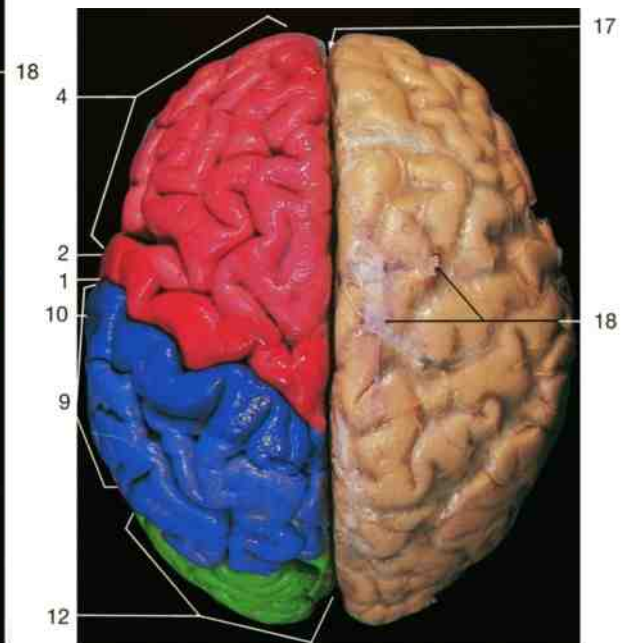
- 1 Central sulcus
- 2 Precentral gyrus
- 3 Precentral sulcus
- 4 Frontal lobe
- 5 Anterior ascending ramus of lateral sulcus
- 6 Anterior horizontal ramus of lateral sulcus
- 7 Lateral sulcus
- 8 Temporal lobe
- 9 Parietal lobe
- 10 Postcentral gyrus
- 11 Postcentral sulcus
- 12 Occipital lobe
- 13 Cerebellum

Brain, left hemisphere (lateral aspect). Frontal pole to the left.

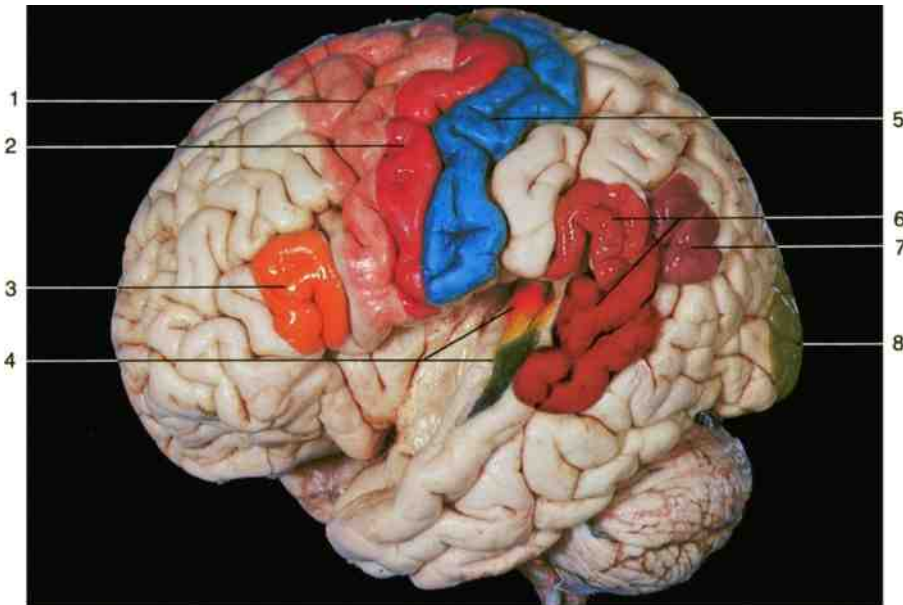


- Pink = Frontal lobe
- Blue = Parietal lobe
- Green = Occipital lobe
- Yellow = Temporal lobe
- Dark red = Precentral gyrus
- Dark blue = Postcentral gyrus

Brain (superior aspect). Right hemisphere with arachnoid and pia mater.

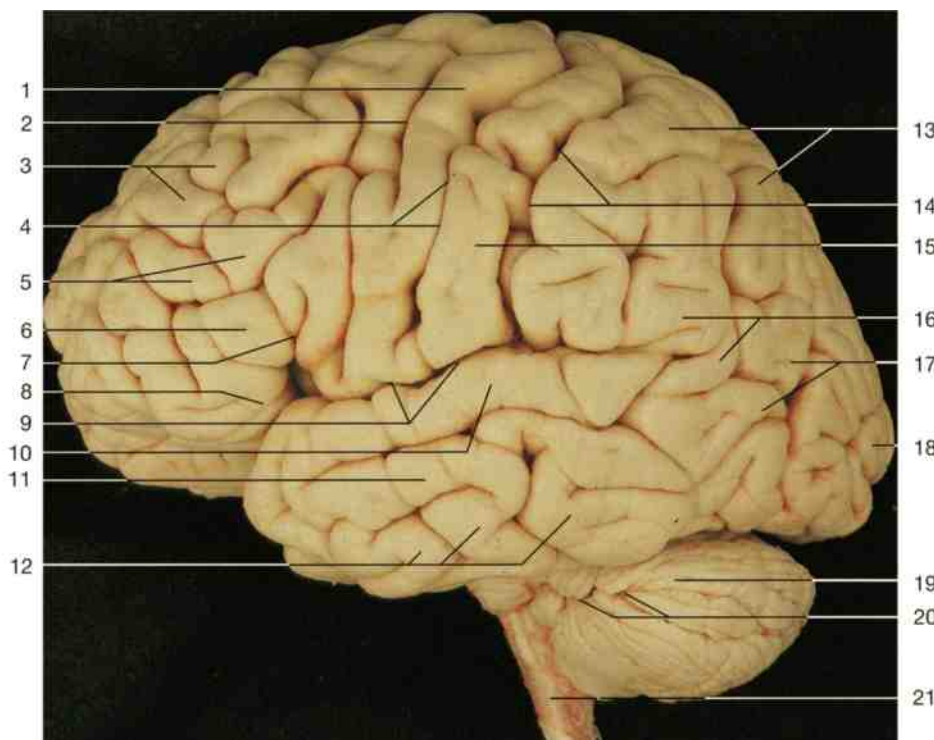


Brain (superior aspect). Lobes of the left hemisphere indicated by color; right hemisphere is covered with arachnoid and pia mater.



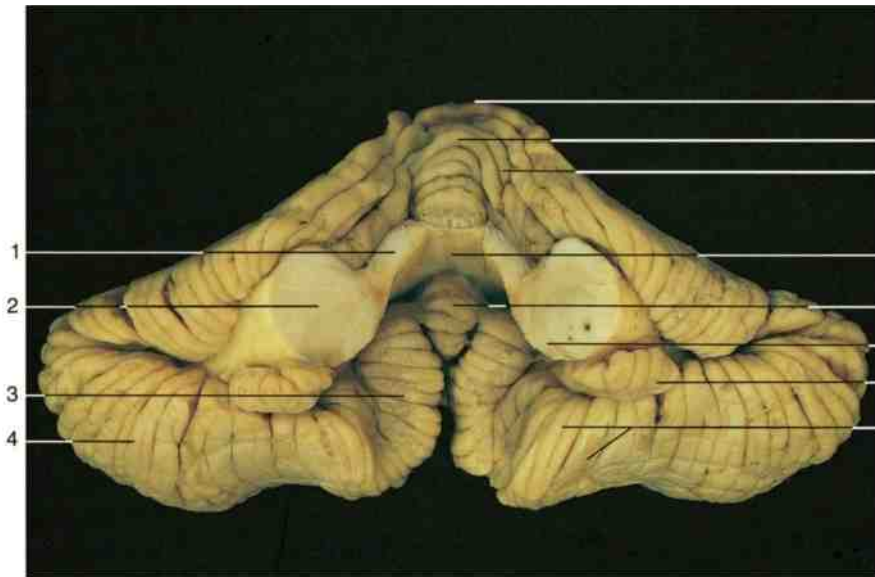
- 1 Premotor area
- 2 Somatomotor area
- 3 Motor speech area of Broca
- 4 Acoustic area
(red: high tone, dark green: low tone)
- 5 Somatosensory area
- 6 Sensory speech area of Wernicke
- 7 Reading comprehension area
- 8 Visuosensory area

Brain, left hemisphere (lateral aspect). Main cortical areas are colored.
The lateral sulcus has been opened to display the insula and the inner surface of the temporal lobe.



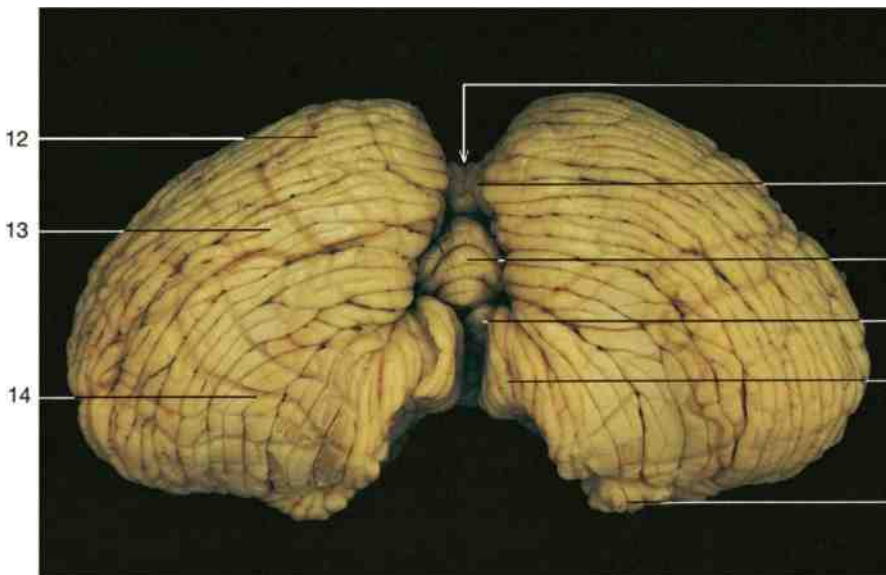
- 1 Precentral gyrus
- 2 Precentral sulcus
- 3 Superior frontal gyrus
- 4 Central sulcus
- 5 Middle frontal gyrus
- 6 Inferior frontal gyrus
- 7 Ascending ramus
- 8 Horizontal ramus
- 9 Posterior ramus
- 10 Superior temporal gyrus
- 11 Middle temporal gyrus
- 12 Inferior temporal gyrus
- 13 Parietal lobe
- 14 Postcentral sulcus
- 15 Postcentral gyrus
- 16 Supramarginal gyrus
- 17 Angular gyrus
- 18 Occipital lobe
- 19 Cerebellum
- 20 Horizontal fissure of cerebellum
- 21 Medulla oblongata

Brain, left hemisphere (lateral aspect). Frontal pole to the left.

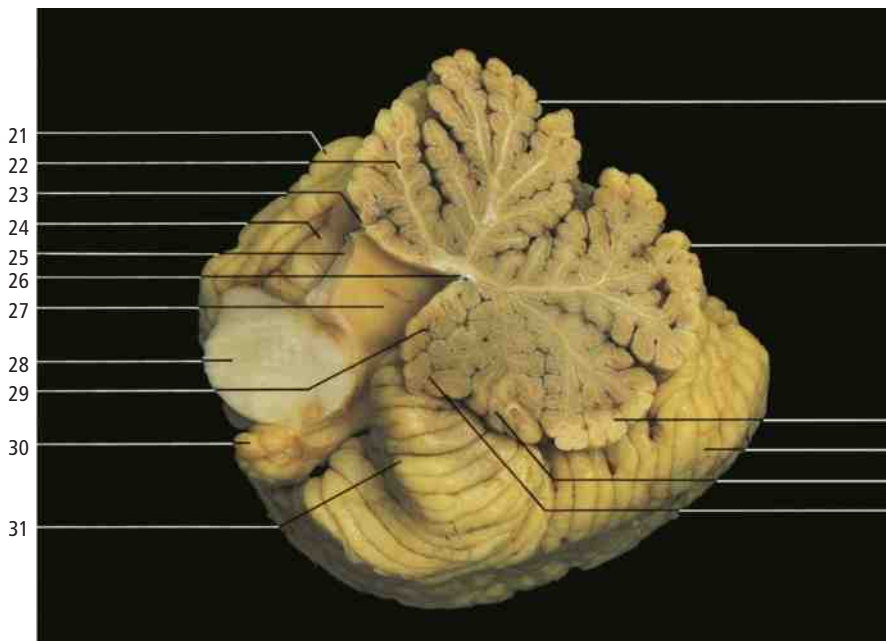


Cerebellum (inferior anterior aspect). The cerebellar peduncles have been severed.

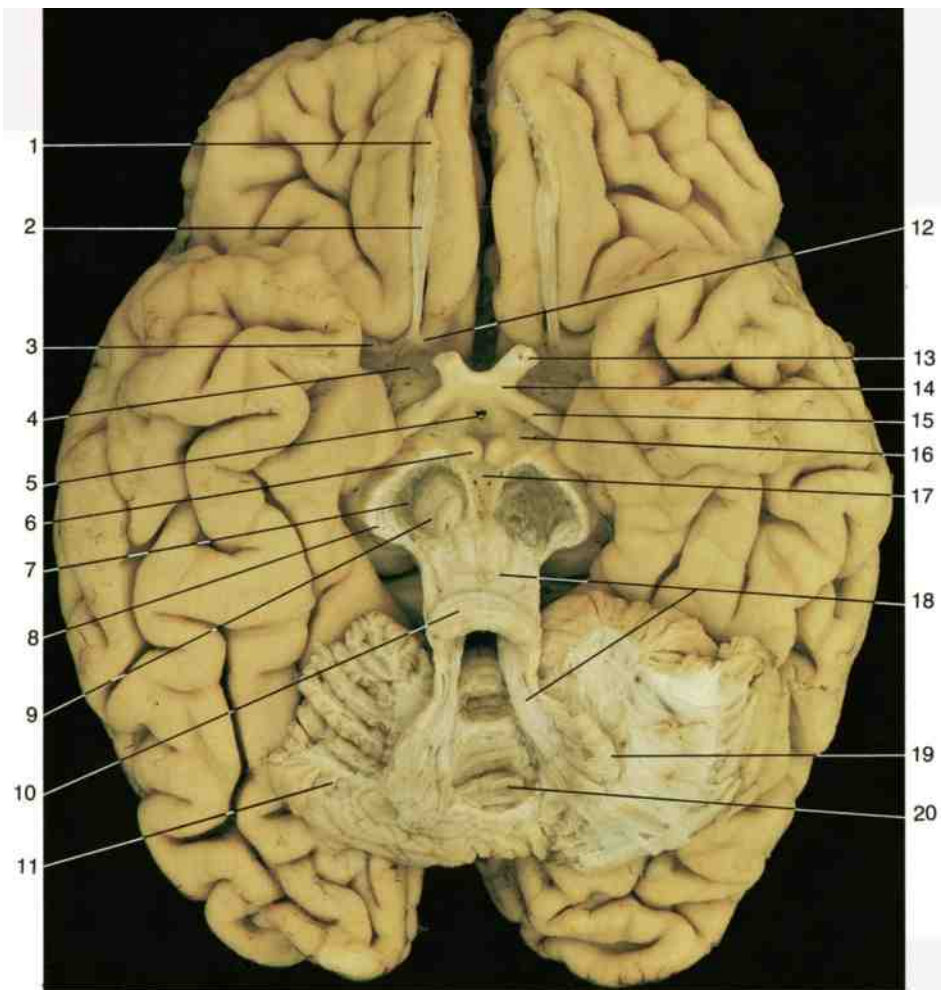
- 1 Superior cerebellar peduncle
- 2 Middle cerebellar peduncle
- 3 Cerebellar tonsil
- 4 Inferior semilunar lobule
- 5 Vermis
- 6 Central lobule of vermis
- 7 Inferior cerebellar peduncle
- 8 Superior medullary velum
- 9 Nodule of vermis
- 10 Flocculus of cerebellum
- 11 Biventral lobule
- 12 Left cerebellar hemisphere
- 13 Inferior semilunar lobule
- 14 Biventral lobule
- 15 Vermis of cerebellum
- 16 Tuber of vermis
- 17 Pyramid of vermis
- 18 Uvula of vermis
- 19 Tonsil of cerebellum
- 20 Flocculus of cerebellum
- 21 Right cerebellar hemisphere
- 22 Vermis (central lobule)
- 23 Cerebellar lingula
- 24 Ala of central lobule
- 25 Superior cerebellar peduncle
- 26 Fastigium
- 27 Fourth ventricle
- 28 Middle cerebellar peduncle
- 29 Nodule of vermis
- 30 Flocculus of cerebellum
- 31 Cerebellar tonsil
- 32 Culmen of vermis
- 33 Declive of vermis
- 34 Tuber of vermis
- 35 Inferior semilunar lobule
- 36 Pyramid of vermis (cut)
- 37 Uvula of vermis



Cerebellum (inferior posterior aspect).

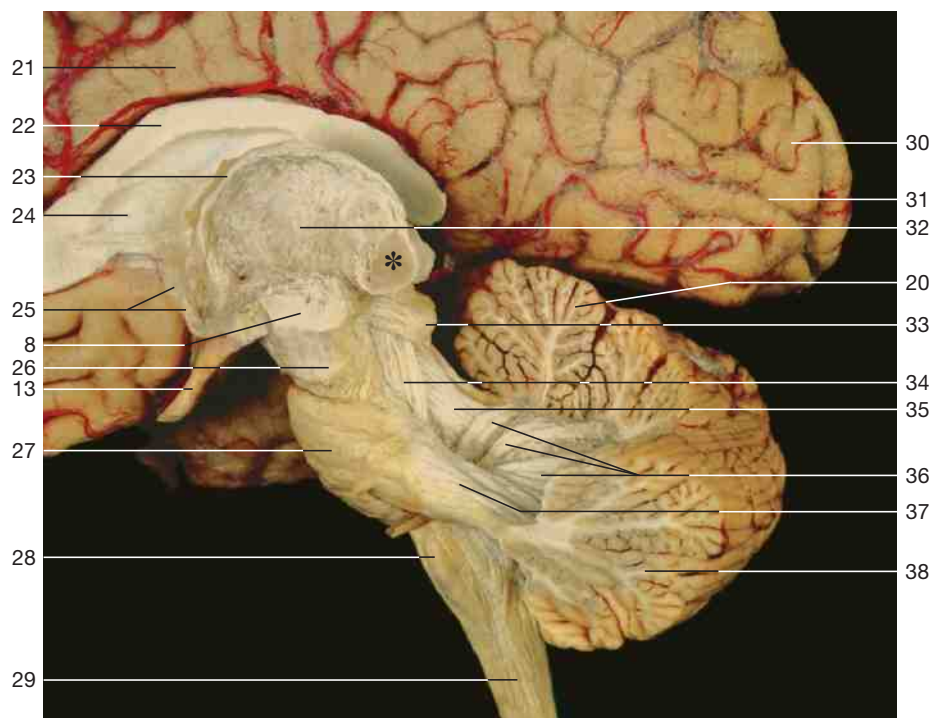


Median section through the cerebellum. Right cerebellar hemisphere and right half of vermis.

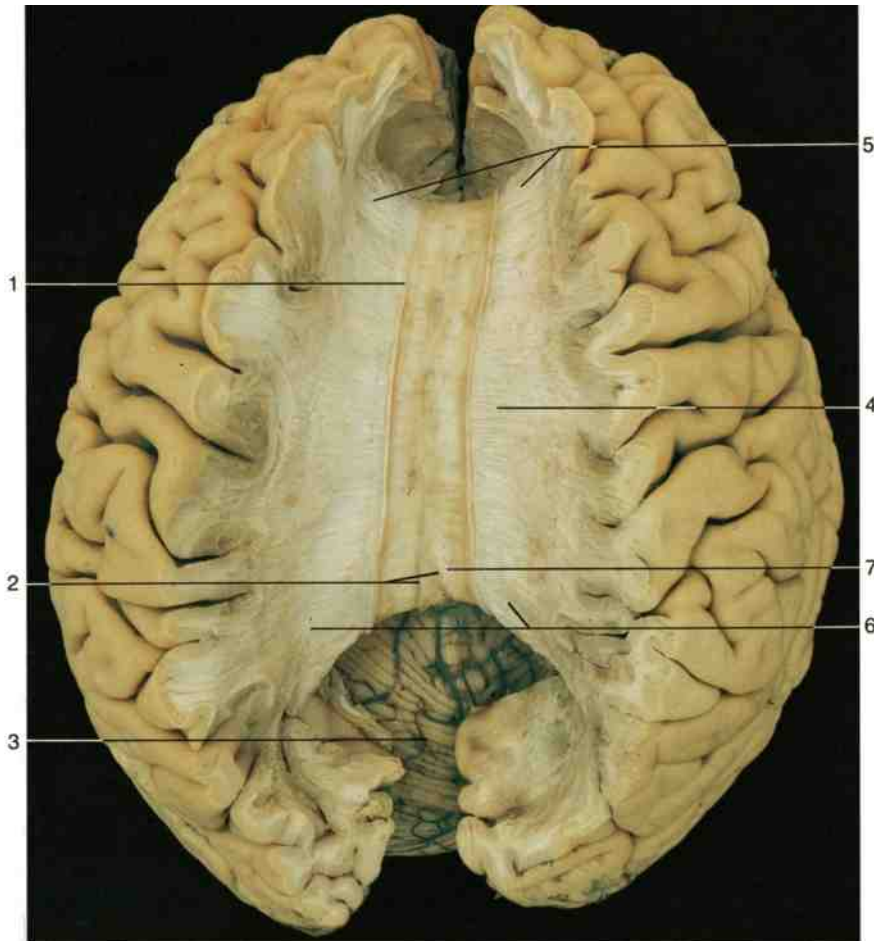
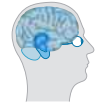

Brain and cerebellum (inferior aspect). Parts of the cerebellum have been removed to display the dentate nucleus and the main pathway to the midbrain (cerebellorubral tract).

- 1 Olfactory bulb
- 2 Olfactory tract
- 3 Lateral olfactory stria
- 4 Anterior perforated substance
- 5 Infundibulum (divided)
- 6 Mamillary body
- 7 Substantia nigra
- 8 Cerebral peduncle (cut)
- 9 Red nucleus
- 10 Decussation of superior cerebellar peduncle
- 11 Cerebellar hemisphere
- 12 Medial olfactory stria
- 13 Optic nerve
- 14 Optic chiasma
- 15 Optic tract
- 16 Posterior perforated substance
- 17 Interpeduncular fossa
- 18 Superior cerebellar peduncle and cerebellorubral tract
- 19 Dentate nucleus
- 20 Vermis of cerebellum
- 21 Cingulate gyrus
- 22 Corpus callosum
- 23 Stria terminalis
- 24 Septum pellucidum
- 25 Columna fornicis
- 26 Cerebral peduncle at midbrain level
- 27 Pons
- 28 Inferior olive
- 29 Medulla oblongata with lateral pyramidal tract
- 30 Occipital lobe
- 31 Calcarine sulcus
- 32 Thalamus
- 33 Inferior colliculus with brachium
- 34 Medial lemniscus
- 35 Superior cerebellar peduncle
- 36 Inferior cerebellar peduncle
- 37 Middle cerebellar peduncle
- 38 Cerebellar hemisphere

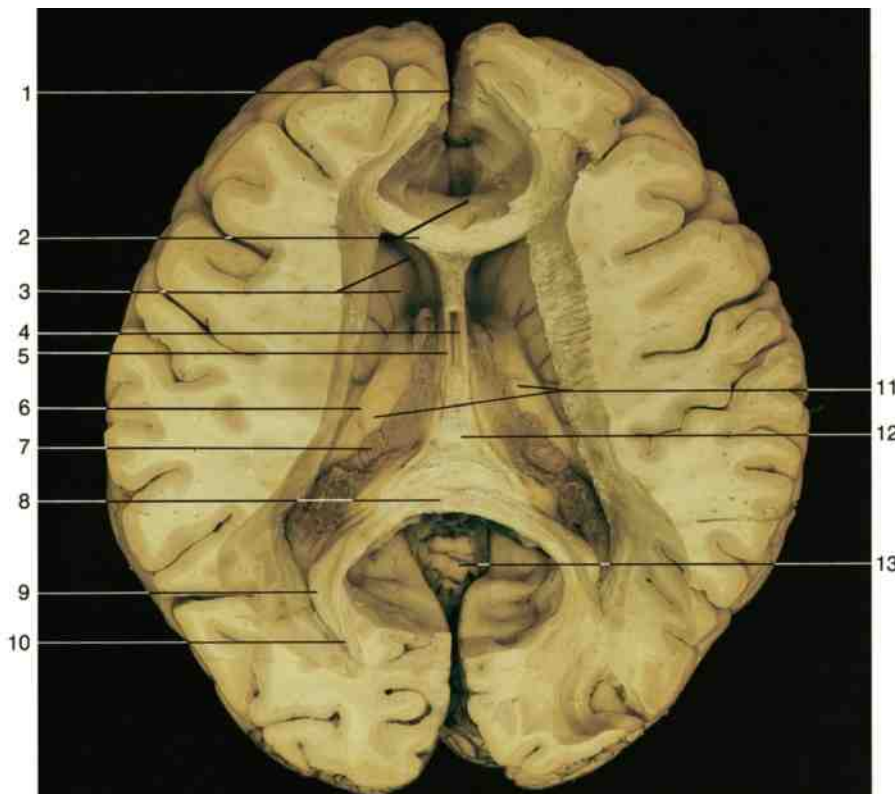


Dissection of the cerebellar peduncles and their connection with midbrain and diencephalon. A small part of pulvinar thalami (*) has been cut to show inferior brachium.



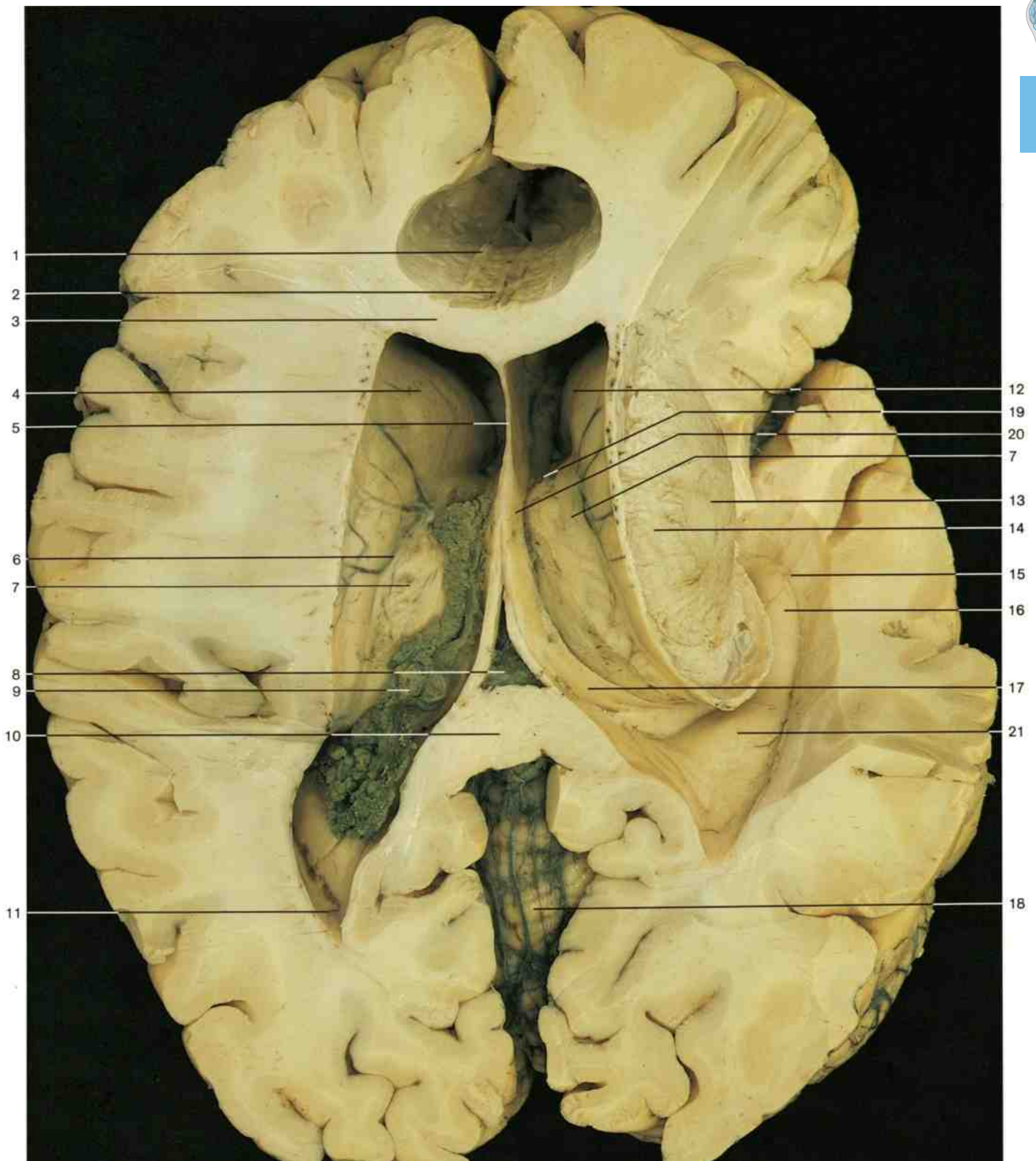
- 1 Lateral longitudinal stria of indusium griseum
- 2 Medial longitudinal stria of indusium griseum
- 3 Cerebellum
- 4 Radiating fibers of the corpus callosum
- 5 Forceps minor of corpus callosum
- 6 Forceps major of corpus callosum
- 7 Splenium of corpus callosum

Dissection of the brain I. The fiber system of the corpus callosum has been displayed by removing the cortex lying above it. Frontal pole at the top.



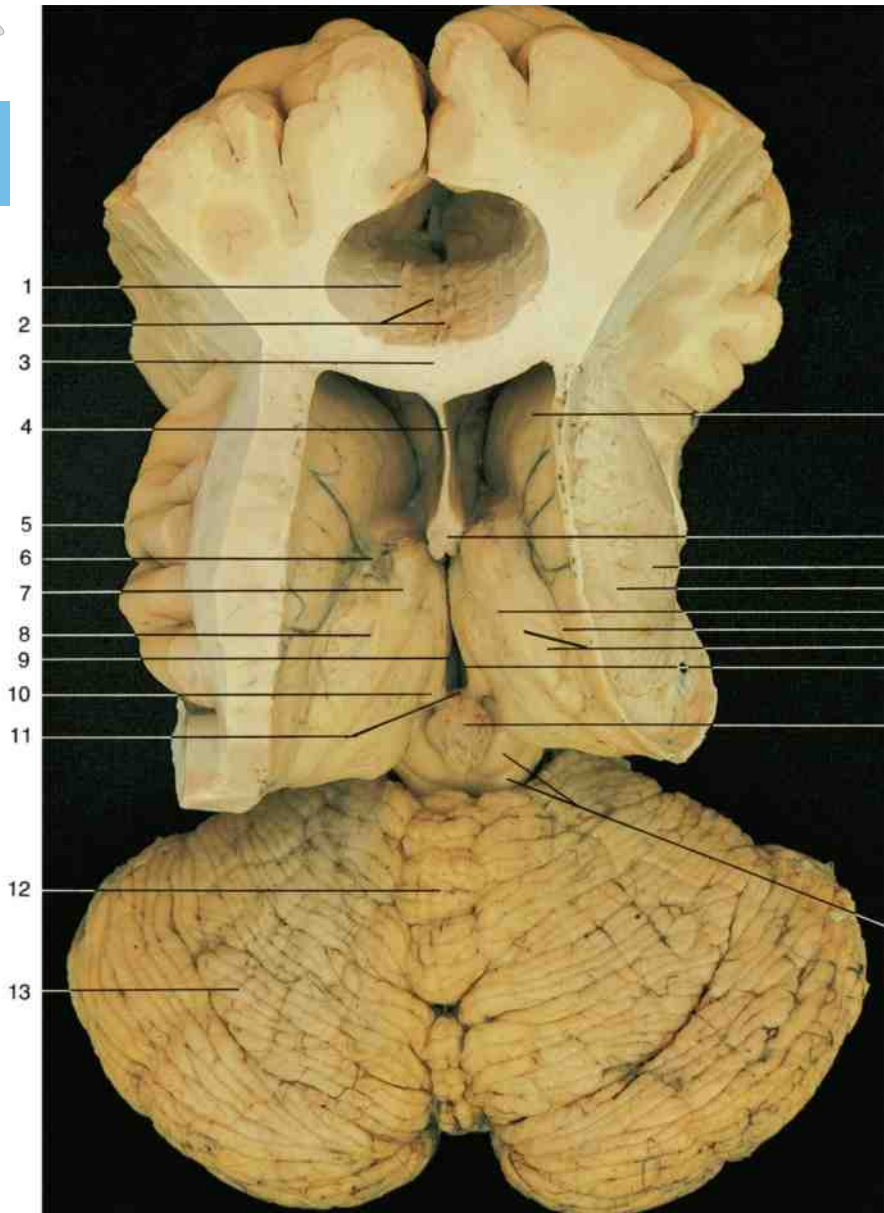
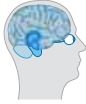- 1 Longitudinal cerebral fissure
- 2 Genu of corpus callosum
- 3 Head of caudate nucleus and anterior horn of lateral ventricle
- 4 Cavum of septum pellucidum
- 5 Septum pellucidum
- 6 Stria terminalis
- 7 Choroid plexus of lateral ventricle
- 8 Splenium of corpus callosum
- 9 Calcar avis
- 10 Posterior horn of lateral ventricle
- 11 Thalamus (lamina affixa)
- 12 Commissure of fornix
- 13 Vermis of cerebellum

Dissection of the brain II. The lateral ventricles and subcortical nuclei of the brain are dissected. The corpus callosum has been partly removed. Frontal pole at the top.



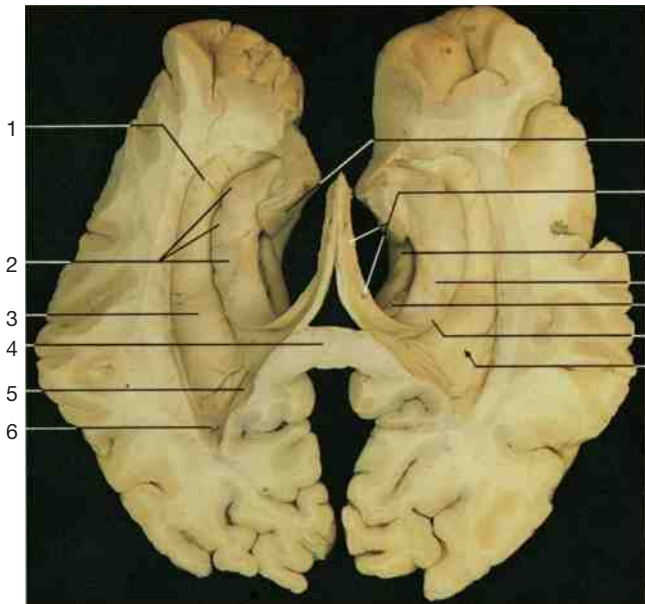
Dissection of the brain III (superior view of lateral ventricle and subcortical nuclei of the brain). Corpus callosum partly removed. At right, the entire lateral ventricle has been opened, the insula with claustrum and the extreme and external capsules have been removed, exposing the lentiform nucleus and the internal capsule.

- | | | |
|-------------------------------------|---|--|
| 1 Lateral longitudinal stria | 9 Choroid plexus of lateral ventricle | 16 Pes hippocampi |
| 2 Medial longitudinal stria | 10 Splenium of corpus callosum | 17 Crus of fornix |
| 3 Genu of corpus callosum | 11 Posterior horn of lateral ventricle | 18 Vermis of cerebellum with arachnoid and pia mater |
| 4 Head of caudate nucleus | 12 Anterior horn of lateral ventricle (head of caudate nucleus) | 19 Interventricular foramen |
| 5 Septum pellucidum | 13 Putamen of lentiform nucleus | 20 Right column of fornix |
| 6 Stria terminalis | 14 Internal capsule | 21 Collateral eminence |
| 7 Thalamus (lamina affixa) | 15 Inferior horn of lateral ventricle | |
| 8 Choroid plexus of third ventricle | | |



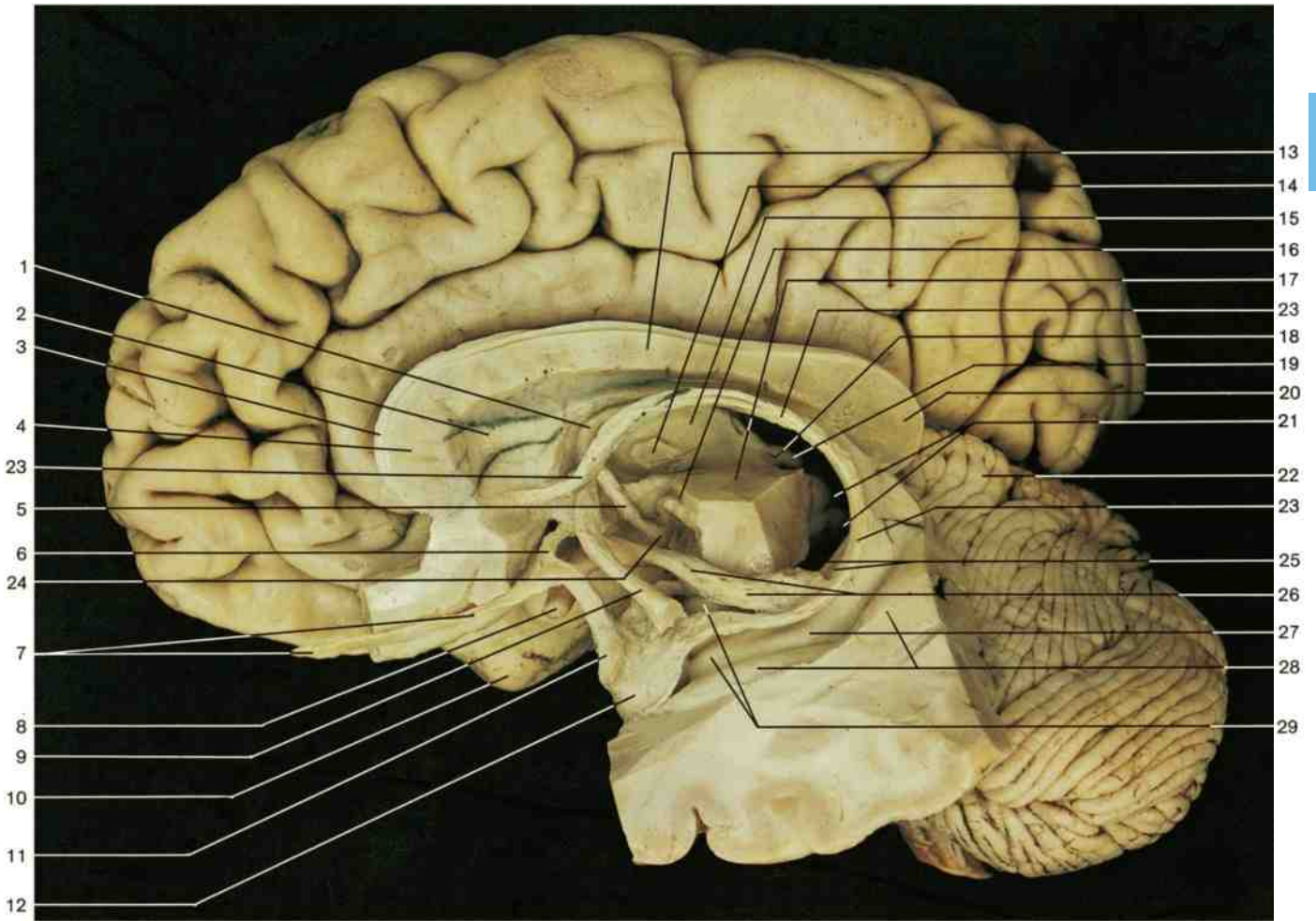
- 1 Lateral longitudinal stria
- 2 Medial longitudinal stria
- 3 Corpus callosum
- 4 Septum pellucidum
- 5 Insular gyri
- 6 Thalamostriate vein
- 7 Anterior tubercle of thalamus
- 8 Thalamus
- 9 Stria medullaris of thalamus
- 10 Habenular trigone
- 11 Habenular commissure
- 12 Vermis of cerebellum
- 13 Left hemisphere of cerebellum
- 14 Head of caudate nucleus
- 15 Columns of fornix
- 16 Putamen of lentiform nucleus
- 17 Internal capsule
- 18 Taenia of choroid plexus
- 19 Stria terminalis and thalamostriate vein
- 20 Lamina affixa
- 21 Third ventricle
- 22 Pineal body
- 23 Superior and inferior colliculus of midbrain

Dissection of the brain IVa. Temporal lobe, fornix, and the posterior corpus callosum have been removed (this part of the specimen is depicted below). Frontal pole at top (superior aspect).

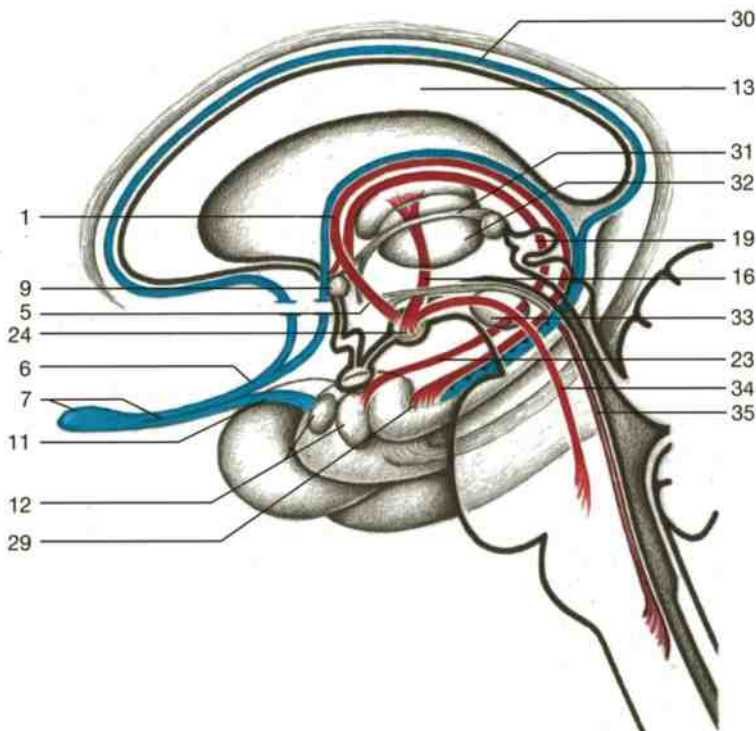


- 1 Inferior horn of lateral ventricle
- 2 Hippocampal digitations
- 3 Collateral eminence
- 4 Splenium of corpus callosum
- 5 Calcar avis
- 6 Posterior horn of lateral ventricle
- 7 Uncus of parahippocampal gyrus
- 8 Body and crus of fornix
- 9 Parahippocampal gyrus
- 10 Pes hippocampi
- 11 Dentate gyrus
- 12 Hippocampal fimbria
- 13 Lateral ventricle

Dissection of the brain IVb. Depicted is the portion of the brain removed from the specimen above. **Temporal lobe and limbic system** (superior aspect). Columns of fornix are cut.

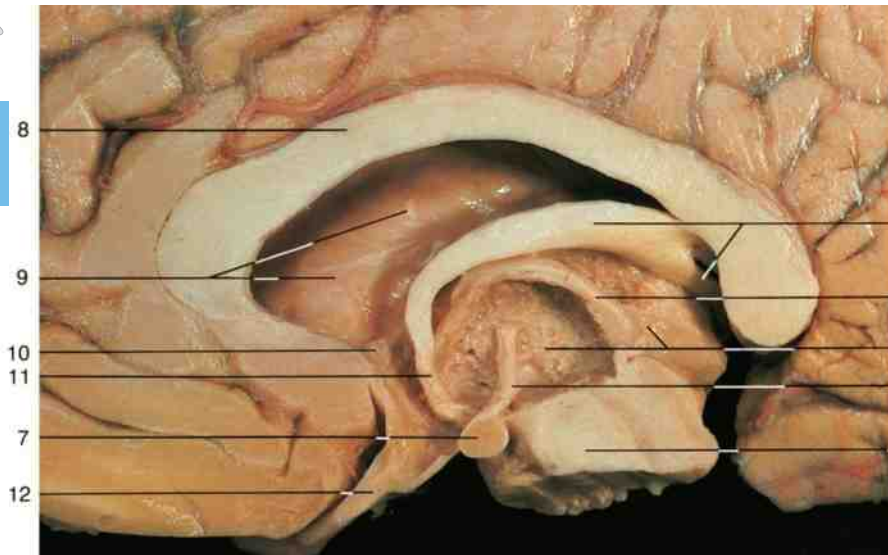
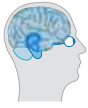

Dissection of the limbic system. Left side, lateral aspect. Corpus callosum has been cut in the median plane. The left thalamus and the left hemisphere have been partly removed.



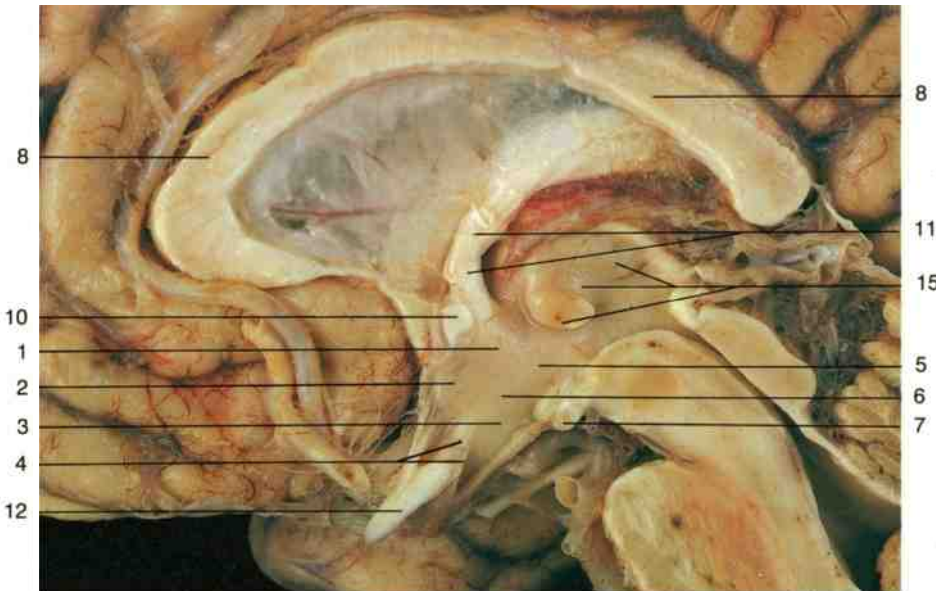
- | | | | |
|----|------------------------------------|----|--|
| 1 | Body of fornix | 21 | Colliculi of midbrain |
| 2 | Septum pellucidum | 22 | Vermis of cerebellum |
| 3 | Lateral longitudinal stria | 23 | Stria terminalis |
| 4 | Genu of corpus callosum | 24 | Mamillary body |
| 5 | Column of fornix | 25 | Fimbria of hippocampus and pes hippocampi |
| 6 | Medial olfactory stria | 26 | Left optic tract and lateral geniculate body |
| 7 | Olfactory bulb and olfactory tract | 27 | Lateral ventricle and parahippocampal gyrus |
| 8 | Optic nerve | 28 | Collateral eminence |
| 9 | Anterior commissure (left half) | 29 | Hippocampal digitations |
| 10 | Right temporal lobe | 30 | Supracallosal gyrus (longitudinal stria) |
| 11 | Lateral olfactory stria | 31 | Stria medullaris of thalamus |
| 12 | Amygdala | 32 | Thalamus |
| 13 | Body of corpus callosum | 33 | Red nucleus |
| 14 | Interthalamic adhesion | 34 | Mamillotegmental fasciculus |
| 15 | Third ventricle and right thalamus | 35 | Dorsal longitudinal fasciculus (Schütz) |
| 16 | Mamillothalamic fasciculus | | |
| 17 | Part of the thalamus | | |
| 18 | Habenular commissure | | |
| 19 | Pineal body | | |
| 20 | Splenium of corpus callosum | | |

Main pathways of limbic and olfactory system (schematic drawing). Blue = afferent pathways; red = efferent pathways.

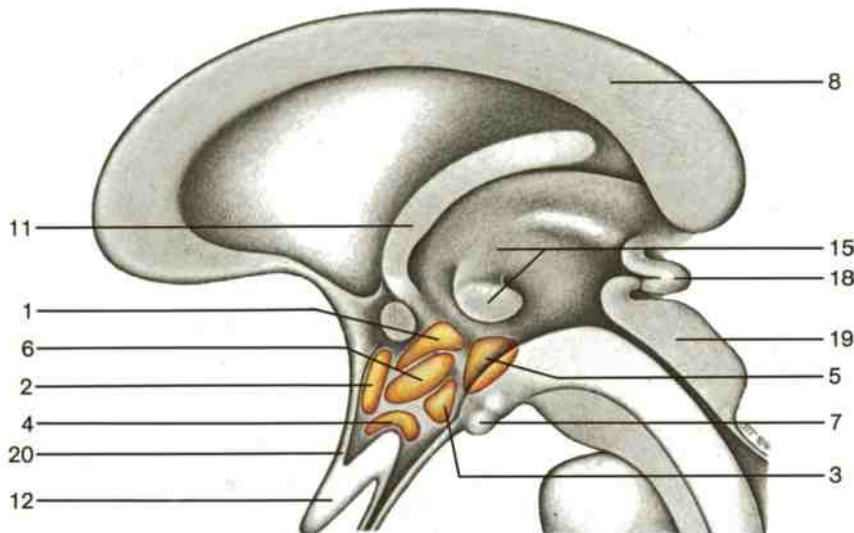


- 1 Paraventricular nucleus
- 2 Pre-optic nucleus
- 3 Ventromedial nucleus
- 4 Supra-optic nucleus
- 5 Posterior nucleus
- 6 Dorsomedial nucleus
- 7 Mamillary body
- 8 Corpus callosum
- 9 Lateral ventricle (showing caudate nucleus)
- 10 Anterior commissure
- 11 Column of fornix
- 12 Optic chiasma
- 13 Crus of fornix
- 14 Stria medullaris of thalamus
- 15 Thalamus and interthalamic adhesion
- 16 Mamillothalamic fasciculus of Vicq d'Azyr
- 17 Cerebral peduncle
- 18 Pineal body
- 19 Tectum of midbrain
- 20 Lamina terminalis

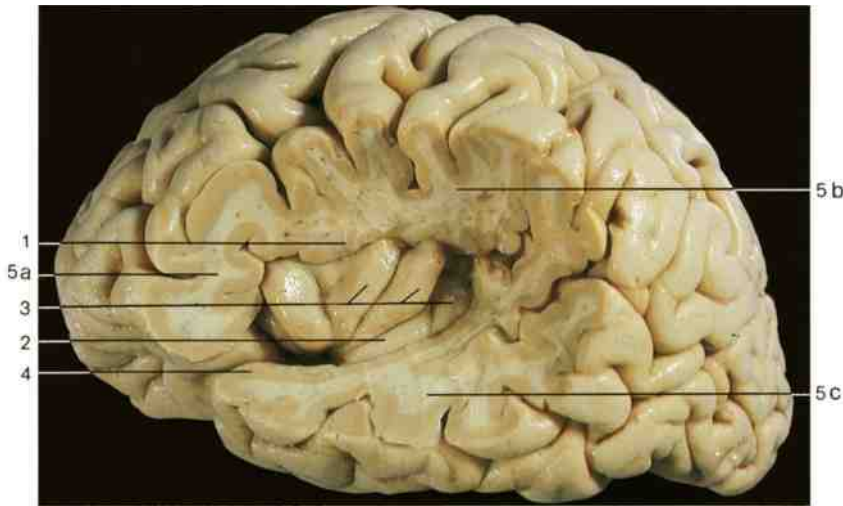
Median section through the diencephalon. Medial part of the thalamus and septum pellucidum have been removed to show the fornix and mamillothalamic fasciculus.



Median section through the diencephalon and midbrain; location of hypothalamic nuclei.

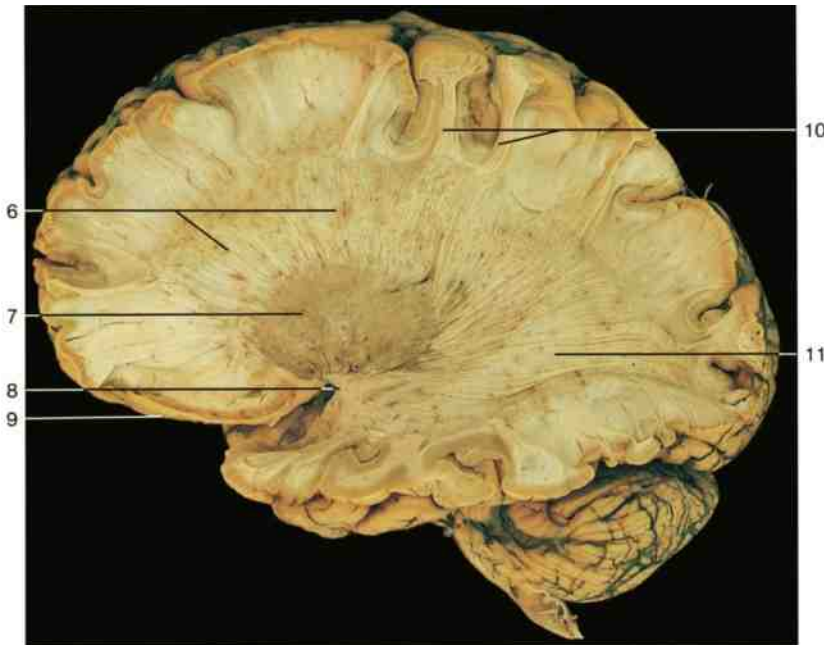


Position of main hypothalamic nuclei (schematic drawing).

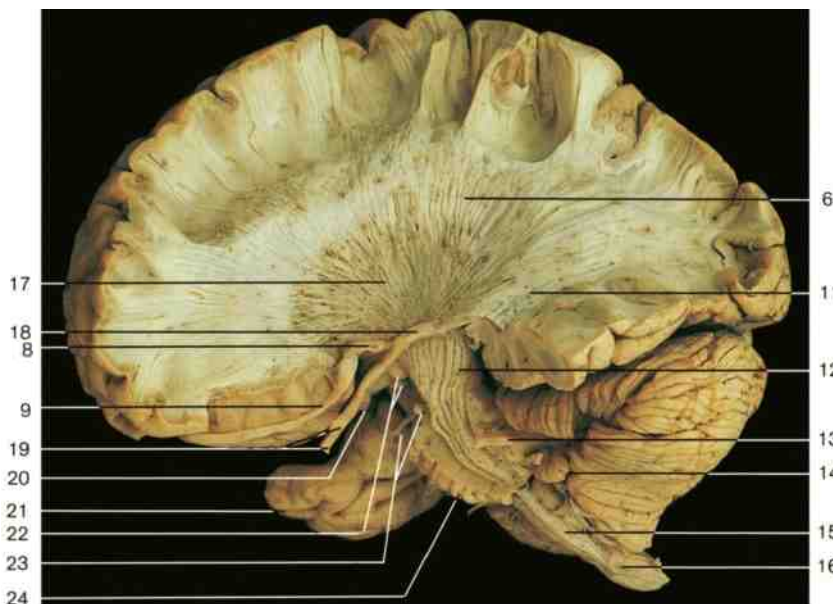


Insula (Reili). The opercula of the frontal, parietal, and temporal lobes have been removed to display the insular gyri. Left hemisphere.

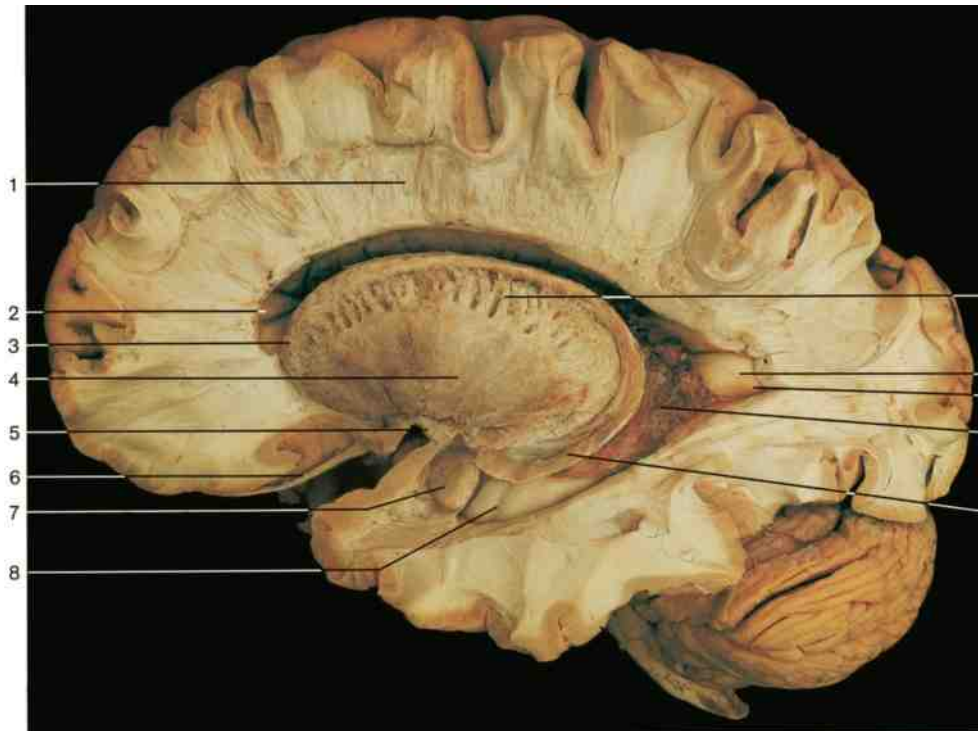
- 1 Circular sulcus of insula
- 2 Long gyrus of insula
- 3 Short gyri of insula
- 4 Limen insulae
- 5 Opercula (cut)
 - a Frontal operculum
 - b Frontoparietal operculum
 - c Temporal operculum
- 6 Corona radiata
- 7 Lentiform nucleus
- 8 Anterior commissure
- 9 Olfactory tract
- 10 Cerebral arcuate fibers
- 11 Optic radiation
- 12 Cerebral peduncle
- 13 Trigeminal nerve (n. V)
- 14 Flocculus of cerebellum
- 15 Pyramidal tract
- 16 Decussation of pyramidal tract
- 17 Internal capsule
- 18 Optic tract
- 19 Optic nerve (n. II)
- 20 Infundibulum
- 21 Temporal lobe (right side)
- 22 Mamillary bodies
- 23 Oculomotor nerve (n. III)
- 24 Transverse fibers of pons



Dissection of the corona radiata, left hemisphere. Frontal pole on the left.

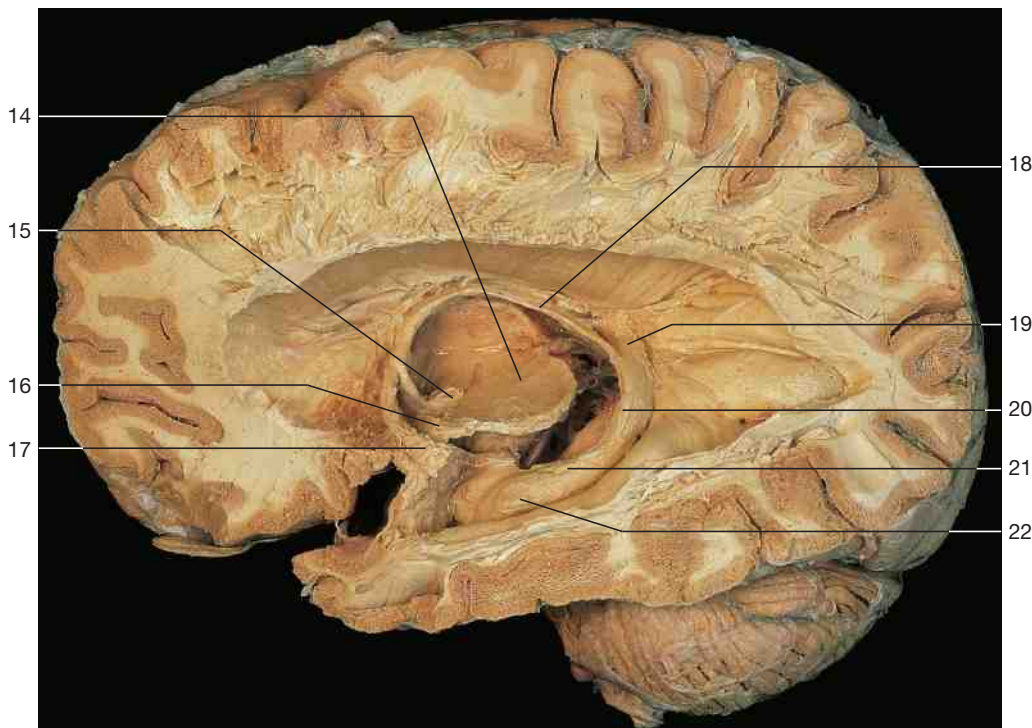


◁ **Corona radiata and internal capsule,** left hemisphere. Lentiform nucleus removed (frontal pole to the left).

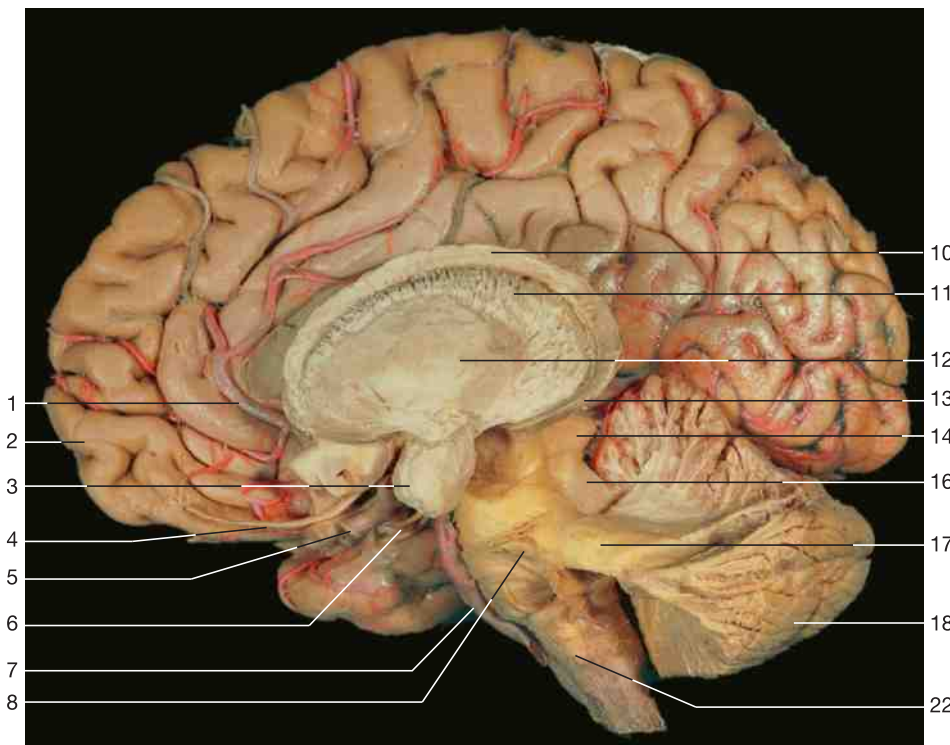


- 1 Corona radiata
- 2 Anterior horn of lateral ventricle
- 3 Head of caudate nucleus
- 4 Putamen
- 5 Anterior commissure
- 6 Olfactory tract
- 7 Amygdala
- 8 Hippocampal digitations
- 9 Internal capsule
- 10 Calcar avis
- 11 Posterior horn of lateral ventricle
- 12 Choroid plexus of lateral ventricle
- 13 Caudal extremity of caudate nucleus
- 14 Pulvinar of thalamus
- 15 Mamillary body
- 16 Optic tract
- 17 Anterior commissure
- 18 Fornix
- 19 Longitudinal stria
- 20 Dentate gyrus
- 21 Hippocampal fimbria
- 22 Pes hippocampi

Dissection of the subcortical nuclei and internal capsule, left hemisphere (lateral aspect). Frontal pole to the left. The lateral ventricle has been opened, and the insular gyri and claustrum have been removed, revealing the lentiform nucleus and the internal capsule.

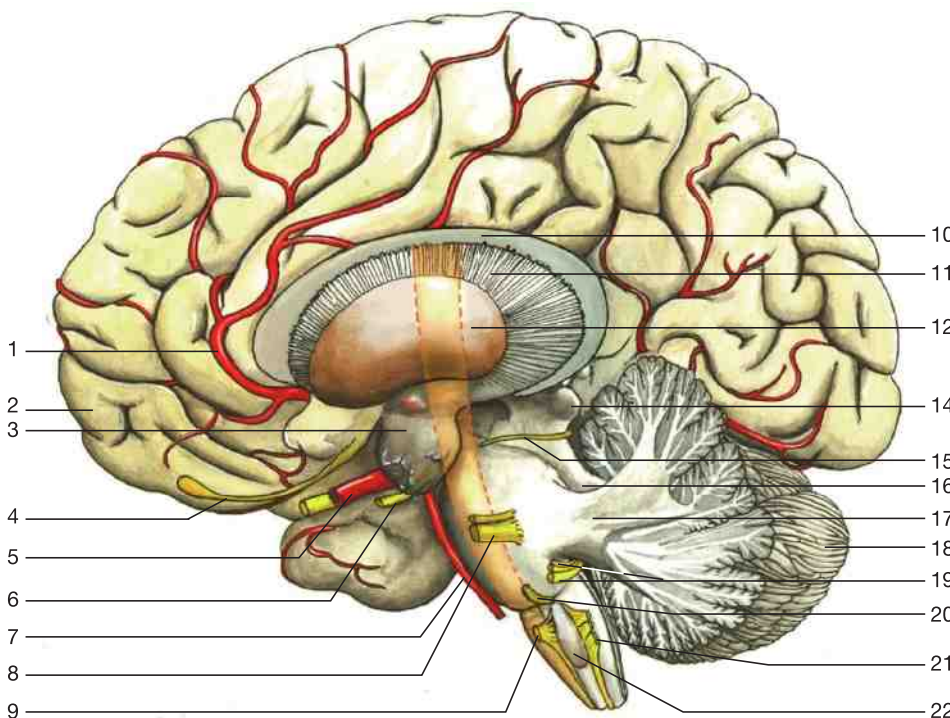


Dissection of the limbic system and the fornix (lateral aspect). Frontal pole to the left.

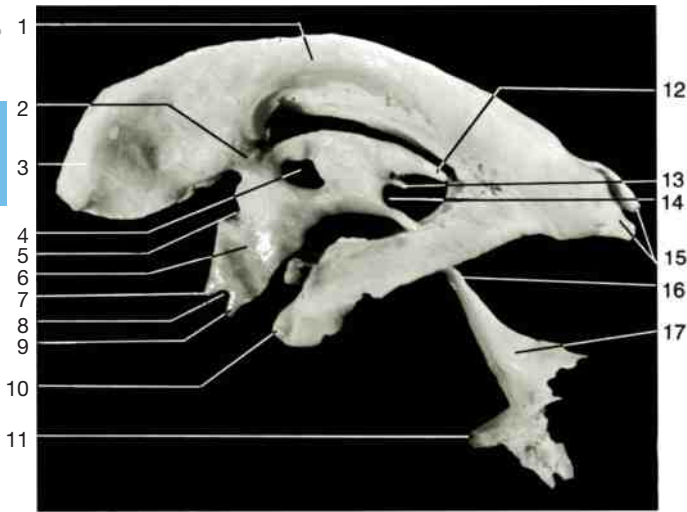
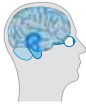

- 1 Anterior cerebral artery
- 2 Frontal lobe
- 3 Amygdala (amygdaloid body)
- 4 Olfactory tract
- 5 Internal carotid artery
- 6 Oculomotor nerve (n. III)
- 7 Basilar artery
- 8 Trigeminal nerve (n. V)
- 9 Hypoglossal nerve (n. XII)
- 10 Caudate nucleus
- 11 Internal capsule
- 12 Lentiform nucleus
- 13 Caudal extremity of caudate nucleus
- 14 Inferior colliculus of midbrain
- 15 Trochlear nerve (n. IV)
- 16 Superior cerebellar peduncle
- 17 Middle cerebellar peduncle
- 18 Cerebellum
- 19 Facial nerve (n. VII) and vestibulocochlear nerve (n. VIII)
- 20 Abducent nerve (n. VI)
- 21 Glossopharyngeal nerve (n. IX), vagus nerve (n. X), and accessory nerve (n. XI)
- 22 Inferior olive

Right hemisphere together with brain stem and cerebellum (lateral aspect).
The connections of the brain stem with the cerebellum are dissected. The amygdala of the left hemisphere is shown. The corpus callosum has been partly removed.

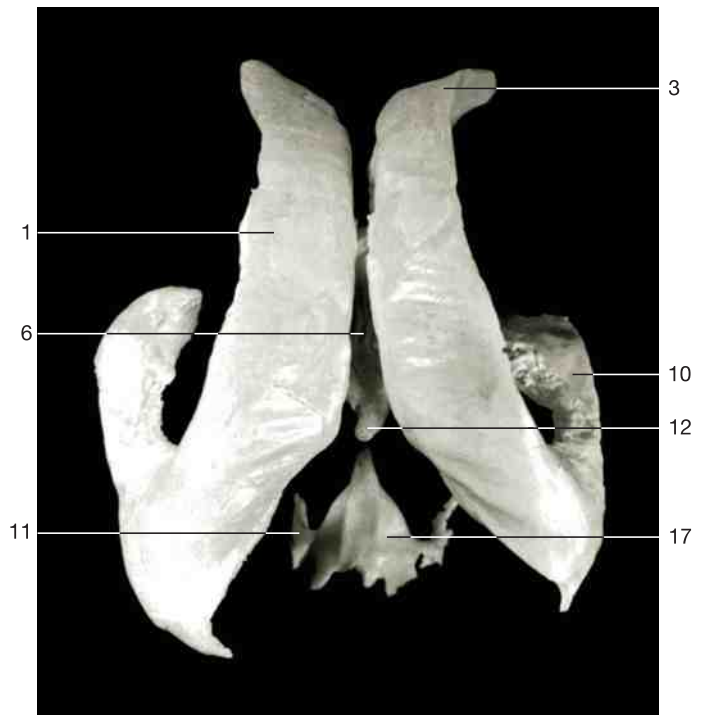


Schematic drawing of the dissected brain shown above (lateral aspect).
The course of the pyramidal tracts is indicated in red. Cranial nerves = yellow.



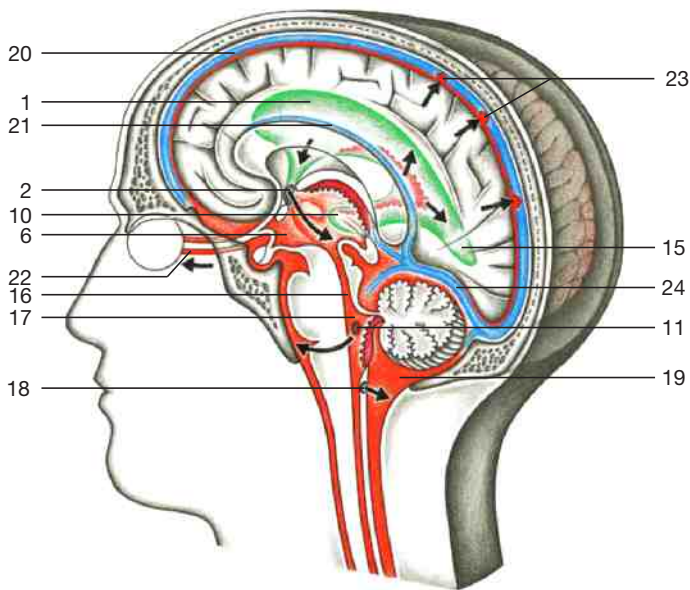
Cast of ventricular cavities of the brain (lateral aspect), frontal pole to the left.

- 1 Central part of the lateral ventricle
- 2 Interventricular foramen of Monro
- 3 Anterior horn of the lateral ventricle
- 4 Site of interthalamic adhesion
- 5 Notch for anterior commissure
- 6 Third ventricle
- 7 Optic recess
- 8 Notch for optic chiasma
- 9 Infundibular recess
- 10 Inferior horn of lateral ventricle with indentation of amygdaloid body
- 11 Lateral recess and lateral aperture of Luschka
- 12 Suprapineal recess
- 13 Pineal recess
- 14 Notch for posterior commissure
- 15 Posterior horn of lateral ventricle
- 16 Cerebral aqueduct

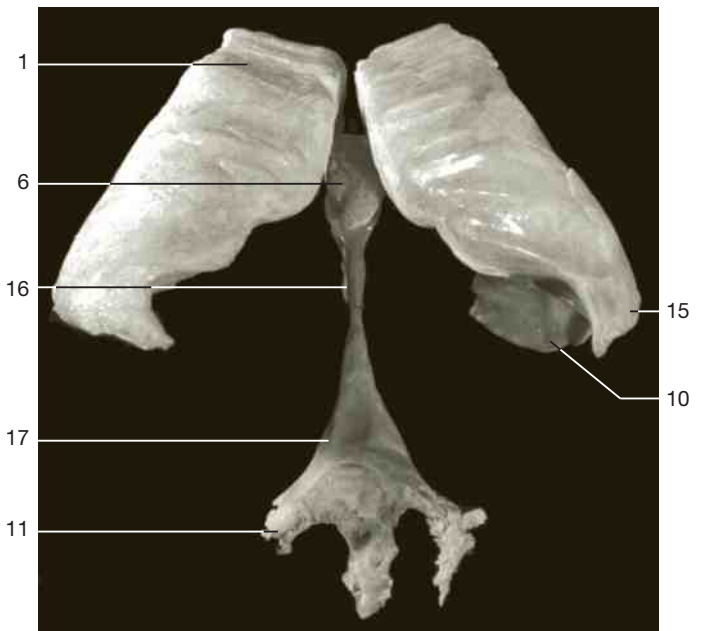


Cast of ventricular cavities of the brain (superior aspect), frontal pole at top.

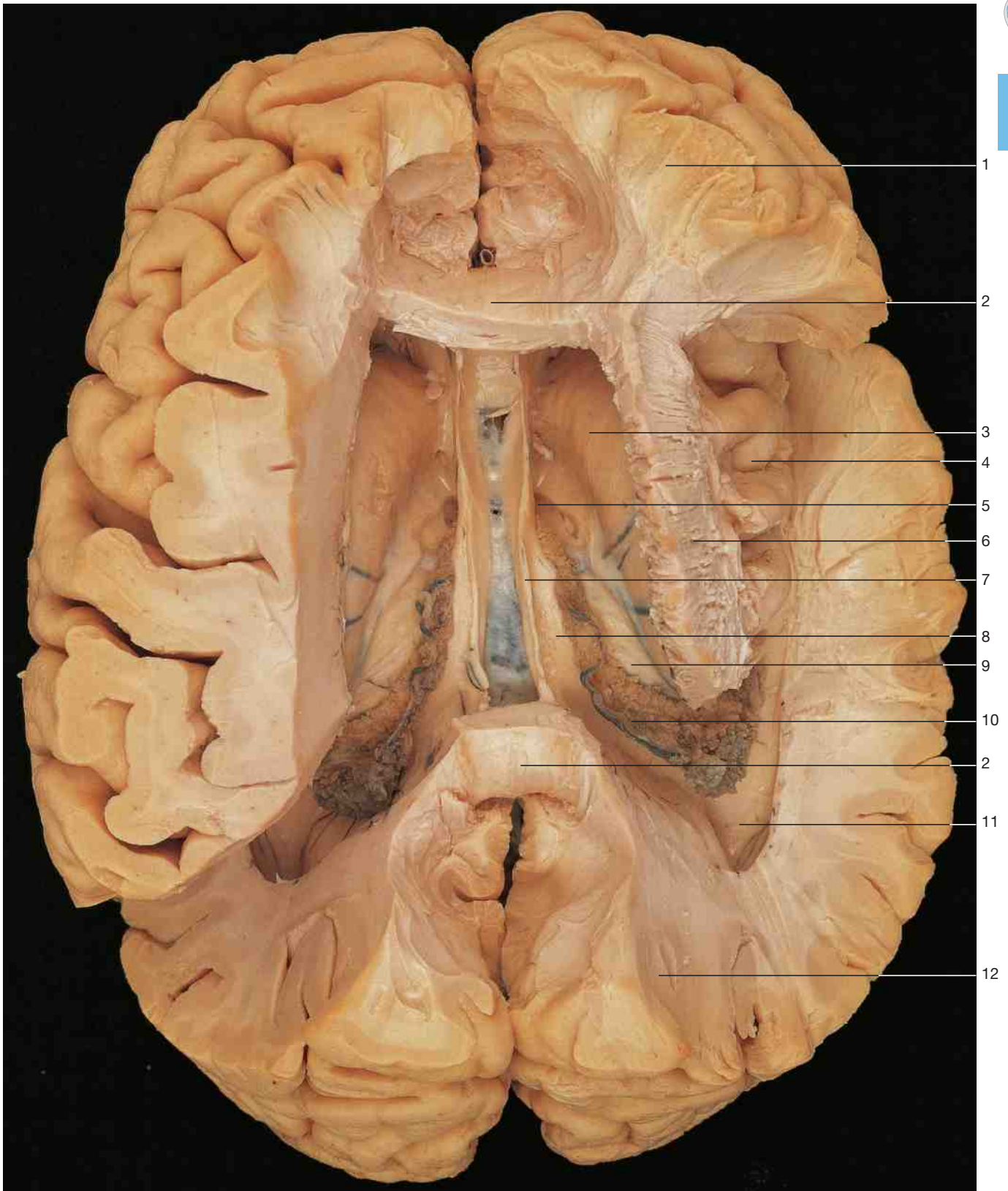
- 17 Fourth ventricle
- 18 Median aperture of Magendie
- 19 Cerebellomedullary cistern
- 20 Superior sagittal sinus
- 21 Inferior sagittal sinus
- 22 Intervaginal space of optic nerve
- 23 Arachnoid granulations of Pacchioni
- 24 Straight sinus



Position of ventricular cavities (schematic drawing). The direction of flow of cerebrospinal fluid is indicated by arrows. Green = right lateral ventricle; red = choroidal plexus with cerebrospinal fluid.

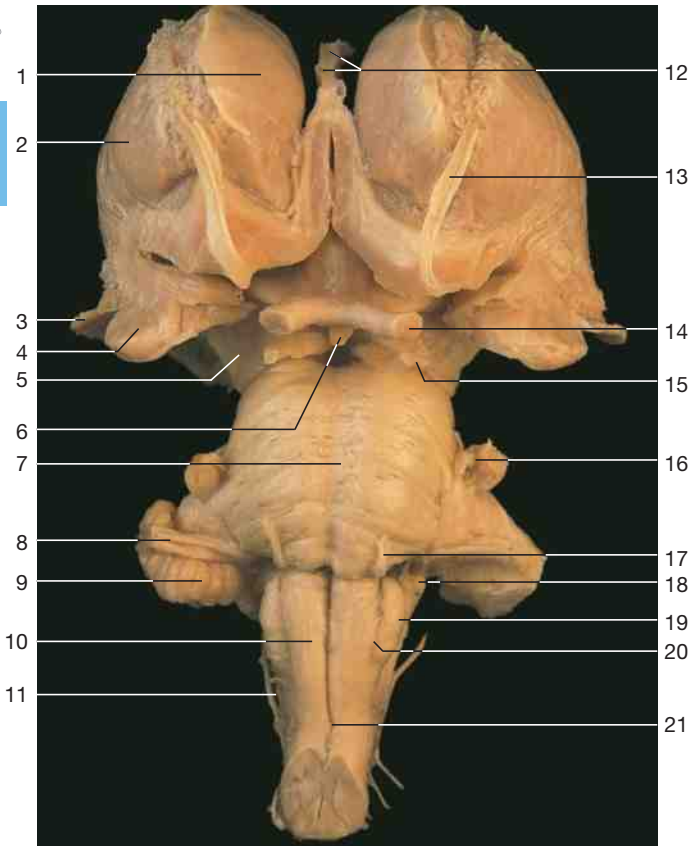


Cast of ventricular cavities of the brain (posterior aspect).



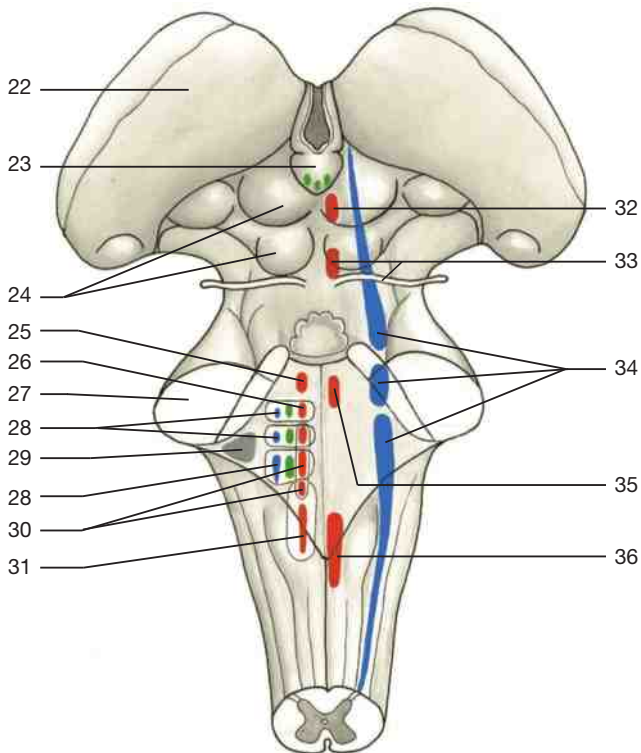
Dissection of the brain (superior view of the lateral ventricle and of the subcortical nuclei of the brain). Corpus callosum partly removed. Fornix and choroid plexus of the left lateral ventricle are shown.

- | | |
|----------------------------|---------------------------------------|
| 1 Frontal lobe of brain | 7 Lateral longitudinal stria |
| 2 Corpus callosum | 8 Body of fornix |
| 3 Caudate nucleus (head) | 9 Thalamus |
| 4 Insular cortex | 10 Choroid plexus |
| 5 Interventricular foramen | 11 Lateral ventricle (occipital horn) |
| 6 Internal capsule | 12 Occipital lobe of brain |

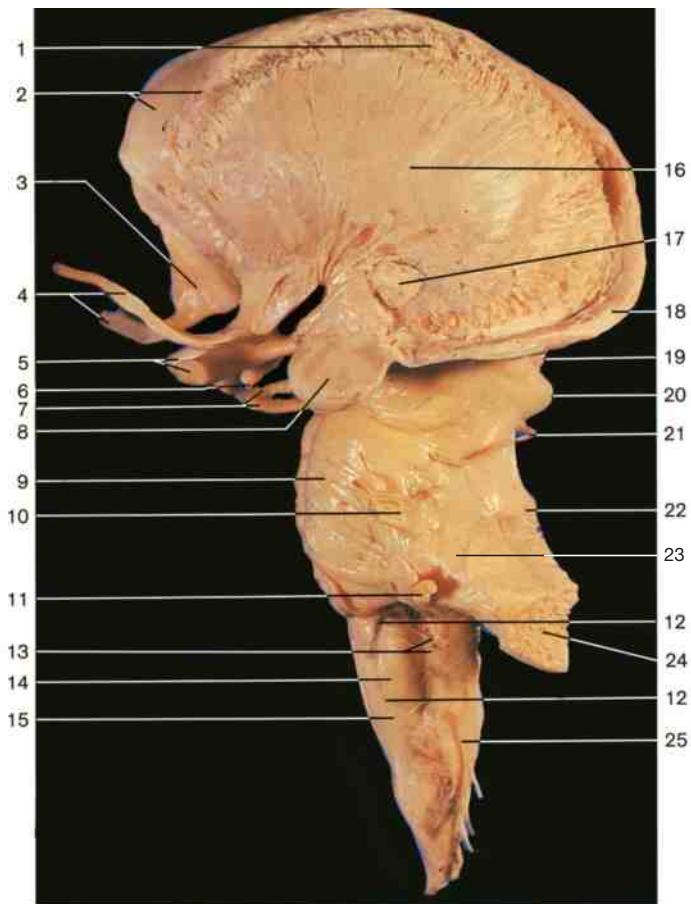
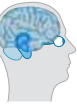

Brain stem (ventral aspect).

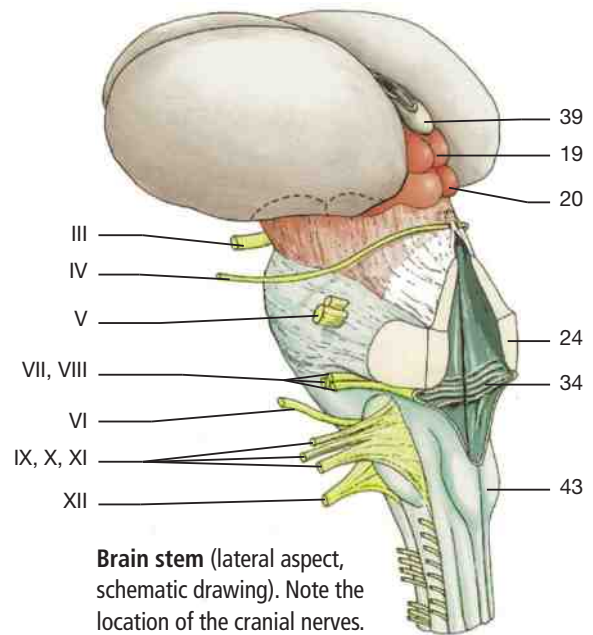
- 1 Caudate nucleus
- 2 Lentiform nucleus
- 3 Caudal extremity of caudate nucleus
- 4 Amygdaloid body
- 5 Cerebral peduncle
- 6 Infundibulum
- 7 Pons
- 8 Facial nerve (n. VII) and vestibulocochlear nerve (n. VIII)
- 9 Cerebellar flocculus
- 10 Medulla oblongata
- 11 Accessory nerve (n. XI)
- 12 Fornix and column of fornix
- 13 Olfactory tract
- 14 Optic nerve (n. II)
- 15 Oculomotor nerve (n. III)
- 16 Trigeminal nerve (n. V)
- 17 Abducent nerve (n. VI)
- 18 Glossopharyngeal nerve (n. IX) and vagus nerve (n. X)
- 19 Inferior olive
- 20 Hypoglossal nerve (n. XII)
- 21 Decussation of the pyramids
- 22 Thalamus
- 23 Epiphysis
- 24 Tectum of midbrain (superior and inferior colliculus)
- 25 Motor nucleus of trigeminal nerve (n. V)
- 26 Facial nucleus (n. VII)
- 27 Middle cerebellar peduncle
- 28 Visceral nucleus of glossopharyngeal and vagus nerves (n. IX and n. X), salivatory nucleus
- 29 Vestibular nucleus (n. VIII)
- 30 Ambiguous nucleus (n. IX, n. X, n. XI)
- 31 Spinal nucleus of accessory nerve (n. XI)
- 32 Motor nucleus of oculomotor nerve (n. III)
- 33 Trochlear nucleus and nerve (n. IV)
- 34 Sensory nucleus of trigeminal nerve (n. V)
- 35 Abducent nucleus (n. VI)
- 36 Hypoglossal nucleus (n. XII)



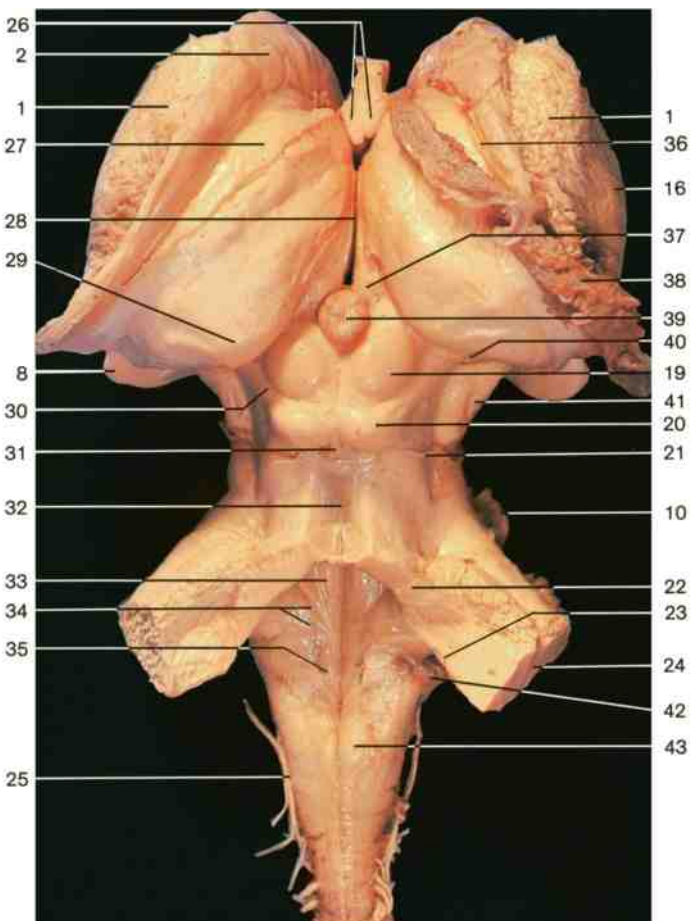
Brain stem (dorsal aspect, schematic drawing).
Location of cranial nerve nuclei.



Brain stem (left lateral aspect). Cerebellar peduncles have been severed, cerebellum and cerebral cortex have been removed.

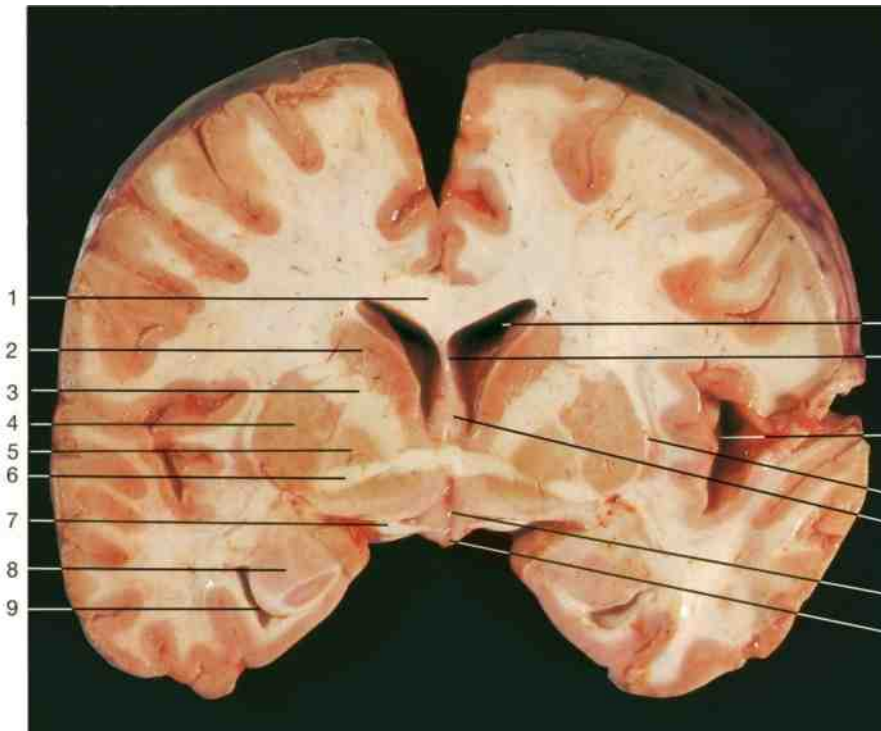


Brain stem (lateral aspect, schematic drawing). Note the location of the cranial nerves. III–XII = cranial nerves.



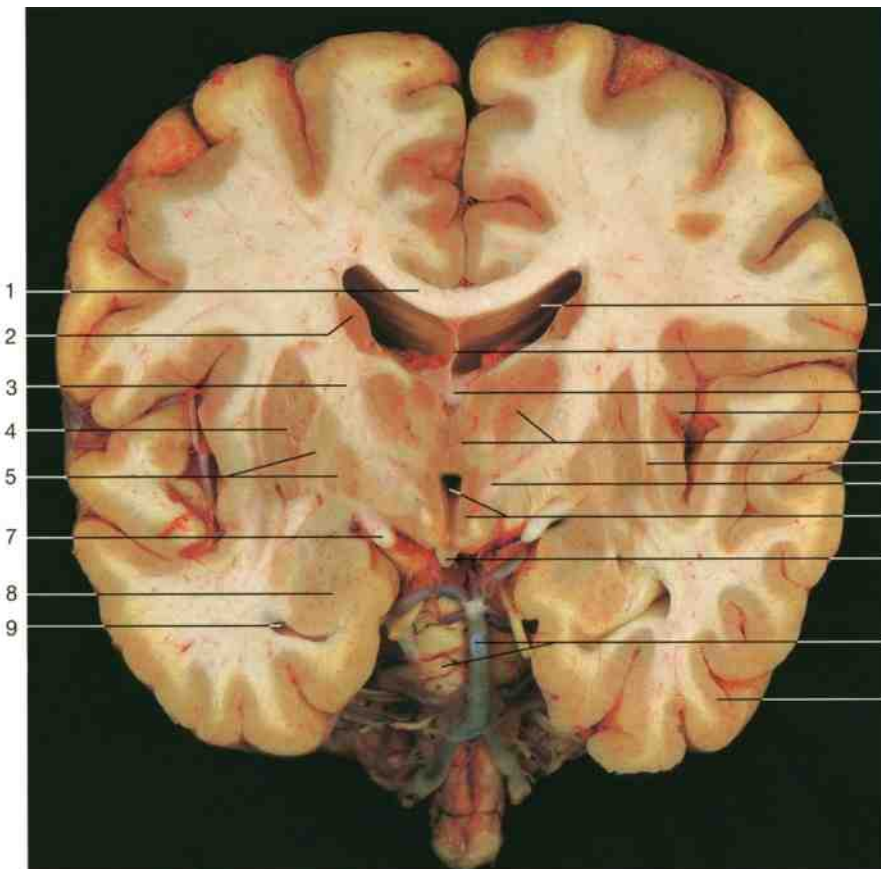
Brain stem (dorsal aspect). Cerebellum removed.

- 1 Internal capsule
- 2 Head of the caudate nucleus
- 3 Olfactory trigone
- 4 Olfactory tracts
- 5 Optic nerves (n. II)
- 6 Infundibulum
- 7 Oculomotor nerve (n. III)
- 8 Amygdaloid body
- 9 Pons
- 10 Trigeminal nerve (n. V)
- 11 Facial and vestibulocochlear nerves (n. VII, n. VIII)
- 12 Hypoglossal nerve (n. XII)
- 13 Glossopharyngeal and vagus nerves (n. IX, n. X)
- 14 Inferior olive
- 15 Medulla oblongata
- 16 Lentiform nucleus
- 17 Anterior commissure
- 18 Tail of caudate nucleus
- 19 Superior colliculus
- 20 Inferior colliculus
- 21 Trochlear nerve (n. IV)
- 22 Superior cerebellar peduncle
- 23 Inferior cerebellar peduncle
- 24 Middle cerebellar peduncle
- 25 Accessory nerve (n. XI)
- 26 Columns of fornix (divided)
- 27 Lamina affixa
- 28 Third ventricle
- 29 Pulvinar of thalamus
- 30 Inferior brachium
- 31 Frenulum veli
- 32 Superior medullary velum
- 33 Facial colliculus
- 34 Striae medullares and rhomboid fossa
- 35 Hypoglossal trigone
- 36 Stria terminalis and thalamostriate vein
- 37 Habenular trigone
- 38 Choroid plexus of lateral ventricle
- 39 Pineal body
- 40 Medial geniculate body
- 41 Cerebral peduncle
- 42 Choroid plexus of fourth ventricle
- 43 Clava



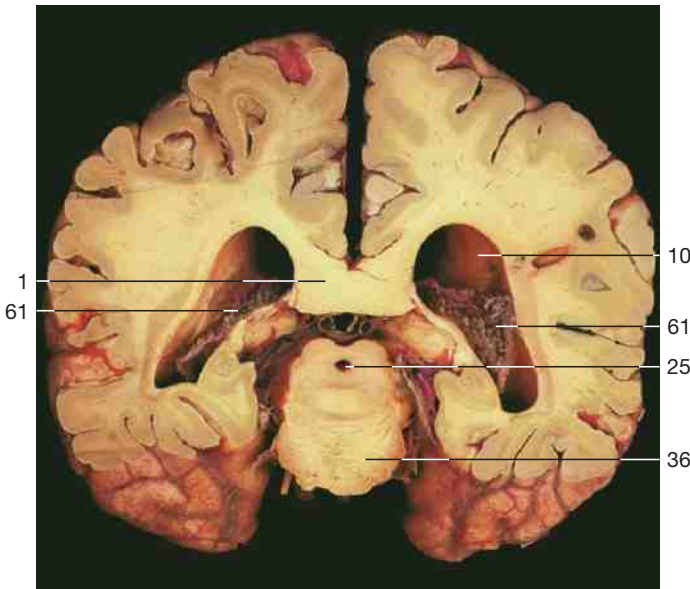
Coronal section through the brain at the level of the anterior commissure. Section 1.

- 1 Corpus callosum
- 2 Head of caudate nucleus
- 3 Internal capsule
- 4 Putamen
- 5 Globus pallidus
- 6 Anterior commissure
- 7 Optic tract
- 8 Amygdaloid body
- 9 Inferior horn of lateral ventricle
- 10 Lateral ventricle
- 11 Septum pellucidum
- 12 Lobus insularis (insula)
- 13 External capsule
- 14 Column of fornix
- 15 Optic recess
- 16 Infundibulum

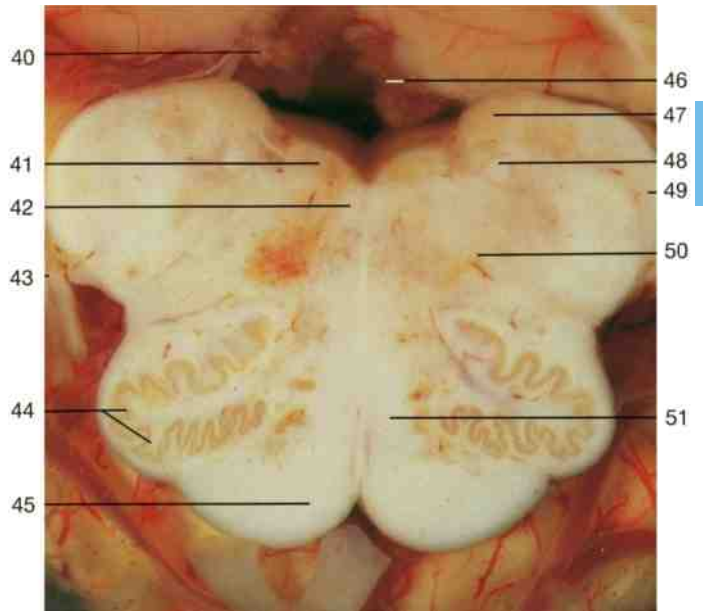


Coronal section through the brain at the level of the third ventricle and the interthalamic adhesion. Section 2.

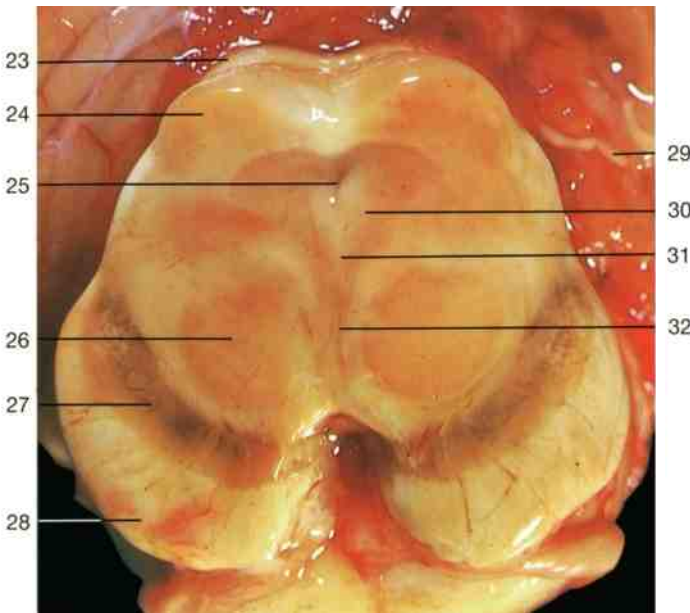
- 17 Thalamus
- 18 Claustrum
- 19 Lenticular ansa
- 20 Third ventricle and hypothalamus
- 21 Basilar artery and pons
- 22 Cortex of temporal lobe
- 23 Inferior colliculus
- 24 Superior colliculus
- 25 Cerebral aqueduct
- 26 Red nucleus
- 27 Substantia nigra
- 28 Cerebral peduncle
- 29 Trochlear nerve (n. IV)
- 30 Gray matter
- 31 Nucleus of oculomotor nerve
- 32 Fibers of oculomotor nerve (n. III)
- 33 Vermis of cerebellum
- 34 Fourth ventricle
- 35 Reticular formation
- 36 Pons and transverse pontine fibers
- 37 Emboliform nucleus
- 38 Dentate nucleus
- 39 Middle cerebellar peduncle
- 40 Choroid plexus
- 41 Hypoglossal nucleus at rhomboid fossa
- 42 Medial longitudinal fasciculus
- 43 Trigeminal nerve (n. V.)
- 44 Inferior olivary nucleus
- 45 Corticospinal fibers and arcuate fibers
- 46 Fourth ventricle with choroid plexus
- 47 Vestibular nuclei
- 48 Nucleus and tractus solitarius
- 49 Inferior cerebellar peduncle (restiform body)
- 50 Reticular formation
- 51 Medial lemniscus
- 52 Cuneate nucleus of Burdach
- 53 Central canal
- 54 Pyramidal tract
- 55 Flocculus of cerebellum
- 56 Cerebellar hemisphere with pia mater
- 57 "Arbor vitae" of cerebellum
- 58 Nucleus gracilis of Goll
- 59 Lateral recess of choroid plexus of fourth ventricle
- 60 Posterior inferior cerebellar artery
- 61 Choroid plexus of lateral ventricle



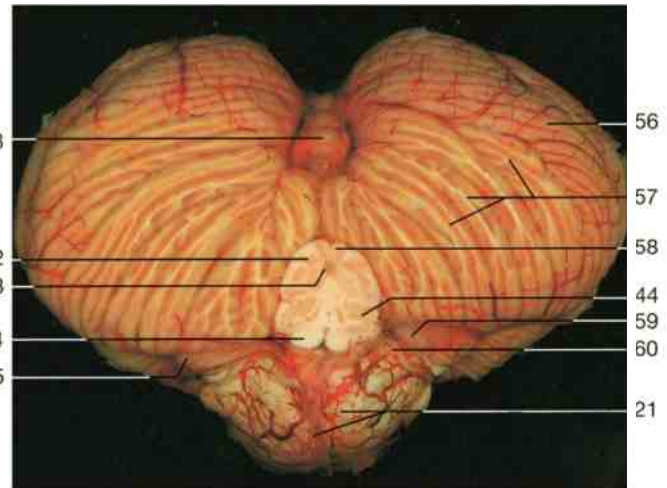
Coronal section through the brain at the level of the inferior colliculus (posterior aspect). Section 3.



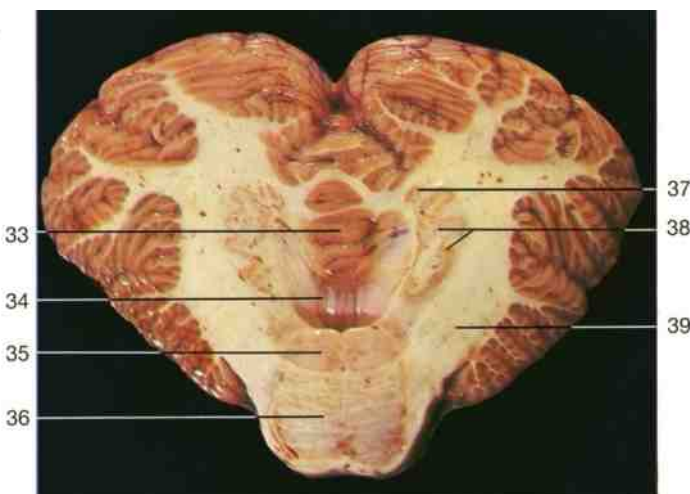
Cross section of the rhombencephalon at the level of the olive (inferior aspect). Section 6.



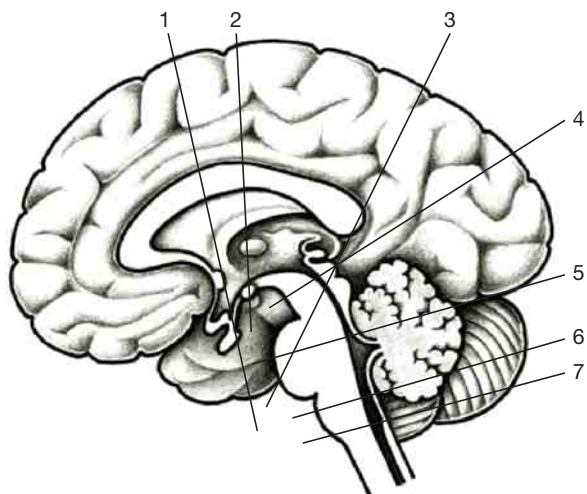
Cross section of the midbrain (mesencephalon) at the level of the superior colliculus (superior aspect). Section 4.



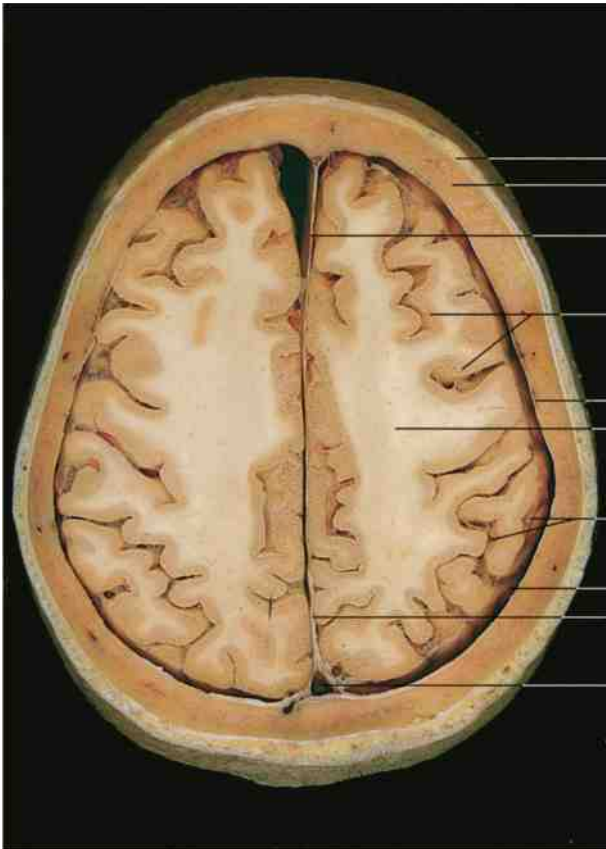
Cross section through medulla oblongata and cerebellum (inferior aspect). Section 7.



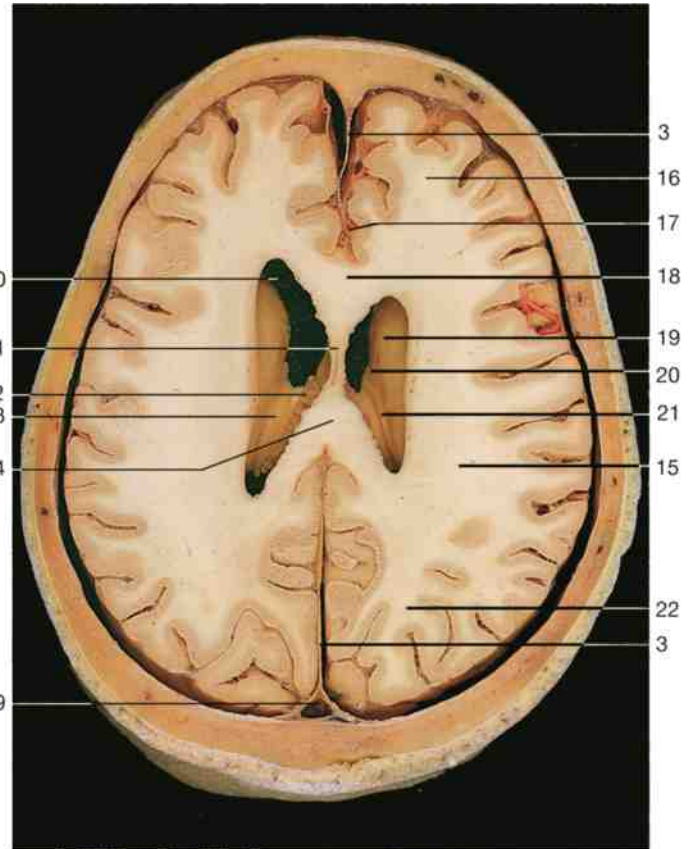
Cross section through the rhombencephalon at the level of the pons (inferior aspect). Section 5.



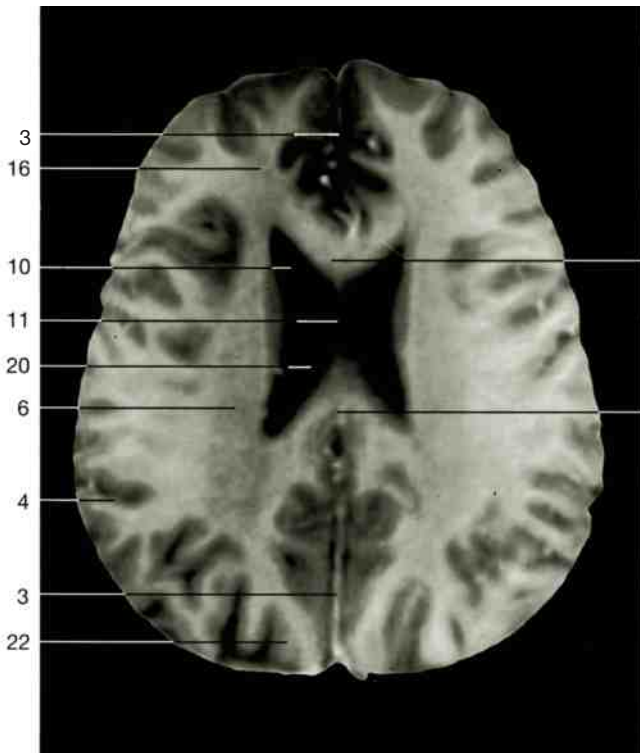
Right half of the brain. Levels of the sections are indicated.



Horizontal section through the head.
Section 1.

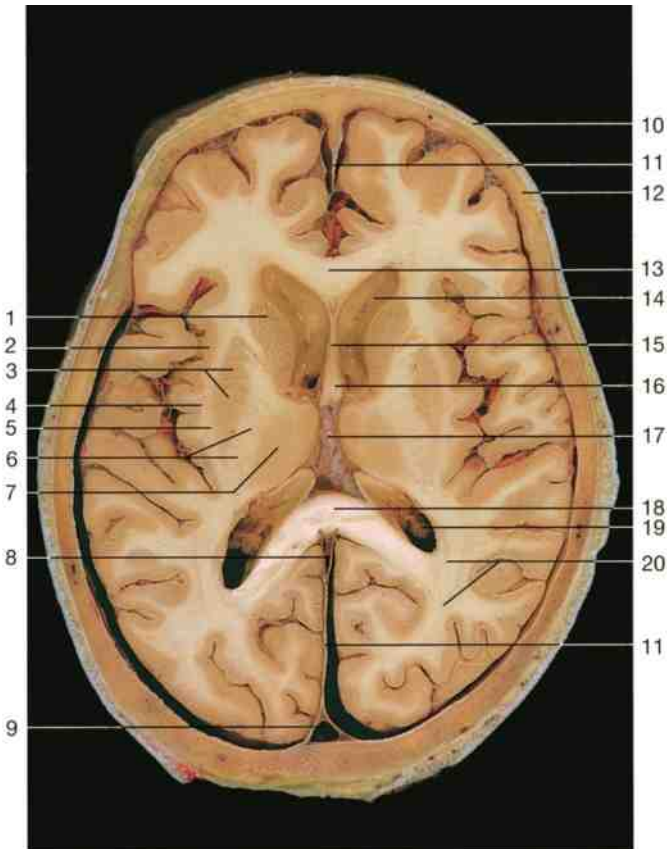


Horizontal section through the head.
Section 2.



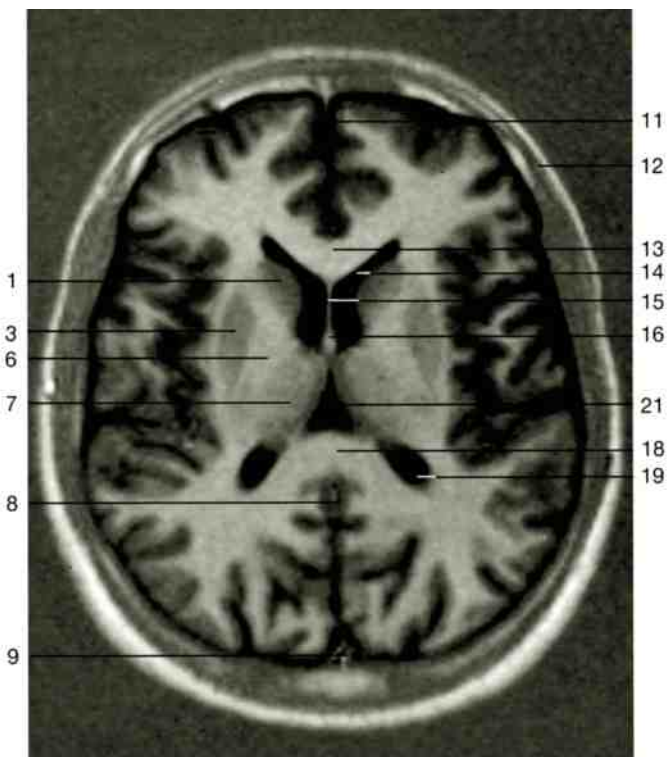
MRI scan of the human head at the level of section 2.

- 1 Skin of scalp
- 2 Calvaria (diploe of the skull)
- 3 Falx cerebri
- 4 Gray matter of brain (cortex)
- 5 Dura mater
- 6 White matter of brain
- 7 Arachnoid and pia mater with vessels
- 8 Subdural space (slightly expanded due to shrinkage of the brain)
- 9 Superior sagittal sinus
- 10 Anterior horn of lateral ventricle
- 11 Septum pellucidum
- 12 Choroid plexus
- 13 Thalamus
- 14 Splenium of corpus callosum
- 15 Parietal lobe
- 16 Frontal lobe
- 17 Anterior cerebral artery
- 18 Genu of corpus callosum
- 19 Caudate nucleus
- 20 Central part of lateral ventricle
- 21 Stria terminalis
- 22 Occipital lobe

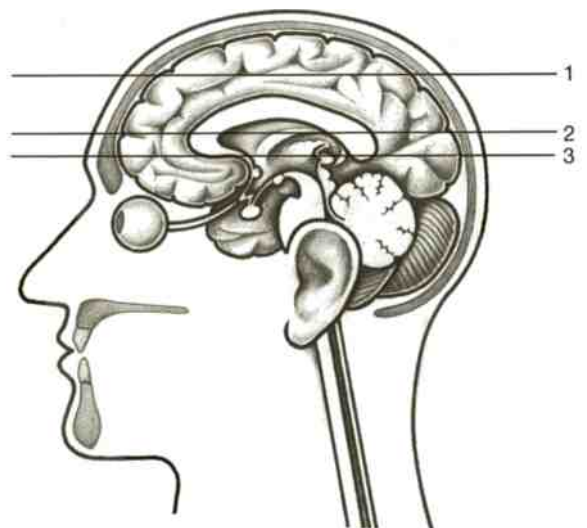


- 1 Caudate nucleus
- 2 Lobus insularis (insula)
- 3 Lentiform nucleus
- 4 Claustrum
- 5 External capsule
- 6 Internal capsule
- 7 Thalamus
- 8 Inferior sagittal sinus
- 9 Superior sagittal sinus
- 10 Skin of scalp
- 11 Falx cerebri
- 12 Calvaria (diploe of skull)
- 13 Genu of corpus callosum
- 14 Anterior horn of lateral ventricle
- 15 Septum pellucidum
- 16 Column of fornix
- 17 Choroid plexus of third ventricle
- 18 Splenium of corpus callosum
- 19 Entrance to inferior horn of lateral ventricle with choroid plexus
- 20 Optic radiation
- 21 Third ventricle

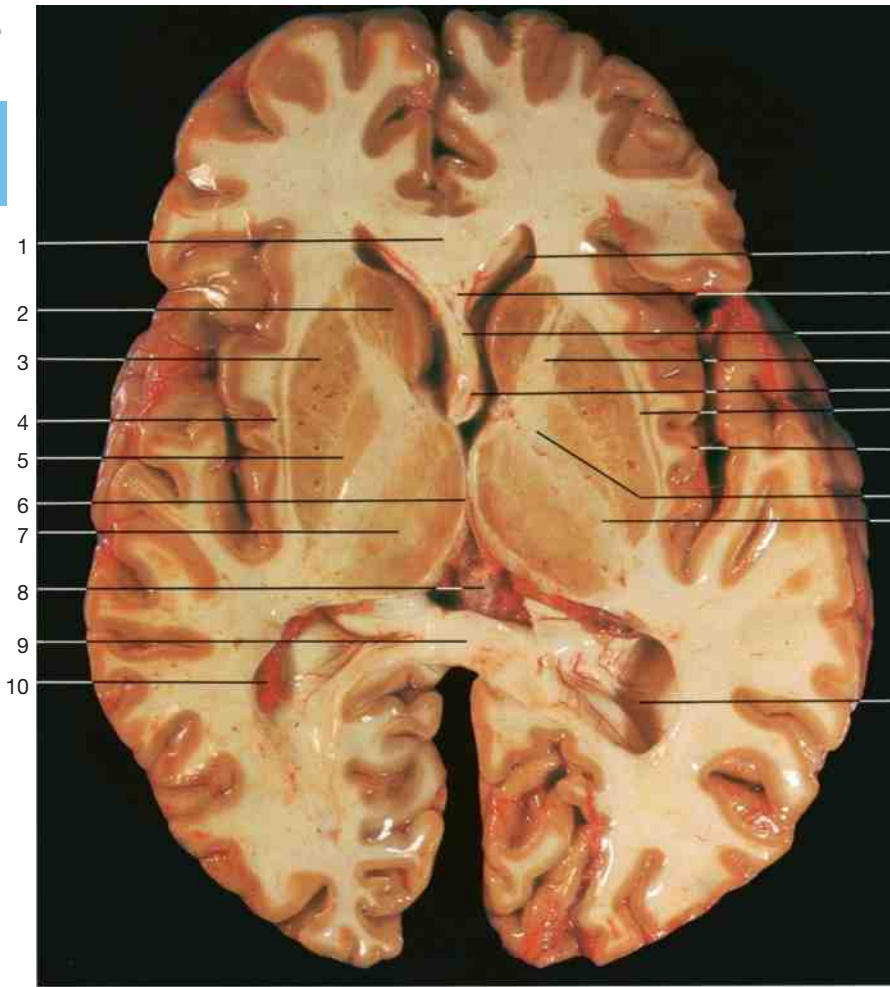
Horizontal section through the head at the level of third ventricle of internal capsule and neighboring nuclei. Section 3.



MRI scan at the corresponding level to the above figure. Section 3.

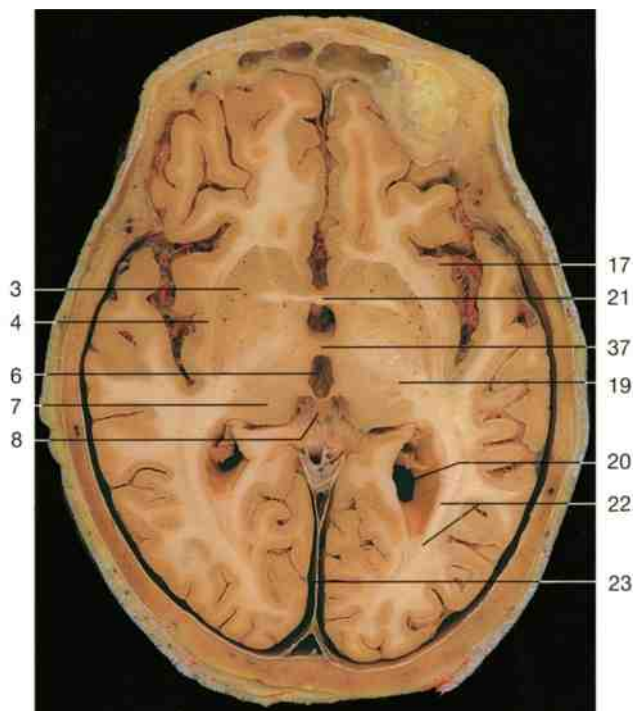


Sagittal section through the head. Levels of the horizontal sections are indicated.

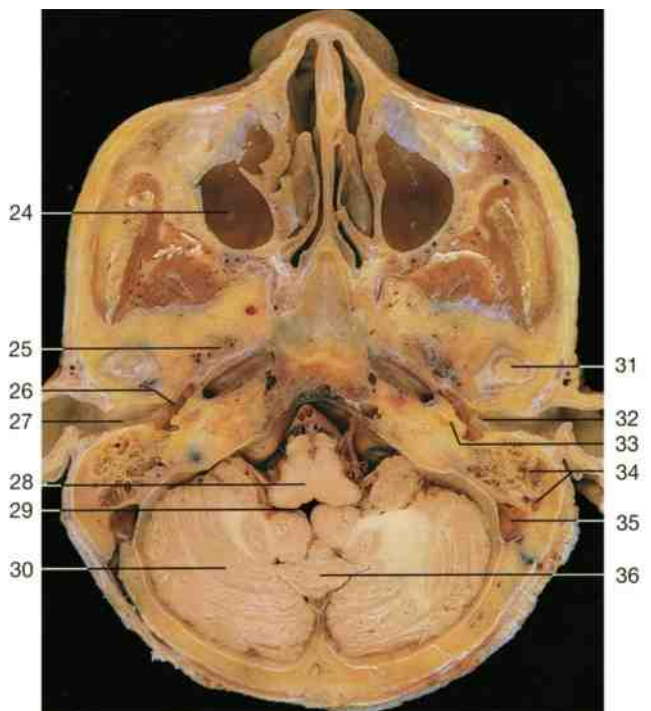


- 1 Genu of corpus callosum
- 2 Head of caudate nucleus
- 3 Putamen
- 4 Claustrum
- 5 Globus pallidus
- 6 Third ventricle
- 7 Thalamus
- 8 Pineal body
- 9 Splenium of corpus callosum
- 10 Choroid plexus of the lateral ventricle
- 11 Anterior horn of lateral ventricle
- 12 Cavity of septum pellucidum
- 13 Septum pellucidum
- 14 Anterior limb of internal capsule
- 15 Column of fornix
- 16 External capsule
- 17 Lobus insularis (insula)
- 18 Genu of internal capsule
- 19 Posterior limb of internal capsule
- 20 Posterior horn of lateral ventricle
- 21 Anterior commissure
- 22 Optic radiation
- 23 Falx cerebri
- 24 Maxillary sinus
- 25 Position of auditory tube
- 26 Tympanic cavity
- 27 External acoustic meatus
- 28 Medulla oblongata
- 29 Fourth ventricle
- 30 Cerebellum (left hemisphere)
- 31 Temporomandibular joint
- 32 Tympanic membrane
- 33 Base of cochlea
- 34 Mastoid air cells
- 35 Sigmoid sinus
- 36 Vermis of cerebellum
- 37 Intermediate mass

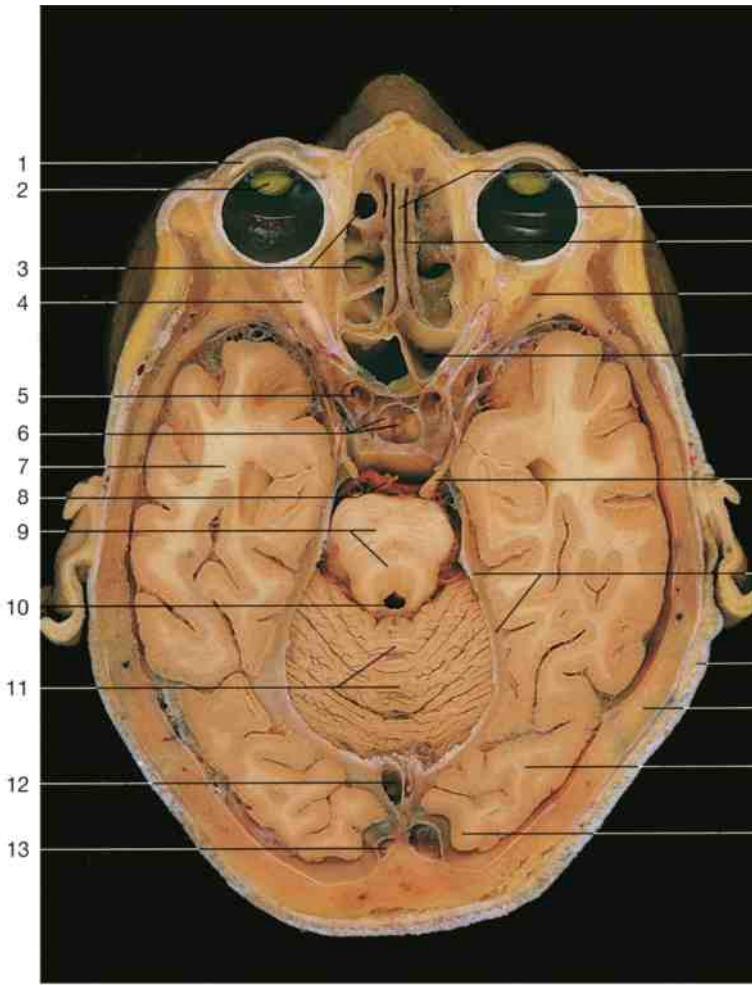
Horizontal section through the brain, showing the subcortical nuclei and internal capsule. Section 1.



Horizontal section through the head. Section 2.

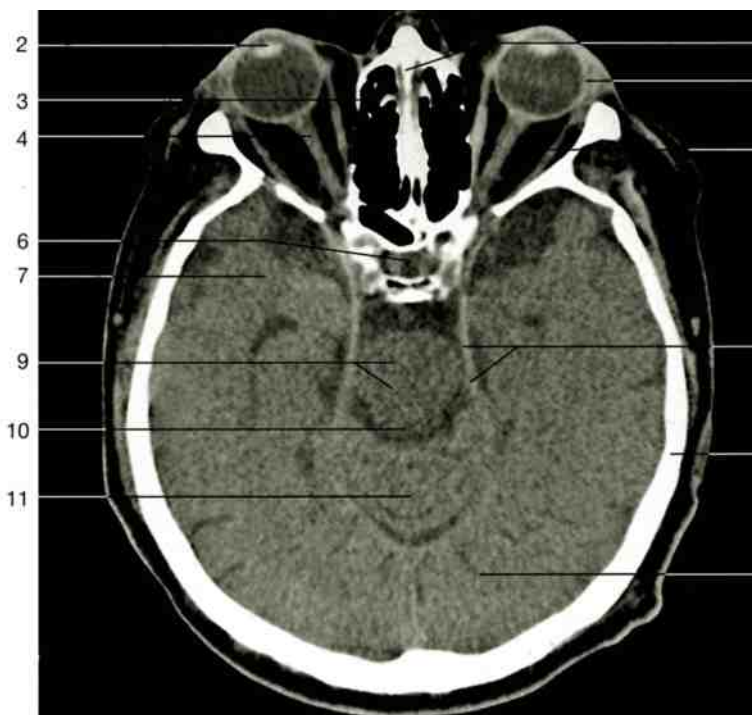


Horizontal section through the head. Section 4.

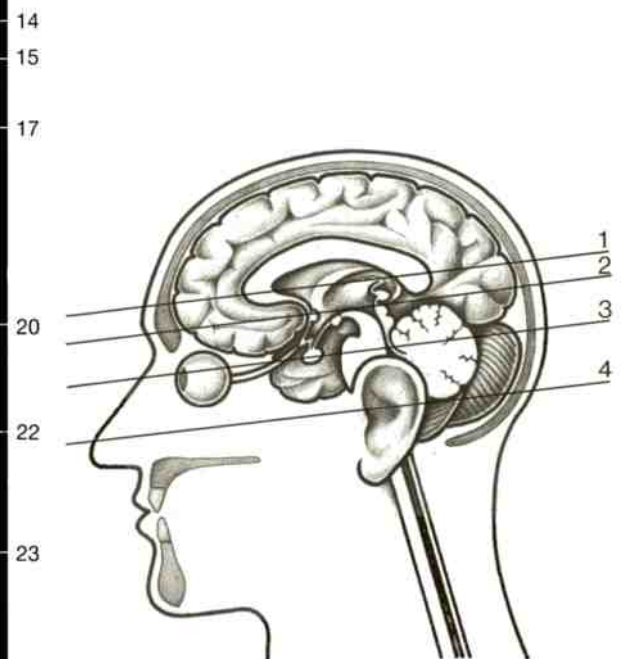


- 1 Upper lid (tarsal plate)
- 2 Lens
- 3 Ethmoidal sinus
- 4 Optic nerve (n. II)
- 5 Internal carotid artery
- 6 Infundibulum and pituitary gland
- 7 Temporal lobe
- 8 Basilar artery
- 9 Pons (cross section of brain stem)
- 10 Cerebral aqueduct (beginning of fourth ventricle)
- 11 Vermis of cerebellum
- 12 Straight sinus
- 13 Transverse sinus
- 14 Nasal septum
- 15 Eyeball (sclera)
- 16 Nasal cavity
- 17 Lateral rectus muscle
- 18 Sphenoidal sinus
- 19 Oculomotor nerve (n. III)
- 20 Tentorium of cerebellum
- 21 Skin of scalp
- 22 Calvaria
- 23 Occipital lobe
- 24 Striate cortex (visual cortex)

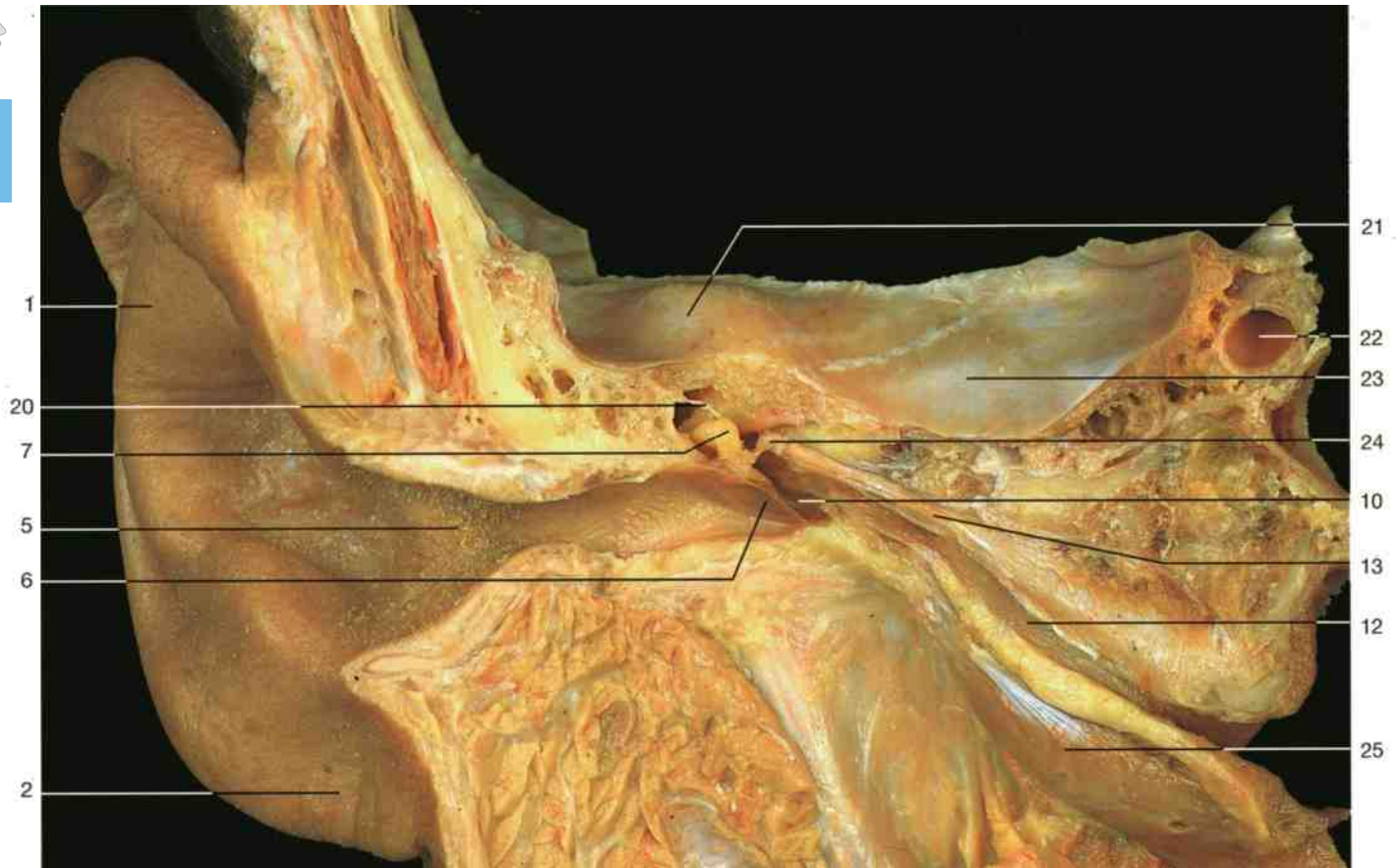
Horizontal section through the head. Section 3.



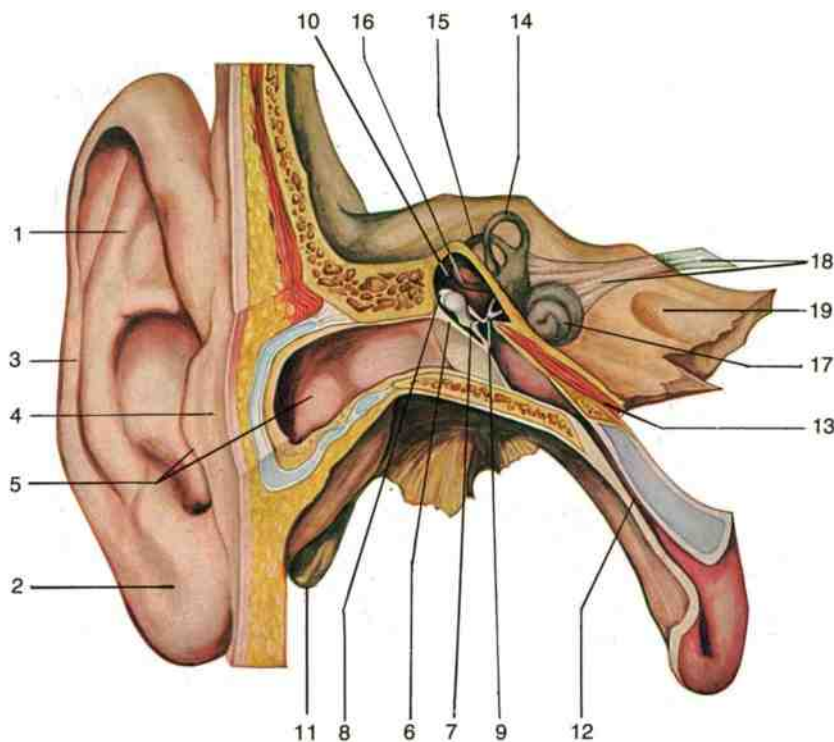
Horizontal section through the head. (CT scan.) Section 3.



Sagittal section through the head.
Levels of the horizontal sections are indicated.



Longitudinal section through the right temporal bone. The outer and middle ear and auditory ossicles and tube are shown (anterior aspect).



Right auditory and vestibular apparatus (anterior aspect). (Schematic drawing.)

Outer ear

- 1 Auricle
- 2 Lobule of auricle
- 3 Helix
- 4 Tragus
- 5 External acoustic meatus

Middle ear

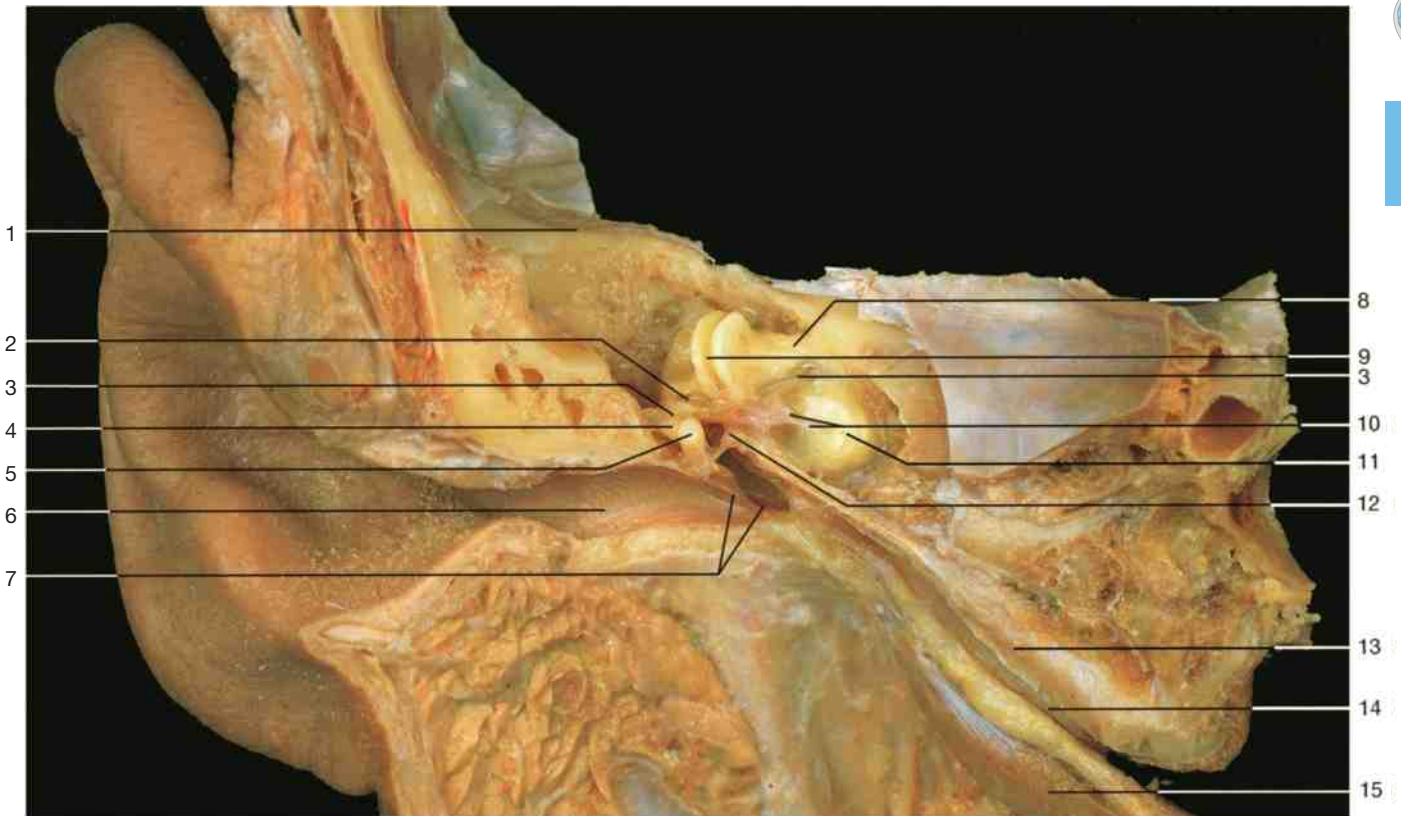
- 6 Tympanic membrane
- 7 Malleus
- 8 Incus
- 9 Stapes
- 10 Tympanic cavity
- 11 Mastoid process
- 12 Auditory tube
- 13 Tensor tympani muscle

Inner ear

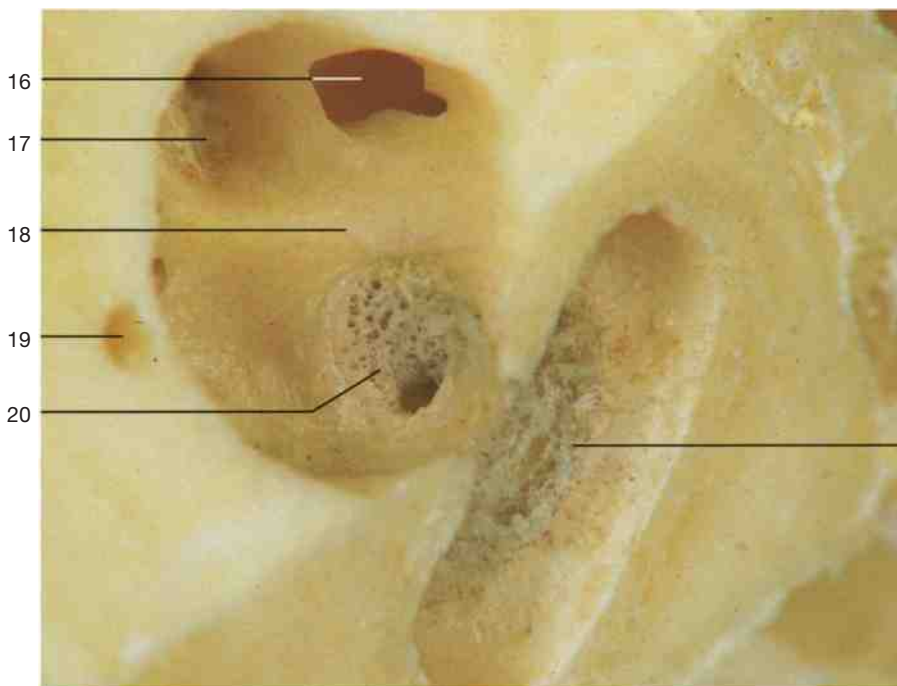
- 14 Anterior semicircular duct
- 15 Posterior semicircular duct
- 16 Lateral semicircular duct
- 17 Cochlea
- 18 Vestibulocochlear nerve
- 19 Petrous part of the temporal bone

Additional structures

- 20 Superior ligament of malleus
- 21 Arcuate eminence
- 22 Internal carotid artery
- 23 Anterior surface of pyramid with dura mater
- 24 Stapes
- 25 Levator veli palatini muscle

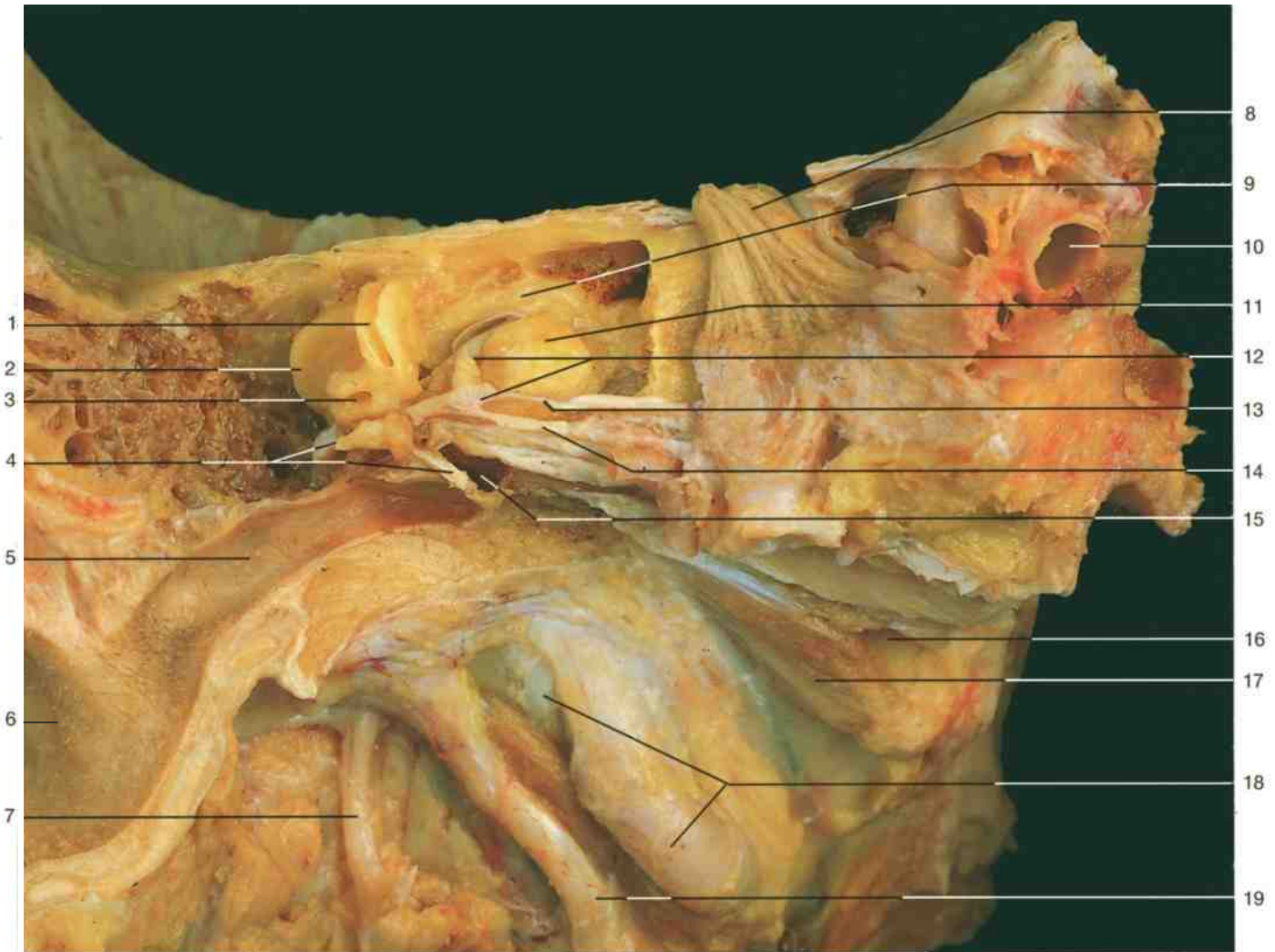


Longitudinal section through the right outer, middle, and inner ear. The cochlea and semicircular canals have been further dissected (anterior aspect).

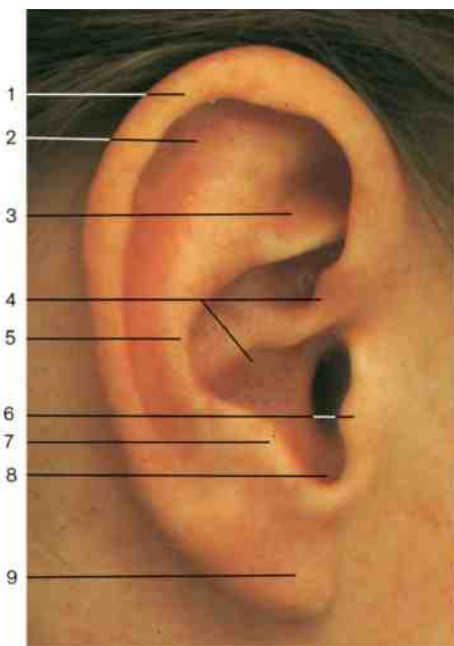


- 1 Roof of tympanic cavity
- 2 Lateral osseous semicircular canal
- 3 Facial nerve
- 4 Incus
- 5 Malleus
- 6 External acoustic meatus
- 7 Tympanic cavity and tympanic membrane
- 8 Vestibulocochlear nerve
- 9 Anterior osseous semicircular canal
- 10 Geniculate ganglion and greater petrosal nerve
- 11 Cochlea
- 12 Stapes
- 13 Tensor tympani muscle
- 14 Auditory tube
- 15 Levator veli palatini muscle
- 16 Area of facial nerve
- 17 Superior vestibular area
- 18 Transverse crest
- 19 Foramen singulare
- 20 Foraminous spiral tract (outlet of cochlear part of vestibulocochlear nerve)
- 21 Base of cochlea

Internal acoustic meatus, left side. The bone was partly removed to show the bottom of the meatus.



Longitudinal section through the outer, middle, and inner ear. Deeper dissection to display facial nerve and lesser and greater petrosal nerves (anterior aspect).



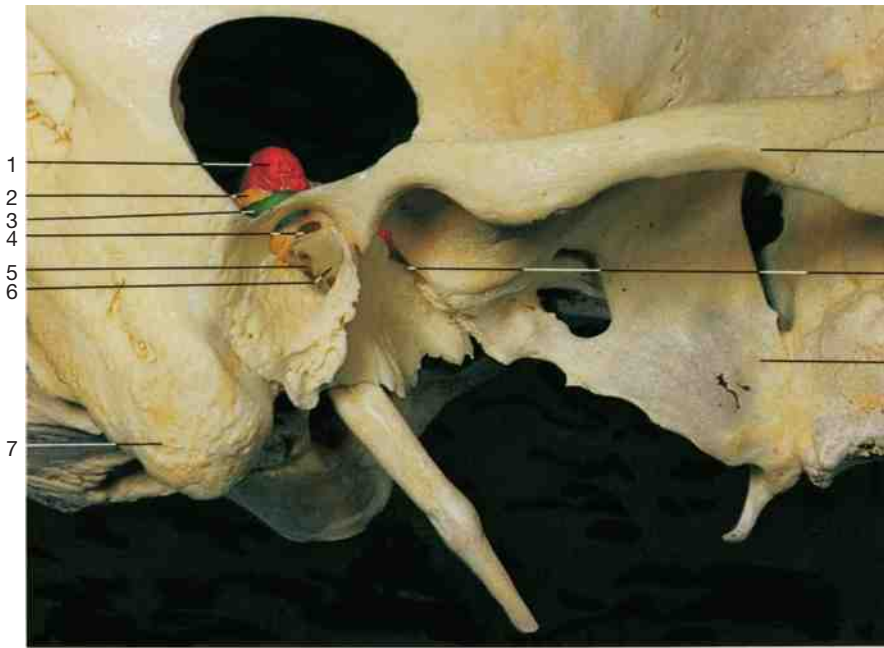
Right auricle (lateral aspect).



- 1 Helix
- 2 Scaphoid fossa
- 3 Triangular fossa
- 4 Concha
- 5 Antihelix
- 6 Tragus
- 7 Antitragus
- 8 Intertragic notch
- 9 Lobule

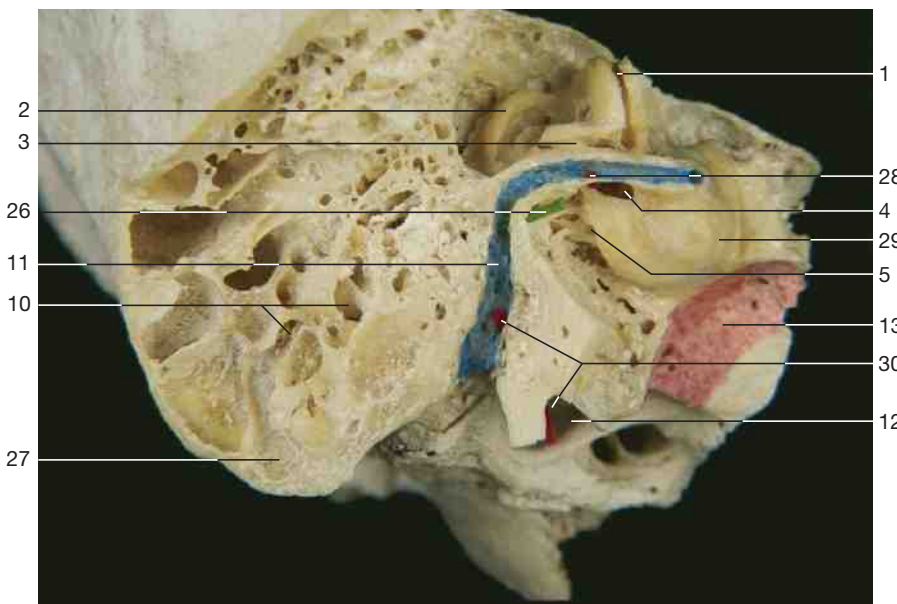


- 1 Anterior osseous semicircular canal (opened)
- 2 Posterior osseous semicircular canal
- 3 Lateral osseous semicircular canal (opened)
- 4 Facial nerve and chorda tympani
- 5 External acoustic meatus
- 6 Auricle
- 7 Facial nerve
- 8 Trigeminal nerve
- 9 Bony base of internal acoustic meatus
- 10 Internal carotid artery within cavernous sinus
- 11 Cochlea
- 12 Facial nerve with geniculate ganglion
- 13 Greater petrosal nerve
- 14 Lesser petrosal nerve
- 15 Tympanic cavity
- 16 Auditory tube
- 17 Levator veli palatini muscle
- 18 Internal carotid artery and internal jugular vein
- 19 Styloid process

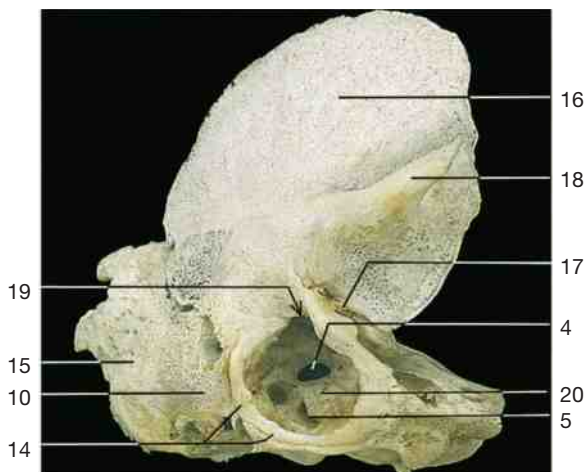


- 1 Anterior semicircular canal (red)
- 2 Posterior semicircular canal (yellow)
- 3 Lateral or horizontal semicircular canal (green)
- 4 Fenestra vestibuli
- 5 Fenestra cochleae
- 6 Tympanic cavity
- 7 Mastoid process
- 8 Petrotympanic fissure (red probe: chorda tympani)
- 9 Lateral pterygoid plate
- 10 Mastoid air cells
- 11 Facial canal (blue)
- 12 Foramen ovale
- 13 Carotid canal (red)
- 14 Tympanic ring
- 15 Petromastoid part of temporal bone
- 16 Squamous part of temporal bone
- 17 Squamomastoid suture
- 18 Zygomatic process of temporal bone
- 19 Incisure of tympanic ring
- 20 Promontory
- 21 Apex of cochlea (cupula)
- 22 Spiral canal of cochlea at base of cochlea
- 23 Epitympanic recess
- 24 Auditory ossicles and tympanic cavity
- 25 Hypotympanic recess
- 26 Canalculus chordae tympani (green probe)
- 27 Mastoid process
- 28 Canalculus for stapedius nerve (red)
- 29 Cochlea
- 30 Canalculus mastoideus (red probe)

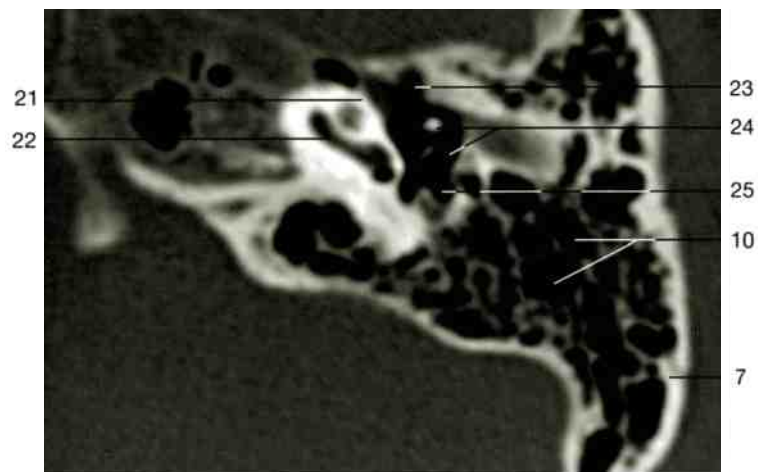
Right temporal bone (lateral aspect). Petrosquamous portion has been partly removed to display the semicircular canals.



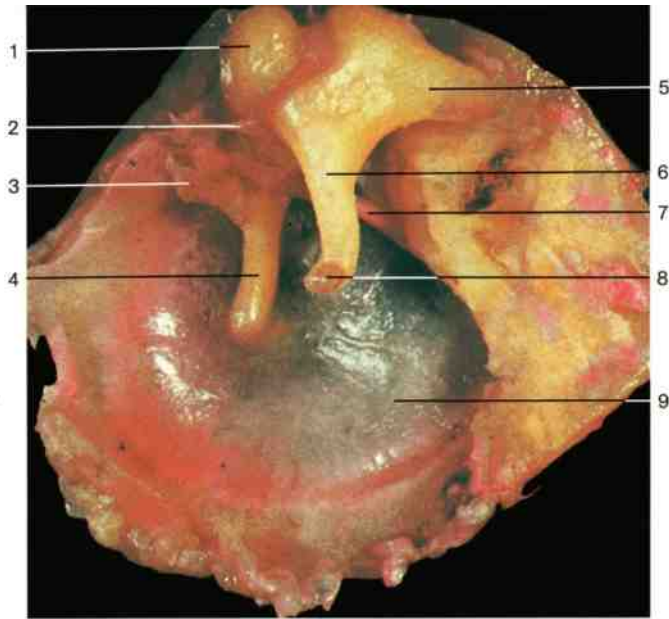
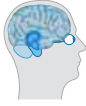Right temporal bone (lateral aspect). Mastoid air cells and facial canal had been opened. The three semicircular canals were dissected.



Right temporal bone of the newborn (lateral aspect).

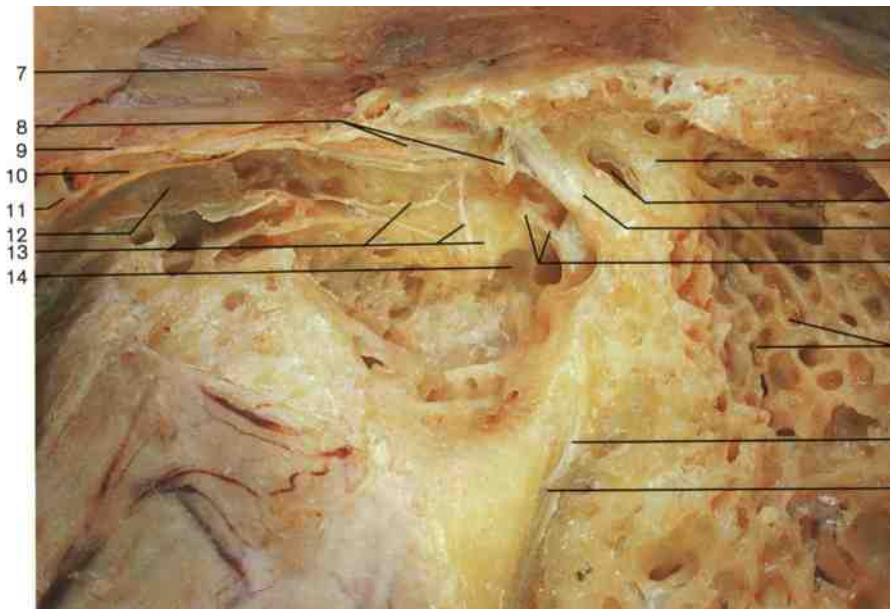


Frontal section through petrous part. (CT scan.)



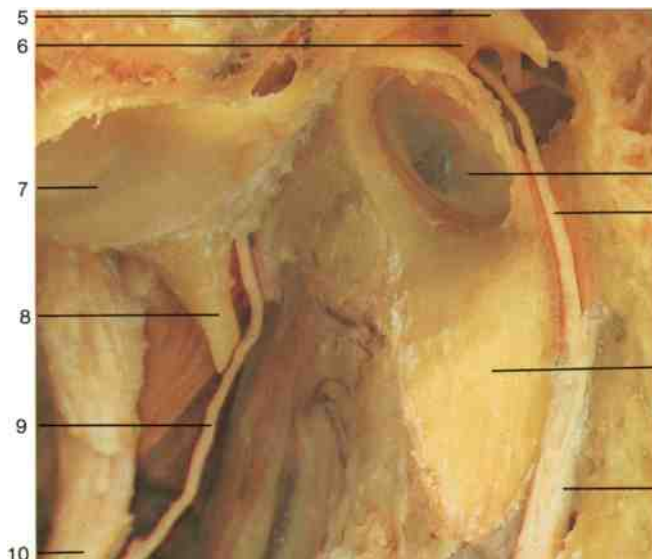- 1 Head of malleus
- 2 Anterior ligament of malleus
- 3 Tendon of tensor tympani muscle
- 4 Handle of malleus
- 5 Short crus of incus
- 6 Long crus of incus
- 7 Chorda tympani
- 8 Lenticular process
- 9 Tympanic membrane

Tympanic membrane with malleus and incus (internal aspect; right side).



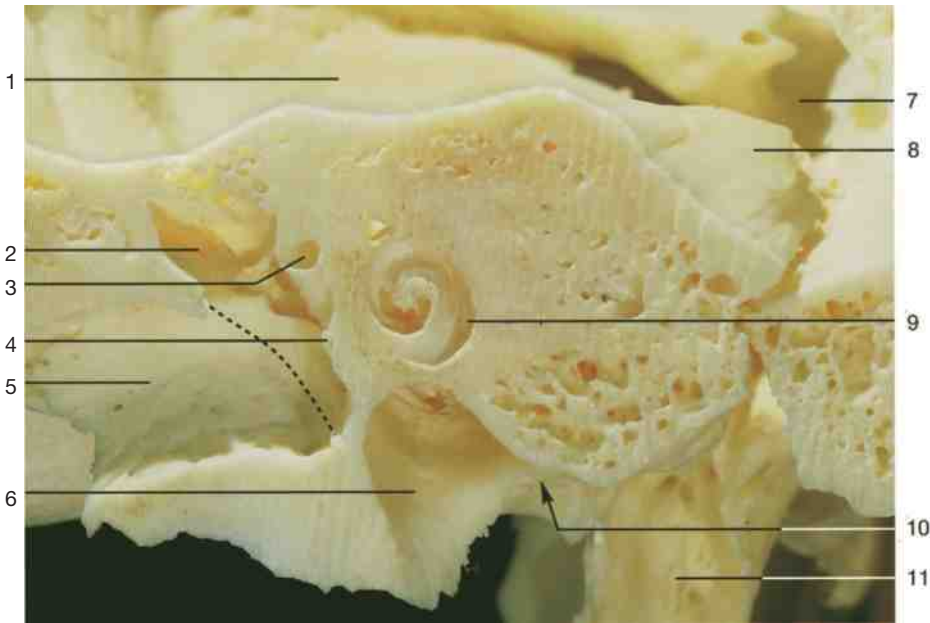
- 1 Tympanic antrum
- 2 Lateral semicircular canal (opened)
- 3 Facial canal
- 4 Stapes with tendon of stapedius
- 5 Mastoid air cells
- 6 Chorda tympani (intracranial part)
- 7 Greater petrosal nerve
- 8 Tensor tympani muscle (processus cochleariformis)
- 9 Lesser petrosal nerve
- 10 Anterior tympanic artery
- 11 Middle meningeal artery
- 12 Auditory tube
- 13 Promontory with tympanic plexus
- 14 Fenestra cochleae

Tympanic cavity, medial wall. External acoustic meatus and lateral wall of tympanic cavity together with incus. Malleus and tympanic membrane have been removed; mastoid air cells are opened (left side).

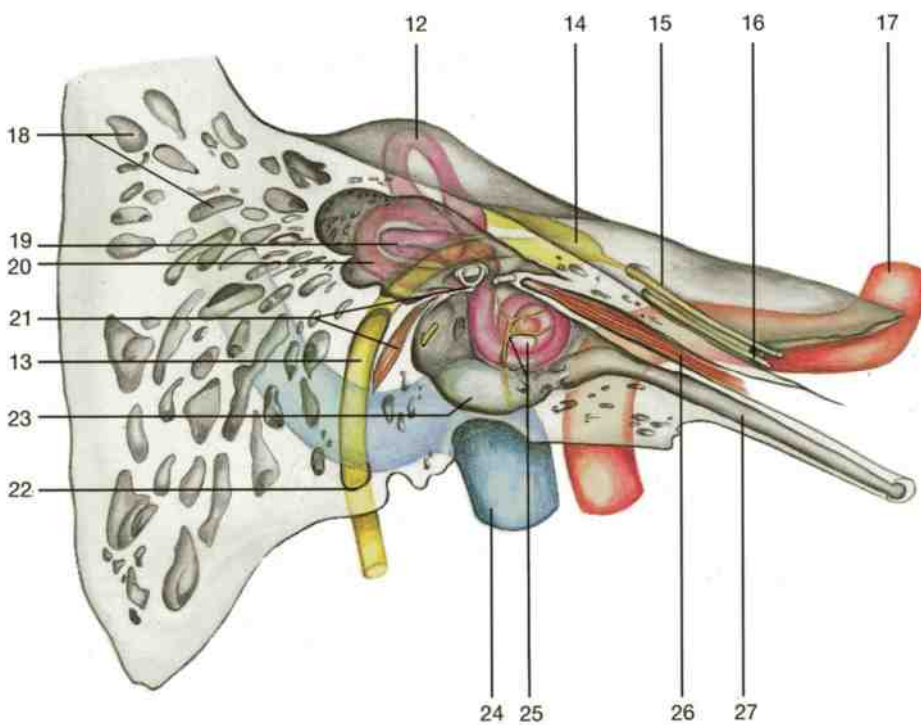


- 1 Tympanic membrane
- 2 Chorda tympani (intracranial part)
- 3 Floor of the external acoustic meatus
- 4 Facial nerve and facial canal
- 5 Incus
- 6 Head of malleus
- 7 Mandibular fossa
- 8 Spine of sphenoid
- 9 Chorda tympani (extracranial part)
- 10 Styloid process

Tympanic membrane (lateral aspect). External acoustic meatus and facial canal have been opened to expose the chorda tympani (magn. ~1.5×) (left side).

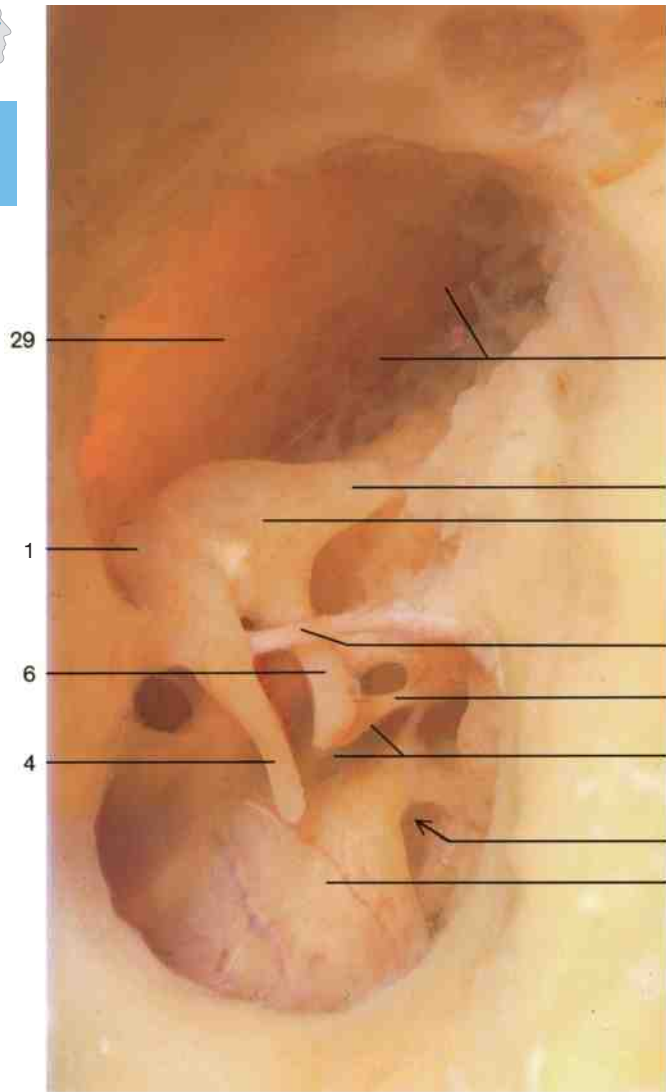


Frontal section through the petrous part of the left temporal bone at the level of the cochlea (posterior aspect). Position of tympanic membrane indicated by dotted line.

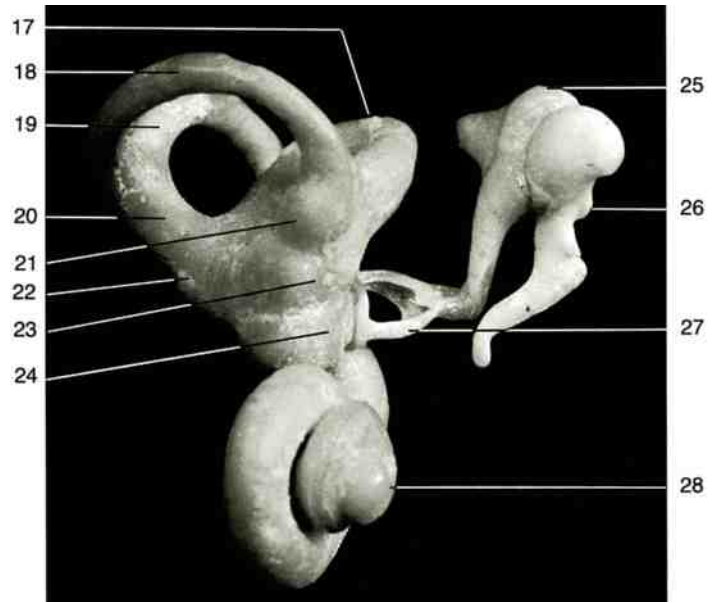


Medial wall of tympanic cavity and its relation to neighboring structures of the inner ear, facial nerve, and blood vessels (schematic drawing). Frontal section through the right temporal bone (anterior aspect).

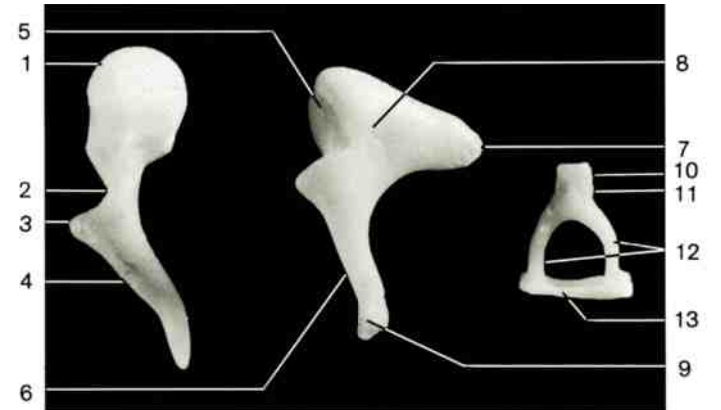
- | | | |
|---|-------------------------------|--|
| 1 Anterior surface of the pyramid | 10 Carotid canal | 20 Posterior semicircular duct |
| 2 Mastoid antrum | 11 Pterygoid process | 21 Stapes with stapedius muscle |
| 3 Lateral semicircular canal | 12 Anterior semicircular duct | 22 Stylomastoid foramen |
| 4 Cochleariform process | 13 Facial nerve | 23 Inferior recess of tympanic cavity (hypotympanon) |
| 5 External acoustic meatus | 14 Geniculate ganglion | 24 Internal jugular vein |
| 6 Jugular fossa | 15 Greater petrosal nerve | 25 Promontory with tympanic plexus (position of cochlea) |
| 7 Foramen lacerum | 16 Lesser petrosal nerve | 26 Tensor muscle of tympanum |
| 8 Apex of petrous part | 17 Internal carotid artery | 27 Auditory tube |
| 9 Position of cochlea (modiolus with crista spiralis ossea) | 18 Mastoid air cells | |
| | 19 Lateral semicircular duct | |



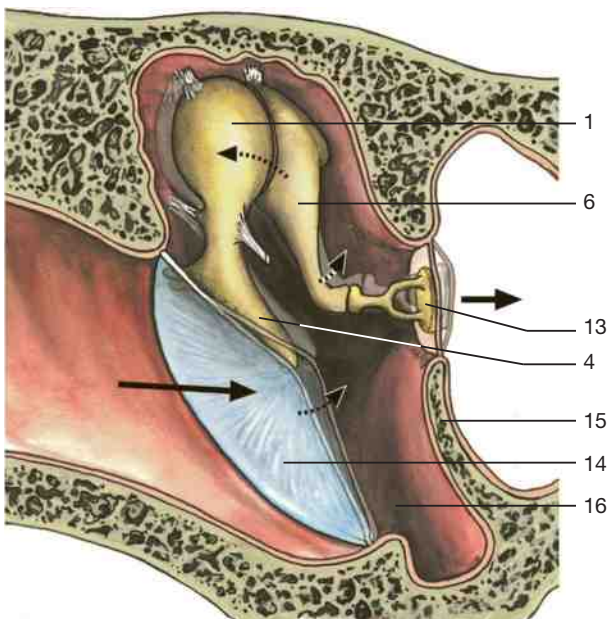
Tympanic cavity with malleus, incus, and stapes, left side (lateral aspect). Tympanic membrane removed, mastoid antrum opened.



Chain of auditory ossicles in connection with the inner ear, left side (antero-lateral aspect).



Auditory ossicles (isolated).



Position and movements of the auditory ossicles (schematic drawing).

Malleus

- 1 Head
- 2 Neck
- 3 Lateral process
- 4 Handle

Incus

- 5 Articular facet for malleus
- 6 Long crus
- 7 Short crus
- 8 Body
- 9 Lenticular process

Stapes

- 10 Head
- 11 Neck
- 12 Anterior and posterior crura
- 13 Base

Walls of tympanic cavity

- 14 Tympanic membrane
- 15 Promontory
- 16 Hypotympanic recess of tympanic cavity

Internal ear (labyrinth)

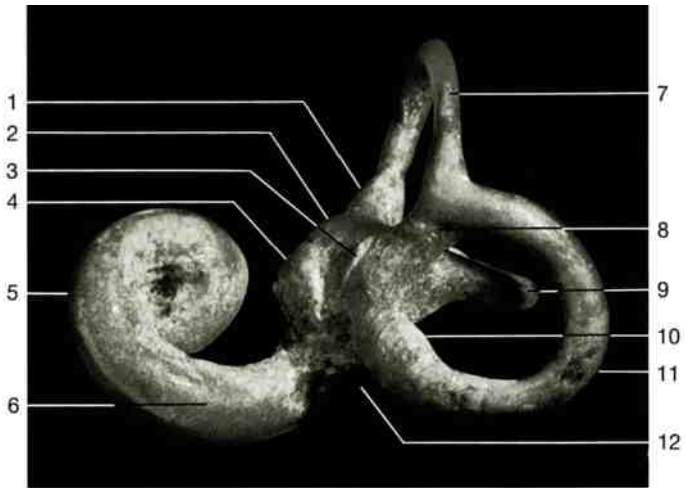
- 17 Lateral semicircular duct
- 18 Anterior semicircular duct
- 19 Posterior semicircular duct
- 20 Common crus
- 21 Ampulla
- 22 Beginning of endolymphatic duct
- 23 Utricular prominence
- 24 Saccular prominence
- 25 Incus
- 26 Malleus
- 27 Stapes
- 28 Cochlea

Tympanic cavity


- 29 Epitympanic recess
- 30 Mastoid antrum
- 31 Chorda tympani
- 32 Tendon of stapedius muscle
- 33 Round window (fenestra cochleae)



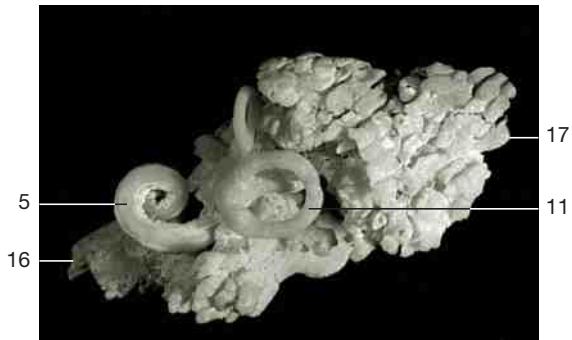
- | | |
|---|--|
| 1 Ampulla (anterior semicircular canal) | 16 External acoustic meatus |
| 2 Elliptical recess | 17 Mastoid air cells |
| 3 Aqueduct of the vestibule | 18 Tympanic cavity and fenestra cochleae (probe) |
| 4 Spherical recess | 19 External acoustic meatus |
| 5 Cochlea | 20 Facial canal |
| 6 Base of cochlea | 21 Base of cochlea and musculotubal canal |
| 7 Anterior semicircular canal | 22 Malleus and incus |
| 8 Crus commune or common limb | 23 Stapes |
| 9 Lateral semicircular canal | 24 Tympanic membrane |
| 10 Posterior bony ampulla | 25 Tympanic cavity |
| 11 Posterior semicircular canal (posterior canal) | 26 Aqueduct of cochlea |
| 12 Fenestra cochleae | 27 Endolymphatic sac |
| 13 Bony ampulla | 28 Endolymphatic duct |
| 14 Fenestra vestibuli | 29 Macula of utricle |
| 15 Cupula of cochlea | 30 Macula of saccule |



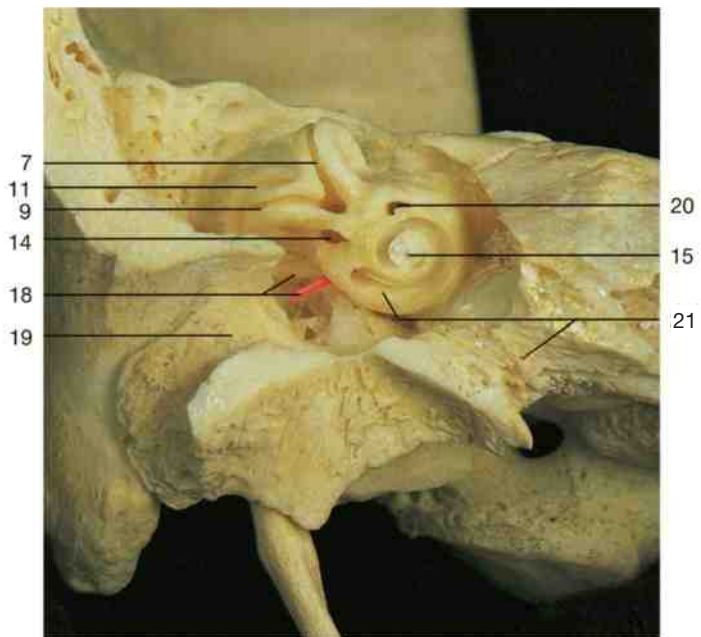
Cast of the right labyrinth (postero-medial aspect).



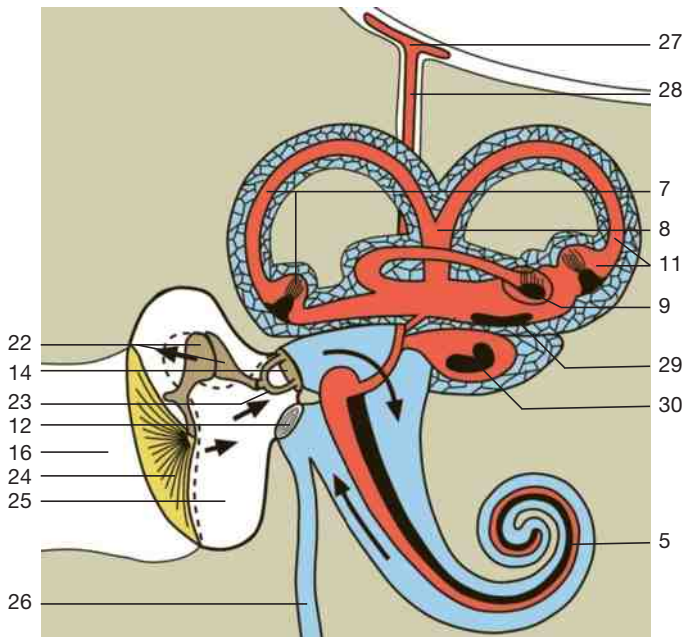
Cast of the right labyrinth (lateral aspect).



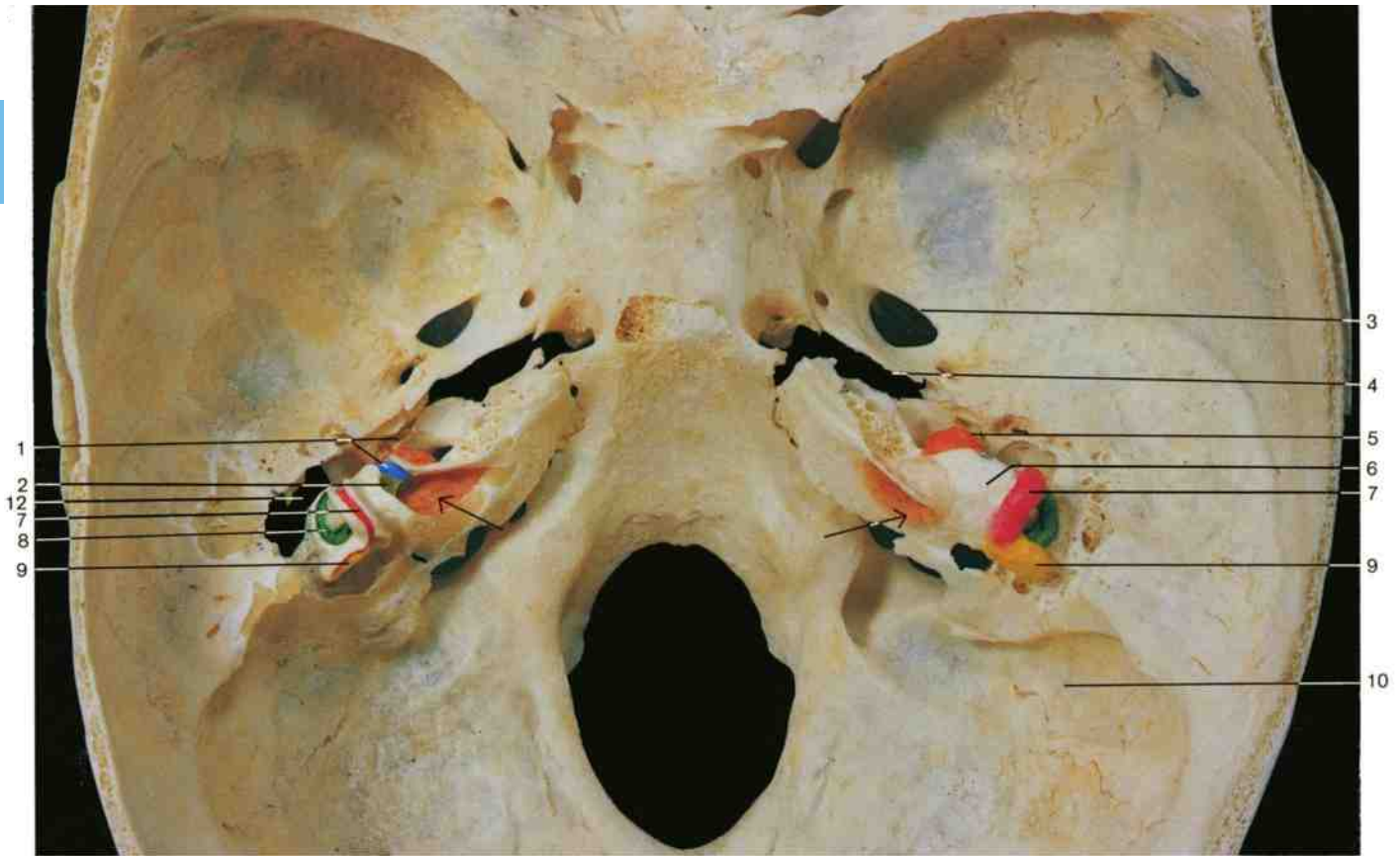
Cast of the labyrinth and mastoid cells. Life size (posterior aspect).



Dissection of bony labyrinth in situ. Semicircular canals and cochlear duct opened.

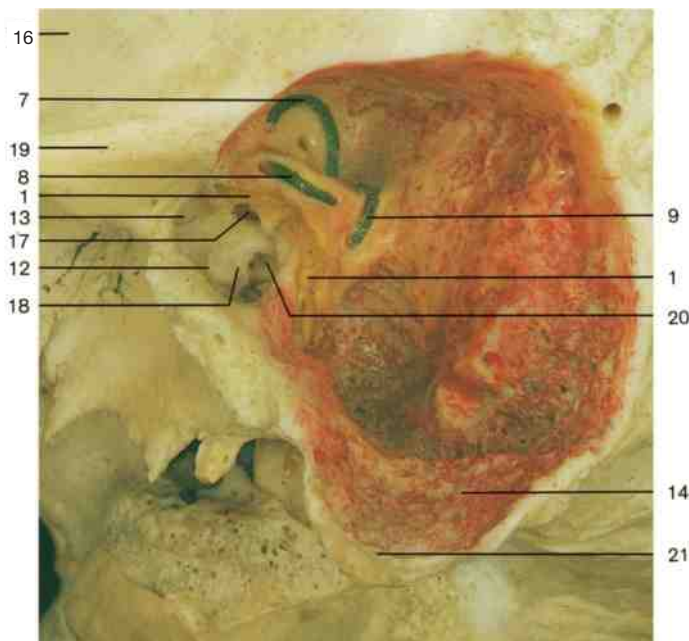


Auditory and vestibular apparatus. Arrows = direction of sound waves; blue = perilymphatic ducts (schematic drawing; from Lütjen-Drecoll, Rohen, Innenansichten des menschlichen Körpers, 2010).

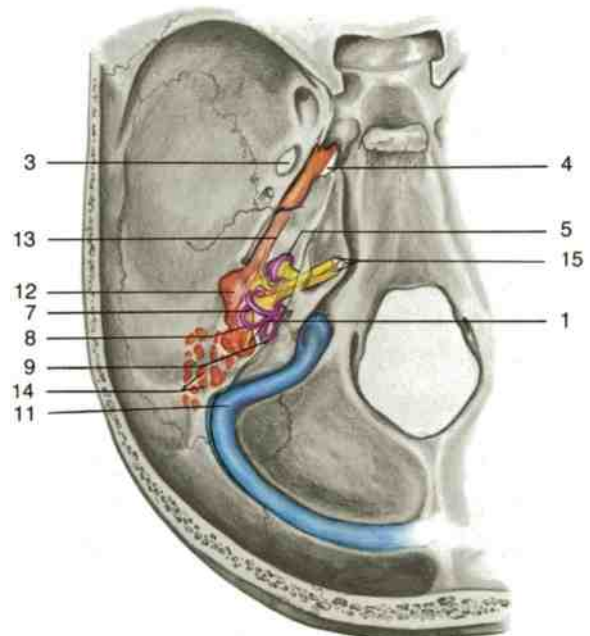


Bony labyrinth, petrous part of the temporal bone (from above). At left: semicircular canals opened; at right: closed. Arrows: internal acoustic meatus.

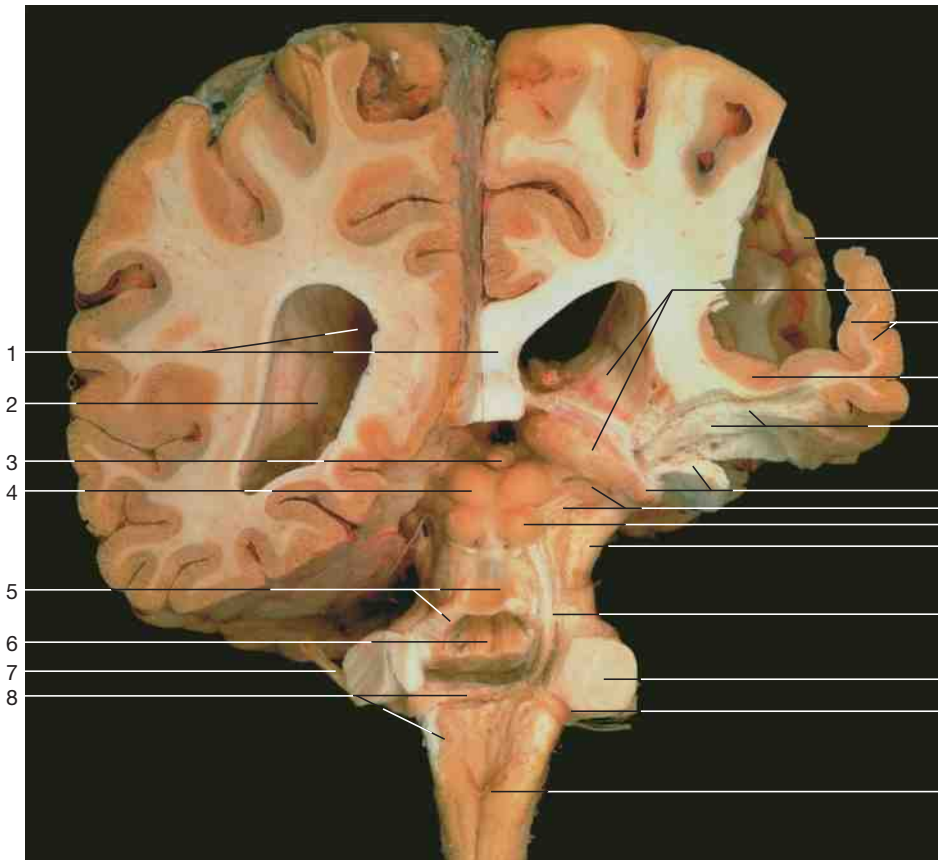
- | | | |
|---|--|-----------------------|
| 1 Facial canal and semicanal of auditory tube | 9 Posterior semicircular canal | 17 Fenestra vestibuli |
| 2 Superior vestibular area | 10 Groove for sigmoid sinus | 18 Promontory |
| 3 Foramen ovale | 11 Sigmoid sinus | 19 Zygomatic process |
| 4 Foramen lacerum | 12 Tympanic cavity | 20 Fenestra cochleae |
| 5 Cochlea | 13 Auditory tube | 21 Mastoid process |
| 6 Vestibule | 14 Mastoid air cells | |
| 7 Anterior semicircular canal | 15 Facial and vestibulocochlear nerves | |
| 8 Lateral semicircular canal | 16 Temporal fossa | |



Bony labyrinth (left lateral aspect). Temporal and tympanic bone partly removed, semicircular canals opened.

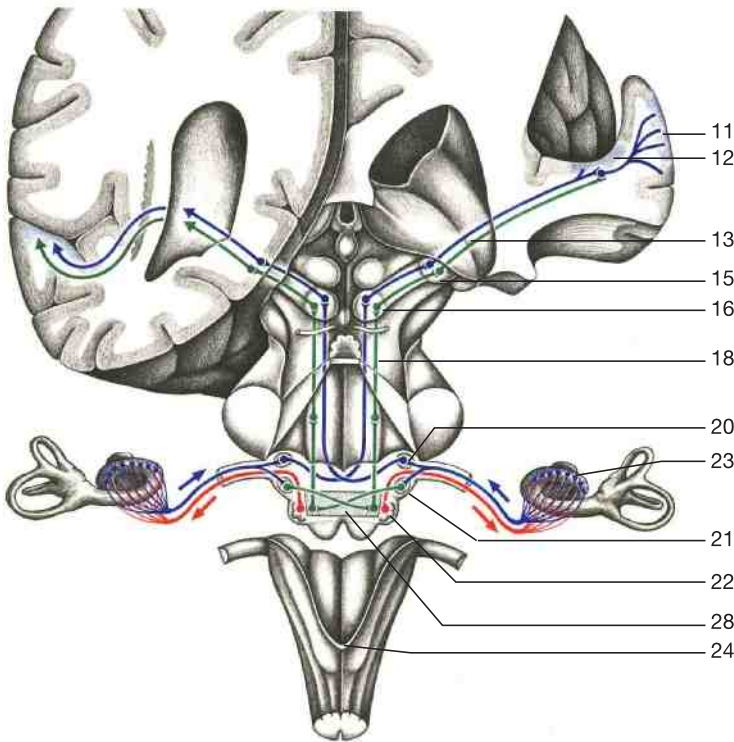


Internal ear. Diagram showing the position of the membranous labyrinth and the tympanic cavity.

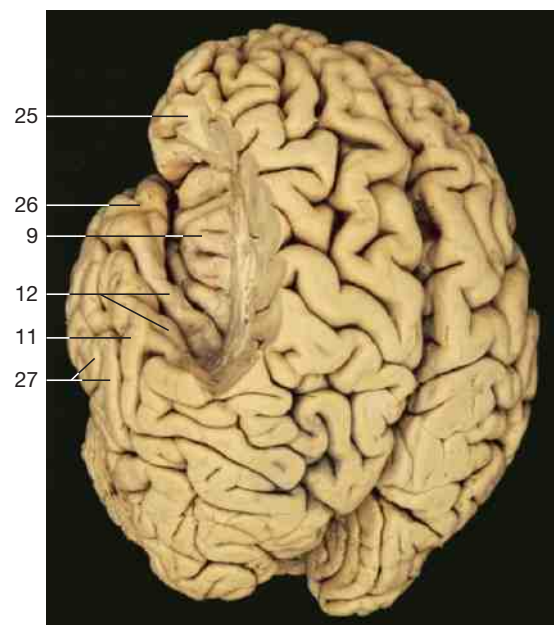


- 1 Left lateral ventricle and corpus callosum
- 2 Thalamus
- 3 Pineal gland (epiphysis)
- 4 Superior colliculus
- 5 Superior medullary velum and superior cerebellar peduncle
- 6 Rhomboid fossa
- 7 Vestibulocochlear nerve (n. VIII)
- 8 Dorsal acoustic striae and inferior cerebellar peduncle
- 9 Insular lobe
- 10 Caudate nucleus and thalamus
- 11 Temporal lobe (superior temporal gyrus) (area of acoustic centers)
- 12 Transverse temporal gyri of Heschl (area of primary acoustic centers)
- 13 Acoustic radiation of internal capsule
- 14 Lateral geniculate body and optic radiation (cut)
- 15 Medial geniculate body and brachium of inferior colliculus
- 16 Inferior colliculus
- 17 Cerebral peduncle
- 18 Lateral lemniscus
- 19 Middle cerebellar peduncle
- 20 Dorsal (posterior) cochlear nucleus
- 21 Ventral (anterior) cochlear nucleus
- 22 Inferior olive with olivo-cochlear tract of Rasmussen (red)
- 23 Ganglion spirale
- 24 Obex
- 25 Frontal lobe
- 26 Temporal lobe
- 27 Middle temporal gyrus (area of tertiary acoustic centers)
- 28 Trapezoid body

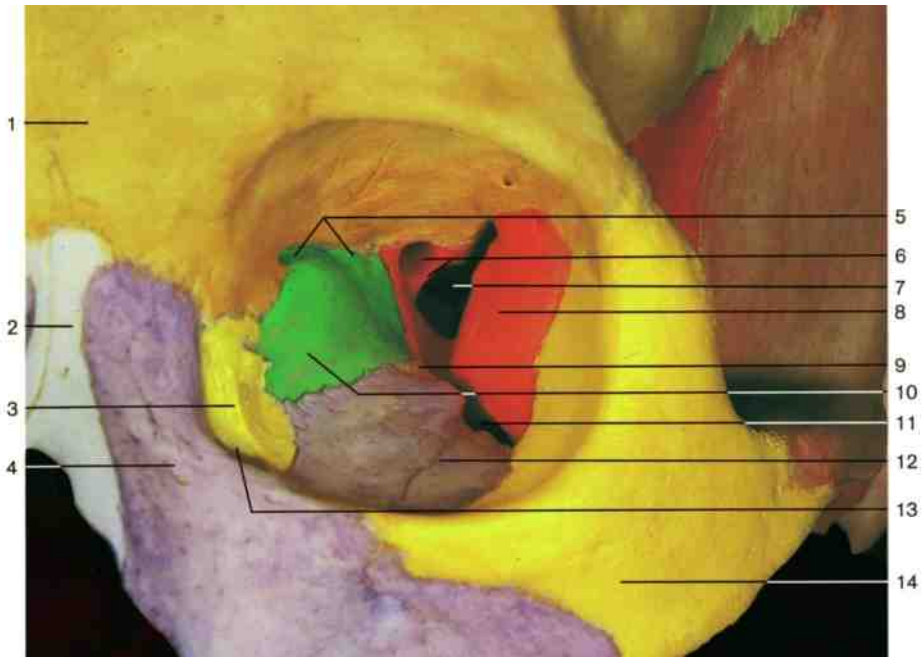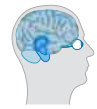Dissection of the brain stem showing the auditory pathway. Cerebellum and posterior part of the two hemispheres have been removed (dorsal aspect).



Auditory pathway (schematic drawing, compare with figure above). Red = descending (efferent) pathway (olivocochlear tract of Rasmussen); green and blue = ascending (afferent) pathways.

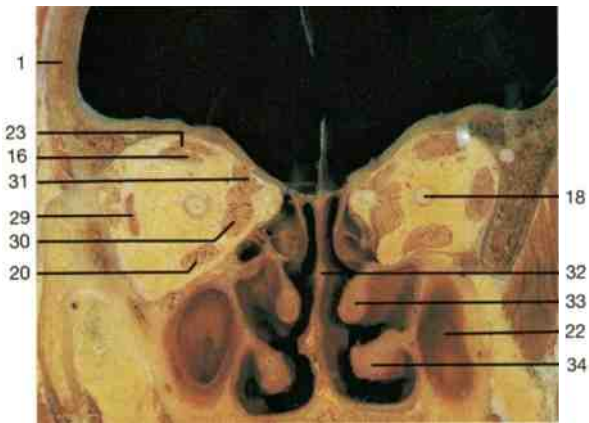

Auditory areas in the left hemisphere (supero-lateral aspect). Parts of the frontal and parietal lobes have been removed.

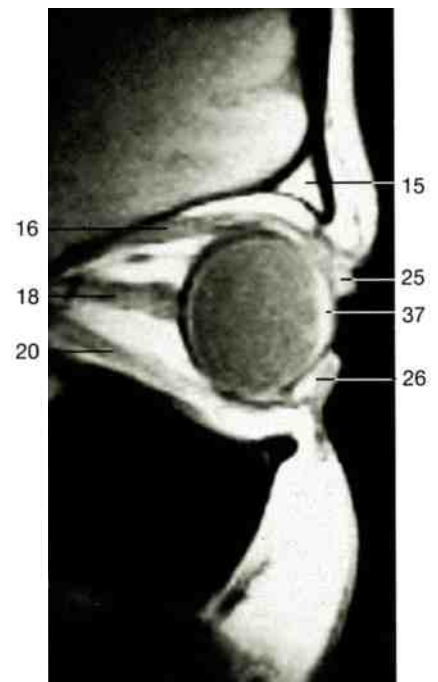
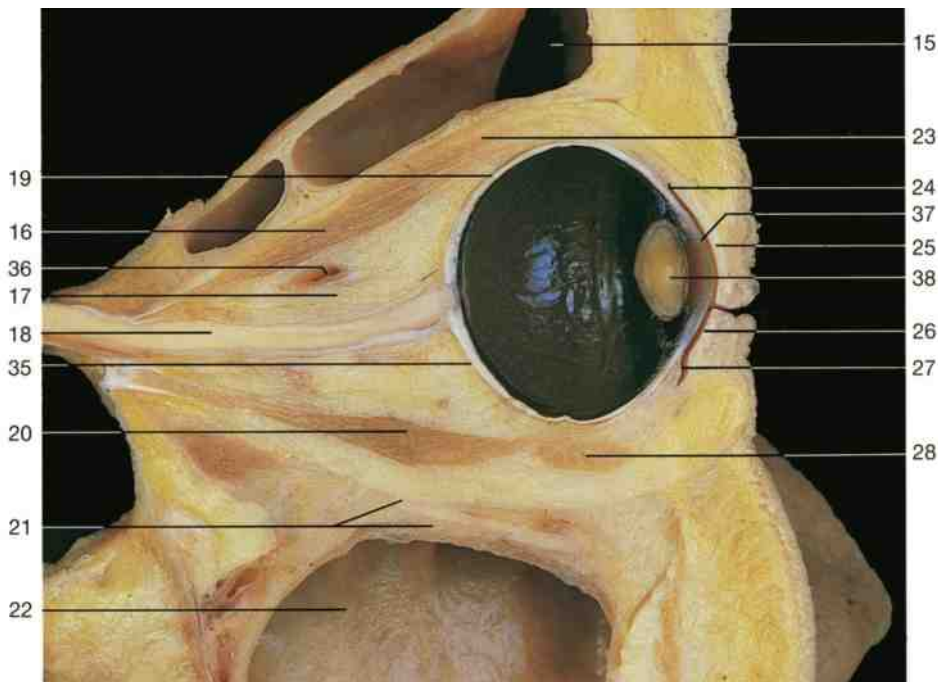

Bones of the left orbit (indicated by different colors).

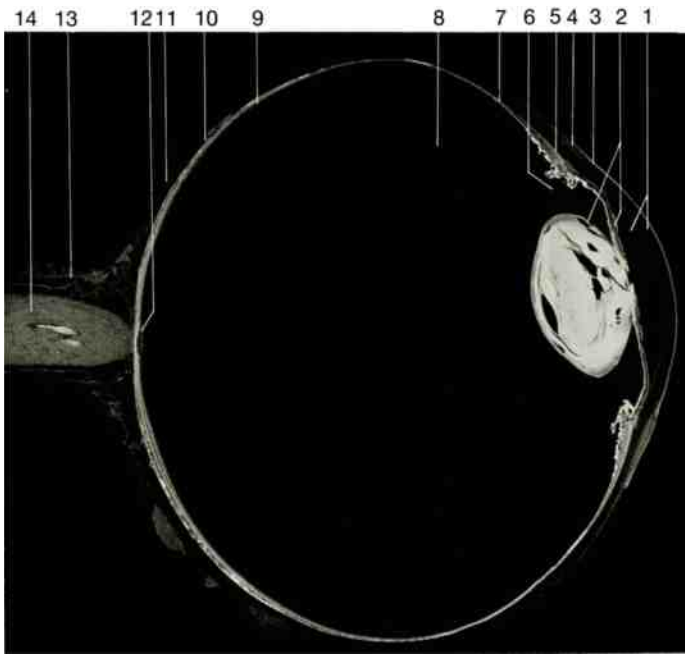
- 1 Frontal bone
- 2 Nasal bone
- 3 Lacrimal bone
- 4 Maxilla (frontal process)
- 5 Ethmoidal foramina
- 6 Lesser wing of sphenoid bone and optic canal
- 7 Superior orbital fissure
- 8 Greater wing of sphenoid bone
- 9 Orbital process of palatine bone
- 10 Orbital plate of ethmoid bone
- 11 Inferior orbital fissure
- 12 Infra-orbital sulcus
- 13 Nasolacrimal canal
- 14 Zygomatic bone
- 15 Frontal sinus
- 16 Superior rectus muscle
- 17 Orbital fatty tissue
- 18 Optic nerve
- 19 Sclera
- 20 Inferior rectus muscle
- 21 Periorbita and maxilla
- 22 Maxillary sinus
- 23 Levator palpebrae superioris muscle
- 24 Superior conjunctival fornix
- 25 Superior tarsal plate
- 26 Inferior tarsal plate
- 27 Inferior conjunctival fornix
- 28 Inferior oblique muscle
- 29 Lateral rectus muscle
- 30 Medial rectus muscle
- 31 Superior oblique muscle
- 32 Nasal septum
- 33 Middle nasal concha
- 34 Inferior nasal concha
- 35 Tenon's space
- 36 Ophthalmic artery
- 37 Cornea
- 38 Lens



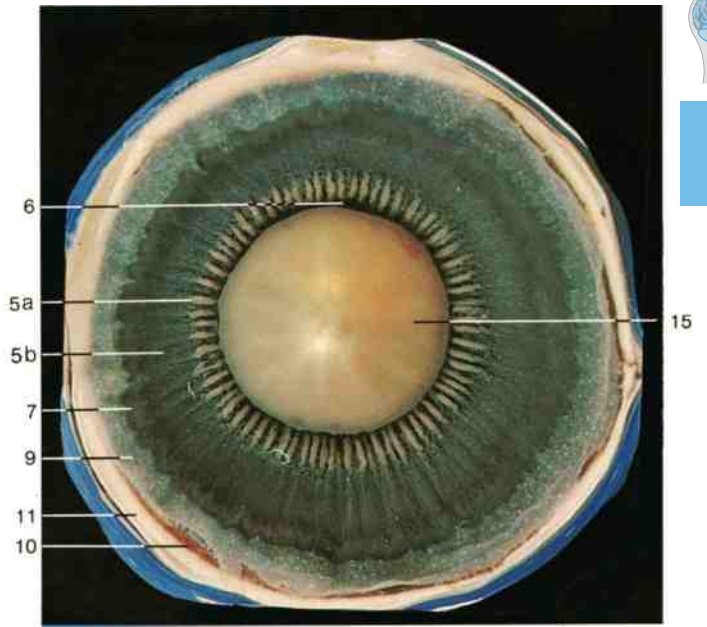
Frontal section through the posterior part of the orbit.



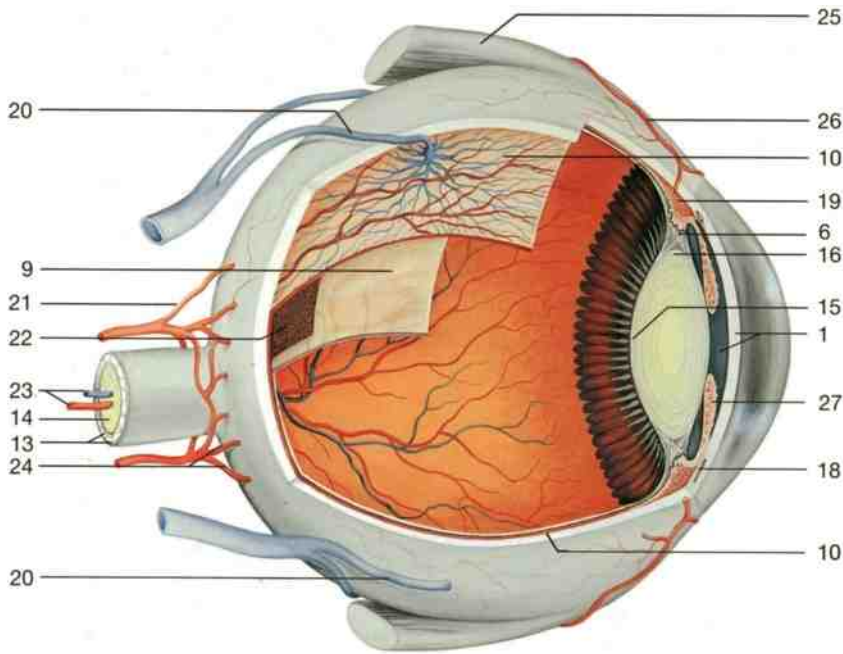
Sagittal section through orbit and eyeball. (Right: MRI scan.)



Horizontal section through the human eye (2×).

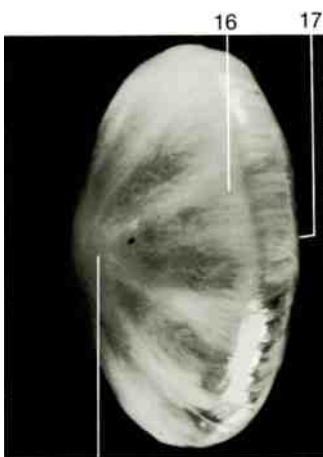

Anterior segment of the eyeball (posterior aspect). The opacity of the lens is an artifact.




Organization of the eyeball. Demonstration of vascular tunic of bulb (schematic drawing).

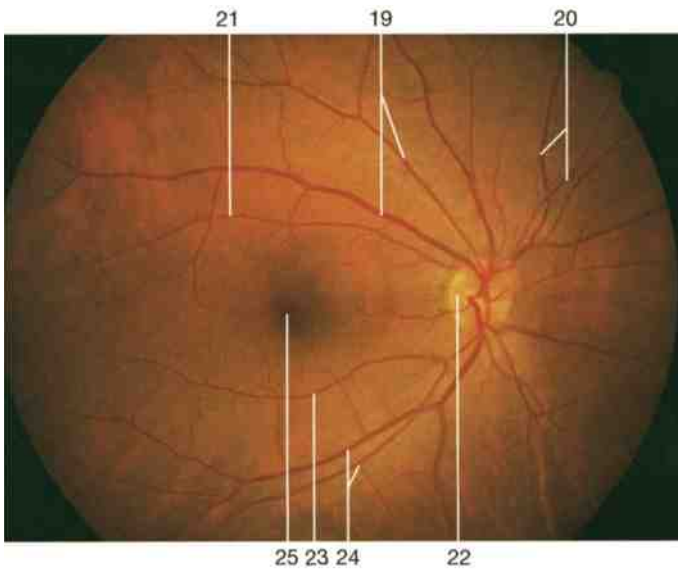
- 1 Cornea and anterior chamber
- 2 Iris and lens
- 3 Transitional zone between corneal and conjunctival epithelium
- 4 Conjunctiva of the eyeball
- 5 Ciliary body
 - a Ciliary processes (pars plicata)
 - b Ciliary ring (pars plana)
- 6 Zonular fibers
- 7 Ora serrata
- 8 Vitreous body
- 9 Retina
- 10 Choroid
- 11 Sclera
- 12 Optic disc
- 13 Dura mater and subarachnoid space
- 14 Optic nerve (n. II)
- 15 Lens (posterior pole)
- 16 Equator of lens
- 17 Lens (anterior pole)
- 18 Canal of Schlemm
- 19 Ciliary muscle
- 20 Vena vorticiosa
- 21 Long posterior ciliary artery
- 22 Retinal pigmented epithelium
- 23 Central retinal artery and vein
- 24 Short posterior ciliary arteries
- 25 External ocular muscle
- 26 Anterior ciliary artery
- 27 Iris



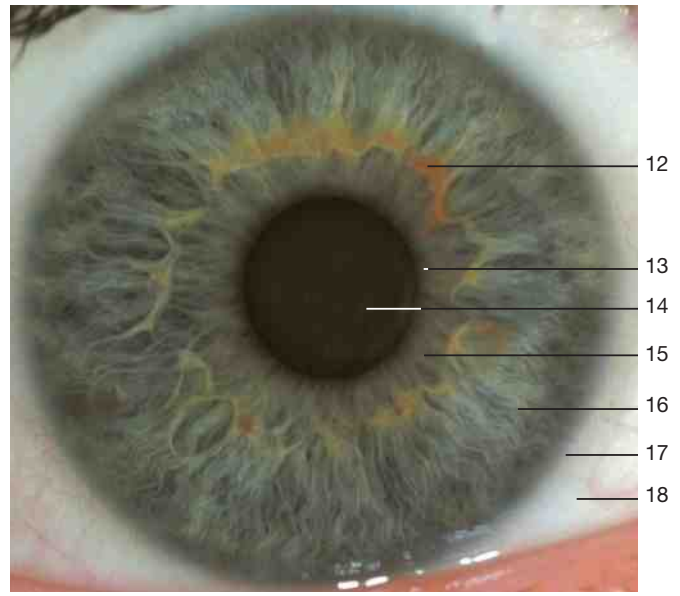
Lens (equatorial aspect), anterior pole to the right.



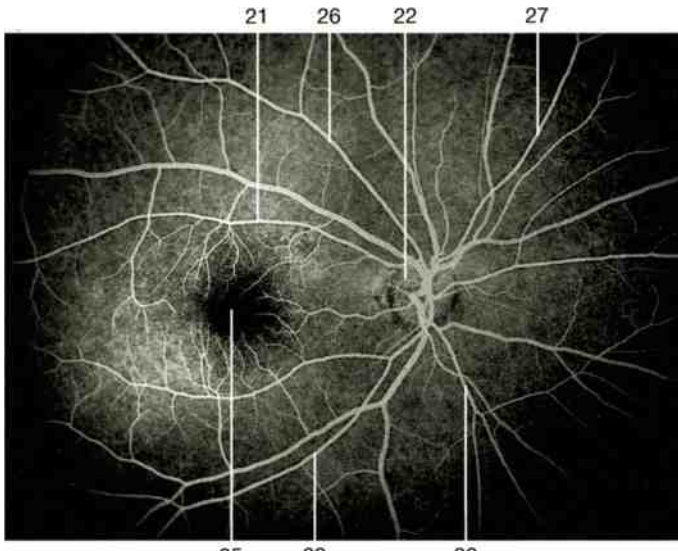
Lens (frontal aspect). Note the magnification effect.



Fundus of a normal right eye (courtesy of Prof. Okamura, Univ. Eye Dept., Kumamoto, Japan). Notice, the arteries are smaller and lighter than the veins.



Anterior segment of the human eye (courtesy of Prof. Naumann, Eye Dept., University of Erlangen, Germany). Note the colored iris (16) and the location of the lens behind the iris (14).



Fluorescent angiography of the right eye; retinal vessels.
The same eye as above (courtesy of Prof. Okamura, Univ. Eye Dept., Kumamoto, Japan).

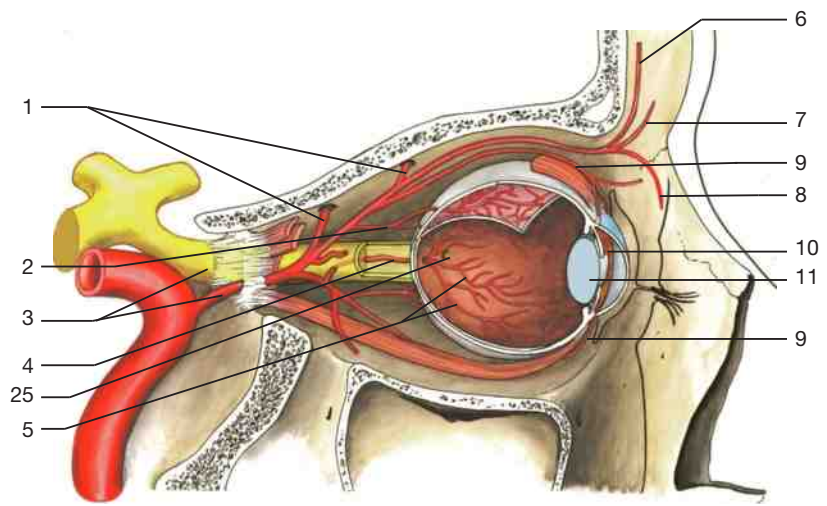
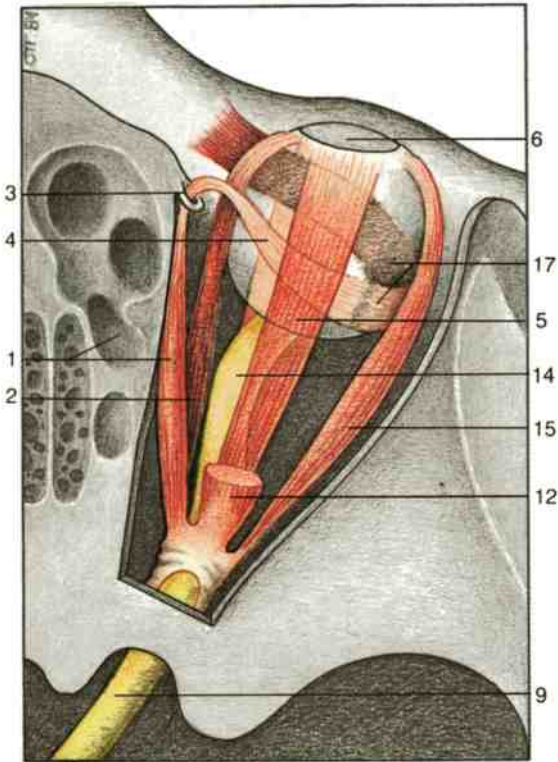
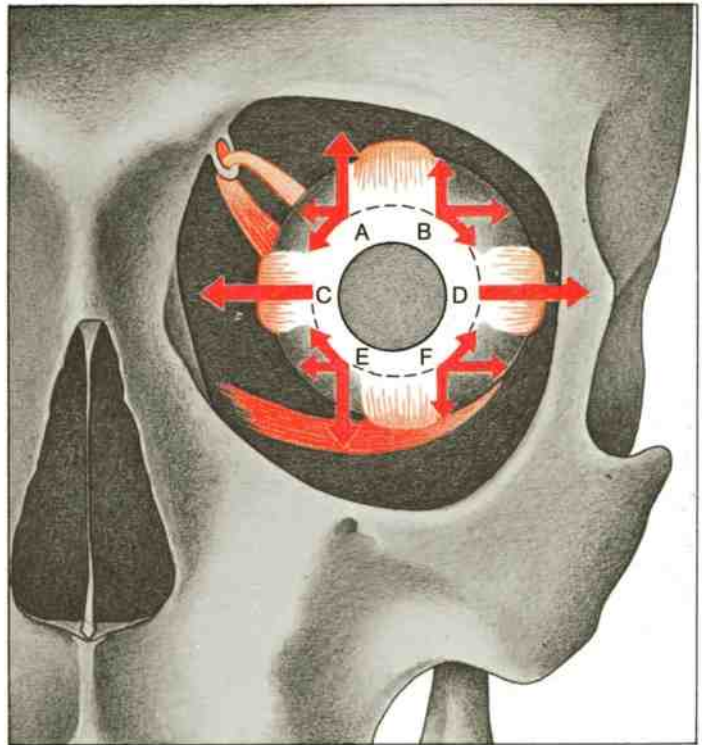


Diagram of the ophthalmic artery and its branches.

- 1 Posterior and anterior ethmoidal arteries
 - 2 Long and short posterior ciliary arteries
 - 3 Optic nerve and ophthalmic artery
 - 4 Central retinal artery
 - 5 Retinal arteries
 - 6 Supratrochlear artery
 - 7 Supra-orbital artery
 - 8 Dorsal nasal artery
 - 9 Anterior ciliary artery
 - 10 Iridial arteries
 - 11 Lens
 - 12 Iridial fold
 - 13 Pupillary margin of iris
 - 14 Anterior pole of lens
 - 15 Lesser circle of iris
 - 16 Greater circle of iris
 - 17 Margin of cornea or limbus
 - 18 Sclera
 - 19 Superior temporal artery and vein of retina
 - 20 Superior nasal artery and vein of retina
 - 21 Superior macular artery
 - 22 Optic disc
 - 23 Inferior macular artery
 - 24 Inferior temporal artery and vein
 - 25 Fovea centralis and macula lutea
 - 26 Superior temporal artery
 - 27 Superior nasal artery
 - 28 Inferior nasal artery
 - 29 Inferior temporal artery
- } of retina

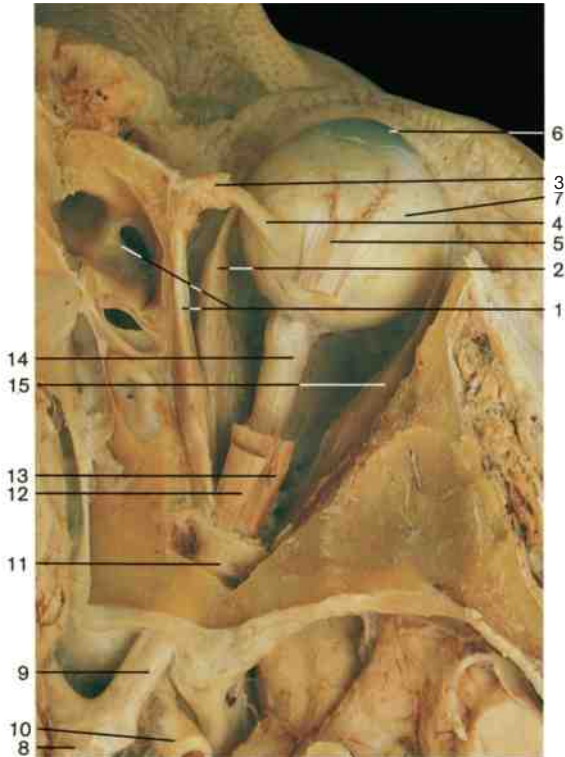


Schematic diagram of the extra-ocular muscles. Right orbit (from above). Levator palpebrae superioris muscle has been severed.

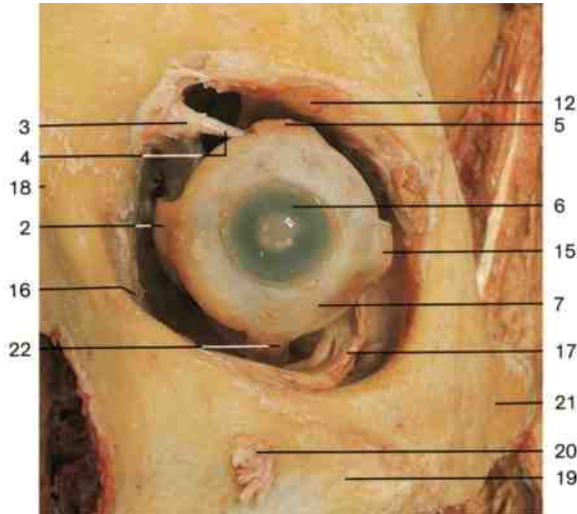


The action of the extra-ocular muscles. Left orbit (anterior aspect).

- | | |
|-----------------------------|-----------------------------|
| A = Superior rectus muscle | D = Lateral rectus muscle |
| B = Inferior oblique muscle | E = Inferior rectus muscle |
| C = Medial rectus muscle | F = Superior oblique muscle |

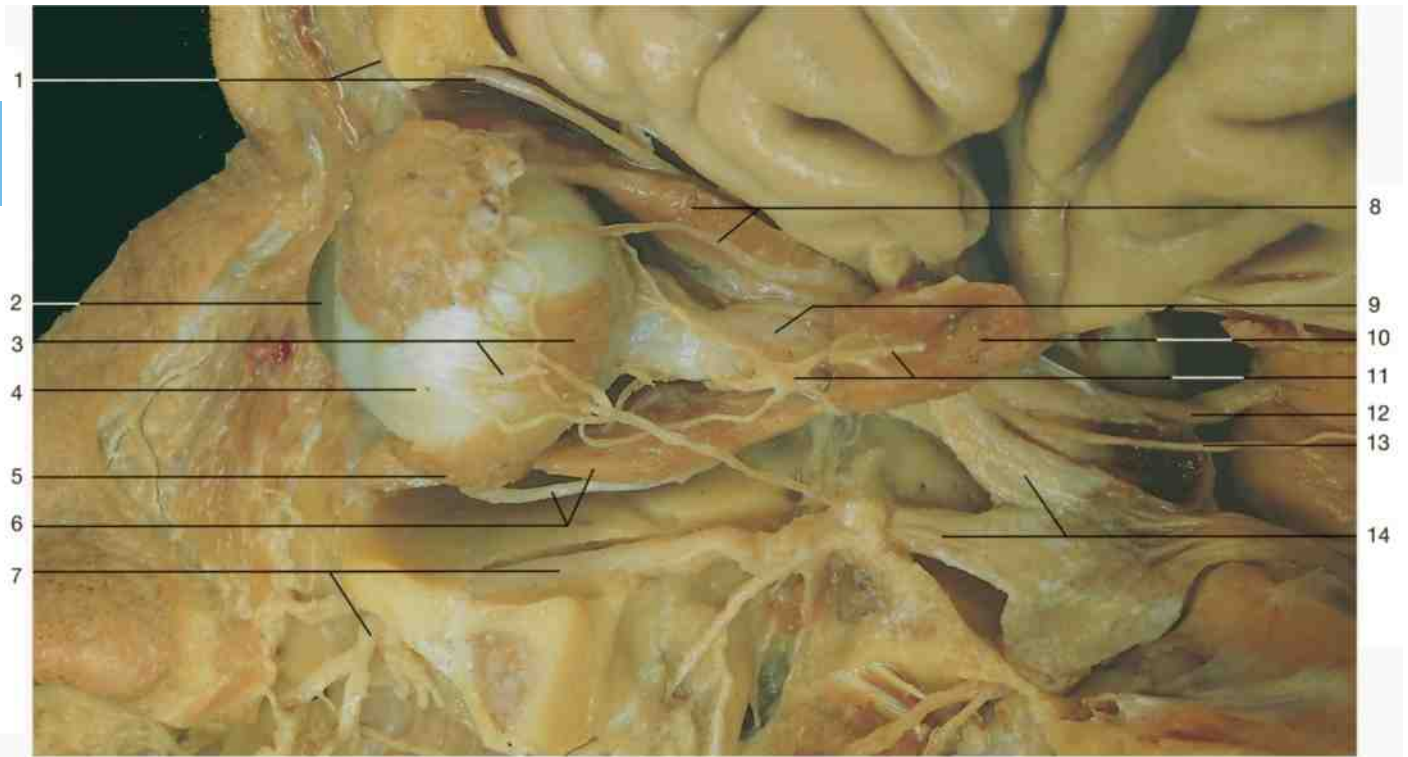
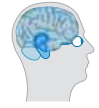

Right orbit with eyeball and extra-ocular muscles (from above). The roof of the orbit has been removed, the superior rectus muscle and the levator palpebrae superioris muscle have been severed.

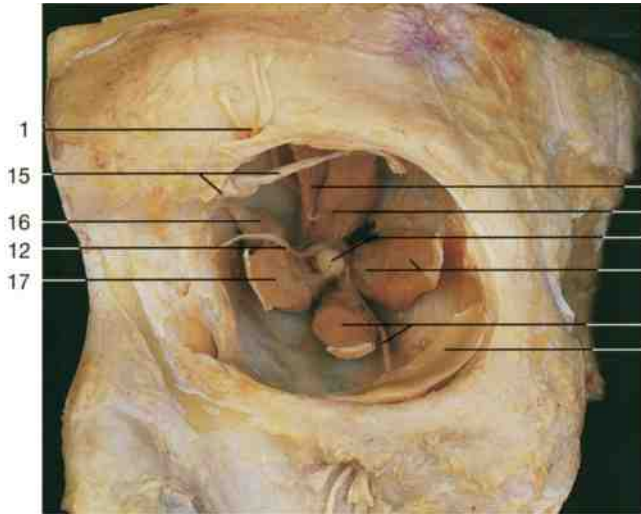


Left orbit with eyeball and extra-ocular muscles (anterior aspect). Lids, conjunctiva, and lacrimal apparatus have been removed.

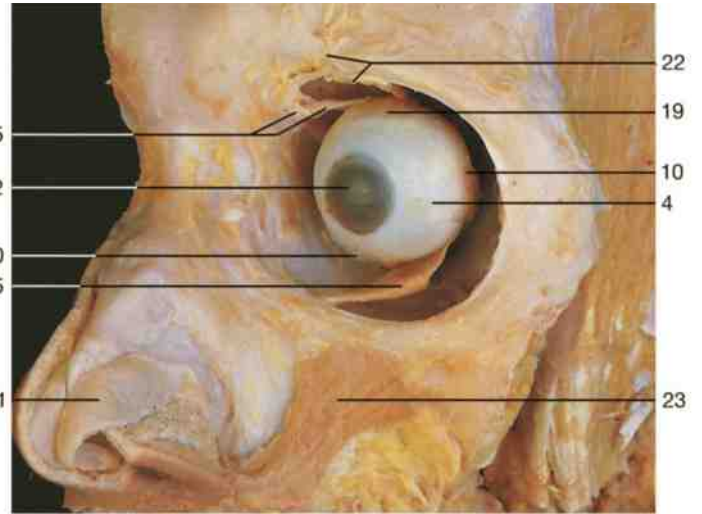
- | | |
|---|--|
| 1 Superior oblique muscle and ethmoid air cells | 12 Levator palpebrae superioris muscle |
| 2 Medial rectus muscle | 13 Superior rectus muscle |
| 3 Trochlea | 14 Optic nerve (extracranial part) |
| 4 Tendon of superior oblique muscle | 15 Lateral rectus muscle |
| 5 Superior rectus muscle | 16 Nasolacrimal duct |
| 6 Cornea | 17 Inferior oblique muscle |
| 7 Eyeball | 18 Nasal bone |
| 8 Optic chiasma | 19 Maxilla |
| 9 Optic nerve (intracranial part) | 20 Infra-orbital foramen and nerves |
| 10 Internal carotid artery | 21 Zygomatic bone |
| 11 Common annular tendon | 22 Inferior rectus muscle |



Extra-ocular muscles and their nerves (lateral aspect of left eye). Lateral rectus divided and reflected.



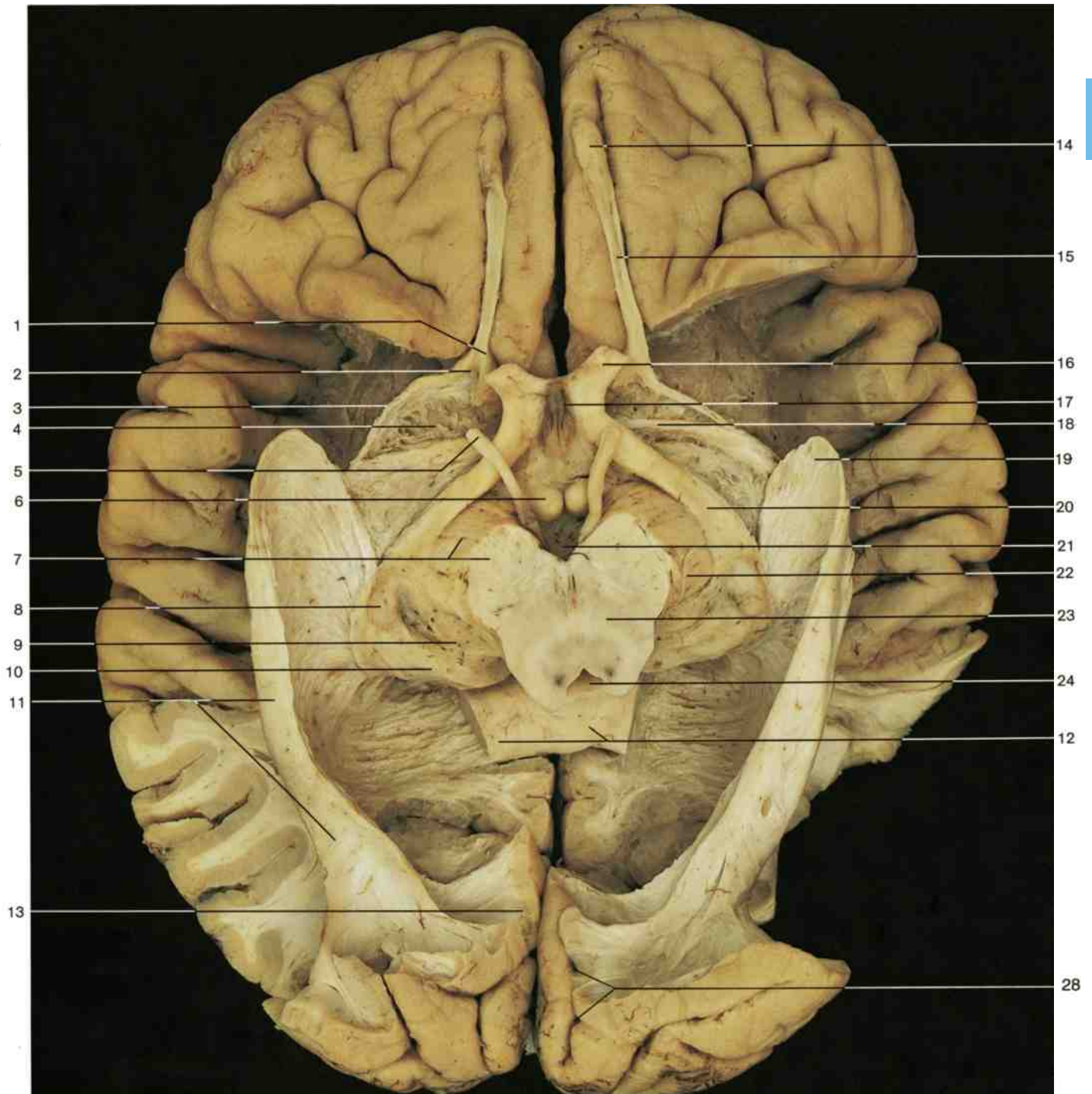
Left orbit with extra-ocular muscles (anterior aspect). Eyeball removed.



Extra-ocular eye muscles (antero-lateral aspect).

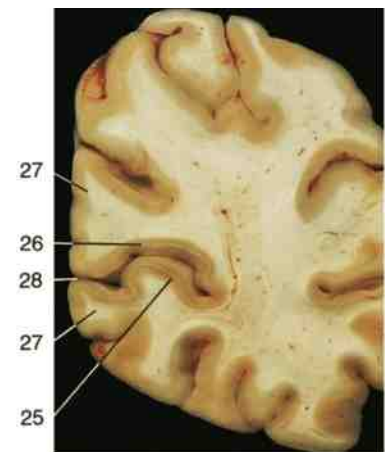
- 1 Supra-orbital nerve
- 2 Cornea
- 3 Insertion of lateral rectus muscle
- 4 Eyeball (sclera)
- 5 Inferior oblique muscle
- 6 Inferior rectus muscle and inferior branch of oculomotor nerve
- 7 Infra-orbital nerve
- 8 Superior rectus muscle and lacrimal nerve
- 9 Optic nerve
- 10 Lateral rectus muscle
- 11 Ciliary ganglion and abducens nerve (n. VI)

- 12 Oculomotor nerve (n. III)
- 13 Trochlear nerve (n. IV)
- 14 Ophthalmic nerve (n. V₁) and maxillary nerve (n. V₂)
- 15 Trochlea and tendon of superior oblique muscle
- 16 Superior oblique muscle
- 17 Medial rectus muscle
- 18 Levator palpebrae superioris muscle
- 19 Superior rectus muscle
- 20 Inferior rectus muscle
- 21 Greater alar cartilage
- 22 Supra-orbital nerve and levator palpebrae superioris muscle
- 23 Levator labii superioris muscle

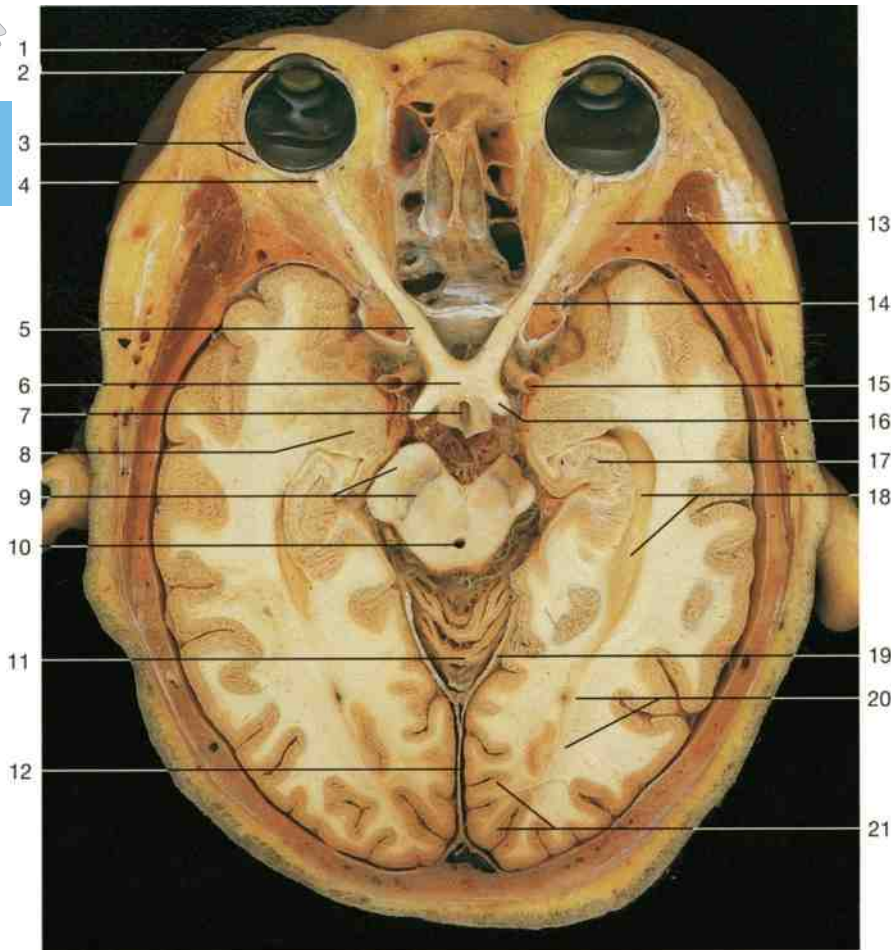


Dissection of the visual pathway (inferior aspect). Frontal pole at top, midbrain divided.

- | | |
|---|---|
| 1 Medial olfactory stria | 15 Olfactory tract |
| 2 Olfactory trigone | 16 Optic nerve (n. II) |
| 3 Lateral olfactory stria | 17 Infundibulum |
| 4 Anterior perforated substance | 18 Anterior commissure |
| 5 Oculomotor nerve (n. III) | 19 Genu of optic radiation |
| 6 Mamillary body | 20 Optic tract |
| 7 Cerebral peduncle | 21 Interpeduncular fossa and posterior perforated substance |
| 8 Lateral geniculate body | 22 Trochlear nerve (n. IV) |
| 9 Medial geniculate body | 23 Substantia nigra |
| 10 Pulvinar of thalamus | 24 Cerebral aqueduct |
| 11 Optic radiation | 25 Visual cortex |
| 12 Splenium of the corpus callosum (commissural fibers) | 26 Line of Gennari |
| 13 Cuneus | 27 Gyrus of striate cortex |
| 14 Olfactory bulb | 28 Calcarine sulcus |

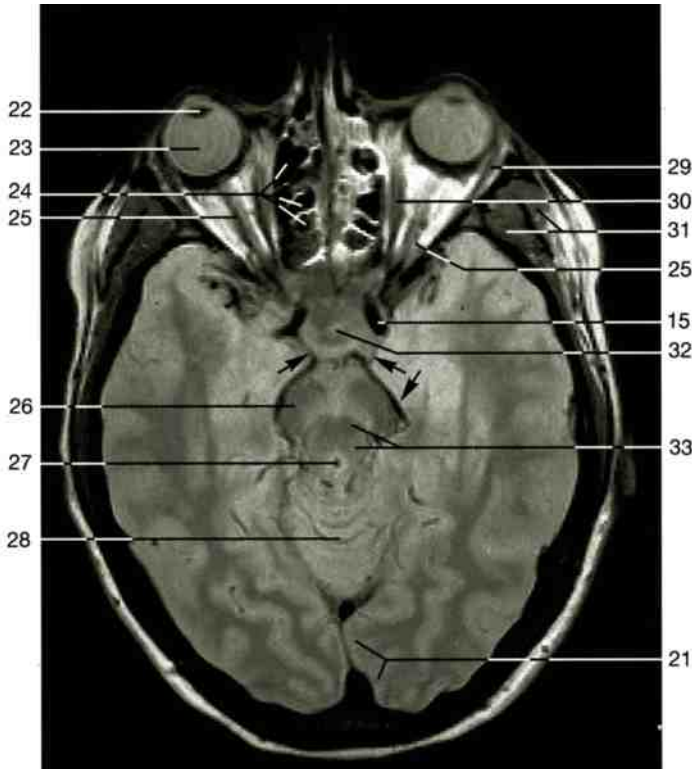


Frontal section of the striate cortex at the level of the striate area in the occipital lobe.



- 1 Upper lid
- 2 Cornea
- 3 Eyeball (sclera, retina)
- 4 Head of optic nerve
- 5 Optic nerve
- 6 Optic chiasma
- 7 Infundibular recess of hypothalamus
- 8 Amygdaloid body
- 9 Substantia nigra and crus cerebri
- 10 Cerebral aqueduct
- 11 Vermis of cerebellum
- 12 Falx cerebri
- 13 Lateral rectus muscle
- 14 Optic canal
- 15 Internal carotid artery
- 16 Optic tract
- 17 Hippocampus
- 18 Inferior horn of lateral ventricle
- 19 Tentorium cerebelli
- 20 Optic radiation of Gratiolet
- 21 Visual cortex (area calcarina, striate cortex)
- 22 Lens
- 23 Eyeball
- 24 Ethmoidal cells
- 25 Optic nerve with dura sheath
- 26 Cerebral peduncle
- 27 Aqueduct of mesencephalon
- 28 Vermis of cerebellum

Horizontal section through the head at the level of optic chiasma and striate cortex (superior aspect). Note the relationship of hypothalamic infundibulum to optic chiasma.



Horizontal section through the human head (MRI scan, courtesy of Prof. W. J. Huk, Erlangen, Germany). Arrows = branches of arterial circle of Willis.

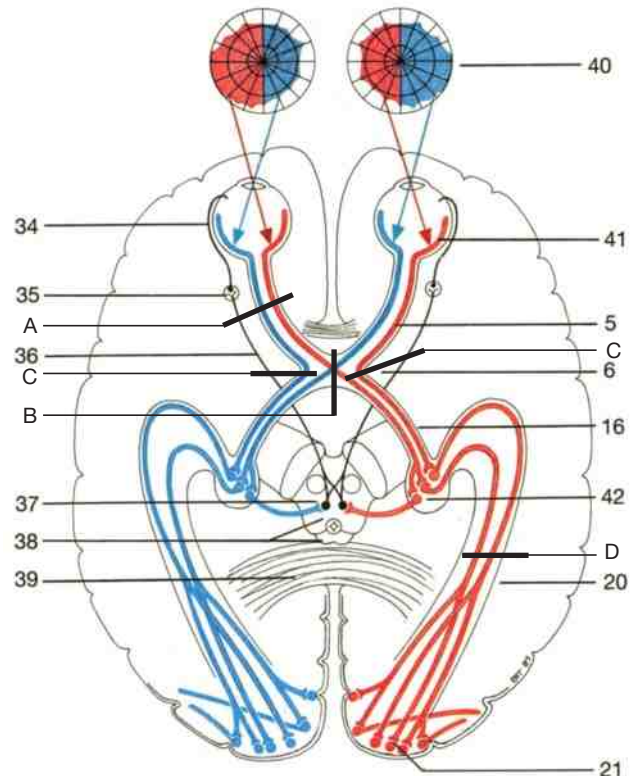
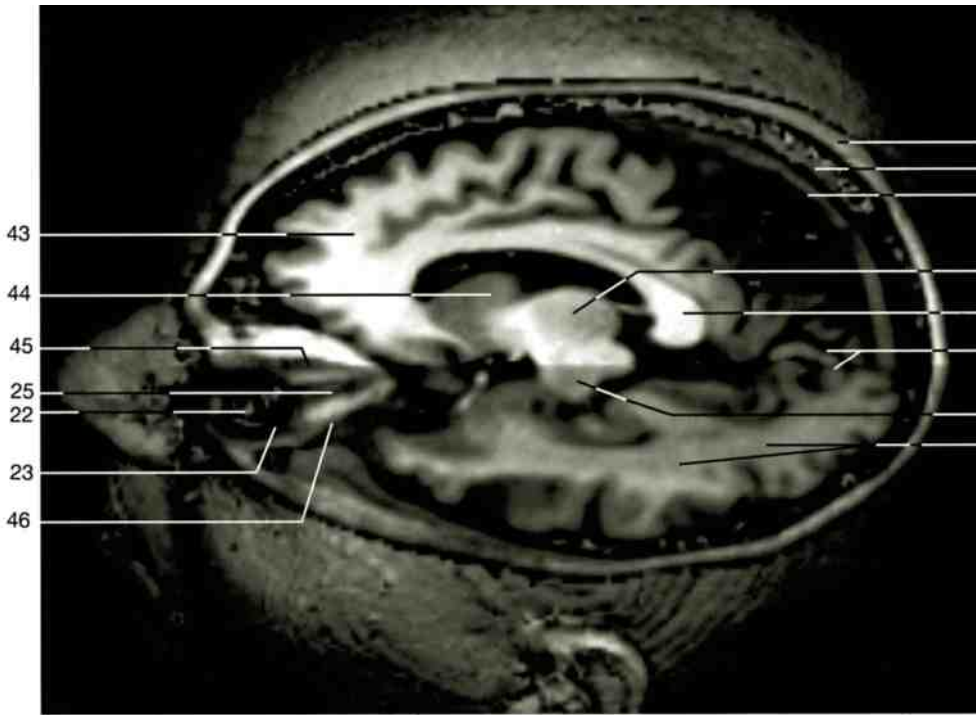
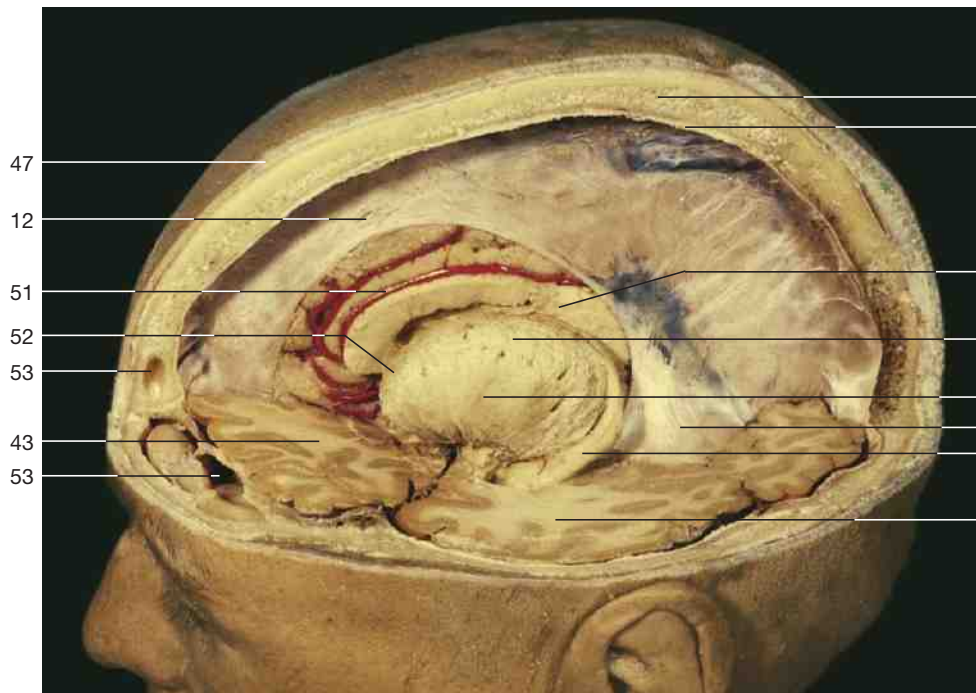


Diagram of the visual pathway and path of the light reflex.



3-D reconstruction of the human visual system (MRI scan flash 40°, courtesy of Prof. Huk, University of Erlangen, Germany).

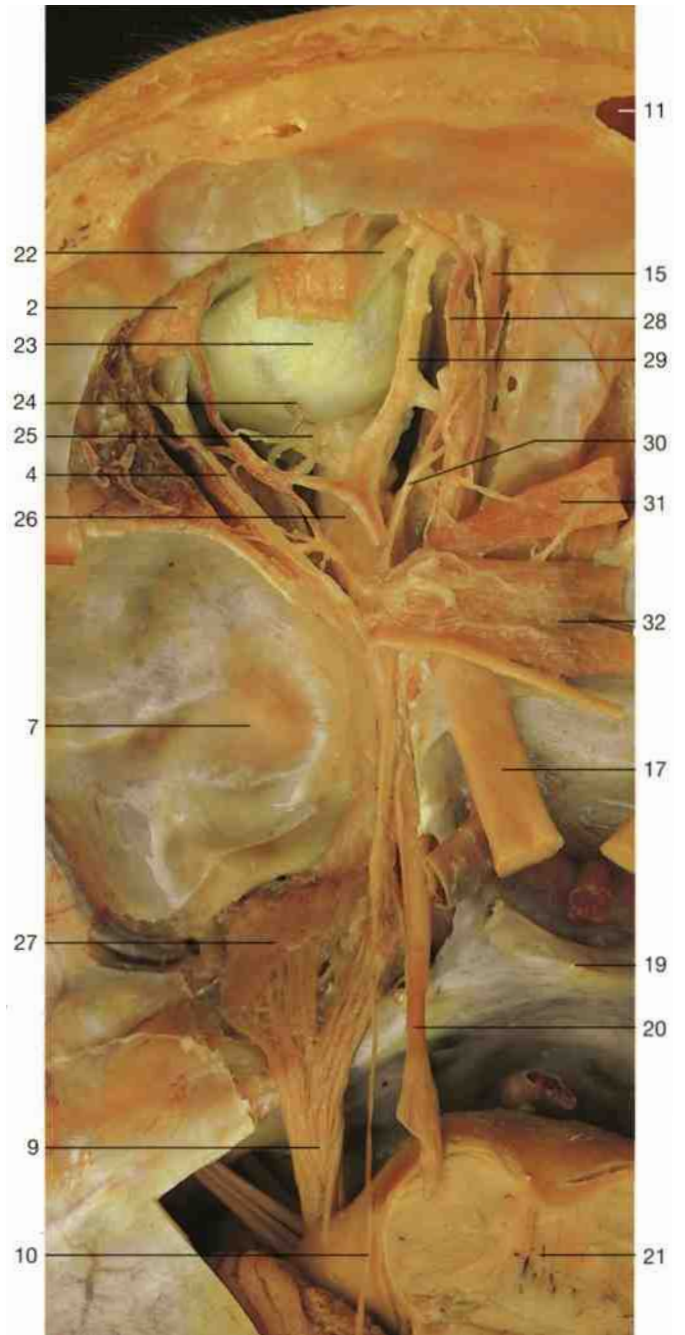- 29 Lateral rectus muscle
- 30 Medial rectus muscle
- 31 Temporalis muscle
- 32 Hypophysis (pituitary gland)
- 33 Midbrain
- 34 Ciliary nerves (long and short)
- 35 Ciliary ganglion
- 36 Oculomotor nerve
- 37 Accessory oculomotor nucleus
- 38 Colliculi of midbrain
- 39 Corpus callosum
- 40 Visual field
- 41 Retina
- 42 Lateral geniculate body
- 43 Frontal lobe
- 44 Caudate nucleus
- 45 Medial rectus muscle
- 46 Lateral rectus muscle
- 47 Skin
- 48 Diploe (skull)
- 49 Dura mater
- 50 Thalamus
- 51 Anterior cerebral artery
- 52 Caudate nucleus
- 53 Frontal sinus
- 54 Internal capsule
- 55 Lentiform nucleus (putamen)
- 56 Hippocampus
- 57 Temporal lobe of left hemisphere



Dissection of brain stem in situ. Left hemisphere has been partly removed (compare with MRI scan above).

In **binocular vision** the visual field (40) is projected upon portions of both retinae (blue and red in the drawing). In the chiasma the fibers from the two retinal portions are combined to form the left optic tract. The fibers of the two eyes remain separated from each other throughout the entire visual pathway up to their final termination in the calcarine cortex (21). **Injuries on the optic pathway** produce visual defects whose nature depends on the location of the injury. Destruction of one optic nerve (A) produces **blindness in the corresponding eye** with loss of pupillary

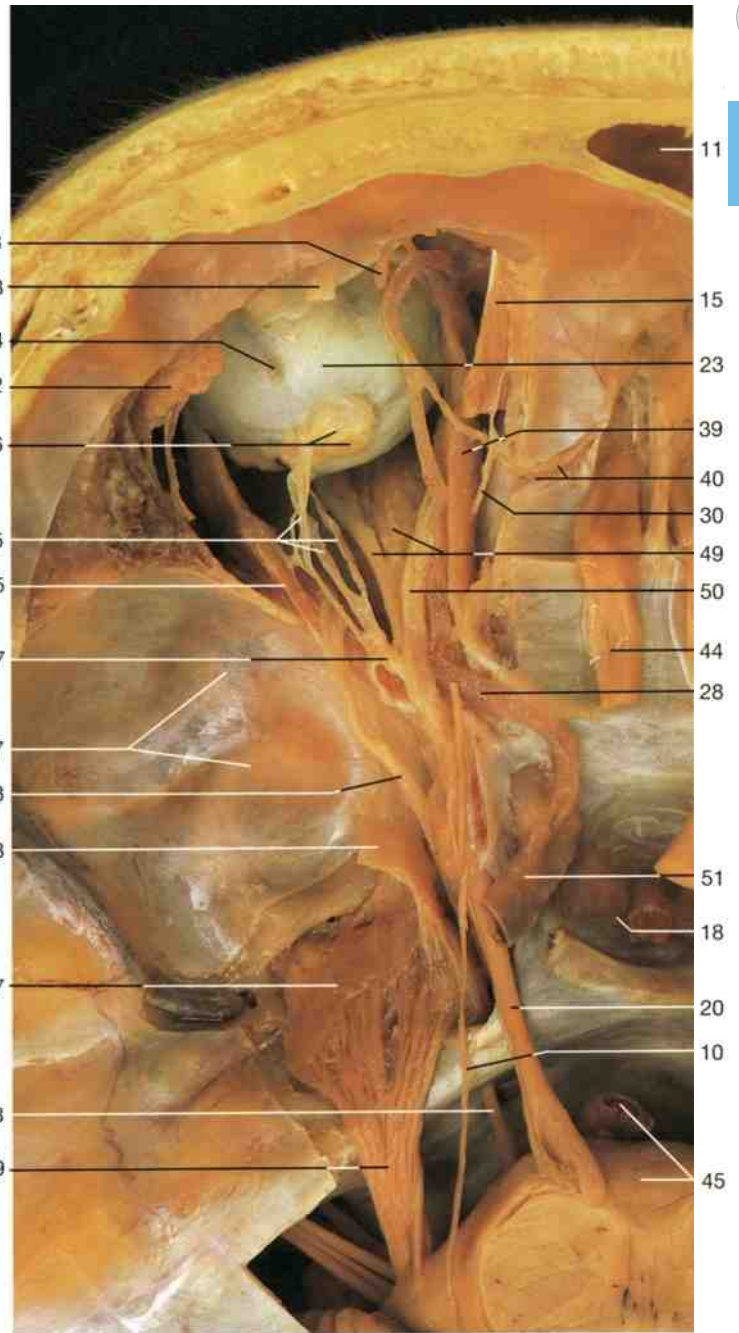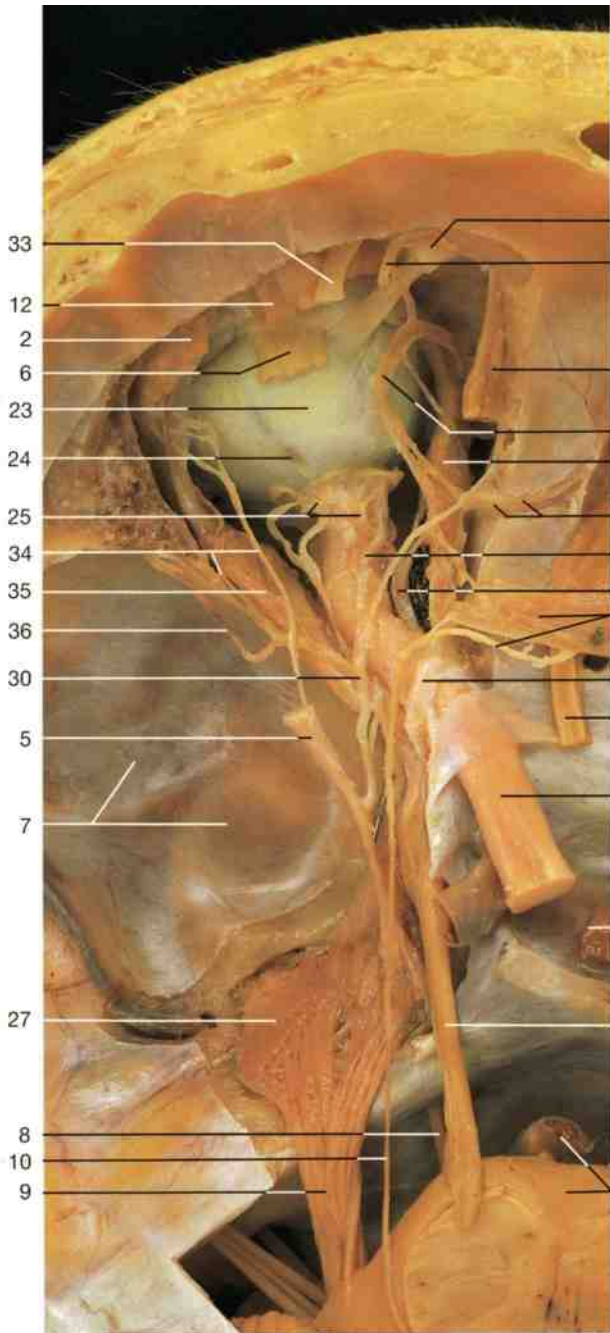
light reflex. If **lesions of the chiasma** destroy the crossing fibers of the nasal portions of the retina (B), both temporal fields of vision are lost (**bitemporal hemianopsia**). If both lateral angles of the chiasma are compressed (C), the nondecussating fibers from the temporal retinae are affected, resulting in loss of nasal visual fields (**binasal hemianopsia**). Lesions posterior to the chiasma (D) (i.e., optic tract, lateral geniculate body, optic radiation, or visual cortex) result in a loss of the entire opposite field of vision (**homonymous hemianopsia**).



Superficial layer of the left orbit (superior aspect). The roof of the orbit and a portion of the left tentorium have been removed.

Middle layer of the left orbit (superior aspect). The roof of the orbit has been removed and the superior extra-ocular muscles have been divided and reflected.

- | | | |
|-----------------------------------|---|--------------------------------------|
| 1 Lateral branch of frontal nerve | 10 Trochlear nerve (intracranial part) (n. IV) | 19 Dorsum sellae |
| 2 Lacrimal gland | 11 Frontal sinus | 20 Oculomotor nerve (n. III) |
| 3 Lacrimal vein | 12 Levator palpebrae superioris muscle | 21 Midbrain |
| 4 Lacrimal nerve | 13 Branches of supratrochlear nerve | 22 Tendon of superior oblique muscle |
| 5 Frontal nerve | 14 Olfactory bulb | 23 Eyeball |
| 6 Superior rectus | 15 Superior oblique muscle | 24 Vena vorticosa |
| 7 Middle cranial fossa | 16 Trochlear nerve (intra-orbital part) (n. IV) | 25 Short ciliary nerves |
| 8 Abducent nerve (n. VI) | 17 Optic nerve (intracranial part) | 26 Optic nerve (extracranial part) |
| 9 Trigeminal nerve (n. V) | 18 Pituitary gland and infundibulum | 27 Trigeminal ganglion |



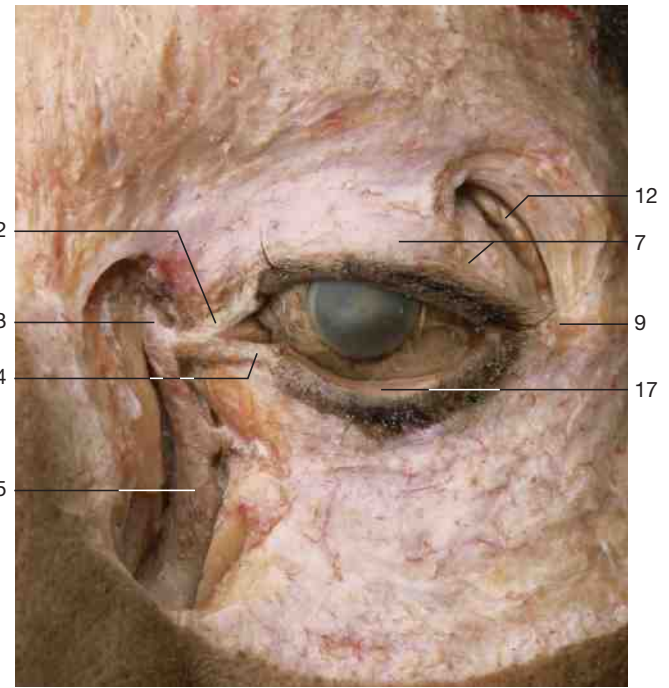
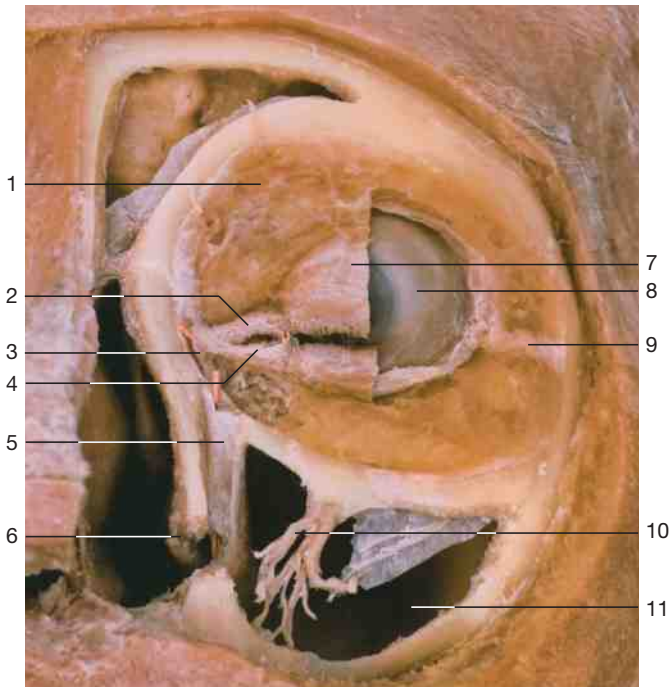
Middle layer of the left orbit (superior aspect). The roof of the orbit and the superior extra-ocular muscles have been removed.

Deeper layer of the left orbit (superior aspect). The optic nerve has now been removed.

- 28 Ophthalmic artery
- 29 Superior ophthalmic vein
- 30 Nasociliary nerve
- 31 Levator palpebrae superioris muscle (reflected)
- 32 Superior rectus muscle (reflected)
- 33 Lateral branch of supra-orbital nerve
- 34 Lacrimal nerve and artery
- 35 Lateral rectus muscle
- 36 Meningolacrimal artery (anastomosing with middle meningeal artery)

- 37 Trochlea
- 38 Medial branch of supra-orbital nerve
- 39 Medial rectus muscle
- 40 Anterior ethmoidal artery and nerve
- 41 Long ciliary nerve
- 42 Superior oblique muscle and trochlear nerve
- 43 Common tendinous ring
- 44 Olfactory tract

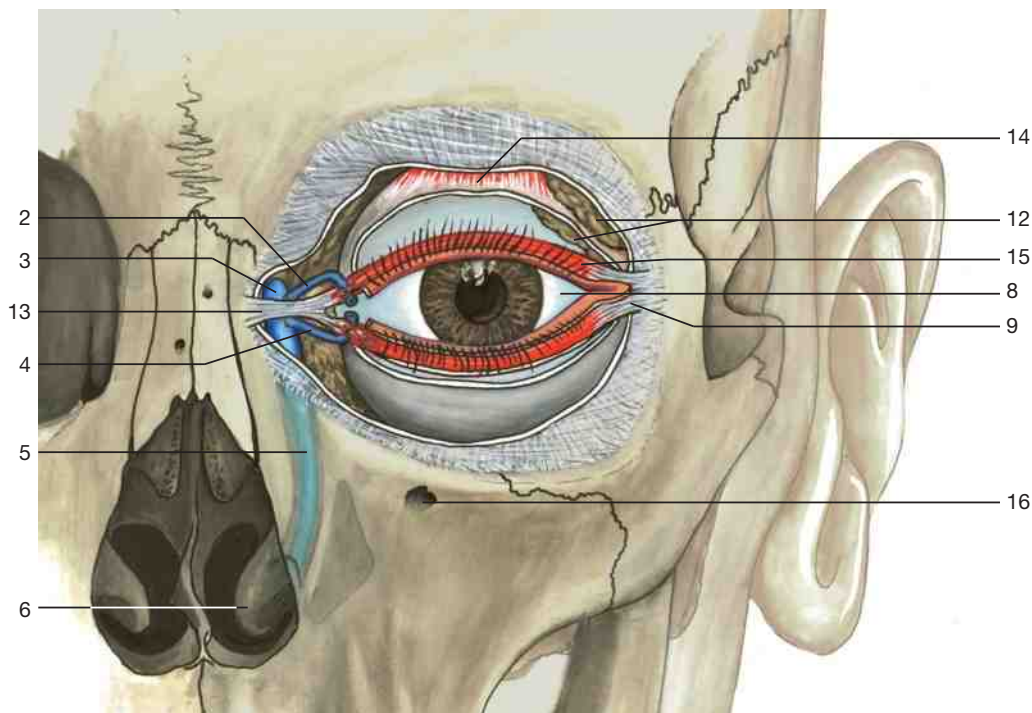
- 45 Basilar artery and pons
- 46 Optic nerve (external sheath of optic nerve, divided)
- 47 Ciliary ganglion
- 48 Ophthalmic nerve (divided, reflected)
- 49 Inferior branch of oculomotor nerve and inferior rectus muscle
- 50 Superior branch of oculomotor nerve
- 51 Internal carotid artery



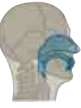Lids and lacrimal apparatus of the left eye. Parts of the eyelids have been removed to reveal the underlying eyeball. The maxillary sinus has been opened.

Lacrimal apparatus of the left eye.

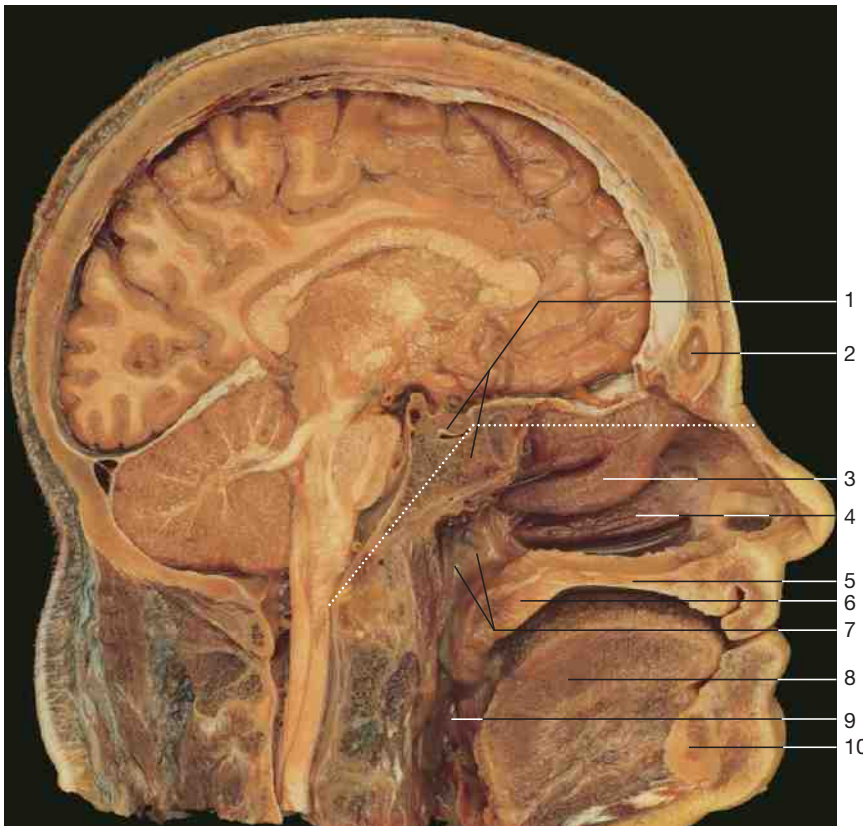
- | | |
|---------------------------------|---|
| 1 Orbicularis oculi muscle | 10 Infra-orbital artery and nerve |
| 2 Superior lacrimal canaliculus | 11 Maxillary sinus |
| 3 Lacrimal sac | 12 Lacrimal gland |
| 4 Inferior lacrimal canaliculus | 13 Medial palpebral ligament |
| 5 Nasolacrimal duct | 14 Aponeurosis of levator palpebrae superioris muscle |
| 6 Inferior nasal concha | 15 Palpebral portion of the orbicularis oculi muscle |
| 7 Upper eyelid | 16 Infra-orbital foramen |
| 8 Eyeball | 17 Palpebral conjunctiva of lower lid |
| 9 Lateral palpebral ligament | |



Lacrimal apparatus of the left eye (schematic drawing). Red = Palpebral portion of the orbicularis oculi muscle.



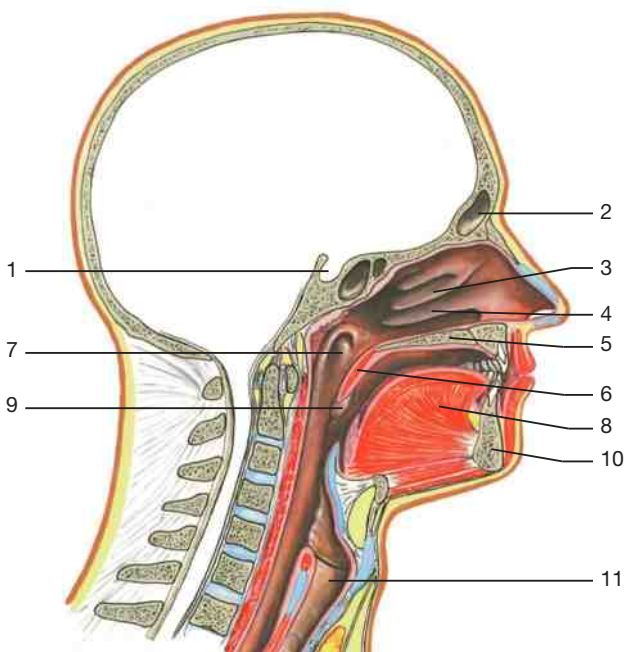
2.4 Oral and Nasal Cavities



Median sagittal section through the head. The palate separates nasal and oral cavities. The base of the skull forms an angle of about 150° at the sella turcica (dotted line).

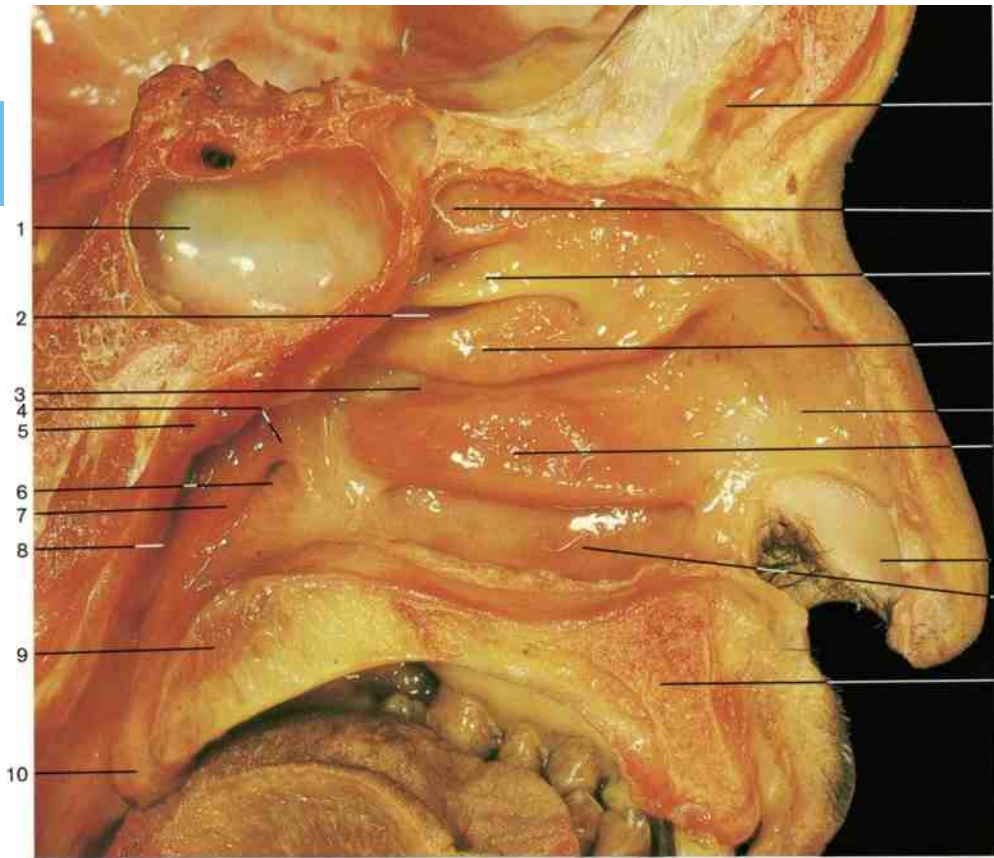
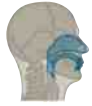During evolution, the oral and nasal cavities of the human head were situated upon each other, so the human face developed in the frontal plane. The **nasal cavities** are separated by the nasal septum. They contain three conchae, where openings to the ethmoidal and maxillary sinus are located. Posteriorly the two nasal cavities open into the nasopharynx through the choanae.

The **oral cavity** is separated from the nasal cavity by the palate. When the mouth is closed, the oral cavity is fully occupied by the tongue, which is characterized by its high mobility, necessary for the development of speech and song. Specific lymphatic organs (tonsils) are located at the entrance of the nasopharynx in both the nasal and oral cavities to protect the digestive tract from infection. The respiratory and digestive tracts cross each other within the nasopharynx, the most important requirement for the development of speech.



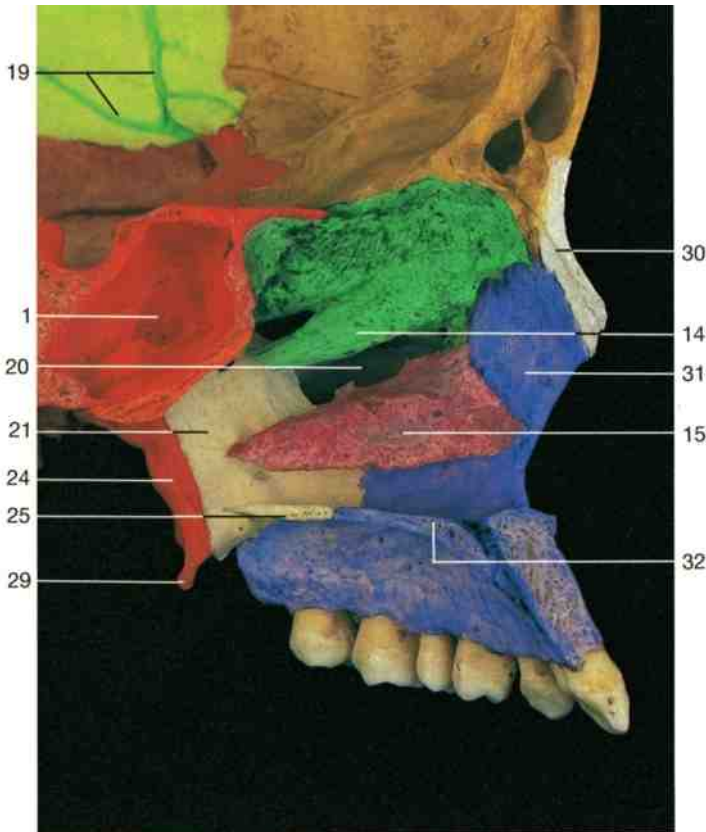
Median sagittal section through the head (schematic drawing). The tongue has been disposed to show the connection of the oral cavity with the pharynx and the position of the palatine tonsil.

- 1 Hypophysis within hypophysial fossa
- 2 Frontal sinus
- 3 Middle nasal concha
- 4 Inferior nasal concha
- 5 Hard palate
- 6 Soft palate
- 7 Pharynx with auditory tube
- 8 Tongue
- 9 Pharynx with palatine tonsil
- 10 Mandible
- 11 Larynx

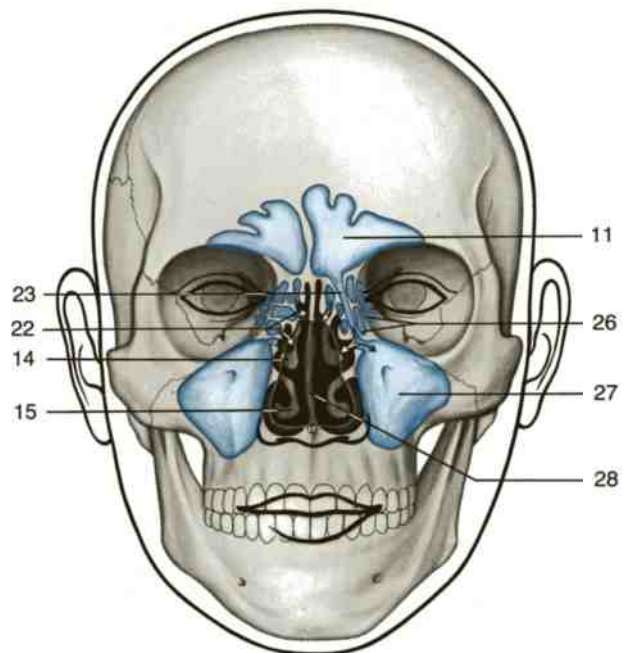


- 1 Sphenoidal sinus
- 2 Superior meatus
- 3 Middle meatus
- 4 Tubal elevation
- 5 Pharyngeal tonsil
- 6 Pharyngeal orifice of auditory tube
- 7 Salpingopharyngeal fold
- 8 Pharyngeal recess
- 9 Soft palate
- 10 Uvula
- 11 Frontal sinus
- 12 Spheno-ethmoidal recess
- 13 Superior nasal concha
- 14 Middle nasal concha
- 15 Inferior nasal concha
- 16 Vestibule
- 17 Inferior meatus
- 18 Hard palate
- 19 Grooves for the middle meningeal artery and parietal bone (yellow)
- 20 Maxillary hiatus
- 21 Perpendicular process of palatine bone
- 22 Openings of ethmoidal air cells
- 23 Opening of frontal sinus
- 24 Medial pterygoid plate (red)
- 25 Horizontal plate of palatine process
- 26 Ethmoidal air cells
- 27 Maxillary sinus
- 28 Nasal septum
- 29 Pterygoid hamulus
- 30 Nasal bone (white)
- 31 Frontal process of maxilla (violet)
- 32 Palatine process of maxilla (violet)
- 33 Nasal atrium

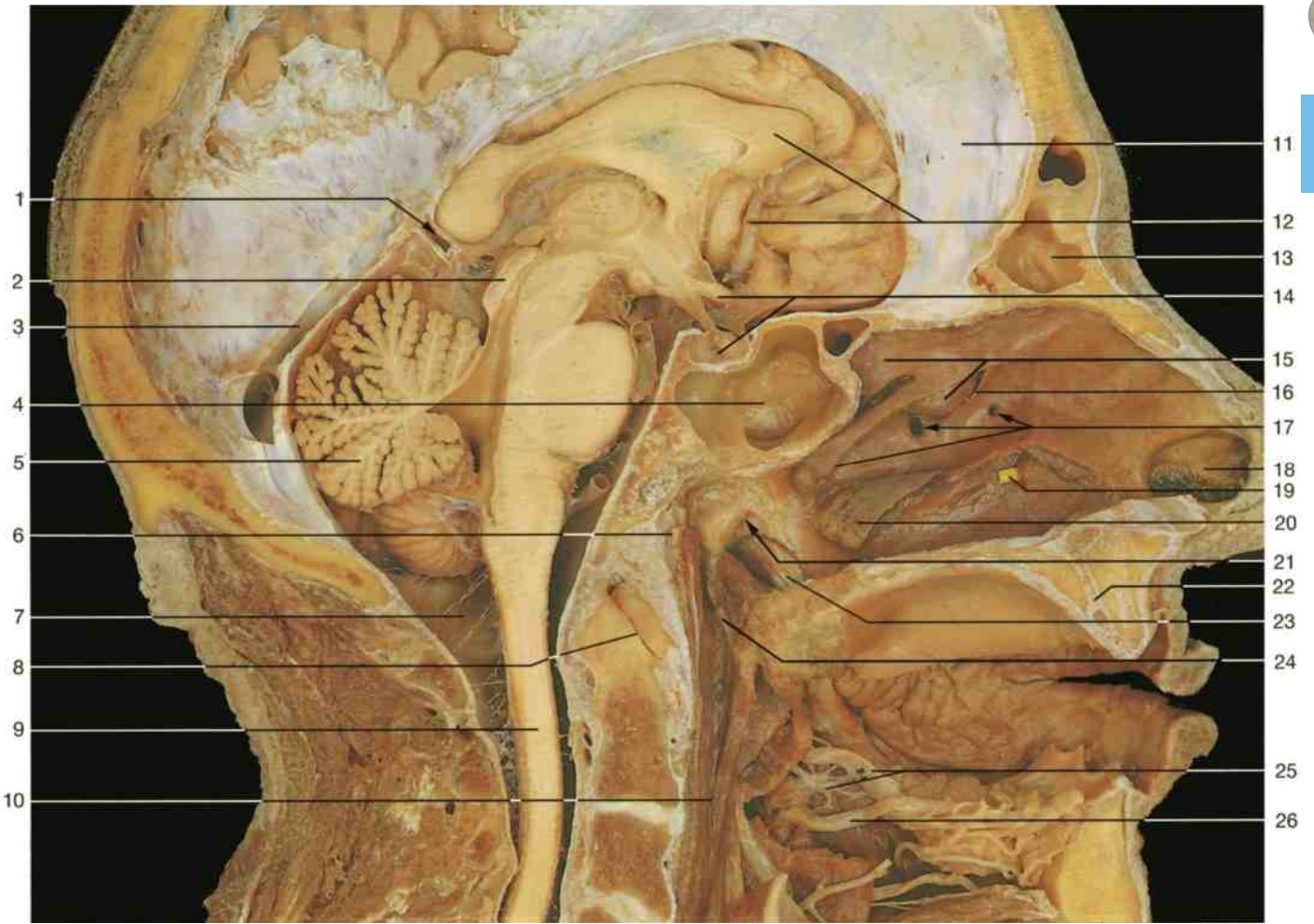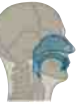Lateral wall of the nasal cavity. Septum removed.



Bones of left nasal cavity (medial aspect).

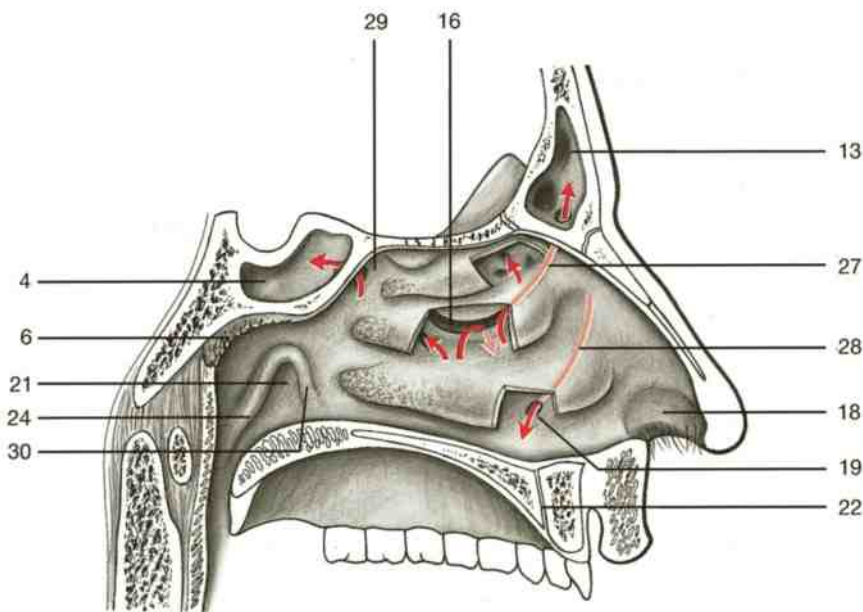


Schematic diagram showing the position of paranasal sinuses. Openings indicated by arrows.



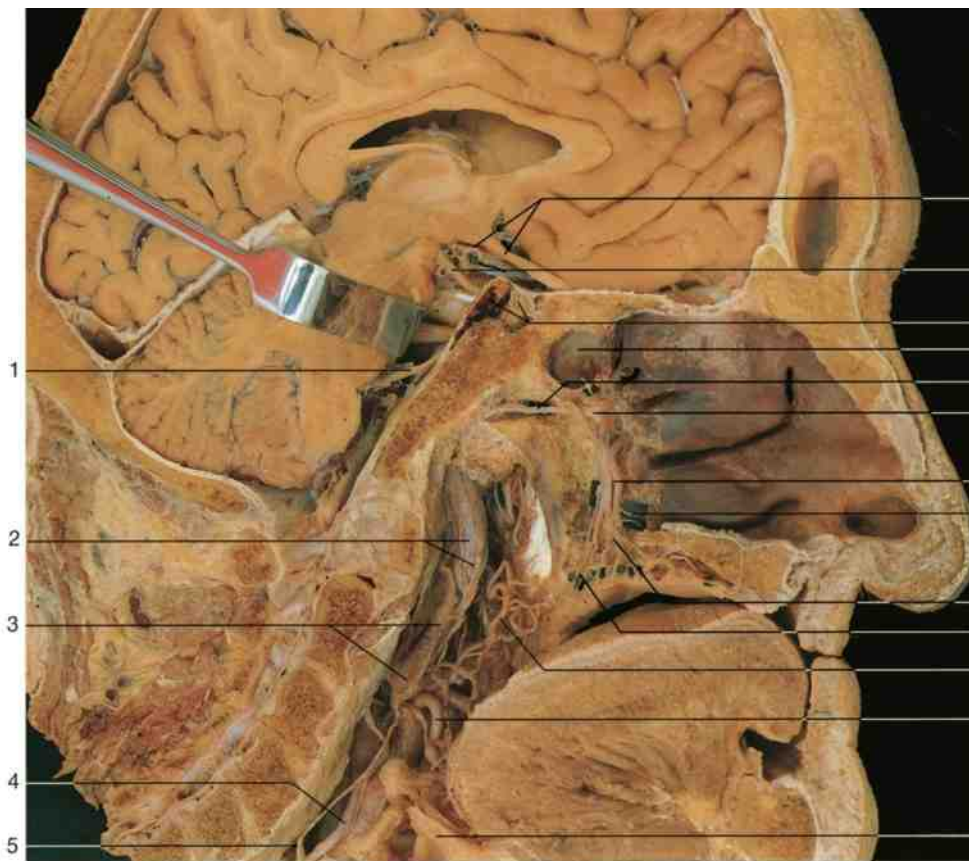
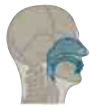Median section through the head with nasal and oral cavities. The middle and inferior nasal conchae have been partly removed to show the openings of paranasal sinuses.

- | | | | |
|---|------------------------------------|----|----------------------------|
| 1 | Great cerebral vein (Galen's vein) | 6 | Pharyngeal tonsil |
| 2 | Tectum of midbrain | 7 | Cerebellomedullary cistern |
| 3 | Straight sinus | 8 | Median atlanto-axial joint |
| 4 | Sphenoidal sinus | 9 | Spinal cord |
| 5 | Cerebellum | 10 | Oral part of pharynx |




Lateral wall of nasal cavity. Openings indicated by red arrows (schematic drawing).

- | | |
|----|---|
| 11 | Falx cerebri |
| 12 | Corpus callosum and anterior cerebral artery |
| 13 | Frontal sinus |
| 14 | Optic chiasm and pituitary gland |
| 15 | Superior nasal concha and ethmoidal bulla |
| 16 | Semilunar hiatus |
| 17 | Accessory openings to maxillary sinus and cut edge of middle nasal concha |
| 18 | Vestibule |
| 19 | Opening of nasolacrimal duct |
| 20 | Inferior nasal concha (cut) |
| 21 | Opening of auditory tube |
| 22 | Incisive canal |
| 23 | Levator veli palatini muscle |
| 24 | Salpingopharyngeal fold |
| 25 | Lingual nerve and submandibular ganglion |
| 26 | Submandibular duct |
| 27 | Nasofrontal duct |
| 28 | Nasolacrimal duct |
| 29 | Spheno-ethmoidal recess (of Rosenmüller) |
| 30 | Salpingopalatine fold |



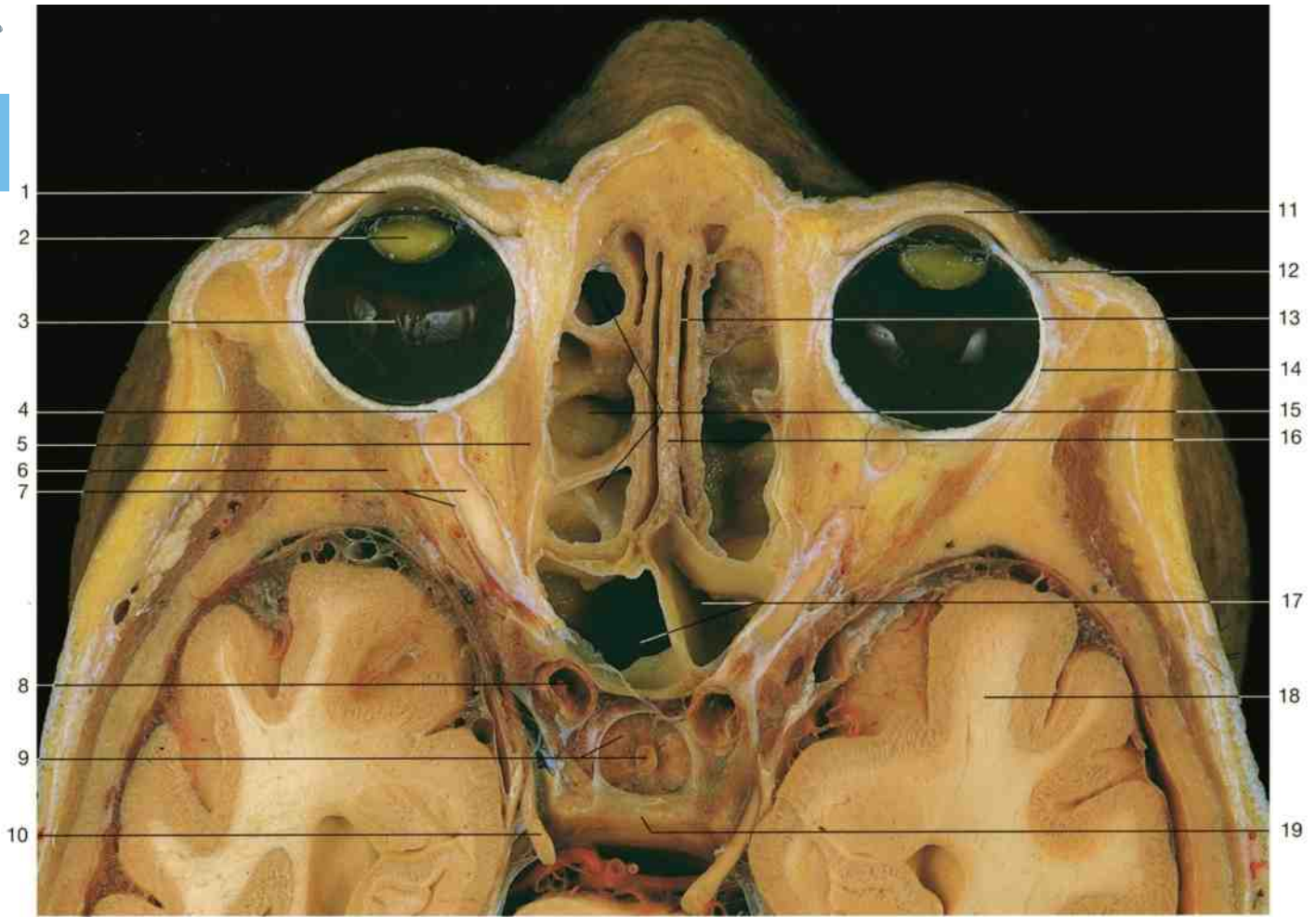
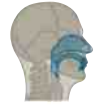Nerves of the lateral wall of nasal cavity. Sagittal section through the head. Mucous membranes partly removed, pterygoid canal opened.

- 1 Facial nerve
- 2 Internal carotid artery and internal carotid plexus
- 3 Superior cervical ganglion
- 4 Vagus nerve
- 5 Sympathetic trunk
- 6 Optic nerve and ophthalmic artery
- 7 Oculomotor nerve
- 8 Internal carotid artery and cavernous sinus
- 9 Sphenoidal sinus
- 10 Nerve of the pterygoid canal
- 11 Pterygopalatine ganglion
- 12 Descending palatine artery
- 13 Lateral inferior posterior nasal branches and lateral posterior nasal and septal arteries
- 14 Greater palatine nerves and artery
- 15 Lesser palatine nerves and arteries
- 16 Branches of ascending pharyngeal artery
- 17 Lingual artery
- 18 Epiglottis

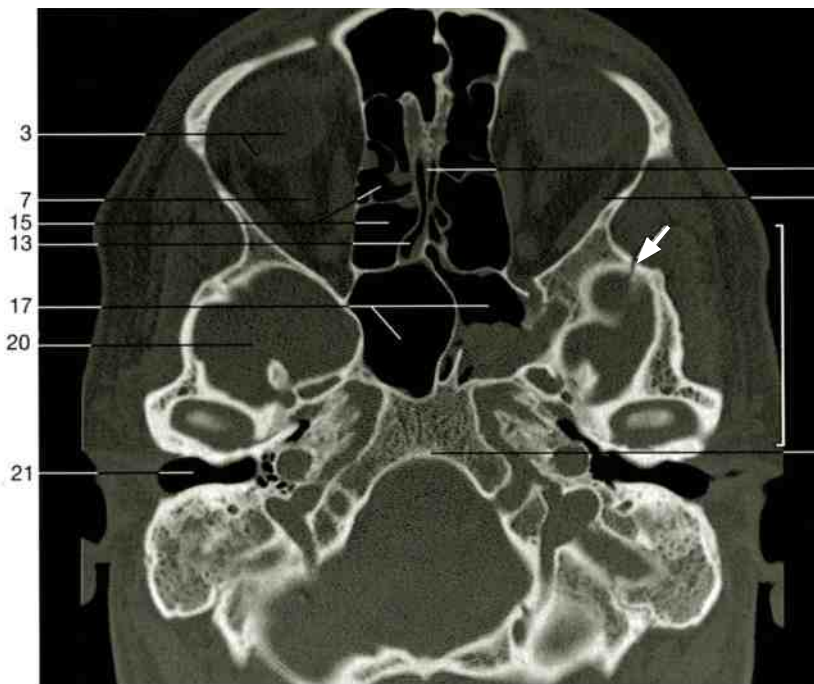


Nasal septum. Dissection of nerves and vessels.

- 19 Anterior ethmoidal artery
- 20 Olfactory bulb
- 21 Olfactory tract
- 22 Nasopalatine nerve
- 23 Choanae
- 24 Frontal sinus
- 25 Crista galli
- 26 Anterior ethmoidal artery and nerve, and nasal branch of anterior ethmoidal artery
- 27 Nasal septum
- 28 Septal artery
- 29 Crest of nasal septum
- 30 Hard palate
- 31 Tentorium cerebelli
- 32 Trochlear nerve
- 33 Trigeminal nerve with motor root
- 34 Internal carotid plexus
- 35 Lingual nerve with chorda tympani
- 36 Medial pterygoid muscle and medial pterygoid plate
- 37 Inferior alveolar nerve
- 38 Sympathetic trunk
- 39 Oculomotor nerve
- 40 Palatine nerves
- 41 Tongue
- 42 Trigeminal ganglion
- 43 Trigeminal nerve (n. V)
- 44 Facial nerve (n. VII)
- 45 Geniculate ganglion
- 46 Stylomastoid foramen
- 47 Medial pterygoid muscle

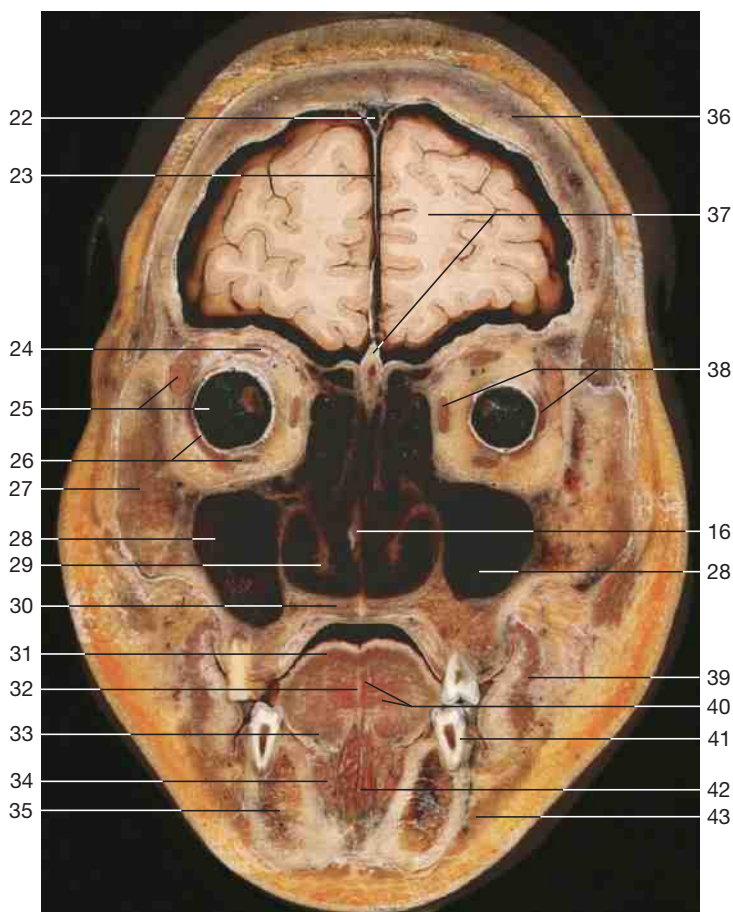
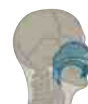

Horizontal section through the nasal cavity, the orbits, and temporal lobes of the brain at the level of pituitary gland.

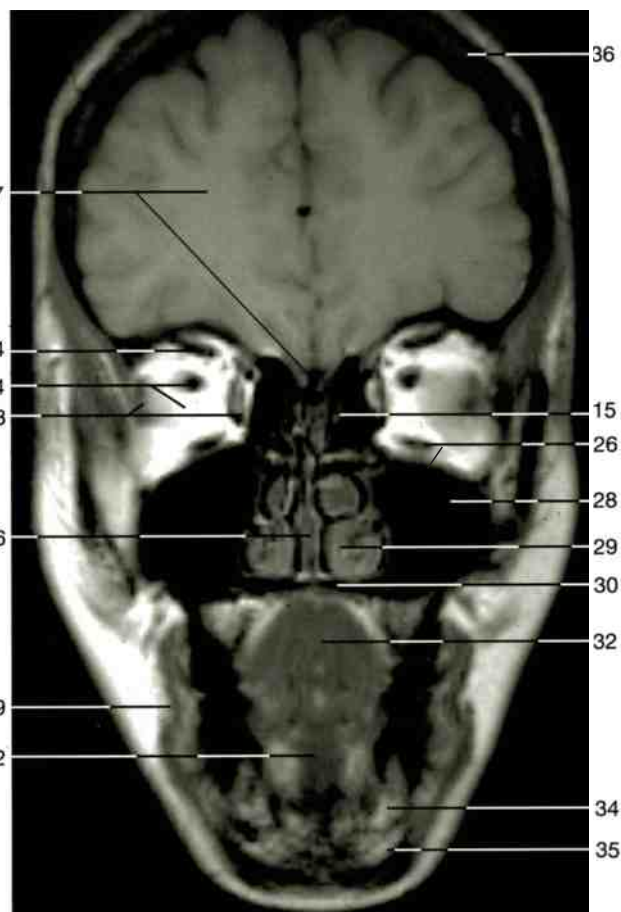


Horizontal section through the head. CT scan. Bar = 2 cm.
Arrow: fracture.

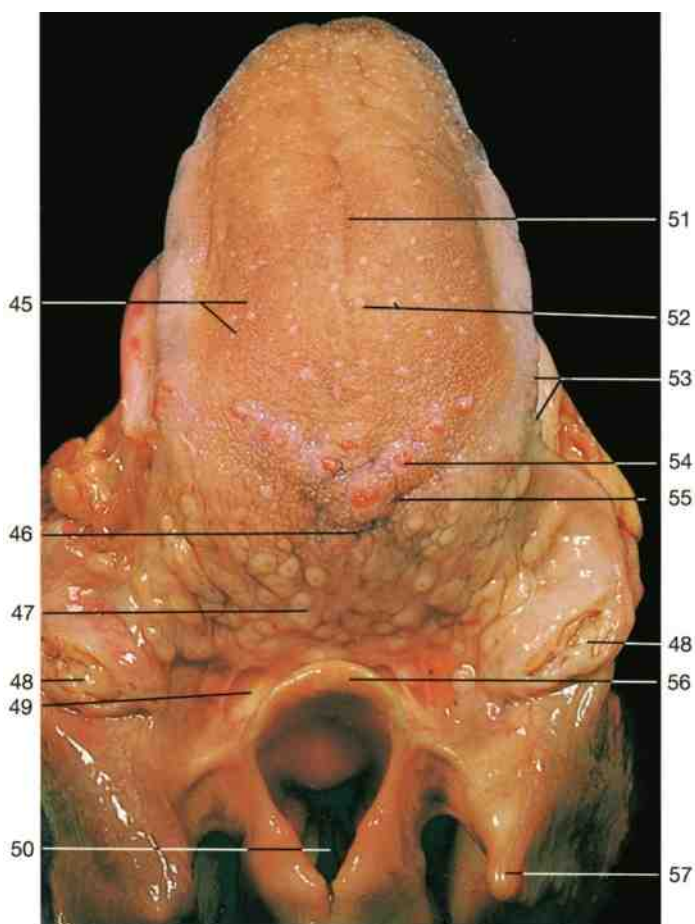
- 1 Cornea
- 2 Lens
- 3 Vitreous body (eyeball)
- 4 Head of optic nerve
- 5 Medial rectus muscle
- 6 Lateral rectus muscle
- 7 Optic nerve with dural sheath
- 8 Internal carotid artery
- 9 Pituitary gland and infundibulum
- 10 Oculomotor nerve
- 11 Superior tarsal plate of eyelid
- 12 Fornix of conjunctiva
- 13 Nasal cavity
- 14 Sclera
- 15 Ethmoidal sinus
- 16 Nasal septum
- 17 Sphenoidal sinus
- 18 Temporal lobe
- 19 Clivus
- 20 Middle cranial fossa
- 21 External acoustic meatus
- 22 Superior sagittal sinus
- 23 Falx cerebri
- 24 Superior rectus and levator palpebrae superioris muscles
- 25 Eyeball and lacrimal gland
- 26 Inferior rectus and inferior oblique muscles
- 27 Zygomatic bone
- 28 Maxillary sinus
- 29 Inferior nasal concha
- 30 Hard palate



Coronal section through the head at the level of the second premolar of the mandible.

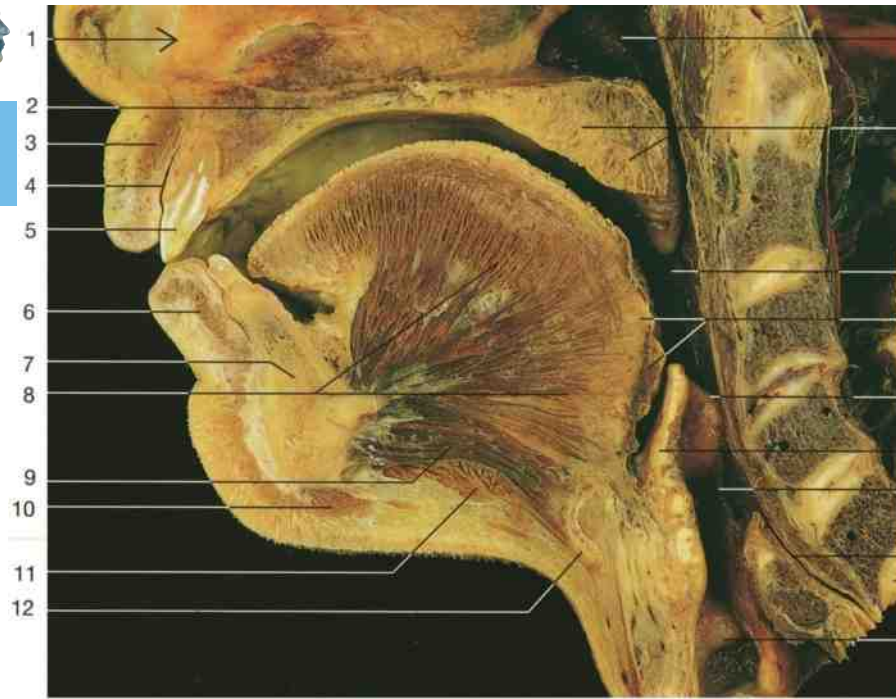
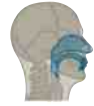
Coronal section through the head (MRI scan, courtesy of Prof. Heuck, Munich, Germany). Note the situation of the head cavities.



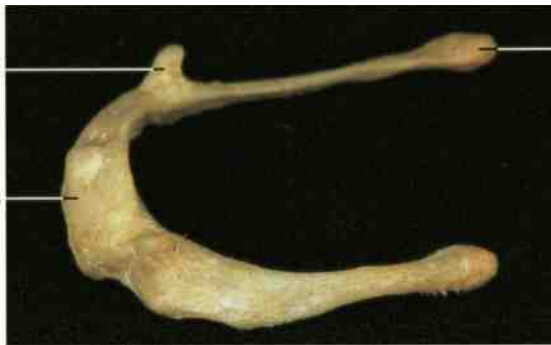- 31 Superior longitudinal muscle of tongue
- 32 Lingual septum
- 33 Inferior longitudinal muscle of tongue
- 34 Sublingual gland
- 35 Mandible
- 36 Calvaria
- 37 Frontal lobe of brain and crista galli
- 38 Lateral and medial rectus muscles
- 39 Buccinator muscle
- 40 Vertical and transverse muscles of tongue
- 41 Second premolar of mandible
- 42 Genioglossus muscle
- 43 Platysma muscle
- 44 Orbit and optic nerve
- 45 Filiform papillae
- 46 Foramen cecum
- 47 Root of tongue (lingual tonsil)
- 48 Palatine tonsil
- 49 Vallecula of epiglottis
- 50 Vestibule of larynx
- 51 Median sulcus of tongue
- 52 Fungiform papillae
- 53 Foliate papillae
- 54 Circumvallate papilla
- 55 Sulcus terminalis
- 56 Epiglottis
- 57 Greater cornu of hyoid bone

◁ Dorsal surface of the tongue and laryngeal inlet.

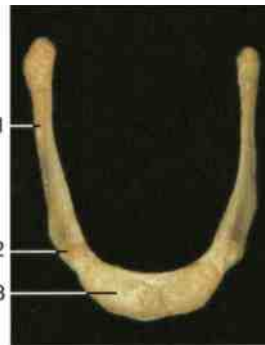

- 1 Nasal cavity
- 2 Hard palate
- 3 Upper lip and orbicularis oris muscle
- 4 Vestibule of oral cavity
- 5 First incisor
- 6 Lower lip and orbicularis oris muscle
- 7 Mandible
- 8 Genioglossus muscle
- 9 Geniohyoid muscle
- 10 Anterior belly of diaphragm muscle
- 11 Mylohyoid muscle
- 12 Hyoid bone
- 13 Nasopharynx
- 14 Soft palate and uvula
- 15 Oropharynx
- 16 Root of tongue and lingual tonsil
- 17 Laryngopharynx
- 18 Epiglottis
- 19 Ary-epiglottic fold
- 20 Laryngopharynx continuous with esophagus
- 21 Larynx

Median sagittal section through the oral cavity and pharynx.

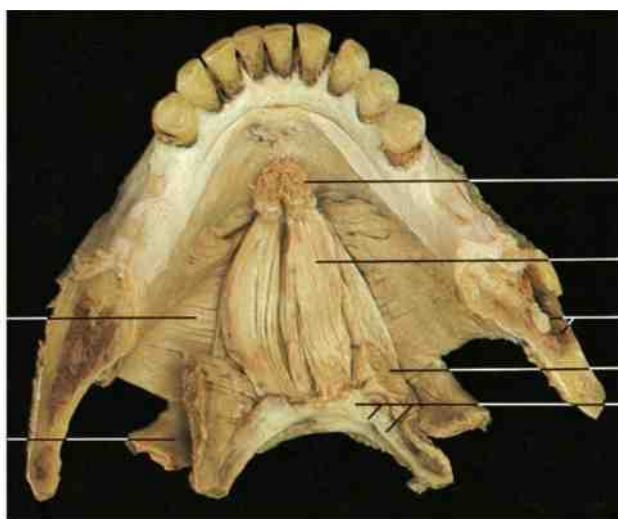


Hyoid bone (oblique lateral aspect).



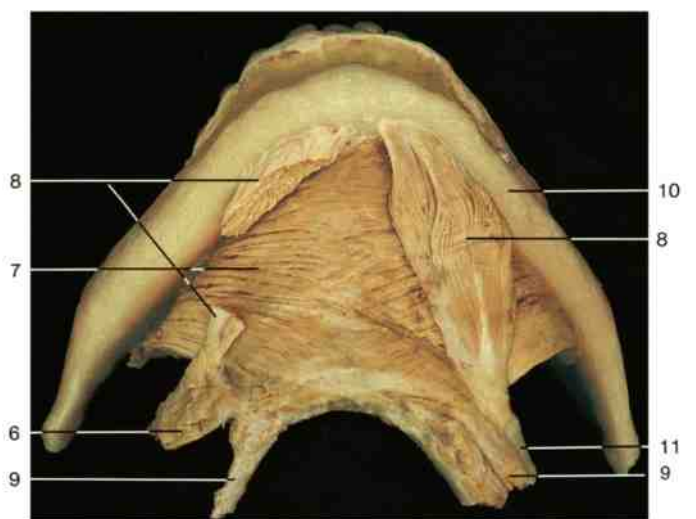
Hyoid bone (anterior aspect).

- 1 Greater cornu
 - 2 Lesser cornu
 - 3 Body
- } of hyoid bone



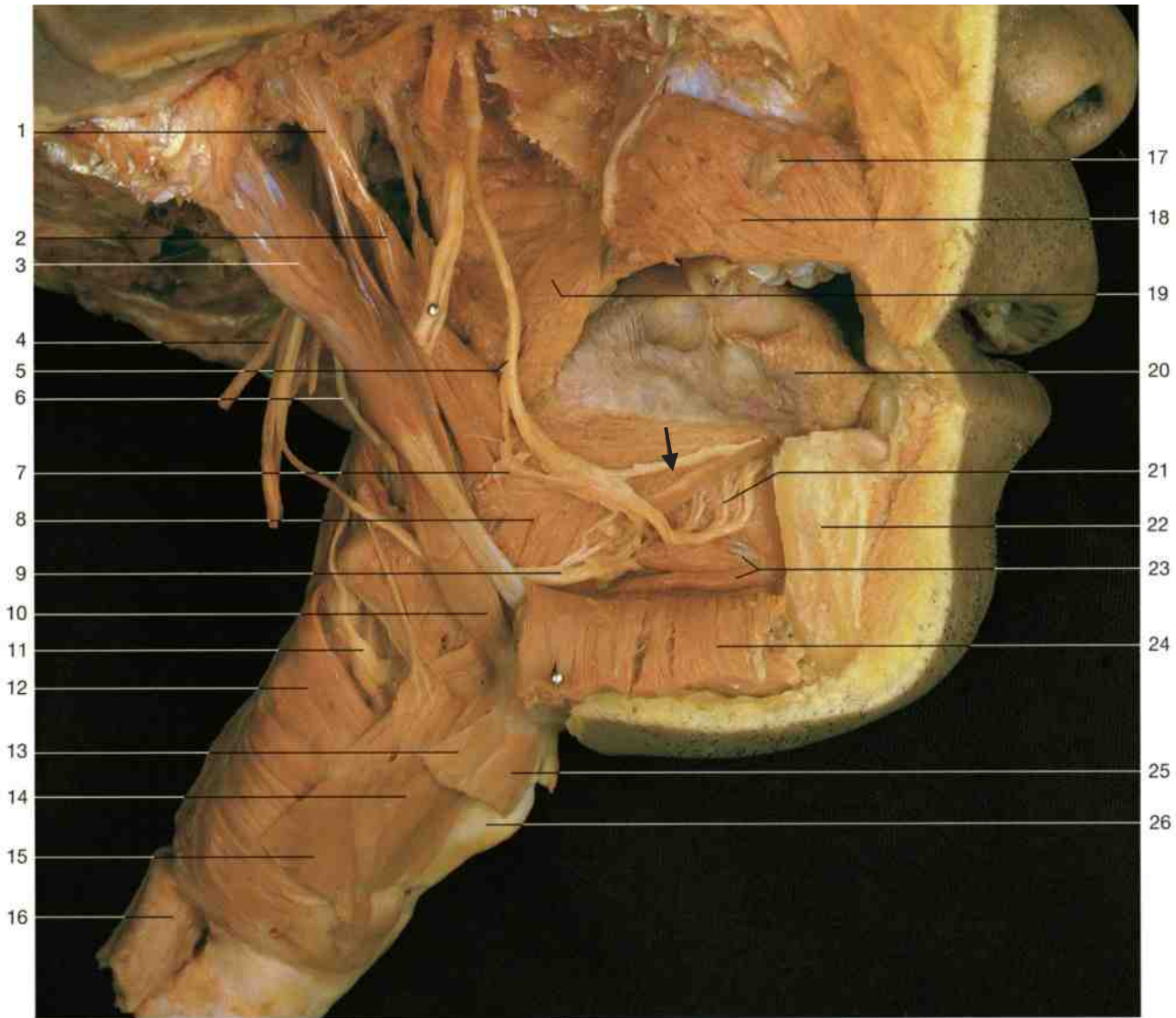
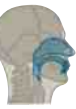Muscles of the floor of the oral cavity (superior aspect).

- 1 Lesser cornu and body of hyoid bone
- 2 Hyoglossus muscle (divided)
- 3 Ramus of mandible and inferior alveolar nerve
- 4 Geniohyoid muscle
- 5 Genioglossus muscle (divided)
- 6 Stylohyoid muscle (divided)

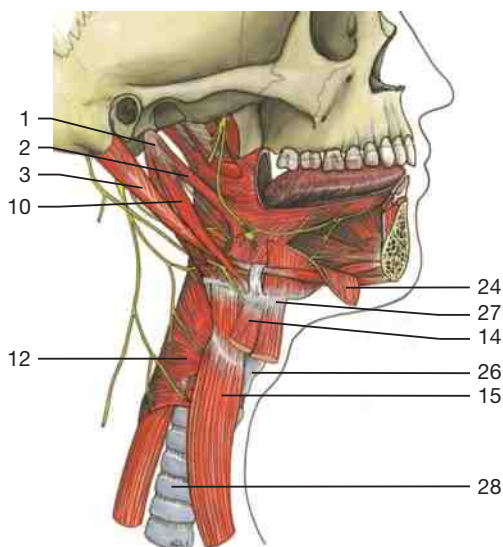


Oral diaphragm, muscles (inferior aspect). Cut on the base.

- 7 Mylohyoid muscle
- 8 Anterior belly of digastric muscle
- 9 Hyoid bone
- 10 Mandible
- 11 Intermediate tendon of digastric muscle

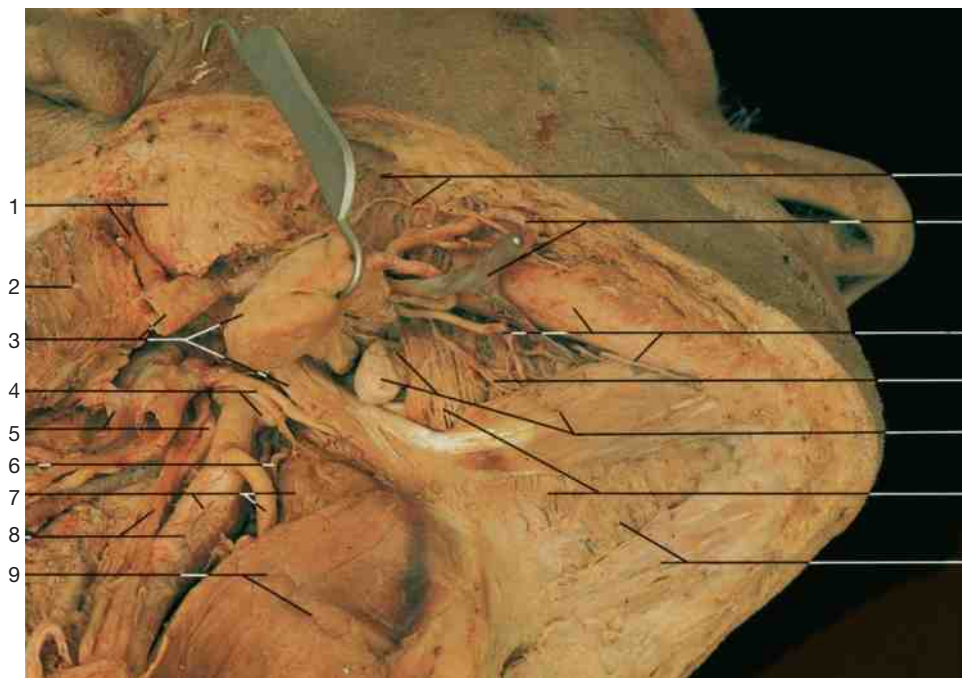


Parapharyngeal and sublingual regions. Innervation of the tongue. Lateral part of face and mandible removed, oral cavity opened. Arrow: submandibular duct.



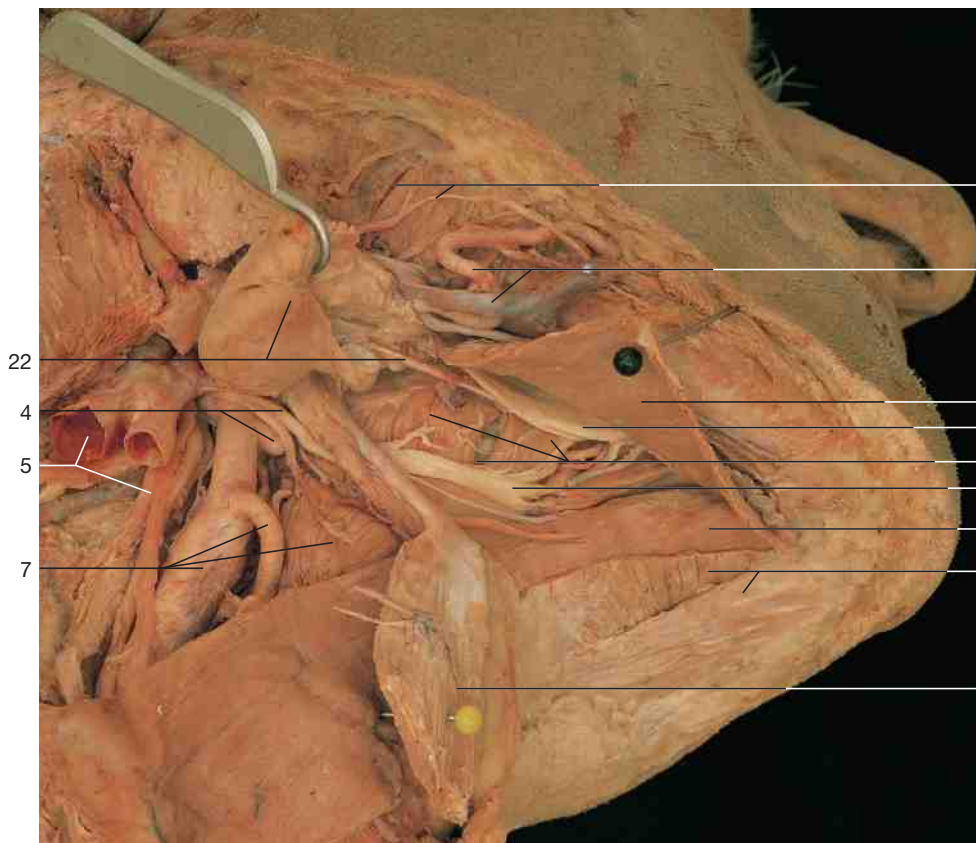
- | | |
|--|---|
| 1 Styloid process | 14 Thyrohyoid muscle |
| 2 Styloglossus muscle | 15 Sternohyoid muscle |
| 3 Digastric muscle (posterior belly) | 16 Esophagus |
| 4 Vagus nerve (n. X) | 17 Parotid duct (divided) |
| 5 Lingual nerve (n. V ₃) | 18 Buccinator |
| 6 Glossopharyngeal nerve (n. IX) | 19 Superior constrictor muscle of pharynx |
| 7 Submandibular ganglion | 20 Tongue |
| 8 Hyoglossus muscle | 21 Terminal branches of lingual nerve |
| 9 Hypoglossal nerve (n. XII) | 22 Mandible (divided) |
| 10 Stylohyoid muscle | 23 Genioglossus and geniohyoid muscles |
| 11 Internal branch of superior laryngeal nerve | 24 Mylohyoid muscle (divided and reflected) |
| 12 Middle constrictor muscle of pharynx | 25 Sternohyoid muscle (divided) |
| 13 Omohyoid muscle (divided) | 26 Thyroid cartilage |
| | 27 Hyoid bone |
| | 28 Trachea |

Supra- and infrahyoid muscles and pharynx (schematic drawing).

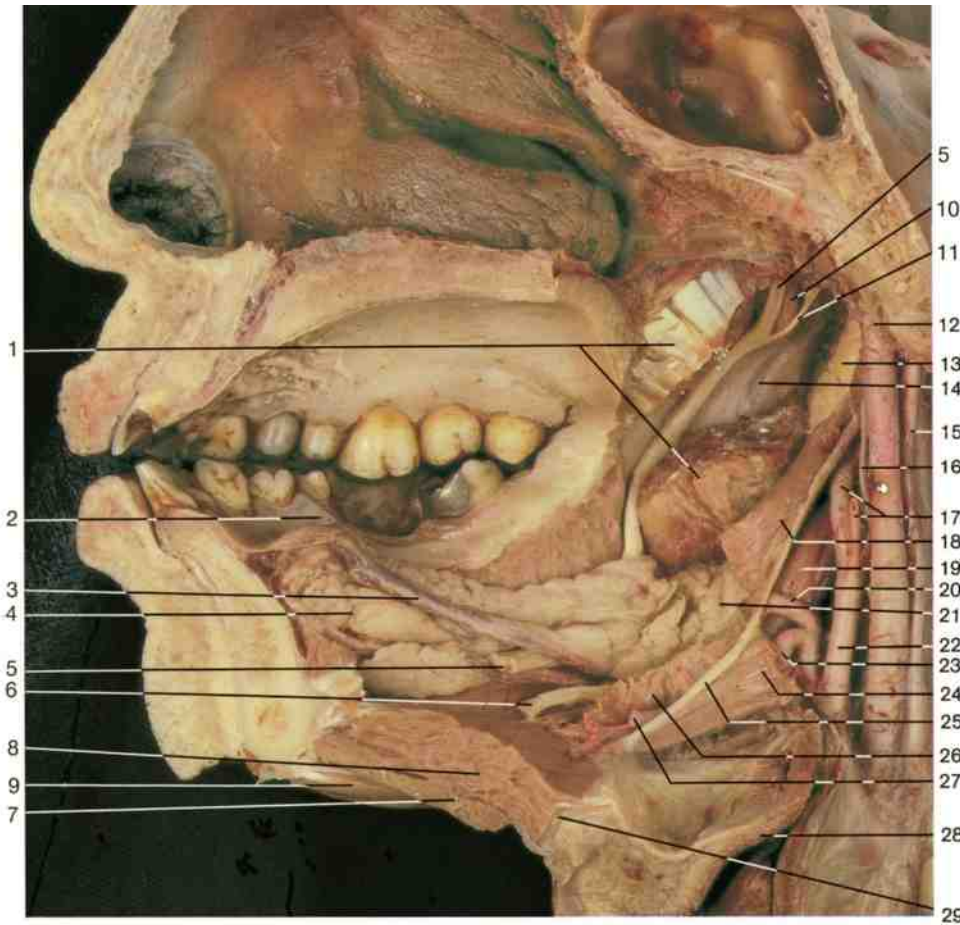
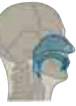

Submandibular triangle, superficial dissection. Right side (inferior aspect). Submandibular gland has been reflected.

- 1 Parotid gland and retromandibular vein
- 2 Sternocleidomastoid muscle
- 3 Retromandibular vein, submandibular gland, and stylohyoid muscle
- 4 Hypoglossal nerve and lingual artery
- 5 Vagus nerve and internal jugular vein
- 6 Superior laryngeal artery
- 7 External carotid artery, thyrohyoid muscle, and superior thyroid artery
- 8 Common carotid artery and superior root of ansa cervicalis
- 9 Omohyoid and sternohyoid muscles
- 10 Masseter muscle and marginal mandibular branch of facial nerve
- 11 Facial artery and vein
- 12 Mandible and submental artery and vein
- 13 Mylohyoid nerve
- 14 Submandibular duct, sublingual gland, and anterior belly of digastric muscle
- 15 Mylohyoid muscle
- 16 Mylohyoid muscle and anterior belly of left digastric muscle
- 17 Hyoglossus muscle and lingual artery
- 18 Lingual nerve
- 19 Hypoglossal nerve
- 20 Geniohyoid muscle
- 21 Anterior belly of right digastric muscle
- 22 Submandibular gland and duct

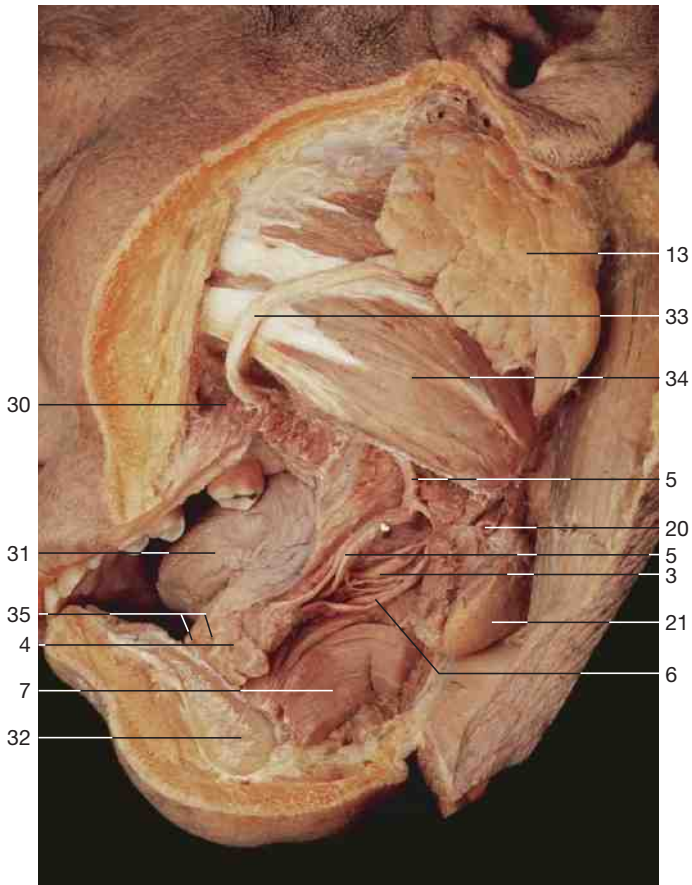


Submandibular triangle, deep dissection. Right side (inferior aspect). Mylohyoid muscle has been severed and reflected to display the lingual and hypoglossal nerves.

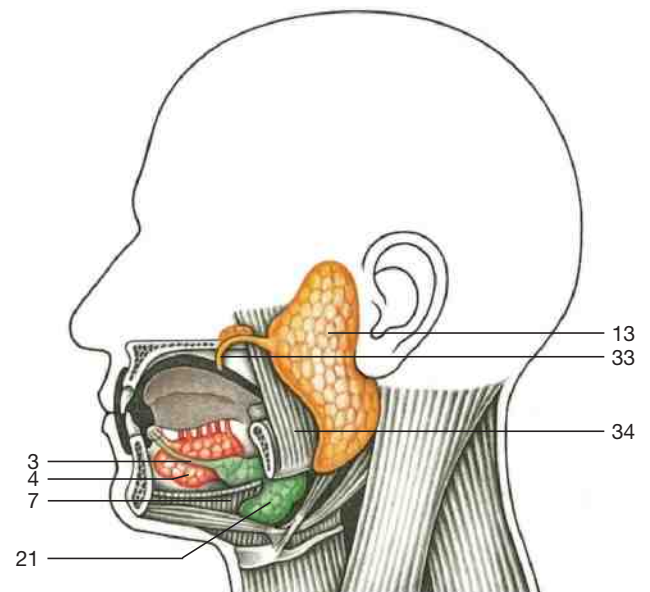


- 1 Medial pterygoid muscle
- 2 Sublingual papilla
- 3 Submandibular duct
- 4 Sublingual gland
- 5 Lingual nerve
- 6 Hypoglossal nerve
- 7 Mylohyoid muscle
- 8 Geniohyoid muscle
- 9 Anterior belly of digastric muscle
- 10 Inferior alveolar nerve
- 11 Chorda tympani
- 12 Internal carotid artery
- 13 Parotid gland
- 14 Sphenomandibular ligament
- 15 Vagus nerve
- 16 Glossopharyngeal nerve
- 17 Superficial temporal artery and ascending pharyngeal artery
- 18 Styloglossus muscle
- 19 Posterior belly of digastric muscle
- 20 Facial artery
- 21 Submandibular gland
- 22 External carotid artery
- 23 Lingual artery
- 24 Middle pharyngeal constrictor muscle
- 25 Stylohyoid ligament
- 26 Hyoglossus muscle
- 27 Deep lingual artery
- 28 Epiglottis
- 29 Hyoid bone
- 30 Buccinator muscle
- 31 Tongue
- 32 Mandible (divided)
- 33 Parotid duct
- 34 Masseter muscle
- 35 Right and left sublingual papillae

Oral cavity (internal aspect). Tongue and pharyngeal wall removed.



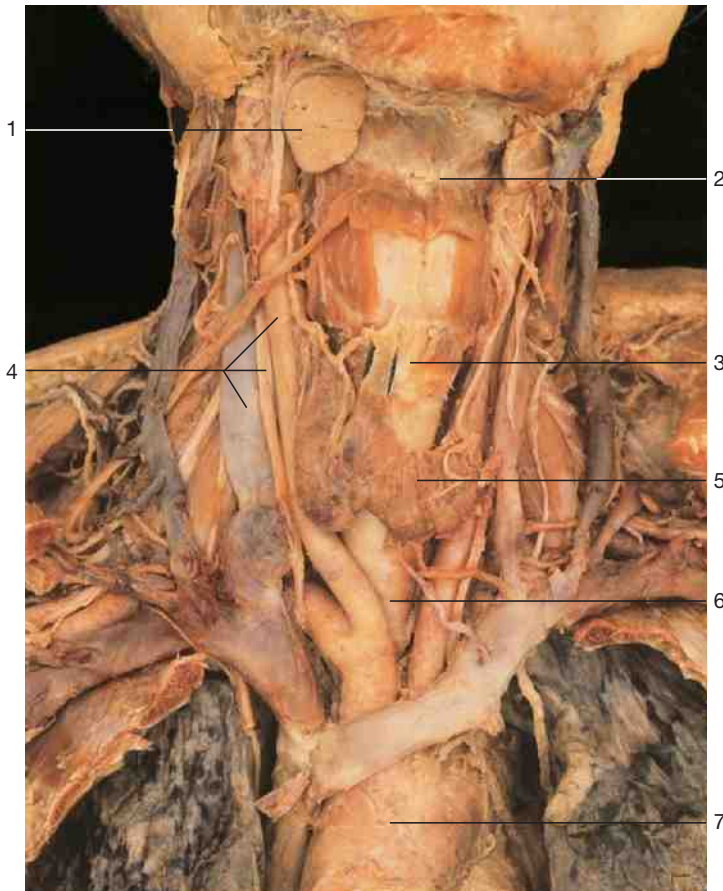
Dissection of major salivary glands. Left mandible and buccinator muscle partly removed to view the oral cavity (infero-lateral aspect).



Location of the major salivary glands in relation to the oral cavity.



2.5 Neck and Organs of the Neck

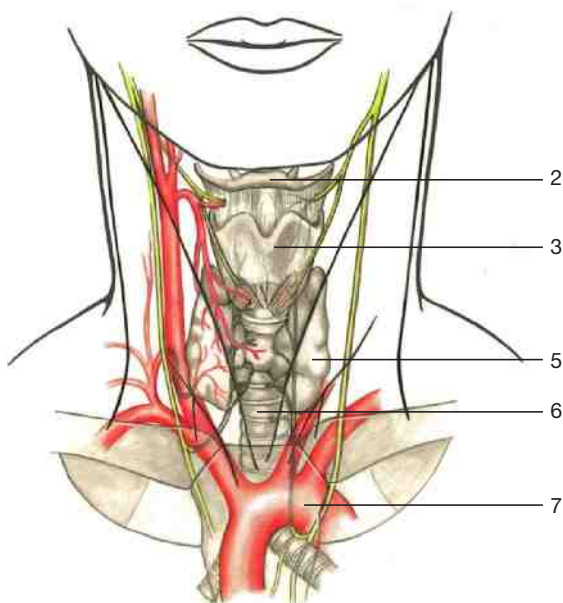


The anterior aspect of the neck contains the trachea and larynx, which are connected to the nasal cavity via the pharynx. Behind the trachea lies the esophagus, which is connected to the oral cavity, again via the pharynx.

The thyroid gland is located anterior to the trachea, whereas the carotid artery and jugular vein together with the vagus nerve are situated laterally, conjoining the head with the thoracic organs and upper limb.

Underneath the sternocleidomastoid muscle, the cervical portion of the spinal nerves forms the cervical and brachial nervous plexuses that give rise to the innervations of neck and upper limb respectively.

Regional anatomy of the neck (anterior aspect). The anteriorly located muscles and the thoracic wall have been removed.

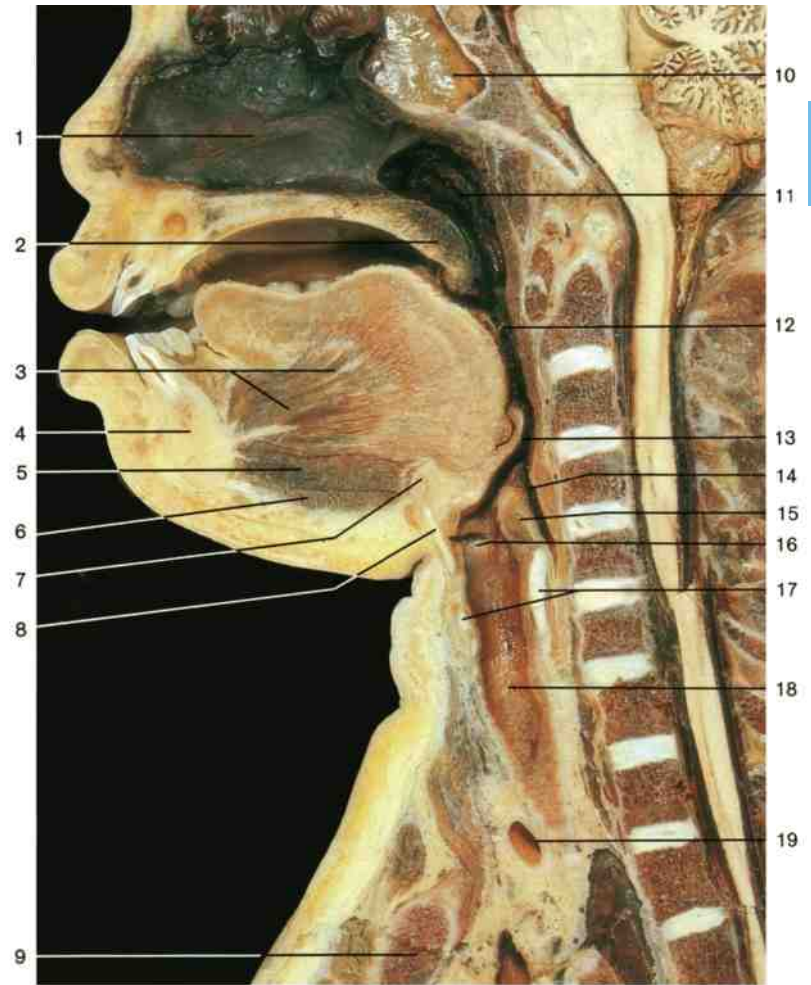


- 1 Submandibular gland
- 2 Hyoid bone
- 3 Larynx (thyroid cartilage)
- 4 Nerves and vessels of the neck (carotid artery, internal jugular vein, and vagus nerve)
- 5 Thyroid gland
- 6 Trachea
- 7 Aortic arch

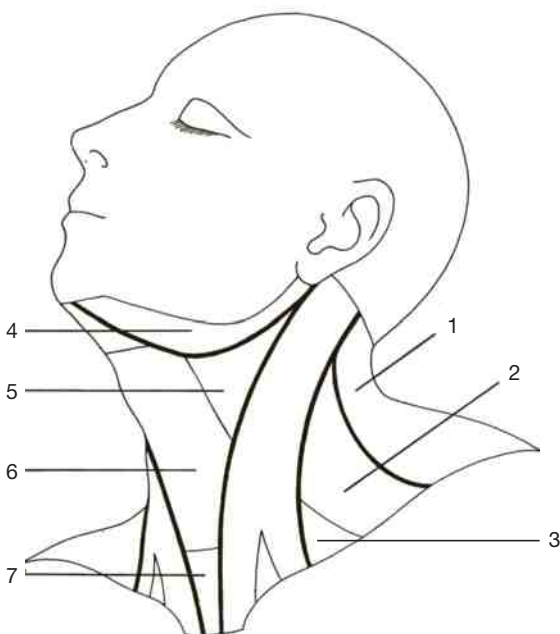
Organs of the neck (anterior aspect, schematic drawing). The main arterial trunks are indicated in red.



- 1 Nasal septum
- 2 Uvula
- 3 Genioglossus muscle
- 4 Mandible
- 5 Geniohyoid muscle
- 6 Mylohyoid muscle
- 7 Hyoid bone
- 8 Thyroid cartilage
- 9 Manubrium sterni
- 10 Sphenoidal sinus
- 11 Nasopharynx
- 12 Oropharynx
- 13 Epiglottis
- 14 Laryngopharynx
- 15 Arytenoid muscle
- 16 Vocal fold
- 17 Cricoid cartilage
- 18 Trachea
- 19 Left brachiocephalic vein
- 20 Thymus
- 21 Esophagus

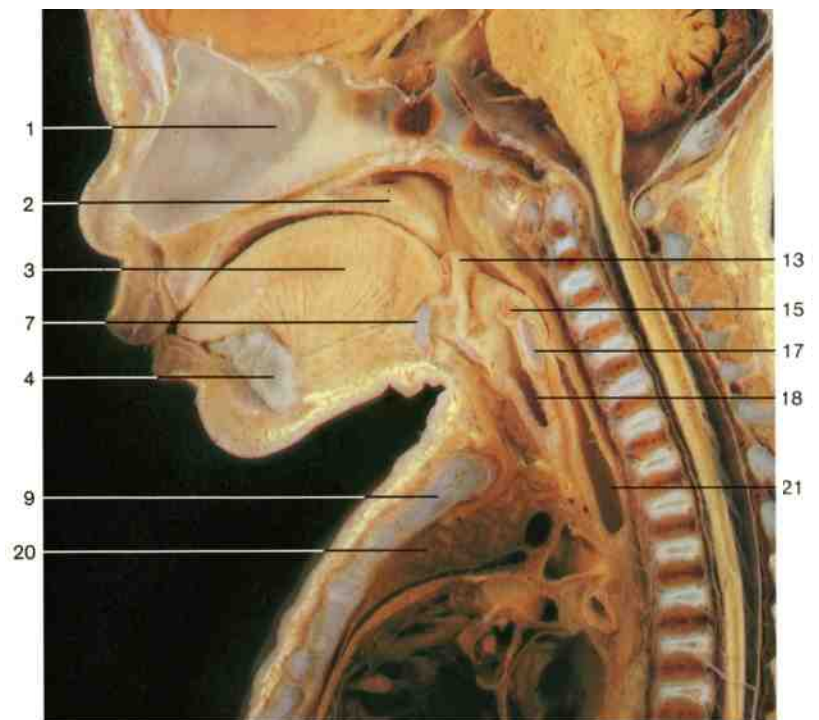


Median section through adult head and neck. Note the low position of the adult larynx when compared with that of the neonate (cf. with the figure below).

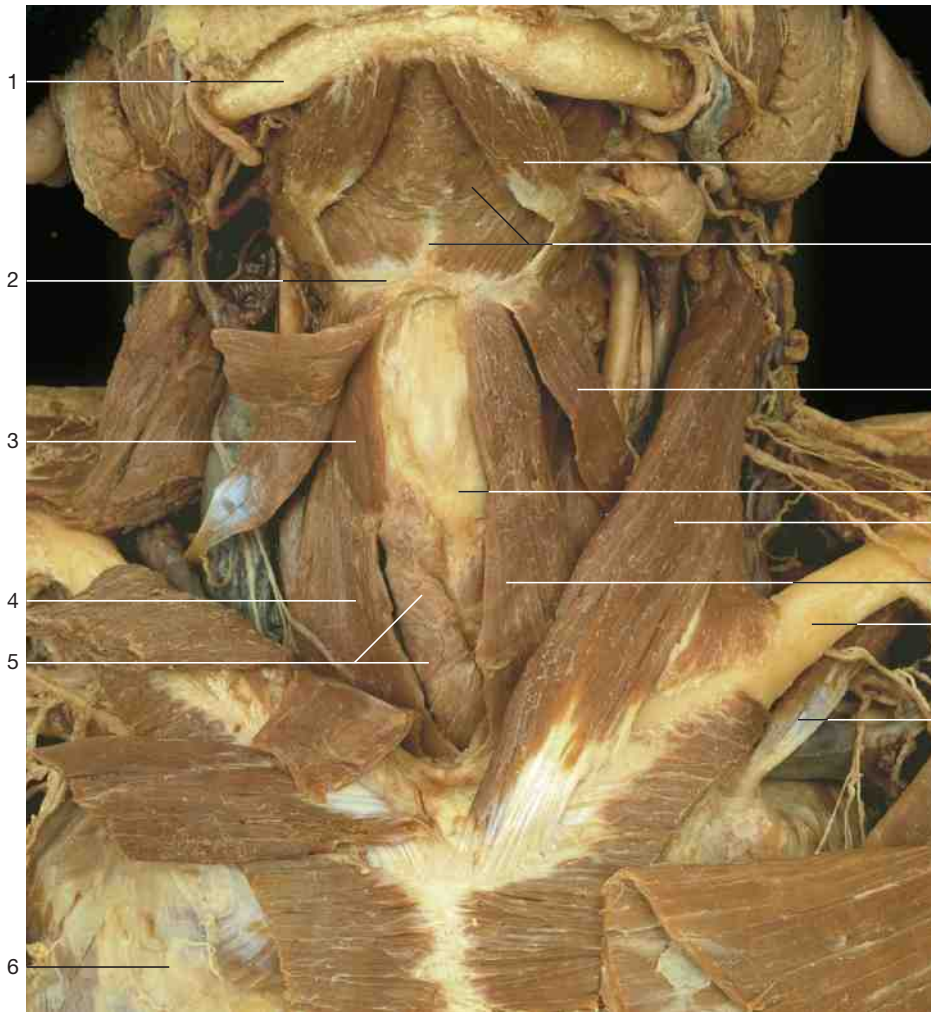


Regions and triangles of the neck (schematic drawing).

- 1 Posterior cervical region
- 2 Lateral cervical region
- 3 Supraclavicular triangle
- 4 Submandibular triangle
- 5 Carotid triangle
- 6 Anterior cervical region
- 7 Jugular fossa

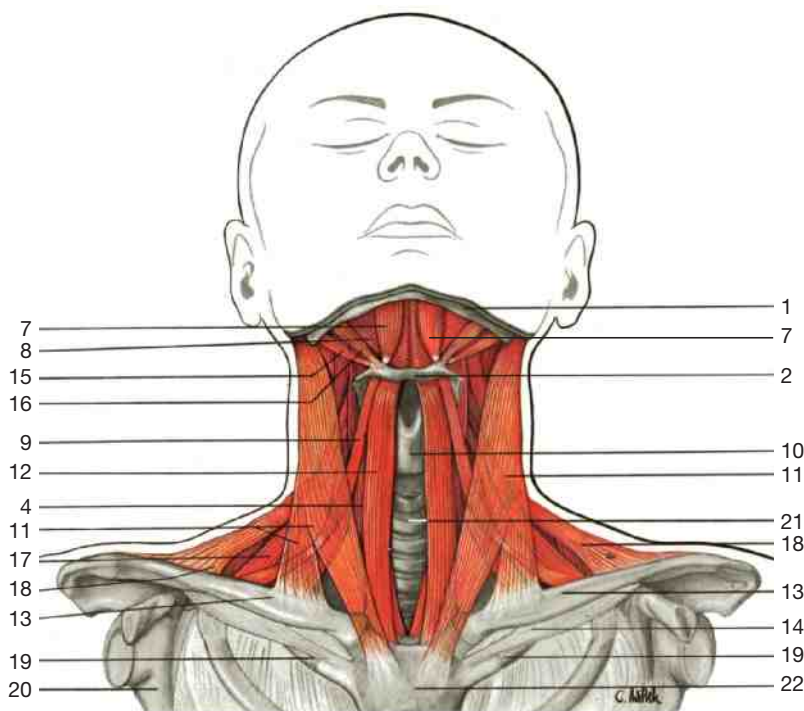


Median section through neonate head and neck. Note the high position of the larynx permitting the epiglottis to nearly reach the uvula (cf. with the figure above).



- 1 Mandible
- 2 Hyoid bone
- 3 Thyrohyoid muscle
- 4 Sternothyroid muscle
- 5 Thyroid gland
- 6 Second rib
- 7 Anterior belly of digastric muscle
- 8 Mylohyoid muscle (and mylohyoid raphe)
- 9 Omohyoid muscle
- 10 Thyroid cartilage
- 11 Sternocleidomastoid muscle
- 12 Sternohyoid muscle
- 13 Clavicle
- 14 Subclavius muscle
- 15 Posterior belly of digastric muscle
- 16 Stylohyoid muscle
- 17 Scalenus muscles
- 18 Trapezius muscle
- 19 First rib
- 20 Scapula
- 21 Trachea
- 22 Manubrium sterni

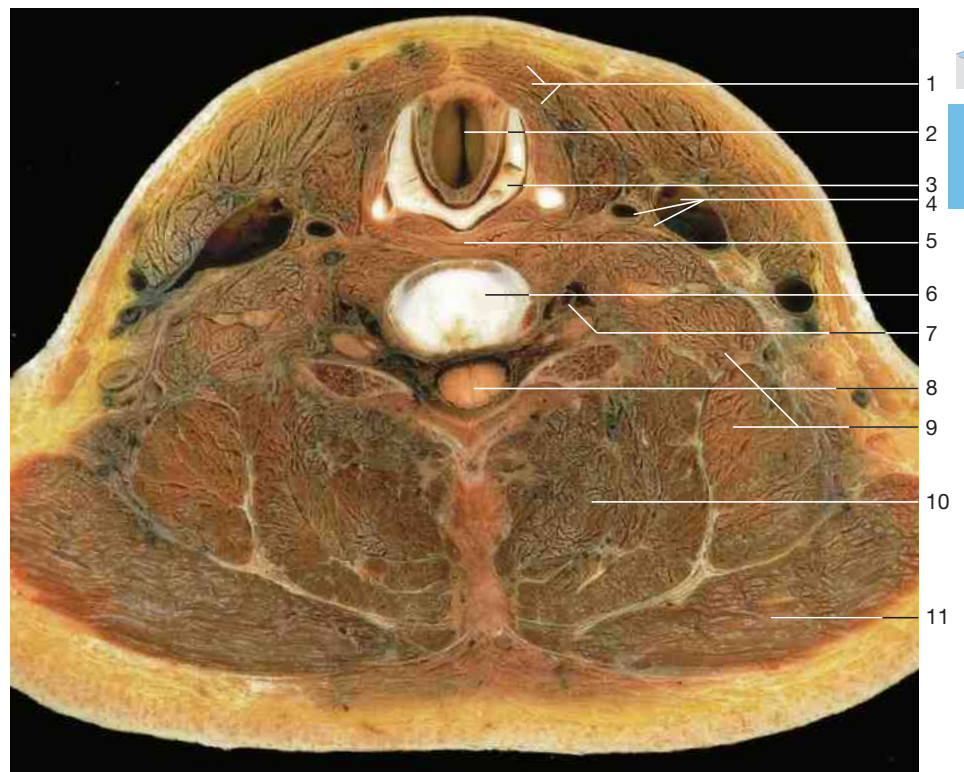
Muscles of the neck (anterior aspect). Sternocleidomastoid and sternohyoid muscles on the right have been divided and reflected.



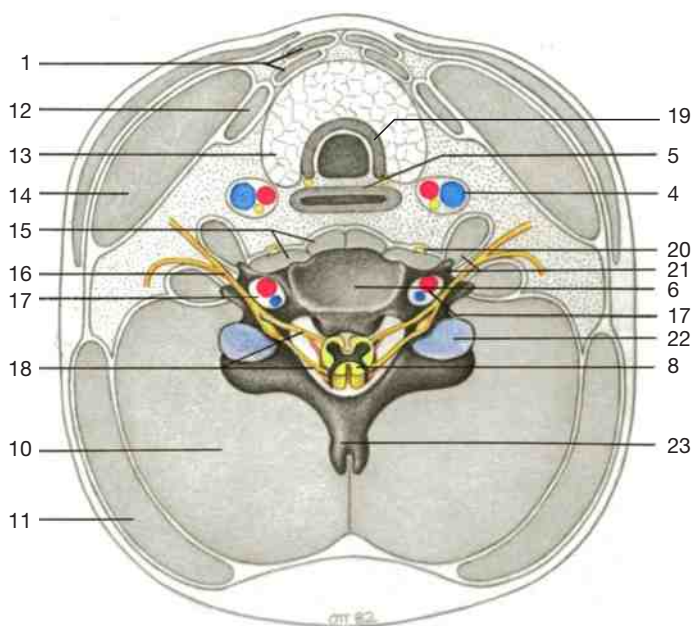
Muscles of the neck (anterior aspect, schematic drawing).

The muscles of the neck are complex and highly sophisticated. There are two major groups of muscles to be distinguished according to their functional aspects. One group is constituted by muscles connecting head to the hyoid bone and the larynx. The second category of muscles links the head and the ribcage. The sternocleidomastoid muscle represents the border between the anterior and posterior cervical triangle.

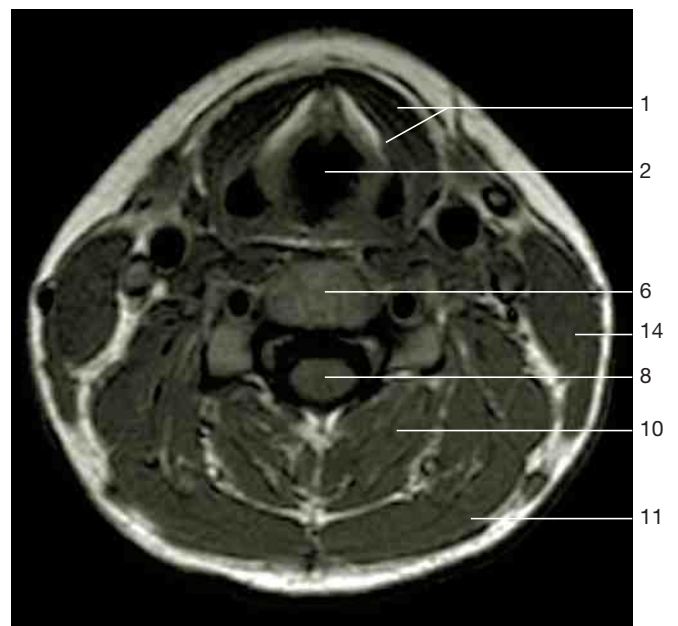
- 1 Sternohyoid and thyrohyoid muscles
- 2 Larynx
- 3 Cricoid cartilage
- 4 Internal jugular vein, common carotid artery, and vagus nerve
- 5 Esophagus
- 6 Body of cervical vertebra
- 7 Vertebral artery
- 8 Spinal cord
- 9 Scalenus posterior muscle
- 10 Deep muscles of the neck
- 11 Trapezius muscle
- 12 Omohyoid muscle
- 13 Thyroid gland
- 14 Sternocleidomastoid muscle
- 15 Longus colli and longus capitis muscles
- 16 Cervical spinal nerve
- 17 Vertebral artery and vein, and foramen transversarium
- 18 Ventral and dorsal root of cervical spinal nerve
- 19 Trachea
- 20 Sympathetic trunk
- 21 Anterior tubercle of transverse process and origin of scalenus anterior and medius muscles
- 22 Superior facet of articular process
- 23 Spinous process




Axial section of the neck at the level of the intervertebral disc between the 5th and 6th cervical vertebra (inferior aspect).




Organization of the neck (axial section at the level of the thyroid gland; schematic drawing).



Axial section of the neck at the level of the 4th cervical vertebra (MRI scan; from Heuck et al., MRT-Atlas, 2009).

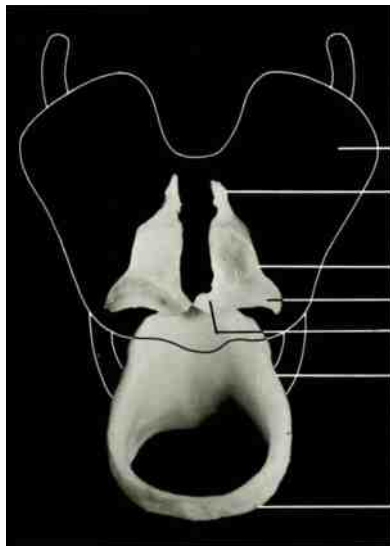


Cartilages of the larynx and the hyoid bone (anterior aspect).

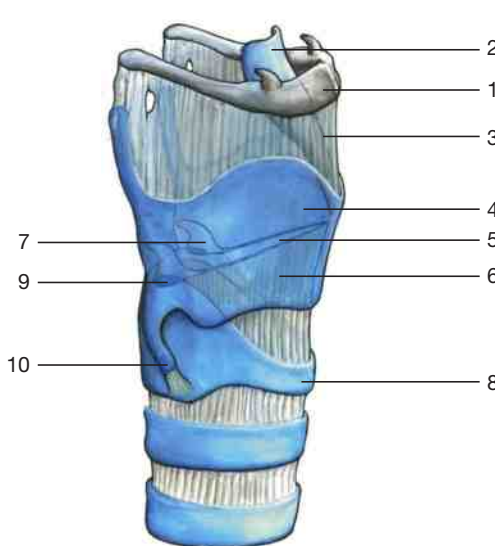


Cartilages of the larynx and the hyoid bone (posterior aspect).

- 1 Epiglottis
- 2 Lesser cornu of hyoid bone
- 3 Greater cornu of hyoid bone
- 4 Lateral thyrohyoid ligament
- 5 Body of hyoid bone
- 6 Superior cornu of thyroid cartilage
- 7 Thyro-epiglottic ligament
- 8 Conus elasticus
- 9 Cricothyroid ligament
- 10 Thyroid cartilage
- 11 Cricoid cartilage
- 12 Trachea
- 13 Corniculate cartilage
- 14 Arytenoid cartilage
- 15 Posterior crico-arytenoid ligament
- 16 Cricothyroid joint
- 17 Crico-arytenoid joint

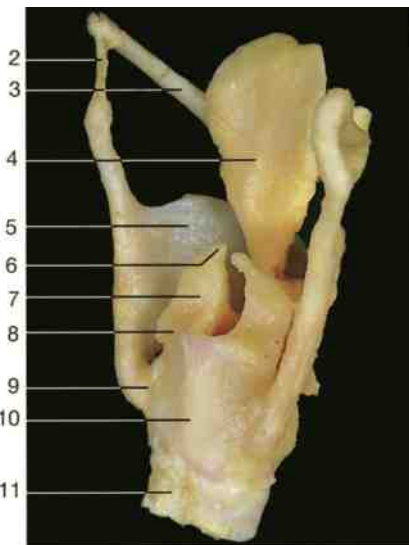


Cartilages of the larynx (anterior aspect). Thyroid cartilage is indicated by the outline.

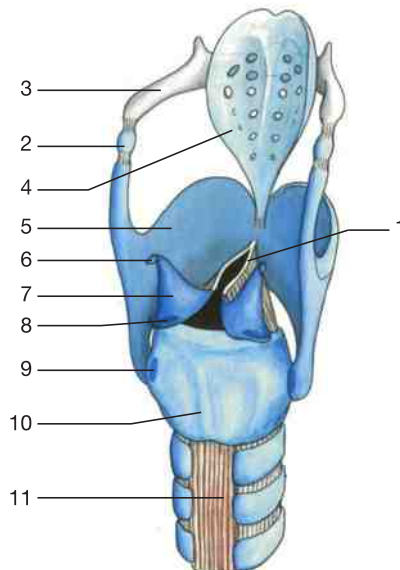


Cartilages and ligaments of the larynx (lateral aspect).

- 1 Hyoid bone
- 2 Epiglottis
- 3 Thyrohyoid membrane
- 4 Thyroid cartilage
- 5 Vocal ligament
- 6 Conus elasticus
- 7 Arytenoid cartilage
- 8 Cricoid cartilage
- 9 Crico-arytenoid joint
- 10 Cricothyroid joint
- 11 Tracheal cartilages
- 12 Corniculate cartilage
- 13 Muscular process of arytenoid cartilage
- 14 Vocal process of arytenoid cartilage
- 15 Lamina of cricoid cartilage
- 16 Arch of cricoid cartilage

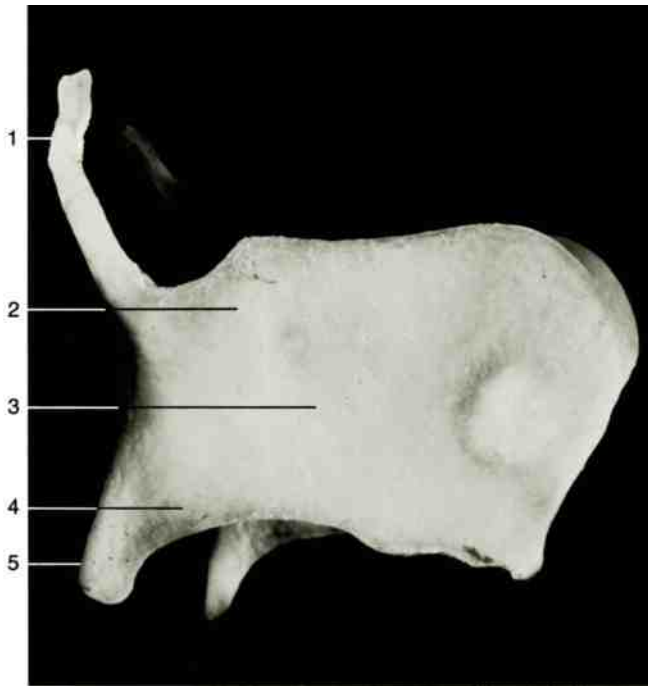


Cartilages of the larynx (oblique-posterior aspect).



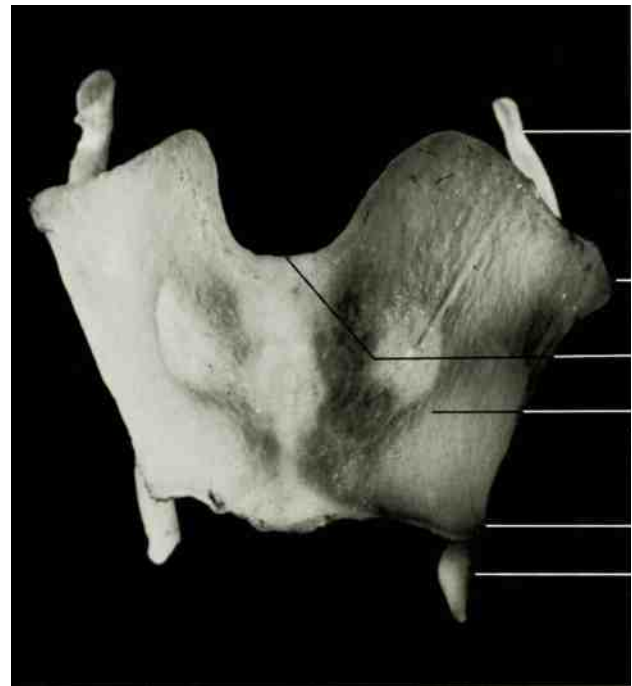
Cartilages of the larynx (oblique-posterior aspect).

- 1 Vocal ligament
- 2 Lateral thyrohyoid ligament
- 3 Greater cornu of hyoid bone
- 4 Epiglottis
- 5 Thyroid cartilage
- 6 Corniculate cartilage
- 7 Arytenoid cartilage
- 8 Crico-arytenoid joint
- 9 Cricothyroid joint
- 10 Cricoid cartilage
- 11 Trachea



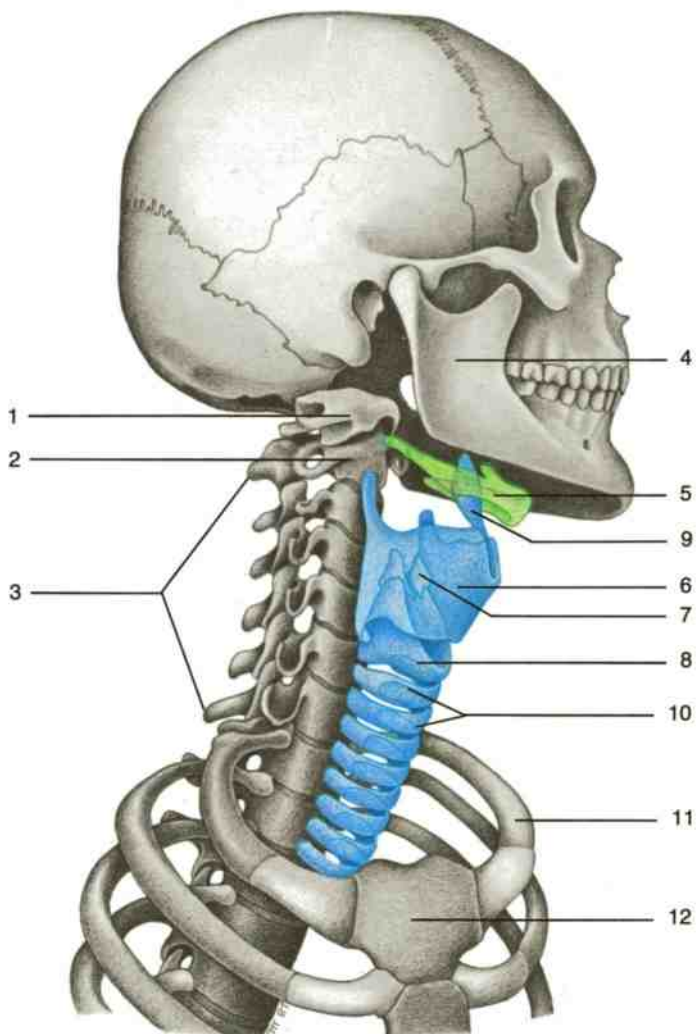
Thyroid cartilage (lateral aspect).

- 1 Superior cornu
- 2 Superior thyroid tubercle
- 3 Lamina of thyroid cartilage



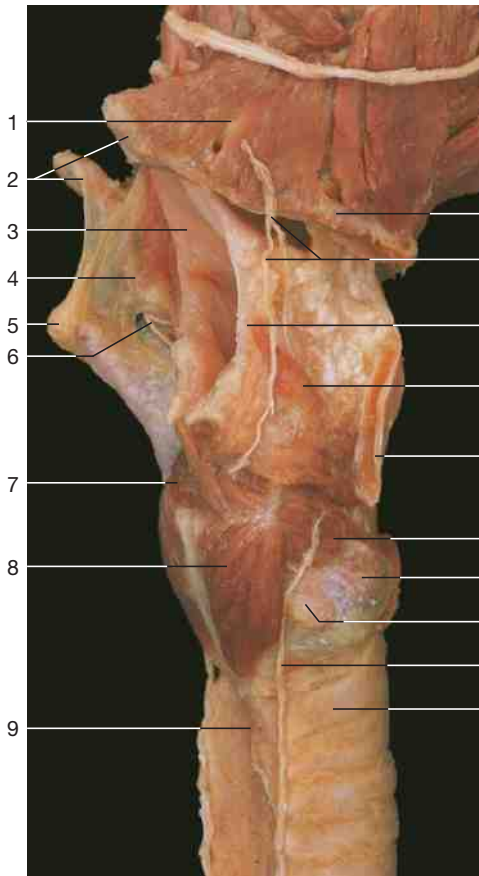
Thyroid cartilage (anterior aspect).

- 4 Inferior thyroid tubercle
- 5 Inferior cornu
- 6 Superior thyroid notch

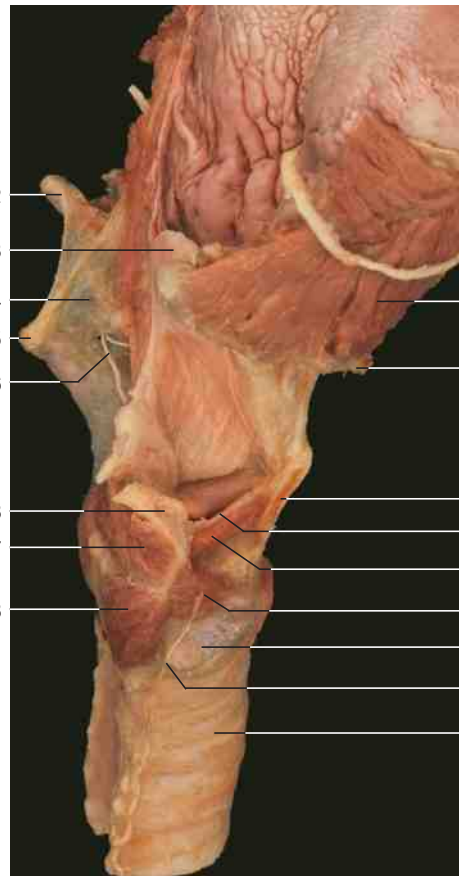

- 1 Atlas
- 2 Axis
- 3 Cervical vertebrae (C₂-C₇)
- 4 Mandible
- 5 Hyoid bone
- 6 Thyroid cartilage
- 7 Arytenoid cartilage
- 8 Cricoid cartilage
- 9 Epiglottis
- 10 Tracheal cartilages
- 11 First rib
- 12 Manubrium sterni

Position of the larynx in the neck (oblique-lateral aspect).
(Schematic drawing.)

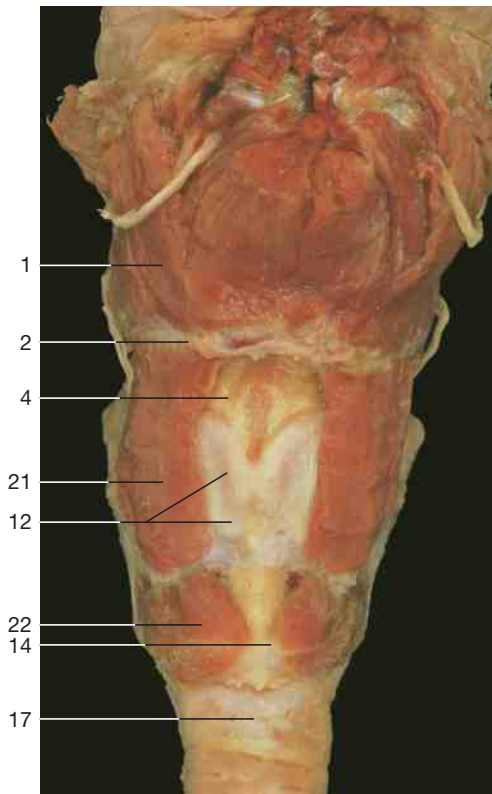


Laryngeal muscles (lateral aspect).
Thyroid cartilage (12) and thyro-arytenoid muscle have been partly removed.

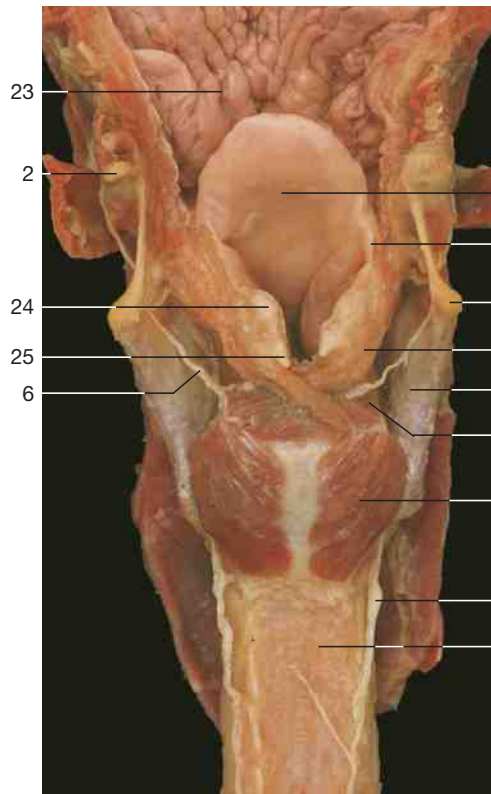


Laryngeal muscles (lateral aspect).
Half of the thyroid cartilage (12) has been removed. Dissection of the vocal ligament (19).

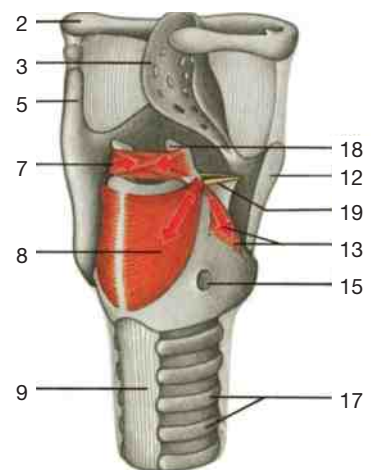
- 1 Hyoglossus muscle
- 2 Hyoid bone
- 3 Epiglottis
- 4 Thyrohyoid membrane
- 5 Superior cornu of thyroid cartilage
- 6 Superior laryngeal nerve
- 7 Transverse arytenoid muscle
- 8 Posterior crico-arytenoid muscle
- 9 Transverse muscle of trachea
- 10 Ary-epiglottic fold
- 11 Thyro-epiglottic muscle
- 12 Thyroid cartilage
- 13 Lateral crico-arytenoid muscle
- 14 Cricoid cartilage
- 15 Articular facet for thyroid cartilage
- 16 Inferior laryngeal nerve (branch of recurrent nerve)
- 17 Trachea
- 18 Arytenoid cartilage
- 19 Vocal ligament
- 20 Vocalis muscle (part of thyro-arytenoid muscle)
- 21 Thyrohyoideus muscle
- 22 Cricothyroideus muscle
- 23 Root of tongue
- 24 Cuneiform tubercle
- 25 Corniculate tubercle
- 26 Ary-epiglottic muscle



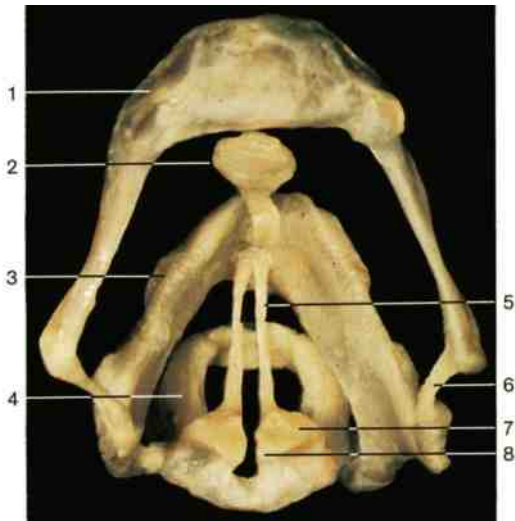
Laryngeal muscles and larynx (anterior aspect).



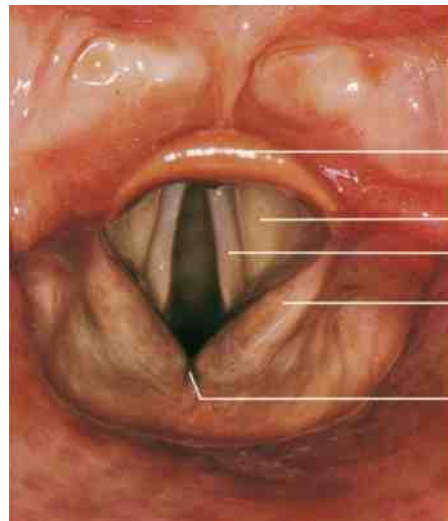
Laryngeal muscles and larynx (posterior aspect).



Action of internal muscles of the larynx (schematic drawing).

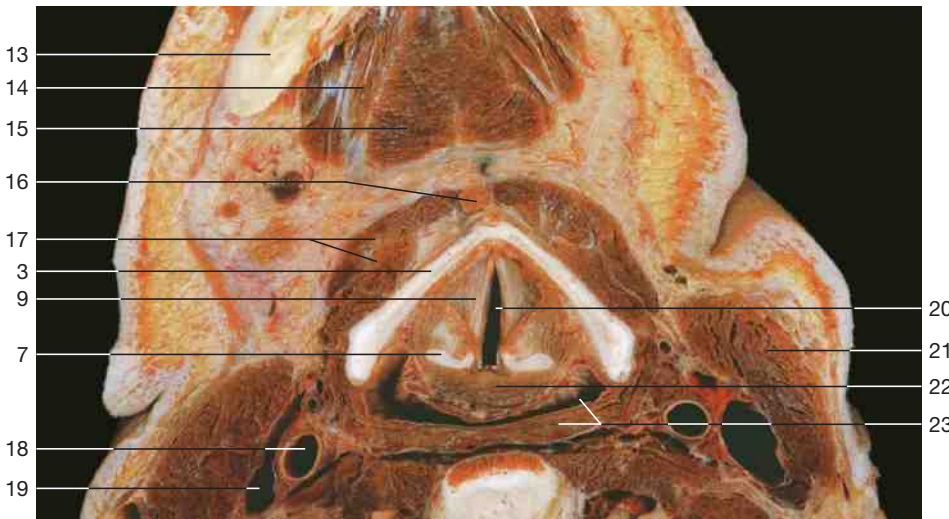

Laryngeal cartilages (superior aspect).

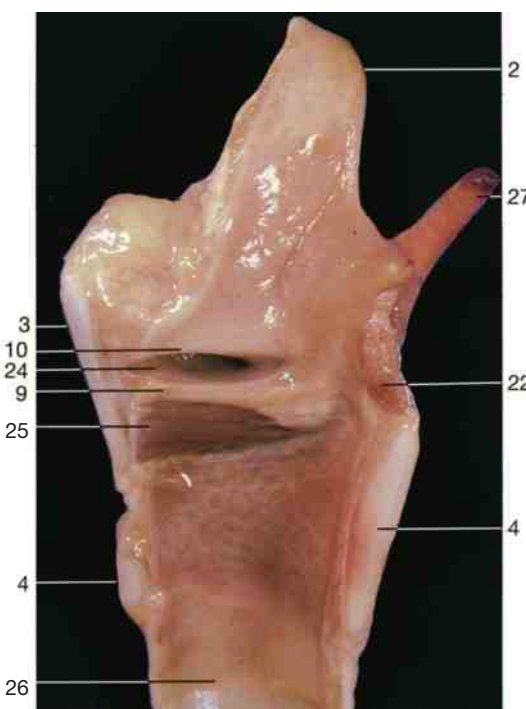


Glottis in vivo (superior aspect).

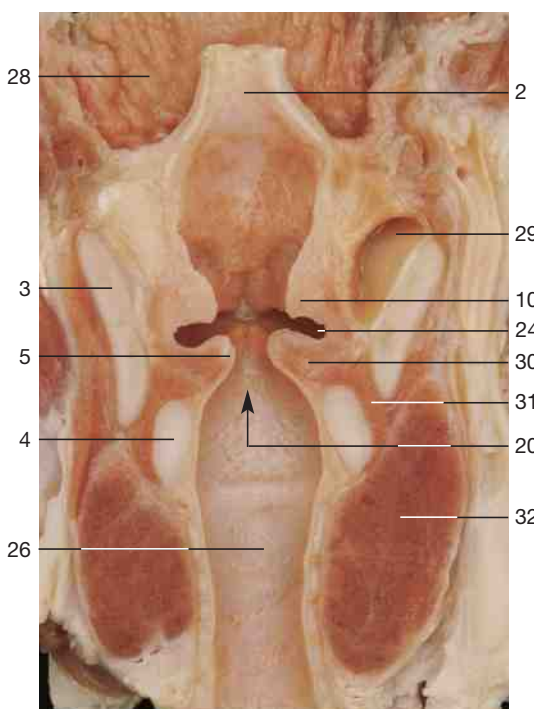
- 1 Hyoid bone
- 2 Epiglottis
- 3 Thyroid cartilage
- 4 Cricoid cartilage
- 5 Vocal ligament
- 6 Thyrohyoid ligament
- 7 Arytenoid cartilage
- 8 Corniculate cartilage
- 9 Vocal fold
- 10 Vestibular fold
- 11 Ary-epiglottic fold
- 12 Interarytenoid notch
- 13 Mandible
- 14 Anterior belly of digastric muscle
- 15 Mylohyoid muscle
- 16 Pyramidal lobe of thyroid gland
- 17 Sternohyoid and sternothyroid muscles
- 18 Common carotid artery
- 19 Internal jugular vein
- 20 Rima glottidis
- 21 Sternocleidomastoid muscle
- 22 Transverse arytenoid muscle
- 23 Pharynx and inferior constrictor muscle
- 24 Ventricle of larynx
- 25 Vocalis muscle
- 26 Trachea
- 27 Superior cornu of thyroid cartilage
- 28 Root of tongue (lingual tonsil)
- 29 Piriform recess
- 30 Vocalis muscle
- 31 Lateral crico-arytenoid muscle
- 32 Thyroid gland



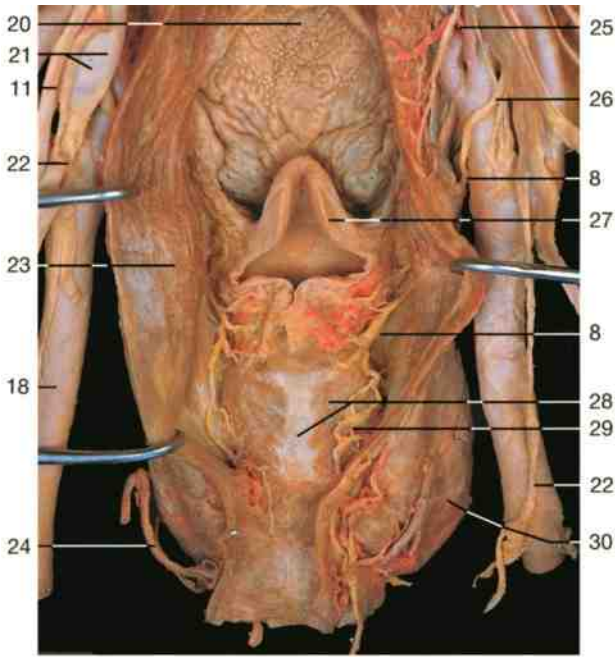
Horizontal section through the larynx at the level of the vocal folds (superior aspect).



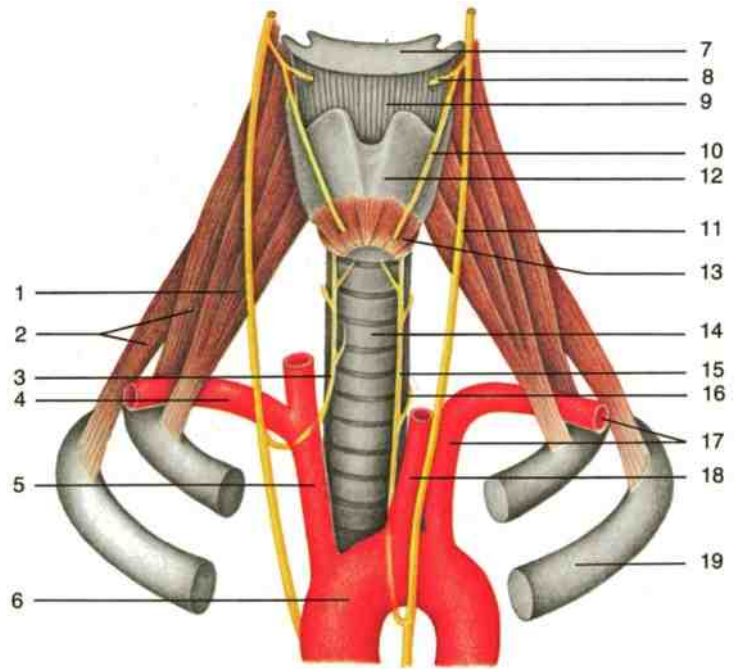
Sagittal section through the larynx.



Coronal section through larynx and trachea.

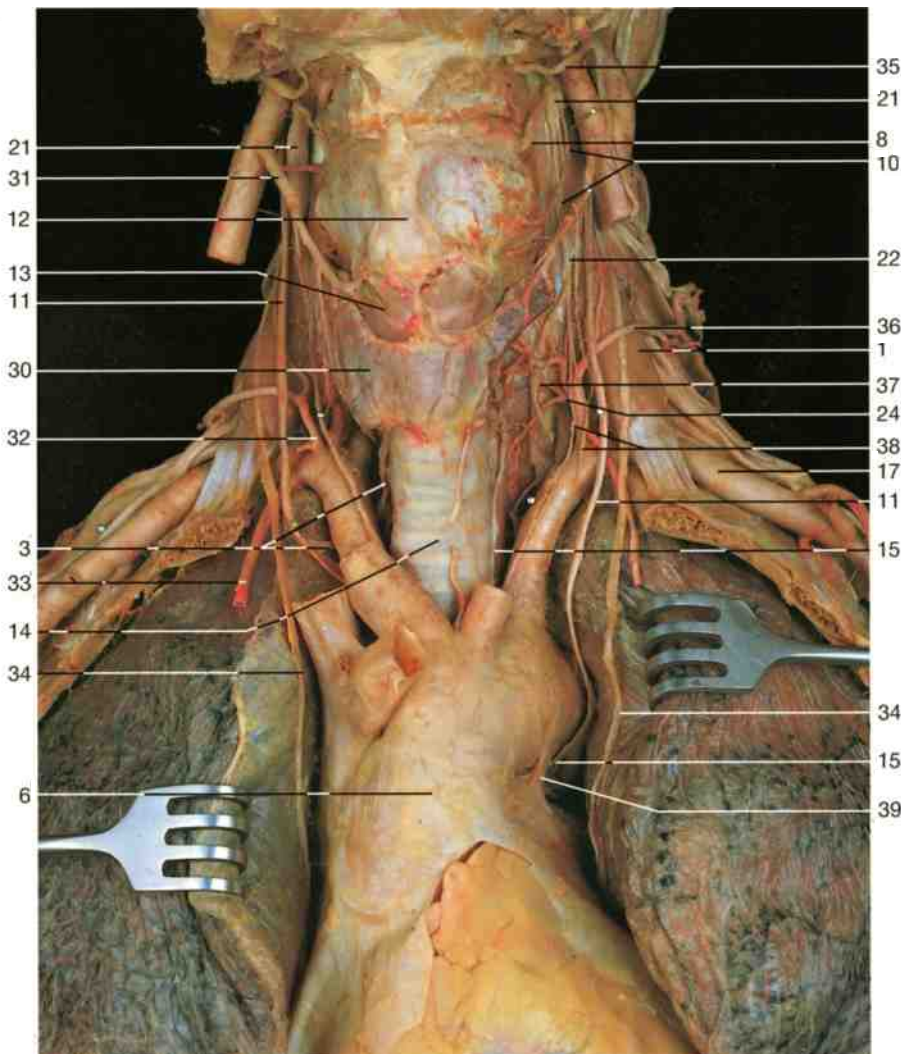


Larynx and its innervation (posterior aspect).
Dissection of superior and inferior laryngeal nerves.
Pharynx has been opened.

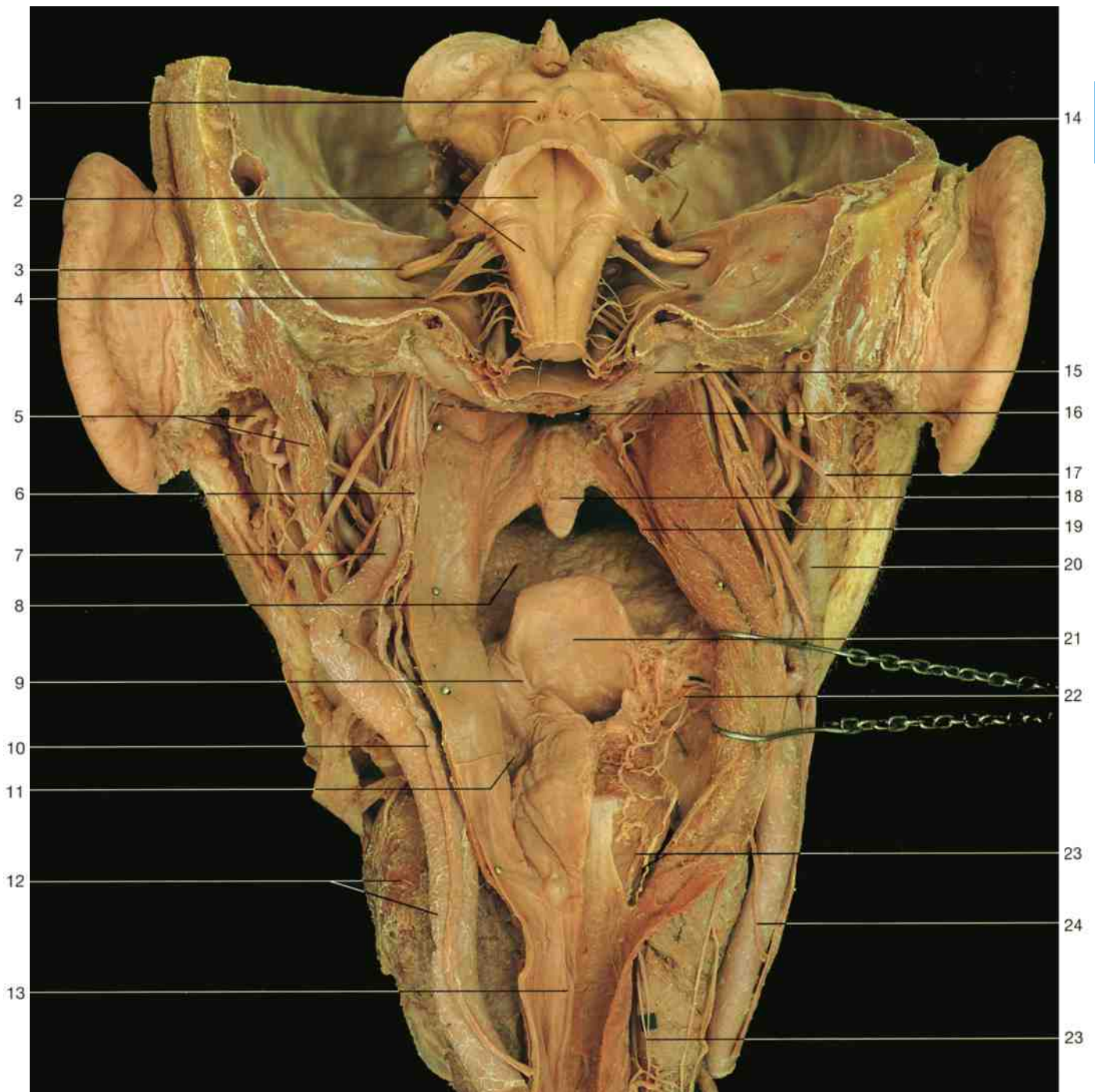


Innervation of the larynx (schematic drawing).

- 1 Scalenus anterior muscle
- 2 Scalenus medius and posterior muscles
- 3 Right recurrent laryngeal nerve
- 4 Right subclavian artery
- 5 Brachiocephalic trunk
- 6 Aortic arch
- 7 Hyoid bone
- 8 Internal branch of superior laryngeal nerve
- 9 Thyrohyoid membrane
- 10 External branch of superior laryngeal nerve
- 11 Vagus nerve
- 12 Thyroid cartilage
- 13 Cricothyroid muscle
- 14 Trachea
- 15 Left recurrent laryngeal nerve
- 16 Esophagus
- 17 Left subclavian artery
- 18 Left common carotid artery
- 19 Second rib
- 20 Tongue
- 21 Superior cervical ganglion
- 22 Sympathetic trunk
- 23 Inferior constrictor muscle of pharynx
- 24 Inferior thyroid artery
- 25 Glossopharyngeal nerve
- 26 Superior laryngeal nerve
- 27 Epiglottis
- 28 Posterior crico-arytenoid muscle and cricoid cartilage
- 29 Inferior laryngeal branch of recurrent laryngeal nerve
- 30 Thyroid gland
- 31 Superior thyroid artery
- 32 Thyrocervical trunk
- 33 Internal thoracic artery
- 34 Phrenic nerve
- 35 Hypoglossal nerve
- 36 Transverse cervical artery
- 37 Middle cervical ganglion
- 38 Middle cervical cardiac nerves (branches of sympathetic trunk)
- 39 Ligamentum arteriosum

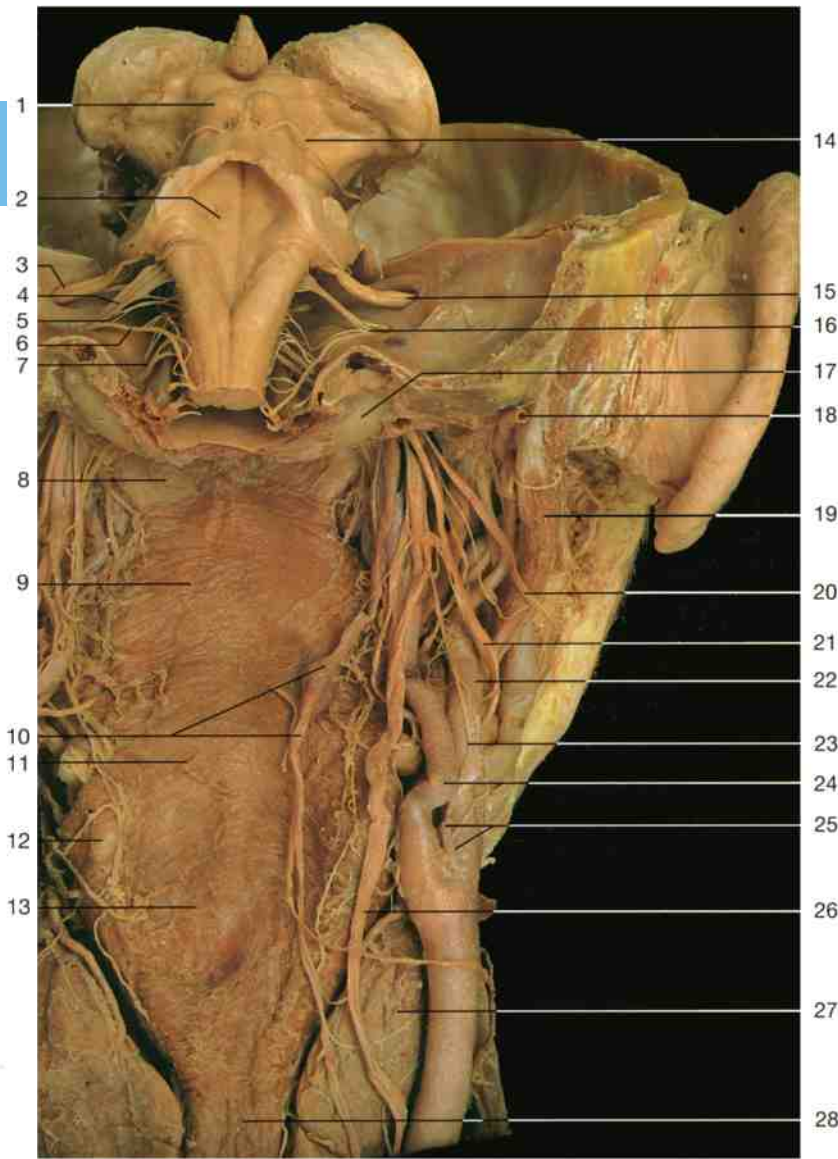


Larynx and thoracic organs (anterior aspect). Dissection of vagus and recurrent laryngeal nerves.



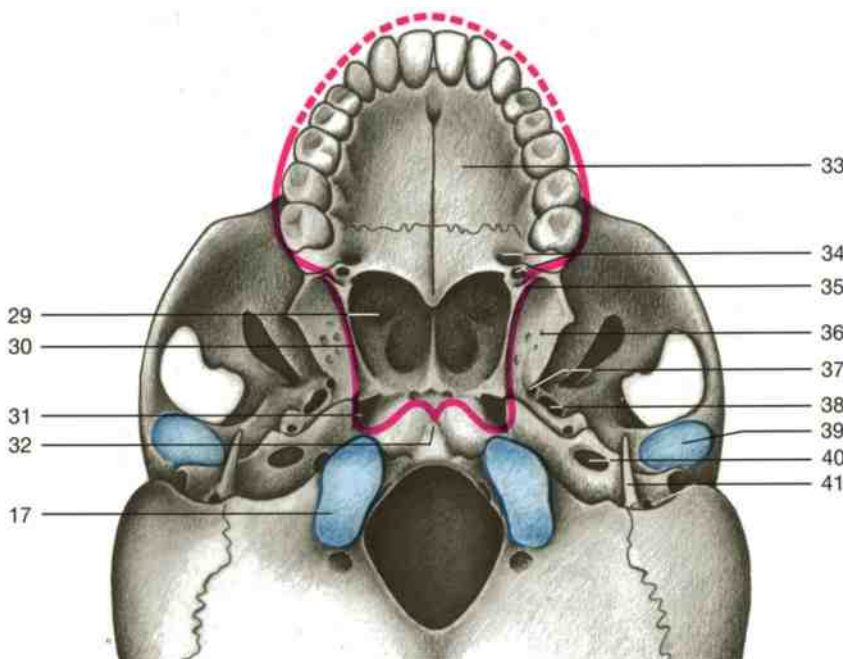
Larynx and oral cavity (posterior aspect). Mucous membrane on the right half of pharynx has been removed.

- | | | |
|--|--|--|
| 1 Midbrain (inferior colliculus) | 9 Ary-epiglottic fold | 18 Uvula and soft palate |
| 2 Rhomboid fossa and medulla oblongata | 10 Vagus nerve | 19 Palatopharyngeus muscle |
| 3 Vestibulocochlear and facial nerve | 11 Piriform recess | 20 External carotid artery |
| 4 Glossopharyngeal, vagus, and accessory nerves | 12 Thyroid gland and common carotid artery | 21 Epiglottis |
| 5 Occipital artery and posterior belly of digastric muscle | 13 Esophagus | 22 Internal branch of superior laryngeal nerve |
| 6 Superior cervical ganglion | 14 Trochlear nerve | 23 Inferior laryngeal nerve |
| 7 Internal carotid artery | 15 Occipital condyle | 24 Ansa cervicalis |
| 8 Oral cavity (tongue) | 16 Nasal cavity (choana) | |
| | 17 Accessory nerve | |

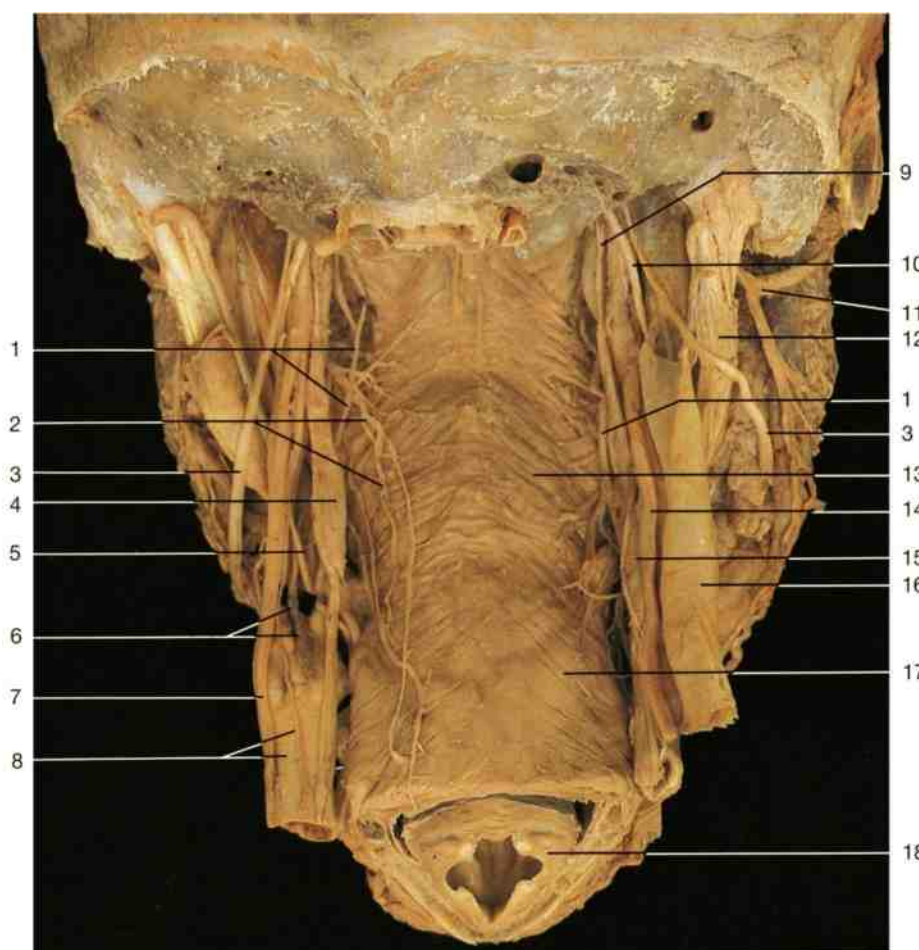


- 1 Inferior colliculus of midbrain
- 2 Facial colliculus in floor of rhomboid fossa
- 3 Vestibulocochlear and facial nerves
- 4 Glossopharyngeal nerve
- 5 Vagus nerve
- 6 Accessory nerve
- 7 Hypoglossal nerve
- 8 Pharyngobasilar fascia
- 9 Superior constrictor muscle of pharynx
- 10 Sympathetic trunk and superior cervical ganglion (medially displaced)
- 11 Middle constrictor muscle of pharynx
- 12 Greater cornu of hyoid bone
- 13 Inferior constrictor muscle of pharynx
- 14 Trochlear nerve
- 15 Internal acoustic meatus with facial and vestibulocochlear nerves
- 16 Jugular foramen with glossopharyngeal, vagus, and accessory nerves
- 17 Occipital condyle
- 18 Occipital artery
- 19 Posterior belly of digastric muscle
- 20 Accessory nerve (extracranial part)
- 21 Hypoglossal nerve (extracranial part)
- 22 External carotid artery
- 23 Carotid sinus nerve
- 24 Internal carotid artery
- 25 Carotid sinus and carotid body
- 26 Vagus nerve
- 27 Thyroid gland
- 28 Esophagus
- 29 Choanae
- 30 Medial pterygoid plate
- 31 Foramen lacerum
- 32 Pharyngeal tubercle
- 33 Hard palate
- 34 Greater and lesser palatine foramen
- 35 Pterygoid hamulus
- 36 Lateral pterygoid plate
- 37 Pterygoid canal
- 38 Foramen ovale
- 39 Mandibular fossa
- 40 Carotid canal
- 41 Styloid process and stylo mastoid foramen

Pharynx and parapharyngeal nerves in connection with brain stem (posterior aspect).

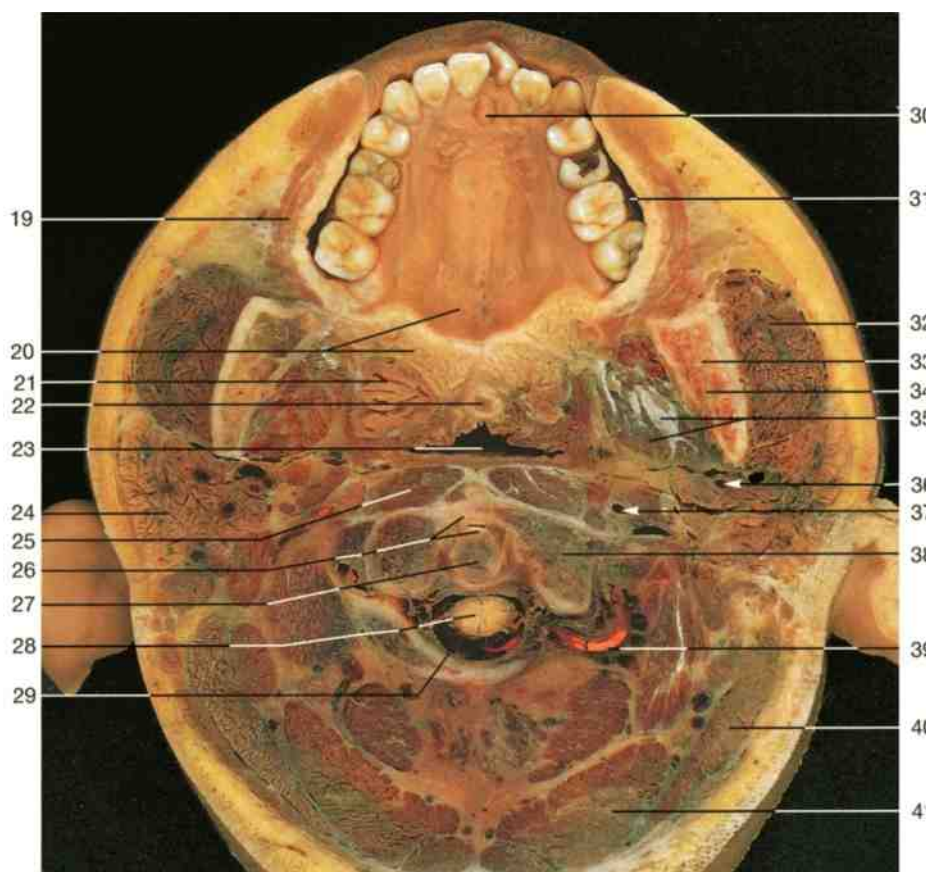


Inferior aspect of the skull.
Red line = outline of superior constrictor muscle in continuation with buccinator muscle and orbicularis oris muscle (semischematic drawing).



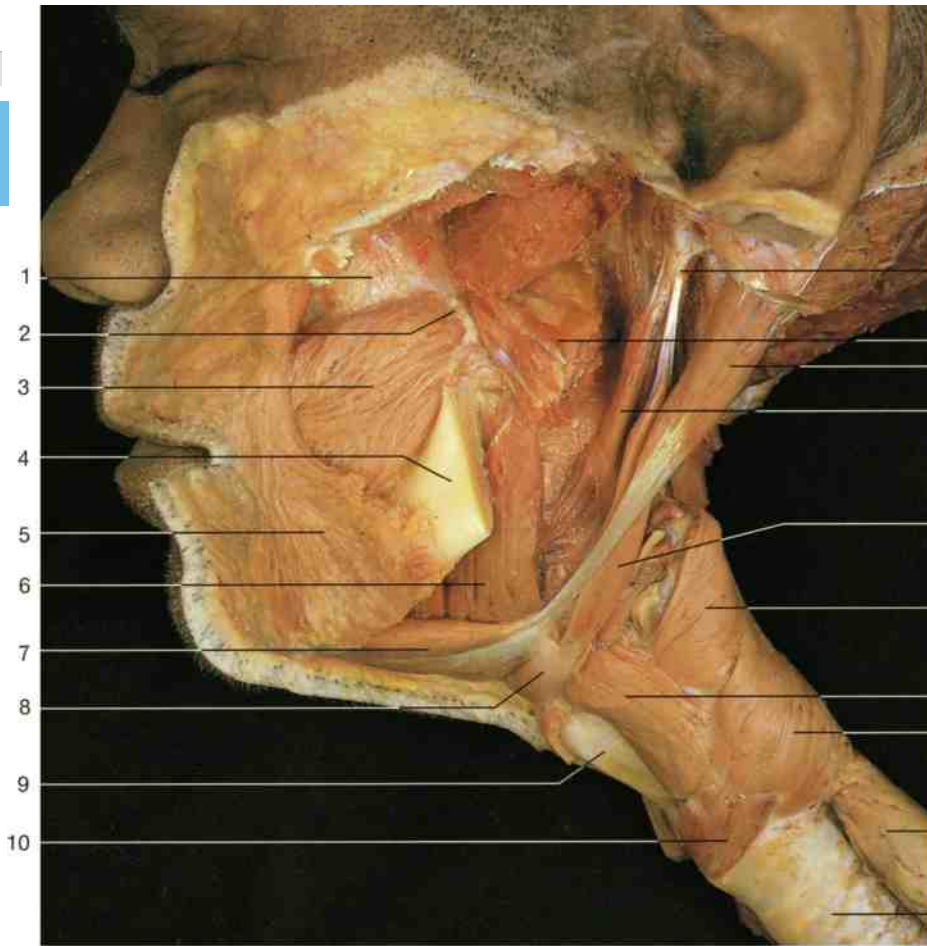
- 1 Ascending pharyngeal artery
- 2 Pharyngeal plexus
- 3 Accessory nerve
- 4 Superior cervical ganglion of sympathetic trunk
- 5 Superior laryngeal nerve
- 6 Carotid body and carotid sinus nerve
- 7 Left vagus nerve
- 8 Common carotid artery and cardiac branch of vagus nerve
- 9 Glossopharyngeal nerve
- 10 Hypoglossal nerve
- 11 Facial nerve
- 12 Posterior belly of digastric muscle
- 13 Middle constrictor muscle of pharynx
- 14 Right vagus nerve
- 15 Sympathetic trunk
- 16 Internal jugular vein
- 17 Inferior constrictor muscle of pharynx
- 18 Larynx

Parapharyngeal nerves and vessels. Dorsal aspect of the pharynx.



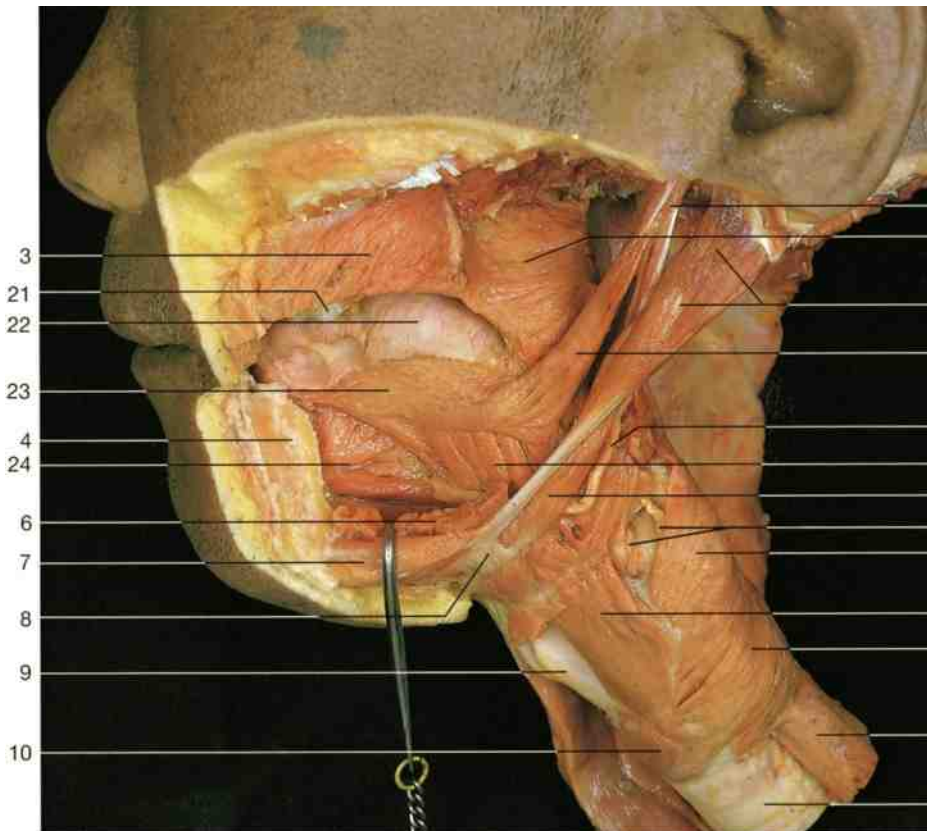
- 19 Buccinator muscle
- 20 Soft palate and palatine glands
- 21 Palatine tonsil
- 22 Uvula of palate
- 23 Pharynx (oral part)
- 24 Parotid gland
- 25 Longus capitis muscle
- 26 Median atlanto-axial joint and anterior arch of atlas
- 27 Dens of axis
- 28 Spinal cord
- 29 Dura mater
- 30 Incisive papilla
- 31 Oral vestibule
- 32 Masseter muscle
- 33 Mandible
- 34 Mandibular canal with vessels and nerve
- 35 Medial pterygoid muscle
- 36 External carotid artery
- 37 Internal carotid artery
- 38 Atlas
- 39 Vertebral artery
- 40 Splenius capitis muscle
- 41 Semispinalis capitis muscle

Cross section of head and neck at the level of the atlas (inferior aspect).

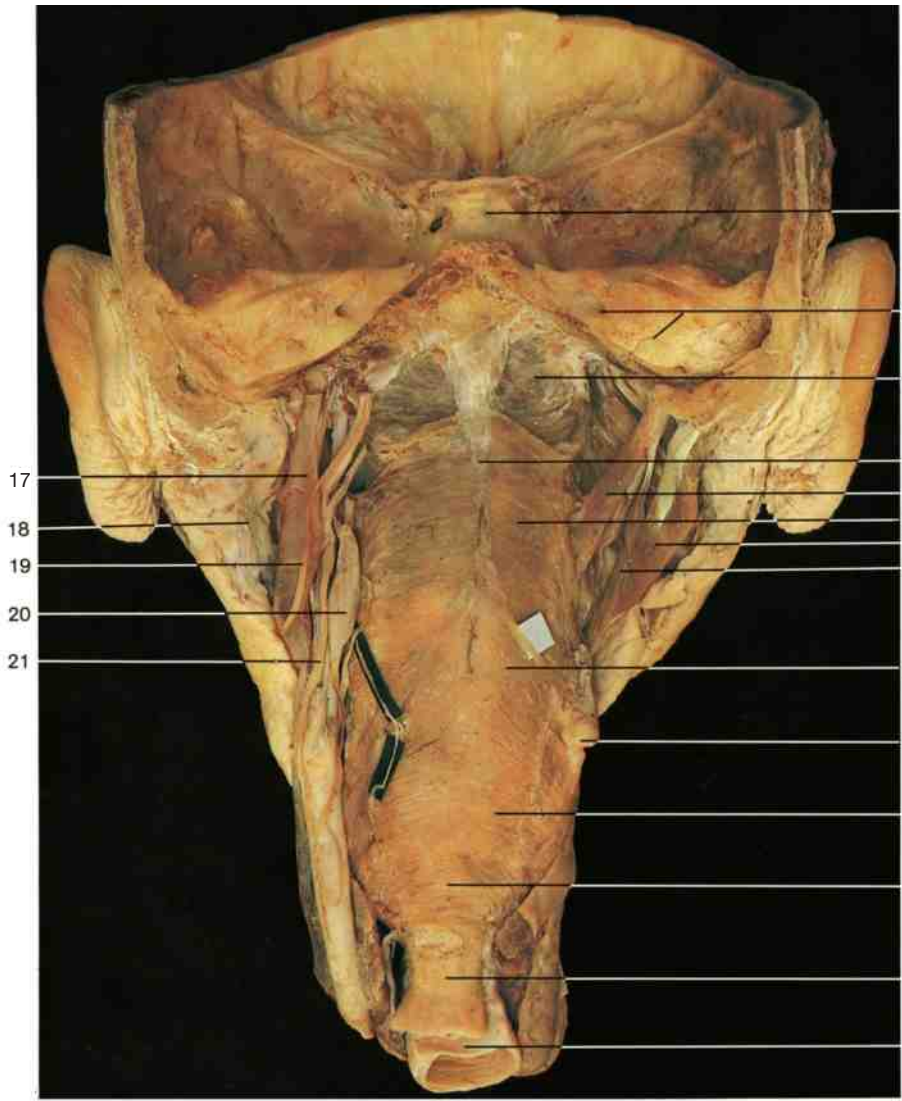


Dissection of pharynx, supra-, and infrahyoid muscles. Mandible partly removed (lateral aspect).

- 1 Maxilla
- 2 Pterygomandibular raphe
- 3 Buccinator muscle
- 4 Mandible (divided)
- 5 Depressor anguli oris muscle
- 6 Mylohyoid muscle
- 7 Anterior belly of digastric muscle
- 8 Hyoid bone
- 9 Thyroid cartilage
- 10 Cricothyroid muscle
- 11 Styloid process
- 12 Medial pterygoid muscle (divided)
- 13 Posterior belly of digastric muscle
- 14 Styloglossus muscle
- 15 Stylohyoid muscle
- 16 Thyropharyngeal part of inferior constrictor muscle of pharynx
- 17 Thyrohyoid muscle
- 18 Cricopharyngeal part of inferior constrictor muscle of pharynx
- 19 Esophagus
- 20 Trachea
- 21 First molar of maxilla
- 22 Tongue
- 23 Inferior longitudinal muscle of tongue
- 24 Genioglossus muscle
- 25 Superior constrictor muscle of pharynx
- 26 Hypoglossal nerve
- 27 Hyoglossus muscle
- 28 Superior laryngeal nerve and superior laryngeal artery

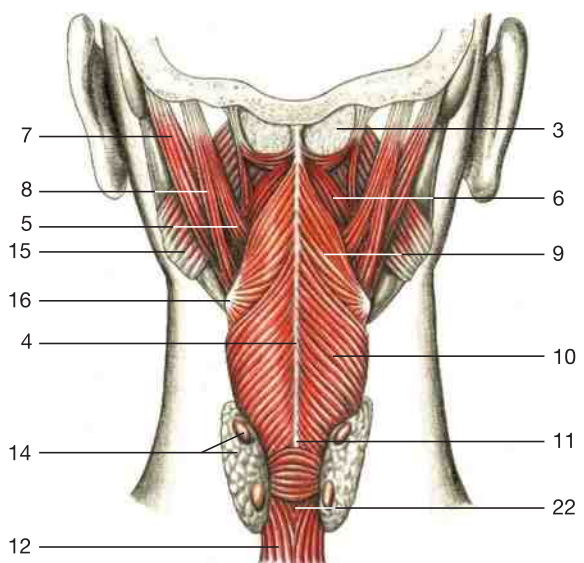


Dissection of pharynx, supra-, and infrahyoid muscles. Oral cavity opened (lateral aspect).

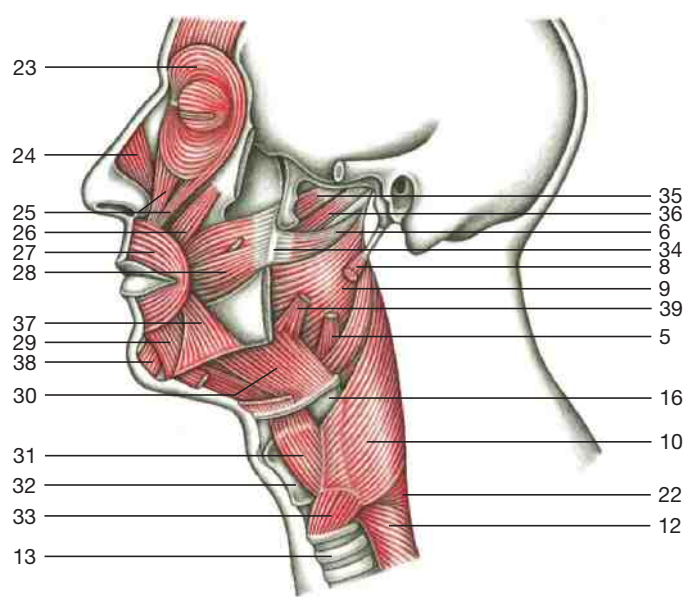


- 1 Sella turcica
- 2 Internal acoustic meatus and petrous part of temporal bone
- 3 Pharyngobasilar fascia
- 4 Fibrous raphe of pharynx
- 5 Stylopharyngeal muscle
- 6 Superior constrictor muscle of pharynx
- 7 Posterior belly of digastric muscle
- 8 Stylohyoid muscle
- 9 Middle constrictor muscle of pharynx
- 10 Inferior constrictor muscle of pharynx
- 11 Muscle-free area (Killian's triangle)
- 12 Esophagus
- 13 Trachea
- 14 Thyroid and parathyroid glands
- 15 Medial pterygoid muscle
- 16 Greater horn of hyoid bone
- 17 Internal jugular vein
- 18 Parotid gland
- 19 Accessory nerve
- 20 Superior cervical ganglion of sympathetic trunk
- 21 Vagus nerve
- 22 Laimer's triangle (area prone to developing diverticula)
- 23 Orbicularis oculi muscle
- 24 Nasalis muscle
- 25 Levator labii superioris and levator labii alaeque nasi muscles
- 26 Levator anguli oris muscle
- 27 Orbicularis oris muscle
- 28 Buccinator muscle
- 29 Depressor labii inferioris muscle
- 30 Hyoglossus muscle
- 31 Thyrohyoid muscle
- 32 Thyroid cartilage
- 33 Cricothyroid muscle
- 34 Pterygomandibular raphe
- 35 Tensor veli palatini muscle
- 36 Levator veli palatini muscle
- 37 Depressor anguli oris muscle
- 38 Mentalis muscle
- 39 Styloglossus muscle

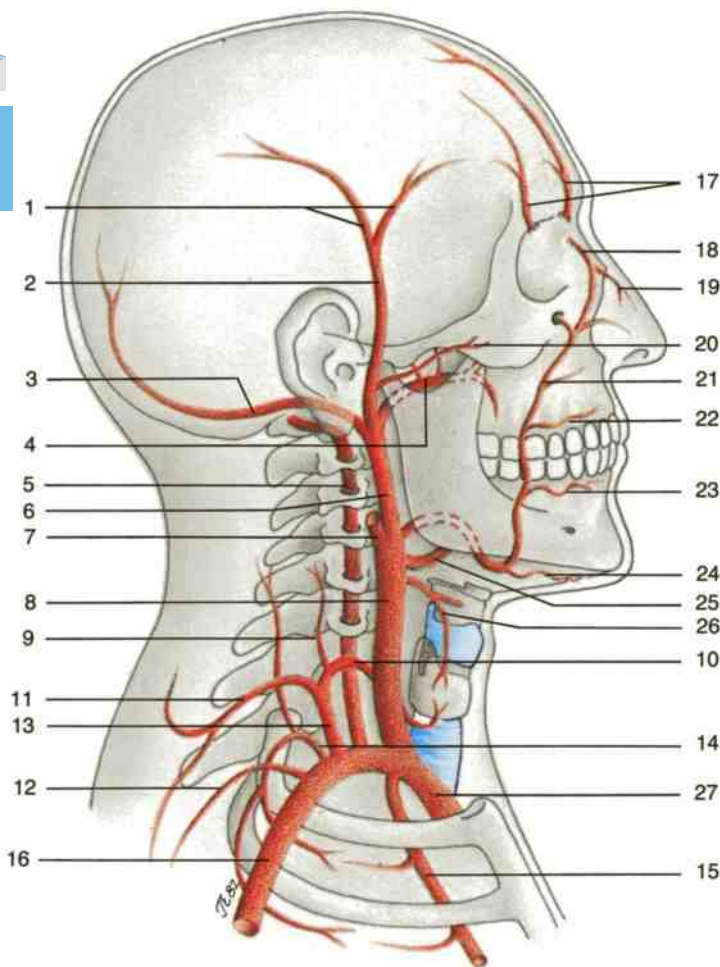
Muscles of the pharynx (posterior aspect).



Muscles of the pharynx (posterior aspect). (Schematic drawing.)



Muscles of the pharynx (lateral aspect). (Schematic drawing.)

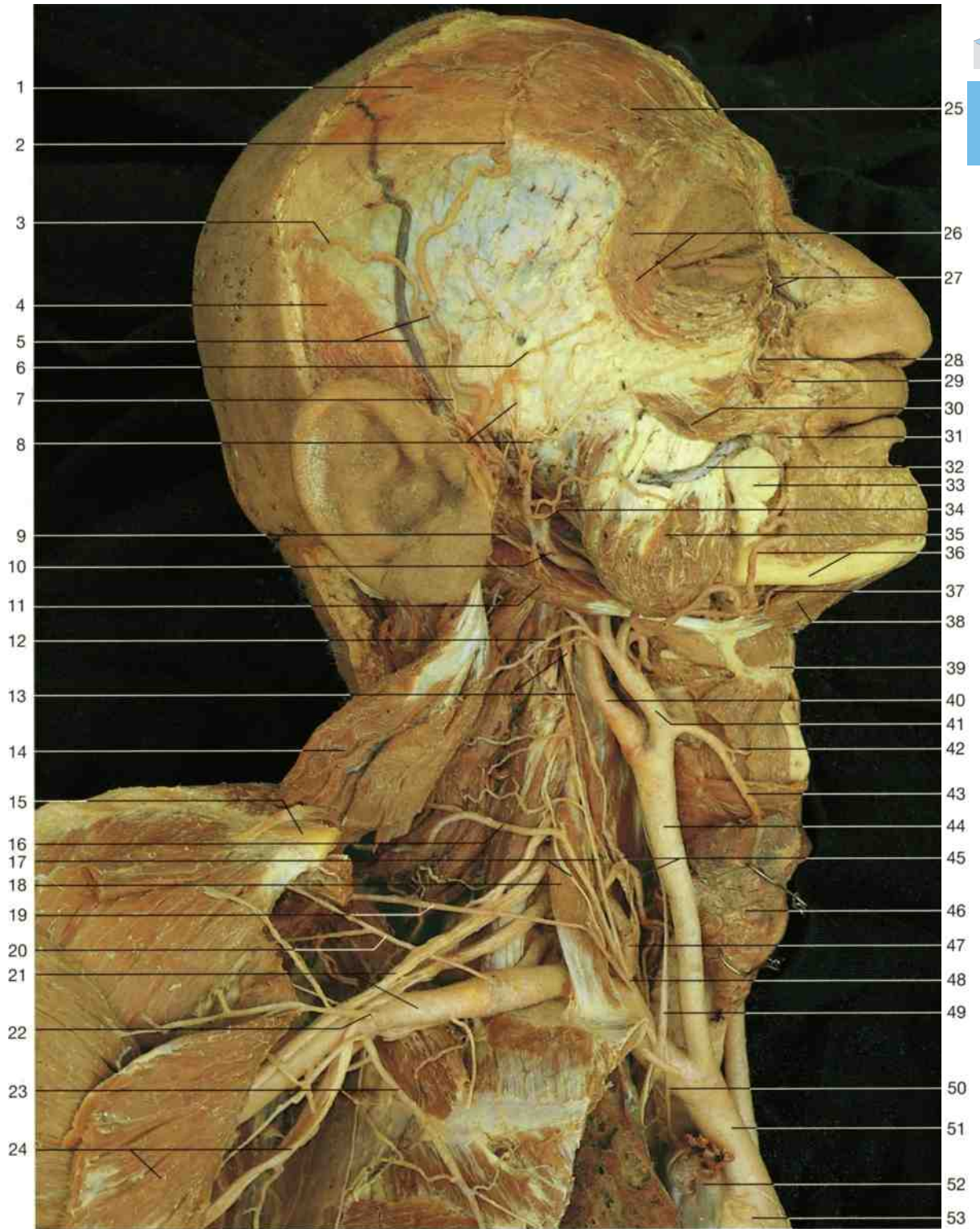


- 1 Frontal and parietal branches of superficial temporal artery
- 2 Superficial temporal artery
- 3 Occipital artery
- 4 Maxillary artery
- 5 Vertebral artery
- 6 External carotid artery
- 7 Internal carotid artery
- 8 Common carotid artery (divided)
- 9 Ascending cervical artery
- 10 Inferior thyroid artery
- 11 Transverse cervical artery with two branches (superficial cervical artery and descending scapular artery)
- 12 Suprascapular artery
- 13 Thyrocervical trunk
- 14 Costocervical trunk with two branches (deep cervical artery and superior intercostal artery)
- 15 Internal thoracic artery
- 16 Axillary artery
- 17 Supra-orbital and supratrochlear arteries
- 18 Angular artery
- 19 Dorsal nasal artery
- 20 Transverse facial artery
- 21 Facial artery
- 22 Superior labial artery
- 23 Inferior labial artery
- 24 Submental artery
- 25 Lingual artery
- 26 Superior thyroid artery
- 27 Brachiocephalic trunk

Arteries of head and neck. Diagram of the main branches of external carotid and subclavian arteries.

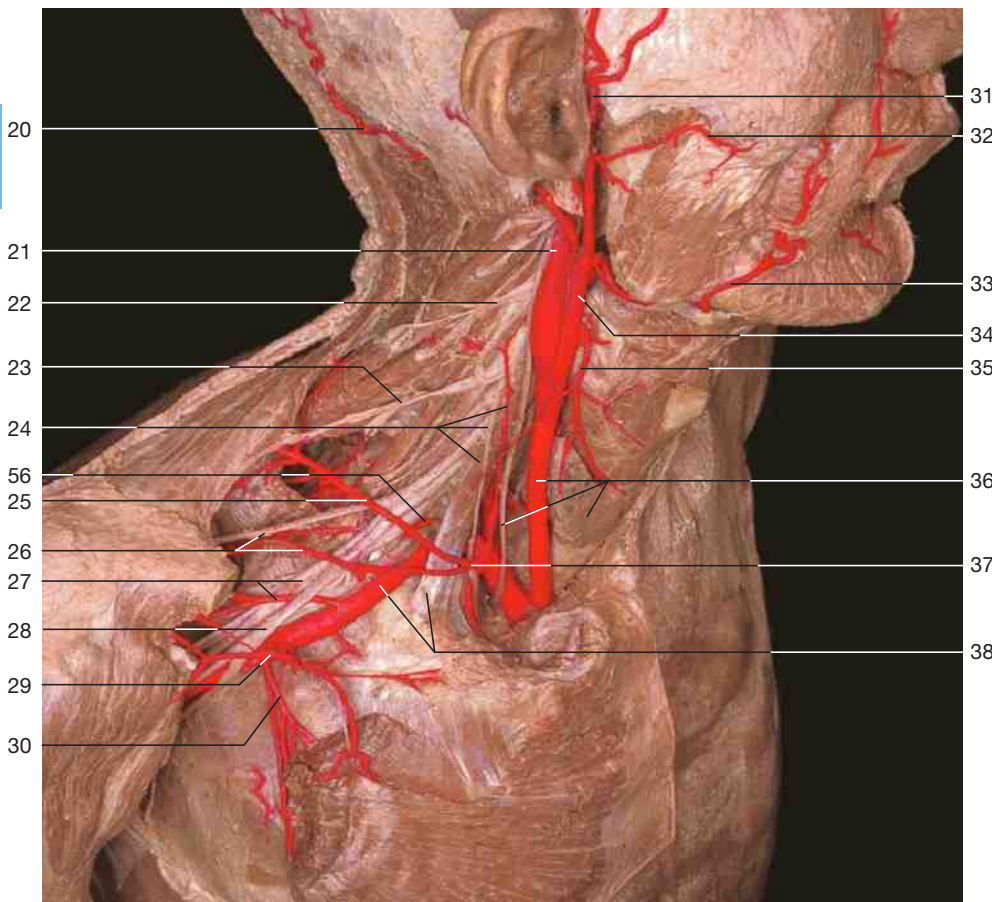
▷ To page 169:

- | | |
|---|---|
| 1 Galea aponeurotica | 20 Dorsal scapular artery |
| 2 Frontal branch } of superficial | 21 Brachial plexus and axillary artery |
| 3 Parietal branch } temporal artery | 22 Thoraco-acromial artery |
| 4 Superior auricular muscle | 23 Lateral thoracic artery |
| 5 Superficial temporal artery and vein | 24 Median nerve (displaced) and pectoralis minor muscle (reflected) |
| 6 Middle temporal artery | 25 Frontal belly of occipitofrontalis muscle |
| 7 Auriculotemporal nerve | 26 Orbital part of orbicularis oculi muscle |
| 8 Branches of facial nerve | 27 Angular artery and vein |
| 9 Facial nerve | 28 Facial artery |
| 10 External carotid artery within the retromandibular fossa | 29 Superior labial artery |
| 11 Posterior belly of digastric muscle | 30 Zygomaticus major muscle |
| 12 Sternocleidomastoid artery | 31 Inferior labial artery |
| 13 Sympathetic trunk and superior cervical ganglion | 32 Parotid duct |
| 14 Sternocleidomastoid muscle (divided and reflected) | 33 Buccal fat pad |
| 15 Clavicle (divided) | 34 Maxillary artery |
| 16 Transverse cervical artery | 35 Masseter muscle |
| 17 Ascending cervical artery and phrenic nerve | 36 Facial artery and mandible |
| 18 Scalenus anterior muscle | 37 Submental artery |
| 19 Suprascapular artery | 38 Anterior belly of digastric muscle |

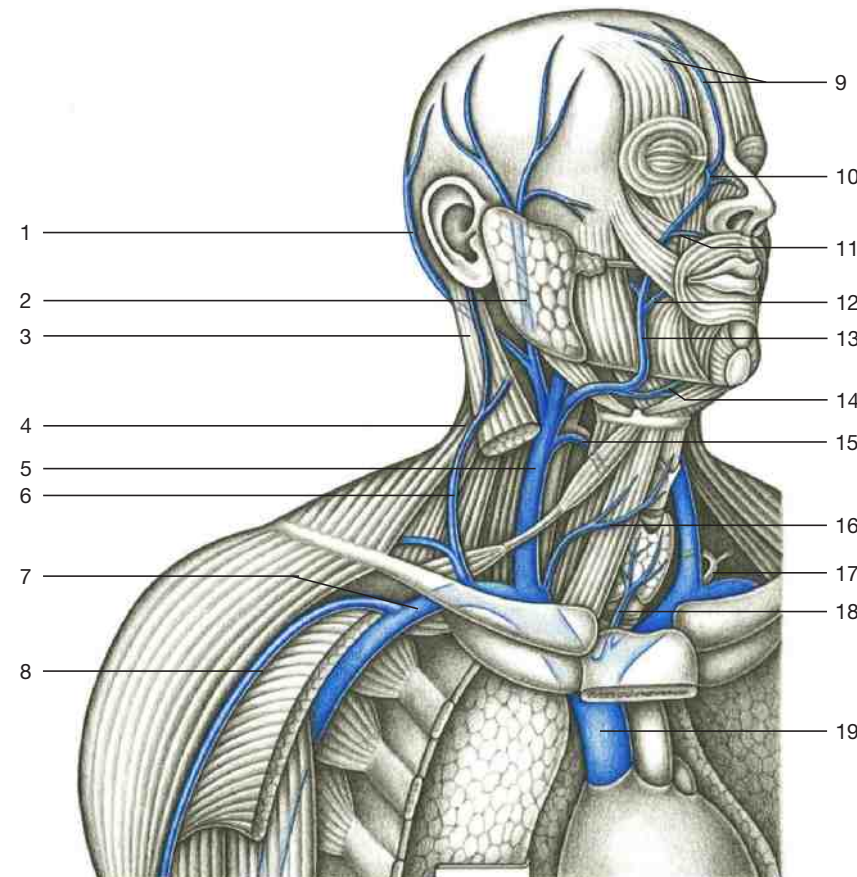


Main branches of head and neck arteries (lateral aspect). Anterior thoracic wall and clavicle partly removed; pectoralis muscles have been reflected to display the subclavian and axillary arteries.

- | | | | |
|----|---|----|-------------------------------------|
| 39 | Hyoid bone | 46 | Thyroid gland (right lobe) |
| 40 | Internal carotid artery | 47 | Vertebral artery |
| 41 | External carotid artery | 48 | Thyrocervical trunk |
| 42 | Superior laryngeal artery | 49 | Vagus nerve |
| 43 | Superior thyroid artery | 50 | Ansa subclavia of sympathetic trunk |
| 44 | Common carotid artery | 51 | Brachiocephalic trunk |
| 45 | Thyroid ansa of sympathetic trunk and inferior thyroid artery | 52 | Superior vena cava (divided) |
| | | 53 | Aortic arch |

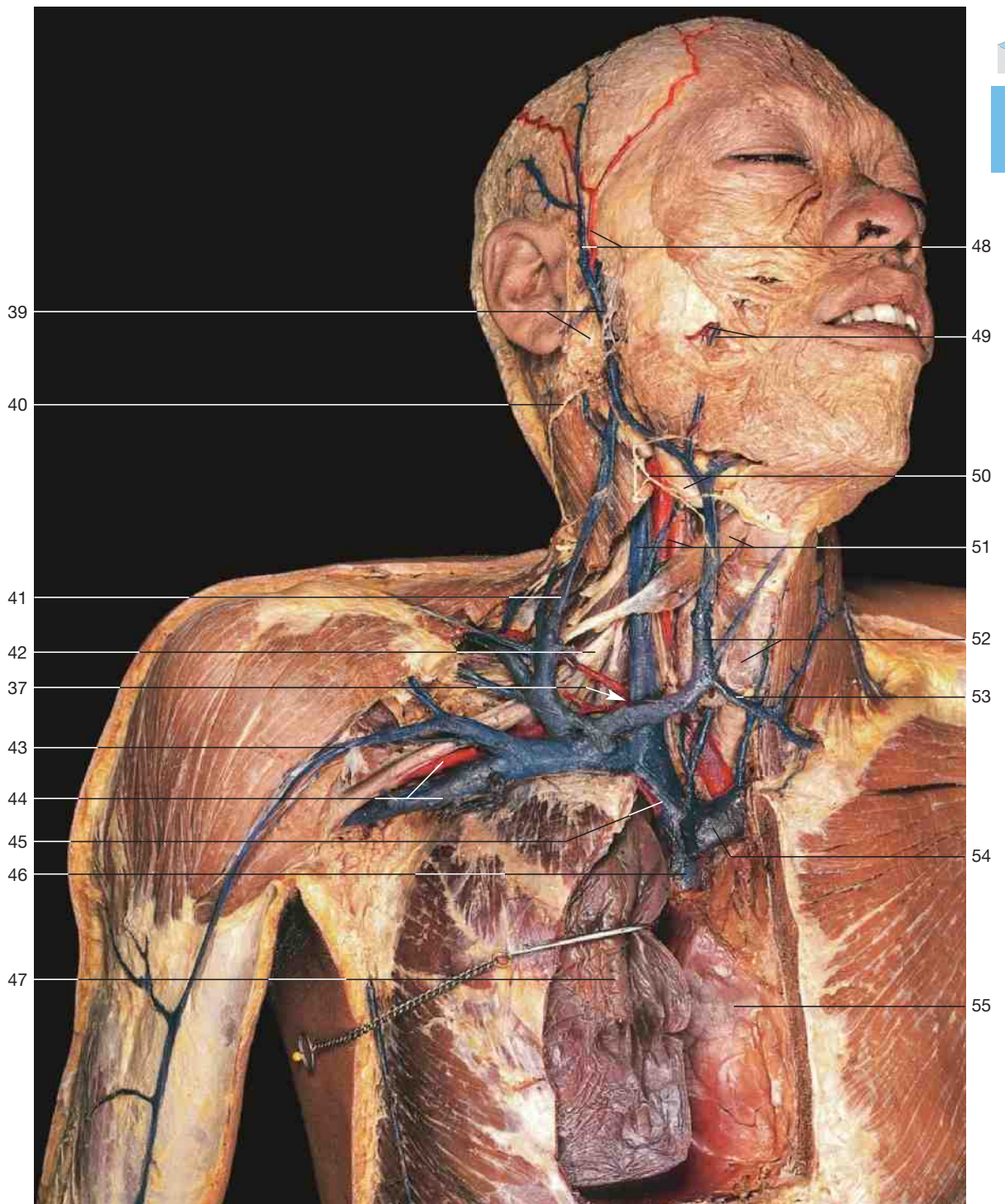


Arteries of head and neck (antero-lateral aspect). Clavicle, sternocleidomastoid muscle, and veins have been partly removed; the arteries have been colored.



Veins of head and neck. Sternocleidomastoid muscle and anterior thoracic wall partly removed. Note the venous connection with the superior vena cava.

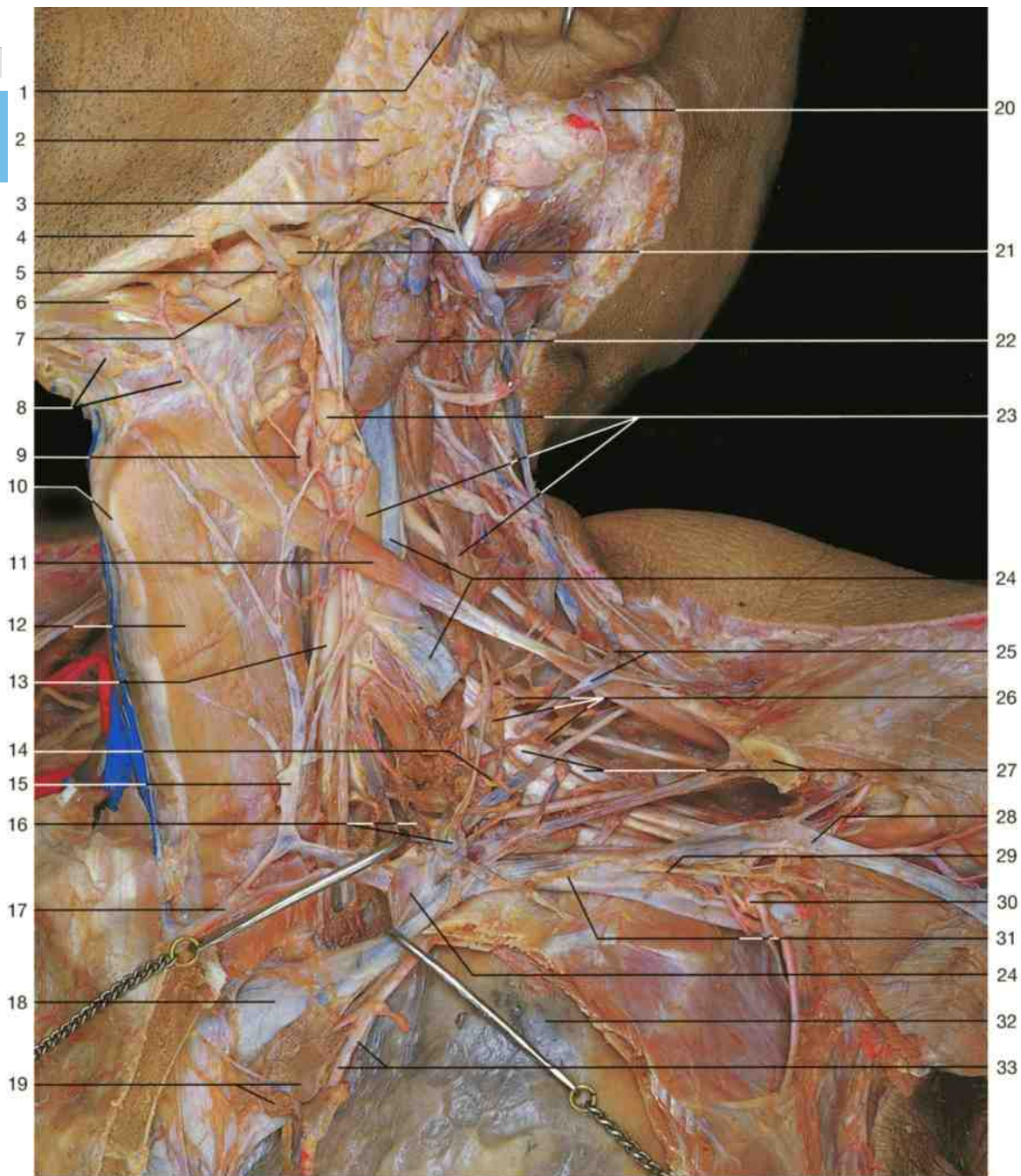
- 1 Occipital vein
- 2 Superficial temporal vein
- 3 Sternocleidomastoid muscle
- 4 Trapezius muscle
- 5 Internal jugular vein
- 6 External jugular vein
- 7 Subclavian vein
- 8 Cephalic vein
- 9 Supra-orbital veins
- 10 Angular vein
- 11 Superior labial vein
- 12 Inferior labial vein
- 13 Facial vein
- 14 Submental vein
- 15 Superior thyroid vein
- 16 Anterior jugular vein
- 17 Thoracic duct
- 18 Inferior thyroid vein
- 19 Superior vena cava
- 20 Occipital branch of occipital artery
- 21 Internal carotid artery
- 22 Cervical plexus
- 23 Supraclavicular nerve
- 24 Phrenic nerve and ascending cervical artery on scalenus anterior muscle
- 25 Superficial cervical artery
- 26 Suprascapular artery and nerve
- 27 Brachial plexus and anterior circumflex humeral artery
- 28 Lateral cord of brachial plexus
- 29 Thoraco-acromial artery
- 30 Lateral thoracic artery
- 31 Superficial temporal artery
- 32 Transverse facial artery
- 33 Facial artery
- 34 External carotid artery
- 35 Superior thyroid artery
- 36 Common carotid artery, vagus nerve, and thyroid gland
- 37 Thyrocervical trunk
- 38 Subclavian artery and scalenus anterior muscle
- 39 Parotid gland and facial nerve
- 40 Great auricular nerve
- 41 External jugular vein
- 42 Brachial plexus
- 43 Cephalic vein in deltopectoral groove
- 44 Axillary vein and artery
- 45 Right brachiocephalic vein
- 46 Superior vena cava
- 47 Right lung (reflected)
- 48 Superficial temporal artery and vein
- 49 Facial artery and vein
- 50 Cervical branch of facial nerve and submandibular gland
- 51 Internal jugular vein, common carotid artery, and omohyoid muscle
- 52 Anterior jugular vein and thyroid gland
- 53 Jugular venous arch
- 54 Left brachiocephalic vein
- 55 Pericardium of heart (location of right atrium)
- 56 Transverse cervical artery



Veins of head and neck (anterior aspect). Part of the thoracic wall, clavicle, and sternocleidomastoid muscle have been removed. Veins are colored blue; arteries, red.

The **internal jugular vein** is the continuation of the sigmoid sinus, which drains most of the venous blood from the brain together with the external cerebrospinal fluid. By joining the subclavian vein, it forms the right brachiocephalic vein, which continues on the right side directly into the superior vena cava. The common way to introduce the lead from a pacemaker device into the heart is by way of the cephalic vein. On the left side, the thoracic duct joins the internal jugular vein at the point where the subclavian vein

and the internal jugular vein form the left brachiocephalic vein. Note that the subclavian vein lies in front of the scalenus anterior muscle, whereas the subclavian artery and the brachial plexus lie posterior to that muscle. The **cephalic vein** joins the axillary vein by passing into the deltopectoral triangle. The **subclavian vein** is strongly fixed to the first rib, so it can be punctured with a needle at that point (underneath the sternal end of the clavicle) to introduce a catheter (subclavian line).

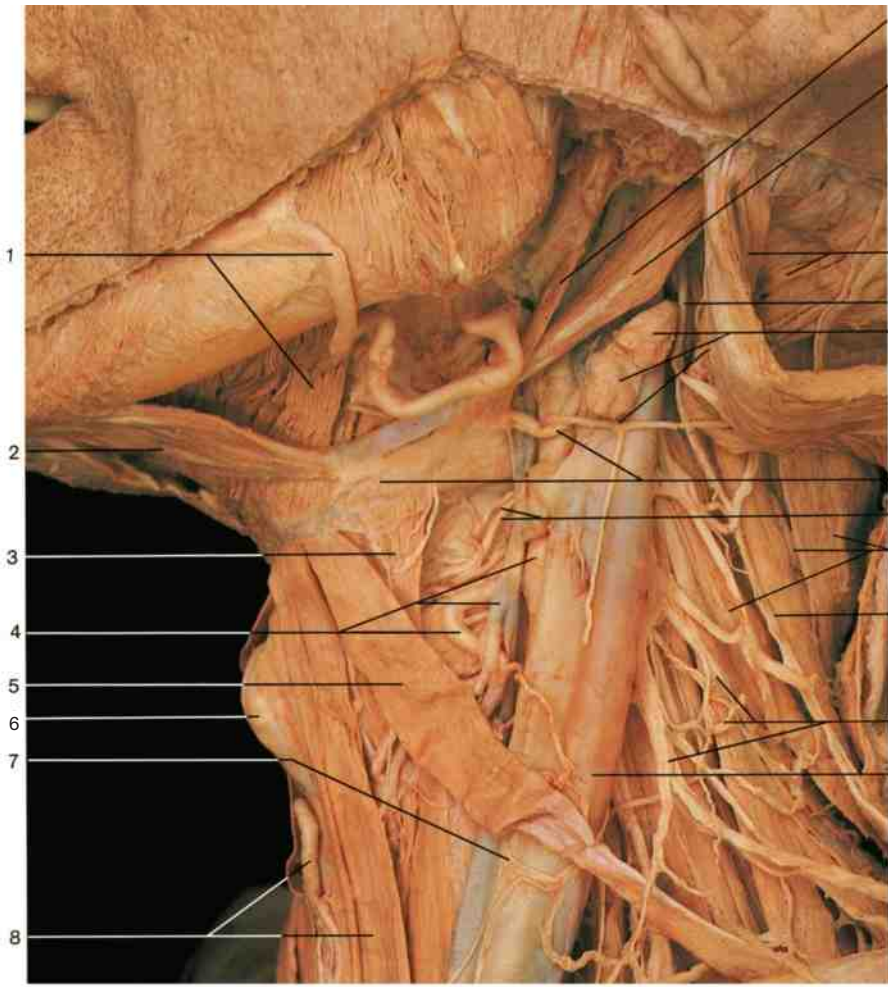


Lymph nodes and lymph vessels of the neck, left side oblique (oblique-lateral aspect). The sternocleidomastoid muscle and the left half of the thoracic wall have been removed. Lower part of the internal jugular vein has been cut and laterally displaced to show the thoracic duct.

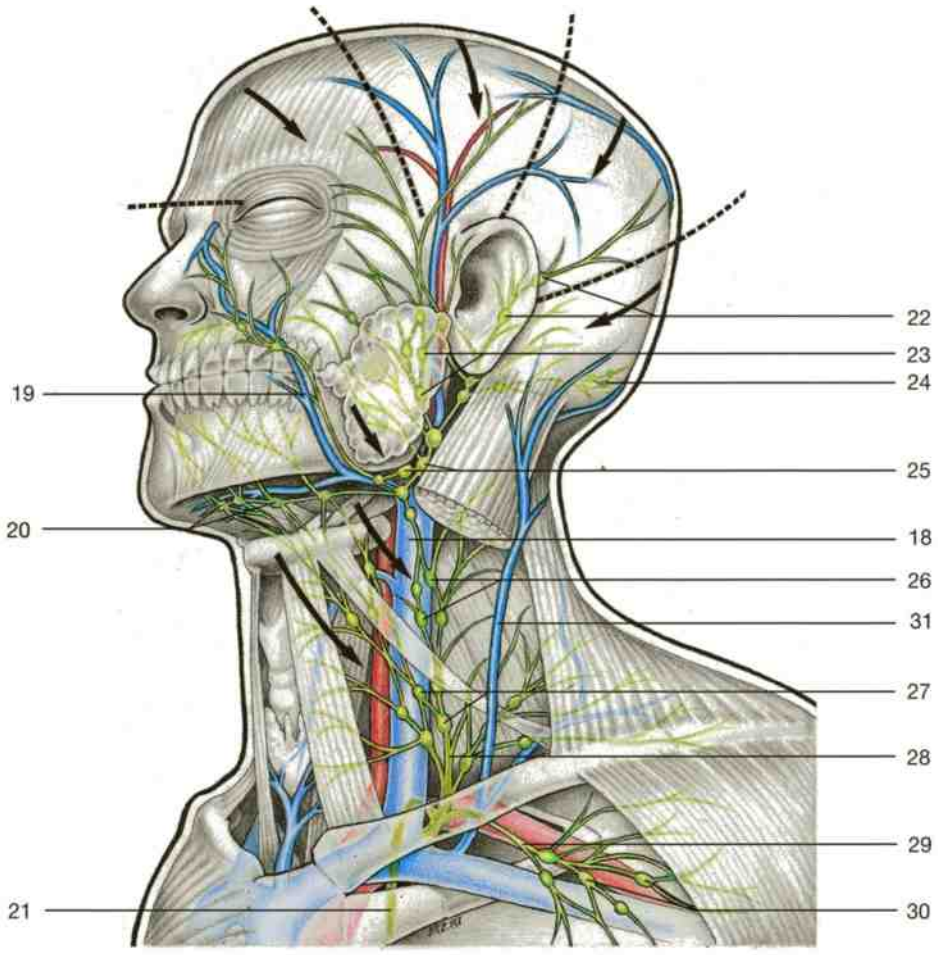
- | | | |
|--------------------------------------|--|--------------------------------------|
| 1 Superficial parotid lymph node | 13 Common carotid artery | 24 Internal jugular vein |
| 2 Parotid gland | 14 Supraclavicular lymph nodes | 25 External jugular vein |
| 3 Great auricular nerve | 15 Anterior jugular vein | 26 Jugulo-omohyoid lymph nodes |
| 4 Mandible | 16 Thoracic duct and internal jugular vein | 27 Brachial plexus |
| 5 Facial vein | 17 Jugular venous arch | 28 Cephalic vein |
| 6 Anterior belly of digastric muscle | 18 Left brachiocephalic vein | 29 Subclavian trunk |
| 7 Submandibular gland | 19 Superior mediastinal lymph nodes | 30 Infraclavicular lymph nodes |
| 8 Submental lymph nodes | 20 Retro-auricular lymph nodes | 31 Subclavian vein |
| 9 Superior thyroid artery | 21 Submandibular nodes | 32 Lung |
| 10 Thyroid cartilage | 22 Superficial cervical lymph nodes | 33 Internal thoracic artery and vein |
| 11 Omohyoid muscle | 23 Jugulodigastric lymph nodes and jugular trunk | |
| 12 Sternohyoid muscle | | |



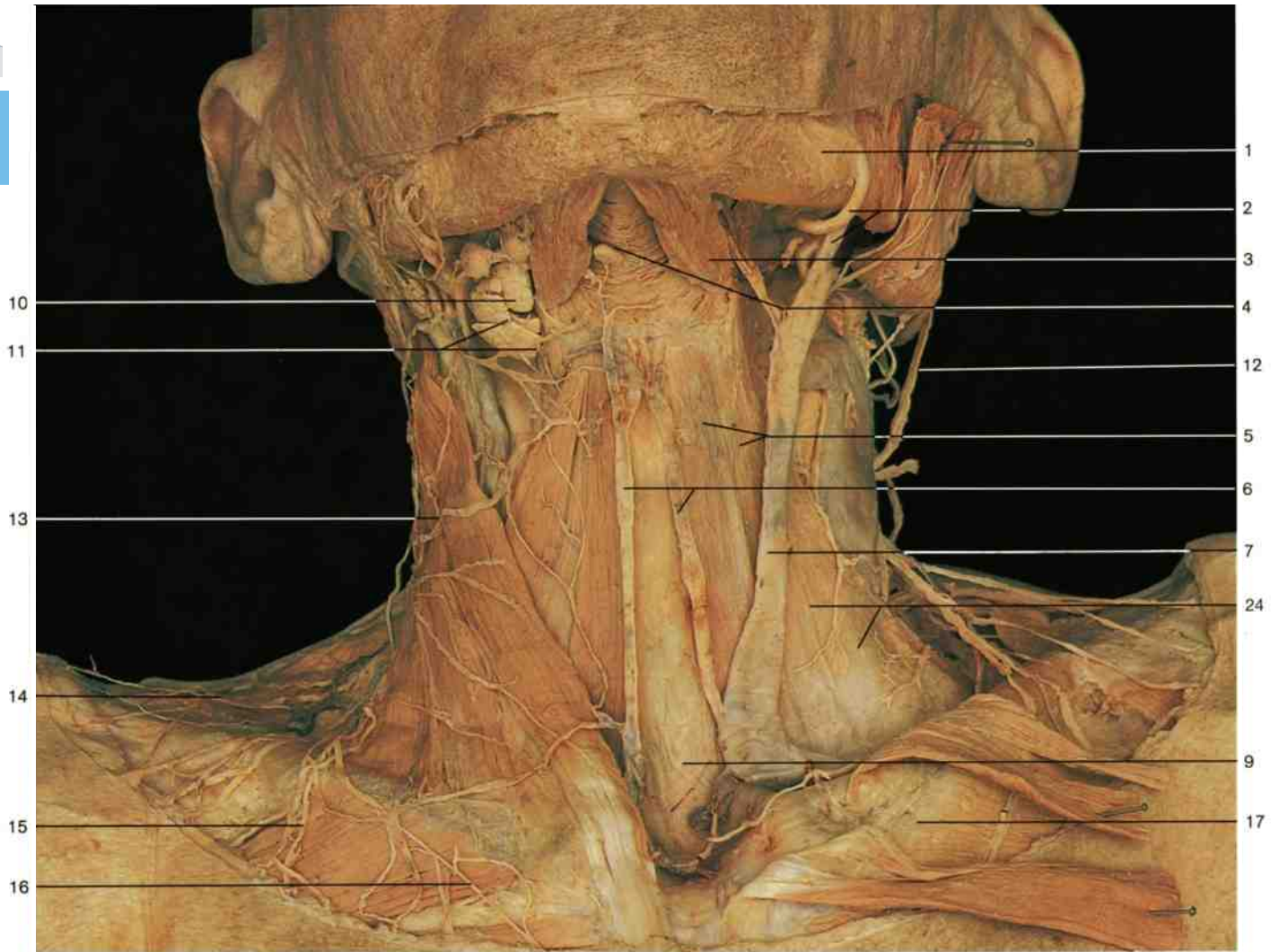
Carotid triangle, left side (lateral aspect). Sternocleidomastoid muscle reflected.



- 1 Mylohyoid muscle and facial artery
- 2 Anterior belly of digastric muscle
- 3 Thyroid
- 4 External carotid artery, superior thyroid artery, and vein
- 5 Omohyoid muscle
- 6 Thyroid cartilage
- 7 Ansa cervicalis
- 8 Sternohyoid muscle and superior thyroid artery
- 9 Stylohyoid muscle
- 10 Posterior belly of digastric muscle
- 11 Sternocleidomastoid muscle (reflected)
- 12 Superior cervical lymph nodes and sternocleidomastoid artery
- 13 Hyoid bone and hypoglossal nerve (n. XII)
- 14 Splenius capitis and levator scapulae muscles
- 15 Superior laryngeal artery and internal branch of superior laryngeal nerve
- 16 Accessory nerve
- 17 Cervical plexus
- 18 Internal jugular vein
- 19 Facial vein
- 20 Submental nodes
- 21 Thoracic duct
- 22 Retro-auricular nodes
- 23 Parotid nodes
- 24 Occipital nodes
- 25 Submandibular nodes
- 26 Jugulodigastric nodes
- 27 Jugulo-omohyoid nodes
- 28 Jugular trunk
- 29 Subclavian trunk
- 30 Infraclavicular nodes
- 31 External jugular vein



Lymph nodes and veins of head and neck. Dotted lines = border between irrigation areas; arrows: direction of lymph flow.

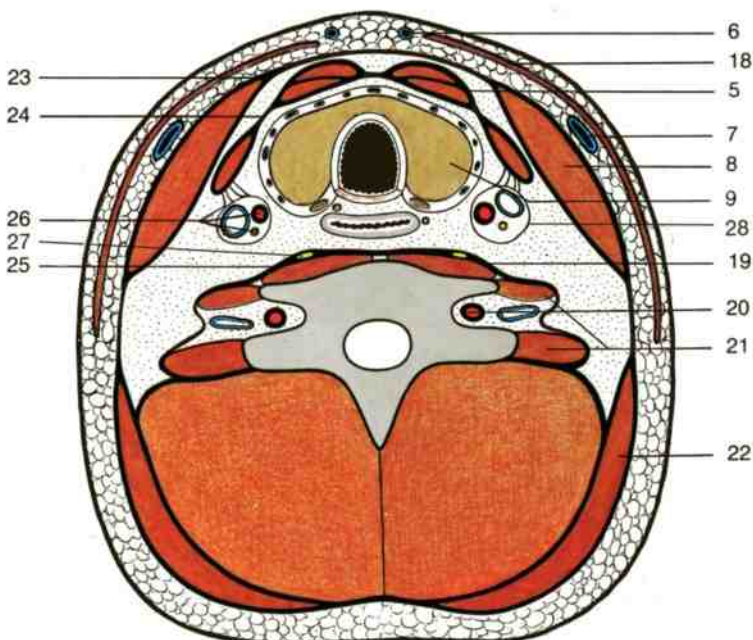


Anterior region of the neck. The superficial fascia has been removed.

- 1 Mandible
- 2 Facial artery and vein
- 3 Anterior belly of digastric muscle
- 4 Mylohyoid muscle
- 5 Infrahyoid muscles (sternohyoid, sternothyroid, and omohyoid muscles)
- 6 Anterior jugular veins
- 7 External jugular vein

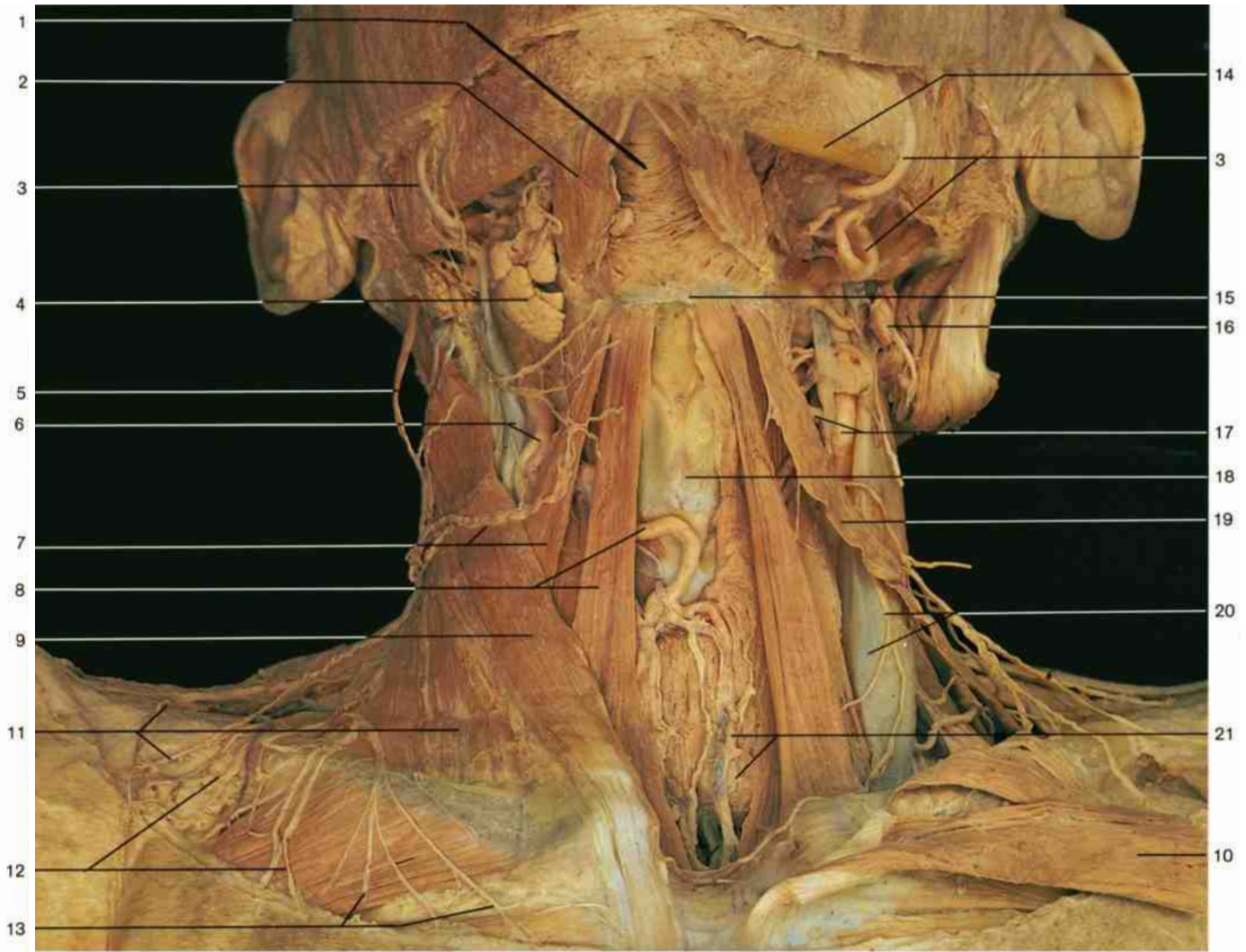
- 8 Sternocleidomastoid muscle
- 9 Thyroid gland
- 10 Submandibular gland
- 11 Cervical branch of facial nerve
- 12 Great auricular nerve
- 13 Transverse cervical nerves
- 14 Lateral supraclavicular nerves
- 15 Middle supraclavicular nerves
- 16 Medial supraclavicular nerves
- 17 Clavicle

} Cutaneous branches of cervical plexus

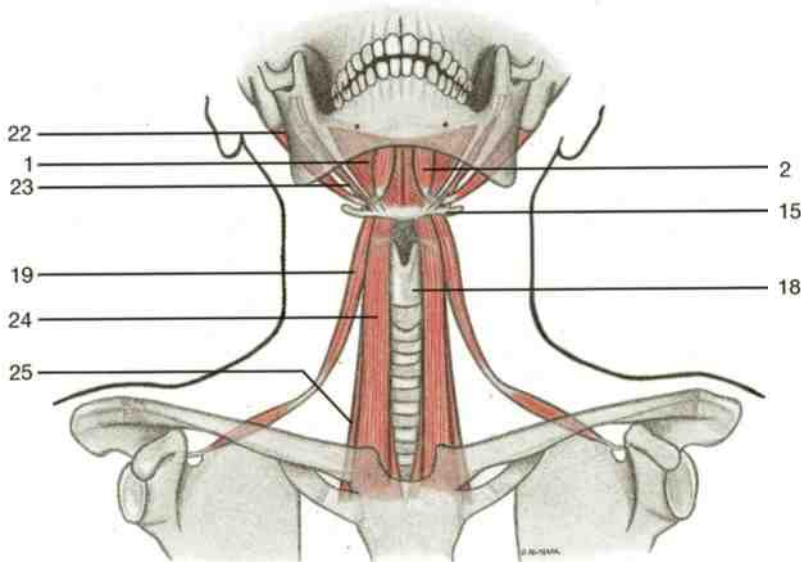


- 18 Platysma muscle
- 19 Prevertebral lamina of cervical fascia, covering longus colli muscle
- 20 Vertebral artery and vein
- 21 Scalenus muscles
- 22 Trapezius muscle
- 23 Superficial lamina of cervical fascia
- 24 Pretracheal lamina of cervical fascia
- 25 Prevertebral lamina of cervical fascia
- 26 Carotid sheath with common carotid artery, internal jugular vein, and vagus nerve
- 27 Cervical part of sympathetic trunk
- 28 Carotid sheath

◁ **Cross section of the neck** at the level of the thyroid gland. Notice the position of the three laminae of cervical fascia (23, 24, 25).

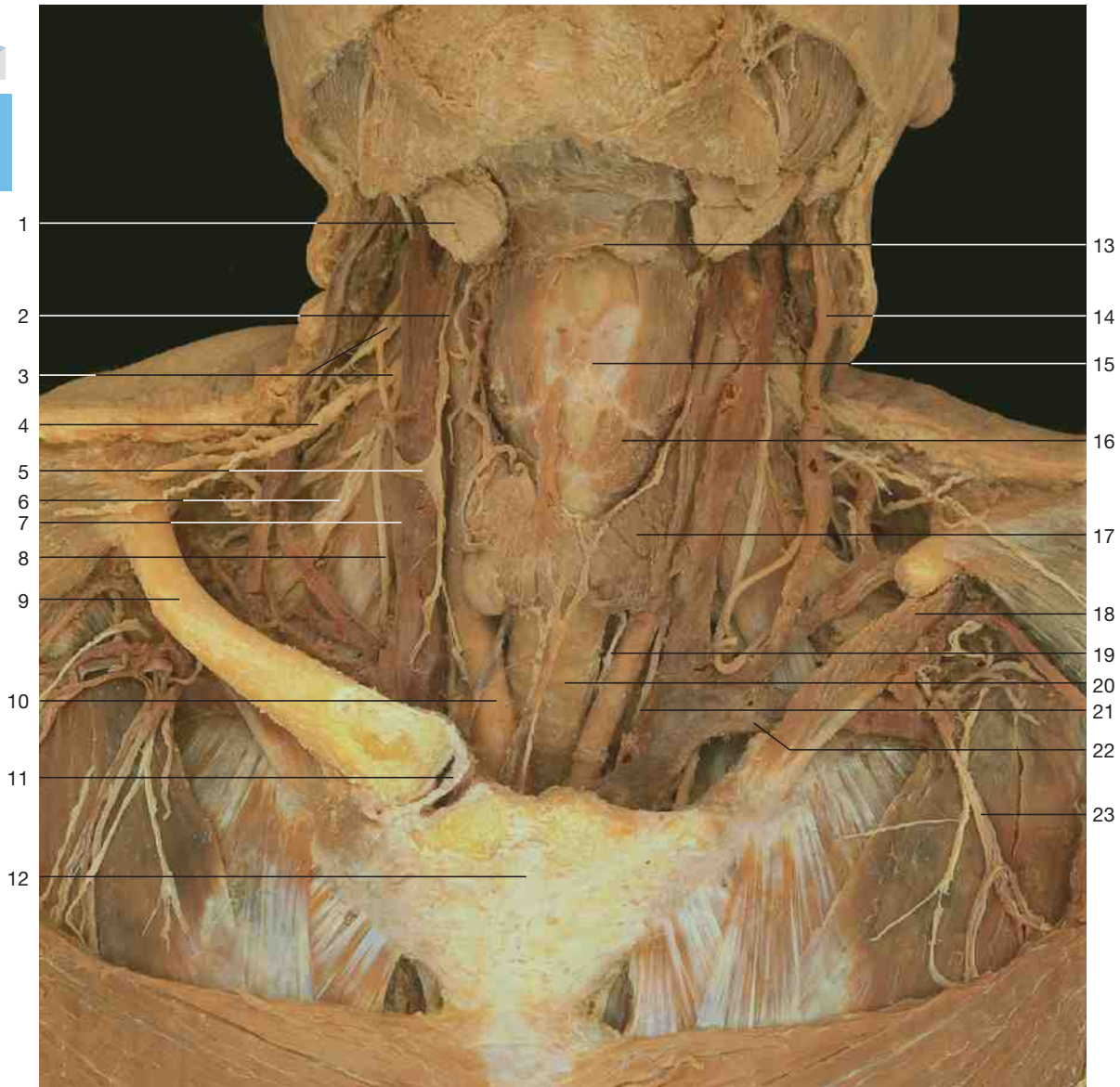


Anterior region of the neck with anterior triangle. The pretracheal lamina of cervical fascia and left sternocleidomastoid muscle have been removed.

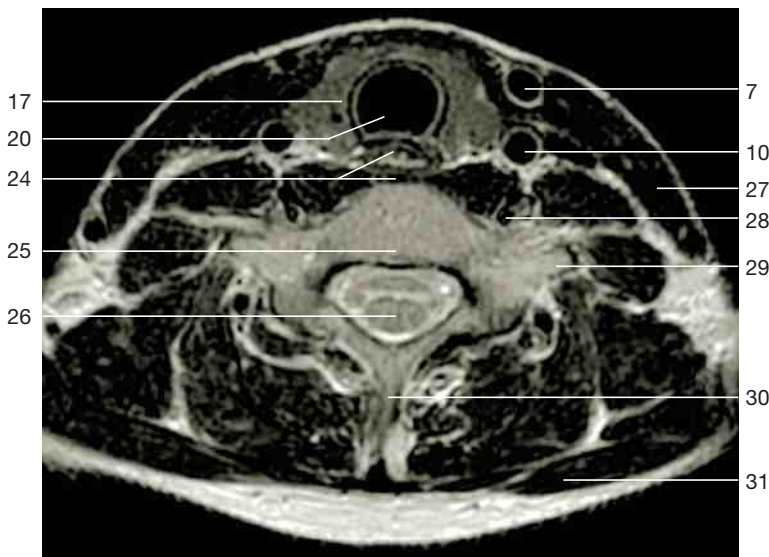


Supra- and infrahyoid muscles (schematic drawing).

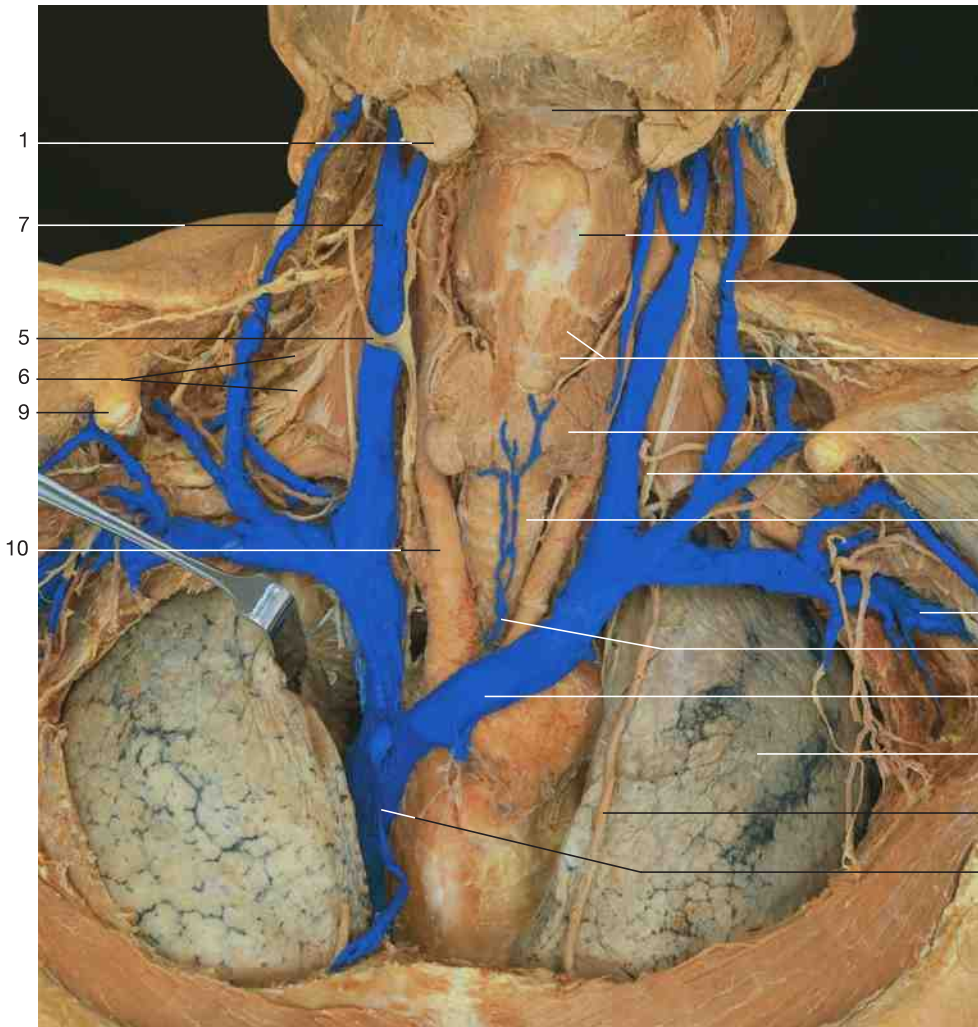
- 1 Mylohyoid muscle
- 2 Anterior belly of digastric muscle
- 3 Facial artery
- 4 Submandibular gland
- 5 Great auricular nerve
- 6 Internal jugular vein and common carotid artery
- 7 Transverse cervical nerve and omohyoid muscle
- 8 Sternohyoid muscle and superior thyroid artery
- 9 Sternocleidomastoid muscle (sternal head)
- 10 Left sternocleidomastoid muscle (reflected)
- 11 Sternocleidomastoid muscle (clavicular head) and lateral supraclavicular nerves
- 12 Middle supraclavicular nerves
- 13 Medial supraclavicular nerves
- 14 Mandible
- 15 Hyoid bone
- 16 Superficial cervical lymph nodes
- 17 Left superior thyroid artery and external carotid artery
- 18 Thyroid cartilage
- 19 Omohyoid muscle (superior belly)
- 20 Internal jugular vein and branches of ansa cervicalis
- 21 Thyroid gland and unpaired inferior thyroid vein
- 22 Posterior belly of digastric muscle
- 23 Stylohyoid muscle
- 24 Sternohyoid muscle
- 25 Sternothyroid muscle



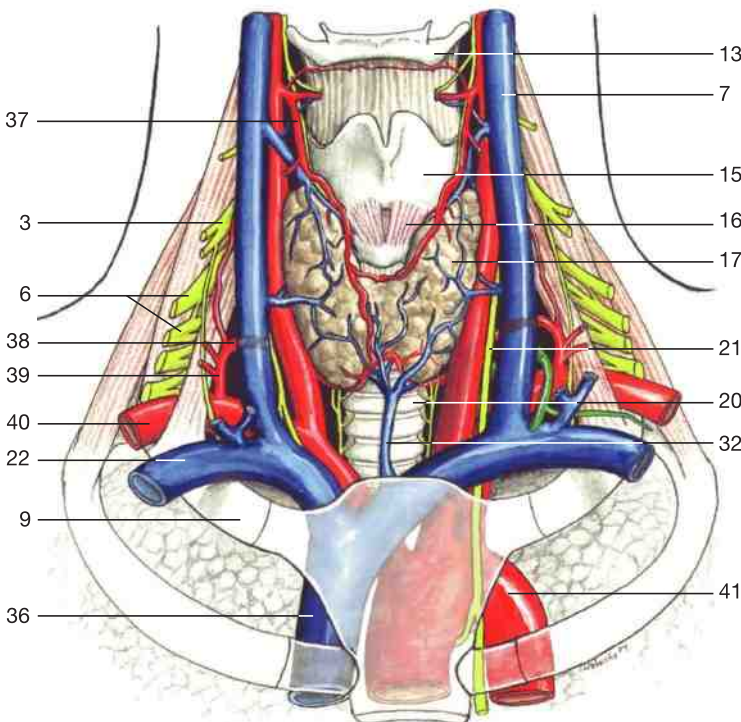
Anterior region of the neck. Sternocleidomastoid muscles and left clavicle have been removed. Thyroid gland in relation to trachea, larynx, and vessels of the neck is shown.



Cross section of the neck at the level of the thyroid gland (MRI scan, courtesy of Prof. Heuck, Munich).

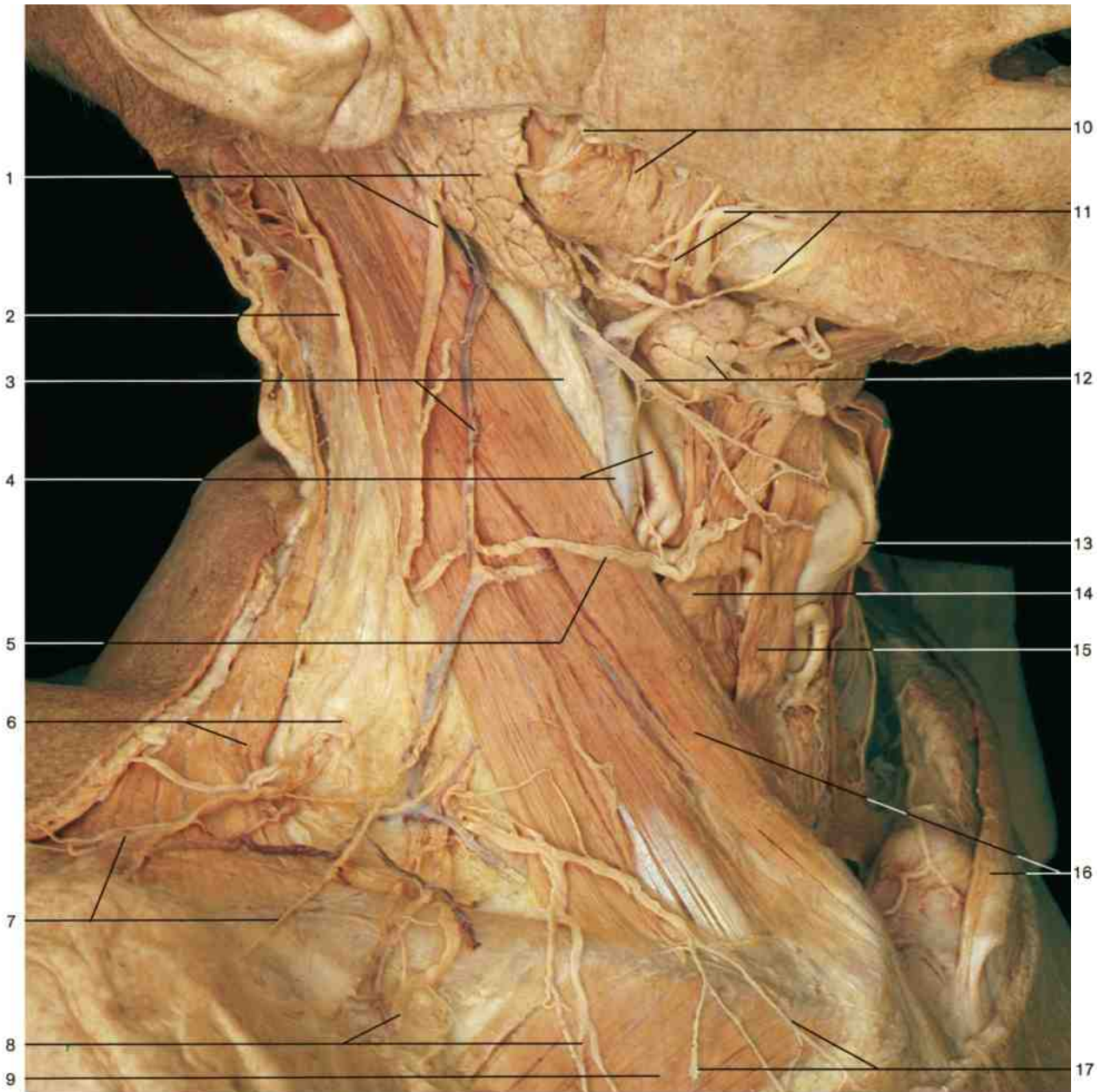


Anterior region of the neck and thoracic cavity. Both clavicles, sternum, and ribs have been removed. Main veins are colored in blue.



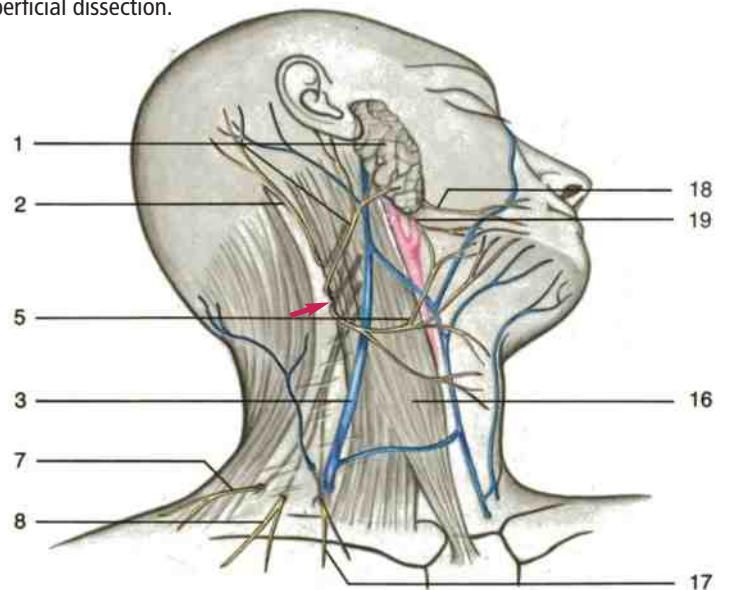
Anterior region of the neck (schematic drawing). Regional anatomy of the thyroid gland with related blood vessels.

- 1 Submandibular gland
- 2 Cervical branch of facial nerve (n. VII)
- 3 Cervical plexus
- 4 Middle supraclavicular nerves
- 5 Ansa cervicalis
- 6 Brachial plexus
- 7 Internal jugular vein
- 8 Phrenic nerve
- 9 Clavicle
- 10 Common carotid artery
- 11 Sternoclavicular articulation with articular disc
- 12 Manubrium of sternum
- 13 Hyoid bone
- 14 External jugular vein
- 15 Thyroid cartilage
- 16 Cricothyroid muscle
- 17 Thyroid gland
- 18 Subclavius muscle
- 19 Recurrent laryngeal nerve
- 20 Trachea
- 21 Vagus nerve (n. X)
- 22 Subclavian vein
- 23 Middle pectoral nerve
- 24 Esophagus
- 25 Body of cervical vertebra
- 26 Spinal cord
- 27 Sternocleidomastoid muscle
- 28 Vertebral artery
- 29 Transverse process of cervical vertebra
- 30 Spinous process of cervical vertebra
- 31 Trapezius muscle
- 32 Inferior thyroid vein
- 33 Left brachiocephalic vein
- 34 Superior lobe of left lung
- 35 Internal thoracic artery
- 36 Superior vena cava
- 37 Superior thyroid artery
- 38 Inferior thyroid artery
- 39 Thyrocervical trunk
- 40 Subclavian artery
- 41 Aortic arch

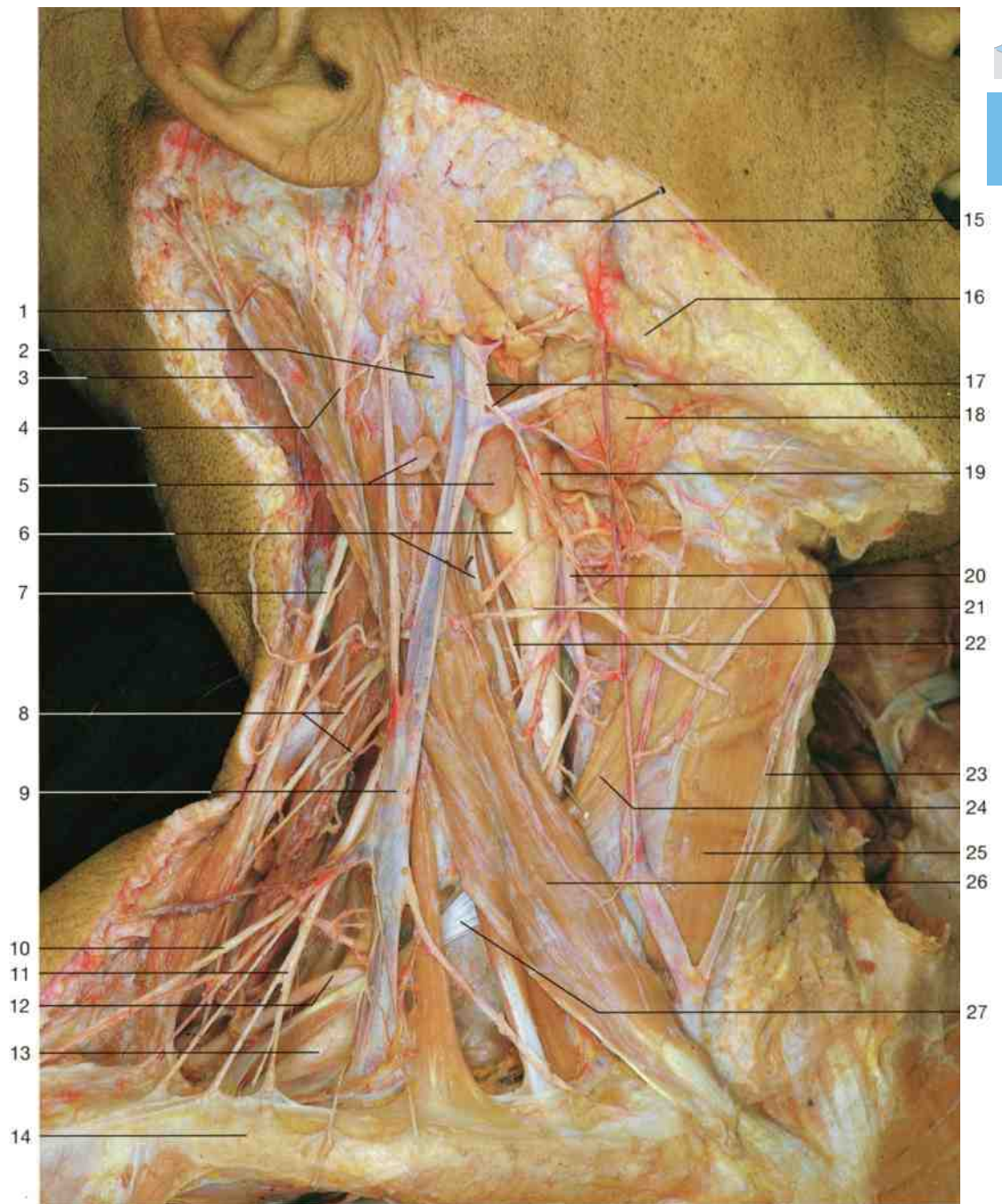


Lateral region of the neck with posterior and carotid triangles. Superficial dissection.

- | | |
|--|---|
| 1 Parotid gland and great auricular nerve | 11 Facial artery and vein and mandibular branch of facial nerve |
| 2 Lesser occipital nerve | 12 Cervical branch of facial nerve and submandibular gland |
| 3 Internal and external jugular veins | 13 Thyroid cartilage |
| 4 Retromandibular vein and external carotid artery | 14 Omohyoid muscle |
| 5 Transverse cervical nerve with communicating branch to cervical branch of facial nerve | 15 Sternohyoid muscle |
| 6 Trapezius muscle and superficial lamina of cervical fascia | 16 Sternocleidomastoid muscle |
| 7 Lateral supraclavicular nerves | 17 Medial supraclavicular nerves |
| 8 Middle supraclavicular nerves | 18 Mandibular branch of facial nerve |
| 9 Pectoralis major muscle | 19 Cervical branch of facial nerve with communicating branch to transverse cervical nerve |
| 10 Buccal branch of facial nerve and masseter muscle | |

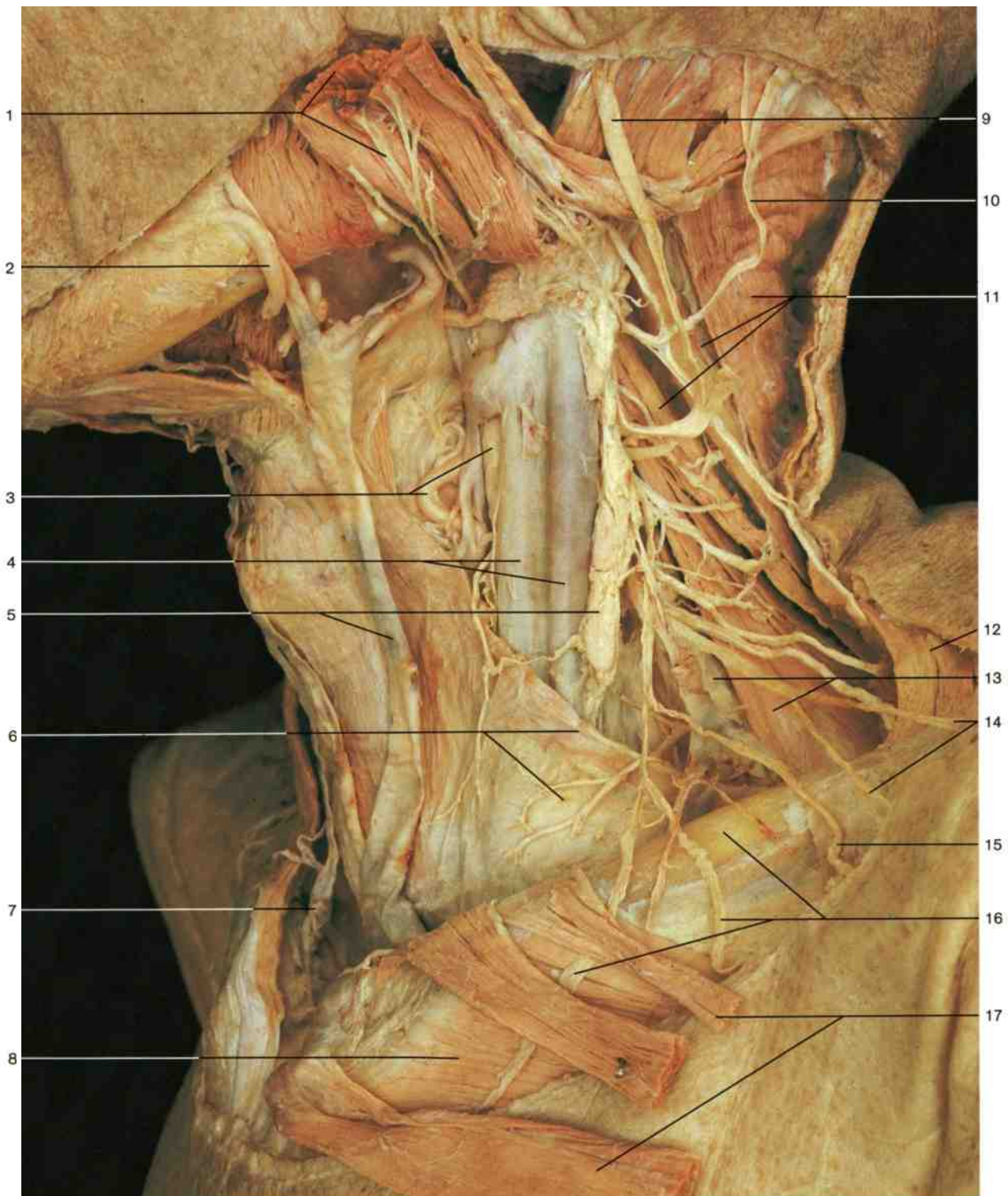


Cutaneous branches of cervical plexus. Erb's point is indicated by an arrowhead (schematic drawing).



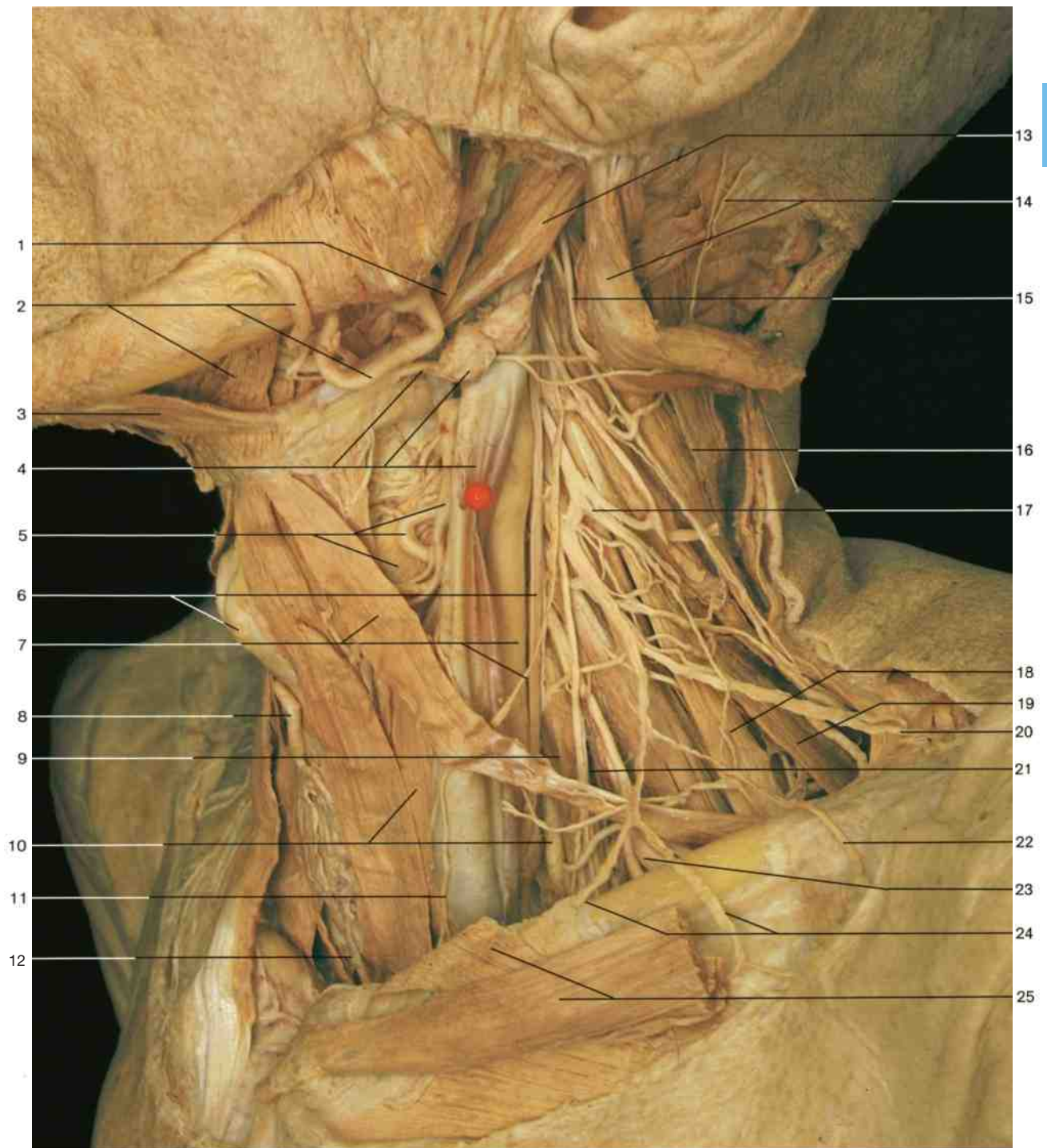
Lateral region of the neck with posterior and carotid triangles. Superficial dissection. The superficial lamina of cervical fascia has been removed to display the cutaneous branches of the cervical plexus and subcutaneous veins.

- | | |
|---|---|
| 1 Lesser occipital nerve | 15 Parotid gland |
| 2 Internal jugular vein | 16 Mandible |
| 3 Splenius capitis muscle | 17 Cervical branch of facial nerve |
| 4 Great auricular nerve | 18 Submandibular gland |
| 5 Submandibular nodes | 19 External carotid artery |
| 6 Internal carotid artery and vagus nerve | 20 Superior thyroid artery |
| 7 Accessory nerve | 21 Transverse cervical nerve |
| 8 Muscular branches of cervical plexus | 22 Superior root of ansa cervicalis |
| 9 External jugular vein | 23 Anterior jugular vein |
| 10 Posterior supraclavicular nerves | 24 Omohyoid muscle |
| 11 Middle supraclavicular nerves | 25 Sternohyoid muscle |
| 12 Suprascapular artery | 26 Sternocleidomastoid muscle |
| 13 Pretracheal lamina of fascia of neck | 27 Intermediate tendon of omohyoid muscle |
| 14 Clavicle | |



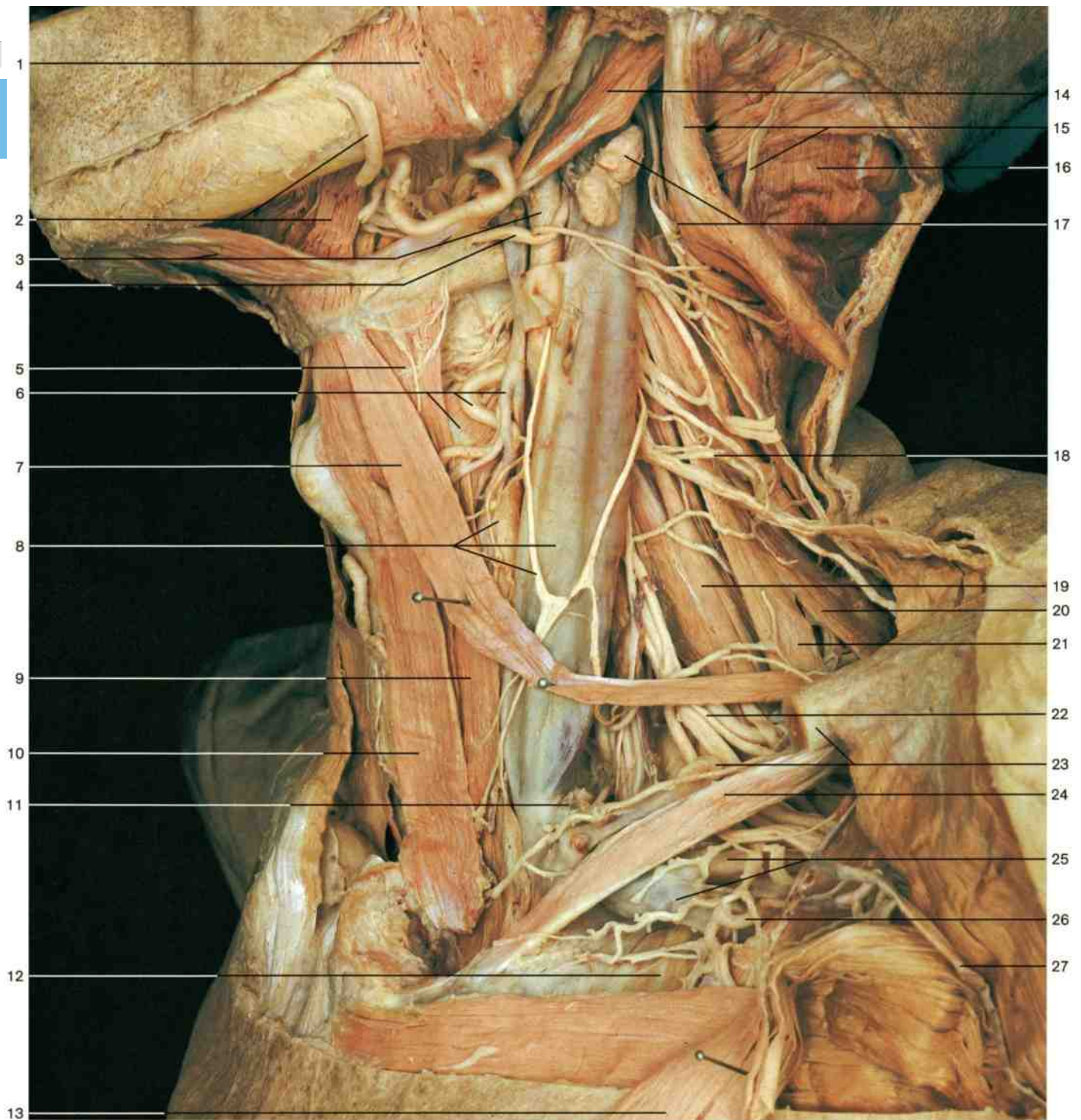
Neck, superficial dissection (lateral aspect). Sternocleidomastoid muscle has been cut and reflected to display the pretracheal lamina of the cervical fascia.

- | | |
|--|--|
| 1 Sternocleidomastoid muscle (reflected) and branch of accessory nerve | 9 Great auricular nerve |
| 2 Facial artery | 10 Lesser occipital nerve |
| 3 External carotid artery and superior thyroid artery | 11 Splenius capitis and levator scapulae muscles |
| 4 Internal jugular vein | 12 Trapezius muscle |
| 5 Deep cervical lymph nodes and external jugular vein | 13 Scalenus medius muscle and brachial plexus |
| 6 Omohyoid muscle and pretracheal lamina of cervical fascia | 14 Posterior supraclavicular nerves |
| 7 Anterior jugular vein | 15 Middle supraclavicular nerve |
| 8 Pectoralis major muscle | 16 Clavicle and anterior supraclavicular nerves |
| | 17 Sternocleidomastoid muscle (reflected) |



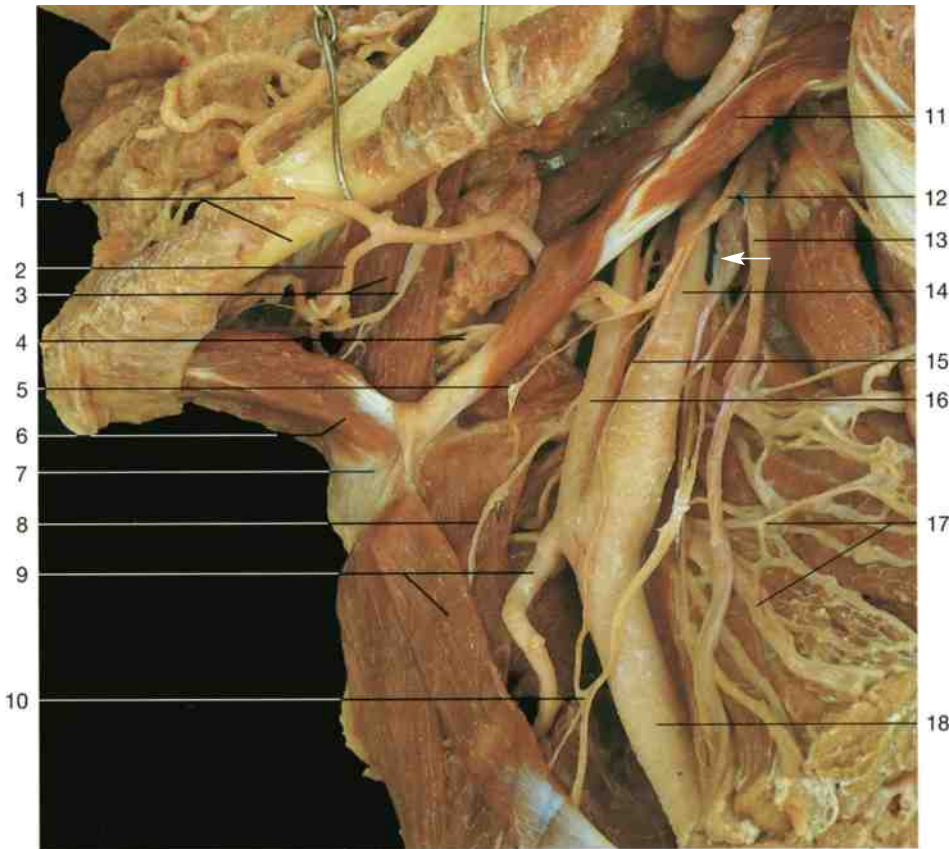
Neck, deep dissection (lateral aspect). The internal jugular vein has been reflected to expose the carotid artery and vagus nerve.

- | | |
|--|--|
| 1 Stylohyoid muscle | 13 Posterior belly of digastric muscle |
| 2 Facial artery and mylohyoid muscle | 14 Sternocleidomastoid muscle and lesser occipital nerve |
| 3 Anterior belly of digastric muscle | 15 Accessory nerve |
| 4 Internal jugular vein, hypoglossal nerve, and superficial cervical lymph nodes | 16 Splenius capitis muscle |
| 5 Superior thyroid artery and vein and inferior pharyngeal constrictor muscle | 17 Cervical plexus |
| 6 Thyroid cartilage and vagus nerve | 18 Scalenus posterior muscle |
| 7 Ansa cervicalis, omohyoid muscle, and common carotid artery | 19 Levator scapulae muscle |
| 8 Right superior thyroid artery | 20 Posterior supraclavicular nerves |
| 9 Scalenus anterior muscle | 21 Phrenic nerve |
| 10 Sternothyroid muscle and inferior thyroid artery | 22 Middle supraclavicular nerve |
| 11 Muscular branches of ansa cervicalis to the infrahyoid muscles | 23 Brachial plexus |
| 12 Inferior thyroid vein | 24 Anterior supraclavicular nerves |
| | 25 Sternocleidomastoid muscle |



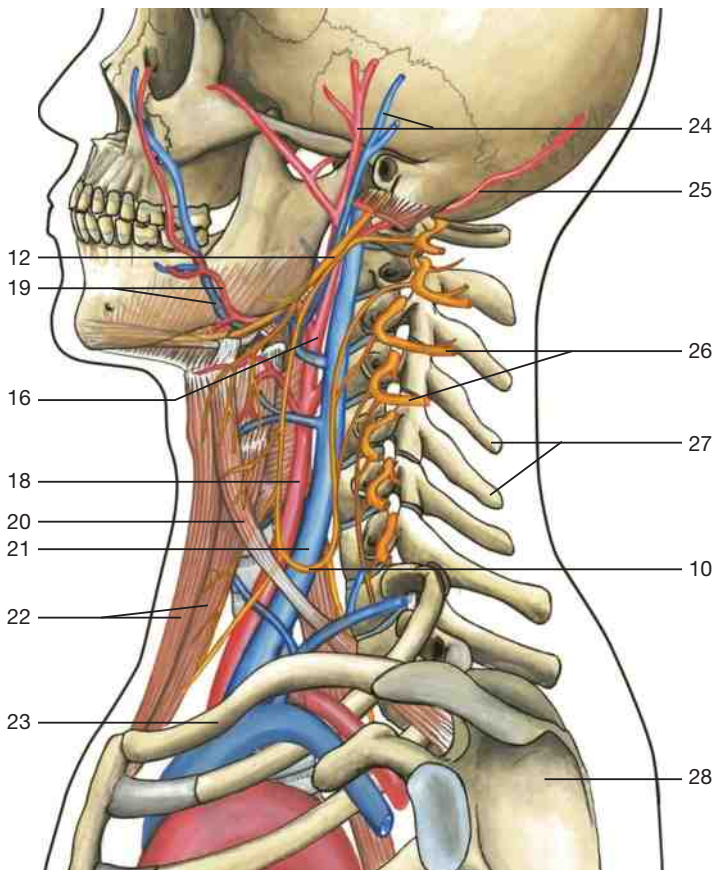
Neck, deeper dissection (lateral aspect). **Ansa cervicalis**. The cervical fascia and the clavicle are partly removed. Ansa cervicalis and infrahyoid muscles are displayed.

- | | | | | | |
|---|---|----|---|----|---|
| 1 | Masseter muscle | 9 | Sternothyroid muscle | 18 | Cervical plexus |
| 2 | Mylohyoid muscle and facial artery | 10 | Sternohyoid muscle | 19 | Scalenus medius muscle |
| 3 | External carotid artery and anterior belly of digastric muscle | 11 | Thoracic duct | 20 | Levator scapulae muscle |
| 4 | Hypoglossal nerve | 12 | Pectoralis minor muscle | 21 | Scalenus posterior muscle |
| 5 | Thyrohyoid muscle | 13 | Pectoralis major muscle | 22 | Brachial plexus |
| 6 | Superior thyroid artery and vein and inferior pharyngeal constrictor muscle | 14 | Posterior belly of digastric muscle | 23 | Transverse cervical artery and clavicle |
| 7 | Omohyoid muscle (superior belly) | 15 | Sternocleidomastoid muscle and lesser occipital nerve | 24 | Subclavius muscle |
| 8 | Ansa cervicalis, thyroid gland, and internal jugular vein | 16 | Splenius capitis muscle | 25 | Subclavian artery and vein |
| | | 17 | Superficial cervical lymph nodes and accessory nerve | 26 | Thoraco-acromial artery |
| | | | | 27 | Cephalic vein |

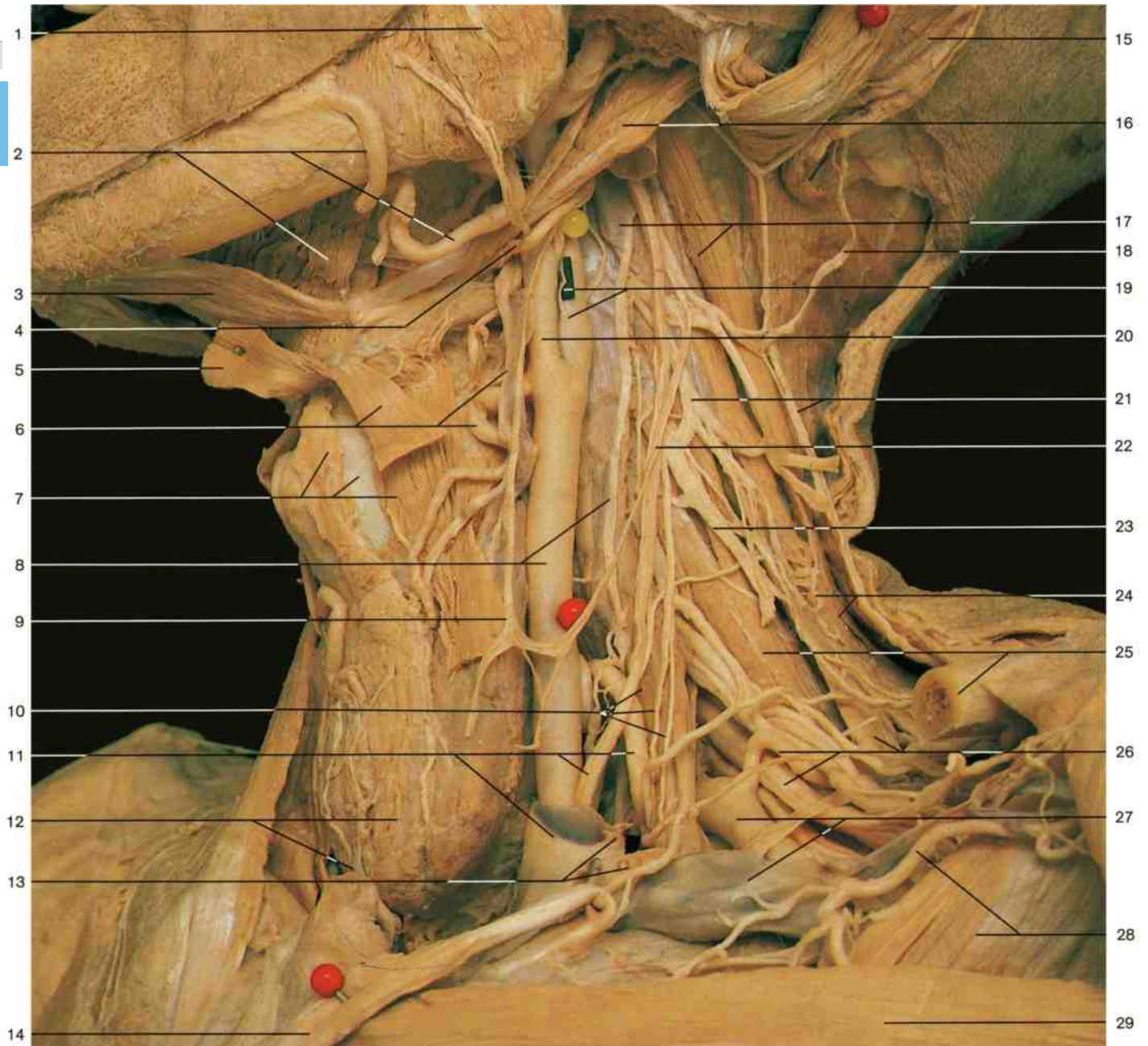


Neck with submandibular region (lateral aspect). Hypoglossal nerve (n. XII). Mandible slightly elevated. Arrow = superior cervical ganglion.

- 1 Facial artery and mandible
- 2 Submental artery
- 3 Mylohyoid muscle and nerve
- 4 Hypoglossal nerve (lingual branches)
- 5 Thyrohyoid branch of hypoglossal nerve (n. XII)
- 6 Anterior belly of digastric muscle
- 7 Hyoid bone
- 8 Omohyoid branch of hypoglossal nerve (n. XII)
- 9 Omohyoid muscle and superior thyroid artery
- 10 Ansa cervicalis
- 11 Posterior belly of digastric muscle
- 12 Hypoglossal nerve (n. XII)
- 13 Vagus nerve (n. X)
- 14 Internal carotid artery
- 15 Superior root of ansa cervicalis
- 16 External carotid artery
- 17 Cervical plexus
- 18 Common carotid artery
- 19 Facial artery and vein
- 20 Omohyoid muscle
- 21 Internal jugular vein
- 22 Sternohyoid and sternothyroid muscles
- 23 Clavicle
- 24 Superficial temporal artery and vein
- 25 Occipital artery
- 26 Spinal nerves (C₃ and C₄)
- 27 Spinal processes of cervical vertebrae (C₄ and C₅)
- 28 Scapula

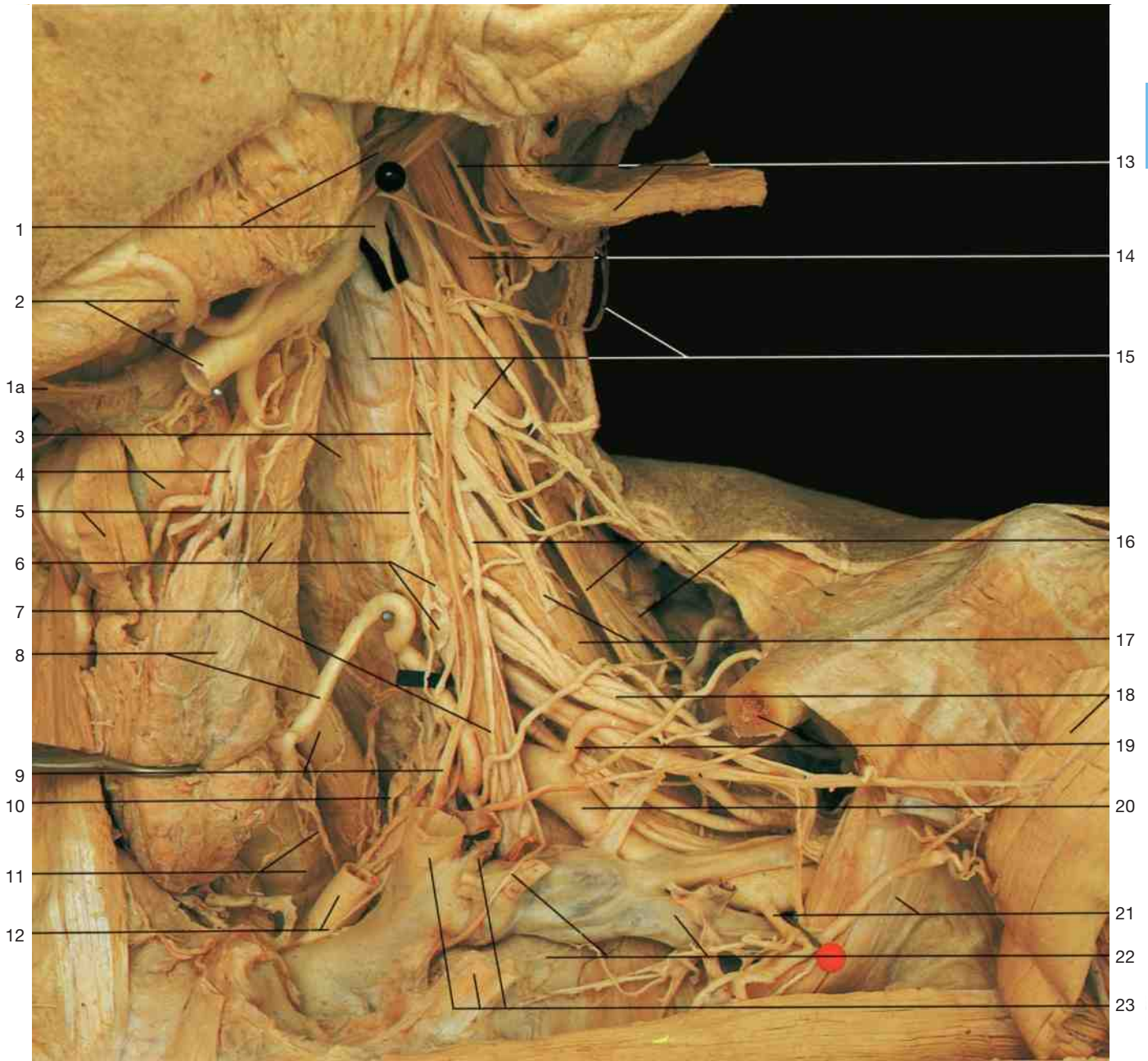


Nerves and vessels of the neck (lateral aspect). The ansa cervicalis with connection to the spinal nerves is depicted.



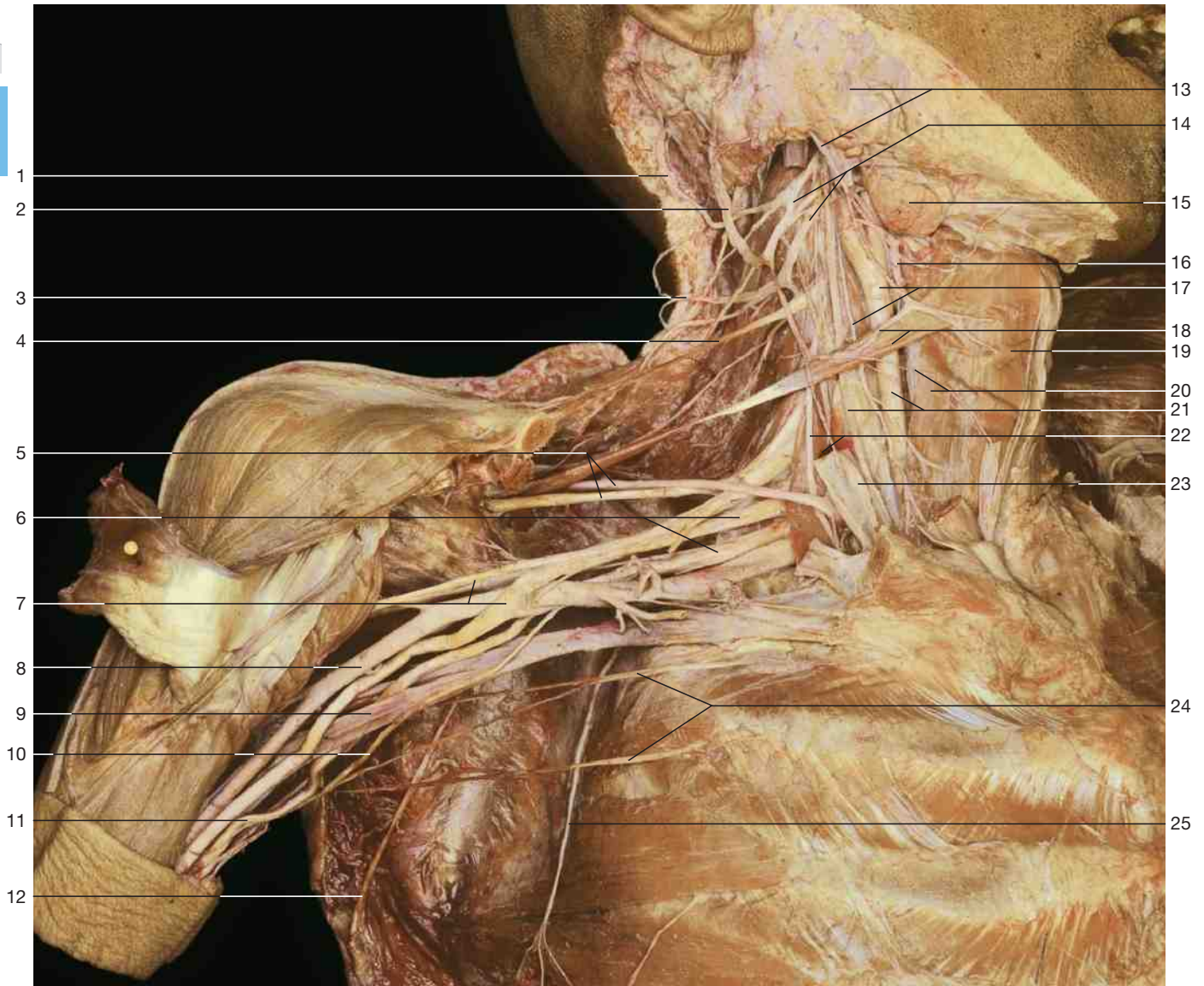
Neck, deeper dissection (lateral aspect). Clavicle partly removed to show the slit between the scalenus muscles. Internal jugular vein removed.

- | | | | | | |
|----|--|----|--|----|--|
| 1 | Masseter muscle | 11 | Inferior thyroid artery, vagus nerve, and internal jugular vein (cut) | 21 | Cervical plexus and accessory nerve |
| 2 | Mylohyoid muscle and facial artery | 12 | Thyroid gland and unpaired inferior thyroid venous plexus | 22 | Inferior root of ansa cervicalis |
| 3 | Anterior belly of digastric muscle | 13 | Thoracic duct and left subclavian trunk | 23 | Supraclavicular nerve |
| 4 | Hypoglossal nerve | 14 | Subclavius muscle (reflected) | 24 | Levator scapulae muscle |
| 5 | Sternohyoid muscle | 15 | Sternocleidomastoid muscle (reflected) | 25 | Scalenus medius muscle and clavicle |
| 6 | Omohyoid muscle, superior thyroid artery and vein | 16 | Posterior belly of digastric muscle | 26 | Transverse cervical artery, brachial plexus, and scalenus posterior muscle |
| 7 | Sternothyroid muscle, thyroid cartilage, and pyramidal lobe of thyroid gland | 17 | Superior cervical ganglion and splenius muscle | 27 | Subclavian artery and vein |
| 8 | Common carotid artery and sympathetic trunk | 18 | Lesser occipital nerve | 28 | Thoraco-acromial artery and pectoralis minor muscle |
| 9 | Ansa cervicalis | 19 | Internal carotid artery and branch of the glossopharyngeal nerve to the carotid body | 29 | Pectoralis major muscle |
| 10 | Phrenic nerve, ascending cervical artery, and anterior scalenus muscle | 20 | External carotid artery | | |



Neck, deepest dissection (antero-lateral aspect). Thyroid gland reflected to expose the esophagus and the recurrent laryngeal nerve.

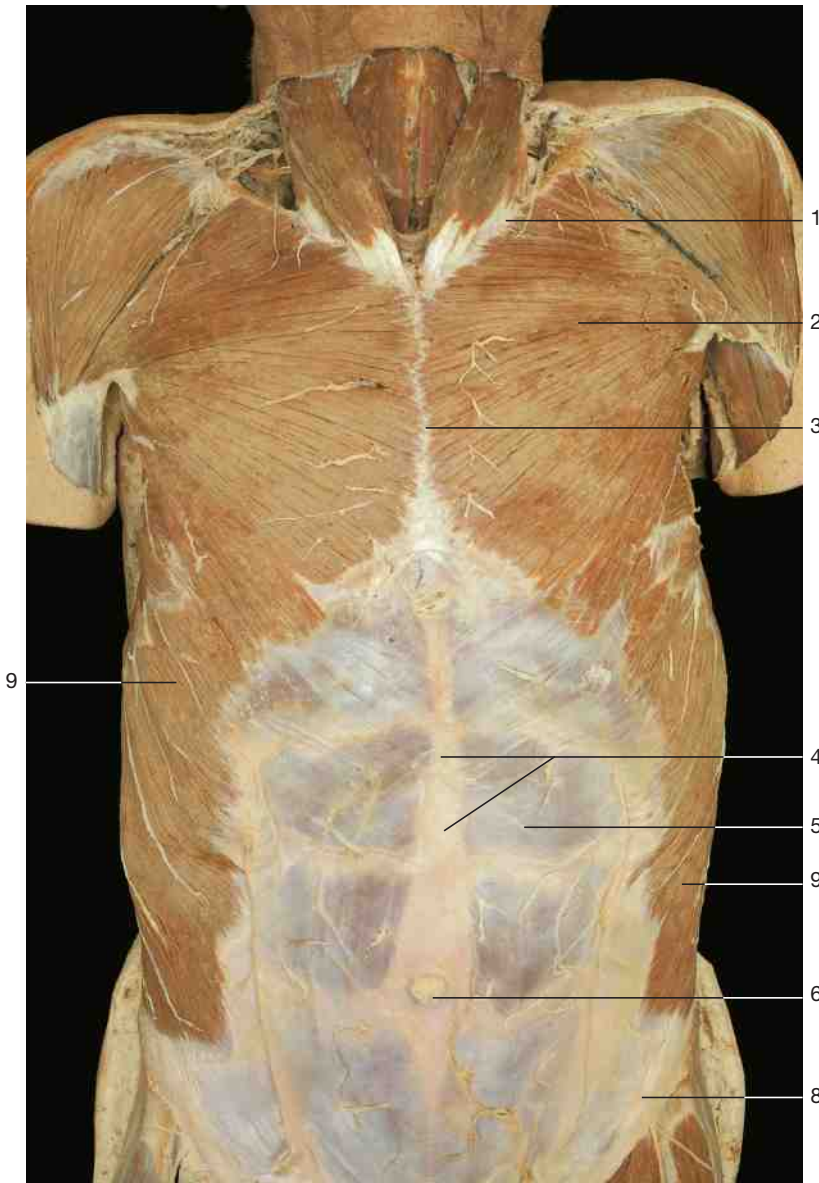
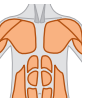- | | |
|---|--|
| 1 Superior cervical ganglion of sympathetic trunk and posterior belly of digastric muscle | 12 Common carotid artery and cervical cardiac branch of vagus nerve |
| 1a Anterior belly of digastric muscle | 13 Sternocleidomastoid muscle and accessory nerve |
| 2 Facial artery and common carotid artery (reflected anteriorly) | 14 Splenius capitis muscle |
| 3 Ascending cervical artery and longus colli muscle | 15 Lesser occipital nerve, longus capitis muscle, and cervical plexus |
| 4 Omohyoid muscle and superior thyroid artery | 16 Phrenic nerve, scalenus posterior muscle, and levator scapulae muscle |
| 5 Sympathetic trunk and sternohyoid muscle | 17 Supraclavicular nerves and scalenus medius muscle |
| 6 Middle cervical ganglion and inferior pharyngeal constrictor muscle | 18 Brachial plexus and pectoralis major muscle (clavicular head) |
| 7 Scalenus anterior muscle and phrenic nerve | 19 Transverse cervical artery and clavicle |
| 8 Thyroid gland and inferior thyroid artery | 20 Subclavian artery |
| 9 Vagus nerve and esophagus | 21 Thoraco-acromial artery and pectoralis minor muscle |
| 10 Stellate ganglion | 22 First rib, accessory phrenic nerve, and subclavian vein |
| 11 Recurrent laryngeal nerve and trachea | 23 Internal jugular vein, thoracic duct, and subclavius muscle |



Neck and arm, deepest dissection (antero-lateral aspect). Cervical and brachial plexuses and their relation to the blood vessels are shown. Note the location and content of scalene triangle. Sternocleidomastoid muscle and clavicle have been removed; the internal jugular vein was divided to display the roots of cervical and brachial plexuses.

- | | |
|--|---|
| 1 Lesser occipital nerve | 15 Submandibular gland |
| 2 Great auricular nerve | 16 Superior thyroid artery |
| 3 Cutaneous branches of cervical plexus | 17 Common carotid artery dividing in internal and external carotid artery and superior root of ansa cervicalis |
| 4 Supraclavicular nerve | 18 Omohyoid muscle and cervical branch of facial nerve joining the transverse cervical nerve (C ₂ , C ₃) |
| 5 Suprascapular nerve and artery | 19 Sternohyoid muscle |
| 6 Brachial plexus | 20 Transverse cervical nerve and sternothyroid muscle |
| 7 Median nerve (with two roots) and musculocutaneous nerve | 21 Common carotid artery and vagus nerve |
| 8 Axillary artery | 22 Phrenic nerve and scalenus anterior muscle |
| 9 Axillary vein | 23 Internal jugular vein |
| 10 Medial brachial cutaneous nerve | 24 Intercostobrachial nerves |
| 11 Ulnar nerve | 25 Long thoracic nerve |
| 12 Thoracodorsal nerve | |
| 13 Parotid gland and facial nerve (cervical branch) | |
| 14 Cervical plexus | |

3 Trunk

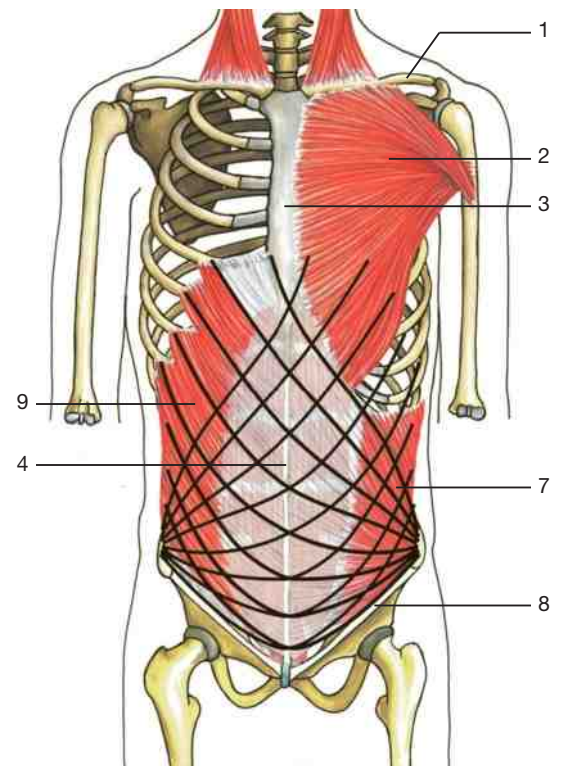


Anterior thoracic and abdominal walls with superficial musculature.
The fascia of pectoralis major muscle and the abdominal wall have been removed; the anterior layer of the sheath of the rectus abdominis muscle is displayed.

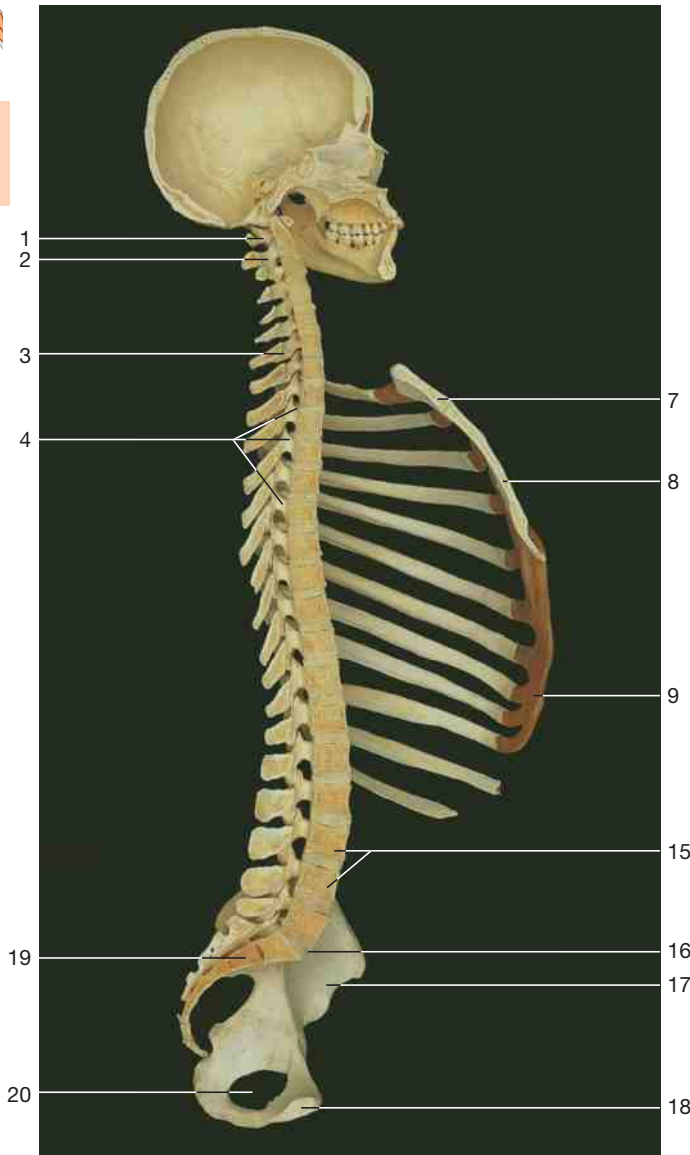
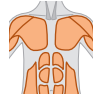
- 1 Clavicle
- 2 Pectoralis major muscle
- 3 Sternum
- 4 Linea alba
- 5 Anterior layer of rectus sheath
- 6 Umbilicus
- 7 Internal abdominal oblique muscle
- 8 Inguinal ligament
- 9 External abdominal oblique muscle

The anterior abdominal and thoracic walls reveal a segmental structure. The ribs are connected by intercostal muscles forming defined skeleto-motoric and neuro-vascular segments.

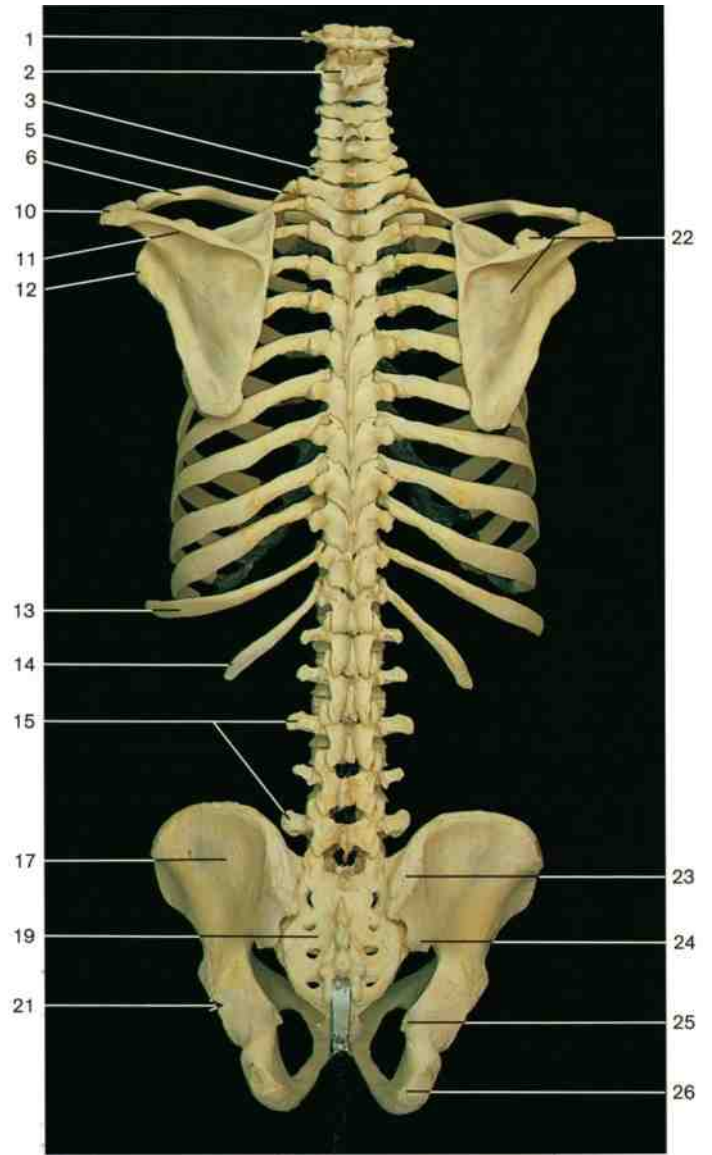
At the abdominal wall, the segments form great flat muscles, that end anteriorly in strong sheet-like aponeuroses. The aponeurosis interlace at the linea alba with their counterparts from the opposite side to form the tough tendinous sheath of the rectus muscle. Movements of the abdominal wall also support the process of respiration functionally related to the diaphragm.



Organization of the thoracic and abdominal walls.
The architecture of tendon fibers of the two abdominal oblique muscles in the rectus sheath is shown.



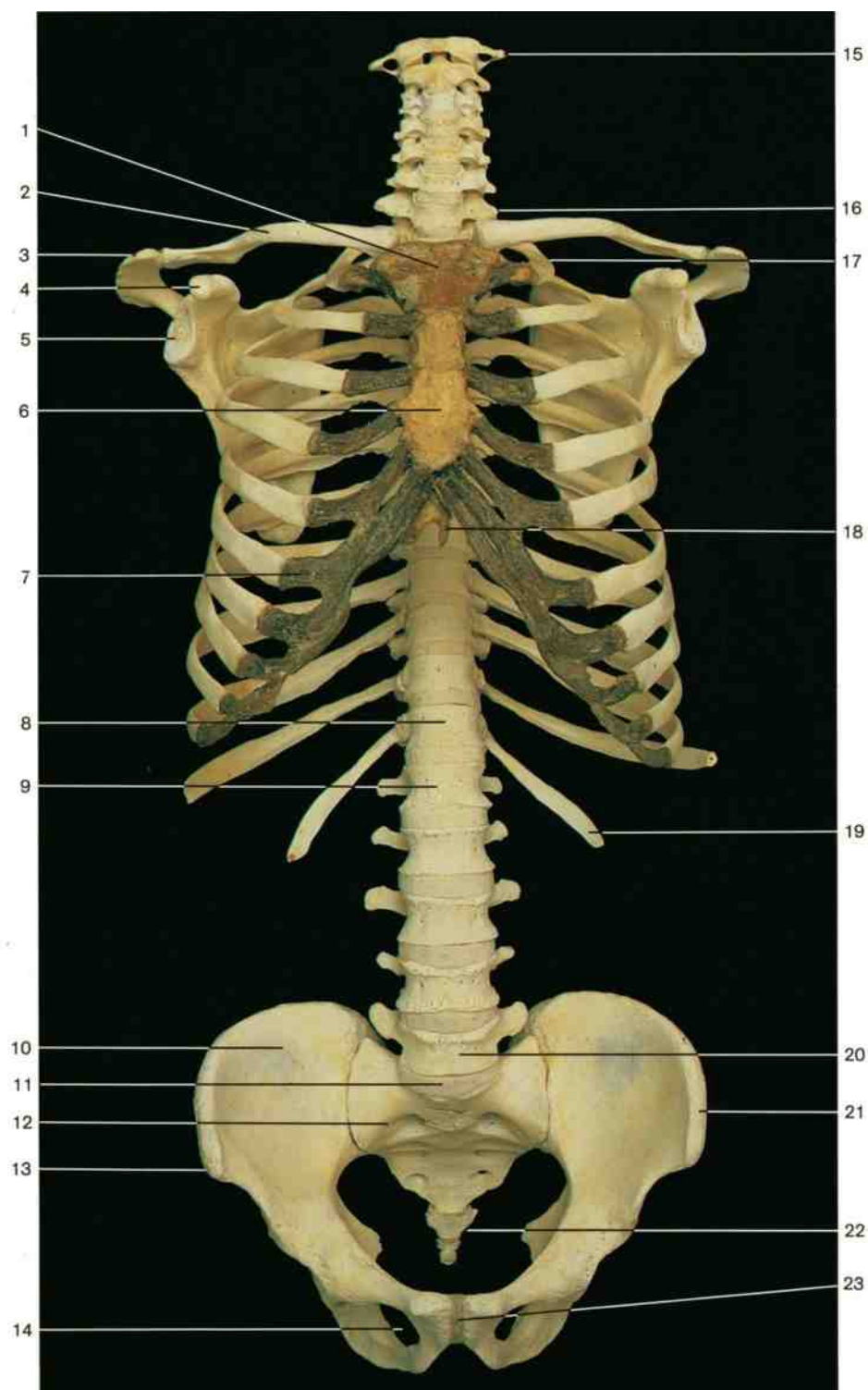
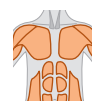Median sagittal section through the vertebral column, head, and thorax of the adult.



Skeleton of the trunk, vertebral column, thorax, and pelvis (posterior aspect).

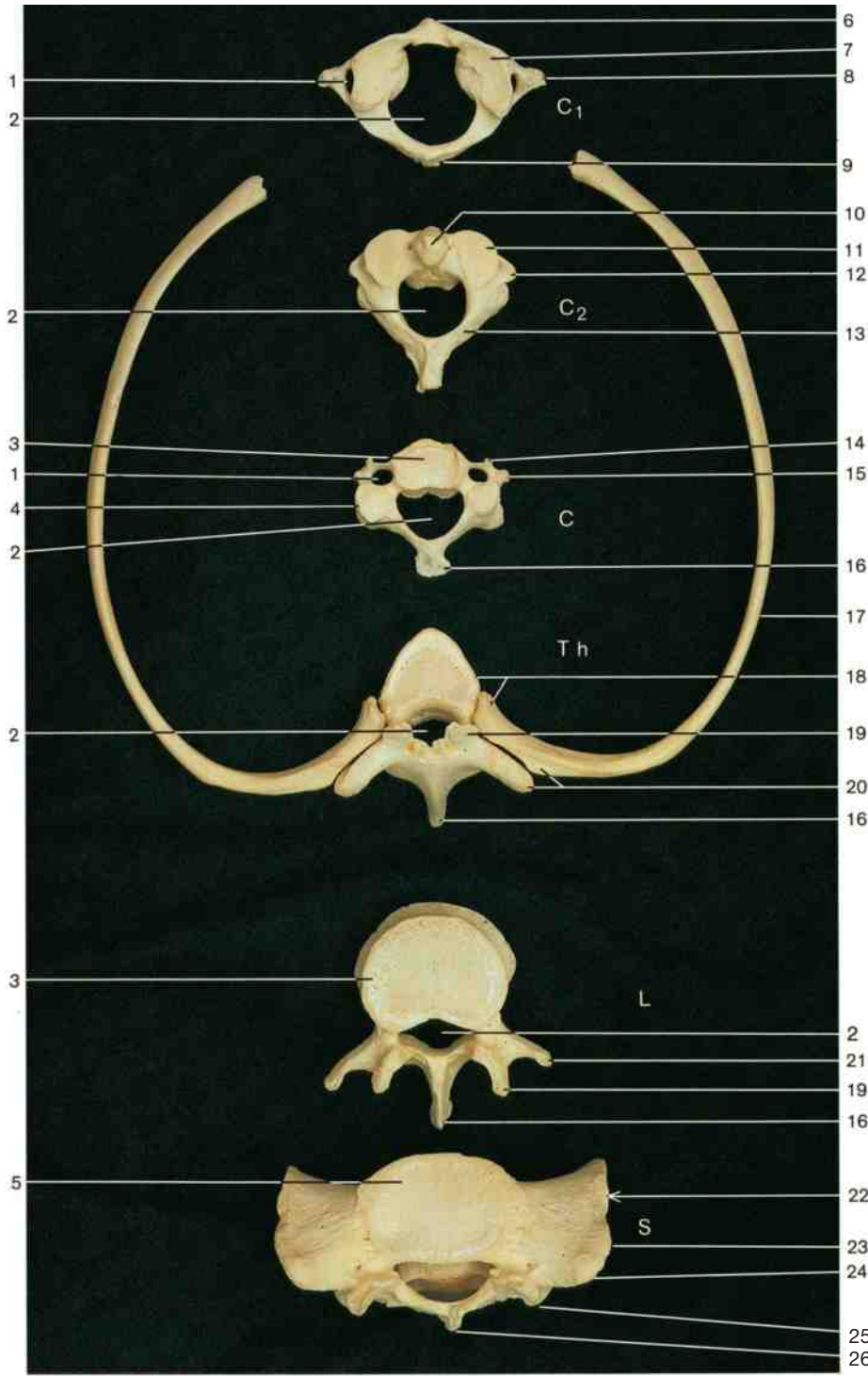
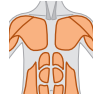
- 1 Atlas
- 2 Axis
- 3 Seventh cervical vertebra (vertebra prominens)
- 4 Vertebral canal
- 5 First rib
- 6 Clavicle
- 7 Manubrium sterni
- 8 Body of sternum
- 9 Costal arch
- 10 Acromion
- 11 Spine of scapula
- 12 Glenoid cavity (lateral angle of scapula)
- 13 Eleventh rib

- 14 Twelfth rib
- 15 Lumbar vertebrae
- 16 Sacral promontory
- 17 Hip bone
- 18 Pubic symphysis
- 19 Sacrum
- 20 Obturator foramen
- 21 Acetabulum
- 22 Scapula with coracoid process
- 23 Posterior superior iliac spine
- 24 Posterior inferior iliac spine
- 25 Ischial spine
- 26 Ischial tuberosity

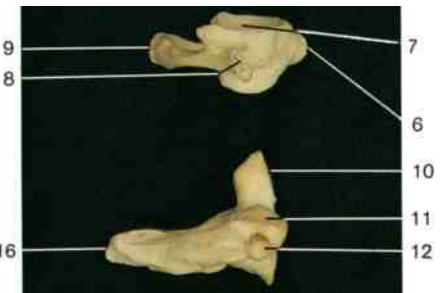


Skeleton of the trunk, vertebral column, pelvis, thorax, and shoulder girdle (anterior aspect).

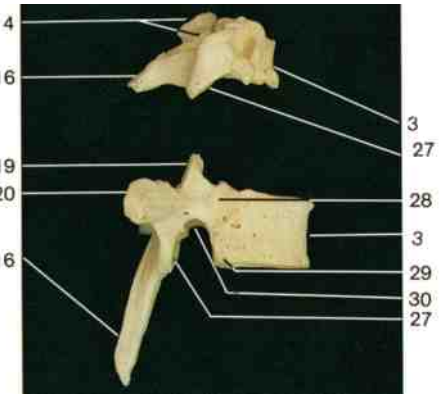
- | | |
|---|--------------------------------------|
| 1 Manubrium sterni | 13 Anterior superior iliac spine |
| 2 Clavicle | 14 Obturator foramen |
| 3 Acromion | 15 Atlas |
| 4 Coracoid process | 16 Seventh cervical vertebra |
| 5 Glenoid cavity | 17 First rib |
| 6 Body of sternum | 18 Xiphoid process |
| 7 Costal cartilage | 19 Twelfth rib |
| 8 Body of the twelfth thoracic vertebra | 20 Body of the fifth lumbar vertebra |
| 9 Body of the first lumbar vertebra | 21 Iliac crest |
| 10 Hip bone | 22 Coccyx |
| 11 Sacral promontory | 23 Pubic symphysis |
| 12 Sacrum | |



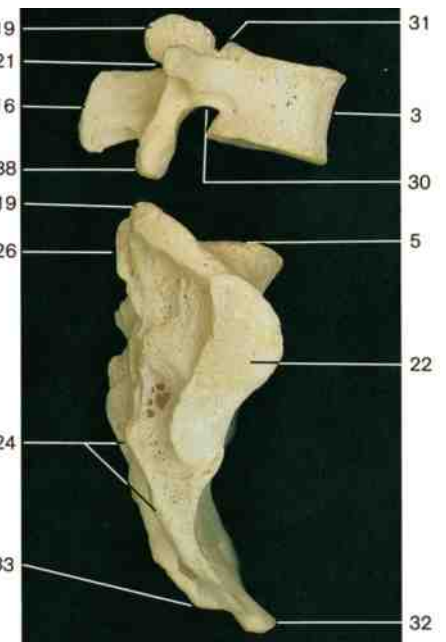
Representative vertebrae from each region of the vertebral column (superior aspect). From top to bottom: atlas (C₁), axis (C₂), cervical vertebra (C), thoracic vertebra (Th), lumbar vertebra (L), and sacrum (S).



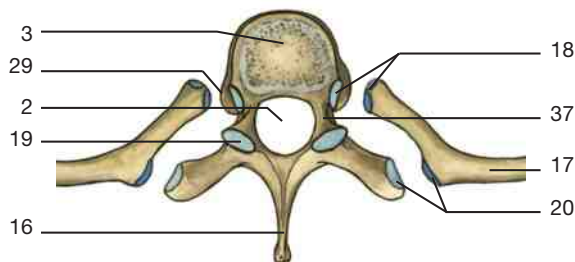
Atlas and axis.



Typical cervical and thoracic vertebrae.

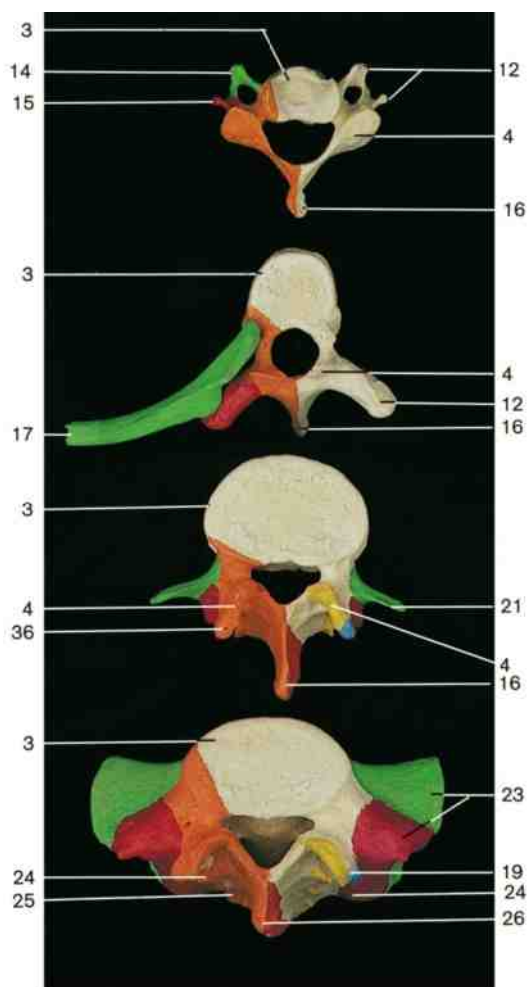


Typical lumbar vertebra and sacrum.

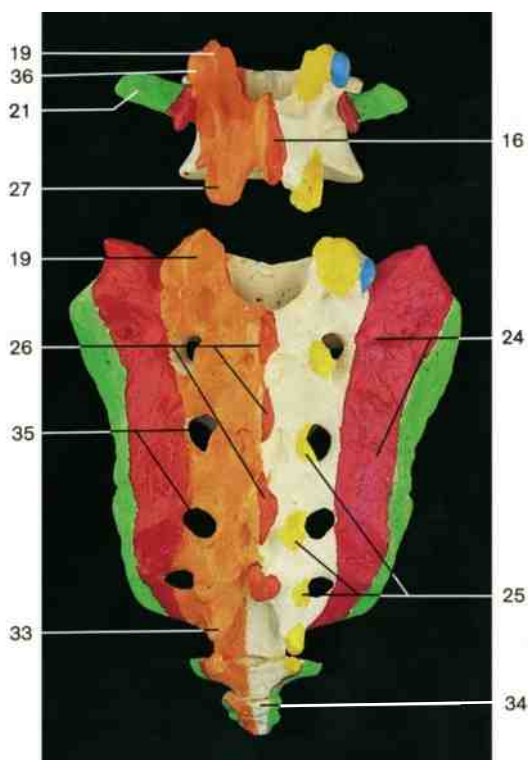


General organization of ribs and vertebrae (schematic drawing).

△ Representative vertebrae from each region of the vertebral column (lateral aspect, ventral surface on the right).



General characteristics of the vertebrae.
Typical cervical, thoracic, and lumbar vertebrae and sacrum.

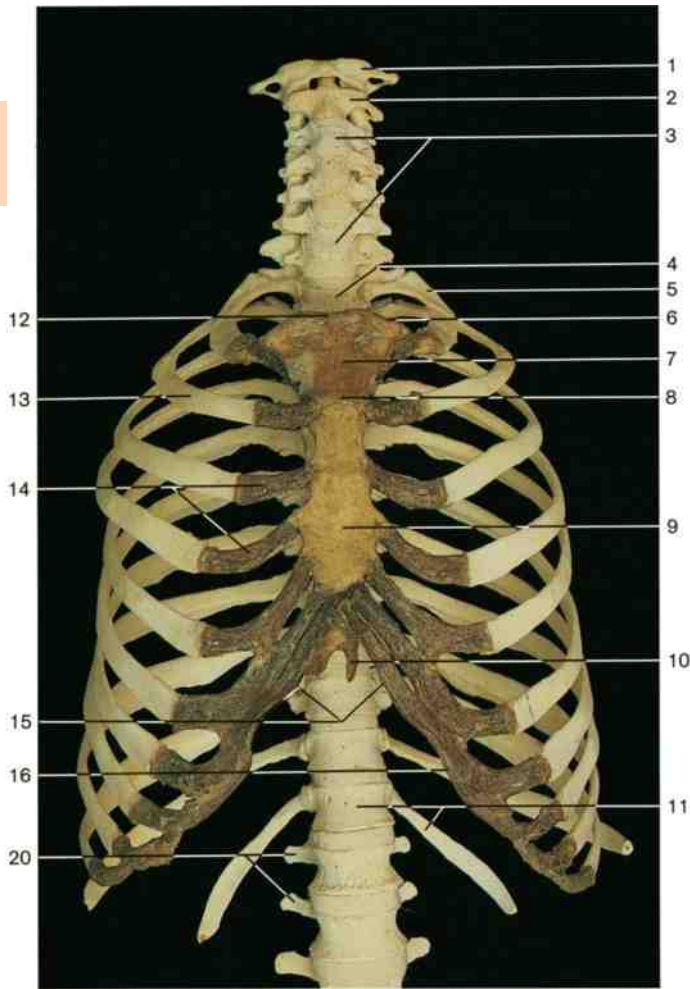
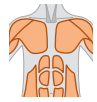


General characteristics of lumbar vertebrae and sacrum (posterior aspect).

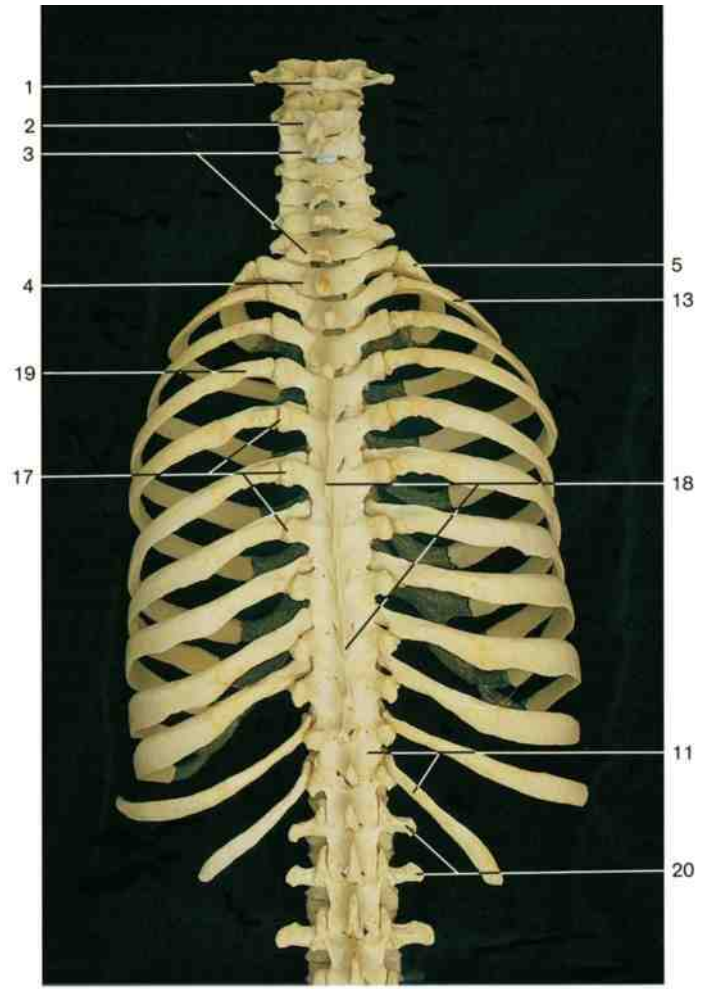
- Green = ribs or homologous processes
- Red = muscular processes
(transverse and spinous processes)
- Orange = laminae and articular processes
- Yellow = articular facets
and blue

- 1 Foramen transversarium
- 2 Vertebral foramen
- 3 Body of vertebra
- 4 Superior articular facet
- 5 Base of sacrum
- 6 Anterior tubercle of atlas
- 7 Superior articular facet of atlas
- 8 Transverse process
- 9 Posterior tubercle of atlas
- 10 Dens of axis
- 11 Superior articular surface
- 12 Transverse process
- 13 Arch of vertebra
- 14 Anterior tubercle of transverse process
- 15 Posterior tubercle of transverse process
- 16 Spinous process
- 17 Shaft of rib
- 18 Body of vertebra and head of rib articulating with each other (costovertebral joint)
- 19 Superior articular process

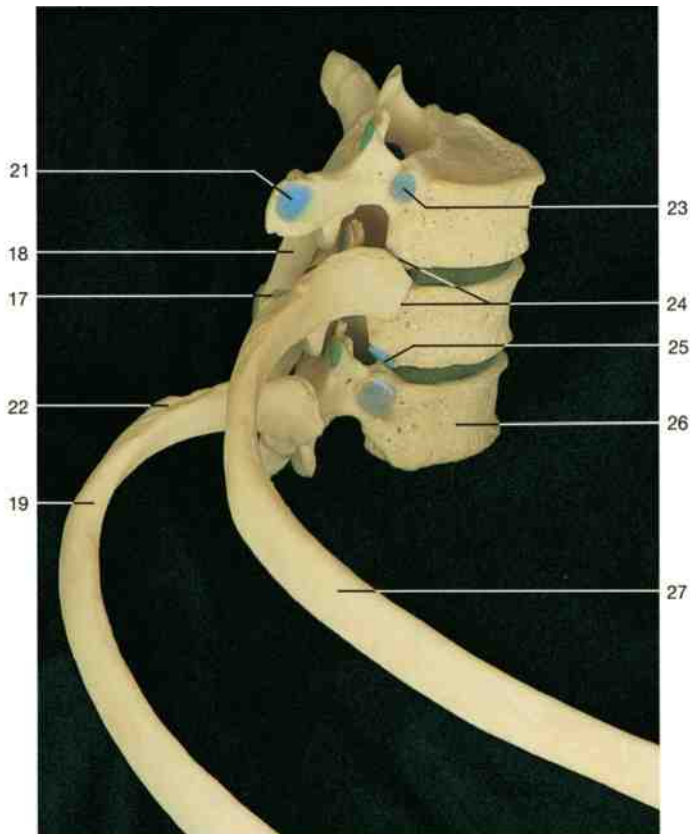
- 20 Transverse process and tubercle of rib articulating with each other (costotransverse joint)
- 21 Costal process
- 22 Auricular surface
- 23 Lateral part of sacrum
- 24 Lateral sacral crest
- 25 Intermediate sacral crest
- 26 Median sacral crest
- 27 Inferior articular facet
- 28 Superior demifacet for head of rib
- 29 Inferior demifacet for head of rib
- 30 Inferior vertebral notch
- 31 Superior vertebral notch
- 32 Apex of the sacrum
- 33 Sacral cornu
- 34 Coccyx
- 35 Dorsal sacral foramina
- 36 Mamillary process
- 37 Pedicle
- 38 Inferior articular process



Skeleton of the thorax (anterior aspect).

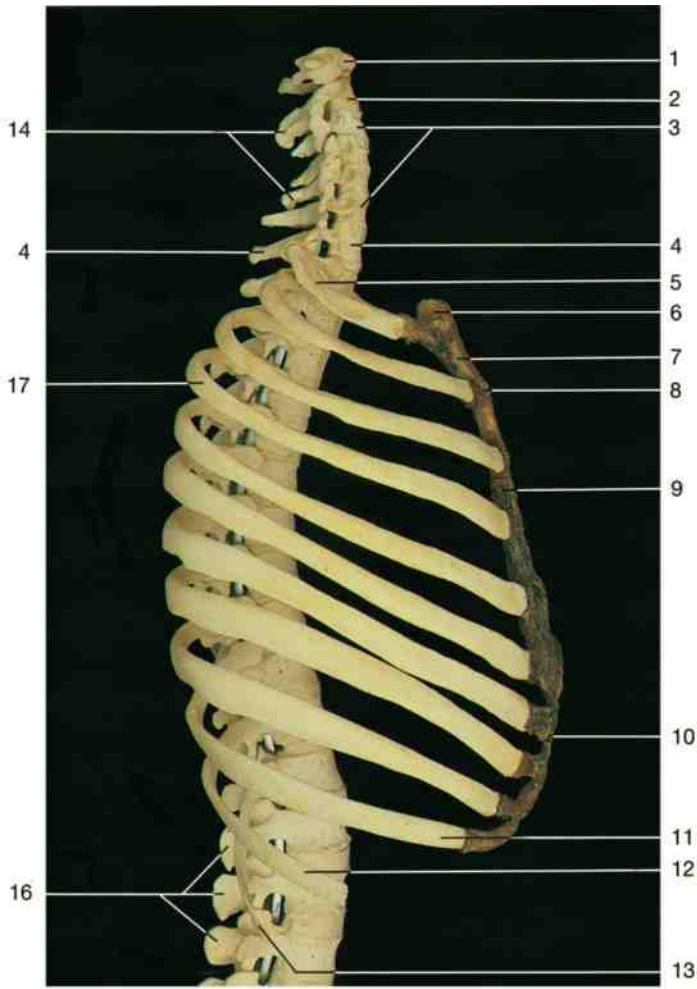
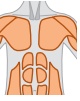


Skeleton of the thorax (posterior aspect).



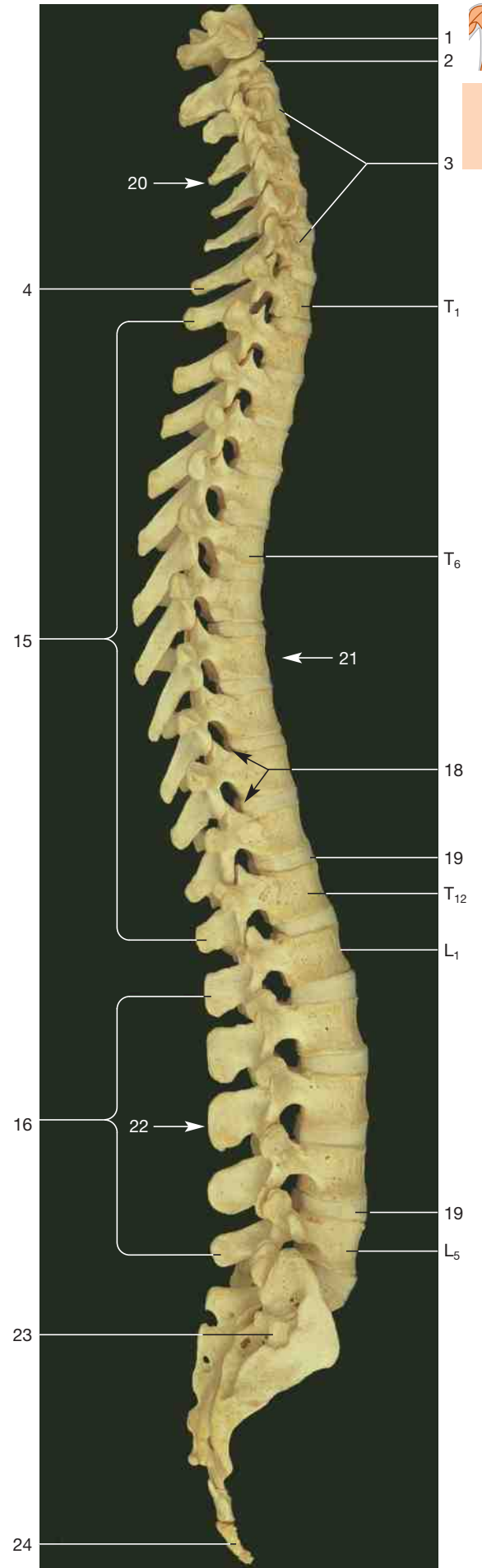
Costovertebral articulation (right lateral aspect).

- 1 Atlas
- 2 Axis
- 3 Cervical vertebrae
- 4 First thoracic vertebra
- 5 First rib
- 6 Facet for clavicle and clavicular notch
- 7 Manubrium sterni
- 8 Sternal angle
- 9 Body of sternum
- 10 Xiphoid process
- 11 Twelfth thoracic vertebra and rib
- 12 Jugular notch
- 13 Second rib
- 14 Costal cartilages
- 15 Infrasternal angle
- 16 Costal arch
- 17 Costotransverse joints between the transverse processes of thoracic vertebra and the tubercles of the ribs
- 18 Spinous processes
- 19 Costal angle
- 20 Costal processes of lumbar vertebrae
- 21 Facet for articulation with rib
- 22 Tubercle of rib
- 23 Superior facet for articulation with head of rib
- 24 Articulation of head of rib with two vertebrae
- 25 Inferior facet for articulation with head of rib
- 26 Body of thoracic vertebra
- 27 Body or shaft of rib

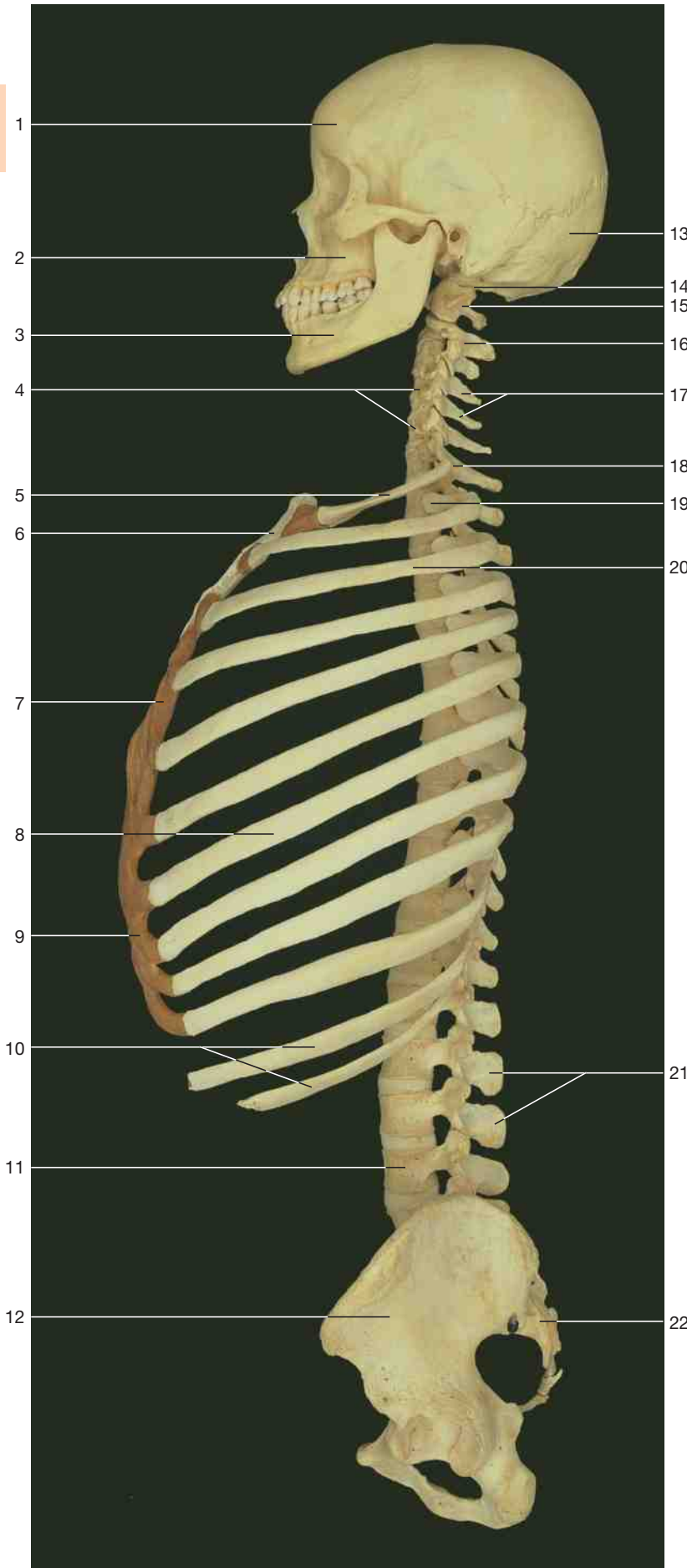


Skeleton of the thorax (right lateral aspect).

- 1 Atlas
- 2 Axis
- 3 Cervical vertebrae
- 4 Seventh cervical vertebra (vertebra prominens)
- 5 First rib
- 6 Facet for clavicle
- 7 Manubrium sterni
- 8 Sternal angle
- 9 Body of sternum
- 10 Costal arch
- 11 Tenth rib
- 12 Eleventh rib
- 13 Twelfth rib
- 14 Spinous processes of cervical vertebrae
- 15 Spinous processes of thoracic vertebrae
- 16 Spinous processes of lumbar vertebrae
- 17 Costal angle
- 18 Intervertebral foramina
- 19 Intervertebral discs
- 20 Cervical curvature
- 21 Thoracic curvature
- 22 Lumbar curvature
- 23 Sacrum
- 24 Coccyx



Vertebral column (right lateral aspect).

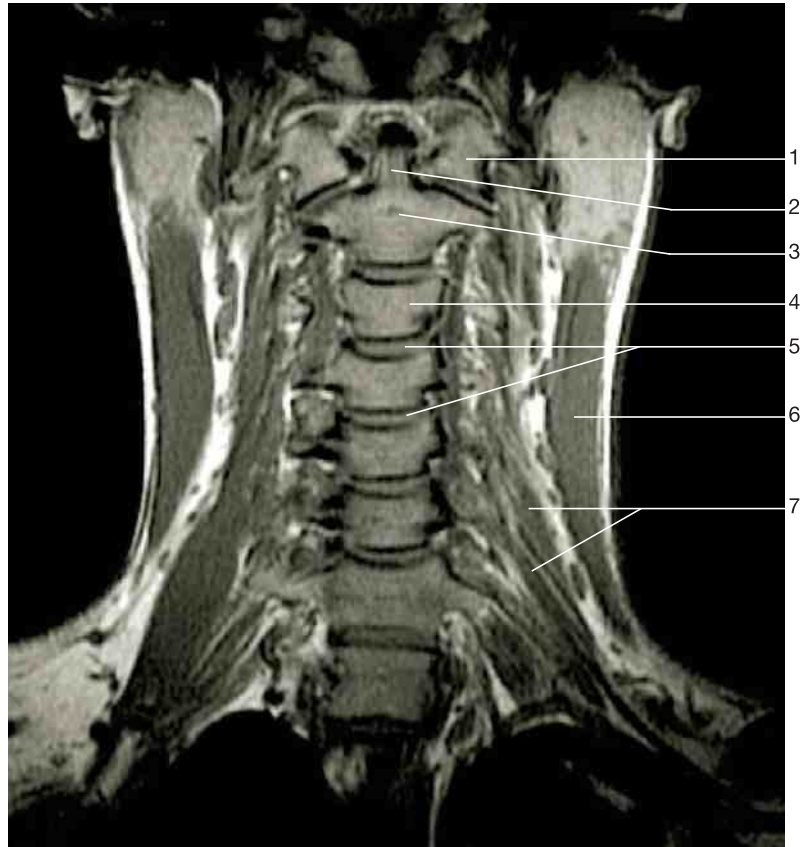


- 1 Frontal bone
- 2 Maxilla
- 3 Mandible
- 4 Bodies of cervical vertebrae
- 5 First rib
- 6 Manubrium of sternum
- 7 Sternum (corpus sterni)
- 8 Seventh rib (last of the true ribs)
- 9 Costal arch (arcus costalis)
- 10 Floating ribs (costae fluctuantes)
- 11 Body of fourth lumbar vertebra
- 12 Pelvis
- 13 Occipital bone
- 14 Atlanto-occipital joint
- 15 Atlas
- 16 Axis
- 17 Spinous processes of cervical vertebrae (C₄, C₅)
- 18 Costovertebral joint of first rib
- 19 Head of second rib
- 20 Third rib
- 21 Spinous processes of lumbar vertebrae (L₂, L₃)
- 22 Sacrum

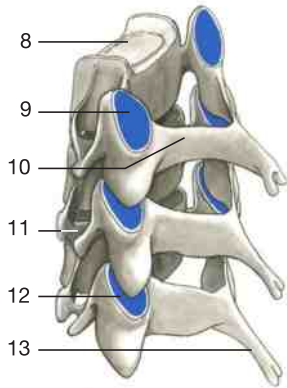
Vertebral column and thorax in connection with head and pelvis (lateral aspect).



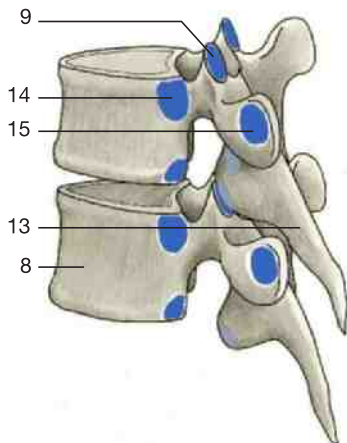
- 1 Atlas
- 2 Dens of axis
- 3 Axis
- 4 Body of cervical vertebra
- 5 Intervertebral discs
- 6 Sternocleidomastoid muscle
- 7 Scalenus muscles
- 8 Body of vertebra
- 9 Superior articular facet
- 10 Vertebral arch
- 11 Transverse process of vertebra
- 12 Zygapophysial joint
- 13 Spinous process
- 14 Articular facet of costovertebral joint
- 15 Transverse process with articular facet of costotransverse joint
- 16 Costal process of lumbar vertebra
- 17 Sacrum
- 18 Median sacral crest
- 19 Dorsal sacral foramina
- 20 Coccyx



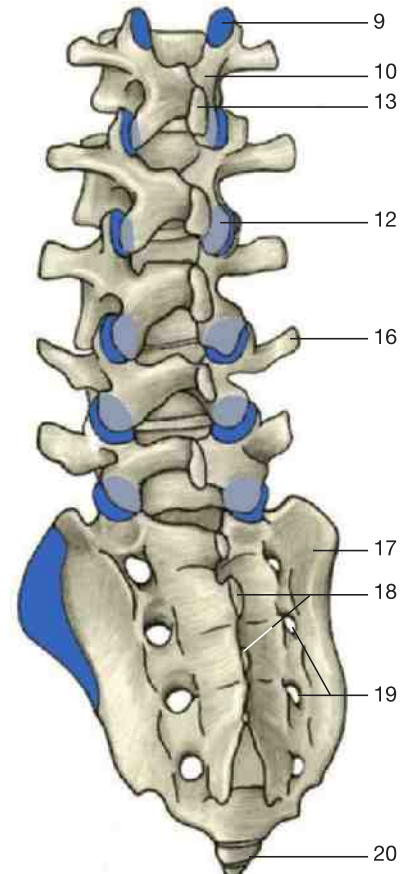
Coronal section through the neck at the level of the cervical vertebrae (MRI scan, courtesy of Prof. Heuck, Munich).



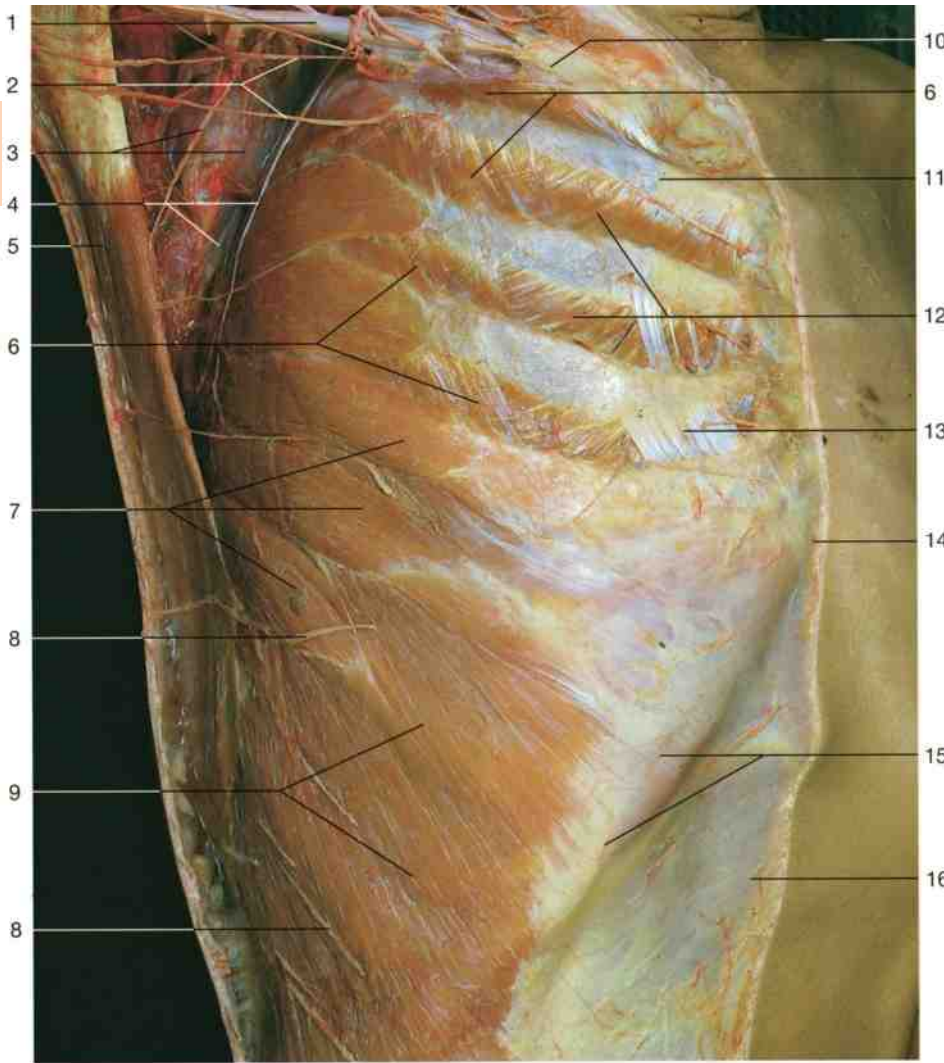
Cervical vertebrae (lateral aspect, articular facets = blue).



Thoracic vertebrae (lateral aspect, articular facets = blue).

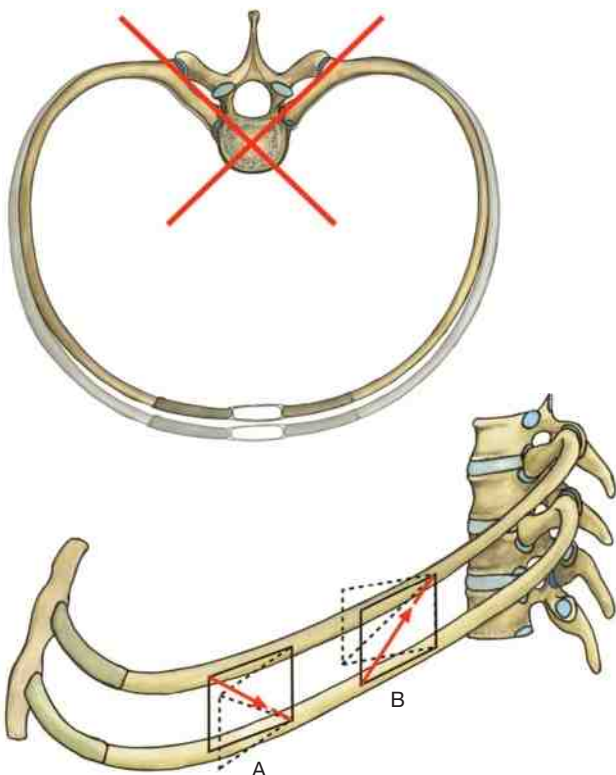


Lumbar vertebrae with sacrum and coccyx (posterior aspect, articular facets = blue).

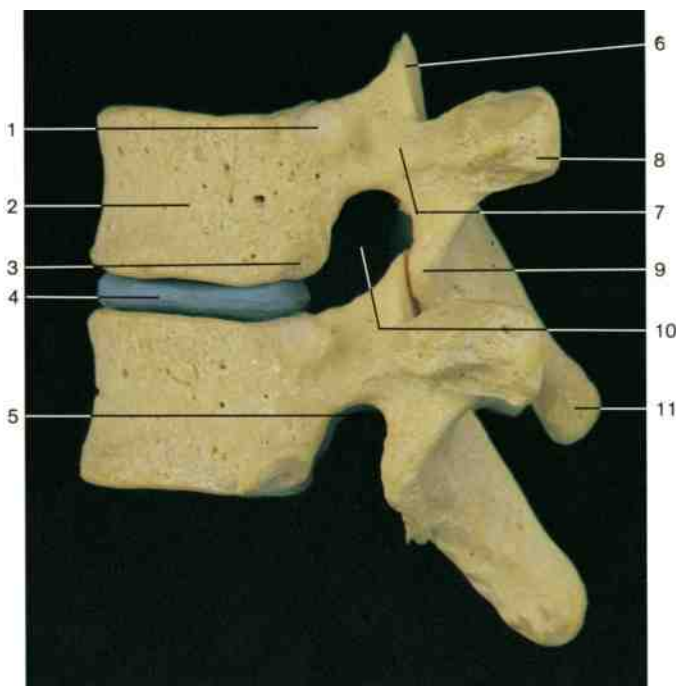


- 1 Axillary vein
- 2 Intercostobrachial nerves
- 3 Subscapularis muscle and thoracodorsal nerve
- 4 Long thoracic nerve, lateral thoracic artery and vein
- 5 Latissimus dorsi muscle
- 6 External intercostal muscles
- 7 Serratus anterior muscle
- 8 Lateral cutaneous branches of intercostal nerves
- 9 External abdominal oblique muscle
- 10 Clavicle (divided)
- 11 Second rib (costochondral junction)
- 12 Internal intercostal muscles
- 13 External intercostal membrane
- 14 Position of xiphoid process
- 15 Costal arch or margin
- 16 Anterior layer of rectus sheath

Muscles of the thorax, superficial layer (lateral aspect). Upper limb elevated. Pectoralis major and minor muscles have been removed.

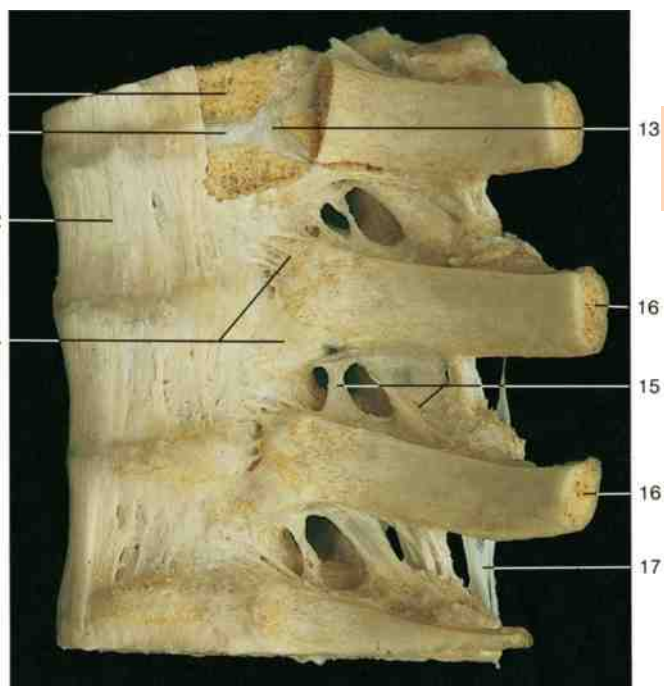


Effect of intercostal muscles on the costovertebral and costotransverse joints. Axes of movement indicated by red lines; direction of movements indicated by red arrows.
 A = action of internal intercostal muscles (expiration);
 B = action of external intercostal muscles (inspiration).



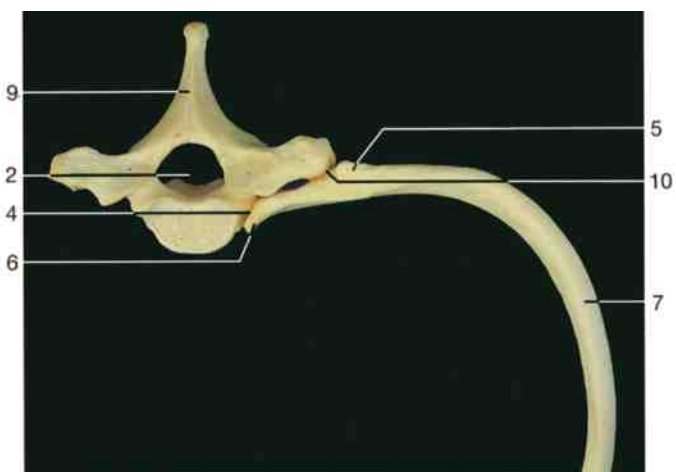
Two thoracic vertebrae (left lateral aspect).

- | | |
|---|--|
| 1 Superior demifacet for head of rib | 8 Transverse process and facet for tubercle of rib |
| 2 Body of vertebra | 9 Inferior articular process |
| 3 Inferior demifacet for head of rib | 10 Intervertebral foramen |
| 4 Intervertebral disc | 11 Spinous process |
| 5 Inferior vertebral notch | 12 Anterior longitudinal ligament |
| 6 Superior articular facet and superior articular process | 13 Intra-articular ligament |
| 7 Pedicle | 14 Radiate ligament |



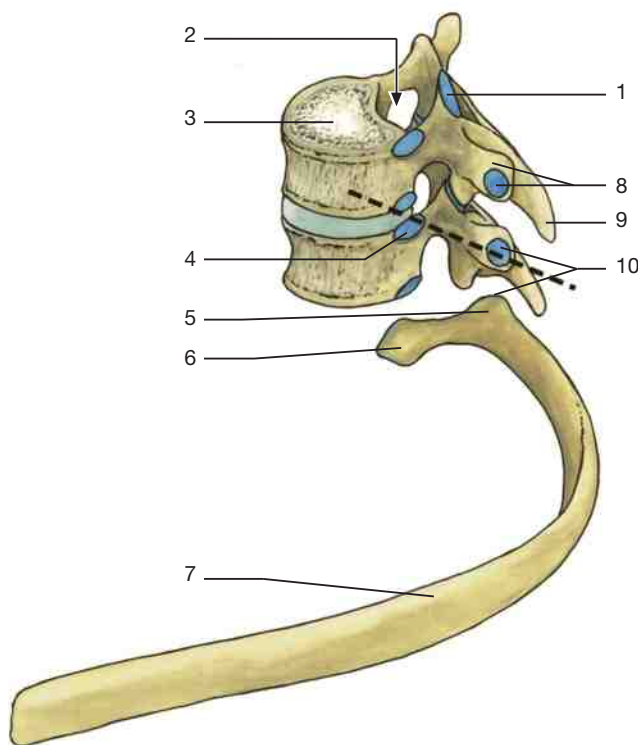
Ligaments of thoracic vertebrae and costovertebral joints (left antero-lateral aspect). In the upper joint, most of the radiate ligament and the anterior part of the head of the rib have been removed to expose the two joint cavities and the interposed intra-articular ligament.

- | |
|--------------------------------------|
| 15 Superior costotransverse ligament |
| 16 Body of rib |
| 17 Intertransverse ligament |

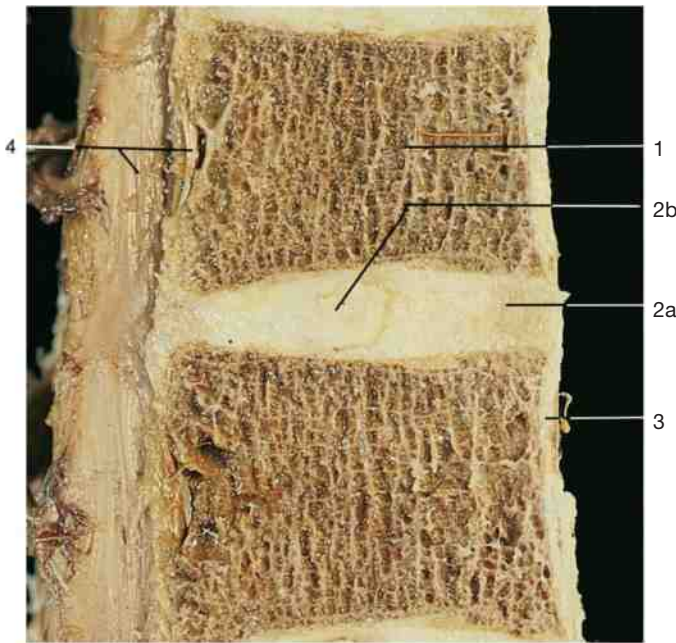


Location of costovertebral joints (superior aspect).

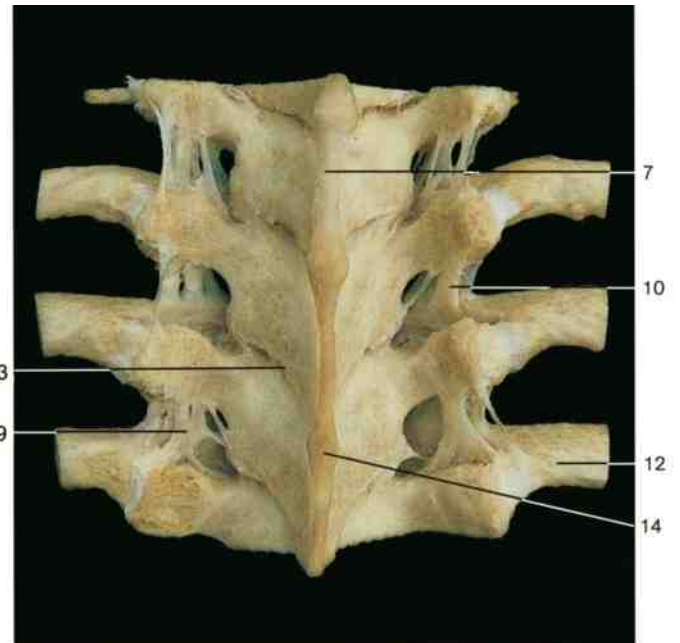
- | | |
|---|---|
| 1 Superior articular process | 7 Shaft or body of rib |
| 2 Vertebral canal | 8 Transverse process with articular facet |
| 3 Body of thoracic vertebra | 9 Spinous process |
| 4 Costovertebral joint (articular facets) | 10 Costotransverse joint (articular facets) |
| 5 Tubercle of rib | |
| 6 Head of rib | |



Costovertebral joints (schematic drawing). Two thoracic vertebrae with an articulating rib (separated). Axis of movement indicated by dashed line. Blue = articular facets.



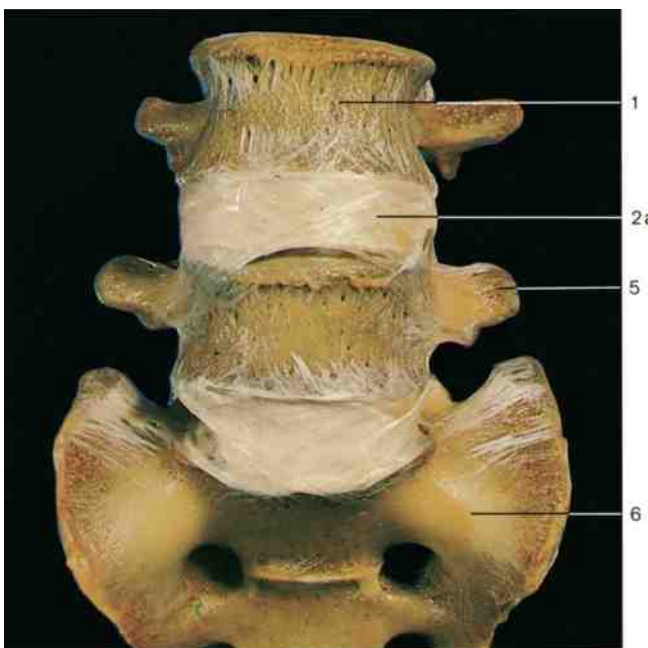
Median-sagittal section of the bodies of the vertebrae, showing the **intervertebral discs**, each of which consists of an outer laminated portion and an inner core.



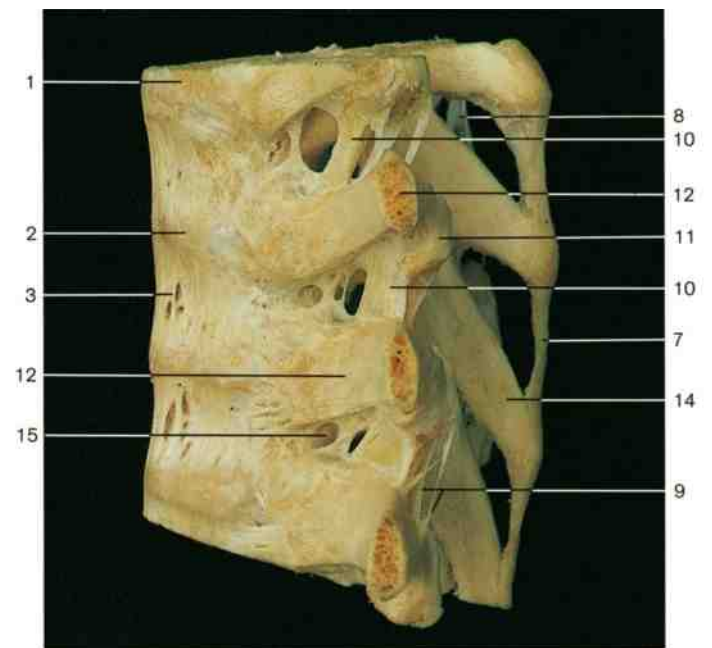
Ligaments of the vertebral column (dorsal aspect).

- 1 Body of vertebra
- 2 Intervertebral disc
 - a Outer portion (anulus fibrosus)
 - b Inner core (nucleus pulposus)
- 3 Anterior longitudinal ligament
- 4 Posterior longitudinal ligament and spinal dura mater
- 5 Costal process of lumbar vertebra
- 6 Sacrum
- 7 Supraspinous ligament

- 8 Interspinous ligament
- 9 Intertransverse ligament
- 10 Superior costotransverse ligament
- 11 Transverse process of thoracic vertebra
- 12 Rib
- 13 Ligamentum flavum
- 14 Spinous process
- 15 Intervertebral foramen



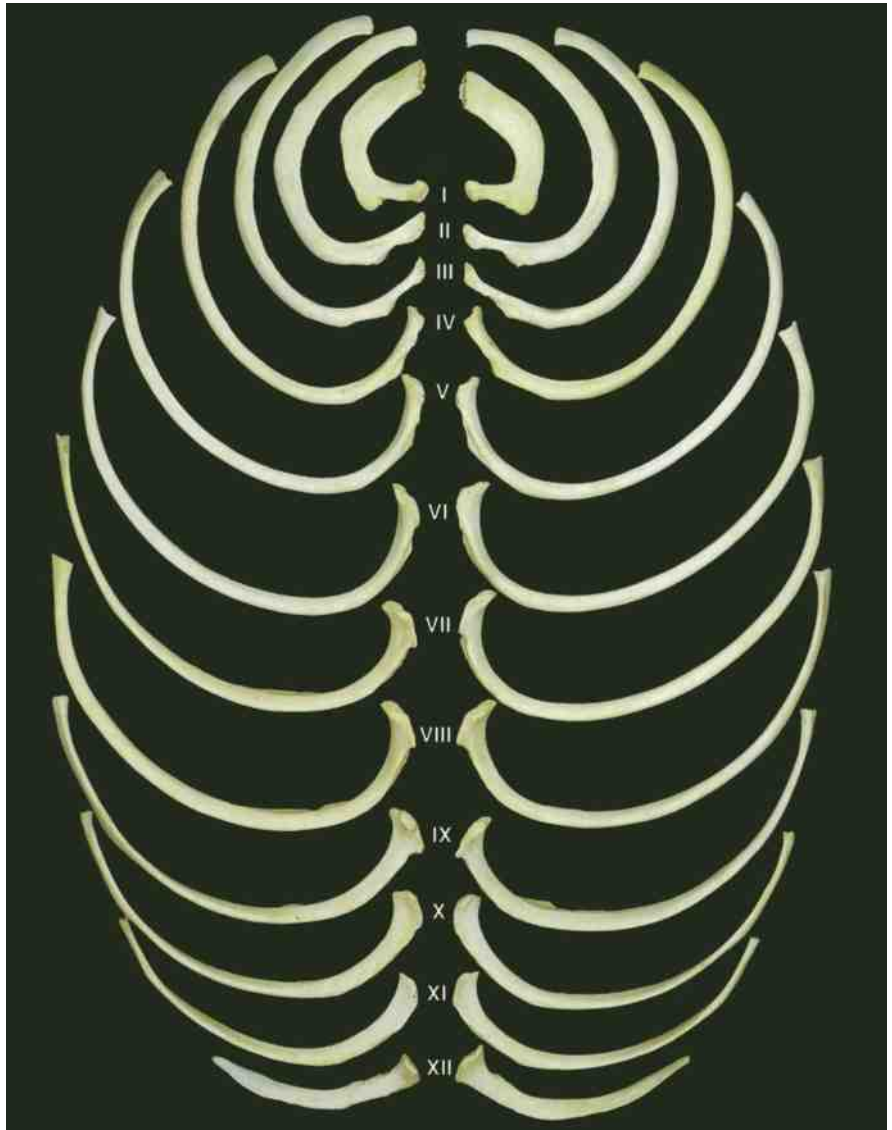
The two caudal lumbar vertebrae and the sacrum with their intervertebral discs (anterior aspect). Anterior longitudinal ligament removed.



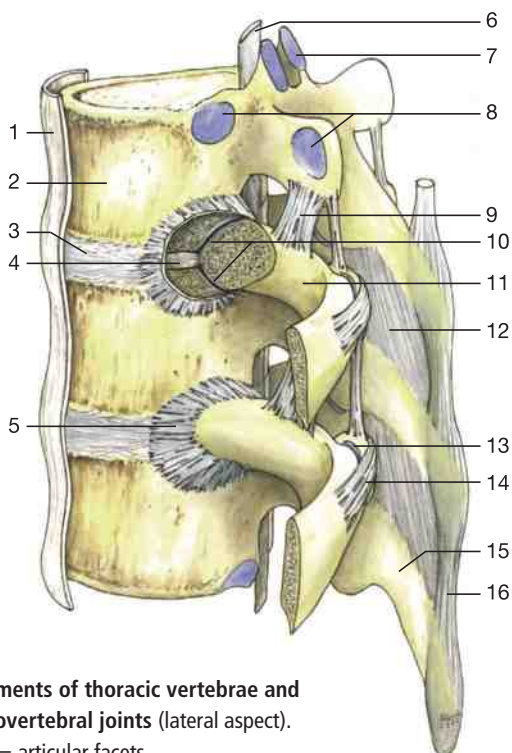
Ligaments of the vertebral column, thoracic part (left lateral aspect).



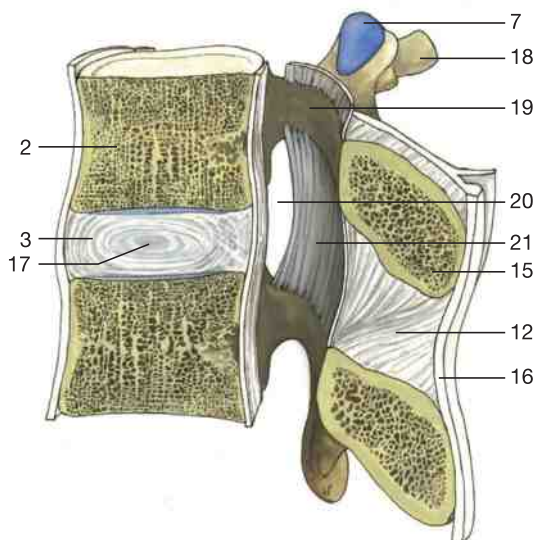
Disarticulated thorax skeleton.
The twelve ribs (I–XII) are arranged in a craniocaudal direction.



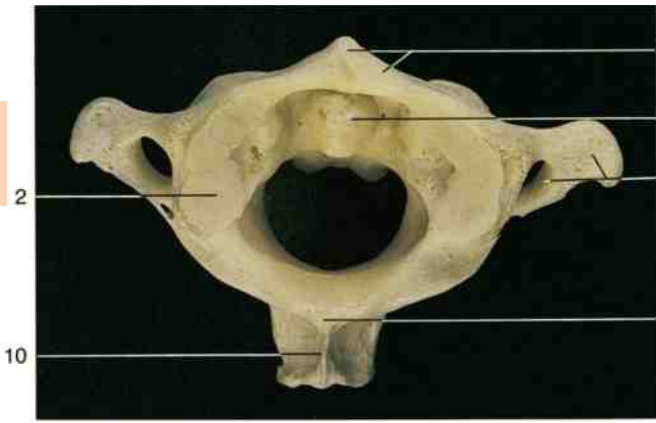
- 1 Anterior longitudinal ligament
- 2 Body of vertebra
- 3 Intervertebral disc
- 4 Intra-articular ligament
- 5 Radiate ligament
- 6 Posterior longitudinal ligament
- 7 Superior articular facet
- 8 Articular facets of costovertebral joints
- 9 Superior costotransverse ligament
- 10 Costovertebral joint
- 11 Rib
- 12 Interspinal ligament
- 13 Costotransverse joint
- 14 Lateral costotransverse ligament
- 15 Spinous process
- 16 Supraspinal ligament
- 17 Nucleus pulposus
- 18 Costal process
- 19 Vertebral arch
- 20 Intervertebral foramen
- 21 Intertransverse ligament



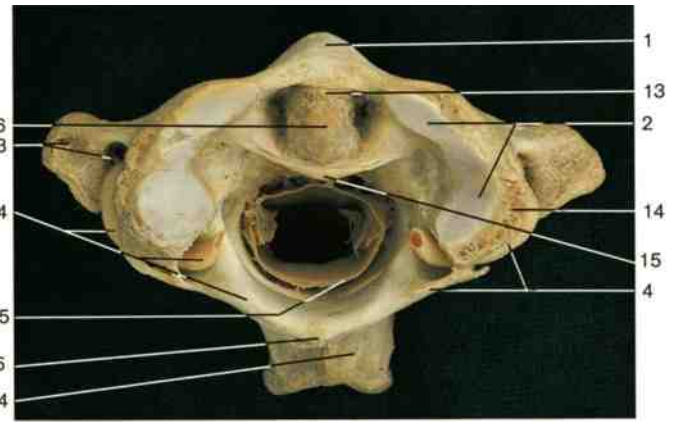
Ligaments of thoracic vertebrae and costovertebral joints (lateral aspect).
Blue = articular facets.



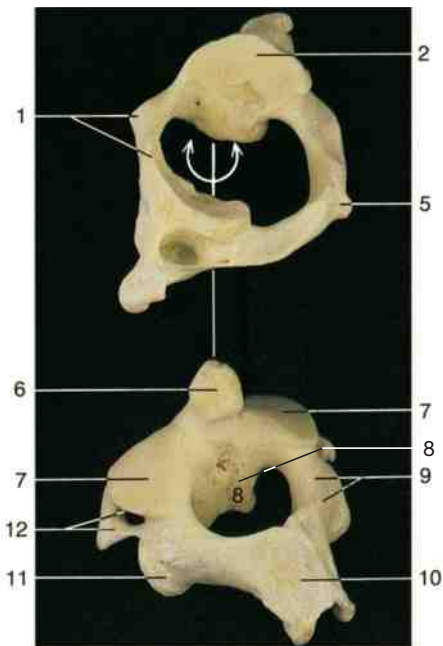
Median-sagittal section of two lumbar vertebrae showing ligaments and vertebral discs.



Atlas and axis (from above).

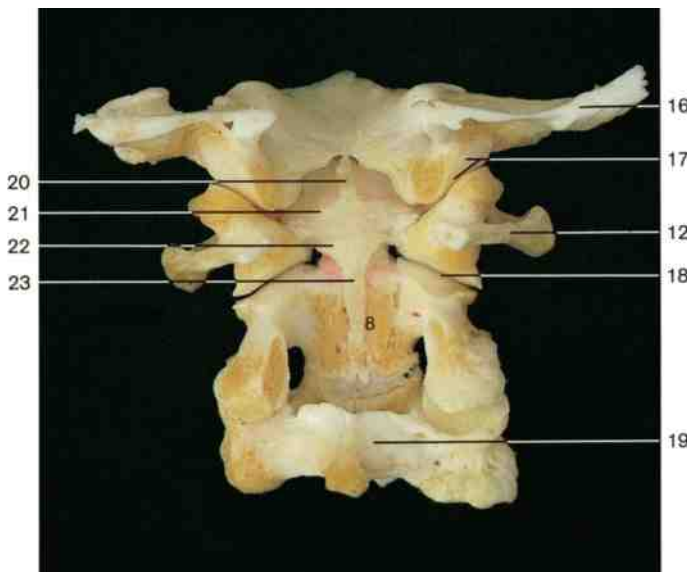


Median atlanto-axial joint and transverse ligament of atlas (from above). Dens of axis partly severed.

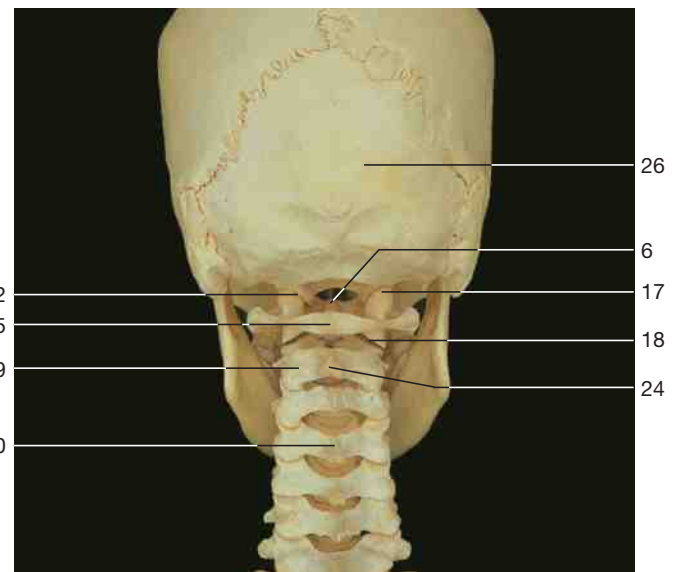


- | | |
|--|---|
| 1 Anterior arch of atlas with anterior tubercle | 14 Articular capsule of atlanto-occipital joint |
| 2 Superior articular facet of atlas | 15 Transverse ligament of atlas |
| 3 Foramen transversarium and transverse process | 16 Occipital bone |
| 4 Posterior arch of atlas and vertebral artery | 17 Atlanto-occipital joint |
| 5 Posterior tubercle of atlas | 18 Lateral atlanto-axial joint |
| 6 Dens of axis | 19 Third cervical vertebra |
| 7 Superior articular surface of axis | 20 Superior longitudinal band of cruciform ligament |
| 8 Body of axis | 21 Alar ligaments |
| 9 Pedicle and lamina of axis | 22 Transverse ligament of atlas |
| 10 Spinous process | 23 Inferior longitudinal band of cruciform ligament |
| 11 Inferior articular process | 24 Spinous process of axis |
| 12 Transverse process and foramen transversarium of axis | 25 Dura mater |
| 13 Median atlanto-axial joint (anterior part) | 26 Occipital bone |

Atlas and axis. Left oblique postero-lateral aspect, demonstrating the articulation of the dens of axis with atlas (cf. arrows).



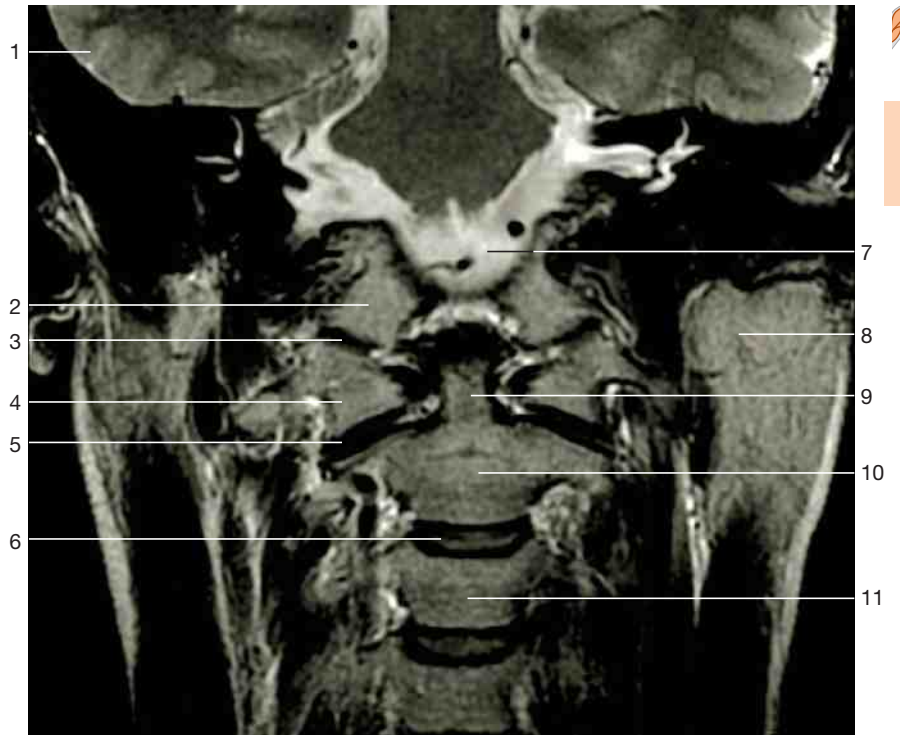
Atlanto-occipital and atlanto-axial joints (posterior aspect). Posterior part of occipital bone, posterior arch of atlas, and axis have been removed to show the cruciform ligament.



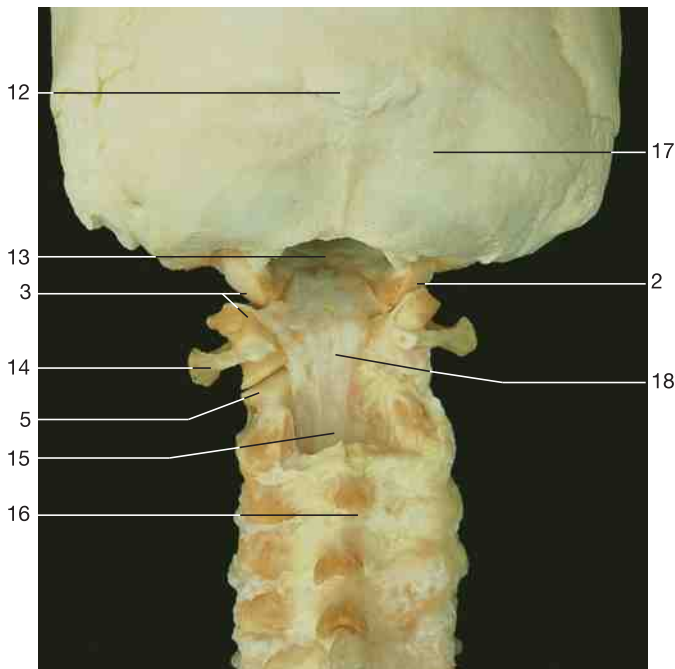
Head and cervical spine (posterior aspect). Bones of atlanto-occipital and atlanto-axial joints.



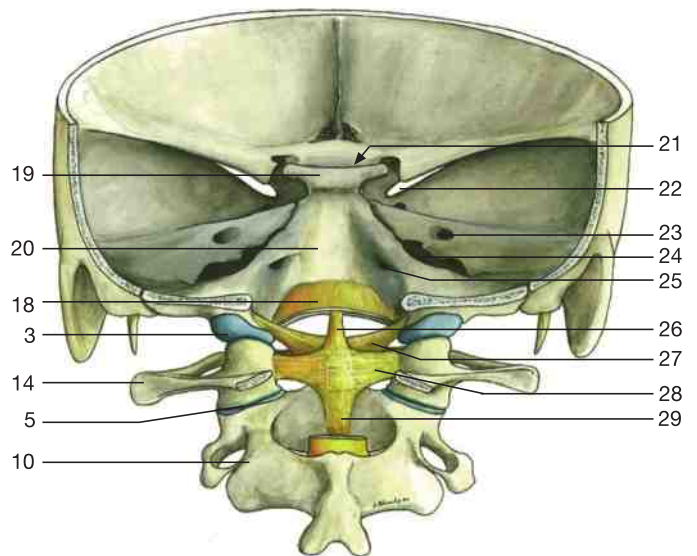
- 1 Cerebellum
- 2 Occipital condyle
- 3 Atlanto-occipital joint
- 4 Atlas
- 5 Lateral atlanto-axial joint
- 6 Intervertebral disc
- 7 Cistern of pons
- 8 Head of mandible
- 9 Dens of axis
- 10 Axis
- 11 Body of cervical vertebra (C₃)
- 12 External occipital protuberance
- 13 Foramen magnum
- 14 Transverse process of atlas
- 15 Posterior longitudinal ligament
- 16 Spinous process of cervical vertebra
- 17 Occipital bone
- 18 Membrana tectoria
- 19 Dorsum sellae
- 20 Clivus
- 21 Sella turcica
- 22 Superior orbital fissure
- 23 Internal acoustic meatus
- 24 Jugular foramen
- 25 Hypoglossal canal
- 26 Superior longitudinal band of cruciform ligament
- 27 Alar ligaments
- 28 Transverse ligament of atlas
- 29 Inferior longitudinal band of cruciform ligament



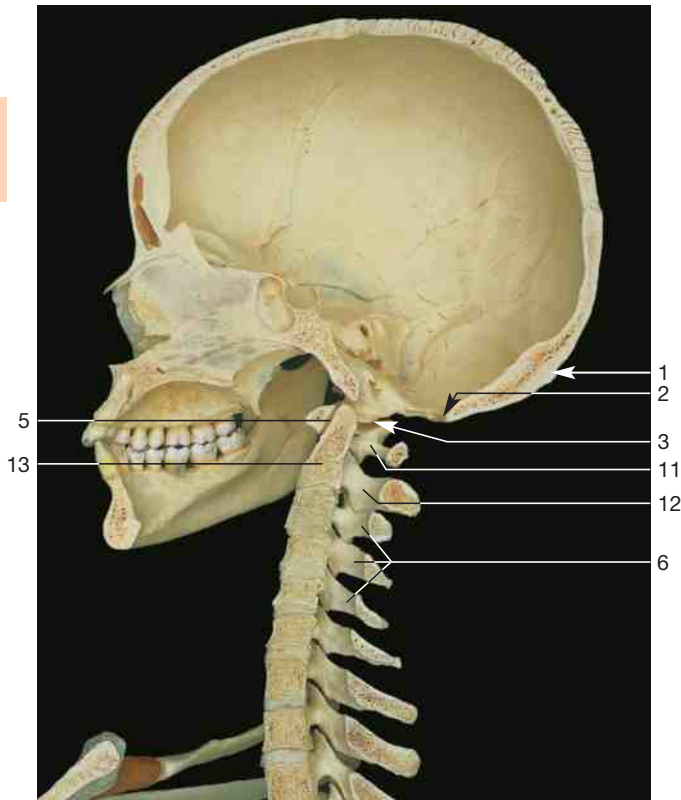
Coronal section of the neck at the level of dens of axis (MRI scan, courtesy of Prof. Heuck, Munich).



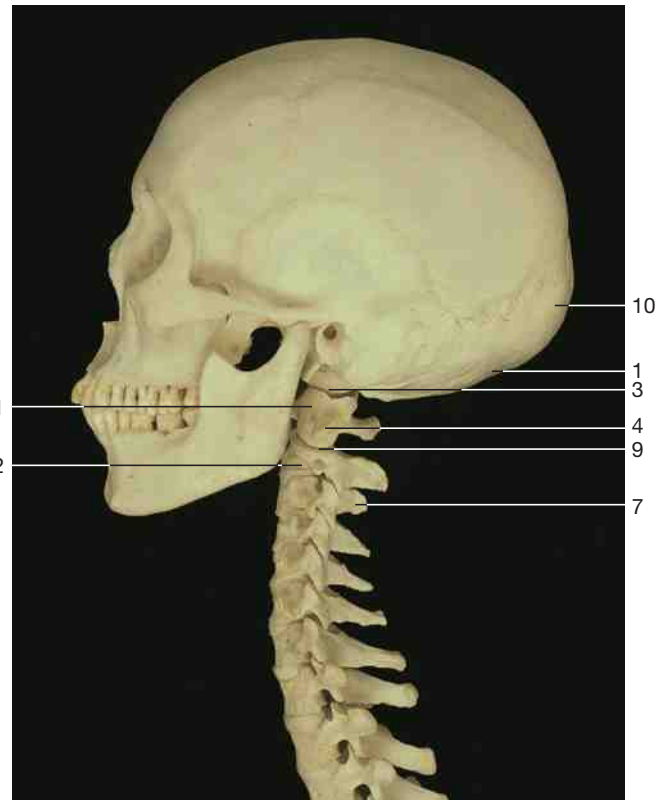
Cervical vertebral column and skull with ligaments (posterior aspect). Posterior arches of atlas and axis removed to show the membrana tectoria.



Atlanto-occipital and atlanto-axial joints with ligaments (posterior aspect). Posterior part of occipital bone and posterior arch of atlas have been removed to show the cruciform ligament.



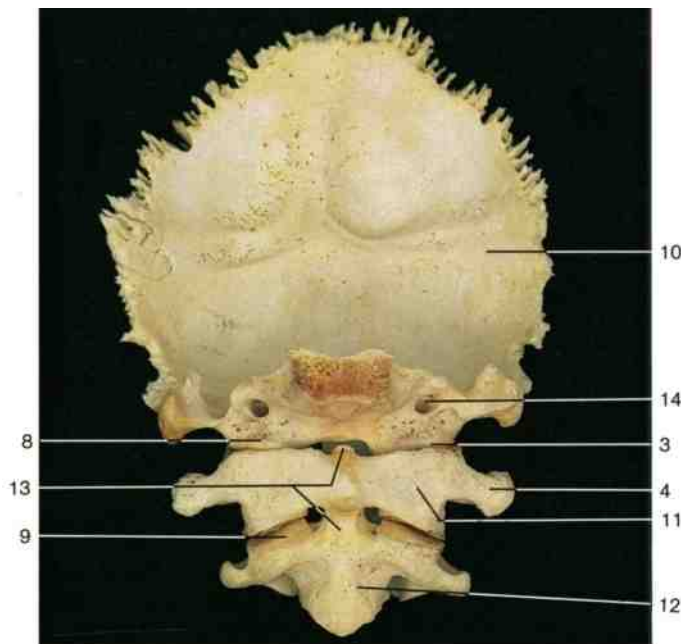
Cervical vertebral column in relation to the head (midsagittal section, medial aspect).



Atlas and axis in relation to the head (lateral aspect).

- 1 External occipital protuberance
- 2 Foramen magnum
- 3 Atlanto-occipital joint
- 4 Transverse process of atlas
- 5 Median atlanto-axial joint
- 6 Vertebral canal
- 7 Spinous process of third cervical vertebra
- 8 Occipital condyle

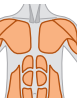
- 9 Lateral atlanto-axial joint
- 10 Occipital bone
- 11 Atlas
- 12 Axis
- 13 Dens of axis
- 14 Hypoglossal canal
- 15 Spinous process of axis



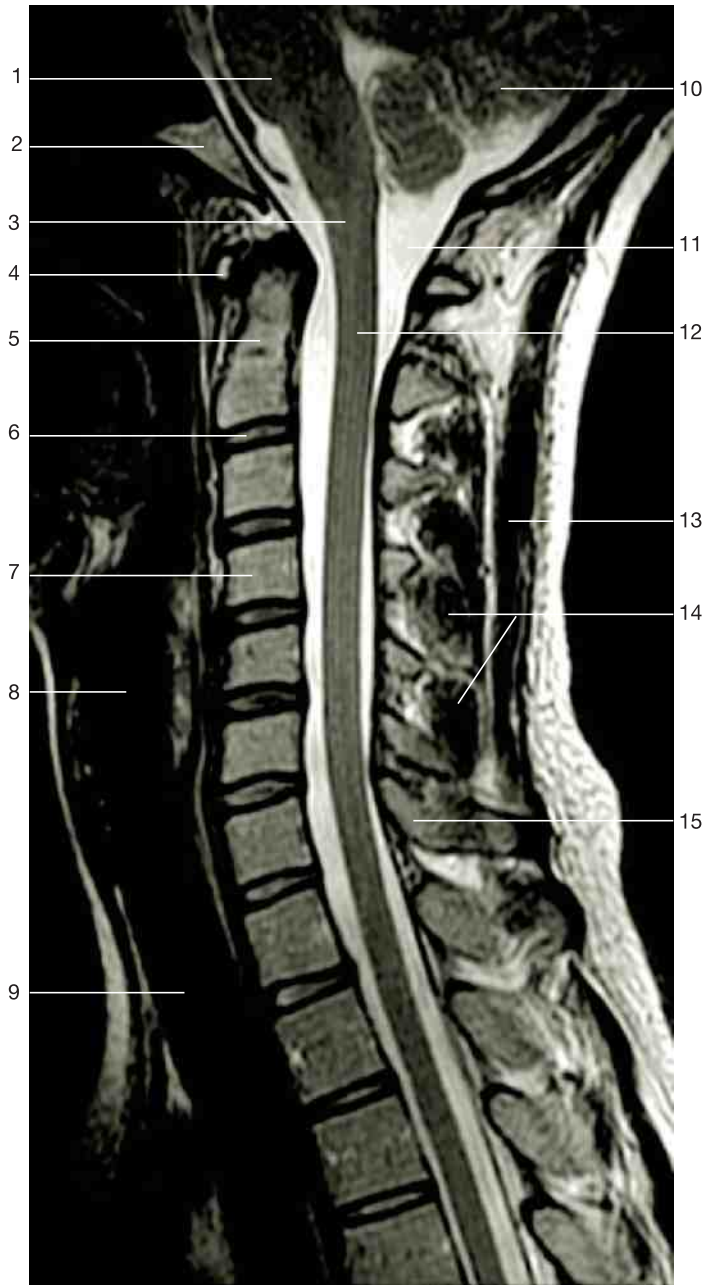Occipital bone, atlas, and axis (anterior aspect).



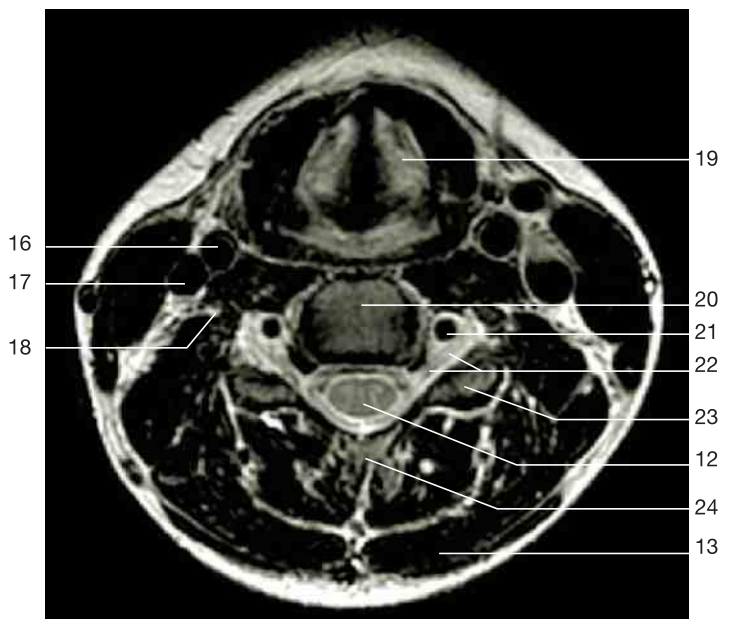
Occipital bone, atlas, and axis (left lateral aspect).



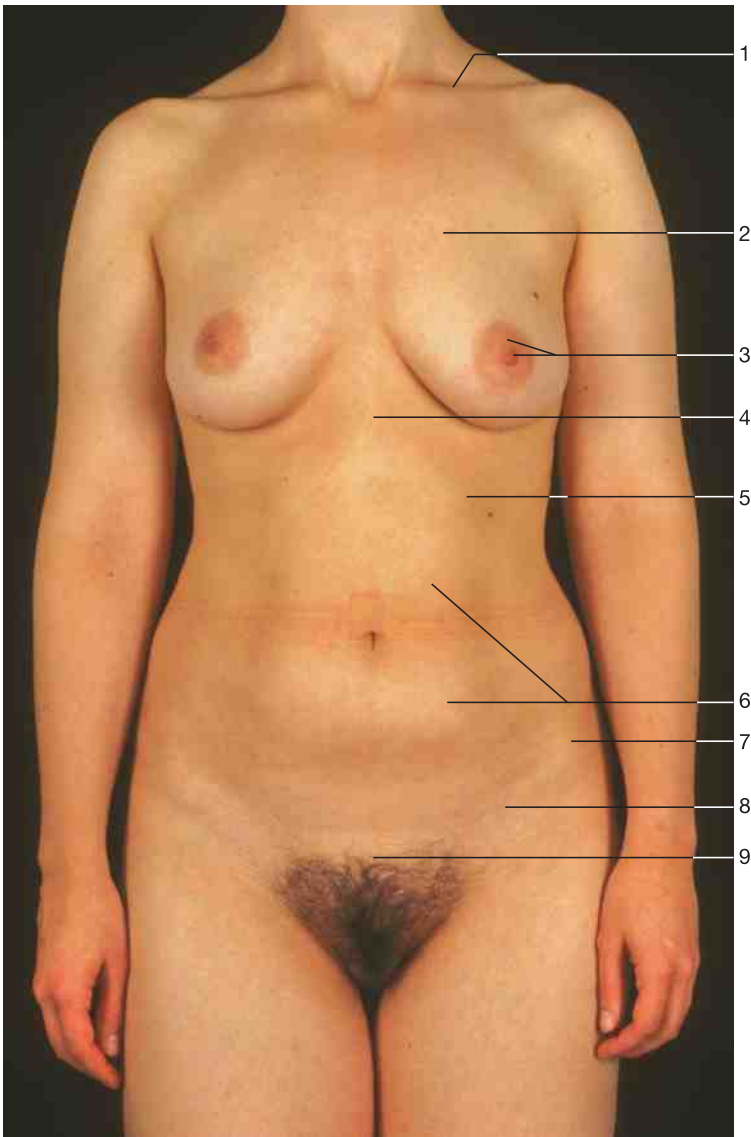
- 1 Pons
- 2 Base of skull (clivus)
- 3 Medulla oblongata
- 4 Atlas (anterior arch)
- 5 Dens of axis
- 6 Intervertebral disc
- 7 Body of cervical vertebra (C₄)
- 8 Site of larynx
- 9 Trachea
- 10 Cerebellum
- 11 Cerebellomedullary cistern
- 12 Spinal cord
- 13 Trapezius muscle
- 14 Muscles of the neck
- 15 Spinous process of cervical vertebra (C₇)
- 16 Internal jugular vein
- 17 Common carotid artery
- 18 Vagus nerve (n. X)
- 19 Larynx
- 20 Body of cervical vertebra
- 21 Vertebral artery
- 22 Spinal nerve with spinal ganglion
- 23 Transverse process of cervical vertebra
- 24 Spinous process of cervical vertebra



Midsagittal section of the neck showing the spinal cord in connection with medulla oblongata (MRI scan, courtesy of Prof. Heuck, Munich).

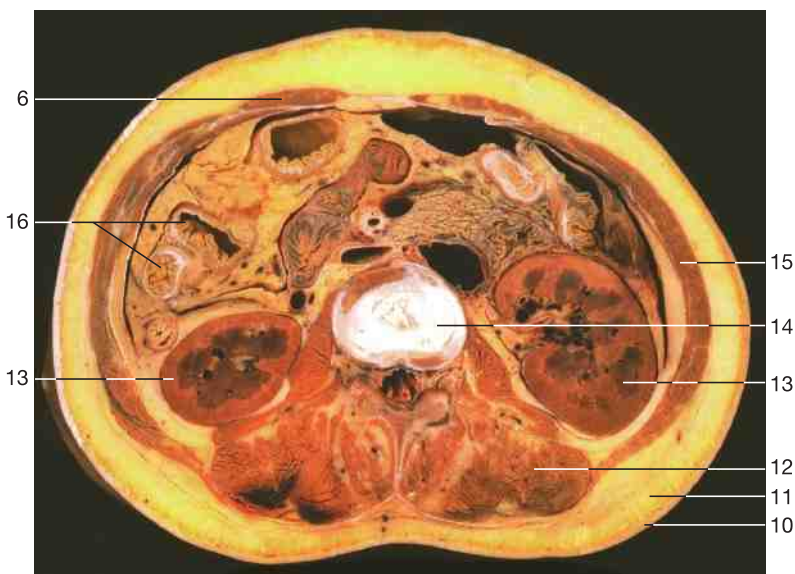


Horizontal section of the neck at the level of the larynx (MRI scan, courtesy of Prof. Heuck, Munich).

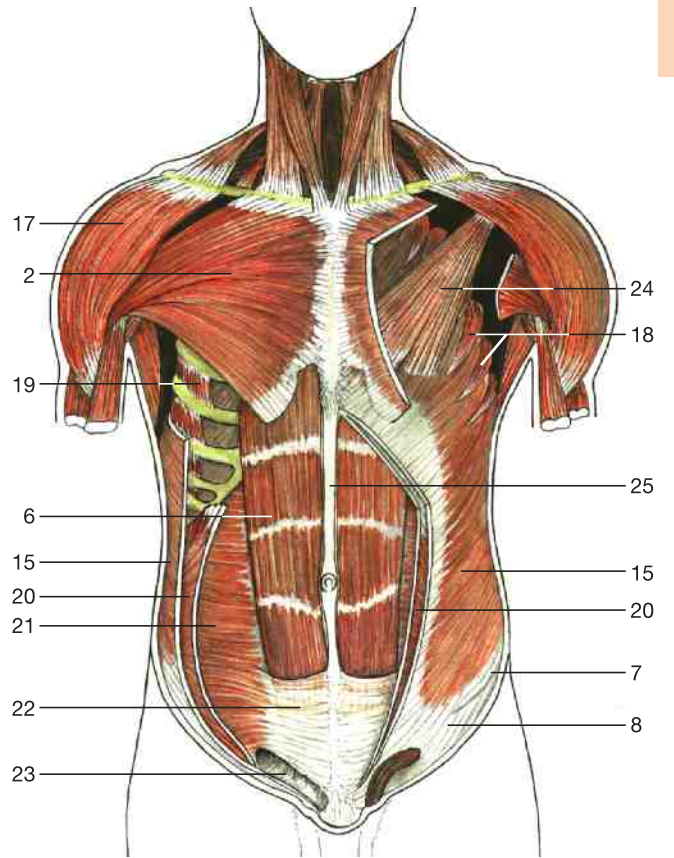
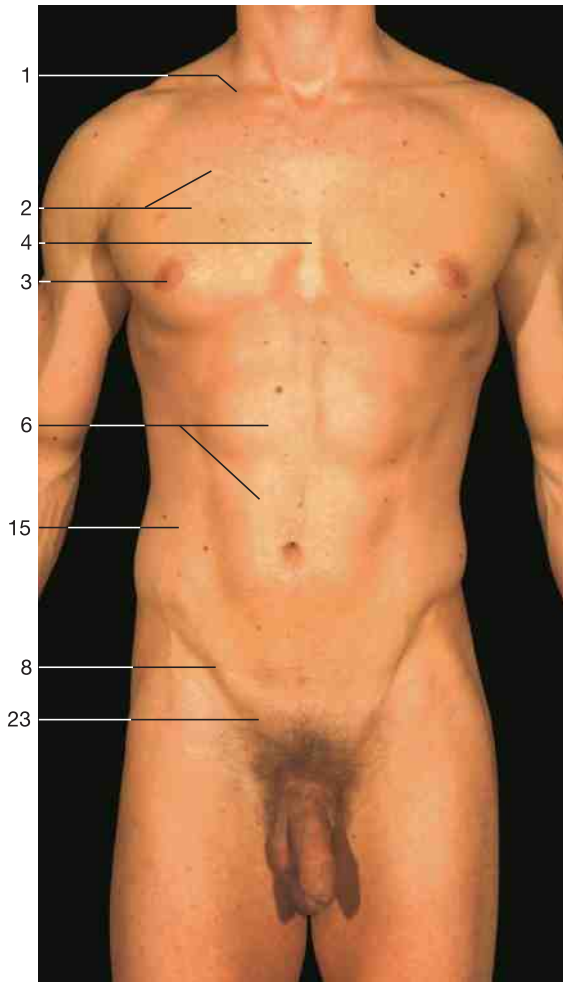
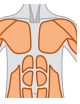


- 1 Clavicle
- 2 Pectoralis major muscle
- 3 Areola and nipple
- 4 Infrasternal angle
- 5 Costal arch
- 6 Rectus abdominis muscle
- 7 Anterior superior iliac spine
- 8 Inguinal ligament
- 9 Mons pubis
- 10 Epidermis
- 11 Subcutaneous layer
- 12 Muscles of the back
- 13 Kidney
- 14 Body of lumbar vertebra
- 15 External abdominal oblique muscle
- 16 Small intestine
- 17 Deltoid muscle
- 18 Anterior serratus muscle
- 19 External intercostal muscle
- 20 Internal abdominal oblique muscle
- 21 Transverse abdominal muscle
- 22 Rectus sheath
- 23 Spermatic cord
- 24 Pectoralis minor muscle
- 25 Linea alba

Surface anatomy of the anterior body wall in the female. Note the differences in thickness and structure of skin and hairs (compare with the section below).

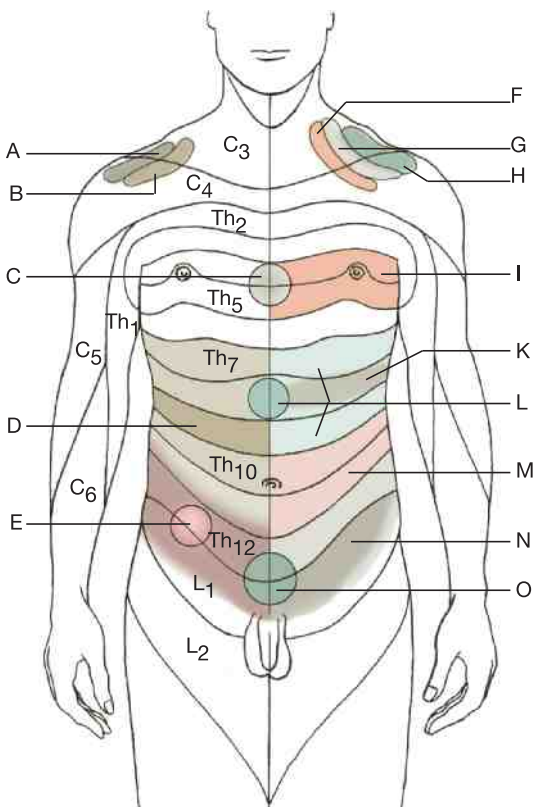


Cross section of the body at the first lumbar vertebra. Note the differences in thickness of the subcutaneous layers.



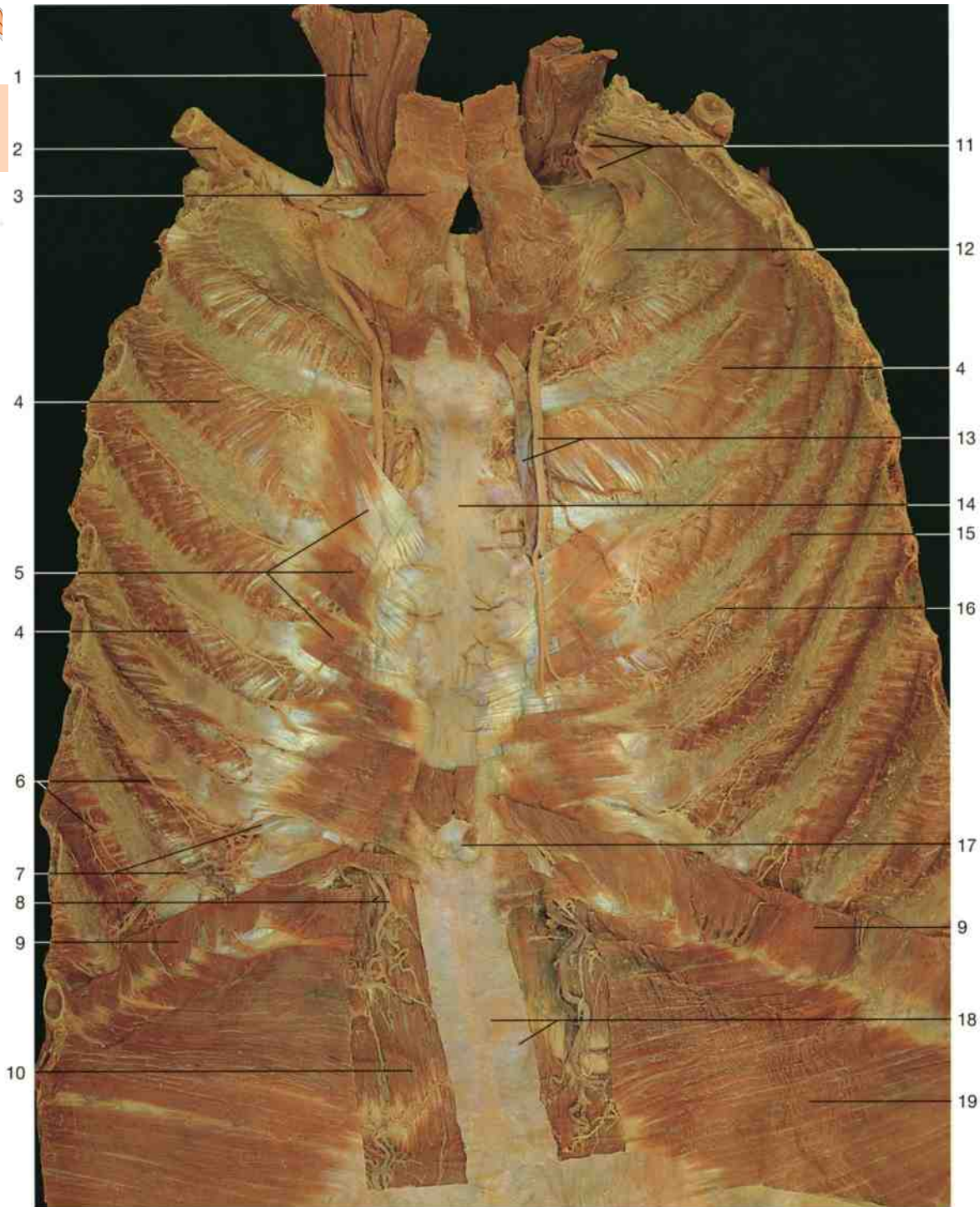
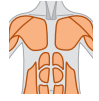
Surface anatomy of the anterior body wall in the male. Localization and structure of the muscles can be identified.

Muscles of the anterior body wall (schematic drawing).



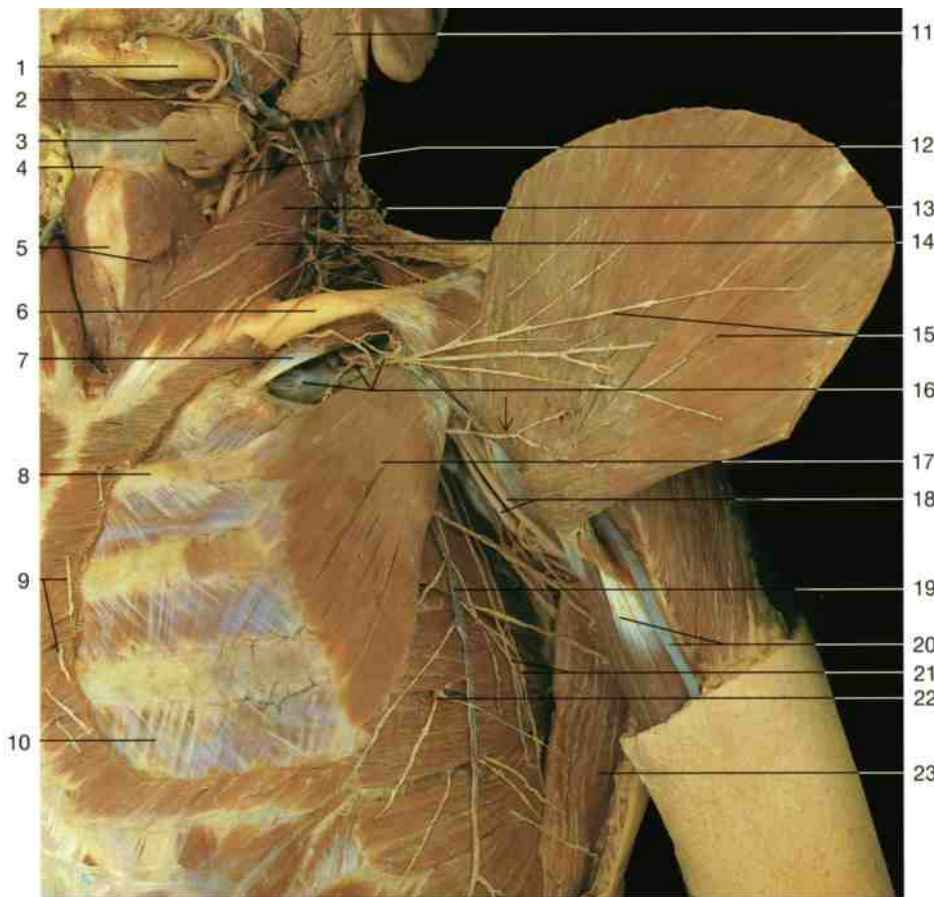
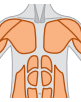- Head's areas**
- A = duodenum
 - B = gallbladder, liver (C₃-C₄)
 - C = esophagus (Th₄, Th₅)
 - D = liver, gallbladder (Th₆-Th₁₁)
 - E = colon, vermiform appendix (Th₁₁₋₁₂, L₁)
 - F = heart
 - G = pancreas
 - H = stomach (C₃, C₄)
 - I = heart (Th₃, Th₄)
 - K = pancreas (Th₈)
 - L = stomach (Th₆-Th₉)
 - M = small intestine (Th₁₀-L₁)
 - N = kidney, ureter, testis (Th₁₀-L₁)
 - O = urinary bladder (Th₁₁-L₁)

◁ Segments of anterior body wall. Head's areas are indicated.



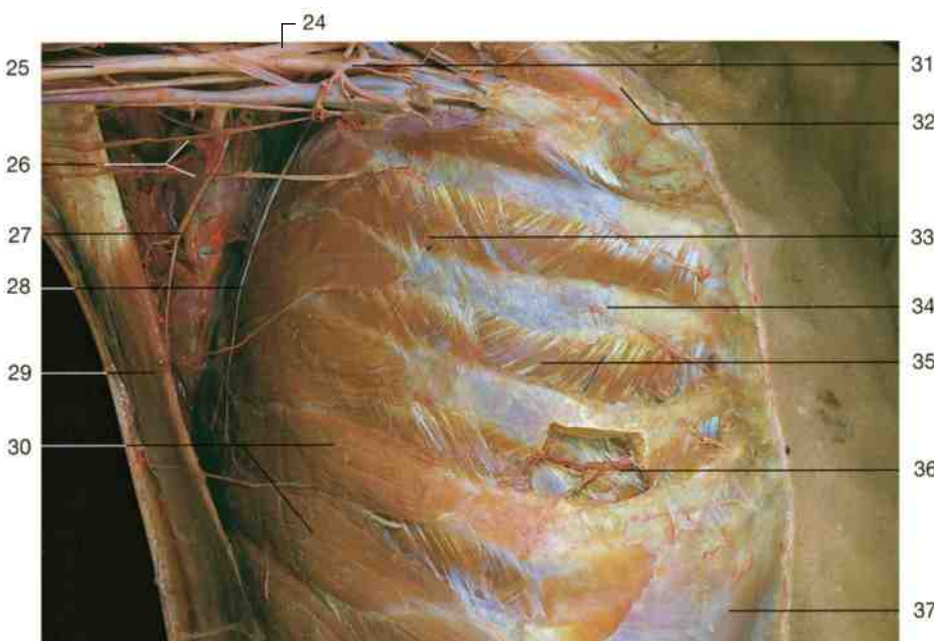
Anterior thoracic wall (posterior aspect). Diaphragm partly removed, posterior layer of rectus sheath fenestrated on both sides.

- | | |
|--|--|
| 1 Sternocleidomastoid muscle (divided) | 11 Subclavian artery and brachial plexus |
| 2 Clavicle | 12 First rib |
| 3 Sternothyroid muscle | 13 Internal thoracic artery and vein |
| 4 Internal intercostal muscle | 14 Sternum |
| 5 Transversus thoracic muscle | 15 Innermost intercostal muscle |
| 6 Intercostal arteries and nerves | 16 Intercostal artery and vein |
| 7 Musculophrenic artery | 17 Xiphoid process |
| 8 Superior epigastric artery and vein | 18 Linea alba and posterior layer of rectus sheath |
| 9 Diaphragm (divided) | 19 Transversus abdominis muscle |
| 10 Rectus abdominis muscle | |

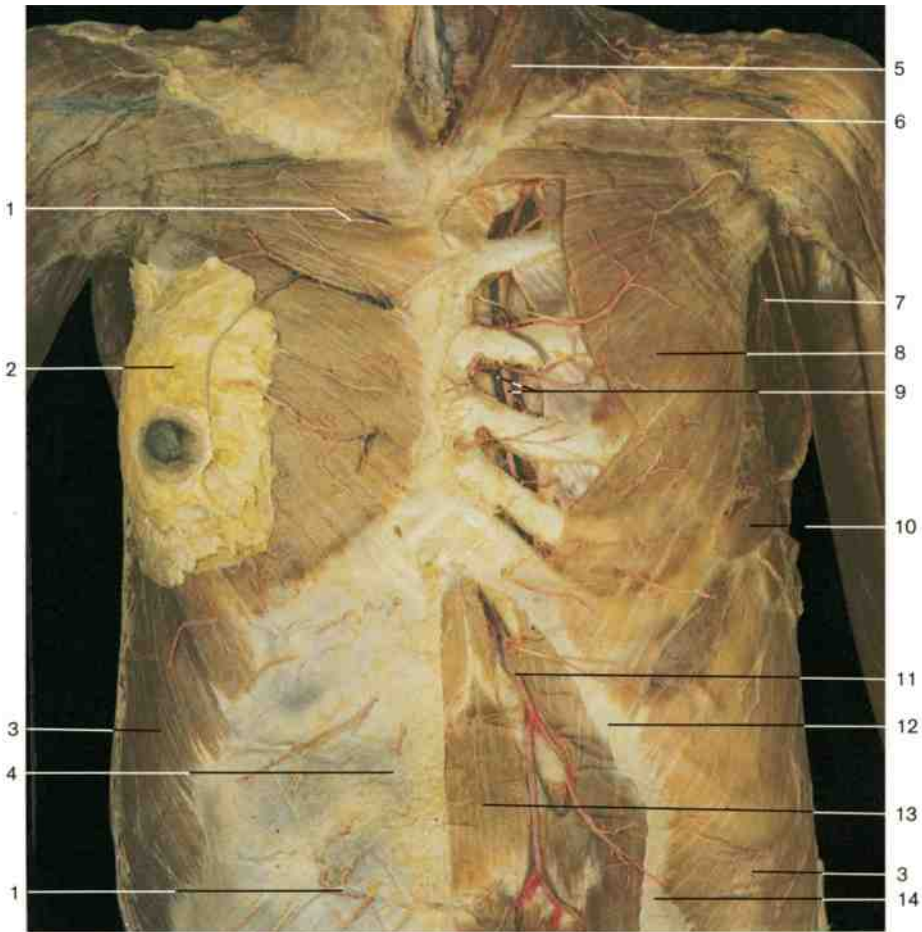
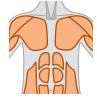


Thoracic wall (anterior aspect). Left pectoralis major muscle has been divided and reflected. Note the connection of the cephalic vein with the subclavian vein. Arrow: medial pectoral nerve.

- 1 Mandible
- 2 Facial artery
- 3 Submandibular gland
- 4 Hyoid bone
- 5 Thyroid cartilage and sternohyoid muscle
- 6 Clavicle
- 7 Subclavius muscle
- 8 Second rib
- 9 Anterior cutaneous branches of intercostal nerves
- 10 External intercostal membrane
- 11 Parotid gland
- 12 External carotid artery
- 13 Sternocleidomastoid muscle and cutaneous branches of cervical plexus
- 14 Supraclavicular nerves
- 15 Pectoralis major muscle and lateral pectoral nerves
- 16 Thoraco-acromial artery and subclavian vein
- 17 Pectoralis minor muscle
- 18 Median and ulnar nerve
- 19 Thoraco-epigastric vein
- 20 Cephalic vein and long head of biceps brachii muscle
- 21 Lateral thoracic artery and long thoracic nerve
- 22 Lateral cutaneous branches of intercostal nerve
- 23 Latissimus dorsi muscle
- 24 Median nerve
- 25 Axillary artery
- 26 Intercostobrachial nerves
- 27 Thoracodorsal nerve
- 28 Long thoracic nerve
- 29 Latissimus dorsi muscle
- 30 Serratus anterior muscle
- 31 Thoraco-acromial artery
- 32 Clavicle
- 33 External intercostal muscle
- 34 Third rib
- 35 Internal intercostal muscle
- 36 Anterior intercostal artery and vein, and intercostal nerve
- 37 Costal arch or margin

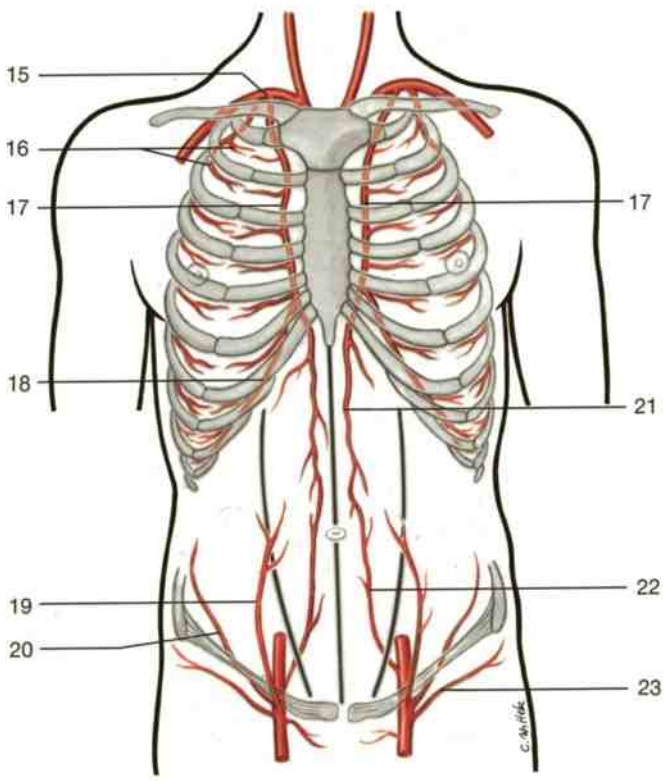


Thoracic wall (lateral aspect). Pectoralis major and minor muscles have been removed. A section of the fourth rib has been cut and removed to display the intercostal vessels and nerve.

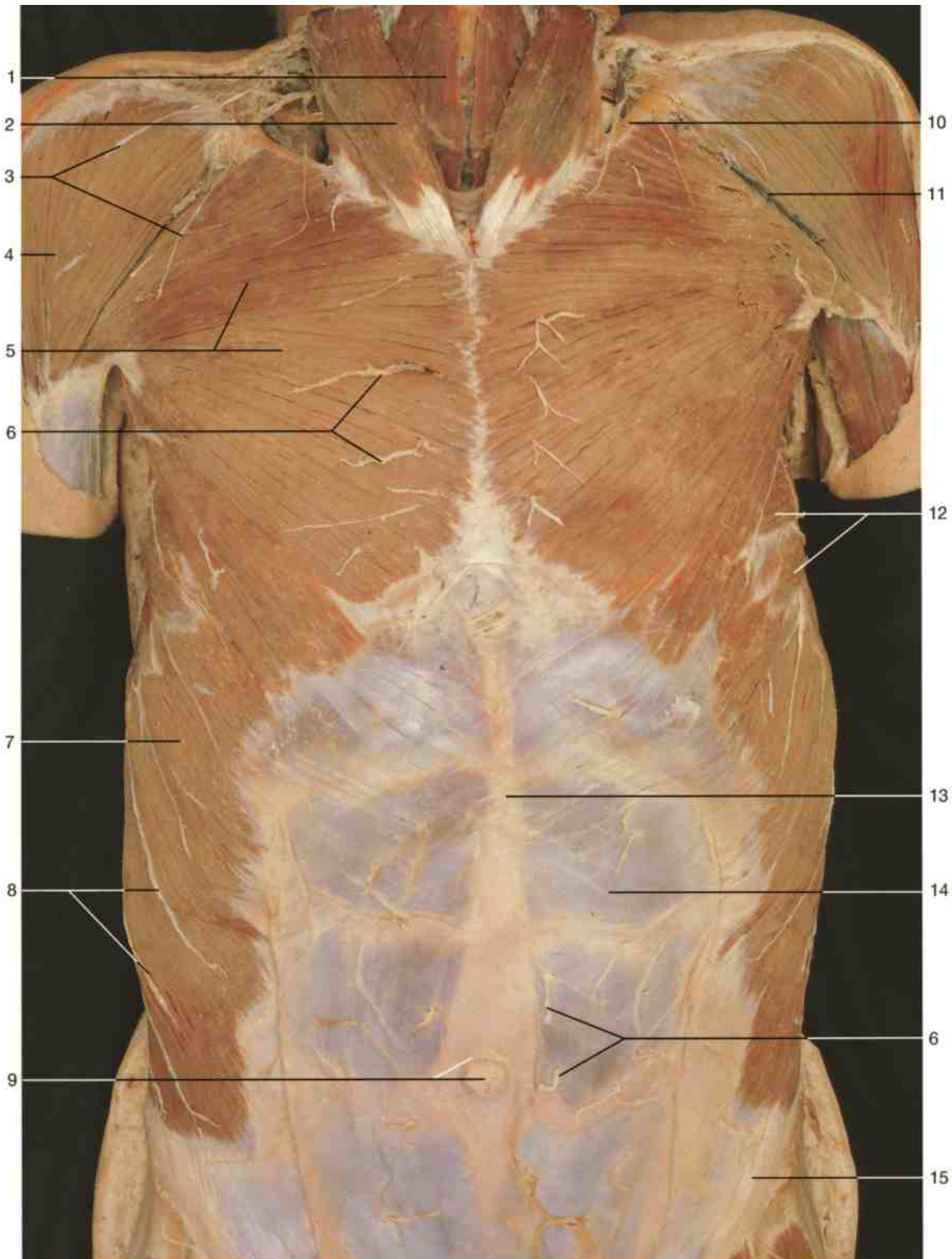


- 1 Anterior perforating branches of intercostal nerve
- 2 Mammary gland
- 3 External abdominal oblique muscle
- 4 Rectus sheath (anterior layer)
- 5 Sternocleidomastoid muscle
- 6 Clavicle
- 7 Lateral thoracic artery and vein
- 8 Pectoralis major muscle
- 9 Internal thoracic artery and vein
- 10 Serratus anterior muscle
- 11 Superior epigastric artery and vein
- 12 Costal margin
- 13 Rectus abdominis muscle
- 14 Cut edge of the anterior layer of the rectus sheath
- 15 Subclavian artery
- 16 Highest intercostal artery
- 17 Internal thoracic artery
- 18 Musculophrenic artery
- 19 Superficial epigastric artery
- 20 Deep circumflex iliac artery
- 21 Superior epigastric artery
- 22 Inferior epigastric artery
- 23 Superficial circumflex iliac artery

Thoracic wall (anterior aspect). Dissection of the internal thoracic artery and vein. Left pectoralis major muscle partly removed. Anterior lamina of the rectus sheath on the left side has been removed.

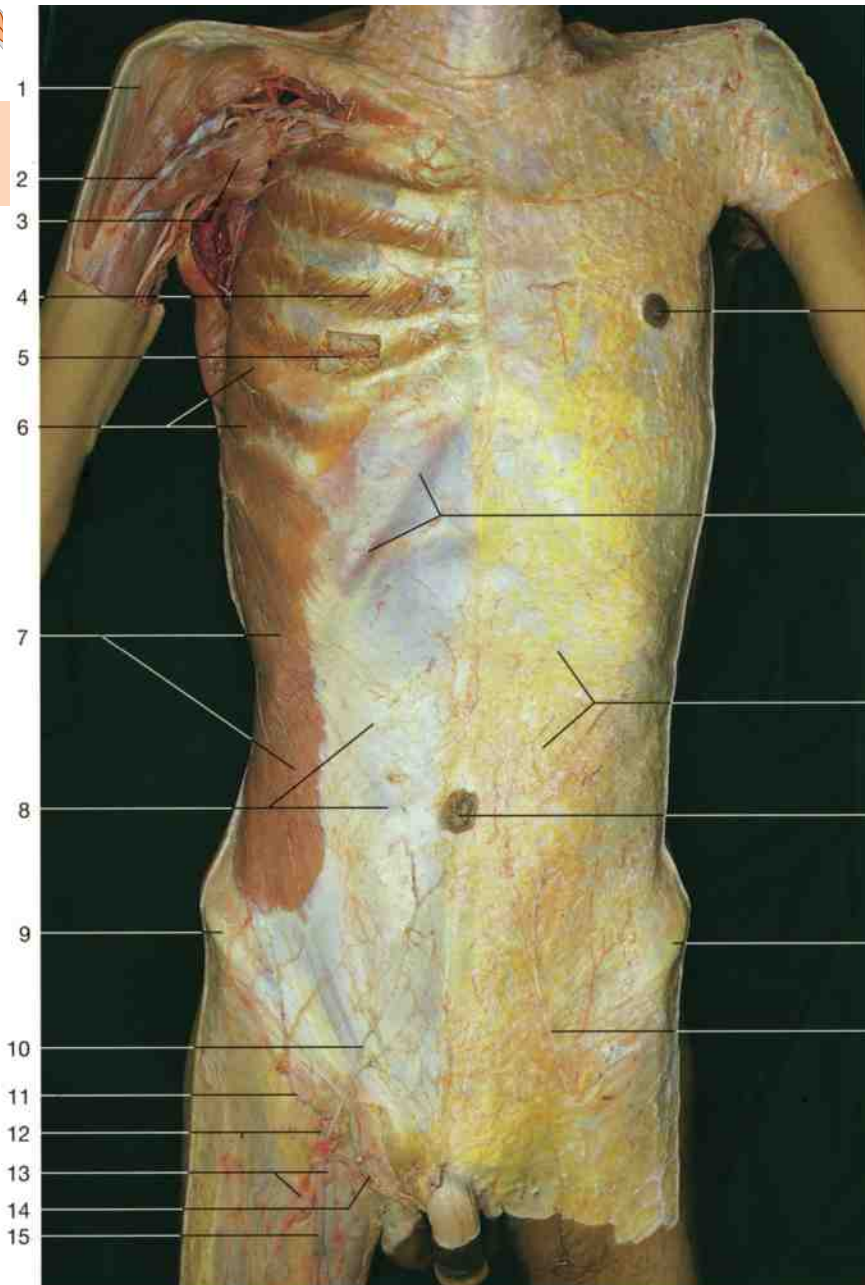


Main arteries of thoracic and abdominal walls.



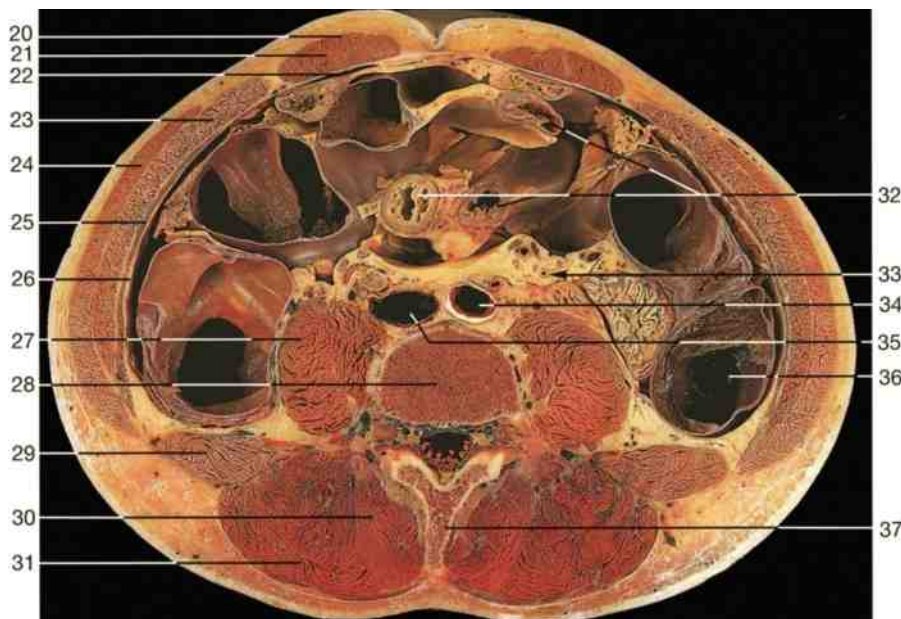
Anterior thoracic and abdominal walls with superficial muscles. The fascia of pectoralis major muscle and the abdominal wall have been removed; the anterior layer of the sheath of the rectus abdominis muscle is displayed.

- | | |
|--|---|
| 1 Sternohyoid muscle | 9 Umbilicus and umbilical ring |
| 2 Sternocleidomastoid muscle | 10 Clavicle |
| 3 Supraclavicular nerves (branches of cervical plexus) | 11 Cephalic vein |
| 4 Deltoid muscle | 12 Serratus anterior muscle |
| 5 Pectoralis major muscle | 13 Linea alba |
| 6 Anterior cutaneous branches of intercostal nerves | 14 Sheath of rectus abdominis muscle (anterior layer) |
| 7 External abdominal oblique muscle | 15 Inguinal ligament |
| 8 Lateral cutaneous branches of intercostal nerves | |

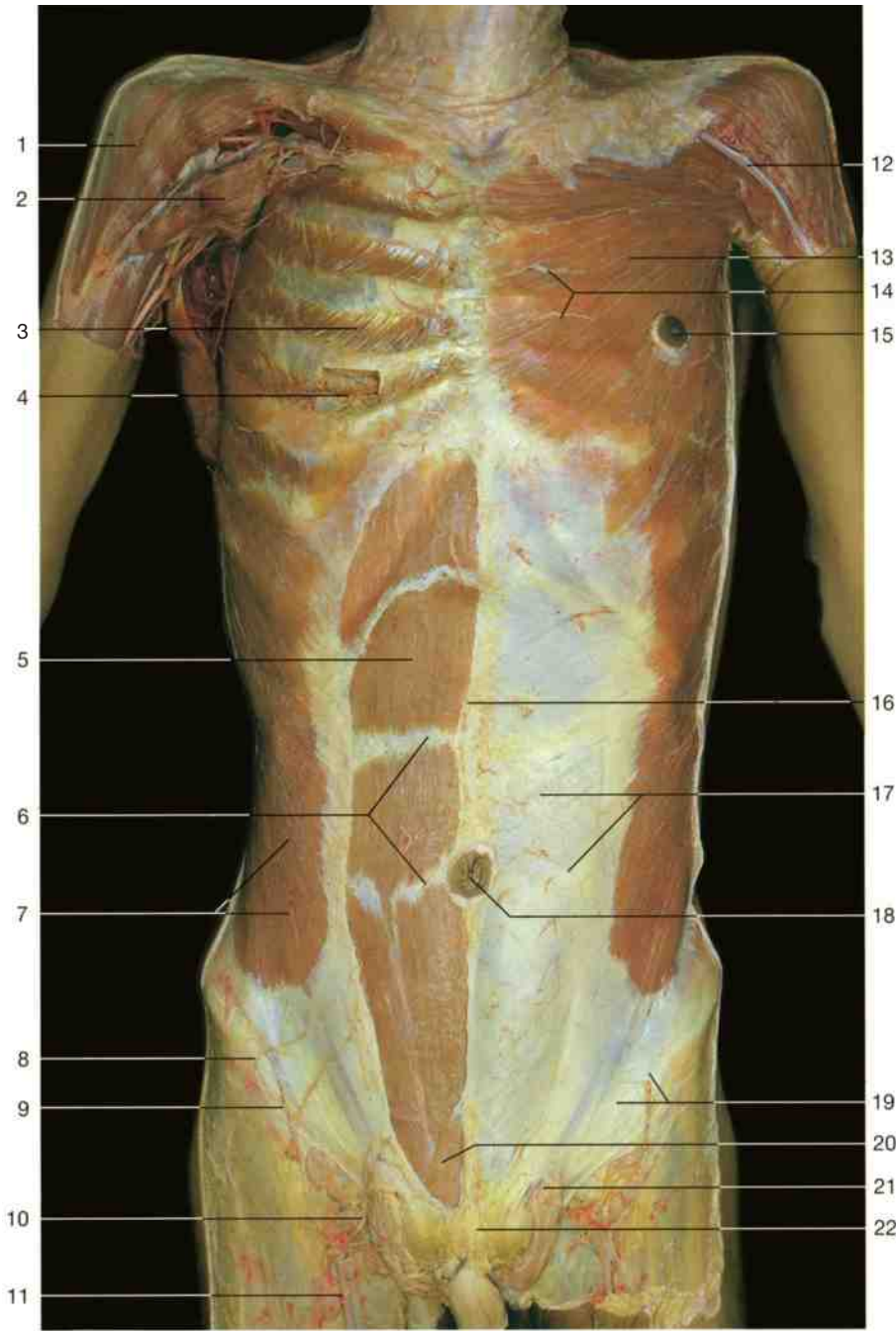
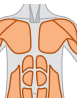


- 1 Deltoid muscle
- 2 Cephalic vein
- 3 Pectoralis major muscle (divided)
- 4 Internal intercostal muscle
- 5 Intercostal artery and vein (intercostal space, fenestrated)
- 6 Serratus anterior muscle
- 7 External abdominal oblique muscle
- 8 Anterior layer of rectus sheath
- 9 Iliac crest
- 10 Superficial epigastric vein
- 11 Superficial circumflex iliac vein
- 12 Saphenous opening
- 13 Superficial inguinal lymph nodes
- 14 Superficial external pudendal veins
- 15 Great saphenous vein
- 16 Nipple
- 17 Costal margin
- 18 Subcutaneous fatty tissue
- 19 Umbilicus
- 20 Anterior layer of rectus sheath
- 21 Rectus abdominis muscle
- 22 Posterior layer of rectus sheath
- 23 Internal abdominal oblique muscle
- 24 External abdominal oblique muscle (cut)
- 25 Transversus abdominis muscle
- 26 Transversalis fascia and peritoneum
- 27 Psoas major muscle
- 28 Body of lumbar vertebra (L₄)
- 29 Quadratus lumborum muscle
- 30 Medial tract of erector spinae muscle
- 31 Lateral tract of erector spinae muscle (longissimus and iliocostalis muscles)
- 32 Small intestine
- 33 Left ureter
- 34 Abdominal aorta
- 35 Inferior vena cava
- 36 Descending colon
- 37 Spinous process

Thoracic and abdominal walls. Right pectoralis major and minor muscles are divided. Muscles of thoracic and abdominal walls on right side are displayed.

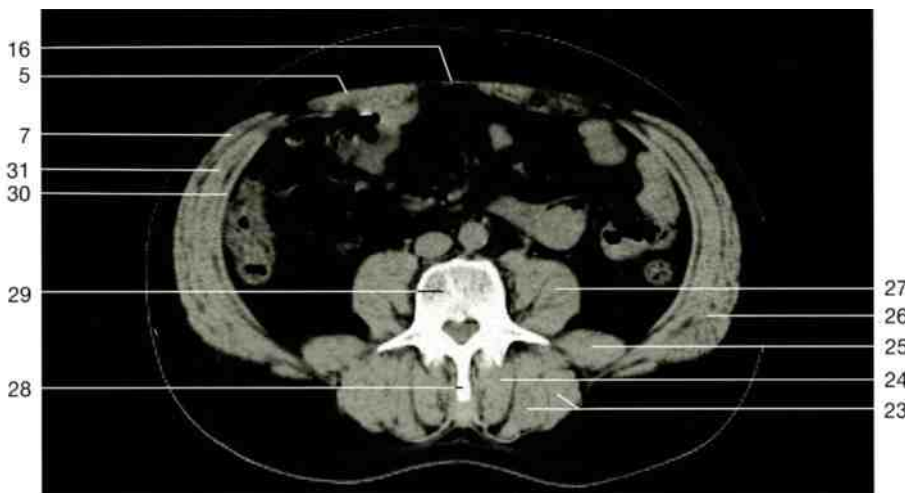

Horizontal section of the trunk at the level of the umbilicus, superior to arcuate line (inferior aspect).

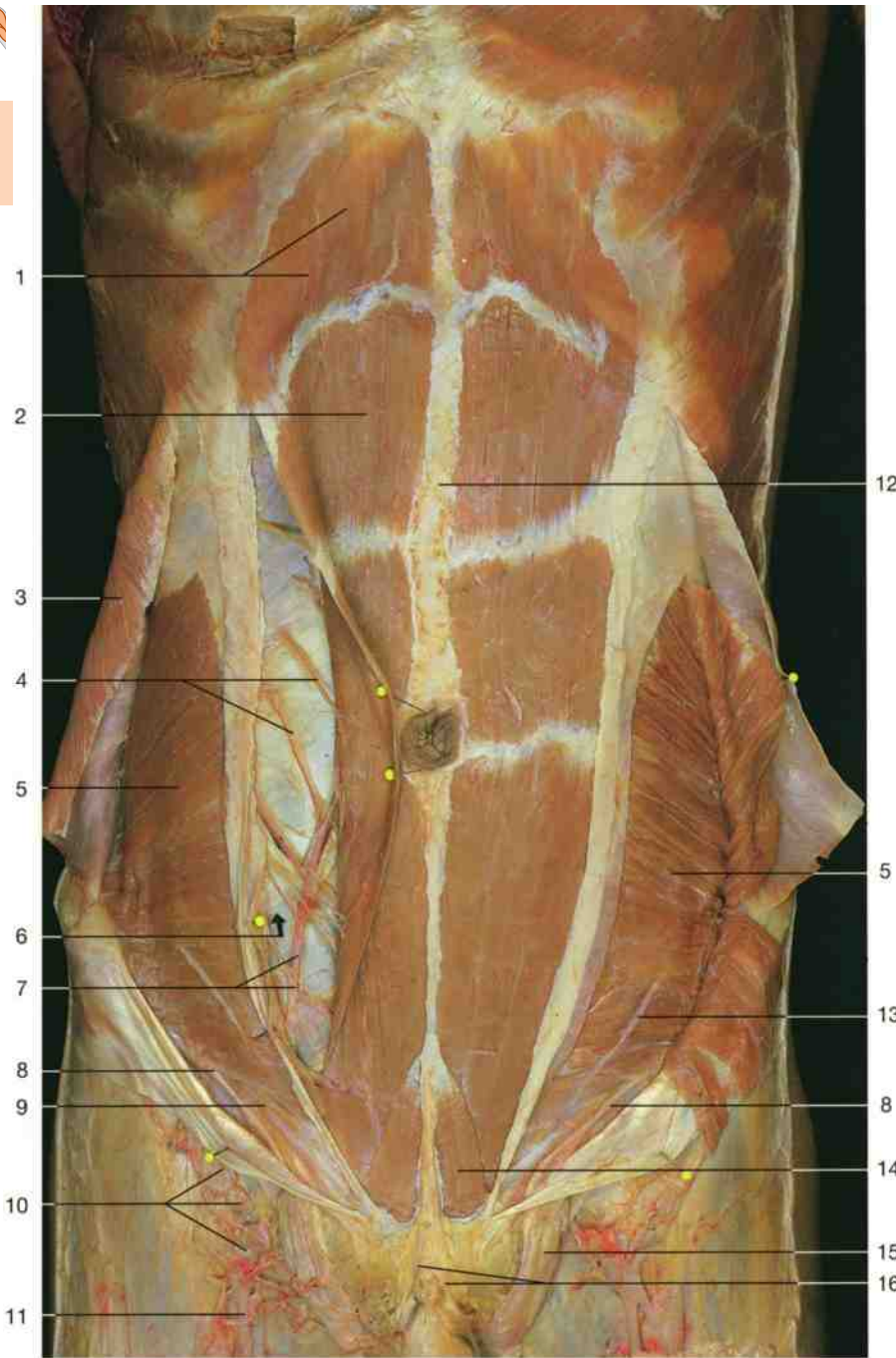


- 1 Deltoid muscle
- 2 Pectoralis major muscle (divided)
- 3 Internal intercostal muscle
- 4 Intercostal artery and vein
- 5 Rectus abdominis muscle
- 6 Tendinous intersections
- 7 External abdominal oblique muscle
- 8 Anterior superior iliac spine
- 9 Superficial circumflex iliac vein
- 10 Superficial epigastric vein
- 11 Great saphenous vein
- 12 Cephalic vein
- 13 Pectoralis major muscle
- 14 Anterior cutaneous branches of intercostal nerves
- 15 Nipple
- 16 Linea alba
- 17 Anterior layer of rectus sheath
- 18 Umbilicus
- 19 Inguinal ligament
- 20 Pyramidal muscle
- 21 Superficial inguinal ring and spermatic cord
- 22 Suspensory ligament of penis
- 23 Longissimus and iliocostalis muscles
- 24 Multifidus muscle
- 25 Quadratus lumborum muscle
- 26 Latissimus dorsi muscle
- 27 Psoas major muscle
- 28 Spinous process
- 29 Body of first lumbar vertebra
- 30 Transversus abdominis muscle
- 31 Internal abdominal oblique muscle

Thoracic and abdominal walls. Right pectoralis major and minor muscles and anterior layer of rectus sheath have been removed on the right side.



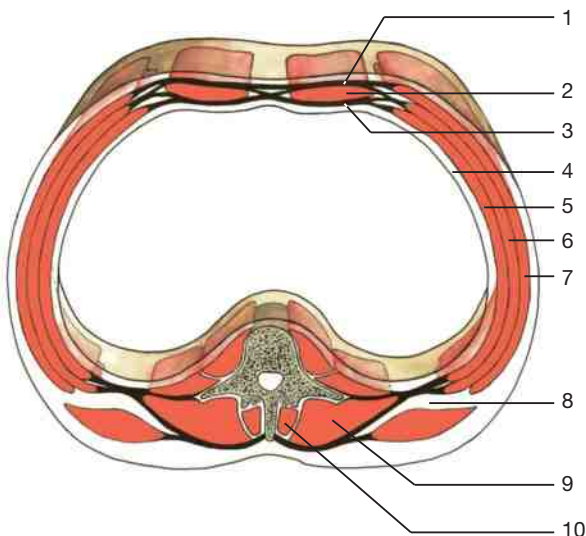
Horizontal section through the body at the level of fourth lumbar vertebra; seen from below. (CT scan.)



- 1 Costal margin
- 2 Rectus abdominis muscle
- 3 External abdominal oblique muscle (reflected)
- 4 Thoraco-abdominal (intercostal) nerves with accompanying vessels
- 5 Internal abdominal oblique muscle
- 6 Arcuate line (arrow)
- 7 Inferior epigastric artery and vein
- 8 Ilio-inguinal nerve
- 9 Position of deep inguinal ring
- 10 Superficial inguinal lymph nodes
- 11 Great saphenous vein
- 12 Linea alba
- 13 Iliohypogastric nerve
- 14 Pyramidal muscle
- 15 Spermatic cord
- 16 Fundiform ligament of penis

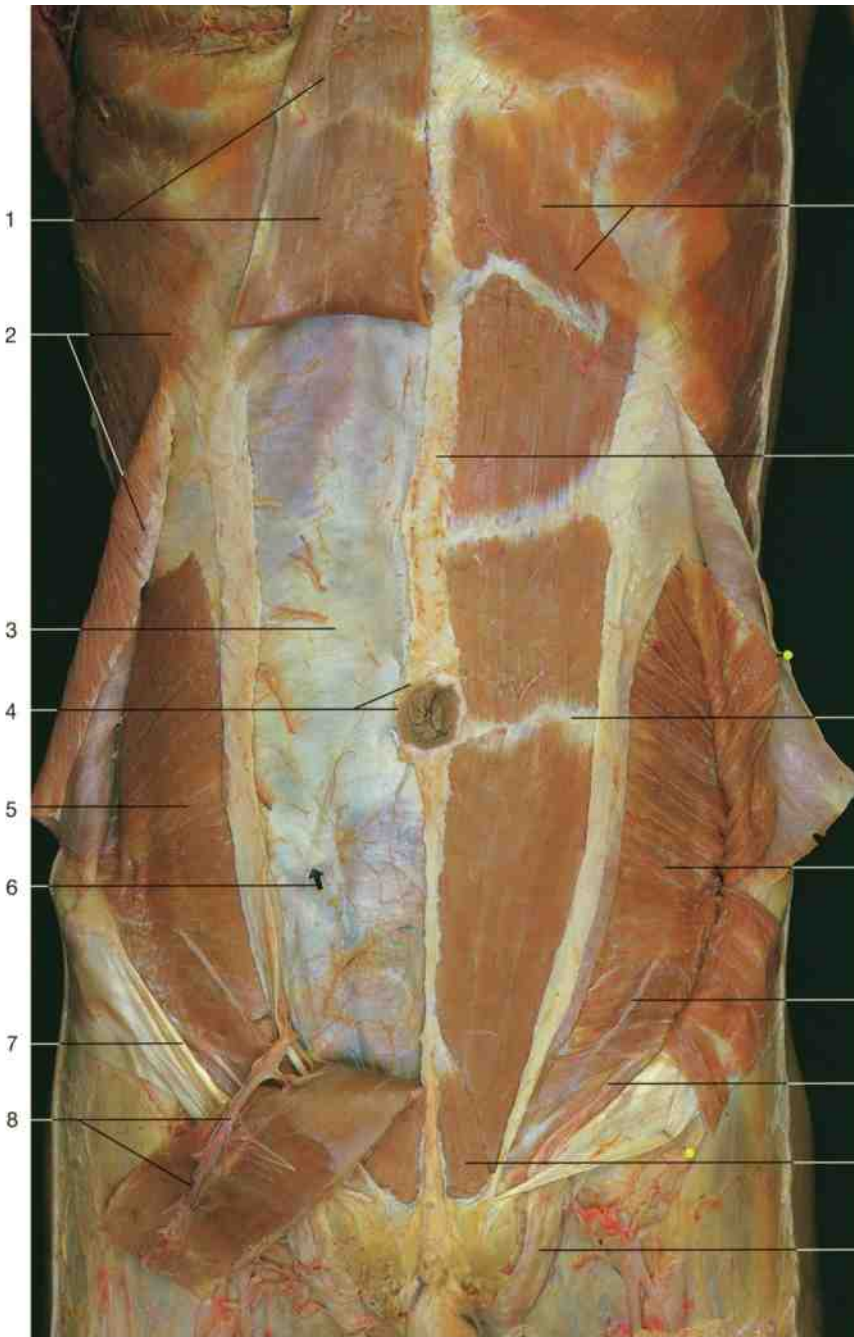
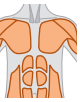
Thoracic and abdominal walls.

External abdominal oblique muscle has been divided and reflected on both sides. The right rectus muscle has been reflected medially to display the posterior layer of rectus sheath. Arrow: location of arcuate line.



- 1 Anterior layer of rectus sheath
- 2 Rectus abdominis muscle
- 3 Posterior layer of rectus sheath
- 4 Transversalis fascia
- 5 Transversus abdominis muscle
- 6 Internal oblique muscle
- 7 External oblique muscle
- 8 Thoracolumbar fascia with superficial and deep layer
- 9 Lateral column of erector spinae muscle
- 10 Medial column of intrinsic muscles of the back

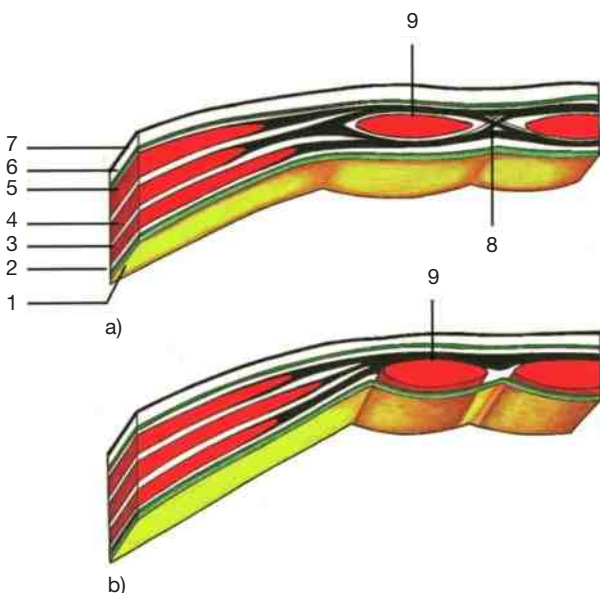
Horizontal section of the trunk superior to arcuate line (schematic drawing).



- 1 Rectus abdominis muscle (reflected)
- 2 External abdominal oblique muscle (divided)
- 3 Posterior layer of rectus sheath
- 4 Umbilical ring
- 5 Internal abdominal oblique muscle
- 6 Arcuate line (arrow)
- 7 Inguinal ligament
- 8 Inferior epigastric artery and vein and rectus abdominis muscle (divided and reflected)
- 9 Costal margin
- 10 Linea alba
- 11 Tendinous intersection
- 12 Iliohypogastric nerve
- 13 Ilio-inguinal nerve
- 14 Pyramidal muscle
- 15 Spermatic cord

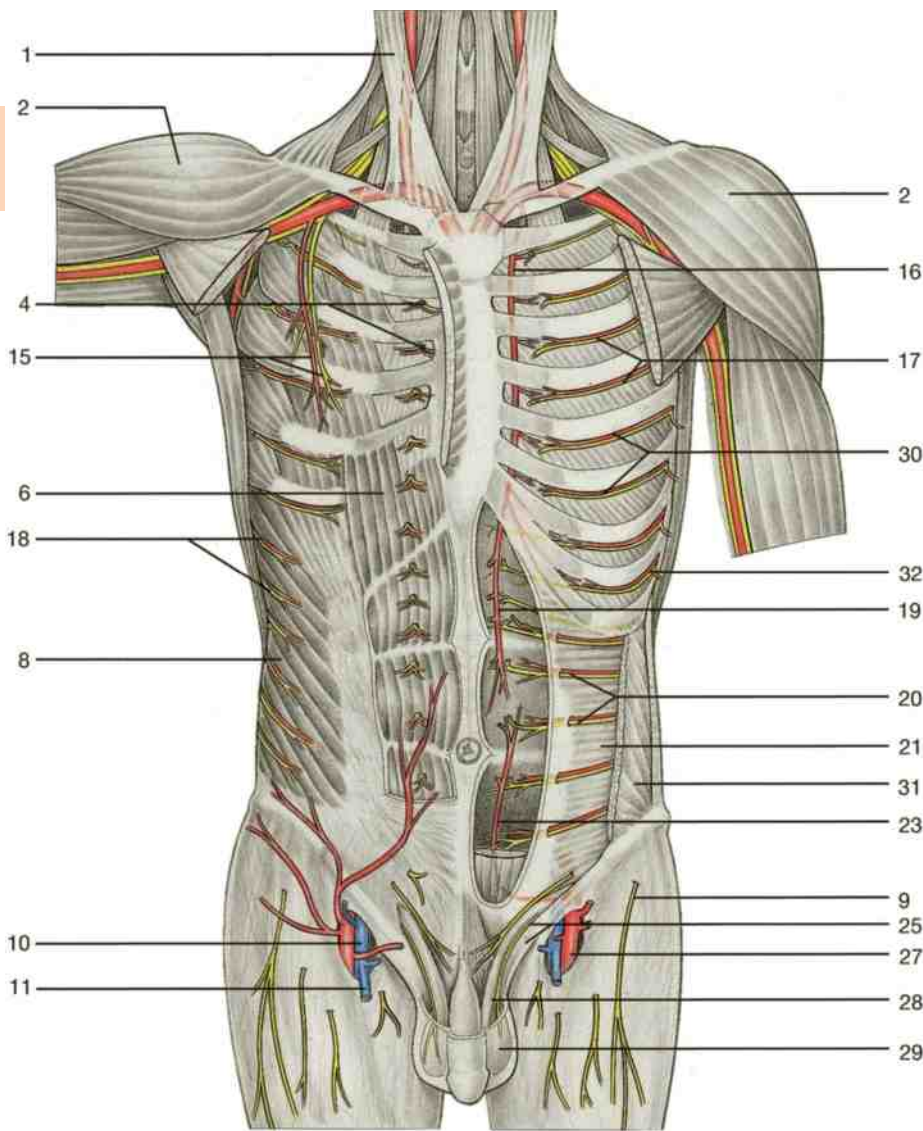
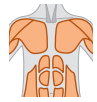
Thoracic and abdominal walls.

External abdominal oblique muscle has been divided and reflected on both sides. The right rectus muscle has been cut and reflected to display the posterior layer of rectus sheath. Arrow: location of arcuate line.



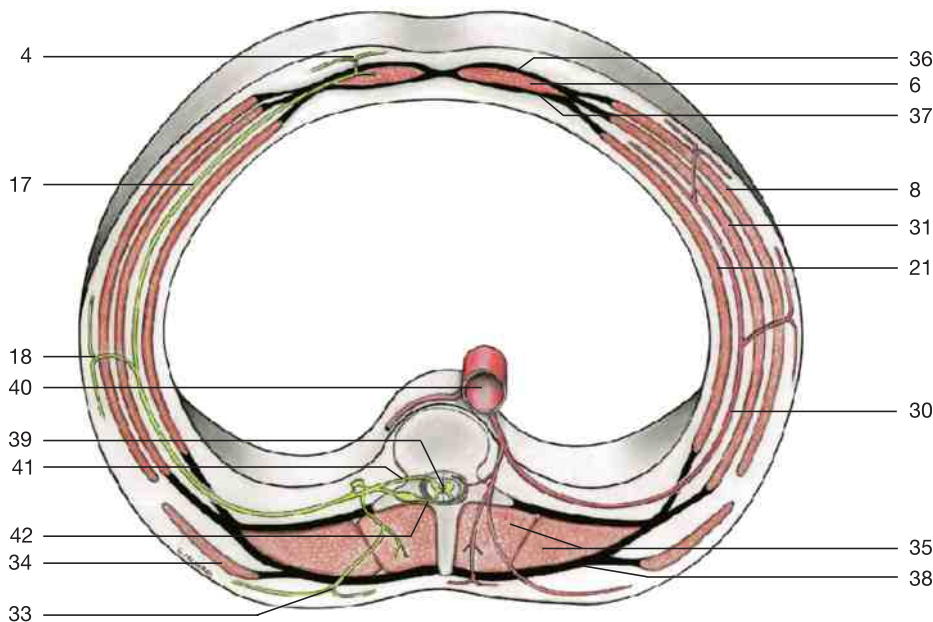
- 1 Peritoneum
- 2 Transversalis fascia (green)
- 3 Transversus abdominis muscle
- 4 Internal abdominal oblique muscle
- 5 External abdominal oblique muscle
- 6 Fascia of external abdominal oblique muscle (green)
- 7 Skin
- 8 Linea alba
- 9 Rectus abdominis muscle

Transverse sections through the abdominal wall superior (a) and inferior (b) to arcuate line.

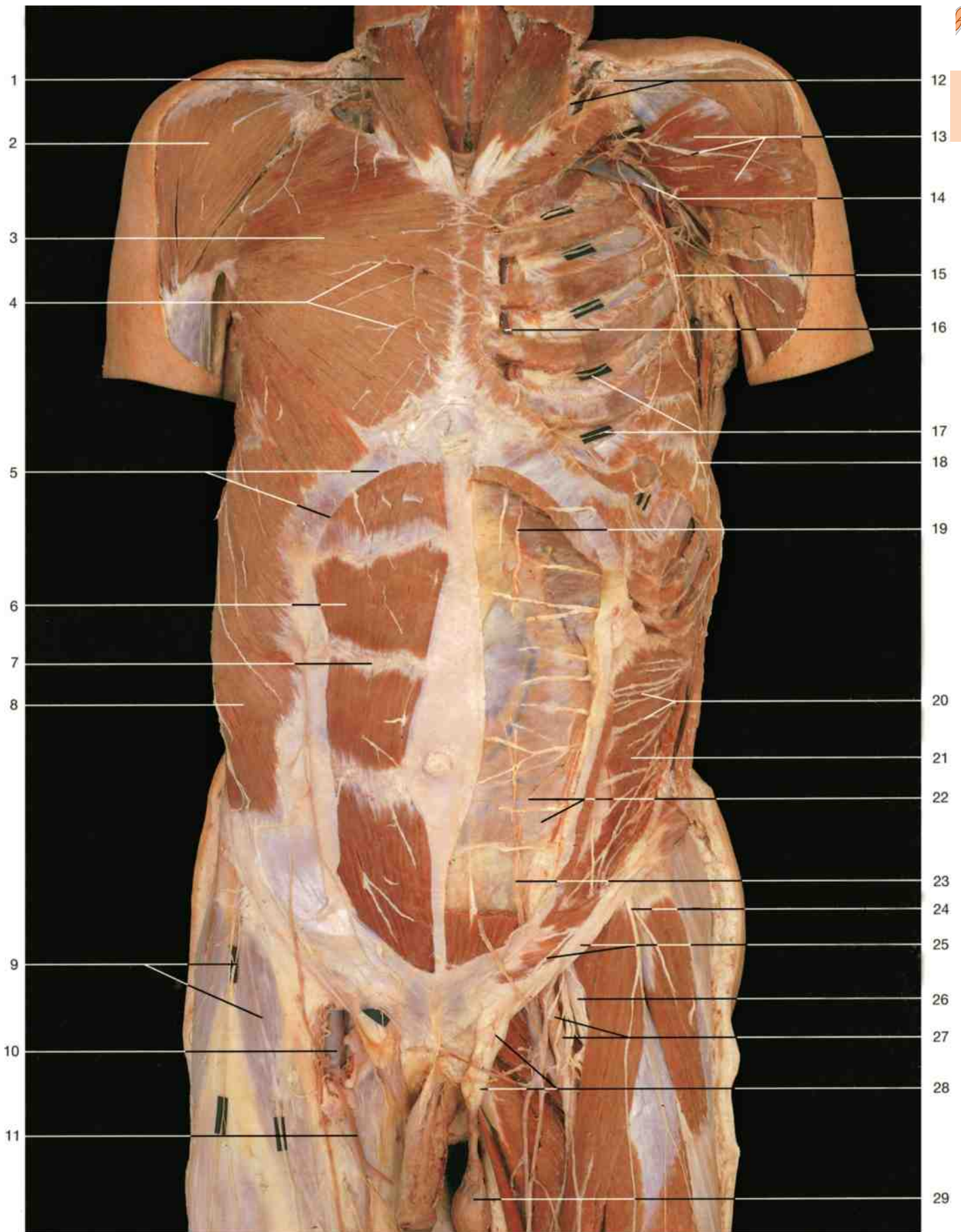
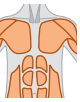


- 1 Sternocleidomastoid muscle
- 2 Deltoid muscle
- 3 Pectoralis major muscle
- 4 Anterior cutaneous branches of intercostal nerves
- 5 Cut edge of anterior layer of rectus sheath
- 6 Rectus abdominis muscle
- 7 Tendinous intersection
- 8 External abdominal oblique muscle
- 9 Lateral femoral cutaneous nerve
- 10 Femoral vein
- 11 Great saphenous vein
- 12 Medial supraclavicular nerves
- 13 Pectoralis minor muscle (reflected) and medial pectoral nerves
- 14 Axillary vein
- 15 Long thoracic nerve and lateral thoracic artery
- 16 Internal thoracic artery
- 17 Intercostal nerves
- 18 Lateral cutaneous branches of intercostal nerves
- 19 Superior epigastric artery
- 20 Thoraco-abdominal (intercostal) nerves
- 21 Transversus abdominis muscle
- 22 Posterior layer of rectus sheath
- 23 Inferior epigastric artery
- 24 Lateral femoral cutaneous nerve
- 25 Inguinal ligament and ilio-inguinal nerve
- 26 Femoral nerve
- 27 Femoral artery
- 28 Spermatic cord
- 29 Testis
- 30 Posterior intercostal arteries
- 31 Internal abdominal oblique muscle
- 32 Lateral cutaneous branch of intercostal nerve
- 33 Dorsal branch of spinal nerve
- 34 Latissimus dorsi muscle
- 35 Deep muscles of the back (medial and lateral tract)
- 36 Anterior layer of rectus sheath
- 37 Posterior layer of rectus sheath
- 38 Thoracolumbar fascia
- 39 Spinal cord
- 40 Aorta
- 41 Ventral root } of spinal nerve
- 42 Dorsal root }

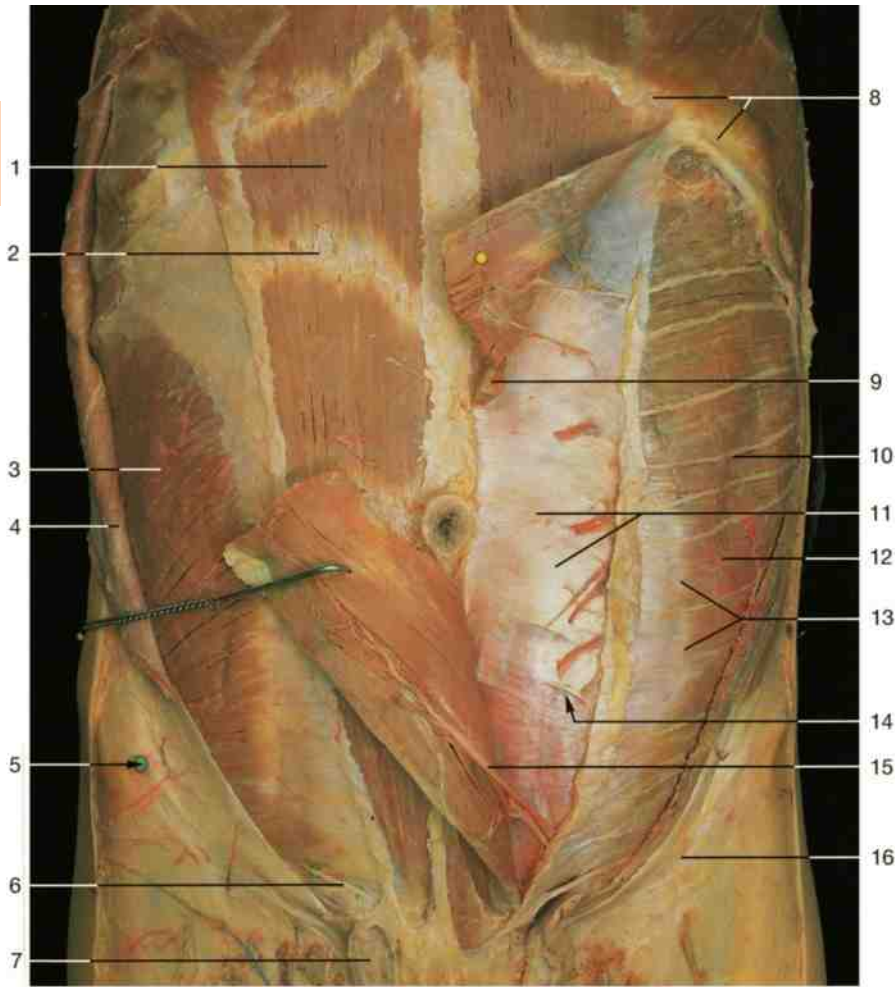
Thoracic and abdominal walls (schematic drawing). Note the segmental organization of the blood vessels and nerves. Right side: superficial layers; left side: deeper layers.



Horizontal section of the abdominal wall (from below) showing the location of the intercostal arteries (left side) and nerves (right side).

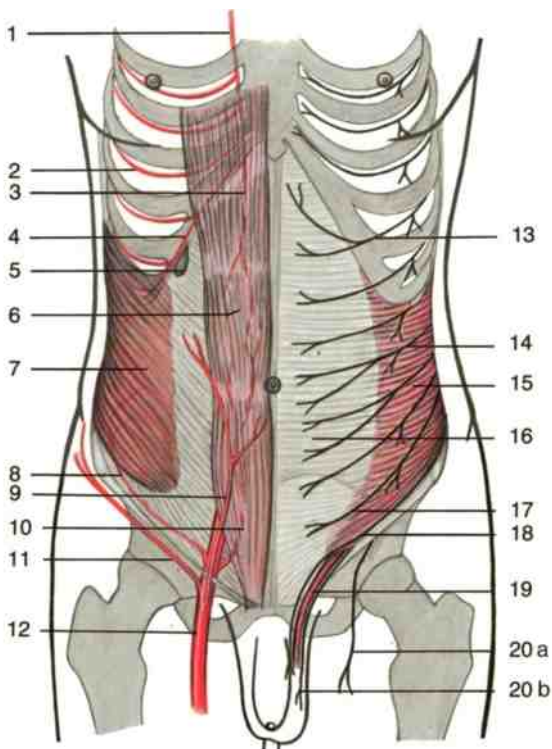


Thoracic and abdominal walls with vessels and nerves (anterior aspect). Right side: superficial layers; left side: deeper layers. Pectoralis major and minor muscles, the external and internal intercostal muscles on the left side have been removed to display the intercostal nerves. The anterior layer of rectus sheath, the left rectus abdominis muscle, and the external and internal abdominal oblique muscles have been removed to show the thoraco-abdominal nerves within the abdominal wall.



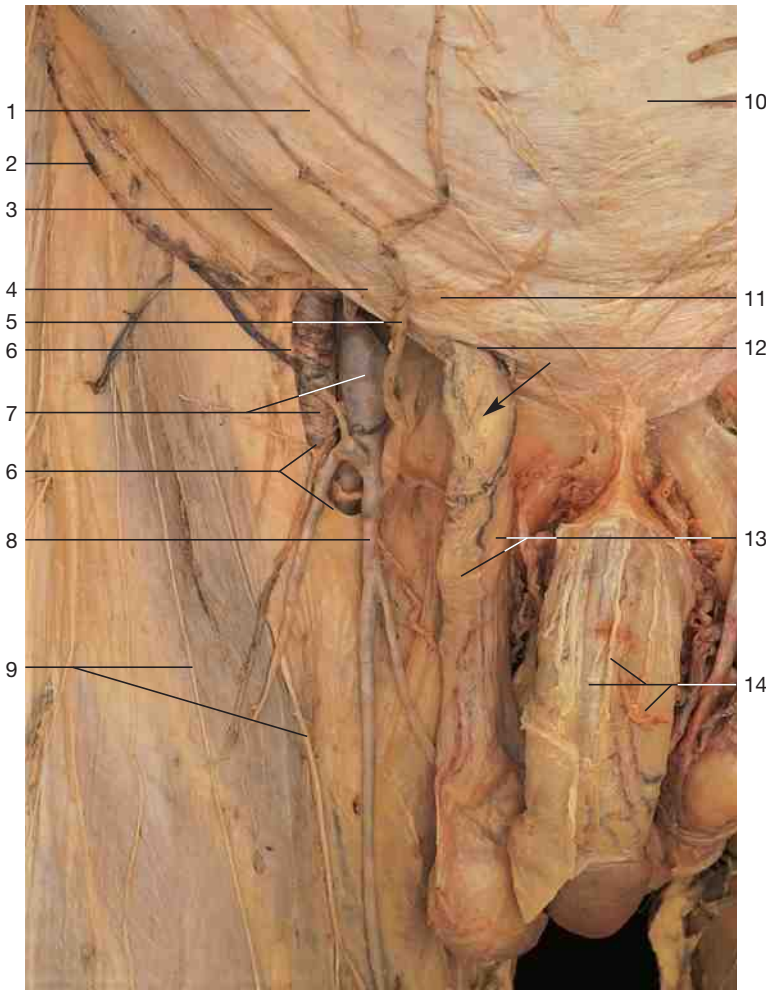
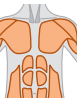
- 1 Rectus abdominis muscle
- 2 Tendinous intersection
- 3 Internal abdominal oblique muscle
- 4 External abdominal oblique muscle (reflected)
- 5 Anterior superior iliac spine
- 6 Ilio-inguinal nerve
- 7 Spermatic cord
- 8 Costal margin
- 9 Superior epigastric artery
- 10 Thoraco-abdominal (intercostal) nerves
- 11 Posterior layer of rectus sheath
- 12 Transversus abdominis muscle
- 13 Semilunar line
- 14 Arcuate line
- 15 Inferior epigastric artery
- 16 Inguinal ligament

Abdominal wall with vessels and nerves. The left rectus abdominis muscle has been divided and reflected to display the inferior epigastric vessels. The left internal abdominal oblique muscle has been removed to show the thoraco-abdominal nerves.



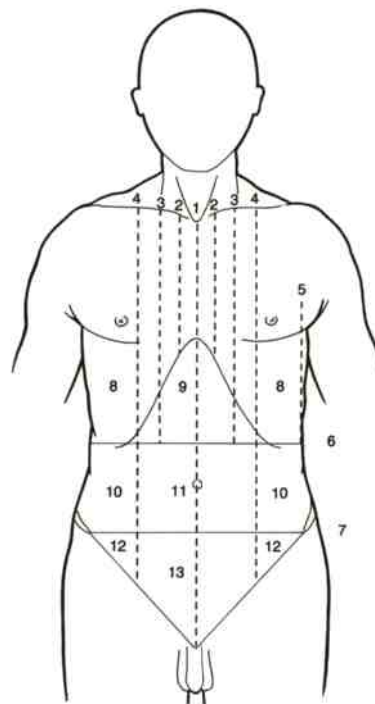
- 1 Internal thoracic artery
- 2 Intercostal artery
- 3 Superior epigastric artery
- 4 Musculophrenic artery
- 5 Gallbladder
- 6 Rectus abdominis muscle
- 7 External abdominal oblique muscle
- 8 Deep circumflex iliac artery
- 9 Superficial epigastric artery
- 10 Inferior epigastric artery
- 11 Superficial circumflex iliac artery
- 12 Femoral artery
- 13 Intercostal nerve
- 14 Thoraco-abdominal nerve (T₁₀)
- 15 Transversus abdominis muscle
- 16 Posterior layer of the rectus sheath
- 17 Iliohypogastric nerve (L₁)
- 18 Ilio-inguinal nerve (L₁)
- 19 Spermatic cord
- 20 Genitofemoral nerve (L₁, L₂)
 - a Femoral branch
 - b Genital branch

Arteries and nerves that supply the thoracic and abdominal walls. Note their segmental arrangement (schematic drawing).



- 1 Aponeurosis of external abdominal oblique muscle
- 2 Superficial circumflex iliac vein
- 3 Inguinal ligament
- 4 Lateral crus of inguinal ring
- 5 Superficial epigastric vein
- 6 Saphenous opening
- 7 Femoral artery and vein
- 8 Great saphenous vein
- 9 Anterior cutaneous branches of femoral nerve
- 10 Anterior layer of rectus sheath
- 11 Intercrural fibers
- 12 Superficial inguinal ring
- 13 Spermatic cord and genital branch of genitofemoral nerve
- 14 Penis with dorsal nerves and deep dorsal vein of penis

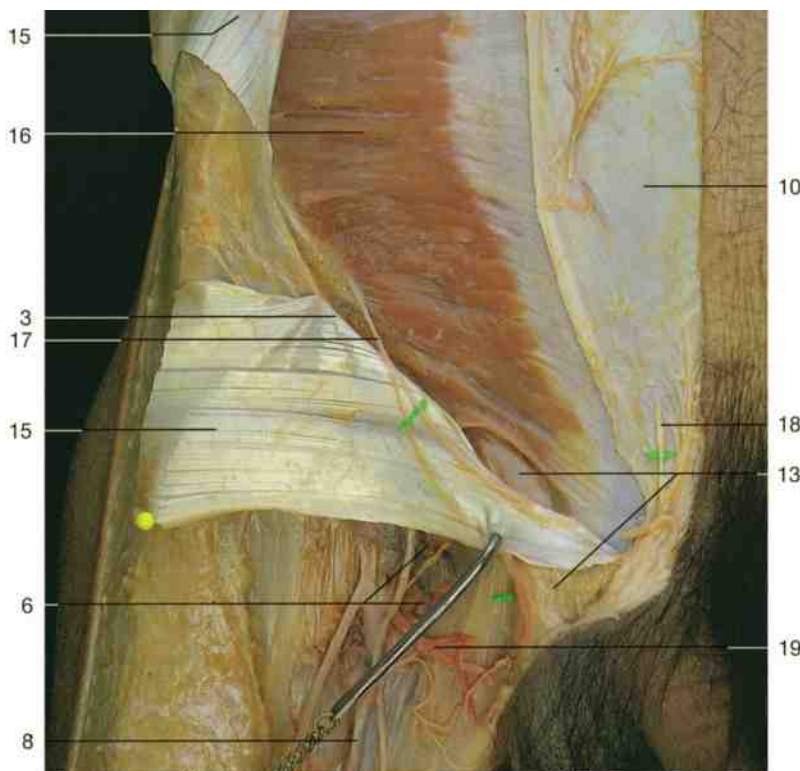
Inguinal canal in the male, right side (superficial layer, anterior aspect). There is a small inguinal hernia (arrow).



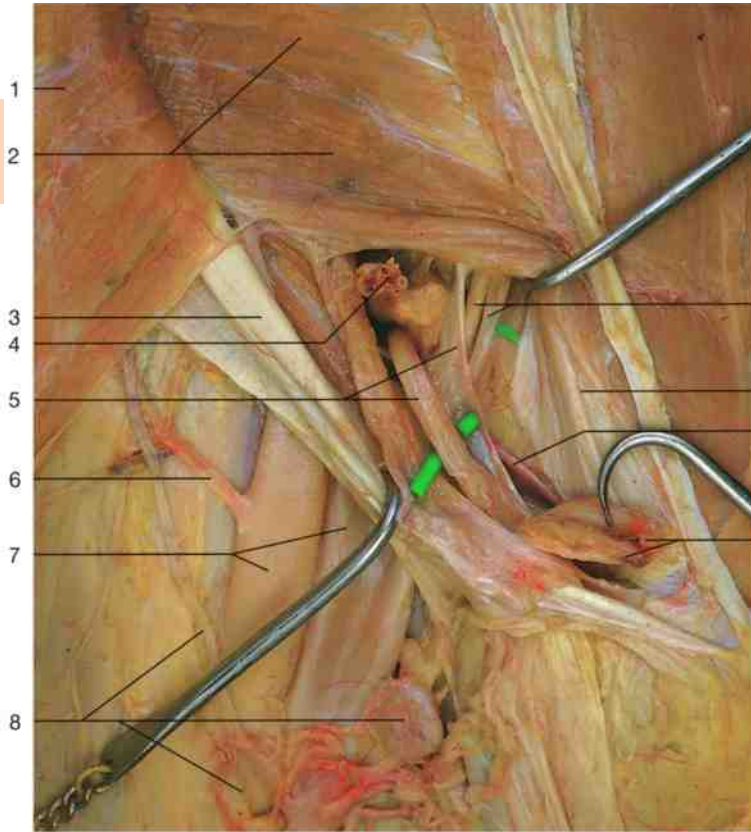
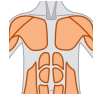
Regions and reference lines

for delineating surface projections.

- 1 Median line
- 2 Lateral sternal line
- 3 Parasternal line
- 4 Midclavicular line
- 5 Axillary line
- 6 Transpyloric plane
- 7 Transtuberular plane
- 8 Hypochondriac region
- 9 Epigastric region
- 10 Lumbar region
- 11 Umbilical region
- 12 Iliac region
- 13 Hypogastric region

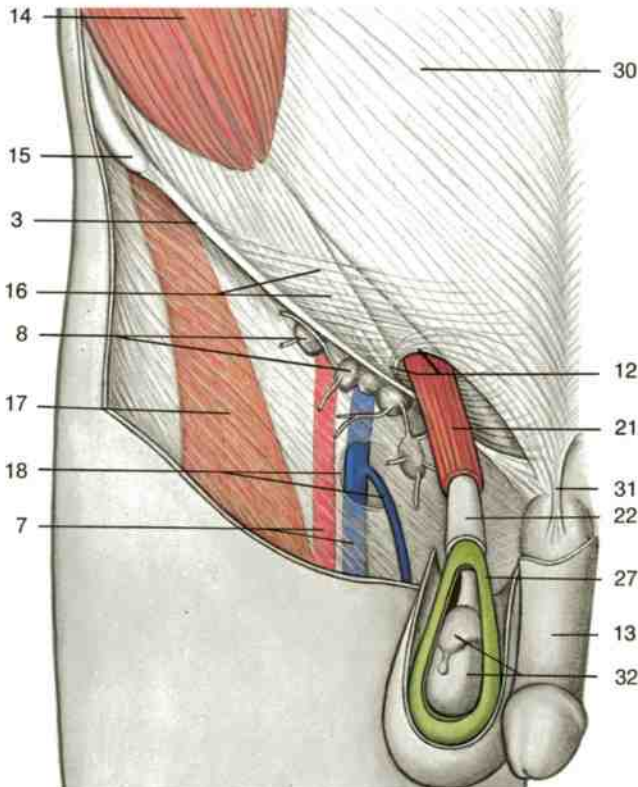


Inguinal canal in the male, right side (anterior aspect). The external abdominal oblique muscle has been divided to display the inguinal canal.



Inguinal canal in the male, right side (deep layer, anterior aspect). Spermatic cord with exception of ductus deferens (probe) has been divided and reflected.

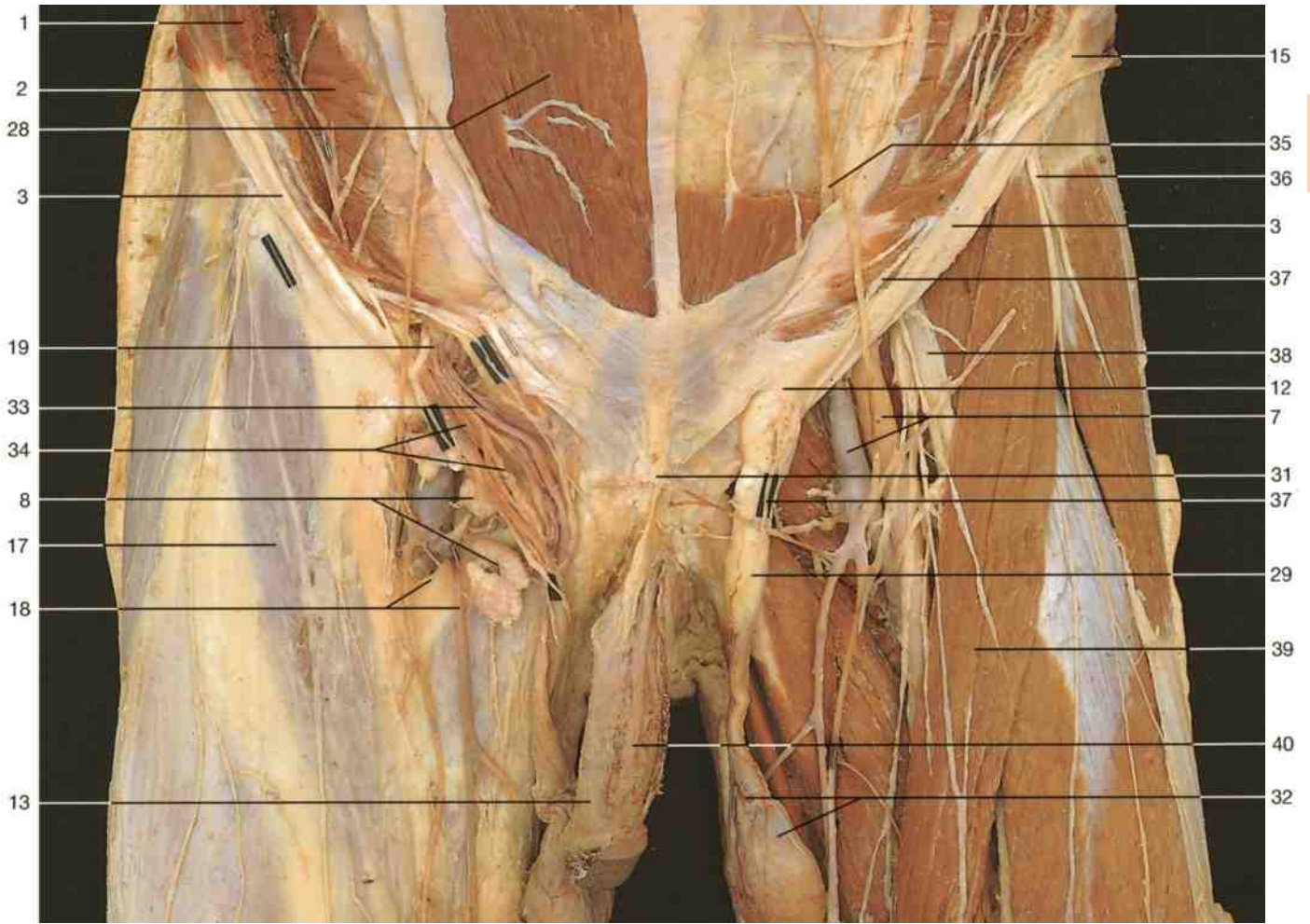
- 1 Internal abdominal oblique muscle (reflected)
- 2 Transversus abdominis muscle
- 3 Inguinal ligament
- 4 Spermatic cord with the exception of the ductus deferens (divided and reflected)
- 5 Ductus deferens and interfoveolar ligament
- 6 Superficial circumflex iliac artery
- 7 Femoral artery and vein
- 8 Superficial inguinal lymph nodes and inguinal lymph vessel
- 9 Inferior epigastric artery and vein
- 10 Falx inguinalis or conjoint tendon (cut)
- 11 Pubic branch of inferior epigastric artery
- 12 Superficial inguinal ring
- 13 Penis
- 14 External abdominal oblique muscle
- 15 Anterior superior iliac spine
- 16 Intercrural fibers
- 17 Fascia lata and sartorius muscle
- 18 Saphenous opening and great saphenous vein
- 19 Deep inguinal ring
- 20 Skin of scrotum and dartos muscle
- 21 Cremaster muscle
- 22 Internal spermatic fascia
- 23 Ductus deferens
- 24 Epididymis
- 25 Peritoneum (blue)
- 26 Remnant of processus vaginalis
- 27 Tunica vaginalis testis
- 28 Rectus abdominis muscle
- 29 Spermatic cord with ductus deferens covered by external spermatic fascia
- 30 Anterior layer of rectus sheath
- 31 Suspensory ligament of penis
- 32 Testis and epididymis
- 33 Ductus deferens
- 34 Pampiniform venous plexus and testicular artery
- 35 Inferior epigastric artery
- 36 Lateral femoral cutaneous nerve
- 37 Ilio-inguinal nerve
- 38 Femoral nerve
- 39 Sartorius muscle
- 40 Deep dorsal vein of penis



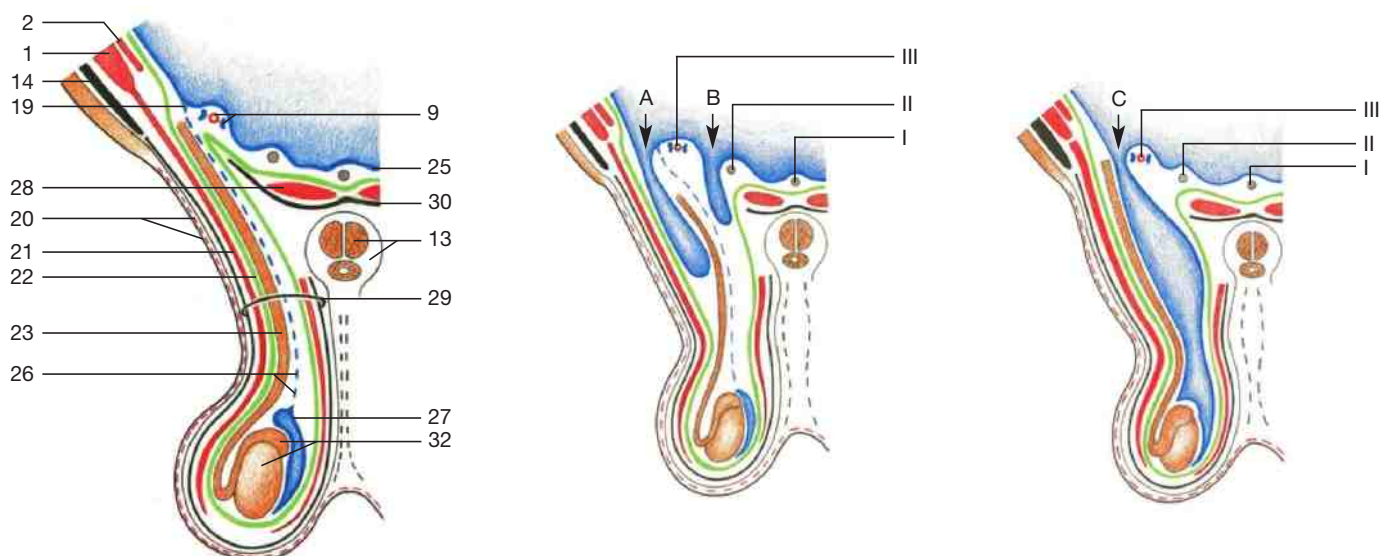
General characteristics of lower part of anterior abdominal wall and inguinal canal (schematic drawing).

Inguinal hernias may either pass through the inguinal canal lateral to the inferior epigastric artery (indirect or lateral inguinal hernias, A and C) or directly penetrate the abdominal wall through the inguinal triangle located medial to the inferior epigastric artery (direct or medial inguinal hernias, B). The lateral hernias can be congenital if the vaginal process remains open (C) or acquired (A) if the hernia develops independently of a patent processus vaginalis.

Femoral hernias generally protrude through the femoral ring below the inguinal ligament. Proper assessment of the site of herniation requires the identification of both the inguinal ligament and the epigastric artery.



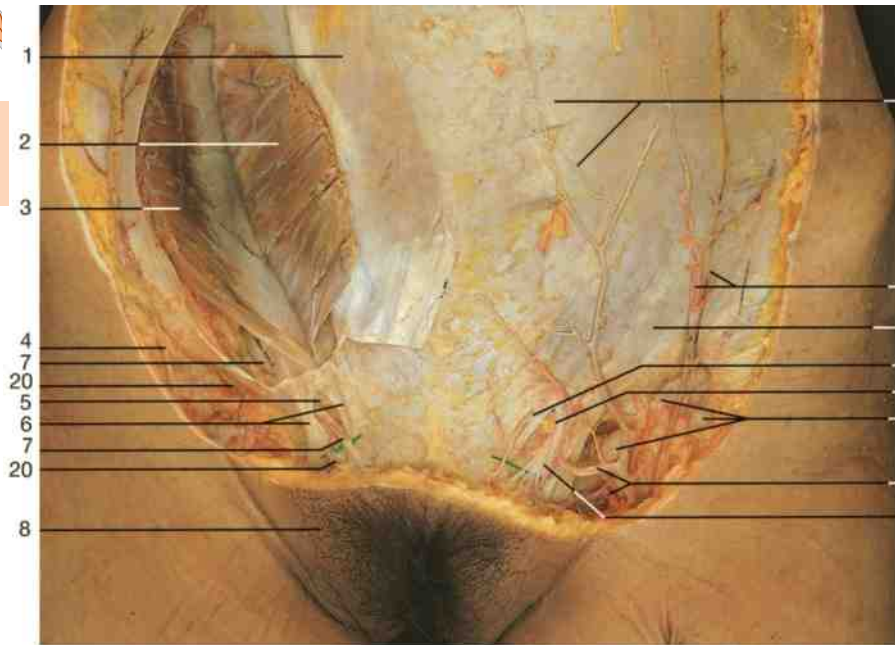
Inguinal and femoral regions in the male (anterior aspect). On the right, the spermatic cord was dissected to display the ductus deferens and the accompanying vessels and nerves. The fascia lata on the left side has been removed.



Layers of spermatic cord and types of hernias. Left: normal situation. Middle: location of acquired inguinal hernias:

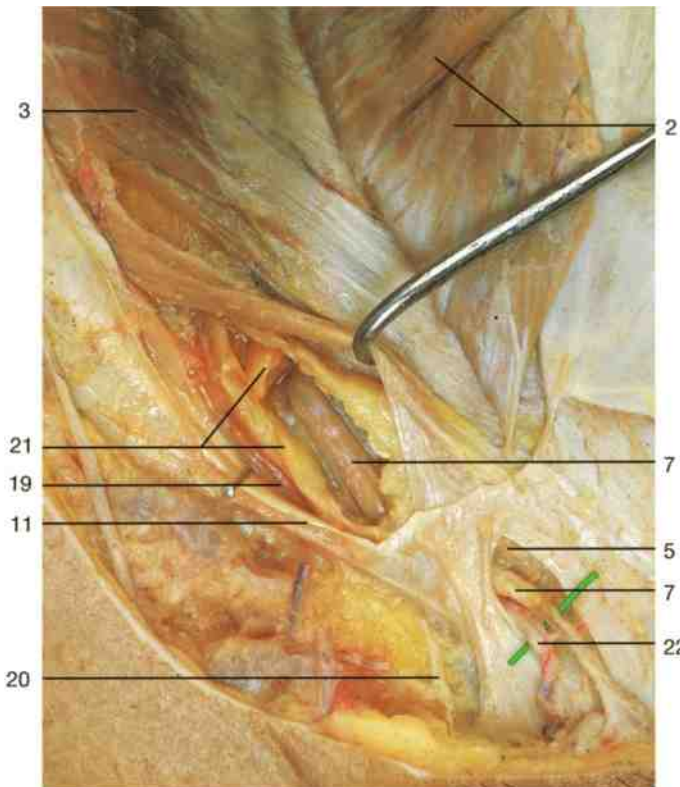
A = indirect; B = direct inguinal hernia. Right: congenital indirect inguinal hernia (C); the vaginal process remained open.

- I = median umbilical fold containing urachus chord.
- II = medial umbilical fold with remnants of umbilical artery.
- III = lateral umbilical fold with inferior epigastric artery and vein.

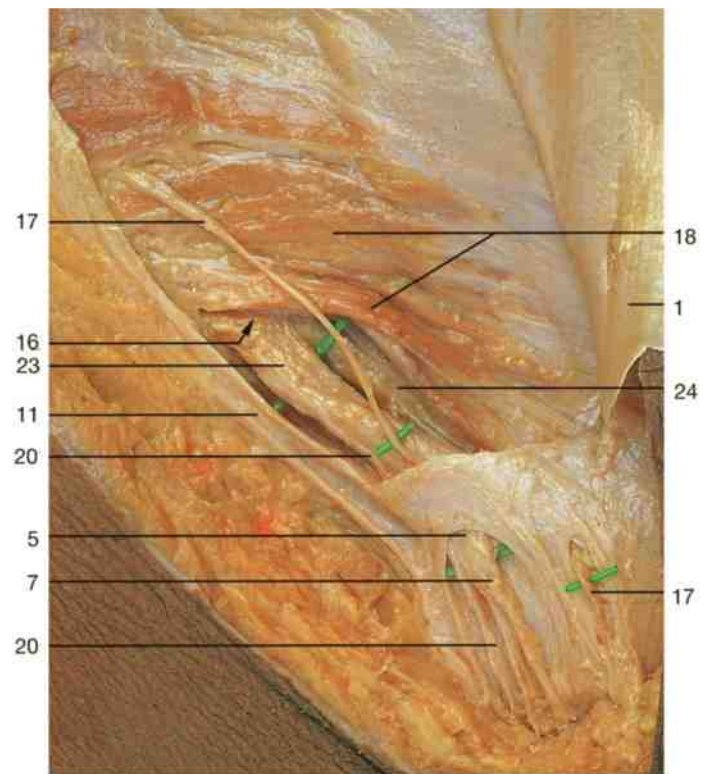


- 1 Aponeurosis of external abdominal oblique muscle
- 2 Internal abdominal oblique muscle (divided and reflected)
- 3 Transversus abdominis muscle
- 4 Superficial circumflex iliac artery and vein
- 5 Superficial inguinal ring with fat pad
- 6 Medial and lateral crural fibers
- 7 Round ligament (ligamentum teres uteri)
- 8 Labium majus pudendi
- 9 Anterior layer of rectus sheath
- 10 Superficial epigastric artery and vein
- 11 Inguinal ligament
- 12 Cutaneous branch of ilio-inguinal nerve
- 13 Superficial inguinal lymph nodes
- 14 Entrance of round ligament into the labium majus
- 15 External pudendal artery and vein
- 16 Position of deep inguinal ring
- 17 Ilio-inguinal nerve
- 18 Internal abdominal oblique muscle
- 19 Pubic branch of inferior epigastric artery
- 20 Genital branch of genitofemoral nerve
- 21 Fat pad of inguinal canal
- 22 Ilio-inguinal nerve
- 23 Sheath of round ligament (inguinal canal)
- 24 Transversalis fascia

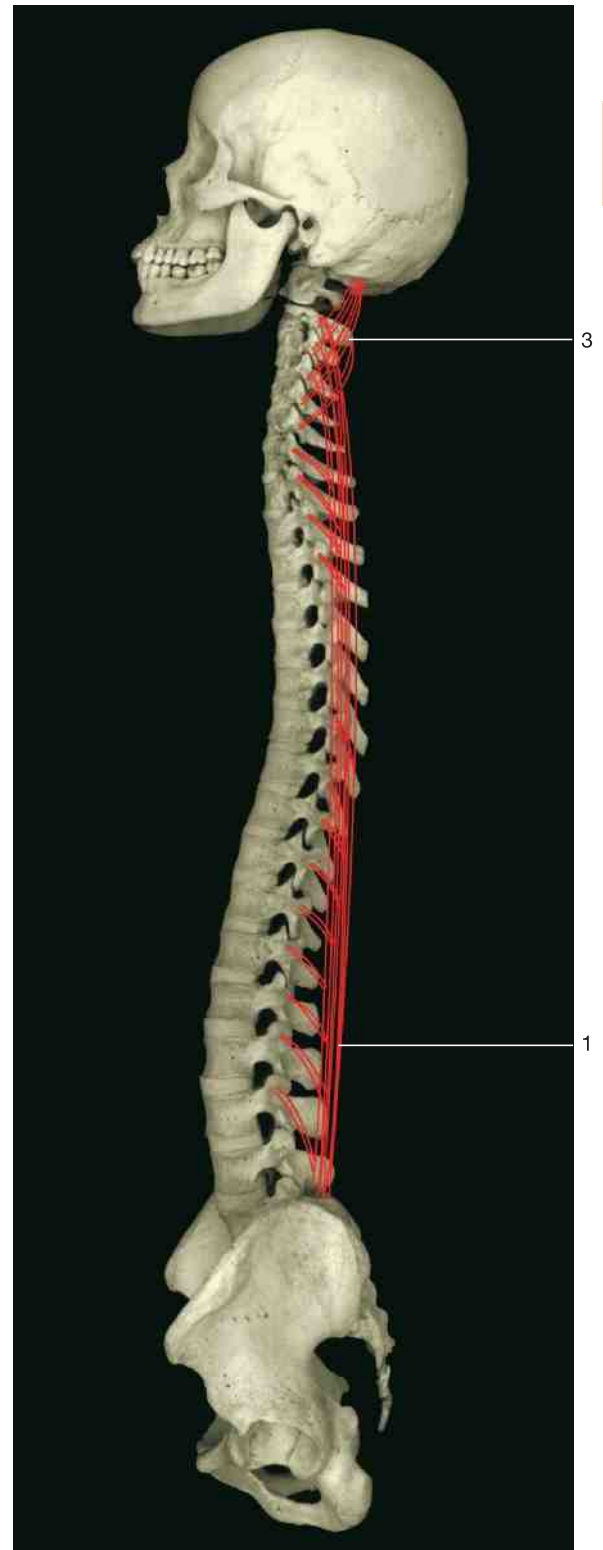
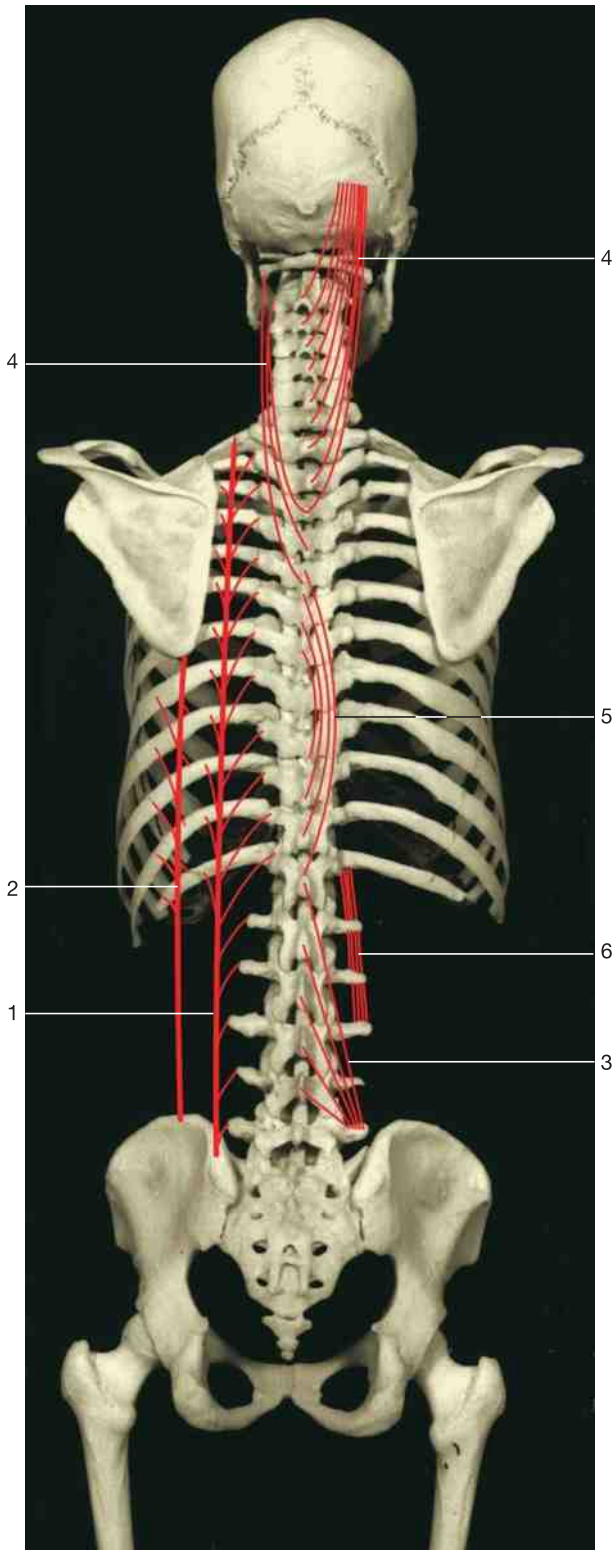
Inguinal region in the female (anterior aspect). Left side: superficial layer; right side: external and internal abdominal oblique muscle divided and reflected.



Inguinal canal of the female (anterior aspect, right side). The external abdominal oblique muscle has been divided and reflected, to display the ilio-inguinal nerve and the round ligament.



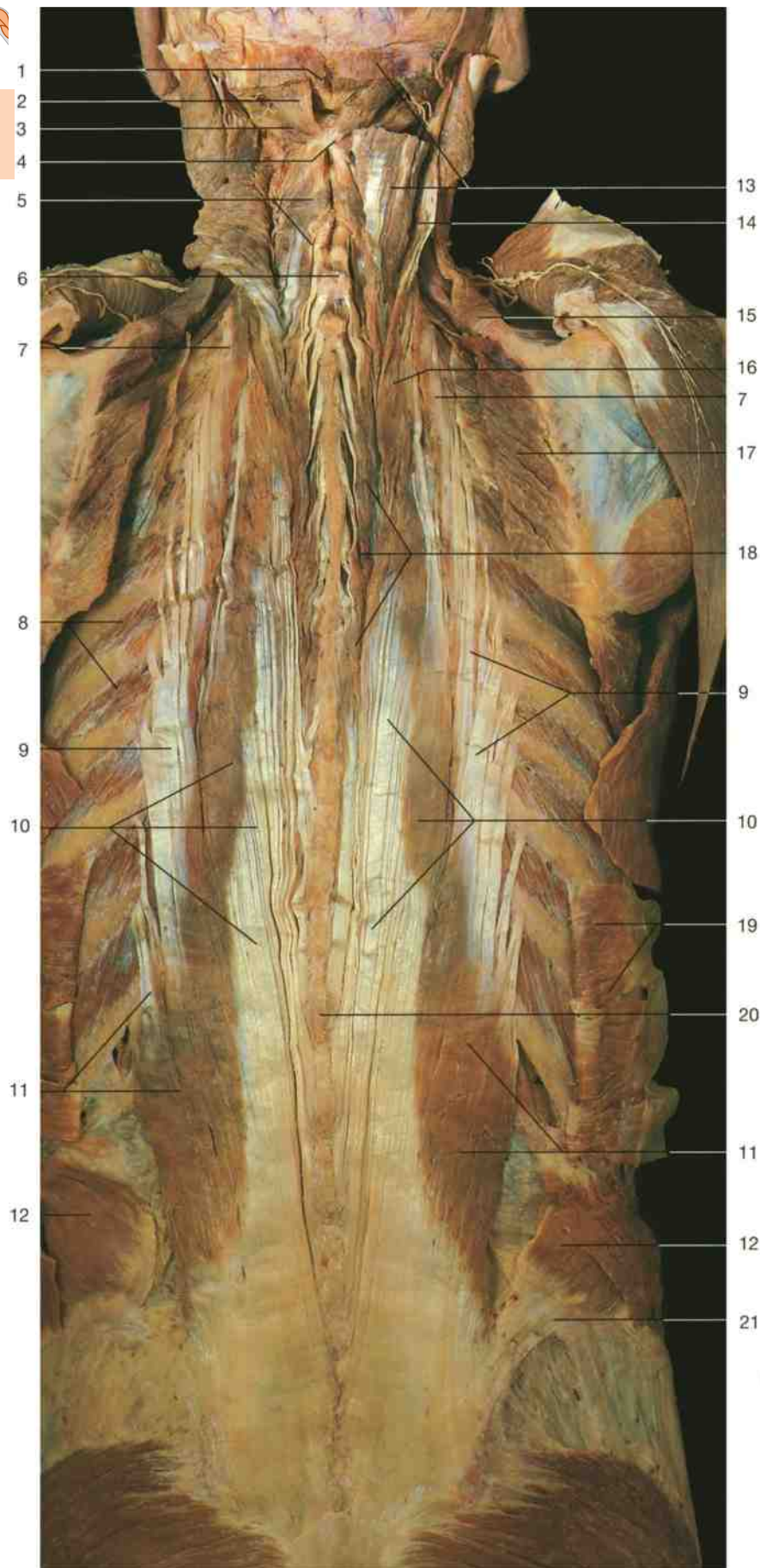
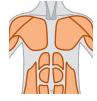
Inguinal canal of the female (anterior aspect, right side). The external and internal abdominal oblique muscle have been divided and reflected to show the content of the inguinal canal.



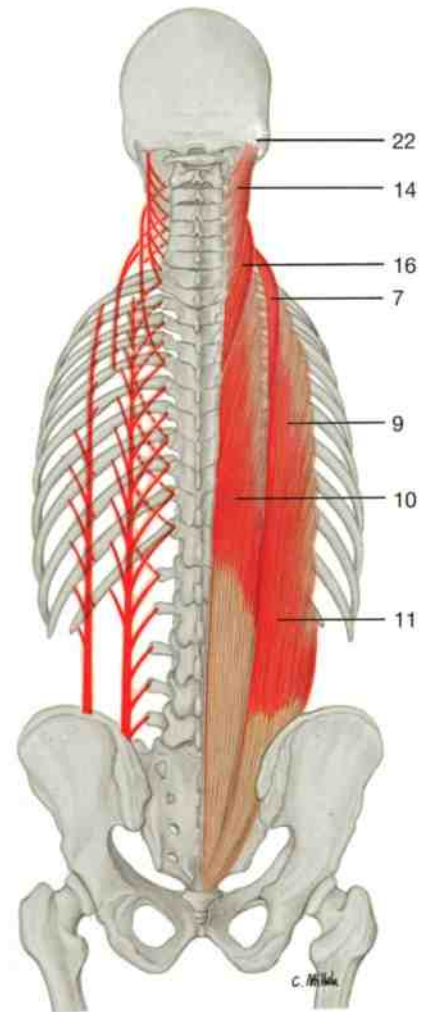
Skeleton of the trunk (dorsal and lateral aspect).

The long muscles of the back [longissimus (1) and iliocostalis (2) muscles] originate at the sacrum and pelvis and insert at the spinous or transverse processes of the vertebrae or at the ribs. There are also muscles that insert at the occipital bone.

The long muscles form the lateral tract, whereas muscles of the medial tract are situated within the groove between the spinous and transverse processes of the vertebrae [transversospinal (3) and spinotransversal (4) muscles] or between the spinous processes [spinalis muscles (5)] or between the transverse processes [intertransversarii muscles (6)] of the vertebrae.

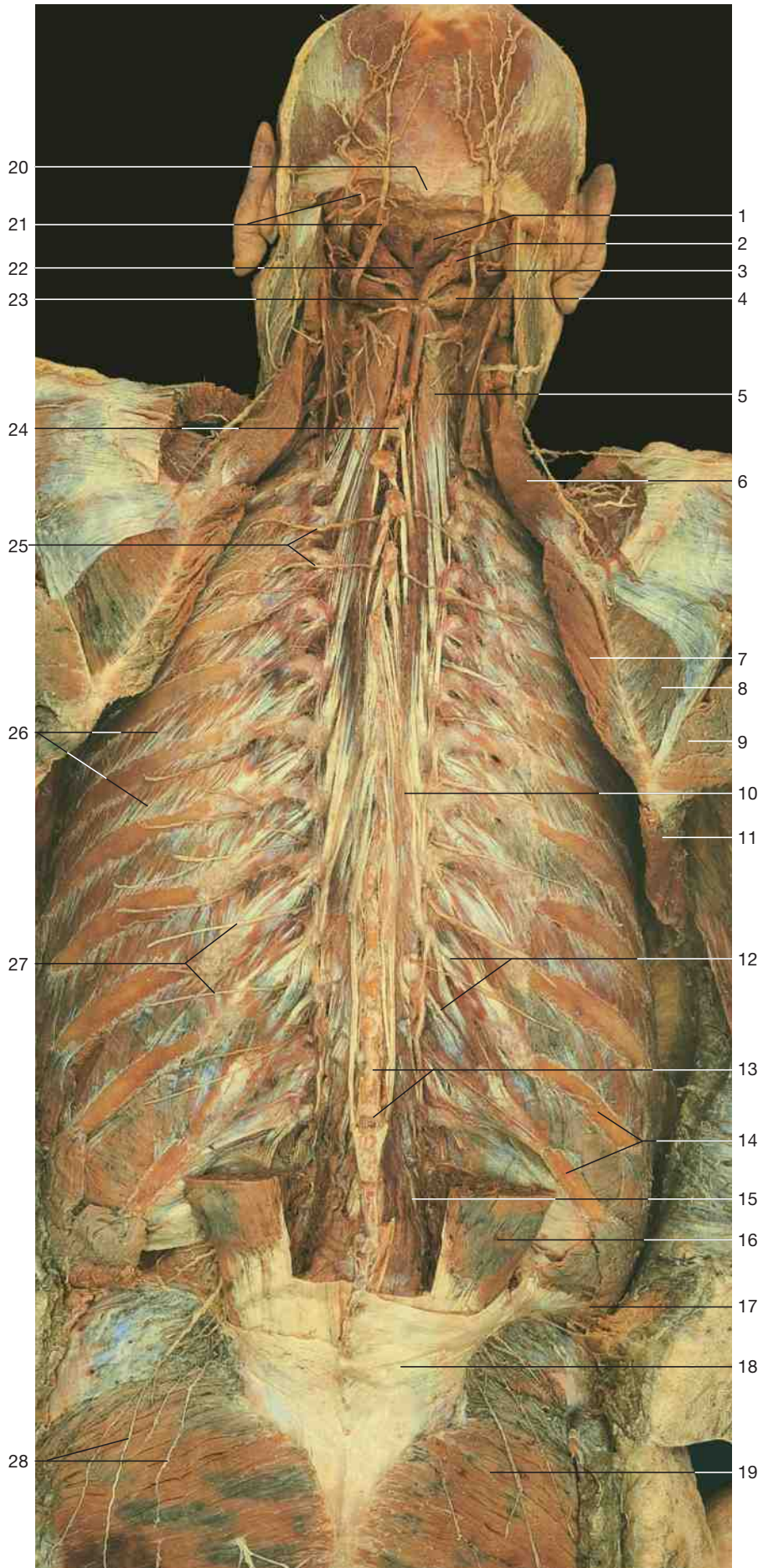
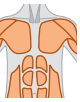


Muscles of the back. Dissection of the erector spinae muscle (lateral column of the intrinsic back muscles).



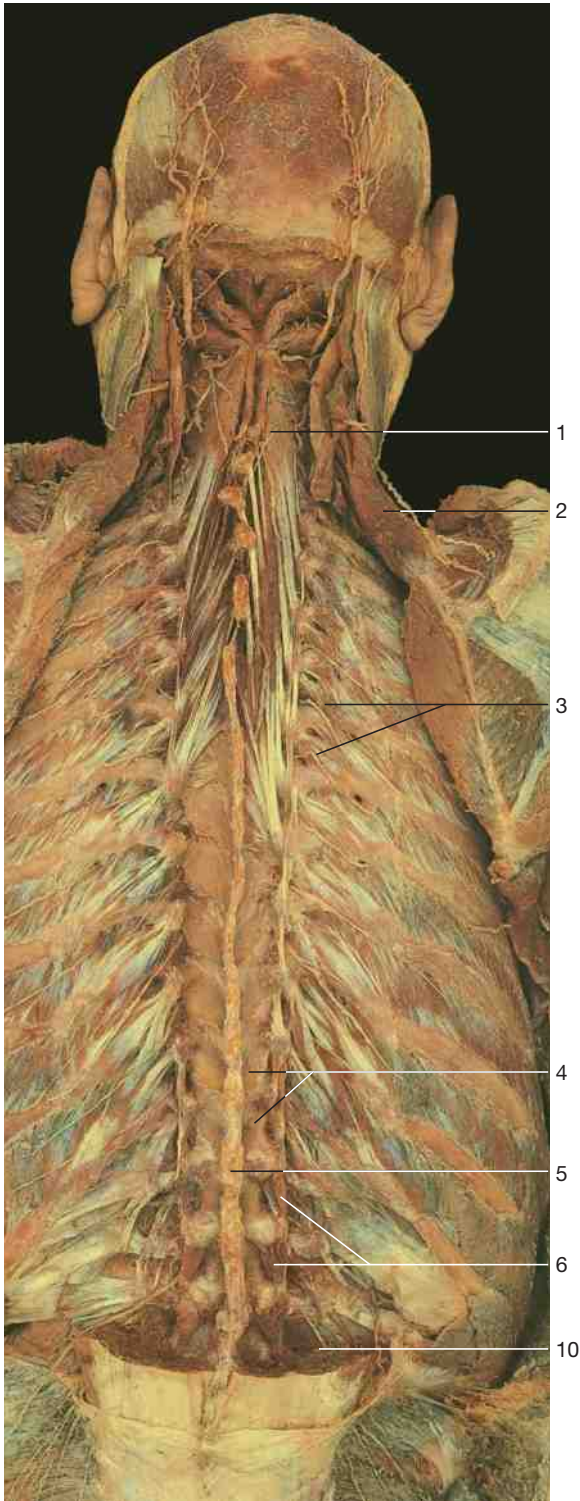
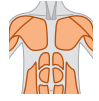
Origin and insertion of iliocostalis and longissimus muscles (schematic drawing).

- 1 Rectus capitis posterior minor muscle
- 2 Rectus capitis posterior major muscle
- 3 Obliquus capitis inferior muscle
- 4 Spinous process of axis
- 5 Semispinalis cervicis muscle
- 6 Spinous process of seventh vertebra
- 7 Iliocostalis cervicis muscle
- 8 External intercostal muscles
- 9 Iliocostalis thoracis muscle
- 10 Longissimus thoracis muscle
- 11 Iliocostalis lumborum muscle
- 12 Internal abdominal oblique muscle
- 13 Semispinalis capitis muscle (divided)
- 14 Longissimus capitis muscle
- 15 Levator scapulae muscle
- 16 Longissimus cervicis muscle
- 17 Rhomboid major muscle
- 18 Spinalis thoracis muscle
- 19 Serratus posterior inferior muscle (reflected)
- 20 Spinous process of second lumbar vertebra
- 21 Iliac crest
- 22 Mastoid process

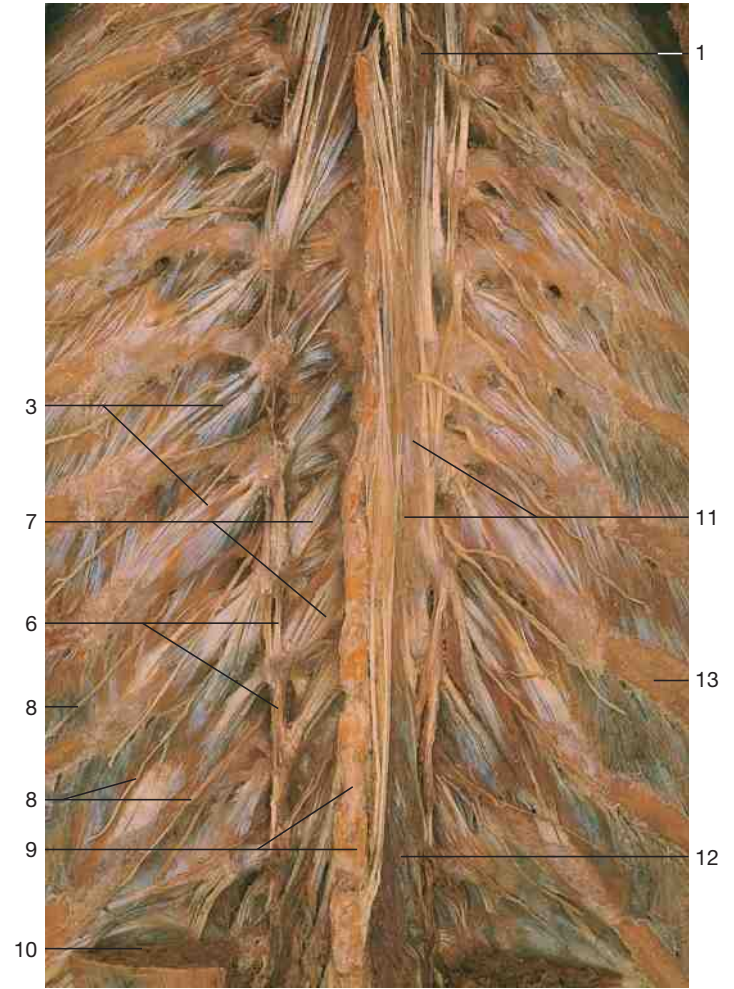


- 1 Rectus capitis posterior minor muscle
- 2 Rectus capitis posterior major muscle
- 3 Obliquus capitis superior muscle
- 4 Obliquus capitis inferior muscle
- 5 Semispinalis cervicis muscle
- 6 Levator scapulae muscle
- 7 Rhomboideus major muscle
- 8 Scapula with infraspinatus muscle
- 9 Teres major muscle
- 10 Spinalis muscle
- 11 Latissimus dorsi muscle
- 12 Levatores costarum muscles
- 13 Spinous processes of lumbar vertebrae
- 14 Ribs (Th₁₁, Th₁₂)
- 15 Multifidus muscle
- 16 Longissimus and iliocostalis muscles (cut)
- 17 Iliac crest (lumbar triangle)
- 18 Thoracolumbar fascia
- 19 Gluteus maximus muscle
- 20 Protuberantia occipitalis externa
- 21 Occipital artery and greater occipital nerve (C₂)
- 22 Posterior tubercle of atlas
- 23 Spinous process of axis
- 24 Spinous process of seventh cervical vertebra (vertebra prominens)
- 25 Medial branches of dorsal branches of spinal nerves
- 26 External intercostal muscles
- 27 Lateral branches of dorsal branches of spinal nerves
- 28 Superior cluneal nerves

Muscles of the back. Dissection of the deeper layer of the intrinsic muscles of the back (longissimus and iliocostalis muscles are cut).

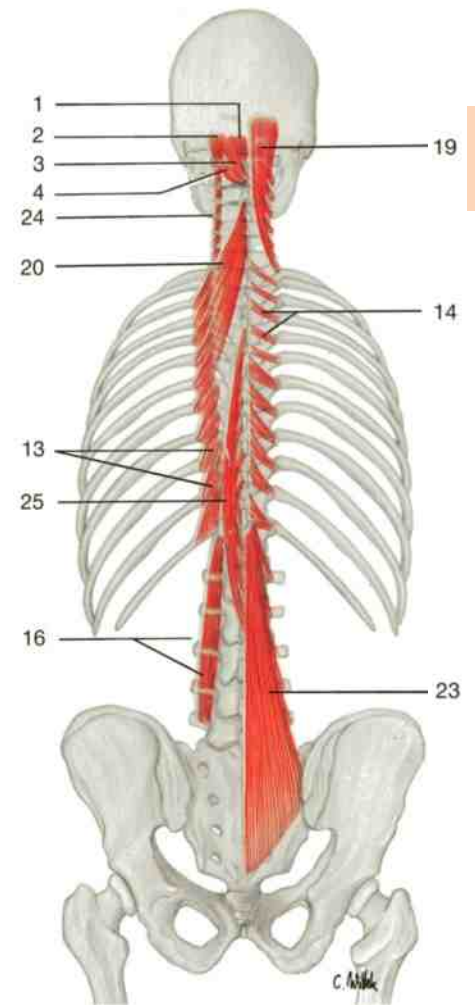
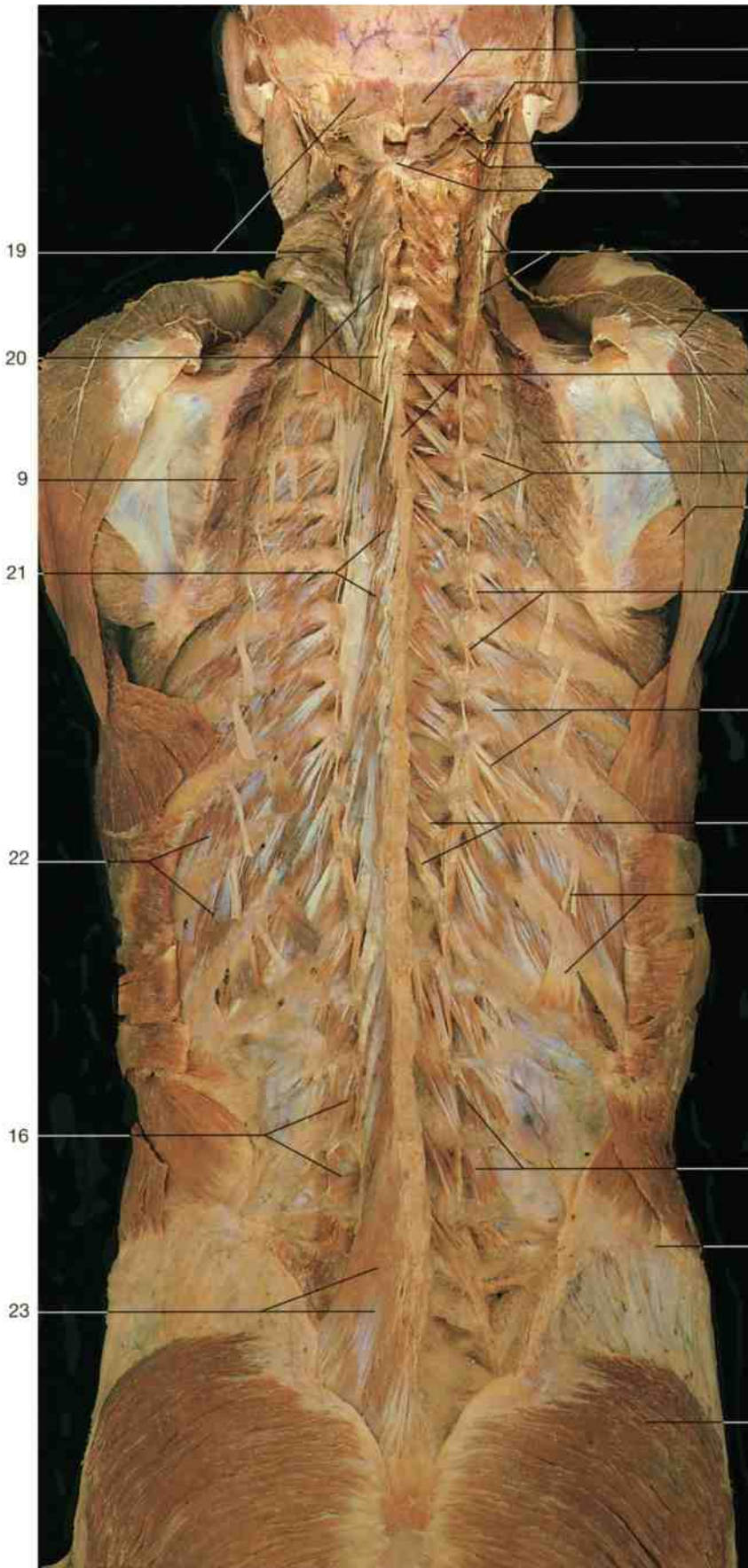


Muscles of the back. Deepest layer.



Muscles of the back. Deepest layer. Lumbar region (higher magnification).

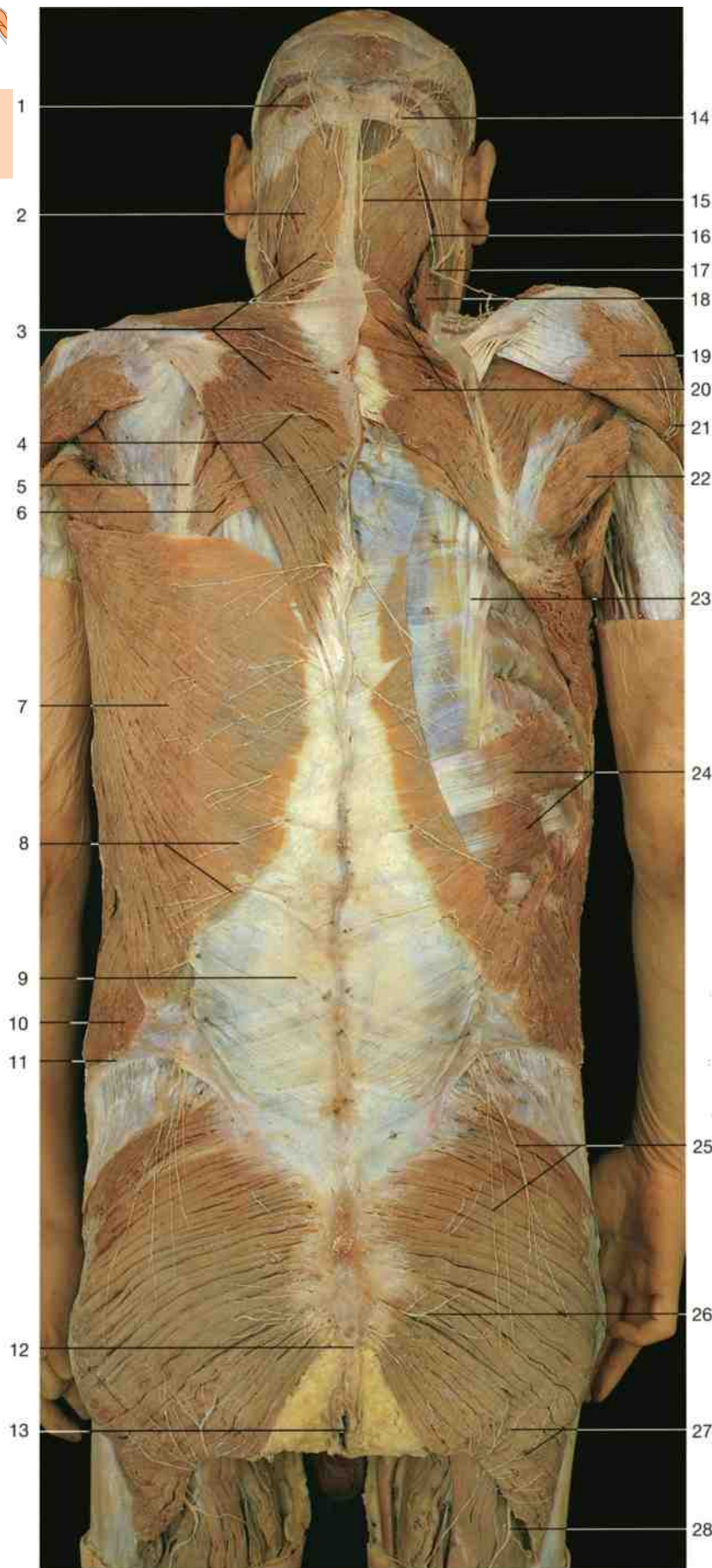
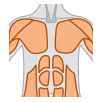
- 1 Semispinalis cervicis muscle
- 2 Levator scapulae muscle
- 3 Levatores costarum muscles
- 4 Vertebral arches of lumbar vertebrae
- 5 Supraspinal ligaments
- 6 Intertransverse lumbar muscles
- 7 Lumbar rotator muscles
- 8 Cutaneous branches of spinal nerves
- 9 Lumbar interspinal muscles
- 10 Longissimus and iliocostalis muscle (cut)
- 11 Spinal muscle of the back
- 12 Multifidus muscle
- 13 Tenth rib (T_{10})



Medial column of intrinsic muscles of the back. Transversospinal and intertransversal system (schematic drawing).

Muscles of the back. Transversospinal muscles, deepest layer on the right, where all parts of semispinalis and multifidus muscles have been removed.

- 1 Rectus capitis posterior minor muscle
- 2 Obliquus capitis superior muscle
- 3 Rectus capitis posterior major muscle
- 4 Obliquus capitis inferior muscle
- 5 Spinous process of axis
- 6 Longissimus capitis muscle
- 7 Trapezius muscle (reflected) and accessory nerve (n. XI)
- 8 Spinous processes
- 9 Rhomboid major muscle
- 10 Transverse processes of thoracic vertebrae
- 11 Teres major muscle
- 12 Intertransverse ligaments
- 13 Levatores costarum muscles
- 14 Rotatores muscles
- 15 Tendons of iliocostalis muscle
- 16 Intertransversarii lumborum muscles (lateral)
- 17 Iliac crest
- 18 Gluteus maximus muscle
- 19 Semispinalis capitis muscle
- 20 Semispinalis cervicis muscle
- 21 Semispinalis thoracis muscle
- 22 External intercostal muscles
- 23 Multifidus muscle
- 24 Posterior cervical intertransversarii muscles
- 25 Spinalis thoracis muscle

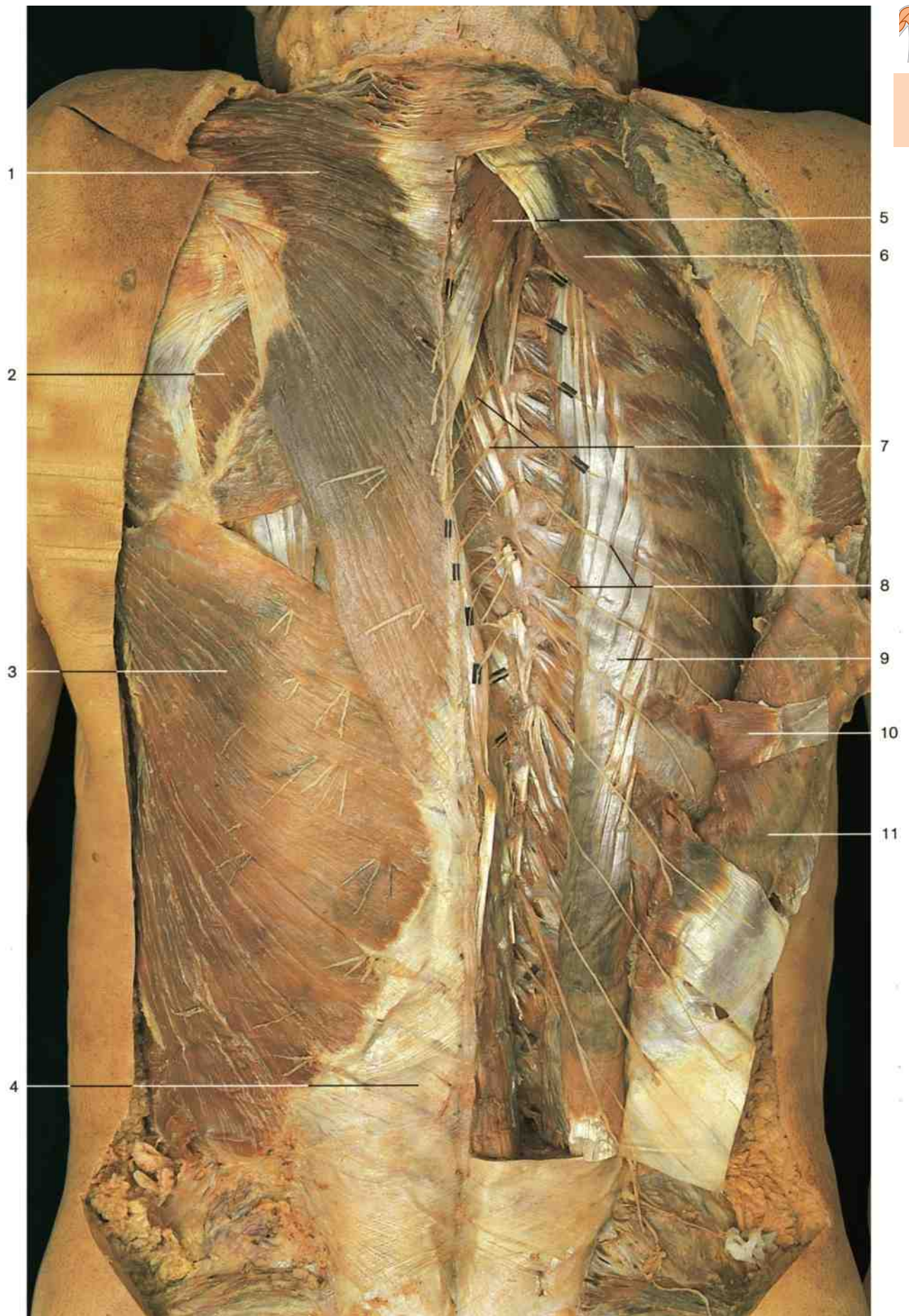
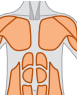


- 1 Occipital belly of occipitofrontalis muscle
- 2 Splenius capitis muscle
- 3 Trapezius muscle
- 4 Medial cutaneous branches of dorsal rami of spinal nerves
- 5 Medial margin of scapula
- 6 Rhomboid major muscle
- 7 Latissimus dorsi muscle
- 8 Lateral cutaneous branches of dorsal rami of spinal nerves
- 9 Thoracolumbar fascia
- 10 External abdominal oblique muscle
- 11 Iliac crest
- 12 Last coccygeal vertebra
- 13 Anus
- 14 Greater occipital nerve
- 15 Third occipital nerve
- 16 Lesser occipital nerve
- 17 Cutaneous branches of cervical plexus
- 18 Levator scapulae muscle
- 19 Deltoid muscle
- 20 Rhomboid major and minor muscles
- 21 Upper lateral cutaneous nerve of arm (branch of axillary nerve)
- 22 Teres major muscle
- 23 Iliocostalis thoracis muscle
- 24 Serratus posterior inferior muscle
- 25 Superior cluneal nerves
- 26 Middle cluneal nerves
- 27 Inferior cluneal nerves
- 28 Posterior femoral cutaneous nerve

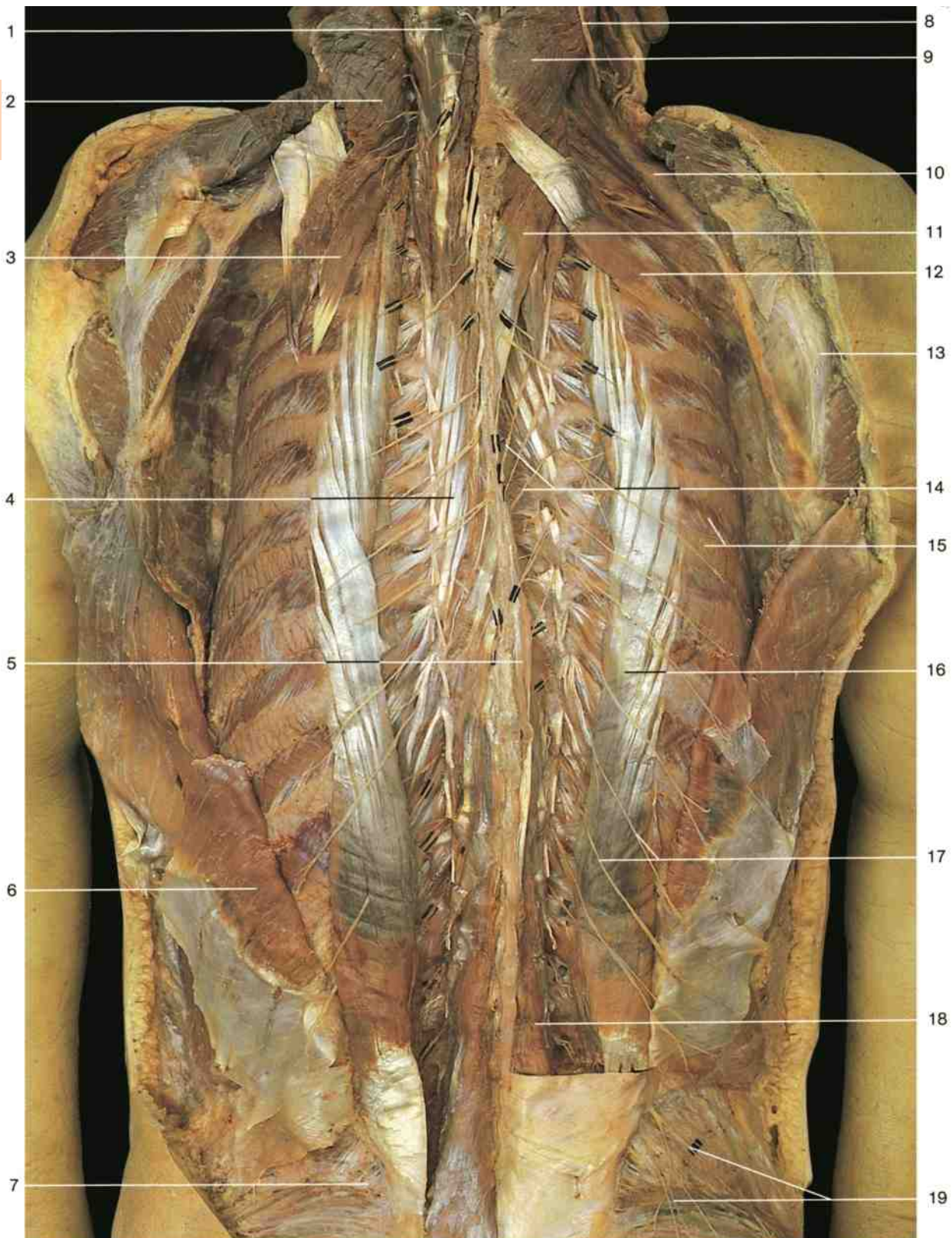
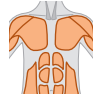
Innervation of the back. Superficial (left) and deeper (right) layers. Right trapezius and latissimus dorsi muscles removed.

▷ **To page 227:**

- 1 Trapezius muscle
- 2 Infrapinatus muscle
- 3 Left latissimus dorsi muscle
- 4 Thoracolumbar fascia
- 5 Splenius cervicis muscle
- 6 Serratus posterior superior muscle
- 7 Medial branches of dorsal rami of thoracic spinal nerves
- 8 Lateral branches of dorsal rami of thoracic spinal nerves
- 9 Iliocostalis muscle
- 10 Serratus posterior inferior muscle
- 11 Latissimus dorsi muscle (reflected)

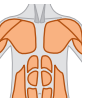

Innervation of the back. Dissection of the dorsal branches of spinal nerves. On the right, longissimus thoracis muscle has been removed and iliocostalis muscle laterally reflected.

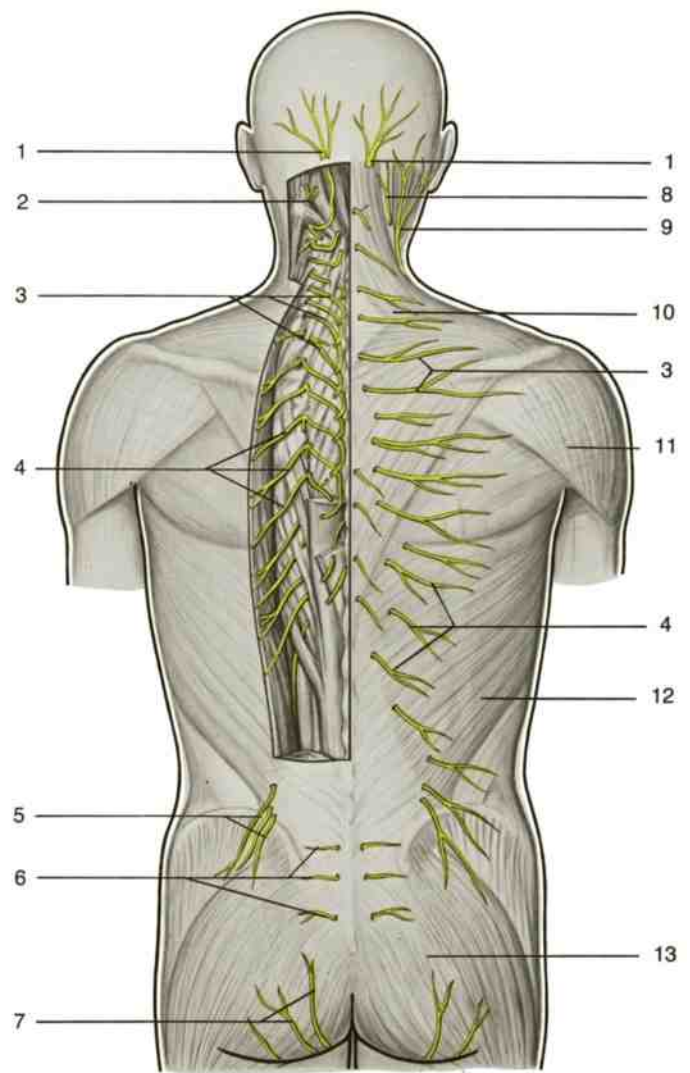


Innervation of the back. Deeper layer (dorsal aspect).

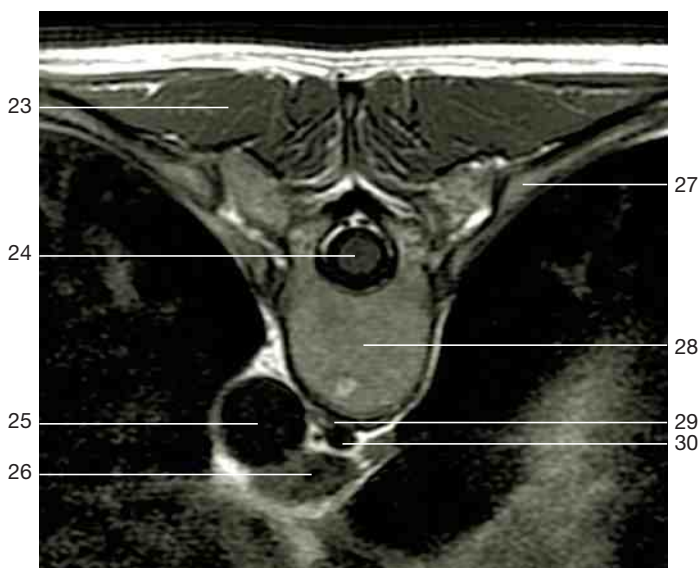
- | | | |
|---|---------------------------------------|---|
| 1 Semispinalis capitis muscle | 7 Iliac crest | 14 Medial branches of dorsal rami of spinal nerves |
| 2 Left splenius capitis muscle (cut and reflected) | 8 Lesser occipital nerve | 15 Rib and external intercostal muscle |
| 3 Left splenius cervicis muscle (cut and reflected) | 9 Splenius capitis muscle | 16 Iliocostalis thoracis muscle |
| 4 Semispinalis thoracis muscle | 10 Levator scapulae muscle | 17 Lateral branches of dorsal rami of spinal nerves |
| 5 Spinalis thoracis muscle | 11 Splenius cervicis muscle | 18 Multifidus muscle |
| 6 Latissimus dorsi muscle (reflected) | 12 Serratus posterior superior muscle | 19 Superior cluneal nerves |
| | 13 Scapula | |



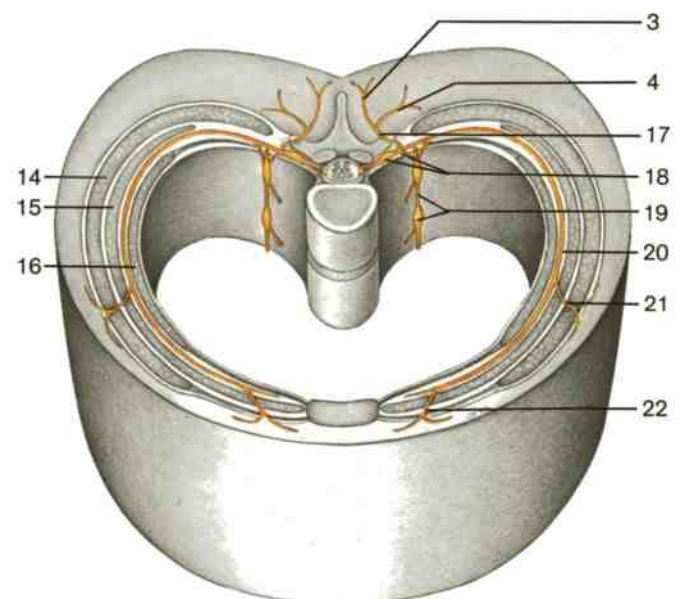
- 1 Greater occipital nerve (C₂)
- 2 Suboccipital nerve (C₁)
- 3 Medial branches of dorsal rami of spinal nerves
- 4 Lateral branches of dorsal rami of spinal nerves
- 5 Superior cluneal nerves (L₁-L₃)
- 6 Middle cluneal nerves (S₁-S₃)
- 7 Inferior cluneal nerves (derived from branches of the sacral plexus, ventral rami)
- 8 Lesser occipital nerve
- 9 Great auricular nerve
- 10 Trapezius muscle
- 11 Deltoid muscle
- 12 Latissimus dorsi muscle
- 13 Gluteus maximus muscle
- 14 External intercostal muscle
- 15 Internal intercostal muscle
- 16 Innermost intercostal muscle
- 17 Dorsal ramus of spinal nerve
- 18 Spinal nerve and spinal ganglion
- 19 Sympathetic trunk with ganglion
- 20 Intercostal nerve
- 21 Lateral cutaneous branch } of intercostal nerve
- 22 Anterior cutaneous branch }
- 23 Longissimus thoracis muscle
- 24 Spinal cord
- 25 Aorta
- 26 Esophagus
- 27 Body of rib
- 28 Thoracic rib
- 29 Thoracic duct
- 30 Azygos vein



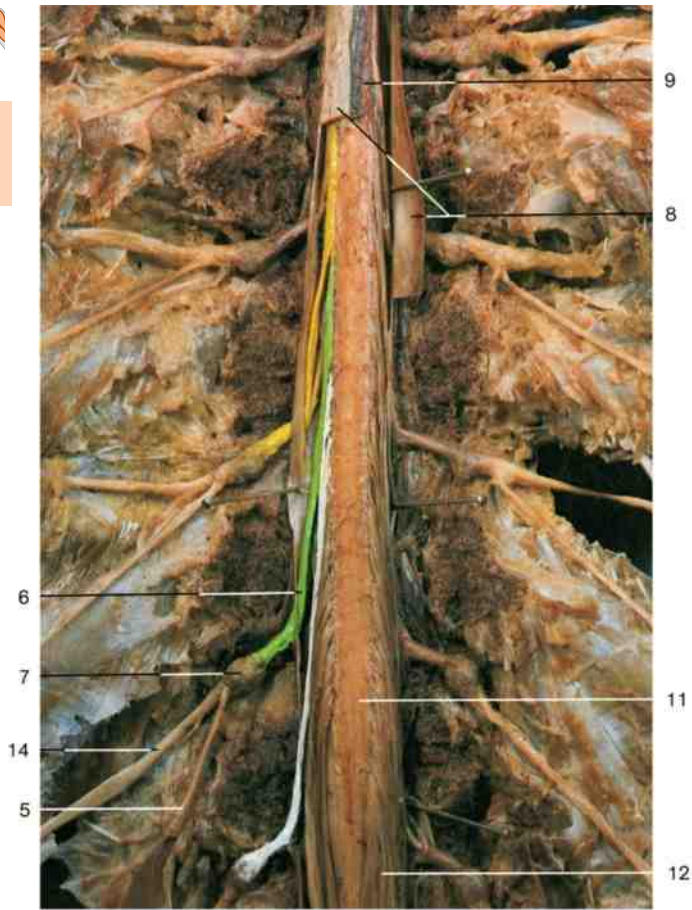
General characteristics of the innervation of the back. Distribution of dorsal branches of spinal nerves. Note the segmental arrangement of the innervation of the dorsal part of the trunk (schematic drawing).



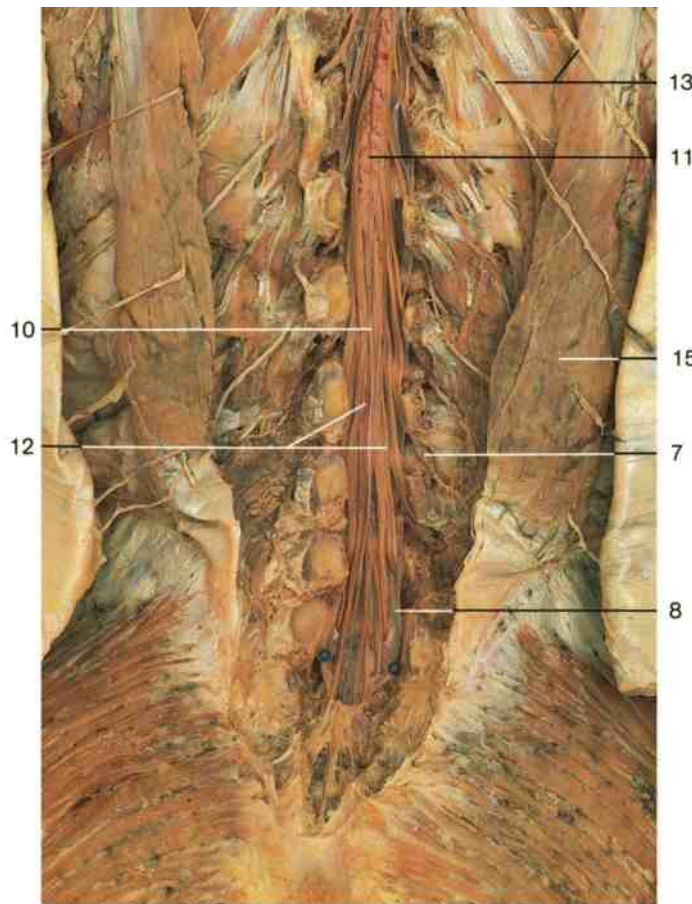
Posterior part of the thoracic wall (MRI scan, coronal section; from Heuck et al., MRT-Atlas, 2009).



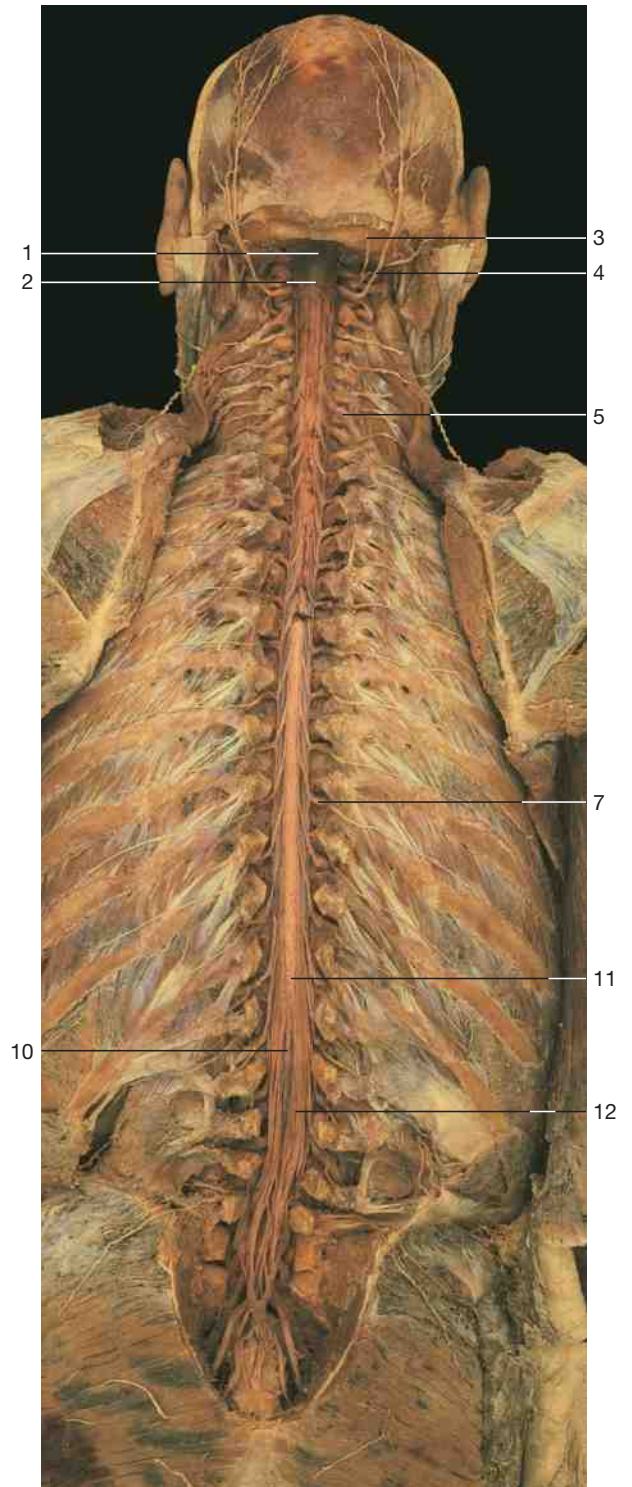
Position and branches of spinal nerves in one segment of thoracic wall (schematic drawing).



Lumbar portion of spinal cord. Note the relation between the nervous and muscular segments.

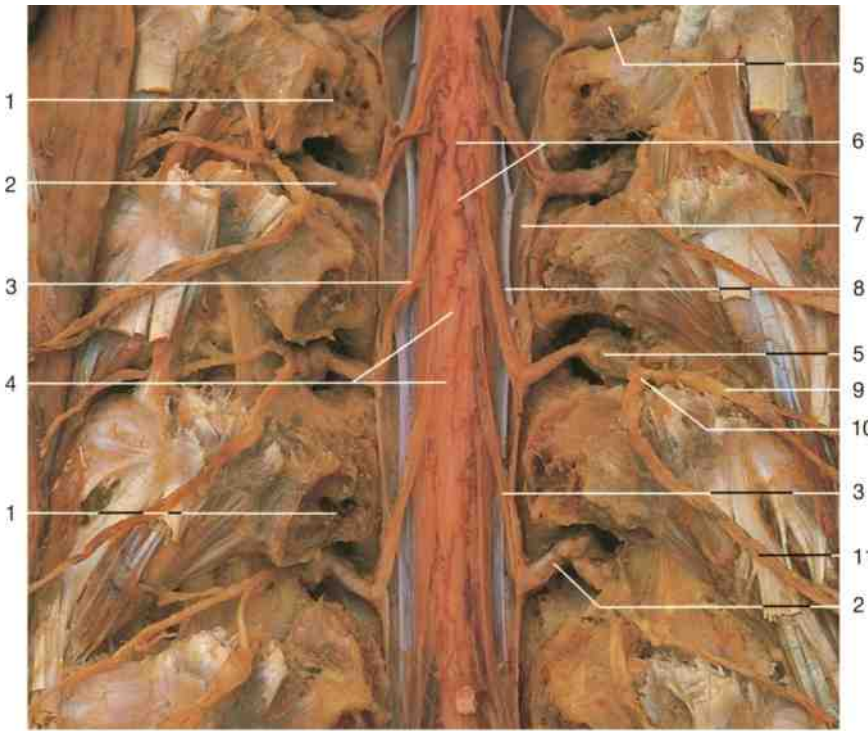
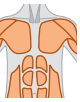


Terminal part of spinal cord. Dura removed.



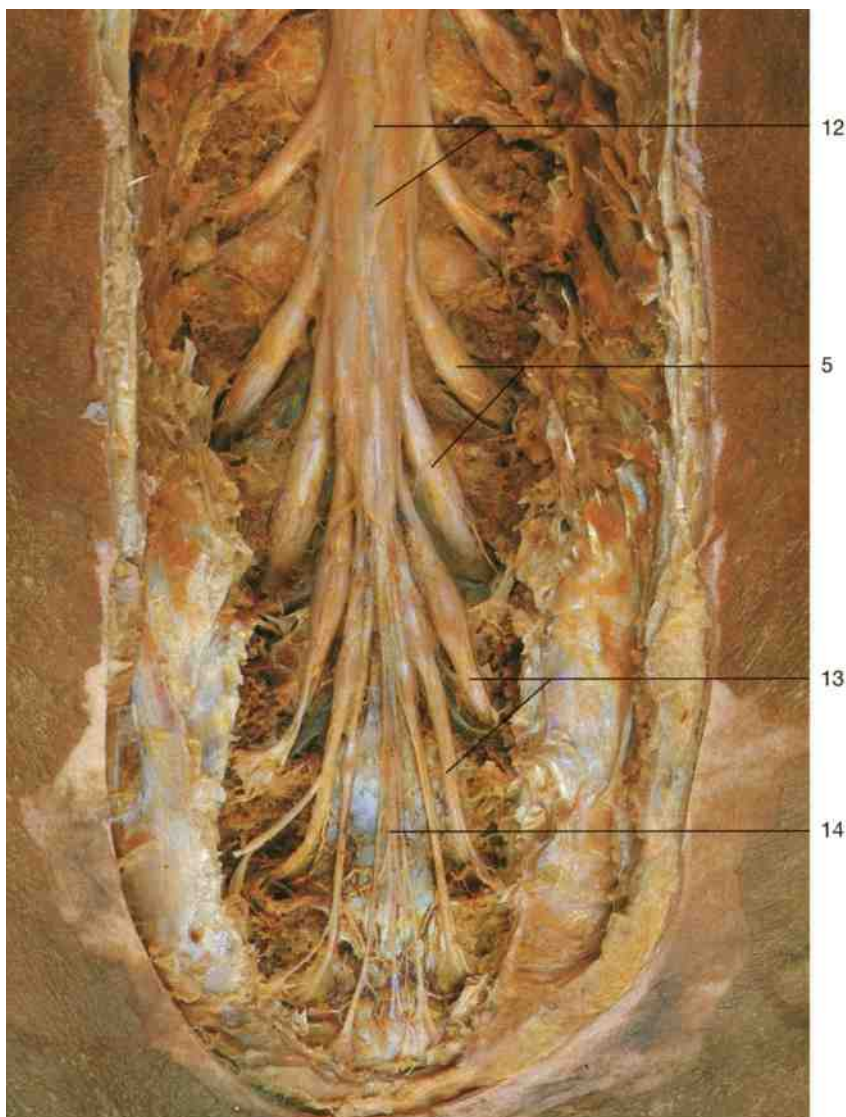
Innervation of the back. Spinal cord in the vertebral canal (opened). Longissimus dorsi and iliocostalis muscles have been removed.

- | | |
|---|--|
| 1 Cerebellomedullary cistern | 9 Spinal arachnoid mater |
| 2 Medulla oblongata | 10 Filum terminale |
| 3 Third cervical nerve (C ₃) | 11 Conus medullaris |
| 4 Greater occipital nerve (C ₂) | 12 Cauda equina |
| 5 Dorsal primary ramus | 13 Lateral branches of dorsal rami of spinal nerves |
| 6 Dorsal roots | 14 Ventral ramus of spinal nerve (intercostal nerve) |
| 7 Spinal ganglion | 15 Iliocostalis muscle |
| 8 Spinal dura mater | |

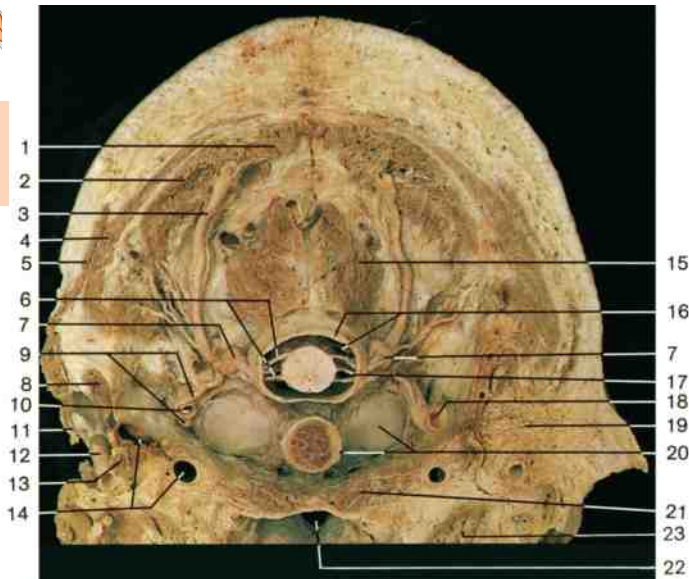
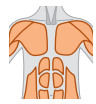


- 1 Arch of vertebra (divided)
- 2 Spinal nerve with meningeal coverings
- 3 Dorsal roots of thoracic spinal nerves
- 4 Spinal cord (thoracic portion)
- 5 Spinal ganglia with meningeal coverings
- 6 Pia mater with blood vessels
- 7 Dura mater (opened)
- 8 Denticulate ligament
- 9 Lateral branch of dorsal ramus
- 10 Dorsal ramus of spinal nerve (dividing into a medial and lateral branch)
- 11 Medial branch of dorsal ramus of spinal nerve
- 12 Spinal dura mater
- 13 Spinal nerves of sacral segments
- 14 Filum terminale

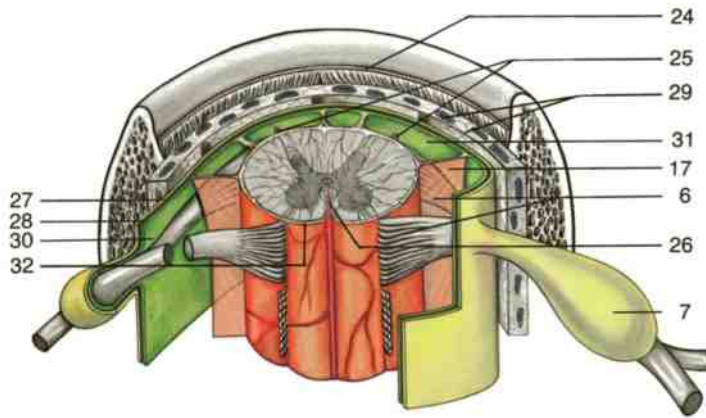
Thoracic portion of spinal cord (dorsal aspect). Vertebral canal and dura mater opened.



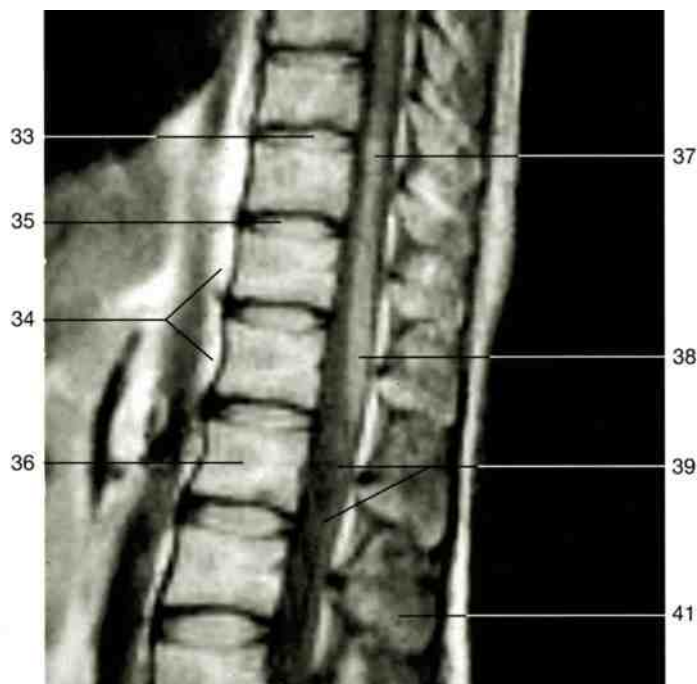
Terminal part of spinal cord with dura mater (dorsal aspect). Dorsal part of sacrum removed.



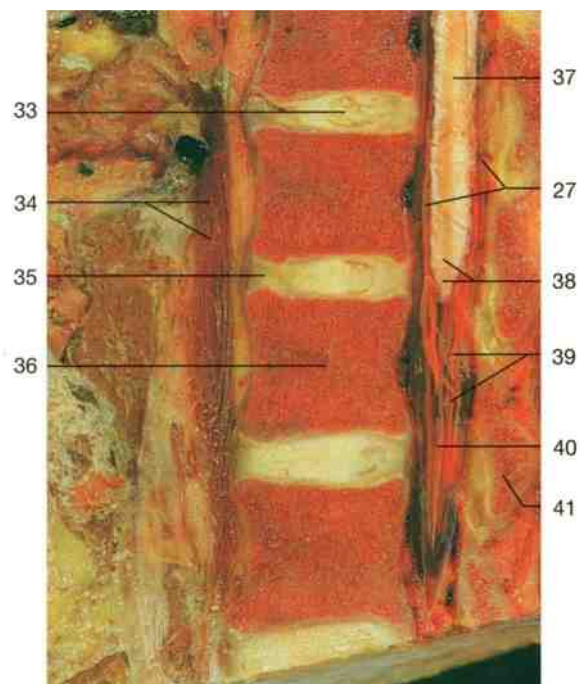
Horizontal section of the neck. Dissection of the second cervical spinal nerve. Posterior surface at top of figure.



Meningeal coverings of the spinal cord (anterior aspect). (Schematic drawing.)



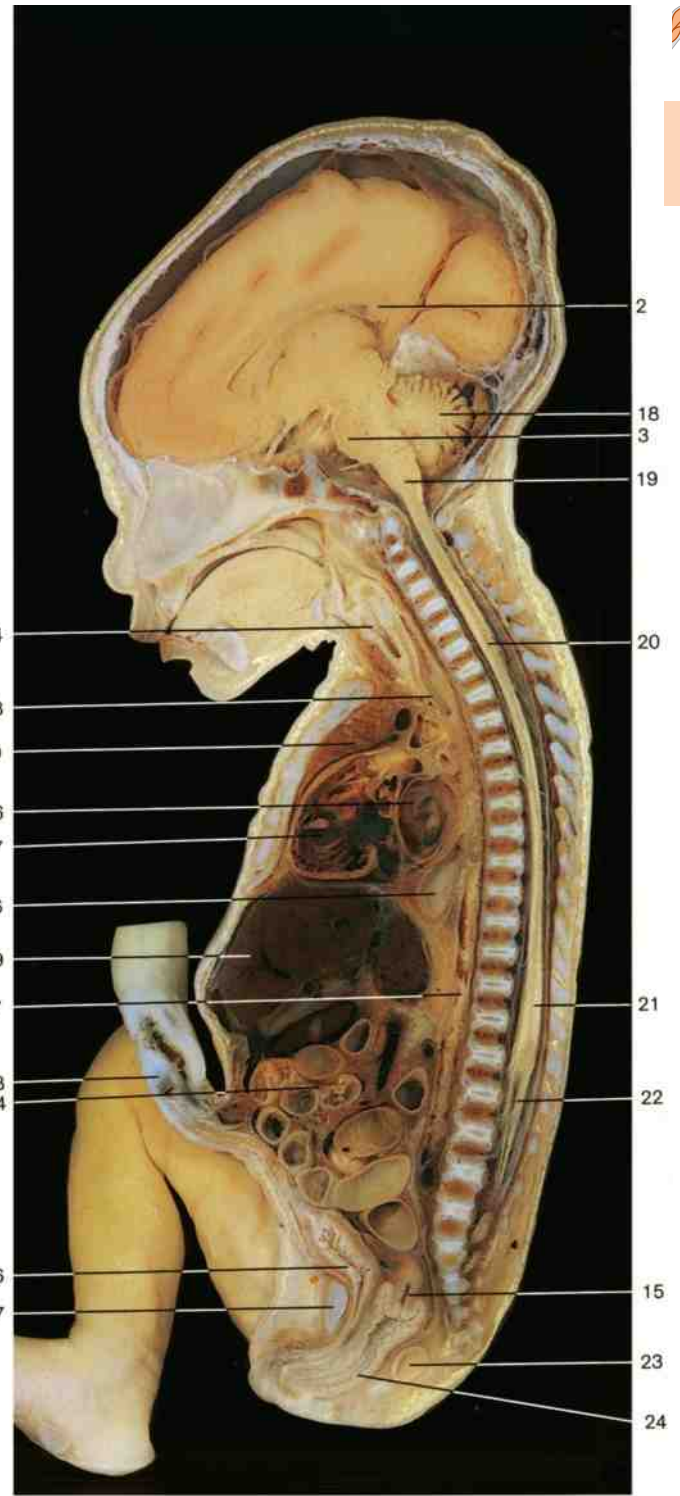
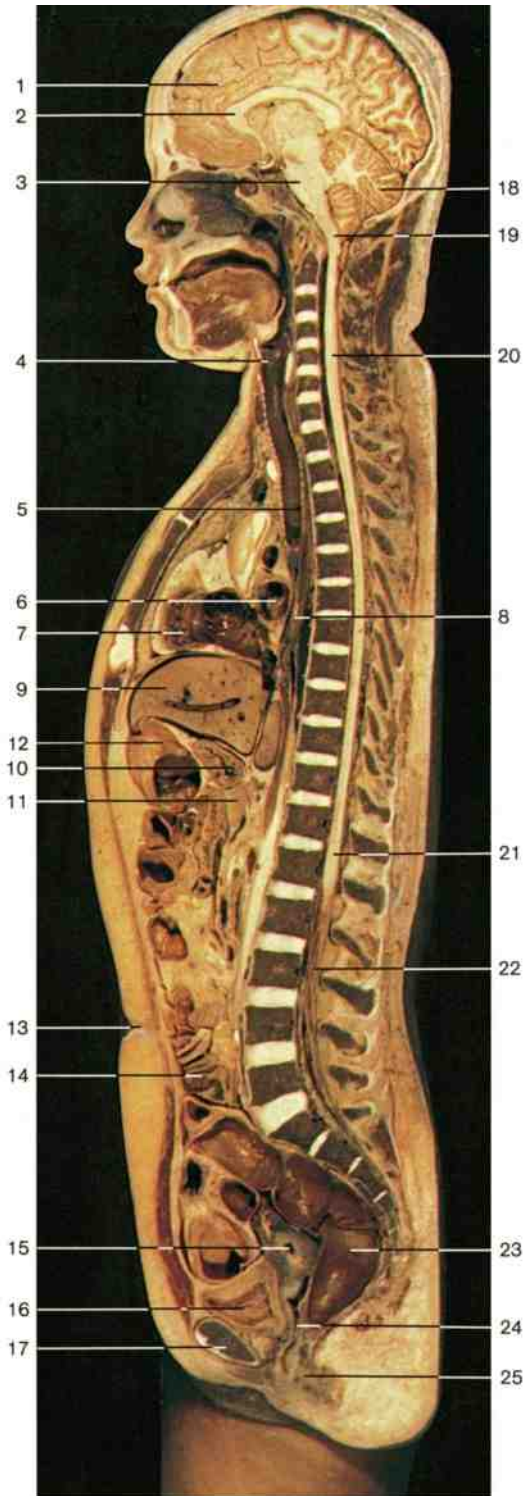
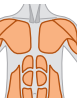
Sagittal section through the vertebral canal, T₉-L₂. (MRI scan.)



Sagittal section through the vertebral canal, T₁₂-L₂. Notice red bone marrow (unfixed).

- 1 Trapezius muscle
- 2 Semispinalis capitis muscle
- 3 Dorsal ramus of spinal nerve
- 4 Sternocleidomastoid muscle
- 5 Platysma muscle
- 6 Dorsal and ventral roots of spinal nerves
- 7 Spinal ganglion
- 8 Posterior belly of digastric muscle
- 9 Ventral ramus of spinal nerve
- 10 Vertebral artery
- 11 Great auricular nerve
- 12 Superficial temporal artery
- 13 Styloid process
- 14 Internal jugular vein and internal carotid artery
- 15 Rectus capitis posterior major muscle
- 16 Dura mater and subarachnoid space
- 17 Denticulate ligament
- 18 Vertebral artery
- 19 Parotid gland
- 20 Dens of axis (divided) and inferior articular facet of atlas
- 21 Longus capitis muscle
- 22 Pharyngeal cavity
- 23 Medial pterygoid muscle
- 24 Periosteum of vertebral canal
- 25 Posterior spinal arteries
- 26 Anterior spinal artery

- Meningeal coverings**
- 27 Dura mater
 - 28 Subdural space
 - 29 Extradural or epidural space with venous plexus and fatty tissue
 - 30 Arachnoid (green)
 - 31 Subarachnoid space
 - 32 Pia mater (pink)
 - 33 Nucleus pulposus
 - 34 Crus of diaphragm
 - 35 Intervertebral disc
 - 36 Body of first lumbar vertebra
 - 37 Spinal cord
 - 38 Conus medullaris
 - 39 Cauda equina
 - 40 Filum terminale
 - 41 Spinous process

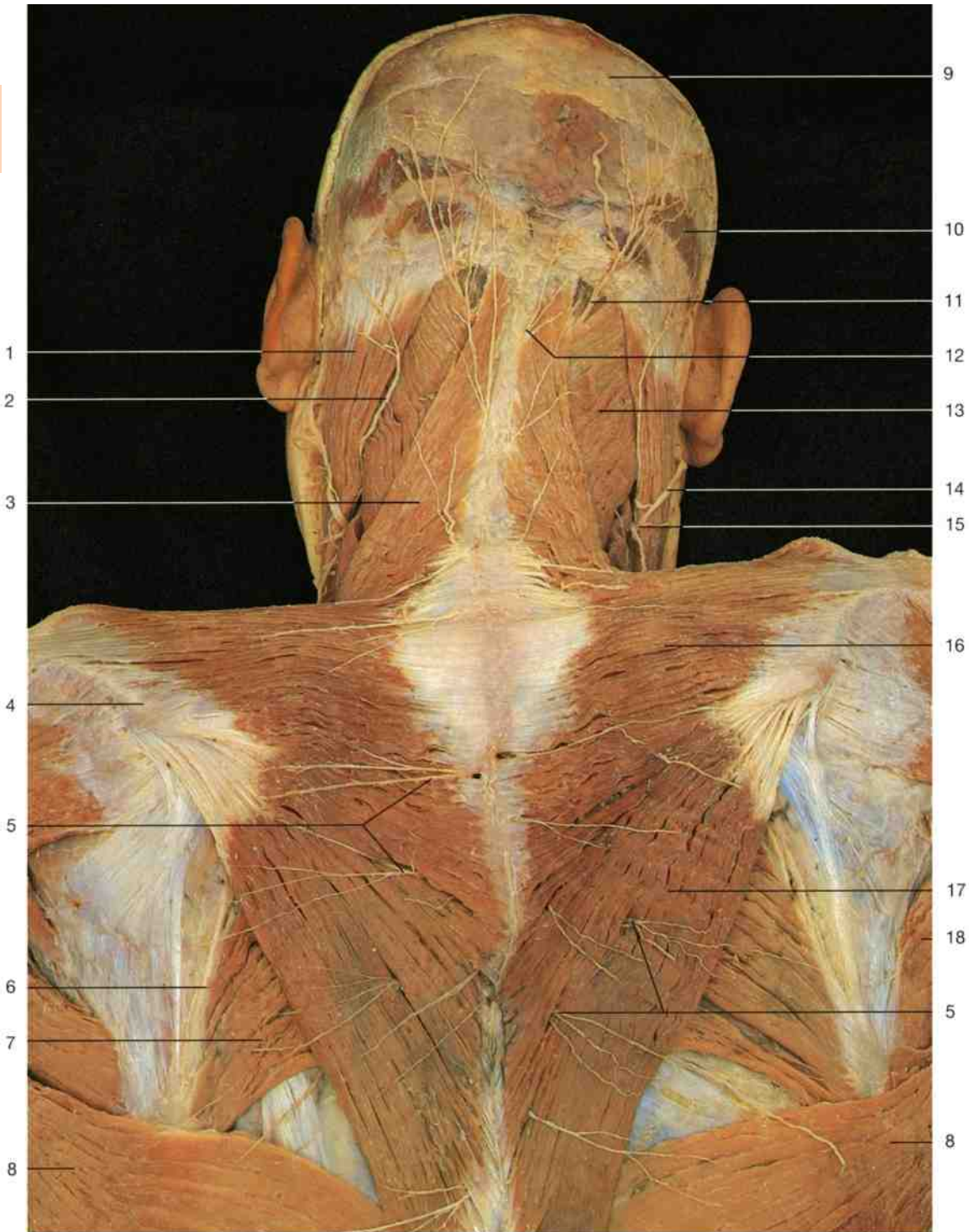
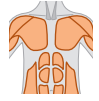


Median section of the head and trunk in the adult (female). The conus medullaris of the spinal cord is located at the level of L₁.

Median section of the head and trunk in the neonate. Note that in the neonate the conus medullaris of the spinal cord extends far more caudally than in the adult.

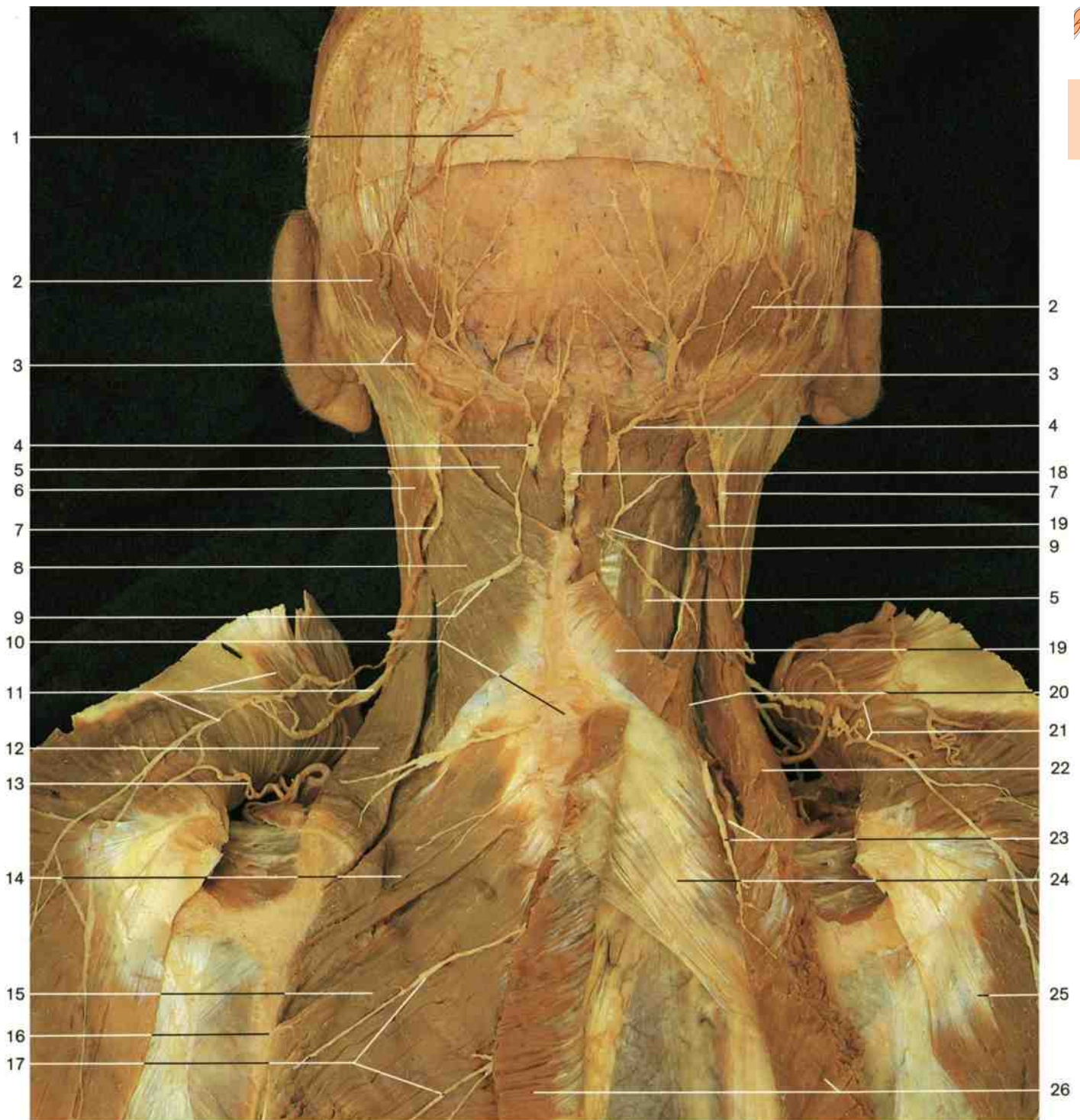
- | | |
|-------------------|----------------------|
| 1 Cerebrum | 11 Pancreas |
| 2 Corpus callosum | 12 Transverse colon |
| 3 Pons | 13 Umbilicus |
| 4 Larynx | 14 Small intestine |
| 5 Trachea | 15 Uterus |
| 6 Left atrium | 16 Urinary bladder |
| 7 Right ventricle | 17 Pubic symphysis |
| 8 Esophagus | 18 Cerebellum |
| 9 Liver | 19 Medulla oblongata |
| 10 Stomach | 20 Spinal cord |

- | |
|-----------------------|
| 21 Conus medullaris |
| 22 Cauda equina |
| 23 Rectum |
| 24 Vagina |
| 25 Anus |
| 26 Inferior vena cava |
| 27 Aorta |
| 28 Umbilical cord |
| 29 Thymus |



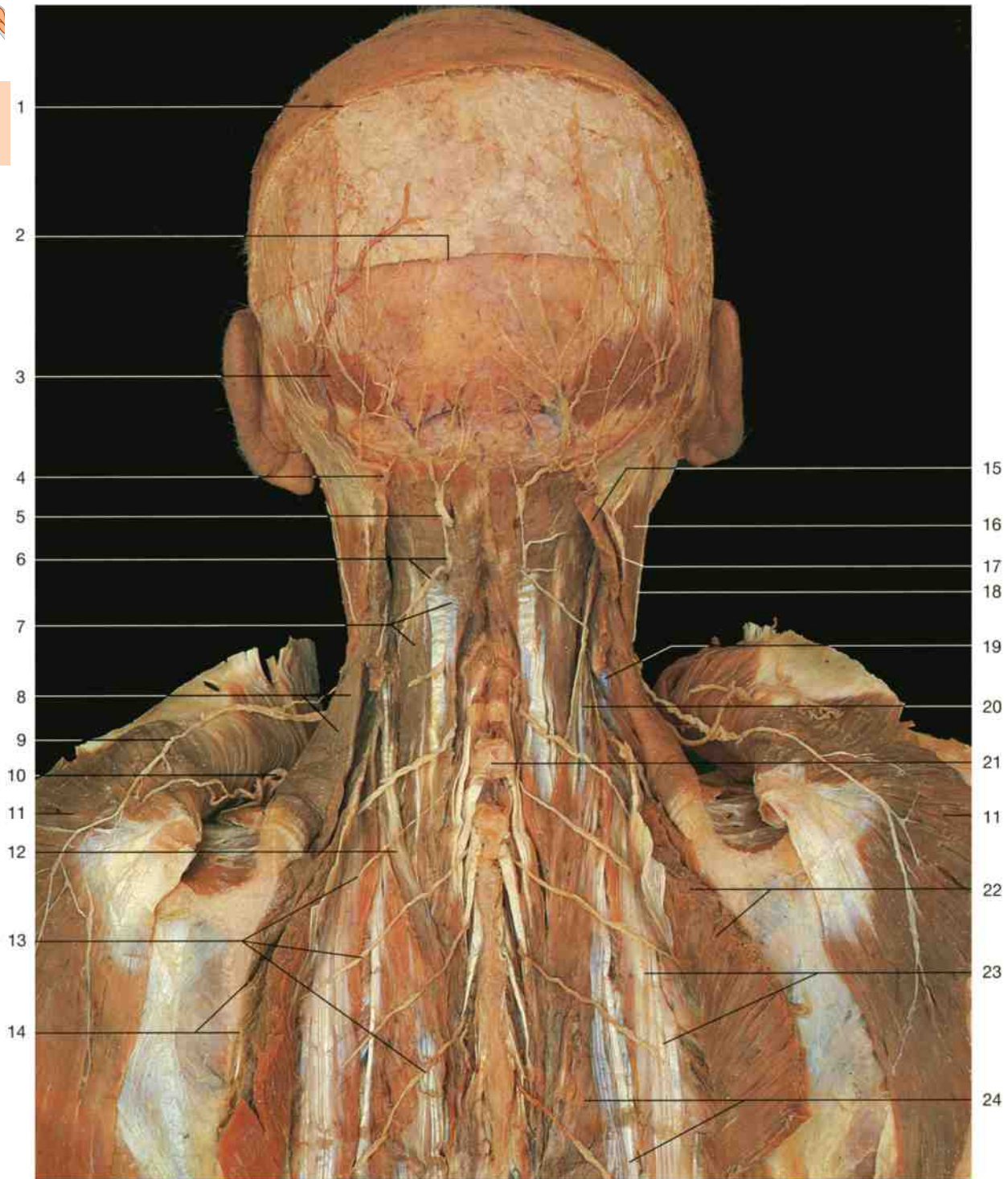
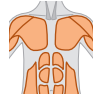
Dorsal aspect of the neck (superficial layer). Nuchal region and shoulder.

- | | |
|---|--|
| 1 Sternocleidomastoid muscle | 10 Occipital belly of occipitofrontalis muscle |
| 2 Lesser occipital nerve | 11 Greater occipital nerve |
| 3 Descending fibers of trapezius muscle | 12 Third occipital nerve |
| 4 Spine of scapula | 13 Splenius capitis muscle |
| 5 Medial cutaneous branches of dorsal rami of spinal nerves | 14 Great auricular nerve |
| 6 Medial margin of scapula | 15 Cutaneous nerves of cervical plexus |
| 7 Rhomboid major muscle | 16 Transverse fibers of trapezius muscle |
| 8 Latissimus dorsi muscle | 17 Ascending fibers of trapezius muscle |
| 9 Galea aponeurotica | 18 Teres major muscle |



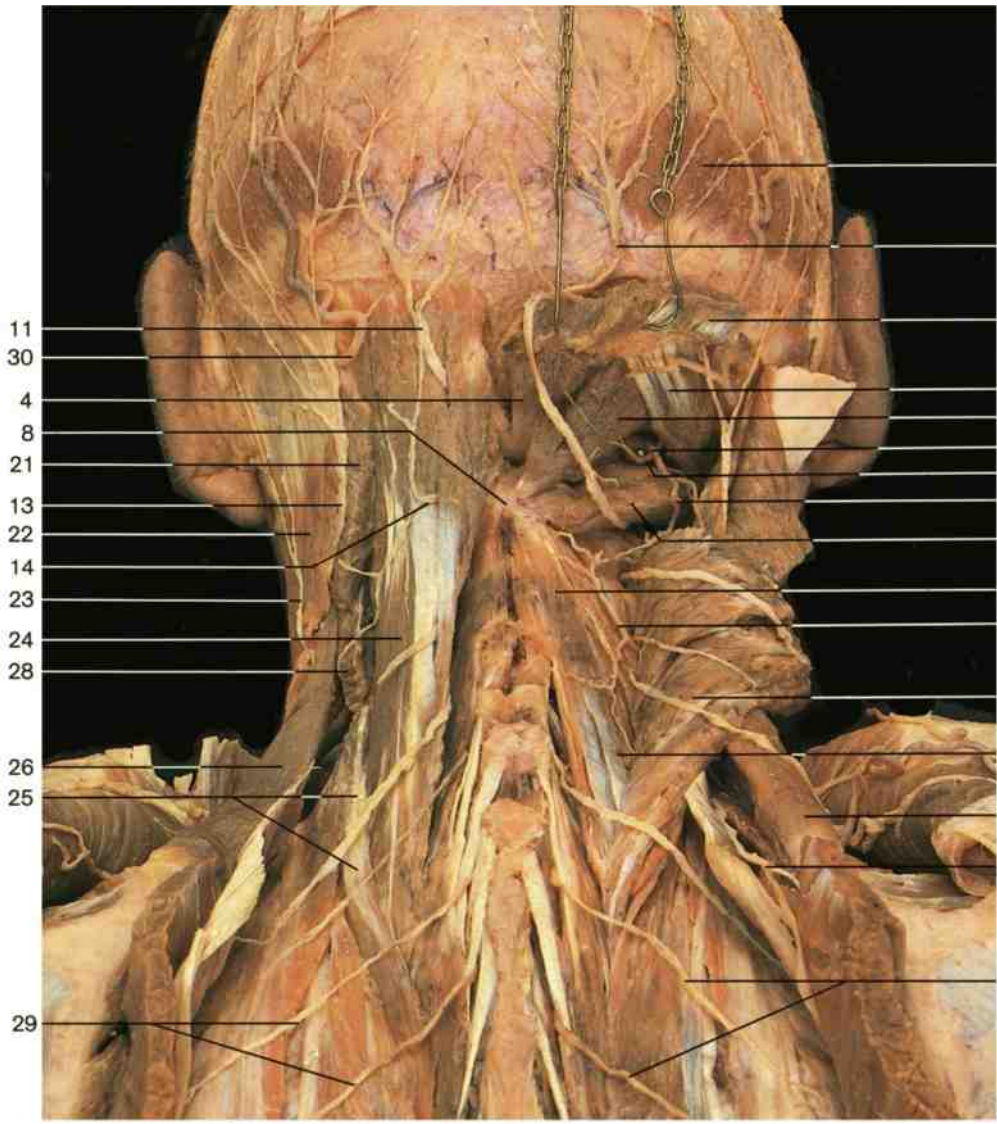
Dorsal aspect of the neck (deeper layer). The left trapezius muscle has been divided and reflected. On the right, trapezius, rhomboid, and splenius muscles have been divided. Right levator scapulae muscle has been slightly reflected.

- | | | |
|--|---|---|
| 1 Galea aponeurotica | 11 Left trapezius muscle and accessory nerve | 20 Splenius cervicis muscle |
| 2 Occipital belly of occipitofrontalis muscle | 12 Levator scapulae muscle | 21 Right accessory nerve and superficial branch of transverse cervical artery |
| 3 Occipital artery | 13 Superficial branch of transverse cervical artery | 22 Right levator scapulae muscle |
| 4 Greater occipital nerve (C ₂) | 14 Rhomboid minor muscle | 23 Dorsal scapular nerve and deep branch of transverse cervical artery |
| 5 Semispinalis capitis muscle | 15 Rhomboid major muscle | 24 Serratus posterior superior muscle |
| 6 Sternocleidomastoid muscle | 16 Medial margin of scapula | 25 Right trapezius muscle (divided and reflected) |
| 7 Lesser occipital nerve | 17 Medial branches of dorsal rami of spinal nerves | 26 Right rhomboid major muscle (divided and reflected) |
| 8 Left splenius capitis muscle | 18 Ligamentum nuchae | |
| 9 Third occipital nerve (C ₃) | 19 Splenius capitis muscle (divided) | |
| 10 Spinous process of vertebra prominens (C ₇) | | |



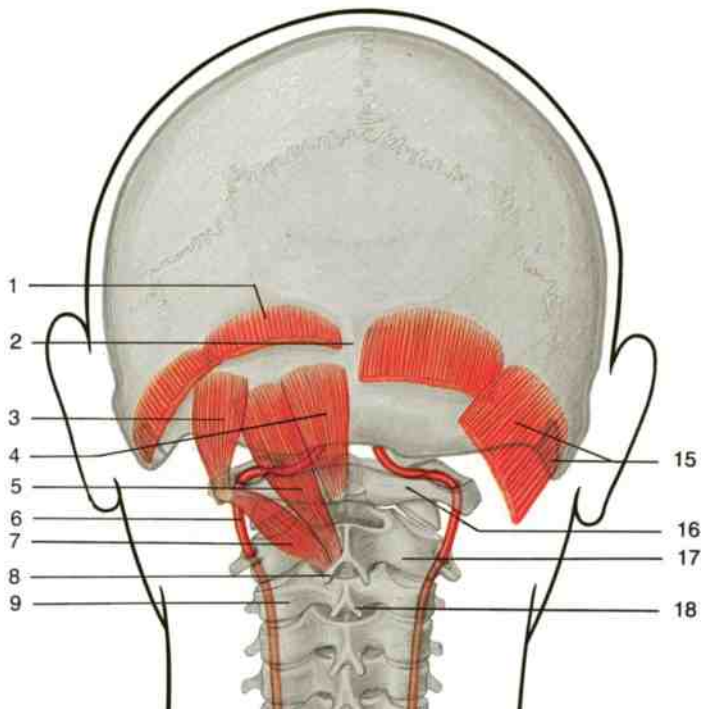
Dorsal aspect of the neck (deepest layer). Trapezius, splenius capitis, and cervicis muscles have been divided and partly removed or reflected.

- | | | |
|---|--|--|
| 1 Skin of scalp | 9 Accessory nerve (n. XI) | 17 Lesser occipital nerve |
| 2 Galea aponeurotica | 10 Superficial cervical artery | 18 Great auricular nerve |
| 3 Occipital belly of occipitofrontalis muscle | 11 Trapezius muscle (reflected) | 19 Splenius cervicis muscle |
| 4 Occipital artery | 12 Longissimus cervicis muscle | 20 Longissimus cervicis muscle |
| 5 Greater occipital nerve | 13 Medial cutaneous branches of dorsal rami of spinal nerves | 21 Spinous process of seventh cervical vertebra (vertebra prominens) |
| 6 Third occipital nerve | 14 Medial margin of scapula | 22 Rhomboid muscles (divided) |
| 7 Semispinalis capitis muscle | 15 Splenius capitis muscle (divided) | 23 Iliocostalis thoracis muscle |
| 8 Levator scapulae muscle | 16 Sternocleidomastoid muscle | 24 Longissimus thoracis muscle |

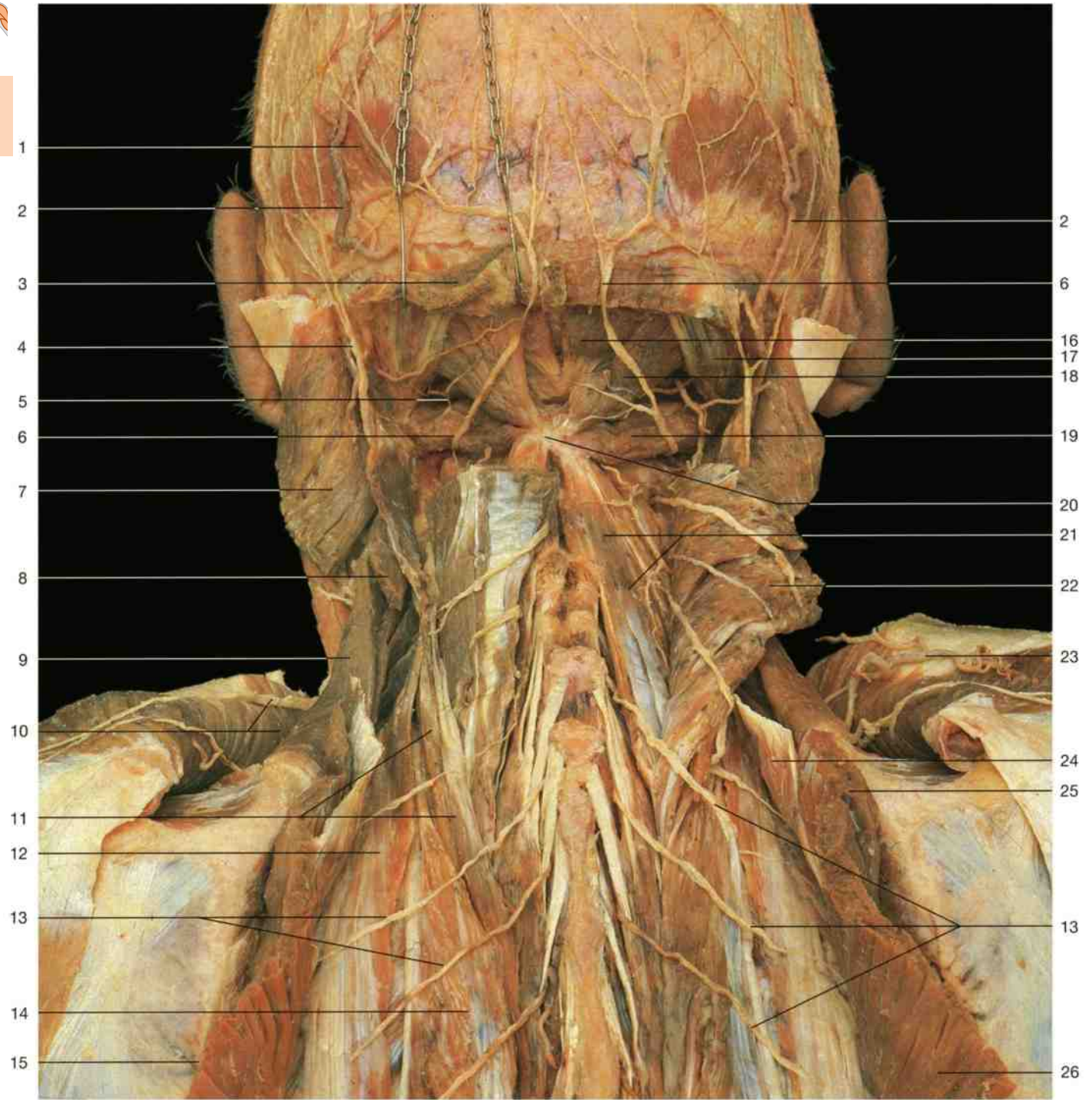
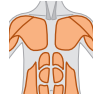


- 1 Semispinalis capitis muscle (divided)
- 2 External occipital protuberance
- 3 Obliquus capitis superior muscle
- 4 Rectus capitis posterior minor muscle
- 5 Rectus capitis posterior major muscle
- 6 Vertebral artery
- 7 Obliquus capitis inferior muscle
- 8 Spinous process of axis
- 9 Third cervical vertebra
- 10 Occipital belly of occipitofrontalis muscle
- 11 Greater occipital nerve
- 12 Suboccipital nerve (C₁)
- 13 Lesser occipital nerve
- 14 Third occipital nerve (C₃)
- 15 Mastoid process and splenius capitis muscle
- 16 Atlas
- 17 Axis
- 18 Spinous process of third cervical vertebra
- 19 Right semispinalis cervicis muscle
- 20 Deep cervical artery
- 21 Left splenius capitis muscle (divided)
- 22 Left sternocleidomastoid muscle
- 23 Great auricular nerve
- 24 Left semispinalis capitis muscle
- 25 Left longissimus cervicis muscle
- 26 Levator scapulae muscle
- 27 Muscular branch of vertebral artery
- 28 Left semispinalis cervicis muscle (divided)
- 29 Medial branches of dorsal rami of spinal nerves
- 30 Occipital artery
- 31 Dorsal scapular nerve

Dorsal aspect of the neck (deepest layer). Suboccipital triangle. Right semispinalis capitis muscle divided and reflected.

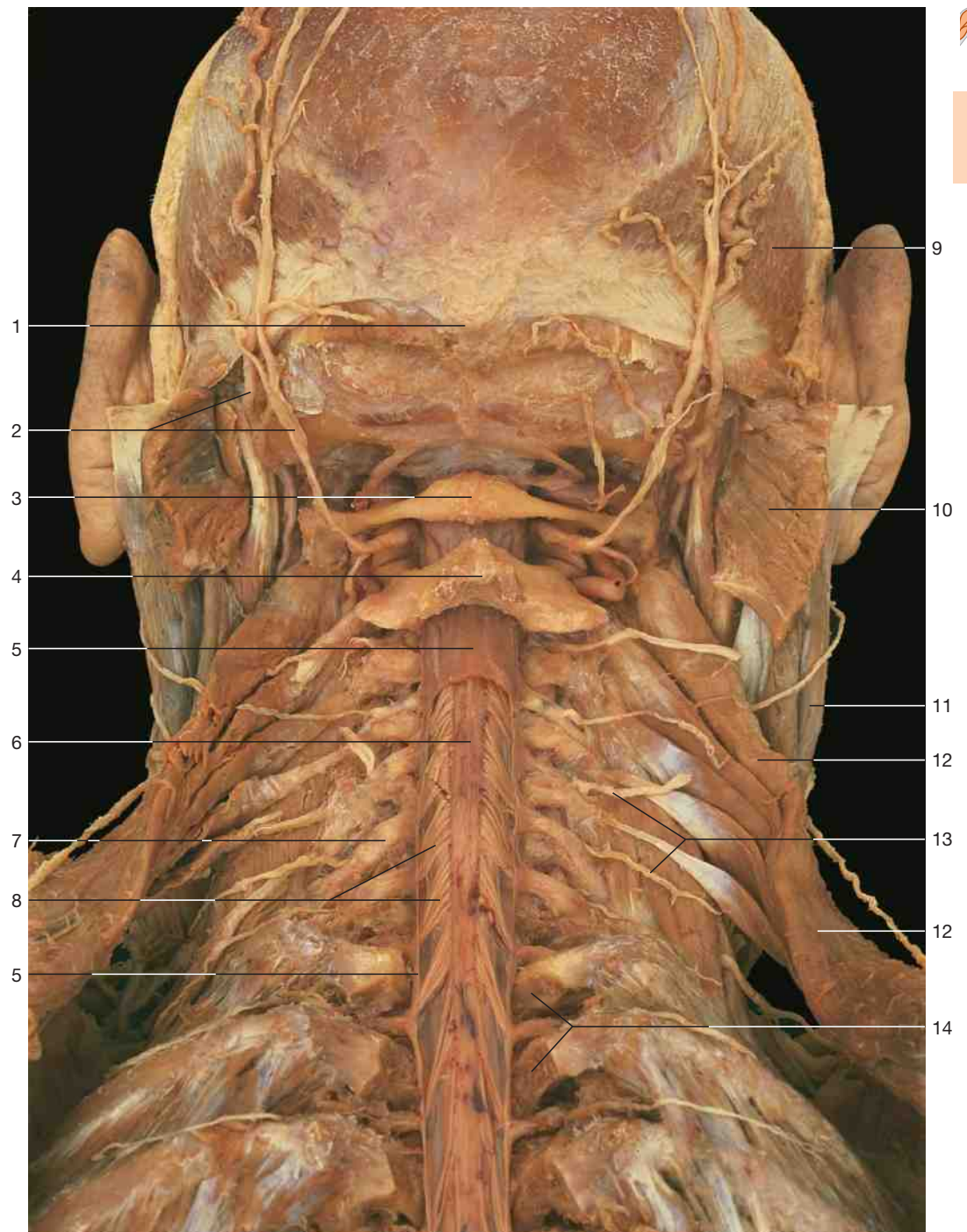


Suboccipital triangle and position of the vertebral artery (schematic drawing).



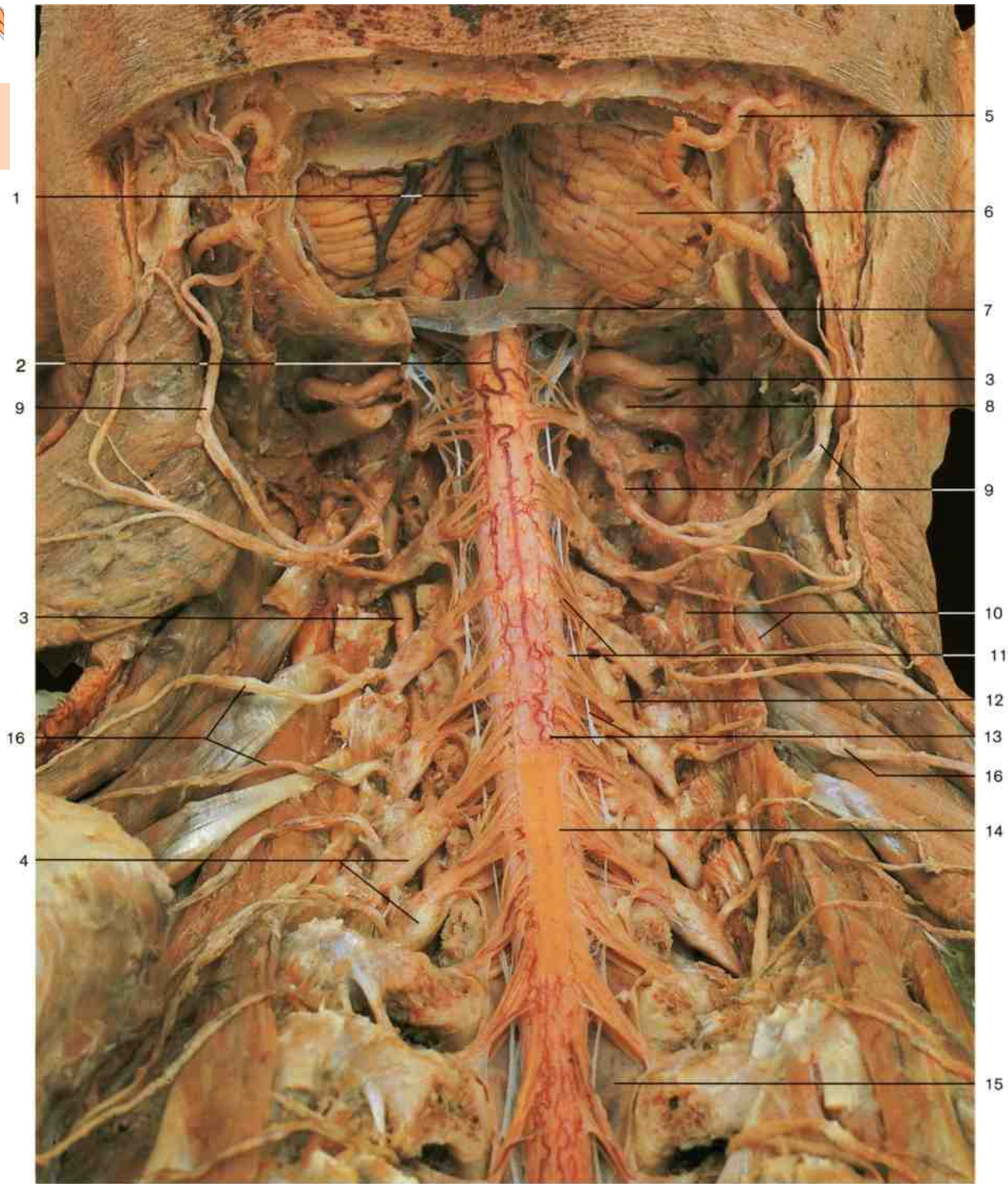
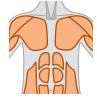
Dorsal aspect of the neck (deepest layer). Dissection of suboccipital triangle on both sides.

- | | | |
|--|---|---|
| 1 Occipital belly of occipitofrontalis muscle | 11 Longissimus cervicis muscle | 21 Semispinalis cervicis muscle |
| 2 Occipital artery | 12 Iliocostalis cervicis muscle | 22 Semispinalis capitis muscle (divided and reflected) |
| 3 Insertion of semispinalis capitis muscle (divided) | 13 Medial cutaneous branches of dorsal rami of spinal nerves (C ₇ , C ₈) | 23 Transverse cervical artery (superficial branch) |
| 4 Lesser occipital nerve (from cervical plexus) | 14 Longissimus thoracis muscle | 24 Serratus posterior superior muscle (divided and reflected) |
| 5 Suboccipital nerve (C ₁) | 15 Medial margin of scapula | 25 Rhomboid minor muscle (divided and reflected) |
| 6 Greater occipital nerve (C ₂) | 16 Rectus capitis posterior minor muscle | 26 Rhomboid major muscle (divided and reflected) |
| 7 Splenius capitis muscle (reflected) | 17 Obliquus capitis superior muscle | |
| 8 Splenius cervicis muscle | 18 Rectus capitis posterior major muscle | |
| 9 Levator scapulae muscle | 19 Obliquus capitis inferior muscle | |
| 10 Accessory nerve (n. XI), trapezius muscle | 20 Spinous process of axis | |



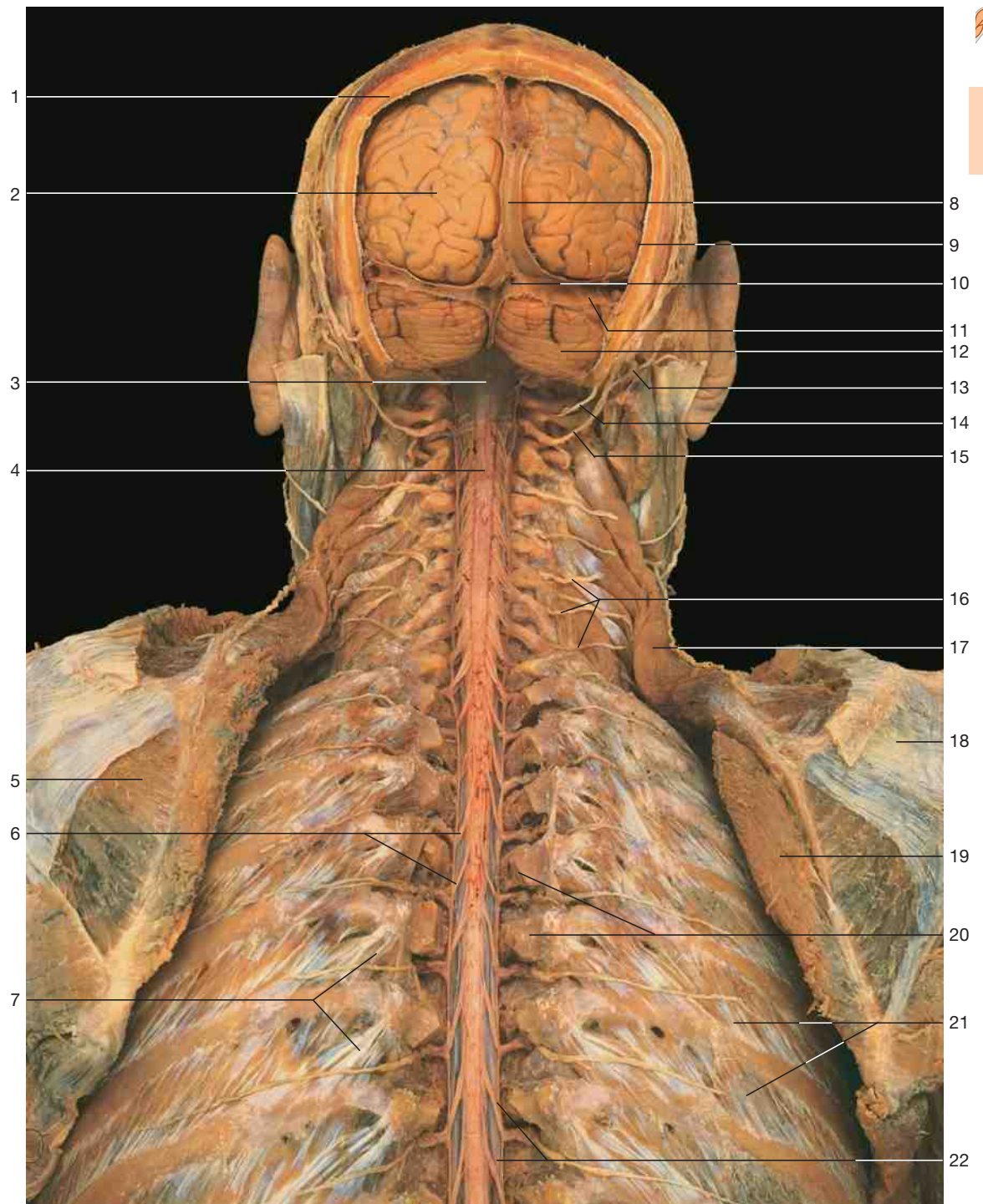
Dorsal aspect of the neck (deepest layer). The vertebral canal caudally of the atlas and axis has been opened to show the spinal cord (dura mater has been partly removed).

- | | |
|--|---|
| 1 Protuberantia occipitalis externa | 8 Posterior root filaments (fila radicularia posterior) |
| 2 Greater occipital nerve (C ₂) and occipital artery | 9 Occipital belly of occipitofrontalis muscle |
| 3 Atlas (posterior arch) | 10 Splenius capitis muscle (cut and reflected) |
| 4 Axis (posterior arch) | 11 Sternocleidomastoid muscle |
| 5 Dura mater | 12 Levator scapulae muscle |
| 6 Spinal cord | 13 Posterior branches of spinal nerves |
| 7 Spinal ganglion | 14 Arches of cervical vertebrae (cut) |



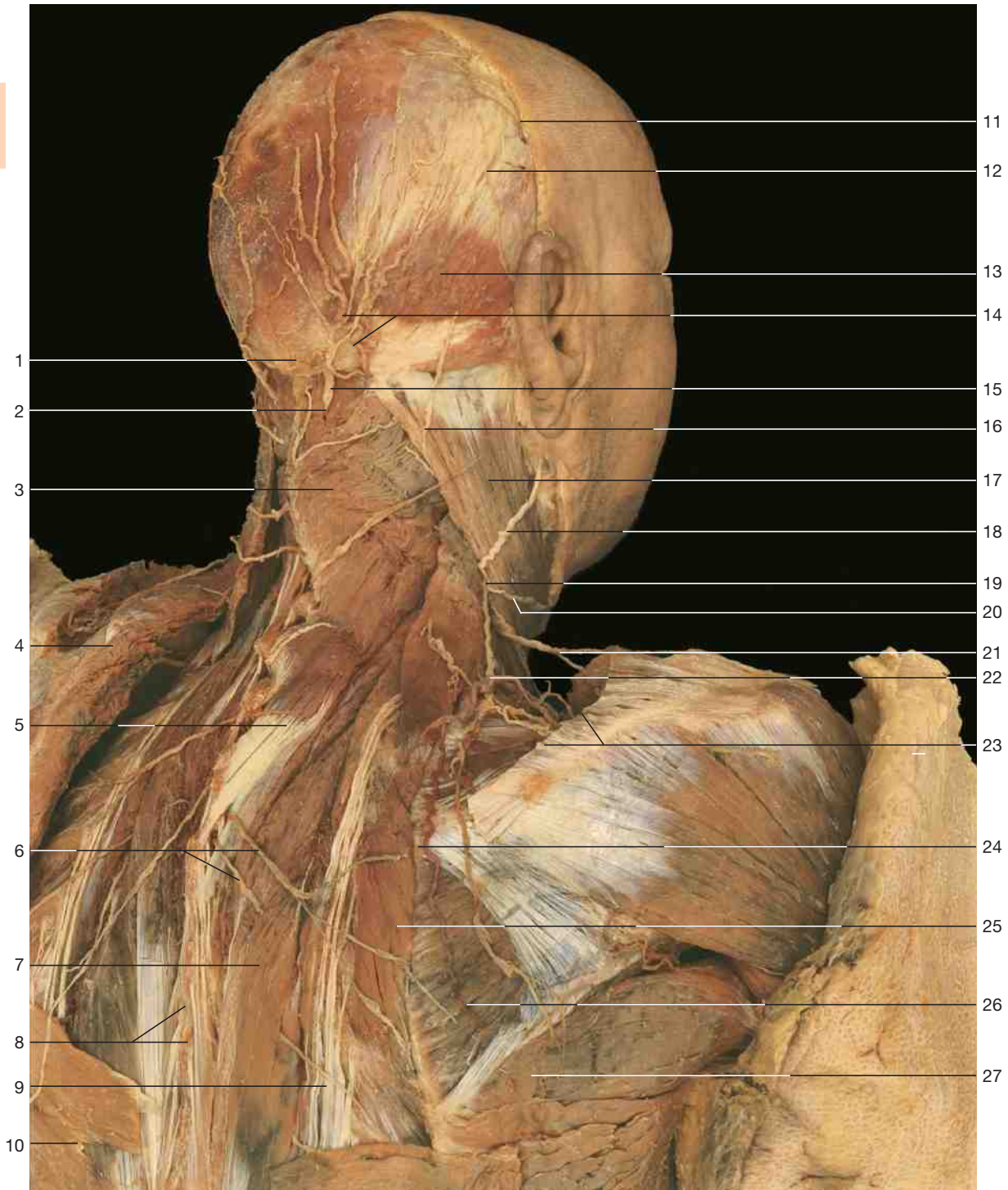
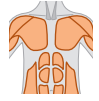
Dorsal aspect of the neck (deepest layer). Dissection of medulla oblongata and spinal cord. Cranial cavity opened.

- | | |
|---|---|
| 1 Vermis of the cerebellum | 9 Greater occipital nerve (C ₂) |
| 2 Medulla oblongata and posterior spinal artery | 10 Levator scapulae muscle and intertransverse ligament |
| 3 Vertebral artery | 11 Dorsal roots of spinal nerves |
| 4 Spinal ganglion | 12 Vertebral arch |
| 5 Occipital artery | 13 Denticulate ligament and arachnoid mater |
| 6 Cerebellum | 14 Area where pia mater has been removed |
| 7 Cerebellomedullary cistern | 15 Dura mater |
| 8 Atlas | 16 Dorsal rami of spinal nerves |



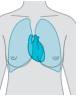
Dorsal aspect of the neck (deepest layer). Dissection of medulla oblongata and spinal cord in relation to the brain.

- | | | | |
|----|---|----|---|
| 1 | Calvaria | 12 | Cerebellum |
| 2 | Left hemisphere of the brain | 13 | Occipital artery |
| 3 | Cerebellomedullary cistern | 14 | Suboccipital nerve (C ₁) |
| 4 | Spinal cord | 15 | Greater occipital nerve (C ₂) |
| 5 | Scapula with infraspinous muscle | 16 | Posterior branches of spinal nerves |
| 6 | Root filaments (fila radicularia posterior) | 17 | Levator scapulae muscle |
| 7 | Levatores costarum muscles | 18 | Deltoid muscle |
| 8 | Falx cerebri with sinus sagittalis superior | 19 | Rhomboid muscles |
| 9 | Subarachnoidal space | 20 | Vertebral arches (cut) |
| 10 | Confluens sinuum | 21 | External intercostal muscle |
| 11 | Transverse sinus | 22 | Dura mater |

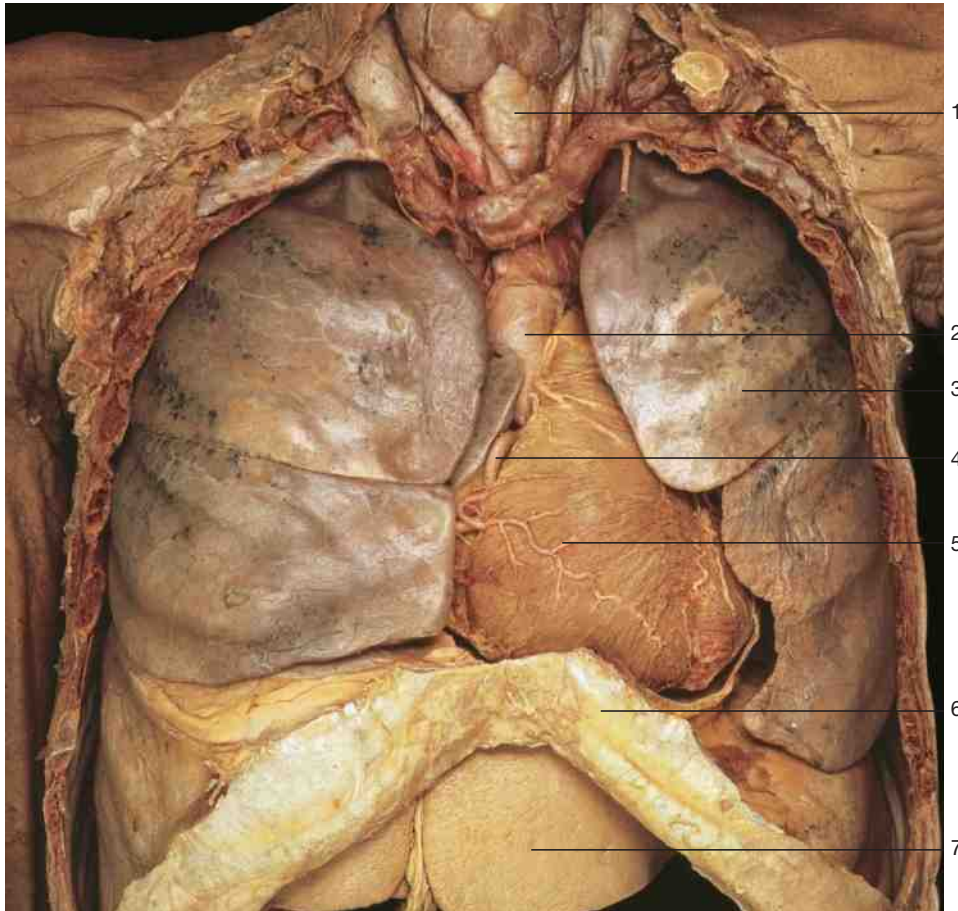


Oblique-lateral aspect of the neck and head (deeper layer). The trapezius muscle has been removed.

- | | | | |
|----|---|----|---|
| 1 | Protuberantia occipitalis externa | 15 | Greater occipital nerve (C ₂) |
| 2 | Semispinalis capitis muscle | 16 | Lesser occipital nerve |
| 3 | Splenius capitis muscle | 17 | Sternocleidomastoid muscle |
| 4 | Scapula | 18 | Great auricular nerve |
| 5 | Splenius cervicis muscle | 19 | Punctum nervosum |
| 6 | Posterior branches of spinal nerves | 20 | Transverse cervical nerve |
| 7 | Longissimus muscle | 21 | Supraclavicular nerves |
| 8 | Spinous processes of thoracic vertebrae | 22 | Accessory nerve (n. XI) |
| 9 | Iliocostalis muscle | 23 | Trapezius muscle (cut edge) |
| 10 | Latissimus dorsi muscle | 24 | Medial margin of scapula |
| 11 | Epidermis of the head (scalp) | 25 | Rhomboid muscle |
| 12 | Galea aponeurotica | 26 | Infraspinous muscle |
| 13 | Occipital belly of occipitofrontalis muscle | 27 | Teres major muscle |
| 14 | Occipital artery | | |

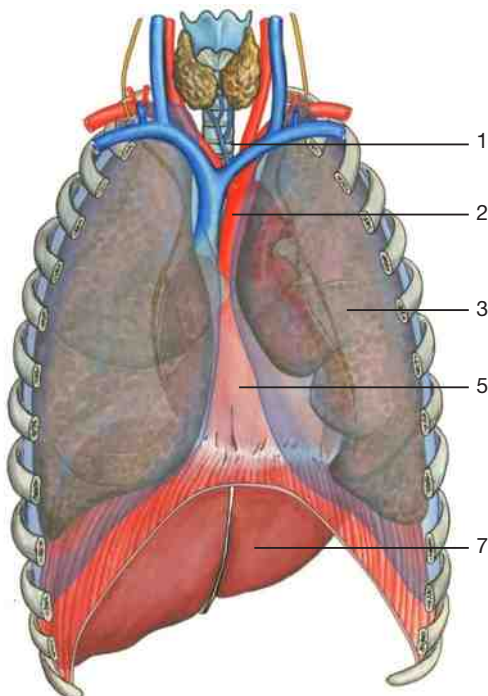


4 Thoracic Organs



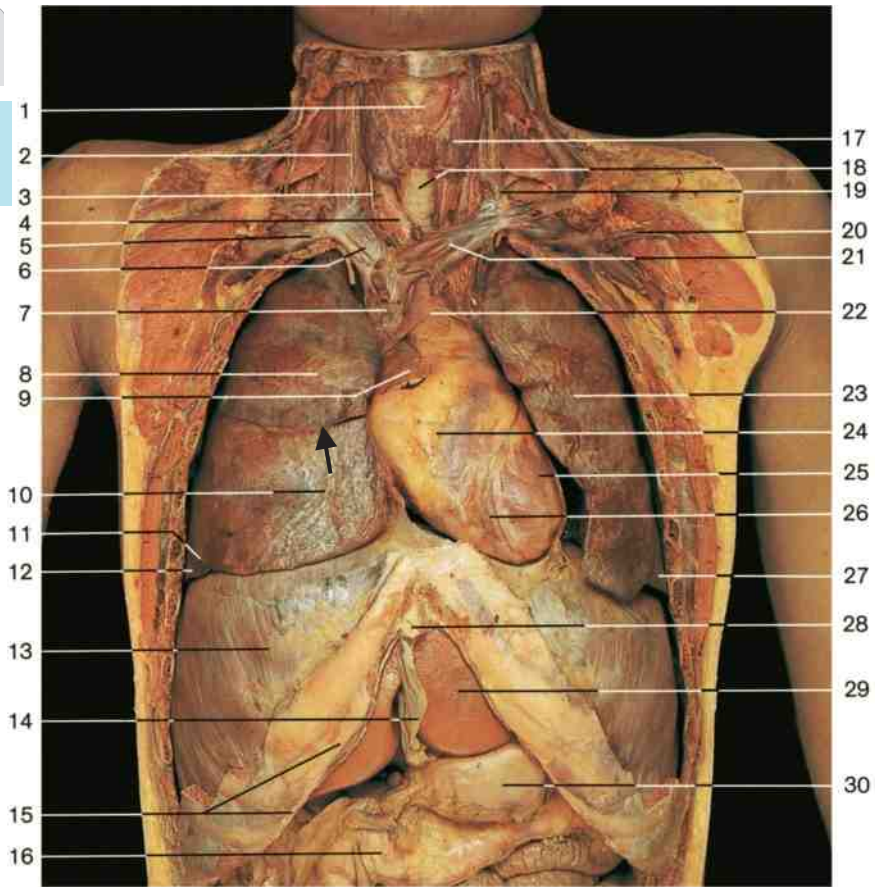
The thoracic cavity contains heart, lungs, and mediastinal organs. The thorax protects all organs but is still movable so that respiration can occur. The respiratory movements of the lung depend on the pleura covering, the thoracic wall, and the surface of the lungs. The mediastinal organs comprise the esophagus, trachea, and the related nerves and vessels, particularly the aorta, superior vena cava, and the thoracic duct. The thoracic cavity is separated from the abdominal cavity by the diaphragm.

Thoracic organs, heart, and lungs in situ (ventral aspect). Anterior thoracic wall, parietal pleura, and pericardium have been removed.



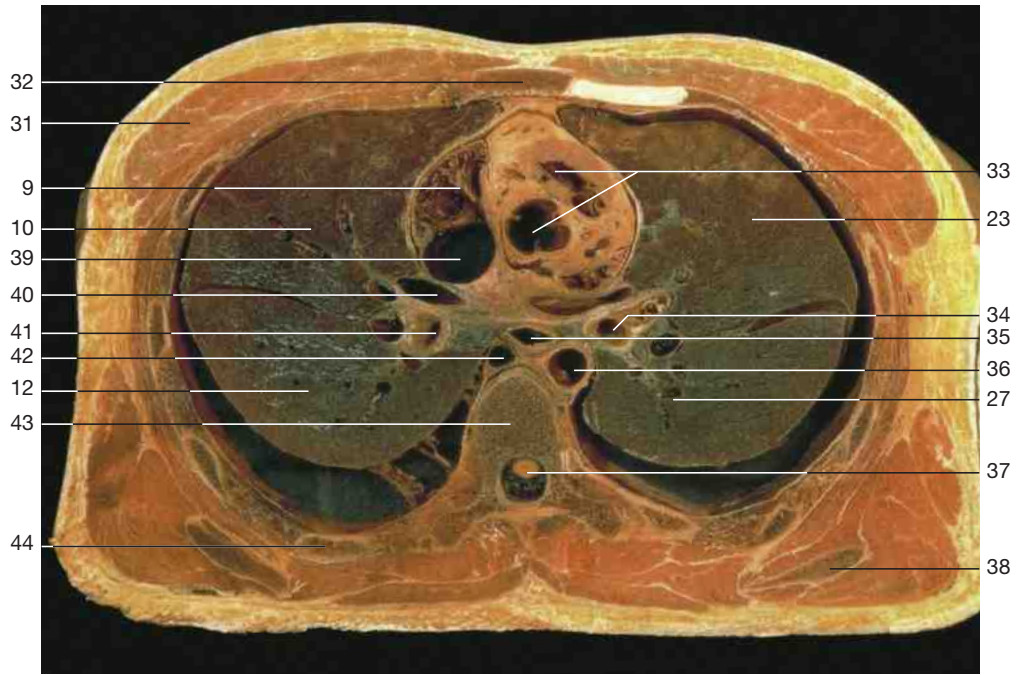
- 1 Trachea
- 2 Ascending aorta
- 3 Left lung
- 4 Right coronary artery
- 5 Heart (right ventricle)
- 6 Costal arch
- 7 Liver

Position of lungs and heart within the thoracic cavity (schematic drawing). The anterior part of the thorax is not depicted.

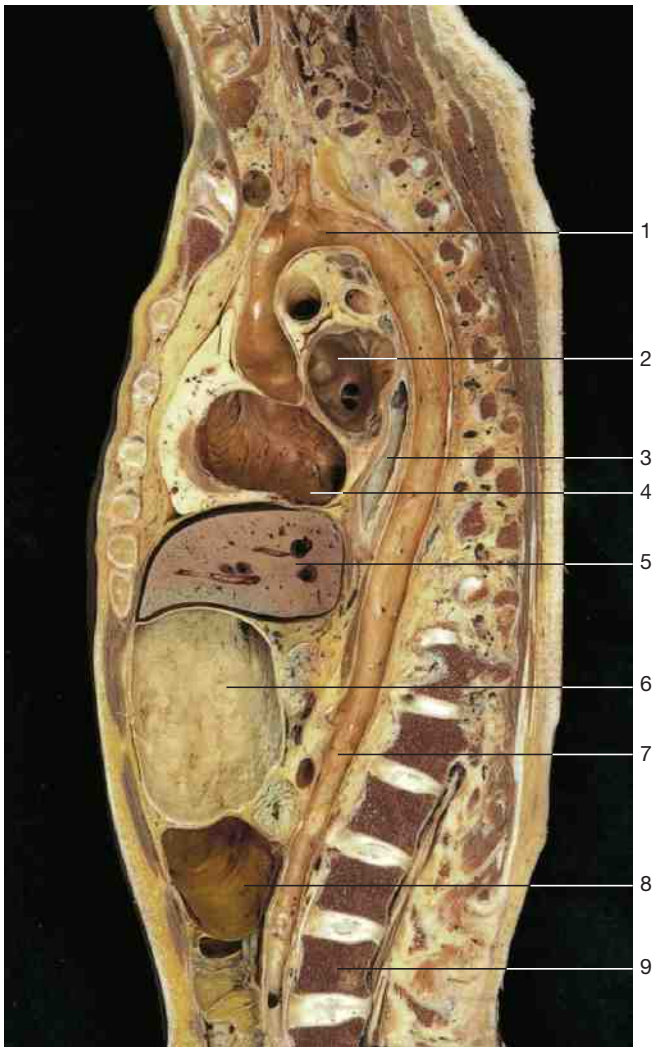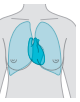


- 1 Cricothyroid muscle
- 2 Right internal jugular vein
- 3 Vagus nerve
- 4 Right common carotid artery
- 5 Right subclavian vein
- 6 Right brachiocephalic vein
- 7 Superior vena cava
- 8 Upper lobe of right lung
- 9 Right auricle
- 10 Middle lobe of right lung
- 11 Oblique fissure of right lung
- 12 Lower lobe of right lung
- 13 Diaphragm
- 14 Falciform ligament
- 15 Costal margin
- 16 Transverse colon
- 17 Thyroid gland
- 18 Trachea
- 19 Left internal jugular vein
- 20 Left cephalic vein
- 21 Left brachiocephalic vein
- 22 Pericardium (cut edge)
- 23 Upper lobe of left lung
- 24 Right ventricle
- 25 Left ventricle
- 26 Anterior interventricular sulcus
- 27 Lower lobe of left lung
- 28 Xiphoid process
- 29 Liver
- 30 Stomach
- 31 Pectoralis major muscle
- 32 Sternum
- 33 Left ventricle and bulb of aorta
- 34 Left main bronchus
- 35 Esophagus
- 36 Descending aorta
- 37 Spinal cord
- 38 Scapula
- 39 Right atrium
- 40 Right pulmonary vein
- 41 Right main bronchus
- 42 Azygos vein
- 43 Body of vertebra
- 44 Rib

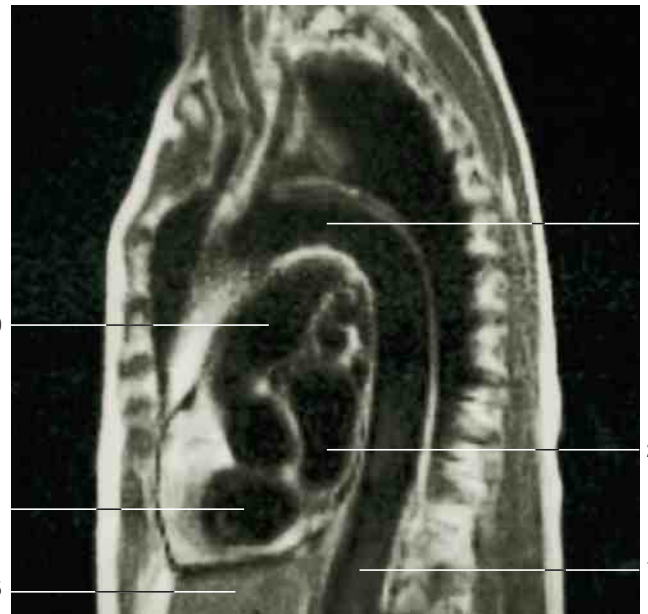Positions of thoracic organs. The anterior thoracic wall has been removed. Arrow: horizontal fissure of right lung.



Horizontal section through the thorax at the level of the seventh thoracic vertebra (from below).

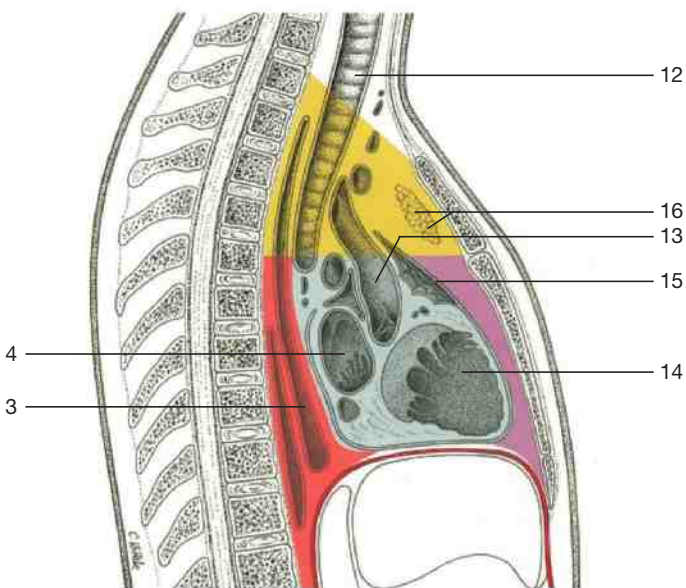


Sagittal section through the thorax, 2 cm lateral to the median plane.



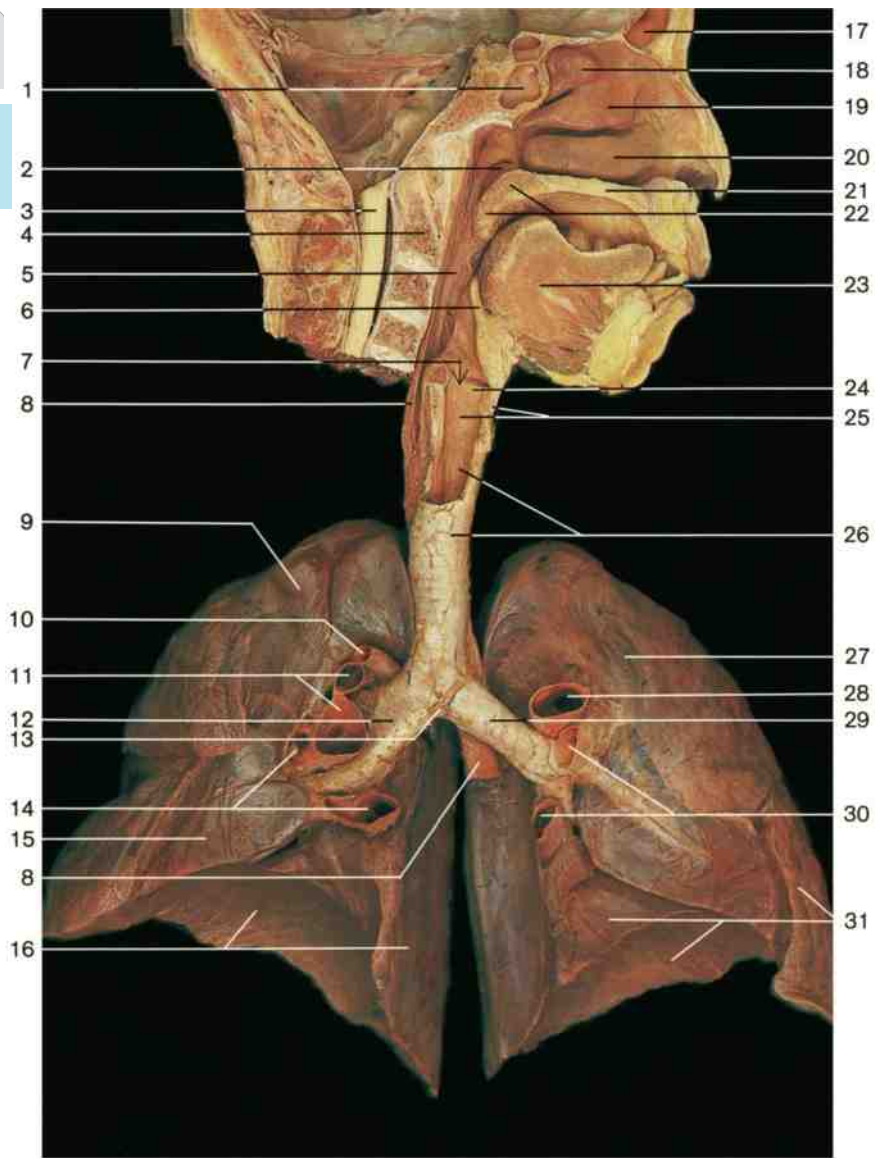
Sagittal section through the thorax (MRI scan).

- 1 Aortic arch
- 2 Left atrium of the heart
- 3 Esophagus
- 4 Right atrium of the heart
- 5 Liver
- 6 Stomach
- 7 Abdominal aorta
- 8 Transverse colon (dilated)
- 9 Lumbar vertebral body
- 10 Pulmonary trunk
- 11 Left ventricle of the heart
- 12 Trachea
- 13 Ascending aorta
- 14 Right ventricle of the heart
- 15 Pericardium
- 16 Remaining parts of thymus gland



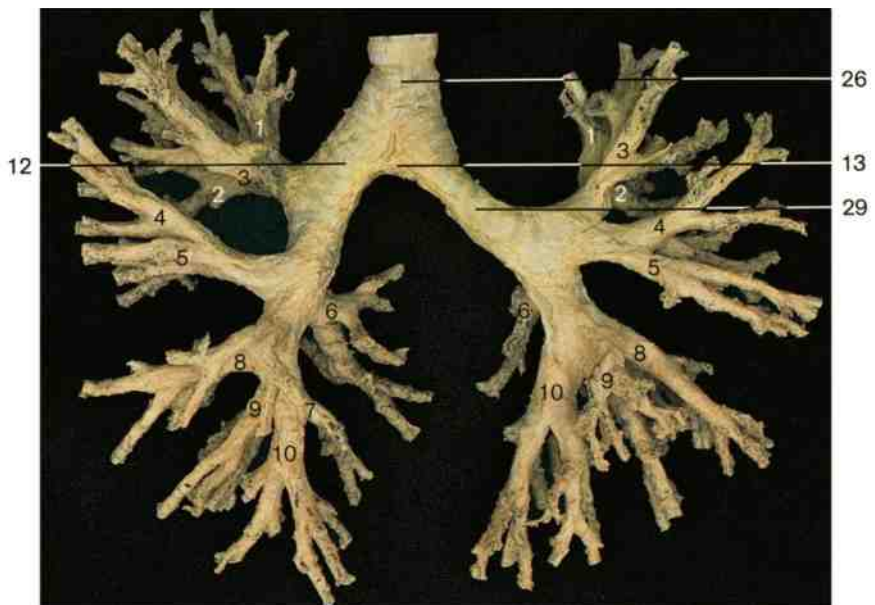
Regional anatomy of the thoracic cavity (midsagittal section). The parts of the mediastinum are indicated by colors.

Parts of mediastinum	Content
Superior mediastinum (yellow)	Trachea, brachiocephalic vein, thymus, aortic arch, esophagus, thoracic duct
Middle portion of mediastinum (light blue)	Heart, ascending aorta, pulmonary trunk, pulmonary veins, phrenic nerves
Posterior mediastinum (red)	Esophagus with vagus nerves, descending aorta, thoracic duct, sympathetic trunks
Anterior portion of mediastinum (light red)	Smaller vessels and nerves, fat and connective tissue, thymus (only in the child)



- 1 Sphenoid sinus
- 2 Pharyngeal opening of auditory tube
- 3 Spinal cord
- 4 Dens of axis
- 5 Oropharynx (oropharyngeal isthmus)
- 6 Epiglottis
- 7 Entrance of larynx
- 8 Esophagus
- 9 Upper lobe of right lung
- 10 Azygos vein
- 11 Branches of pulmonary artery
- 12 Right main bronchus
- 13 Bifurcation of trachea
- 14 Tributaries of right pulmonary veins
- 15 Middle lobe of right lung
- 16 Lower lobe of right lung
- 17 Frontal sinus
- 18 Superior nasal concha
- 19 Middle nasal concha
- 20 Inferior nasal concha
- 21 Hard palate
- 22 Soft palate with uvula
- 23 Tongue
- 24 Vocal fold
- 25 Larynx
- 26 Trachea
- 27 Upper lobe of left lung
- 28 Left pulmonary artery
- 29 Left main bronchus
- 30 Left pulmonary veins
- 31 Lower lobe of left lung

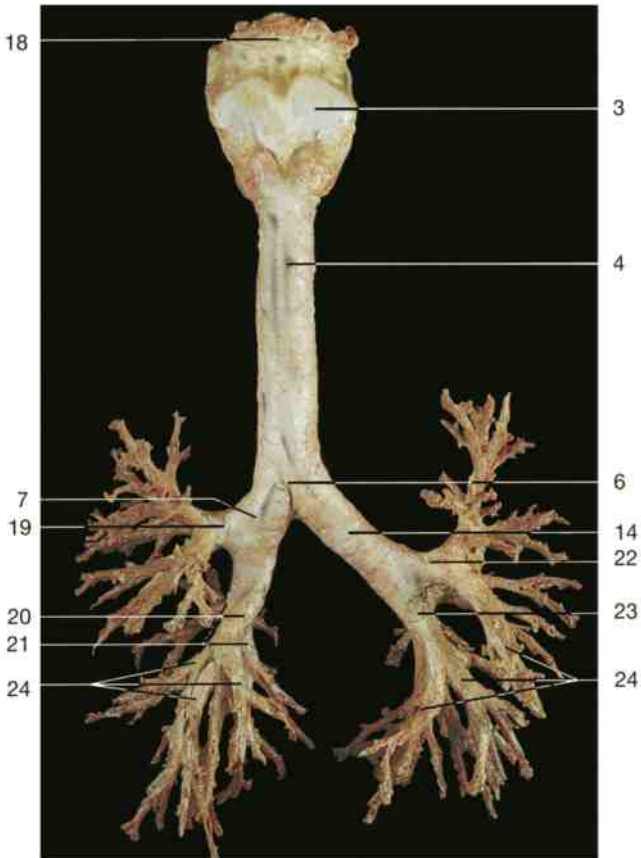
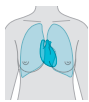
Respiratory system. The lungs have been fixed in expiration and turned laterally. Head bisected and turned laterally.



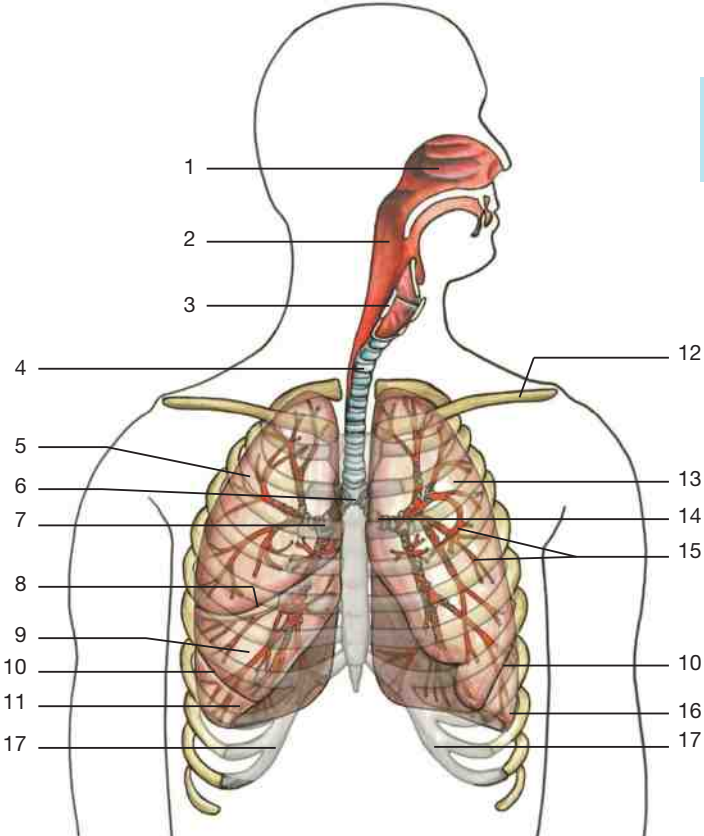
▷ **To page 247:**

- 1 Nasal cavity
- 2 Pharynx
- 3 Larynx (thyroid cartilage)
- 4 Trachea
- 5 Upper lobe of right lung
- 6 Bifurcation of trachea
- 7 Right main bronchus
- 8 Horizontal fissure of right lung
- 9 Middle lobe of right lung
- 10 Oblique fissures of lungs
- 11 Lower lobe of right lung
- 12 Clavicle
- 13 Upper lobe of left lung
- 14 Left main bronchus
- 15 Bronchi supplying bronchopulmonary segments
- 16 Lower lobe of left lung
- 17 Costal margin
- 18 Hyoid bone
- 19 Right superior lobe bronchus
- 20 Right middle lobe bronchus
- 21 Right inferior lobe bronchus
- 22 Left superior lobe bronchus
- 23 Left inferior lobe bronchus
- 24 Segmental bronchi
- 25 Branches of pulmonary arteries
- 26 Branches of pulmonary veins

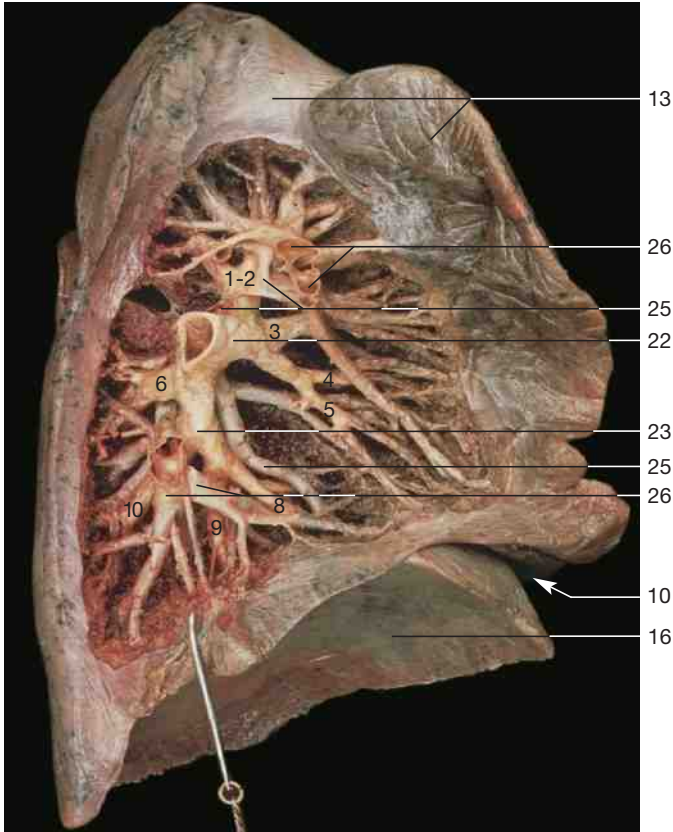
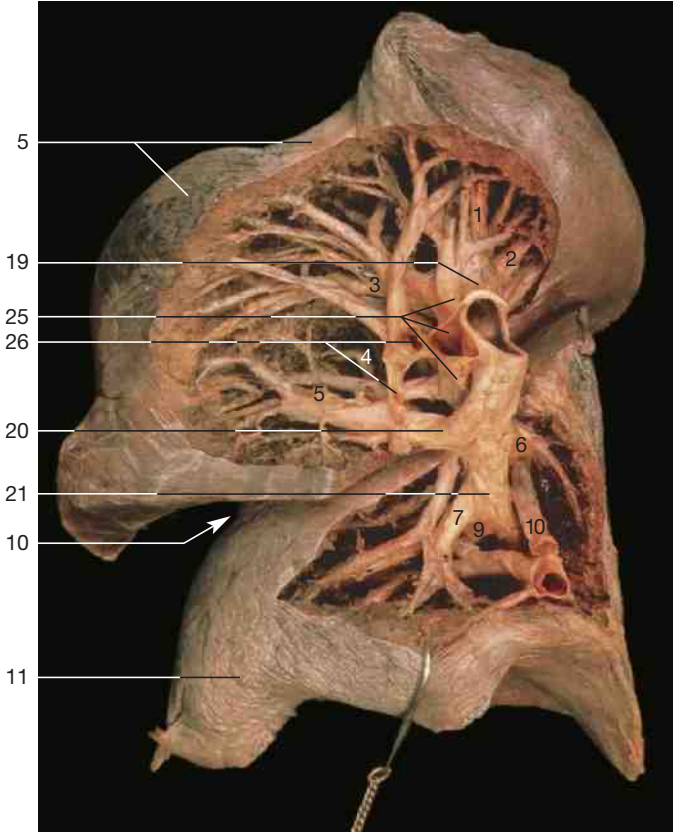
Bronchial tree (ventral aspect). The lung tissue has been removed. The bronchopulmonary segments are numbered 1–10.



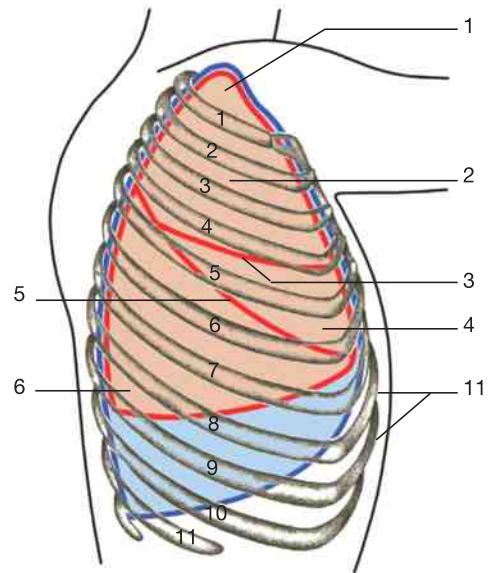
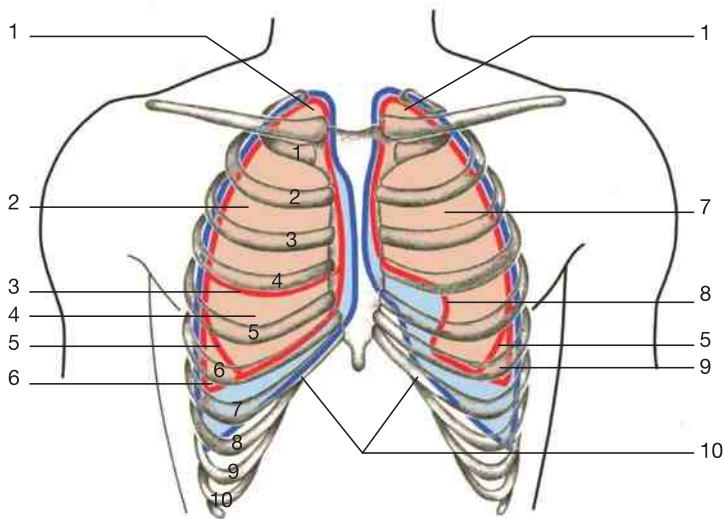
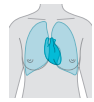
Larynx, trachea, and bronchial tree (anterior aspect).



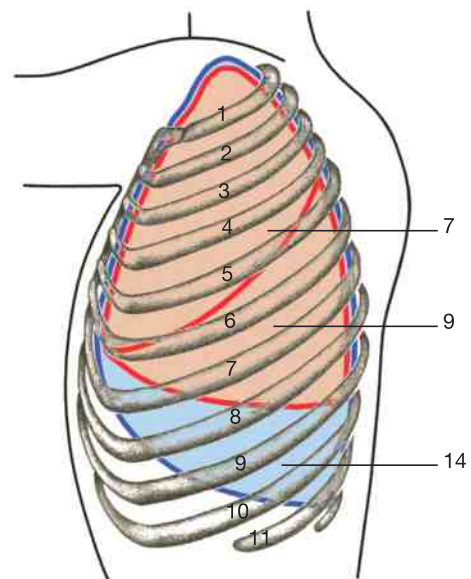
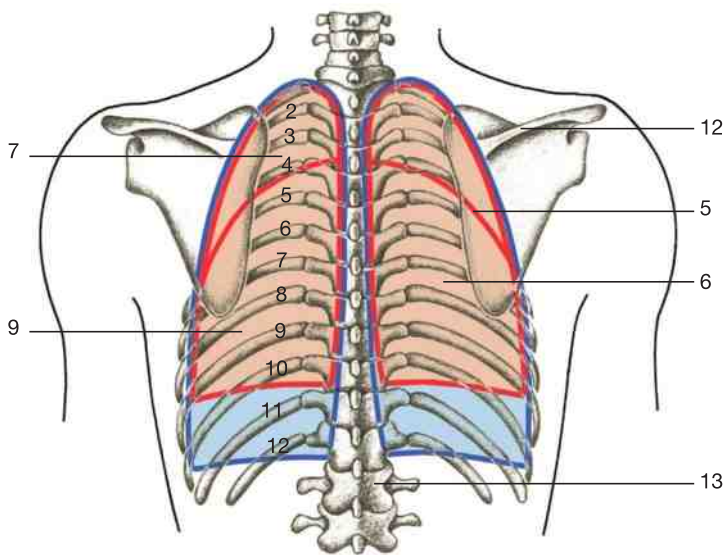
Organization and positions of respiratory organs (schematic drawing).



Mediastinal dissection of the bronchial tree, pulmonary veins, and pulmonary arteries of right lung (left) and left lung (right) (medial aspect). The bronchopulmonary segments are numbered 1–10.

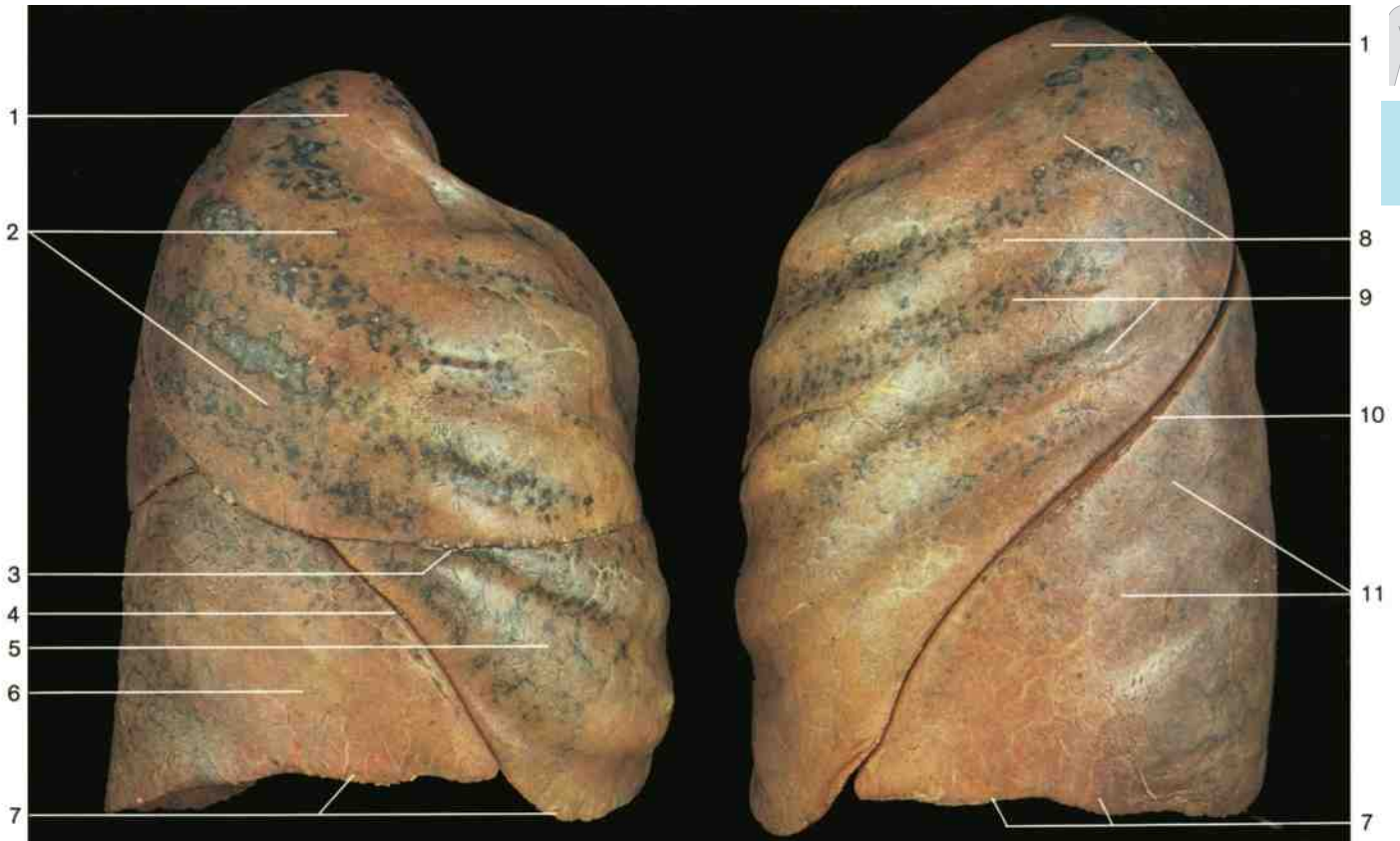

Surface projections of lungs and pleura on the thoracic wall. Left: anterior aspect; right: right-lateral aspect. Red = margins of the lung; blue = margins of pleura. The numbers indicate ribs.



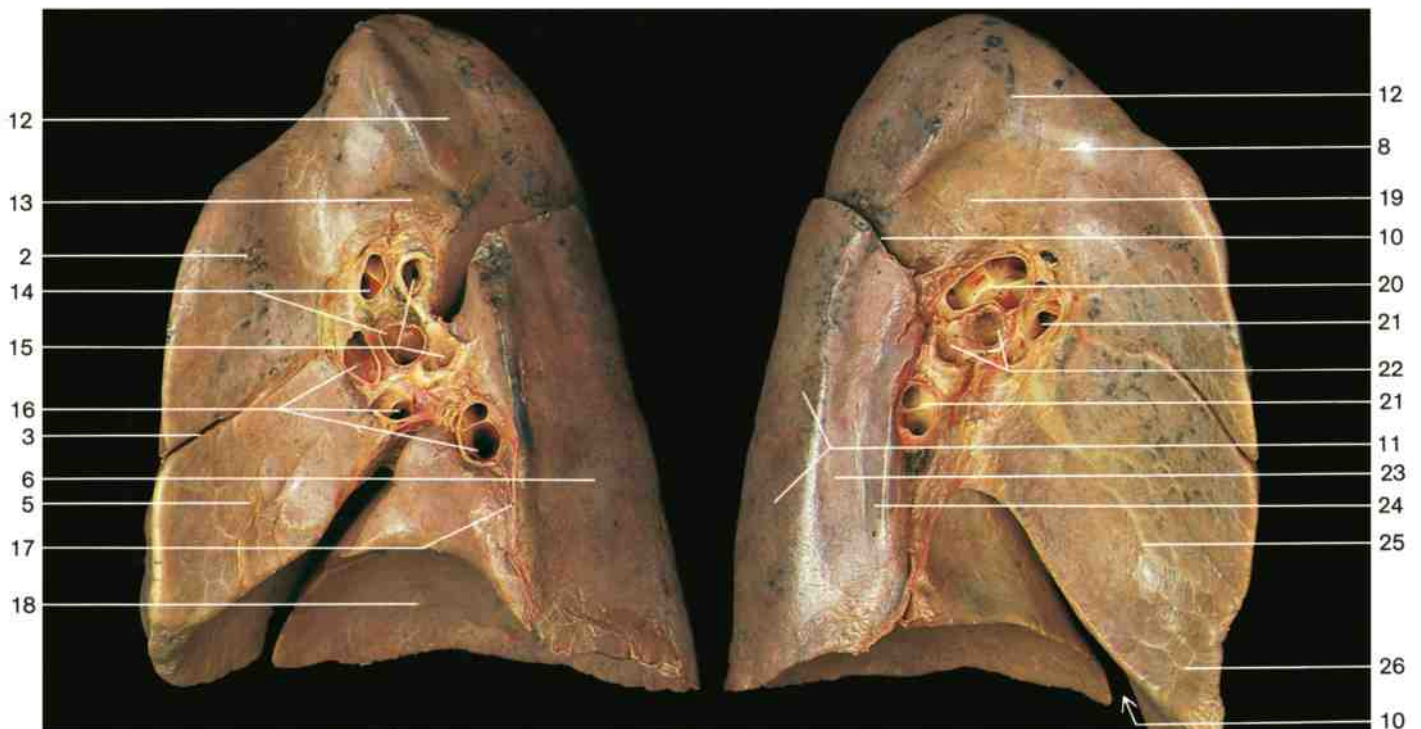
Surface projections of lungs and pleura on the thoracic wall. Left: posterior aspect; right: left-lateral aspect. Red = margins of lung; blue = margins of pleura. The numbers indicate ribs.

- | | | |
|------------------------------------|------------------------------|--|
| 1 Apex of lung | 6 Lower lobe of right lung | 11 Costal margin |
| 2 Upper lobe of right lung | 7 Upper lobe of left lung | 12 Spine of scapula |
| 3 Horizontal fissure of right lung | 8 Cardiac notch of left lung | 13 First lumbar vertebra |
| 4 Middle lobe of right lung | 9 Lower lobe of left lung | 14 Space between border of lung and pleura (costodiaphragmatic recess) |
| 5 Oblique fissures of lungs | 10 Infrasternal angle | |



Right lung (lateral aspect).

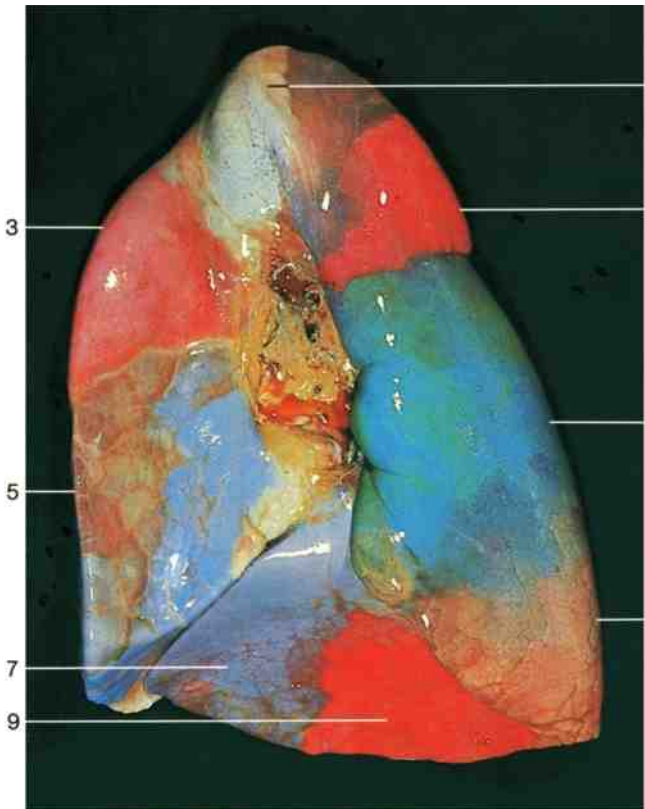
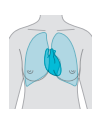
Left lung (lateral aspect).



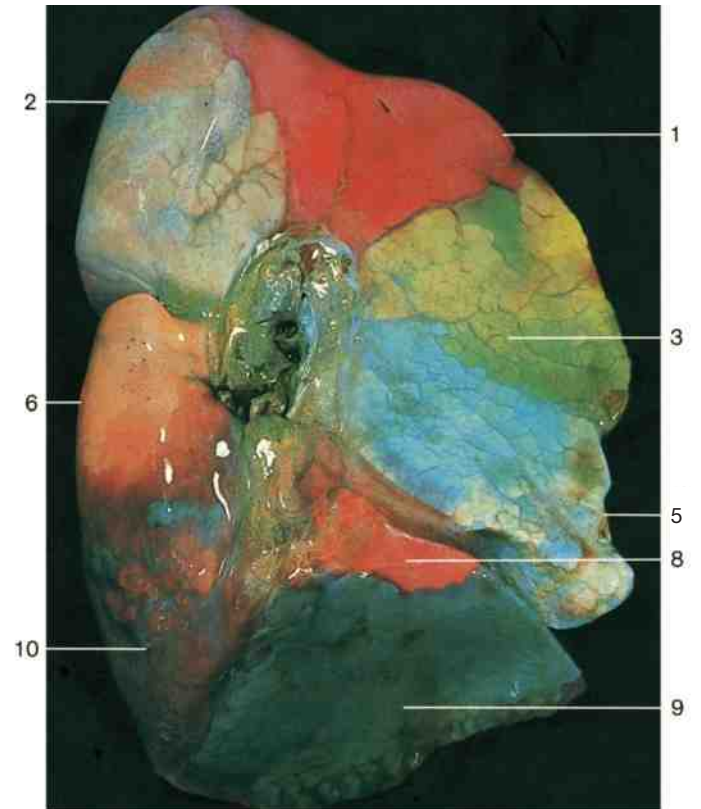
Right lung (medial aspect).

Left lung (medial aspect).

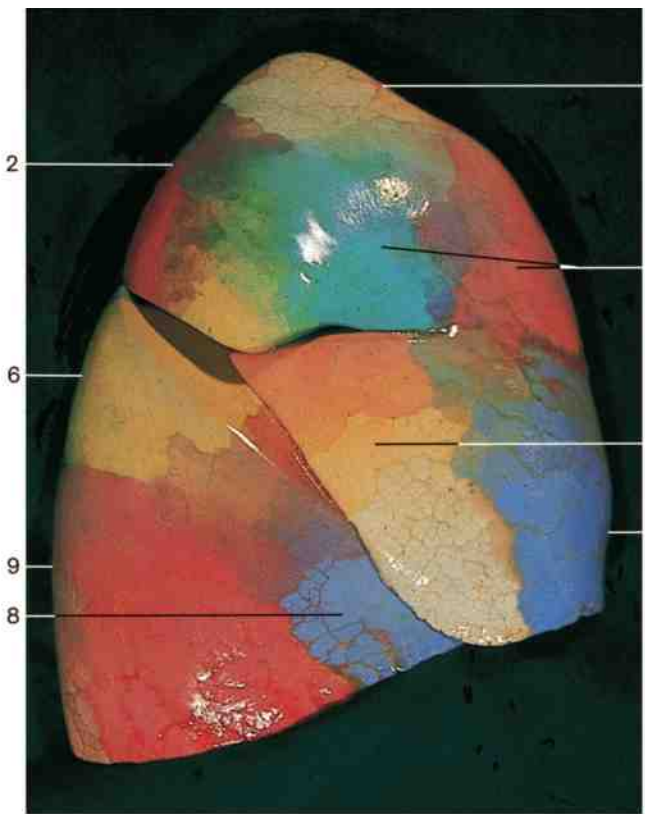
- | | | | |
|------------------------------------|---------------------------------------|-------------------------------------|-----------------------------|
| 1 Apex of lung | 8 Upper lobe of left lung | 15 Bronchi | 22 Left secondary bronchi |
| 2 Upper lobe of right lung | 9 Impressions of ribs | 16 Right pulmonary veins | 23 Groove of thoracic aorta |
| 3 Horizontal fissure of right lung | 10 Oblique fissure of left lung | 17 Pulmonary ligament | 24 Groove of esophagus |
| 4 Oblique fissure of right lung | 11 Lower lobe of left lung | 18 Diaphragmatic surface | 25 Cardiac impression |
| 5 Middle lobe of right lung | 12 Groove of subclavian artery | 19 Groove of aortic arch | 26 Lingula |
| 6 Lower lobe of right lung | 13 Groove of azygos arch | 20 Left pulmonary artery | |
| 7 Inferior border | 14 Branches of right pulmonary artery | 21 Branches of left pulmonary veins | |



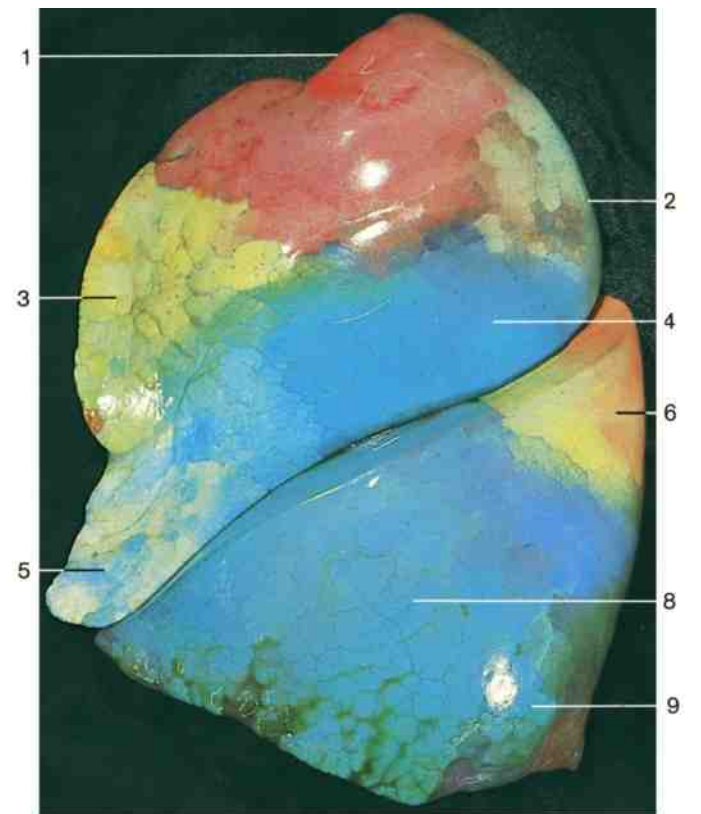
Right lung (medial aspect).



Left lung (medial aspect).



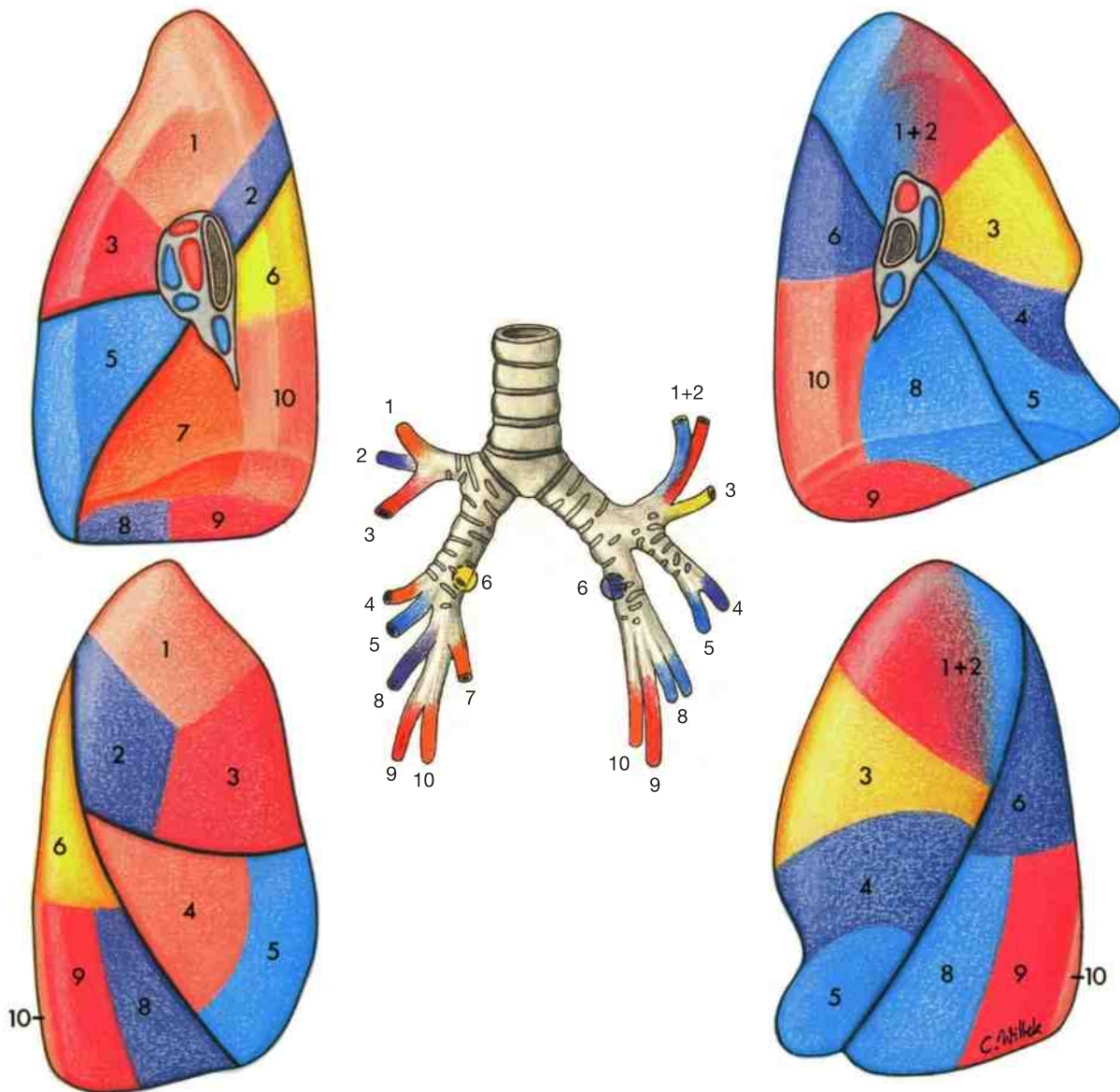
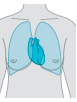Right lung (lateral aspect).



Left lung (lateral aspect).

The bronchopulmonary segments of the lungs are differentiated by the various colors. Notice that there is no segment in the left lung that corresponds to the seventh

segment of the right lung. Compare with the schematic drawing on the facing page.

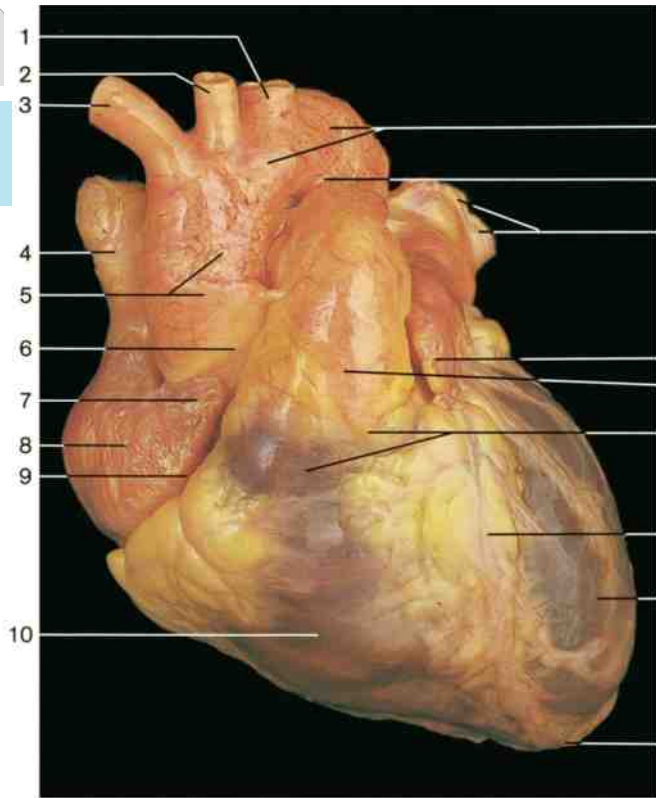


Distribution of bronchopulmonary segments of the lungs and their relation to the bronchial tree (after J. F. Huber).

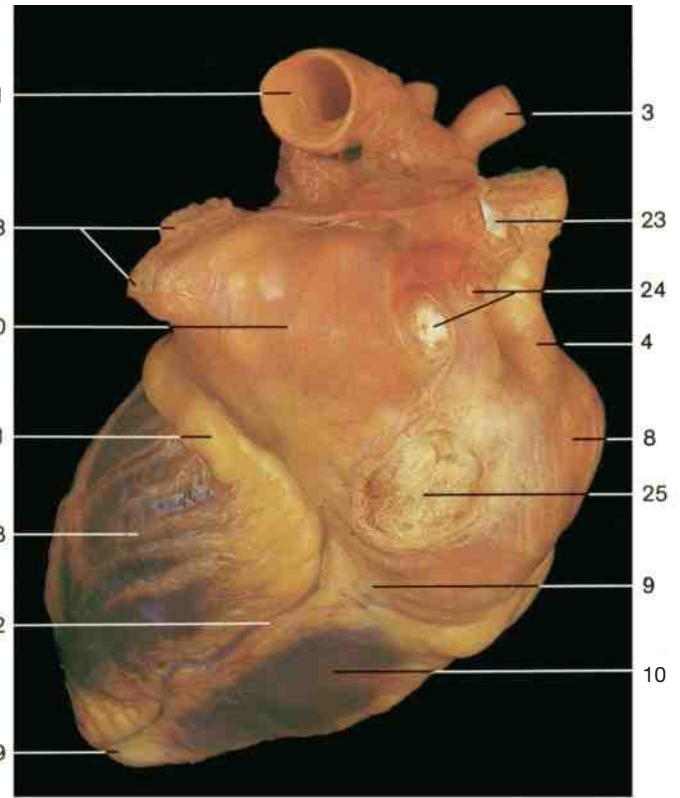
The bronchopulmonary segments are morphologically and functionally separate, independent respiratory units of the lung tissue. Each segment is surrounded by connective tissue that is continuous with the visceral pleura. The segmental bronchi are centrally located in each segment and are closely accompanied by branches of the pulmonary

arteries, whereas the tributaries of the pulmonary veins run **between** the segments. Thus, the veins serve two adjacent segments that drain for the most part into more than one vein. A bronchopulmonary segment is therefore not a complete vascular unit, but segmentation is the result of a specific architecture of the lung vasculature.

Right lung	Left lung				
1 Apical segment 2 Posterior segment 3 Anterior segment <table style="display: inline-table; vertical-align: middle;"> <tr> <td style="font-size: 2em;">}</td> <td>Upper lobe bronchus</td> </tr> </table>	}	Upper lobe bronchus	1+2 Apicoposterior segment 3 Anterior segment <table style="display: inline-table; vertical-align: middle;"> <tr> <td style="font-size: 2em;">}</td> <td>Superior division</td> </tr> </table>	}	Superior division
}	Upper lobe bronchus				
}	Superior division				
4 Lateral segment 5 Medial segment <table style="display: inline-table; vertical-align: middle;"> <tr> <td style="font-size: 2em;">}</td> <td>Middle lobe bronchus</td> </tr> </table>	}	Middle lobe bronchus	4 Superior lingular segment 5 Inferior lingular segment <table style="display: inline-table; vertical-align: middle;"> <tr> <td style="font-size: 2em;">}</td> <td>Inferior division</td> </tr> </table>	}	Inferior division
}	Middle lobe bronchus				
}	Inferior division				
6 Superior (apical) segment 7 Medial basal segment 8 Anterior basal segment 9 Lateral basal segment 10 Posterior basal segment <table style="display: inline-table; vertical-align: middle;"> <tr> <td style="font-size: 2em;">}</td> <td>Lower lobe bronchus</td> </tr> </table>	}	Lower lobe bronchus	6 Superior (apical) segment 7 Absent 8 Anteromedial basal segment 9 Lateral basal segment 10 Posterior basal segment <table style="display: inline-table; vertical-align: middle;"> <tr> <td style="font-size: 2em;">}</td> <td>Lower lobe bronchus</td> </tr> </table>	}	Lower lobe bronchus
}	Lower lobe bronchus				
}	Lower lobe bronchus				



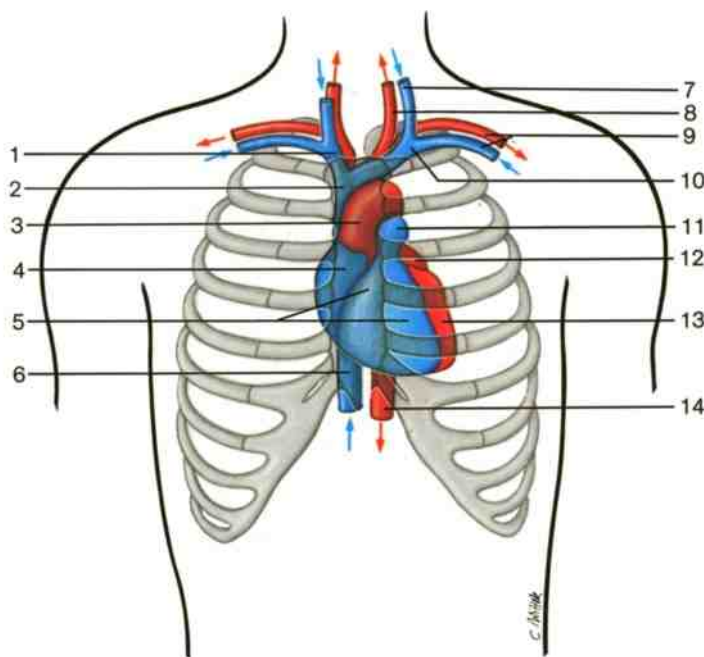
Heart of 30-year-old woman (anterior aspect).



Heart of 30-year-old woman (oblique-posterior view).

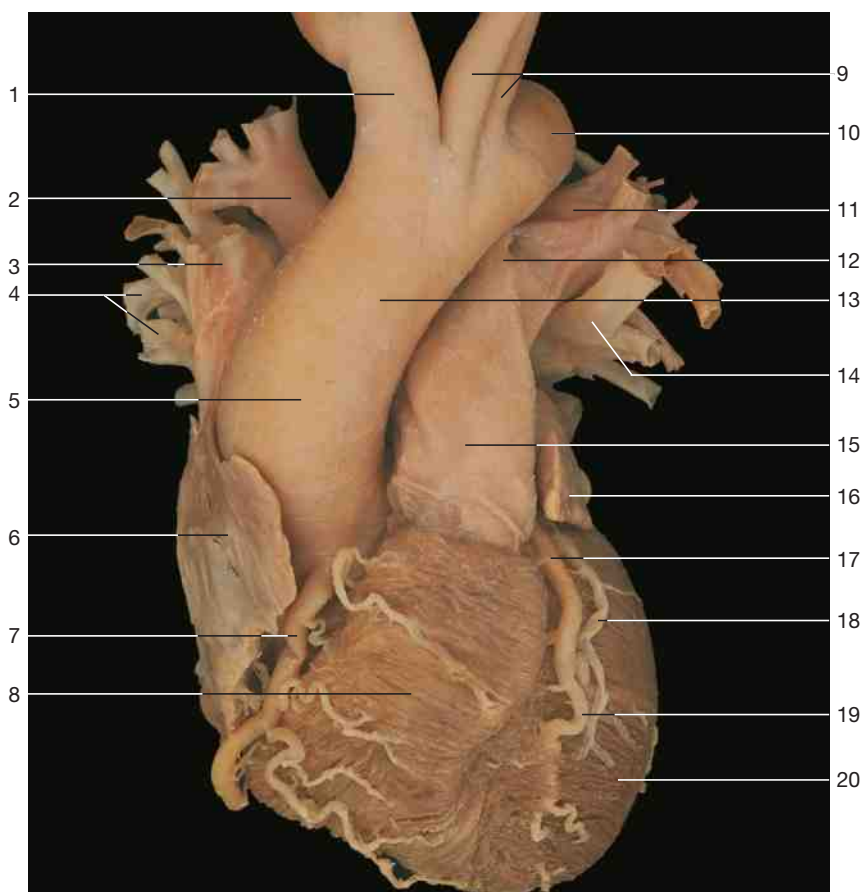
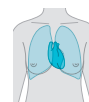- | | |
|------------------------------|-------------------------------------|
| 1 Left subclavian artery | 9 Coronary sulcus |
| 2 Left common carotid artery | 10 Right ventricle |
| 3 Brachiocephalic trunk | 11 Aortic arch |
| 4 Superior vena cava | 12 Ligamentum arteriosum |
| 5 Ascending aorta | 13 Left pulmonary veins |
| 6 Bulb of the aorta | 14 Left auricle |
| 7 Right auricle | 15 Pulmonary trunk |
| 8 Right atrium | 16 Sinus of pulmonary trunk |
| | 17 Anterior interventricular sulcus |

- | |
|--|
| 18 Left ventricle |
| 19 Apex of the heart |
| 20 Left atrium |
| 21 Epicardial fat overlying coronary sinus |
| 22 Posterior interventricular sulcus |
| 23 Right pulmonary artery |
| 24 Right pulmonary veins |
| 25 Inferior vena cava |



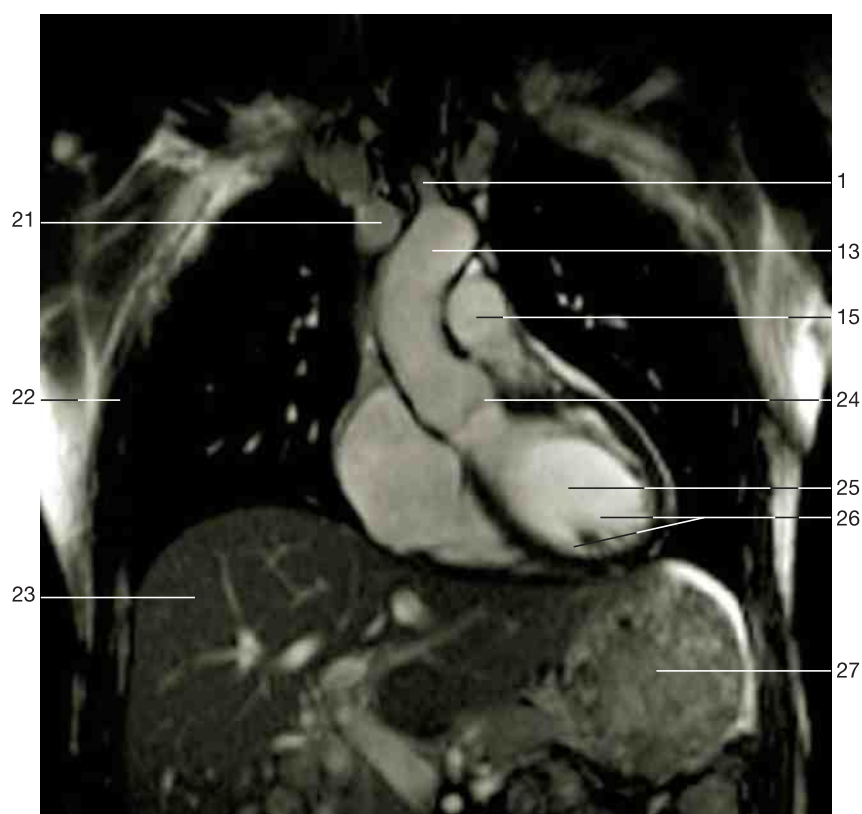
Position of heart and its vessels within the thorax (schematic drawing).

- | |
|---------------------------------|
| 1 Right brachiocephalic vein |
| 2 Superior vena cava |
| 3 Ascending aorta |
| 4 Right atrium |
| 5 Right ventricle |
| 6 Inferior vena cava |
| 7 Left internal jugular vein |
| 8 Left common carotid artery |
| 9 Left axillary artery and vein |
| 10 Left brachiocephalic vein |
| 11 Pulmonary trunk |
| 12 Left auricle |
| 13 Left ventricle |
| 14 Descending aorta |

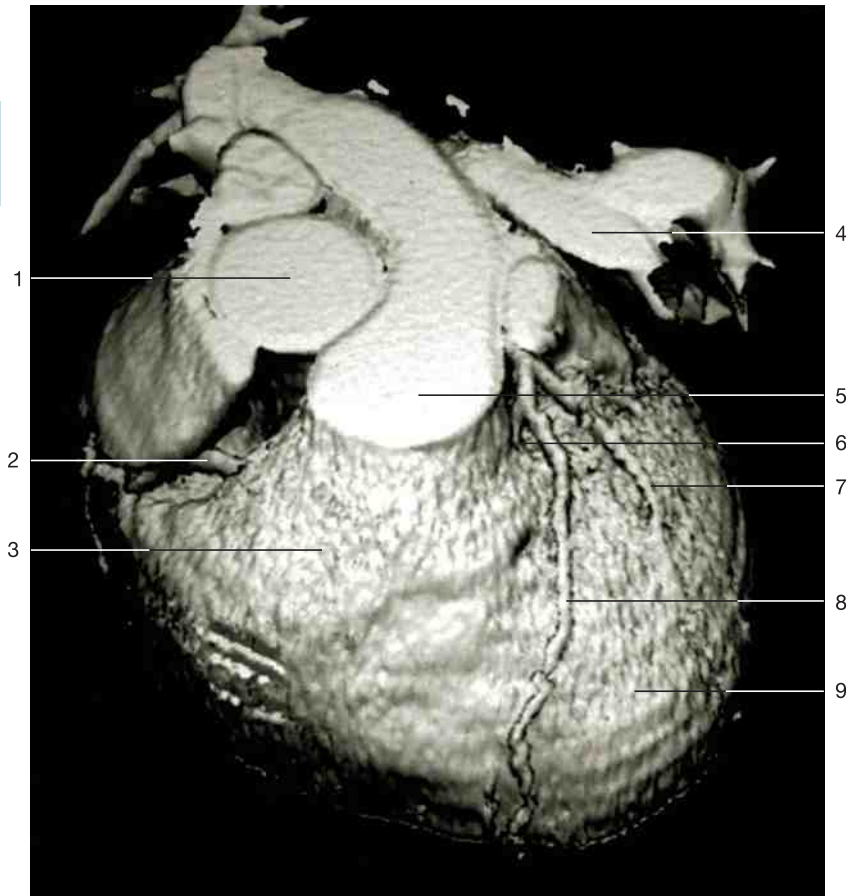
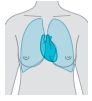

- 1 Brachiocephalic trunk
- 2 Right pulmonary artery
- 3 Superior vena cava
- 4 Right pulmonary veins
- 5 Ascending aorta
- 6 Right atrium
- 7 Right coronary artery
- 8 Right ventricle
- 9 Left common carotid artery and left subclavian artery
- 10 Descending aorta (thoracic part)
- 11 Ligamentum arteriosum (remnant of ductus arteriosus Botalli)
- 12 Left pulmonary artery
- 13 Aortic arch
- 14 Left pulmonary veins
- 15 Pulmonary trunk
- 16 Left atrium
- 17 Left coronary artery
- 18 Diagonal branch of left coronary artery
- 19 Interventricular branch of left coronary artery
- 20 Left ventricle
- 21 Right brachiocephalic vein
- 22 Thoracic wall
- 23 Liver
- 24 Aortic valve
- 25 Chordae tendineae
- 26 Papillary muscles
- 27 Stomach

Heart with related vessels. Dissection of coronary arteries (anterior aspect, systolic phase of heart action).

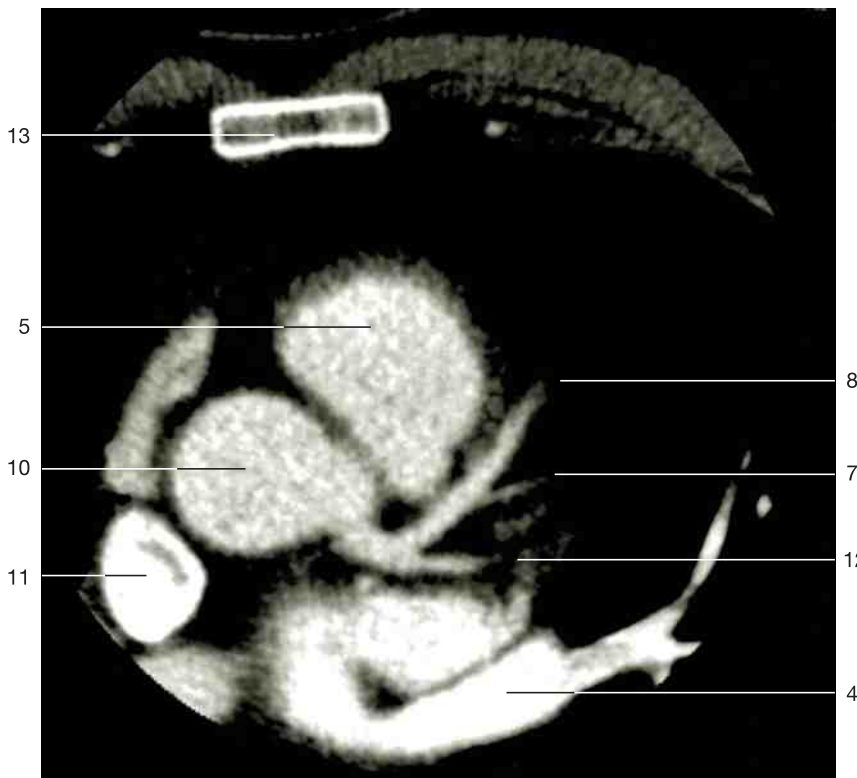


Coronal section through the thorax at the level of the ascending aorta (MRI scan, courtesy of Prof. W. Bautz and R. Janka, M. D., University of Erlangen, Germany).



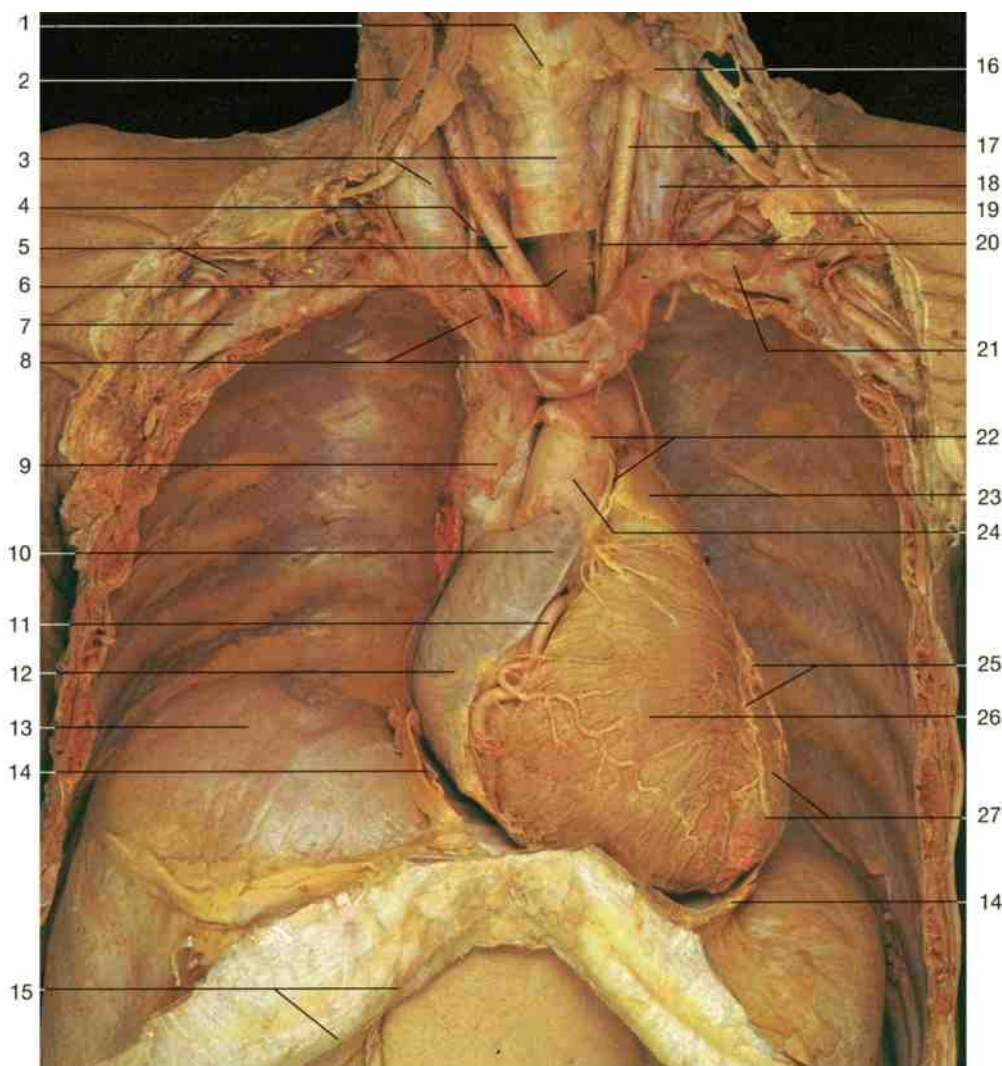
- 1 Ascending aorta
- 2 Right coronary artery
- 3 Right ventricle
- 4 Left atrium
- 5 Pulmonary trunk
- 6 Septal branch of left coronary artery
- 7 Diagonal branch
- 8 Anterior interventricular branch of left coronary artery
- 9 Left ventricle
- 10 Aortic root
- 11 Superior vena cava
- 12 Circumflex branch of left coronary artery
- 13 Sternum

Human heart (3-D reconstruction of electron beam CT scans as "Shaded Surface Display"¹).



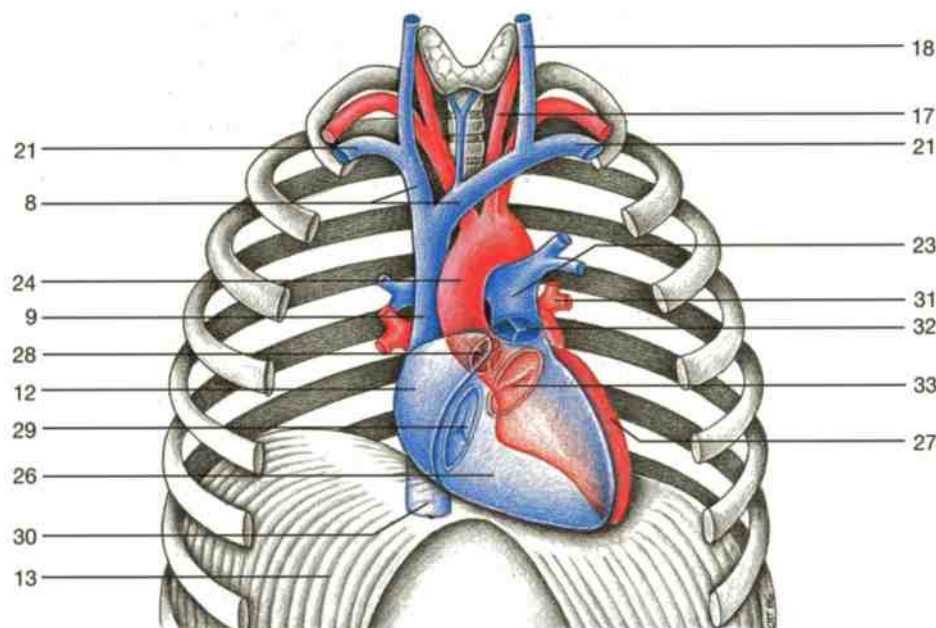
Electron beam tomographic image of the human heart (axial section after injection of contrast medium¹).

¹ Courtesy of Drs. W. Moshage, S. Achenbach, and D. Ropers, Dept. of Internal Medicine II, University of Erlangen-Nürnberg, Germany.

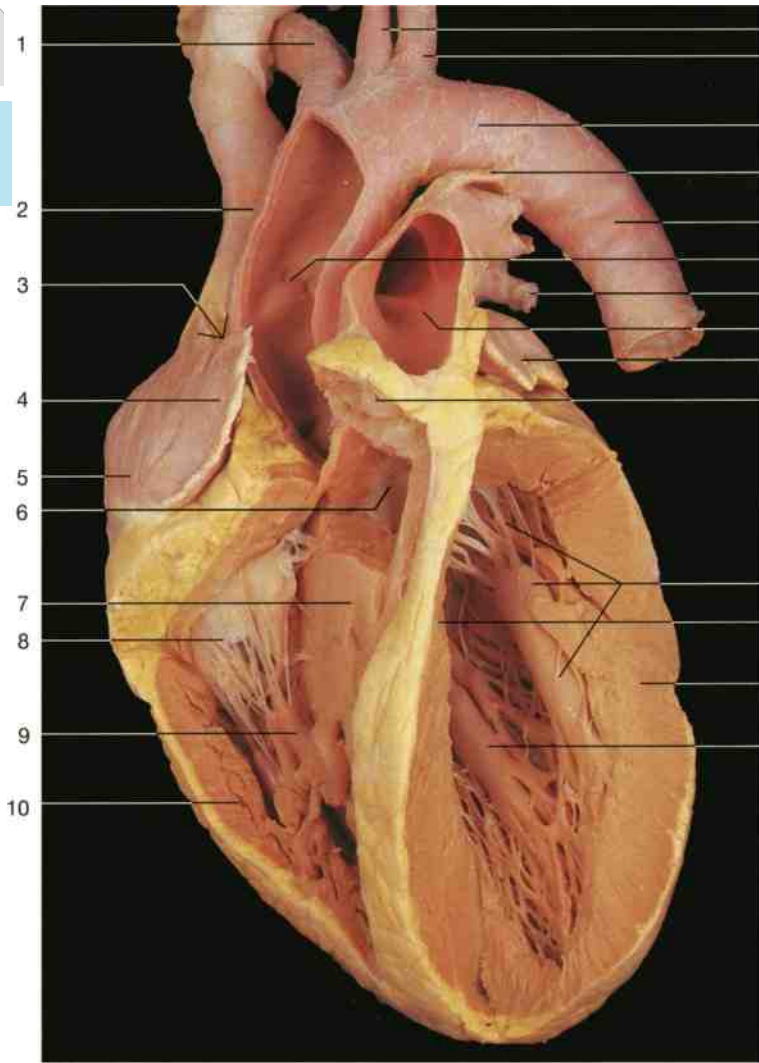


- 1 Larynx (thyroid cartilage)
- 2 Sternocleidomastoid muscle (divided)
- 3 Trachea (divided) and right internal jugular vein
- 4 Vagus nerve
- 5 Right common carotid artery and cephalic vein
- 6 Esophagus
- 7 Right axillary vein
- 8 Right and left brachiocephalic veins
- 9 Superior vena cava
- 10 Right auricle
- 11 Right coronary artery
- 12 Right atrium
- 13 Diaphragm
- 14 Pericardium (cut edges)
- 15 Costal margin
- 16 Omohyoid muscle
- 17 Left common carotid artery
- 18 Left internal jugular vein
- 19 Clavicle (divided)
- 20 Left recurrent laryngeal nerve
- 21 Subclavian vein
- 22 Pericardial reflection
- 23 Pulmonary trunk
- 24 Ascending aorta
- 25 Anterior interventricular sulcus and anterior interventricular branch of left coronary artery
- 26 Right ventricle
- 27 Left ventricle
- 28 Aortic valve
- 29 Tricuspid or right atrioventricular valve
- 30 Inferior vena cava
- 31 Pulmonary veins
- 32 Pulmonary valve
- 33 Left atrioventricular (bicuspid or mitral) valve

Heart and related vessels in situ (anterior aspect). Anterior thoracic wall, pericardium, and epicardium have been removed; trachea divided.

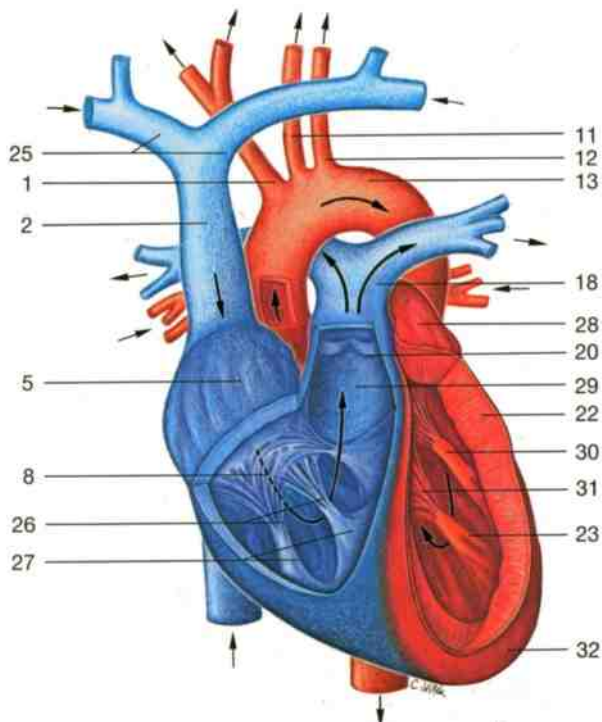


Heart in situ. Position of valves (anterior aspect). (Schematic drawing.)

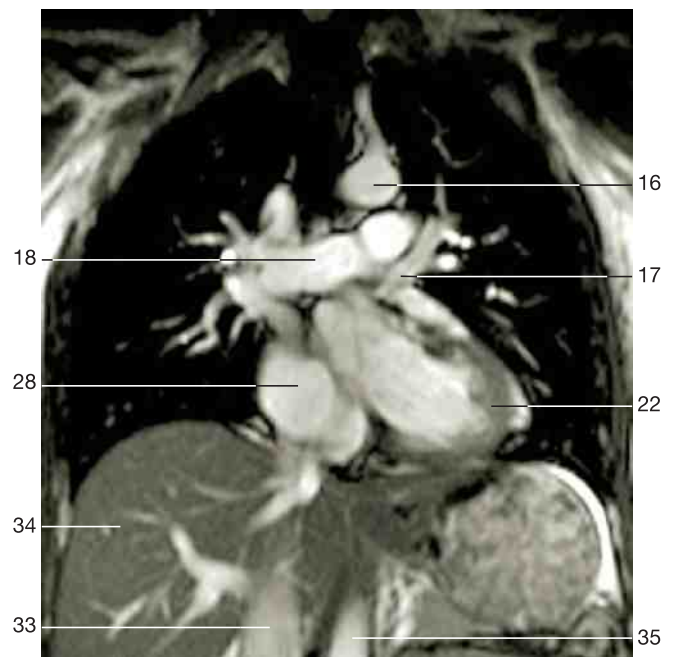

- 1 Brachiocephalic trunk
- 2 Superior vena cava
- 3 Sulcus terminalis
- 4 Right auricle
- 5 Right atrium
- 6 Aortic valve
- 7 Conus arteriosus (interventricular septum)
- 8 Right atrioventricular (tricuspid) valve
- 9 Anterior papillary muscle
- 10 Myocardium of right ventricle
- 11 Left common carotid artery
- 12 Left subclavian artery
- 13 Aortic arch
- 14 Ligamentum arteriosum (remnant of ductus arteriosus)
- 15 Thoracic aorta (descending aorta)
- 16 Ascending aorta
- 17 Left pulmonary vein
- 18 Pulmonary trunk
- 19 Left auricle
- 20 Pulmonic valve
- 21 Anterior papillary muscle with chordae tendineae
- 22 Myocardium of left ventricle
- 23 Posterior papillary muscle
- 24 Interventricular septum
- 25 Right and left brachiocephalic veins
- 26 Chordae tendineae
- 27 Papillary muscles of right ventricle
- 28 Left atrium
- 29 Infundibulum
- 30 Anterior papillary muscle of left ventricle
- 31 Left atrioventricular (bicuspid or mitral) valve and chordae tendineae
- 32 Apex of heart
- 33 Inferior vena cava
- 34 Liver
- 35 Aorta (pars abdominalis)

Anterior aspect of the heart. Dissection of the four valves.



Circulation within the heart (anterior aspect).
Arrows = direction of blood flow.

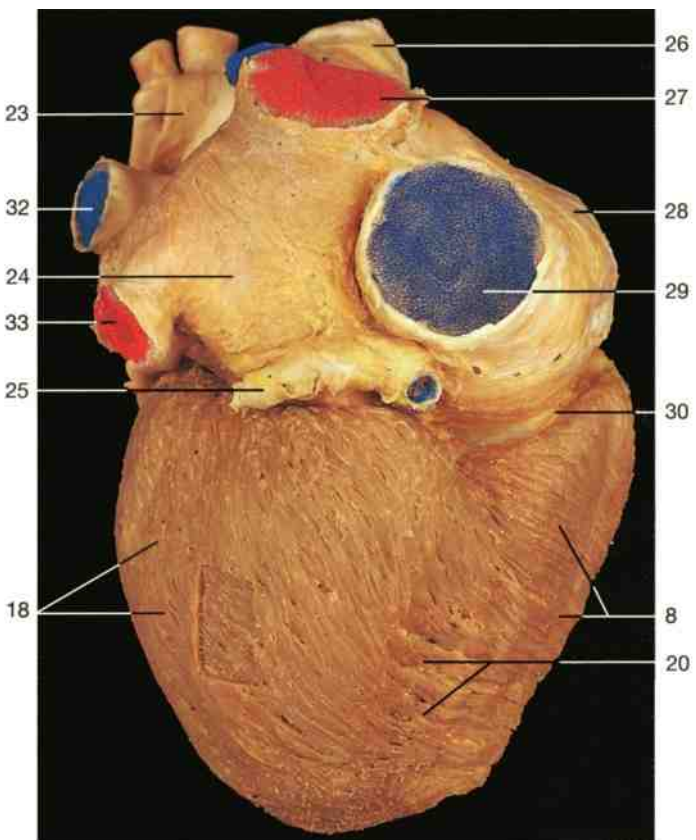
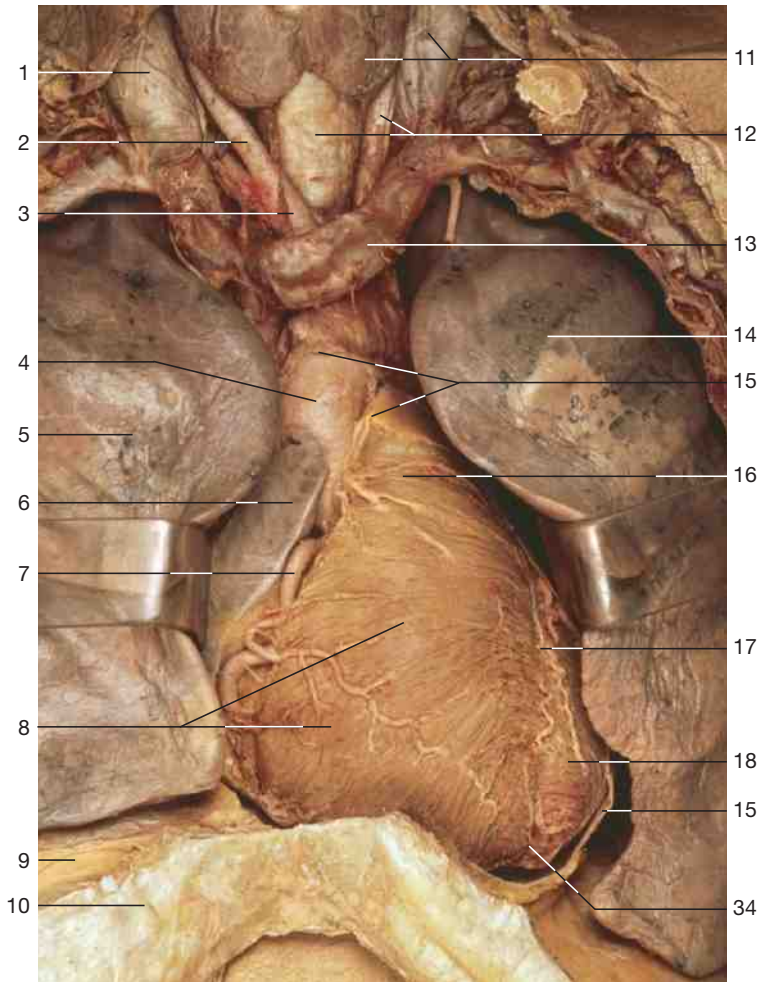


MRI scan of the heart (coronal section at the level of the left atrium; courtesy of Prof. W. Bautz and R. Janka, M. D., University of Erlangen, Germany).

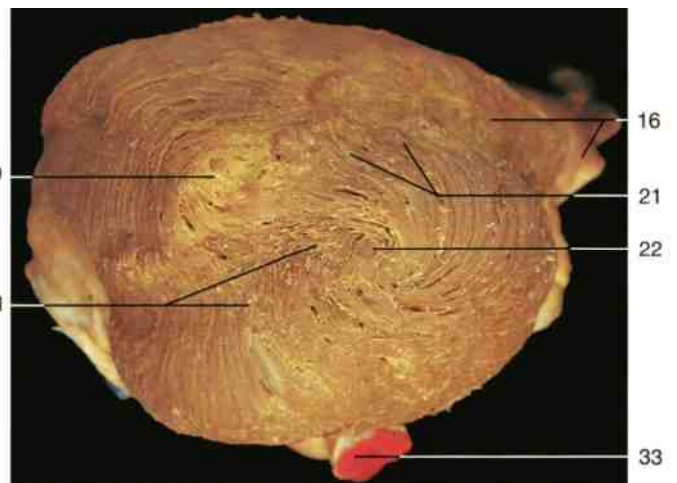


Heart in situ. Myocardium and coronary arteries (anterior aspect).

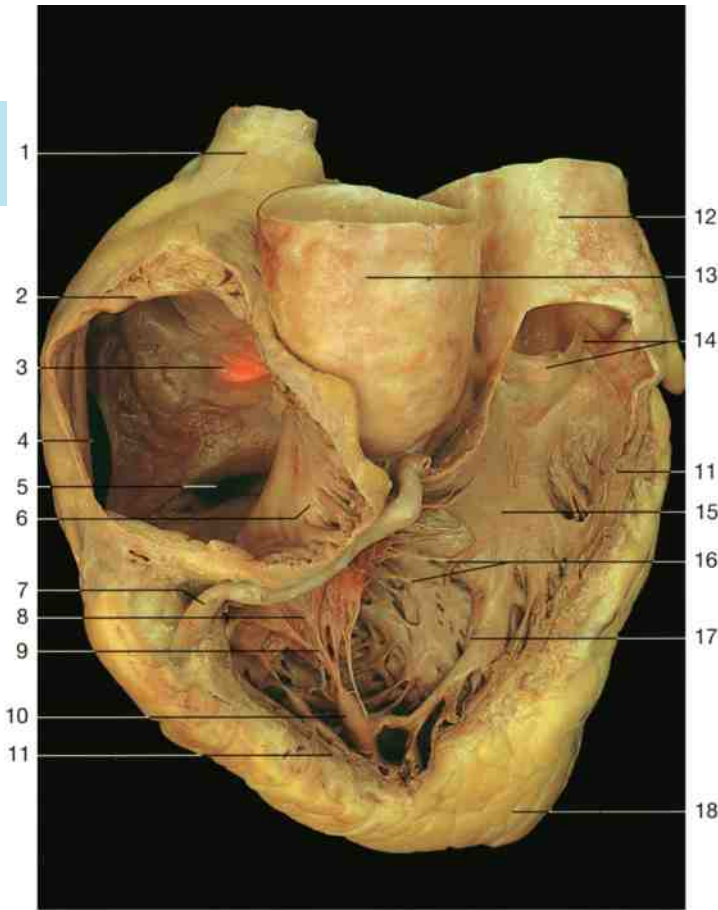
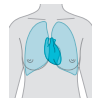
- 1 Internal jugular vein
- 2 Common carotid artery
- 3 Brachiocephalic trunk
- 4 Ascending aorta
- 5 Right lung
- 6 Right auricle
- 7 Right coronary artery
- 8 Myocardium of right ventricle
- 9 Diaphragm
- 10 Costal margin
- 11 Thyroid gland and internal jugular vein
- 12 Trachea and left common carotid artery
- 13 Left brachiocephalic vein
- 14 Left lung
- 15 Pericardium (cut edge)
- 16 Pulmonary trunk
- 17 Anterior interventricular artery
- 18 Myocardium of left ventricle
- 19 Muscular vortex (right ventricle)
- 20 Posterior interventricular sulcus
- 21 Anterior interventricular sulcus
- 22 Muscular vortex (left ventricle)
- 23 Aortic arch
- 24 Left atrium
- 25 Coronary sinus
- 26 Superior vena cava
- 27 Right pulmonary vein
- 28 Right atrium
- 29 Inferior vena cava
- 30 Coronary sulcus
- 31 Myocardium of left ventricle
- 32 Left pulmonary artery
- 33 Left pulmonary vein
- 34 Apex of heart



Heart (posterior aspect). The myocardium of the left ventricle has been fenestrated to show the muscle fiber bundles of the deeper layer with their more circular course.

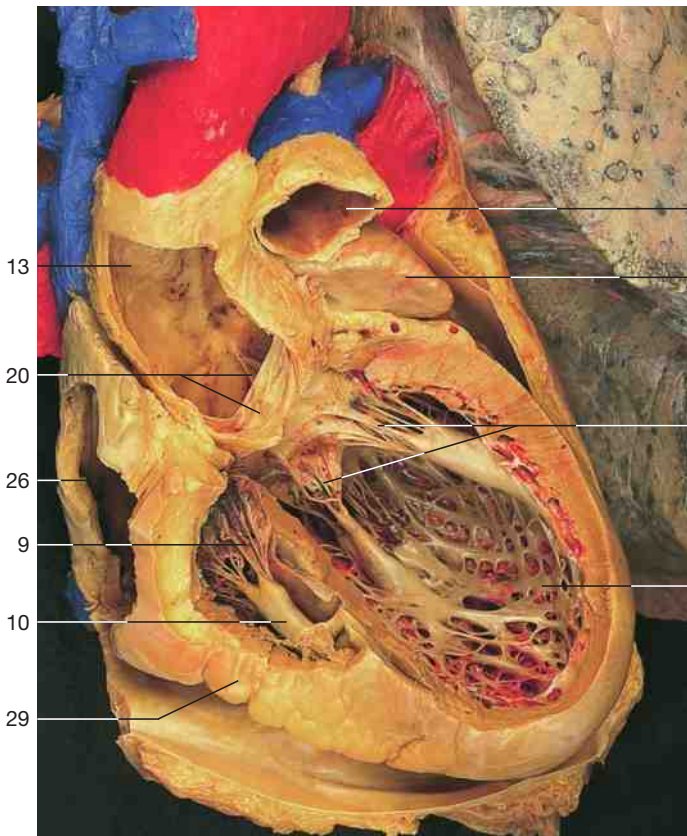


Vortex of cardiac muscle fibers (from below).

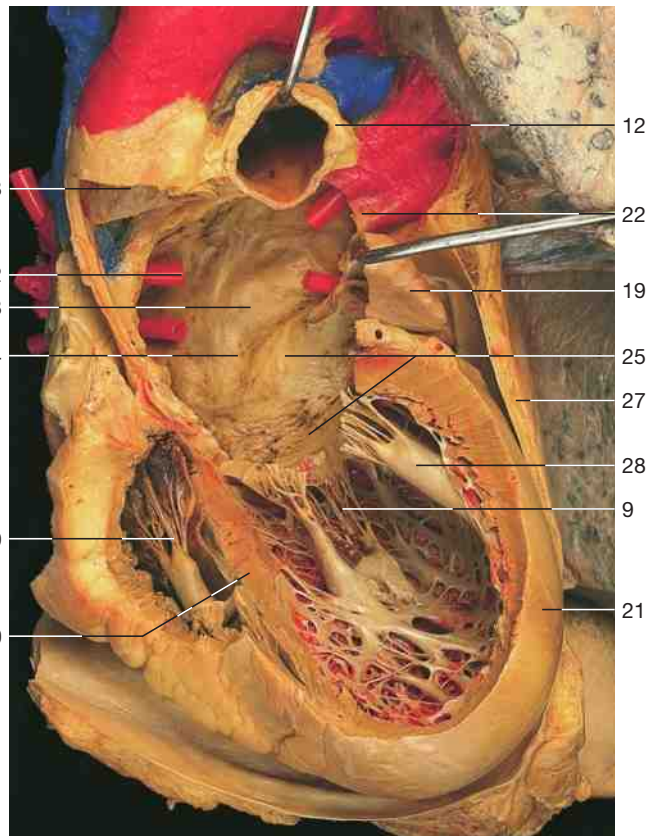


- 1 Superior vena cava
- 2 Crista terminalis
- 3 Fossa ovalis
- 4 Opening of inferior vena cava
- 5 Opening of coronary sinus
- 6 Right auricle
- 7 Right coronary artery and coronary sulcus
- 8 Anterior cusp of tricuspid valve
- 9 Chordae tendineae
- 10 Anterior papillary muscle
- 11 Myocardium
- 12 Pulmonary trunk
- 13 Ascending aorta
- 14 Pulmonic valve
- 15 Conus arteriosus (interventricular septum)
- 16 Septal papillary muscles
- 17 Septomarginal trabecula or moderator band
- 18 Apex of heart
- 19 Left auricle
- 20 Aortic valve
- 21 Left ventricle
- 22 Pulmonary veins
- 23 Position of fossa ovalis
- 24 Left atrium
- 25 Left atrioventricular (bicuspid or mitral) valve
- 26 Right atrium
- 27 Pericardium
- 28 Posterior papillary muscle
- 29 Right ventricle
- 30 Interventricular septum

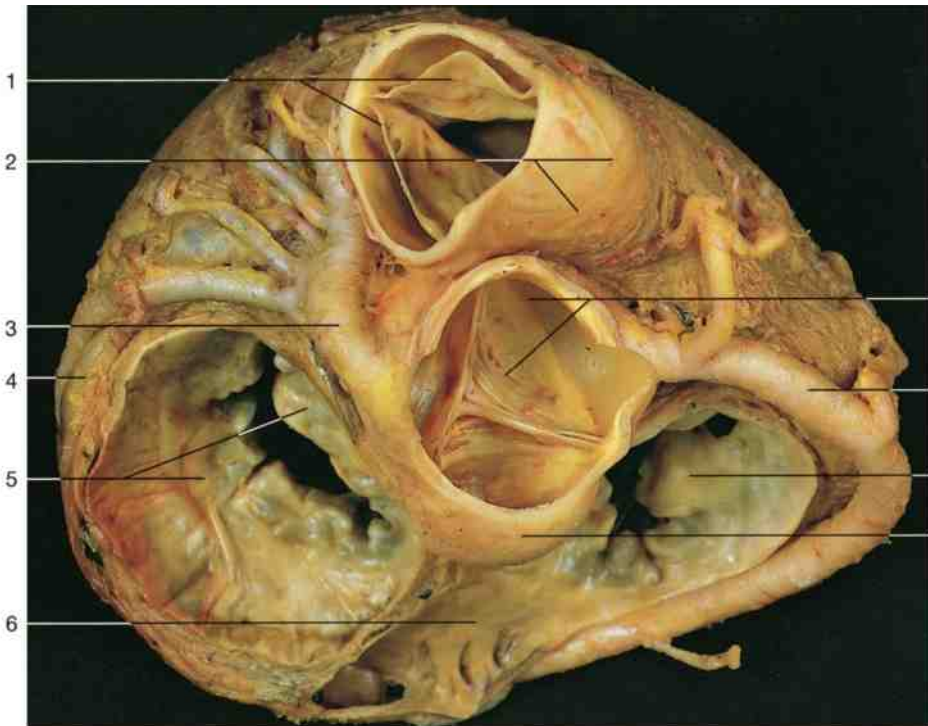
Right heart (anterior aspect). Anterior wall of right atrium and ventricle removed.



Heart, left ventricle with mitral valve, papillary muscles, and aortic valve (anterior portion of the heart removed).

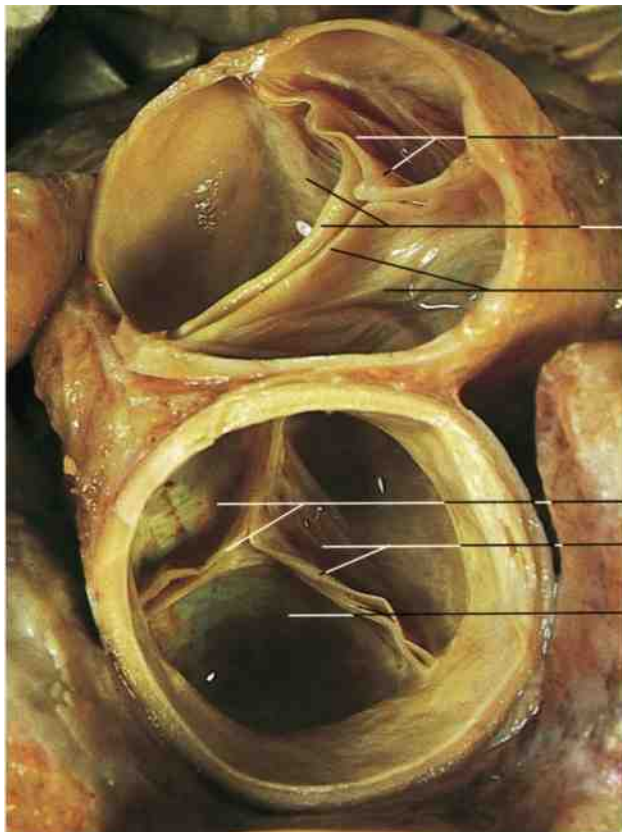


Heart, left ventricle, and atrium (opened) showing the posterior part of the mitral valve with papillary muscles.

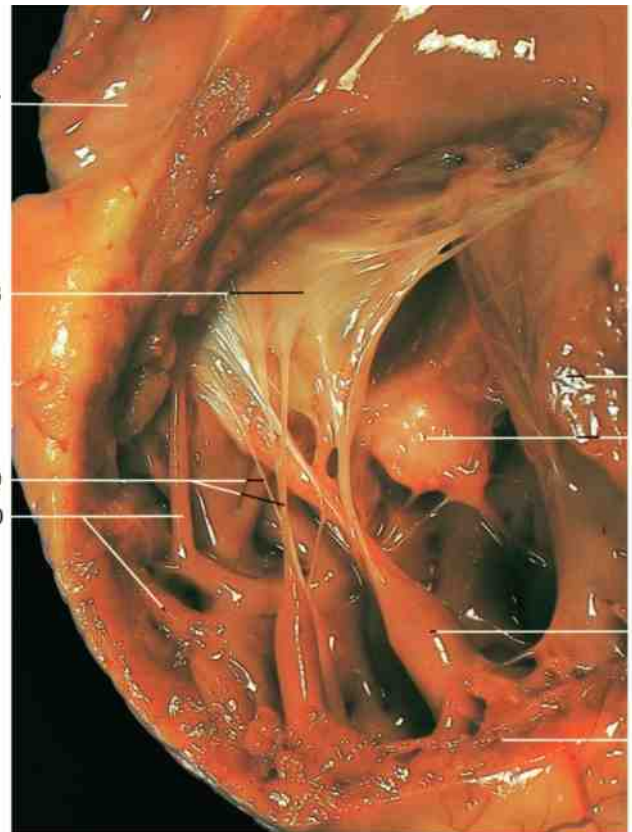


- 1 Pulmonic valve
- 2 Sinus of pulmonary trunk
- 3 Left coronary artery
- 4 Great cardiac vein
- 5 Left atrioventricular (mitral) valve
- 6 Coronary sinus
- 7 Aortic valve
- 8 Right coronary artery
- 9 Right atrioventricular (tricuspid) valve
- 10 Bulb of aorta
- 11 Anterior semilunar cusp of pulmonic valve
- 12 Left semilunar cusp of pulmonic valve
- 13 Right semilunar cusp of pulmonic valve
- 14 Left semilunar cusp of aortic valve
- 15 Right semilunar cusp of aortic valve
- 16 Posterior semilunar cusp of aortic valve
- 17 Right atrium
- 18 Anterior cusp of tricuspid valve
- 19 Chordae tendineae
- 20 Trabeculae carneae
- 21 Interventricular septum
- 22 Septal cusp of tricuspid valve
- 23 Anterior papillary muscle
- 24 Myocardium of right ventricle

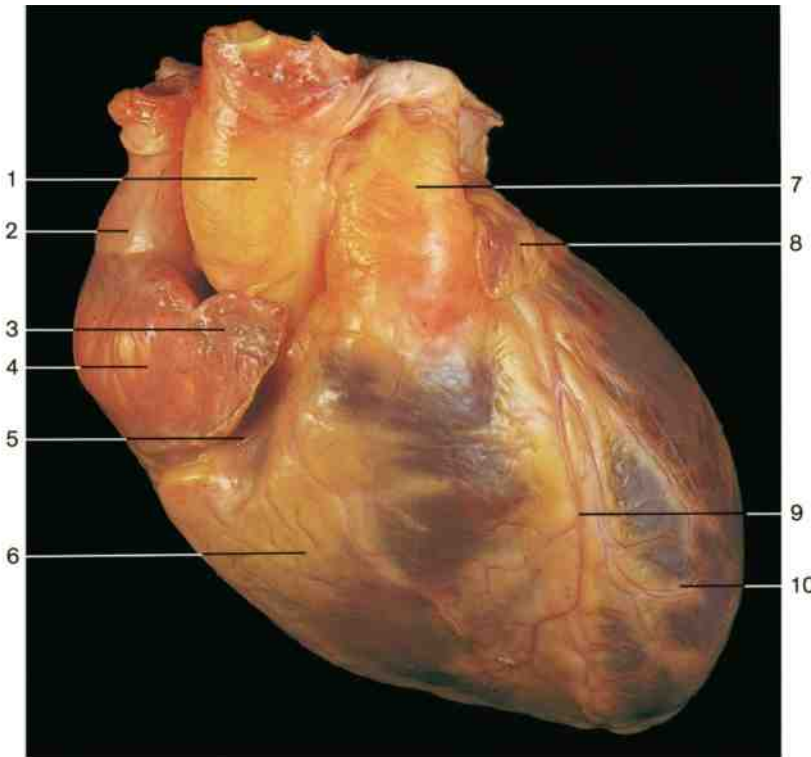
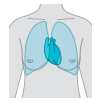
Valves of heart (superior aspect). Left and right atria removed. Dissection of coronary arteries. Above: anterior wall of the heart.



Pulmonic and aortic valves (from above). Anterior wall of the heart at the top. Both valves are closed.

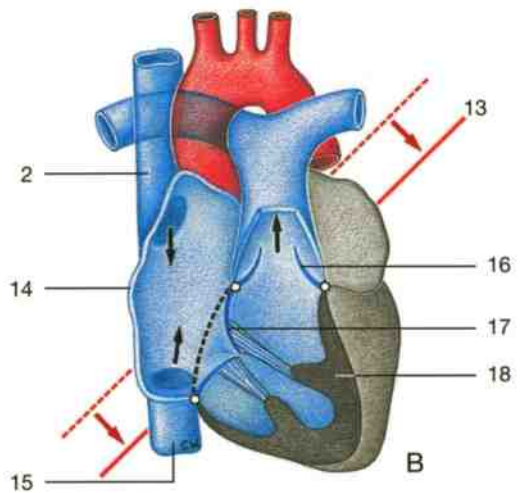
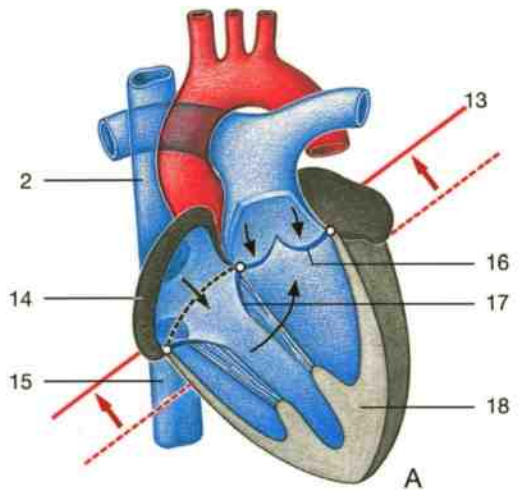


Right atrioventricular (tricuspid) valve (anterior aspect after removal of the anterior wall of the right ventricle).



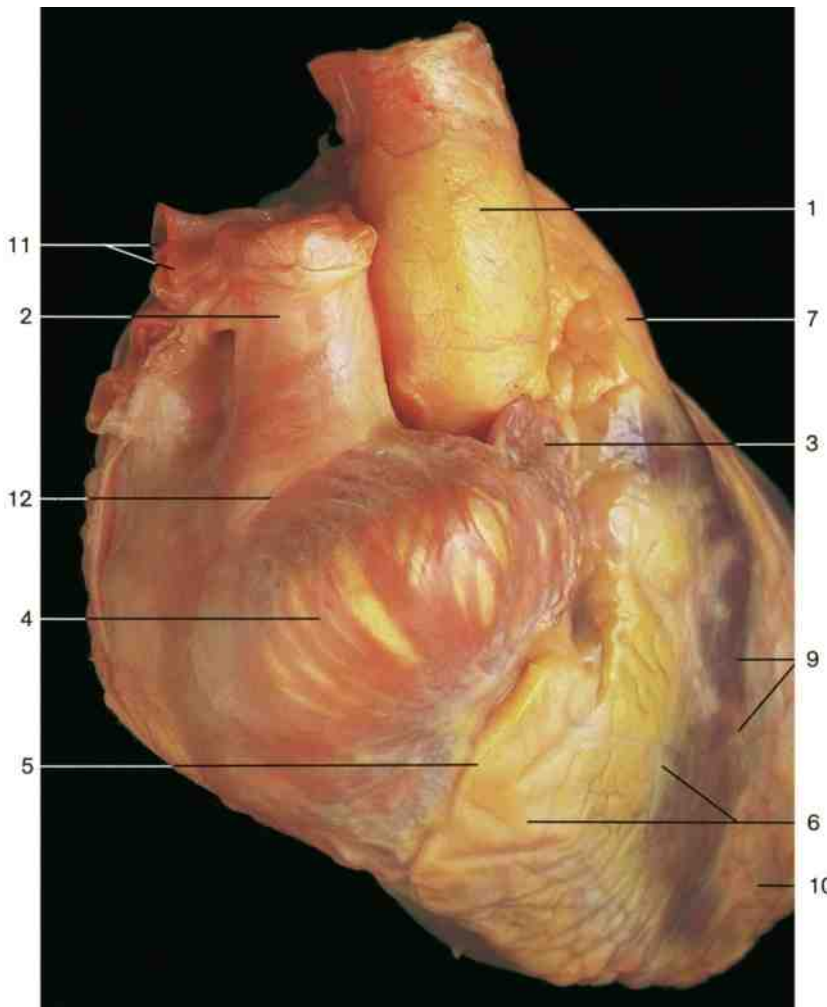
Heart, fixed in diastole (anterior aspect). The ventricles are relaxed, atria contracted.

- 1 Ascending aorta
- 2 Superior vena cava
- 3 Right auricle
- 4 Right atrium
- 5 Coronary sulcus
- 6 Right ventricle
- 7 Pulmonary trunk
- 8 Left auricle
- 9 Anterior interventricular sulcus
- 10 Left ventricle
- 11 Right pulmonary artery
- 12 Sulcus terminalis with sinu-atrial node
- 13 Line indicating plane of position of valves
- 14 Myocardium of right atrium
- 15 Inferior vena cava
- 16 Valve of pulmonary trunk
- 17 Tricuspid valve
- 18 Myocardium of right ventricle

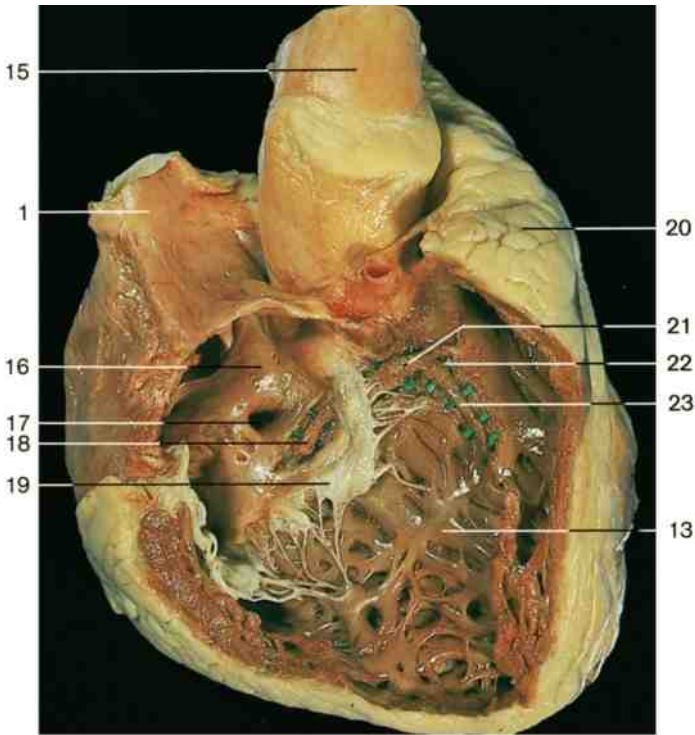


Morphological changes during heart movements. Note the changes in position of the valves (red arrows). Contracted portions of heart are indicated in black.

A. Diastole: muscles of the ventricles relaxed, atrioventricular valves open, semilunar valves closed.
B. Systole: muscles of ventricles contracted, atrioventricular valves closed, semilunar valves open.

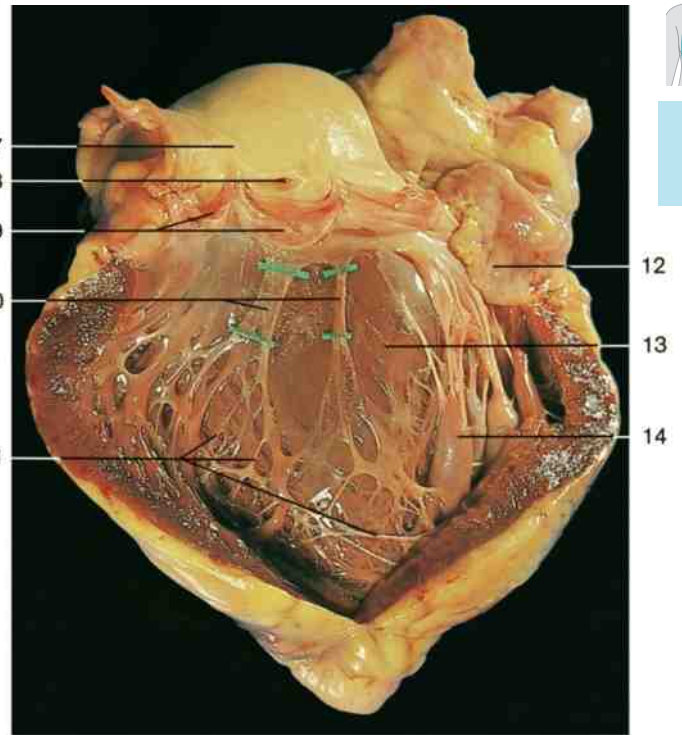


Heart, fixed in systole (antero-lateral aspect). The ventricles are contracted, atria dilated.



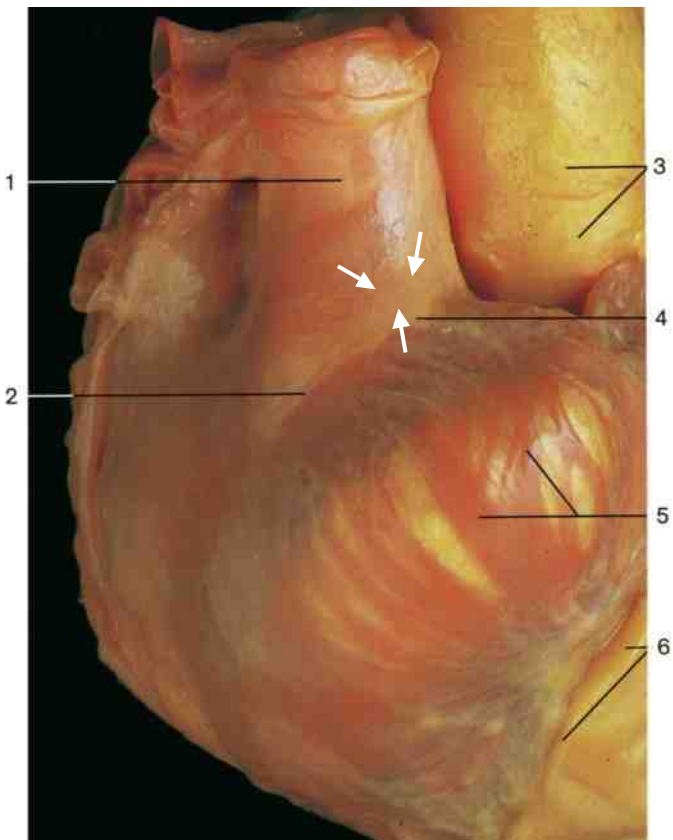
Right ventricle, dissection of atrioventricular node, atrioventricular bundle (bundle of His), and right limb or bundle branch (probes).

- 1 Superior vena cava
- 2 Sulcus terminalis
- 3 Bulb of aorta
- 4 Sinu-atrial node (arrows)
- 5 Muscle fiber bundles of right atrium
- 6 Coronary sulcus (with right coronary artery)
- 7 Aortic sinus
- 8 Entrance to left coronary artery

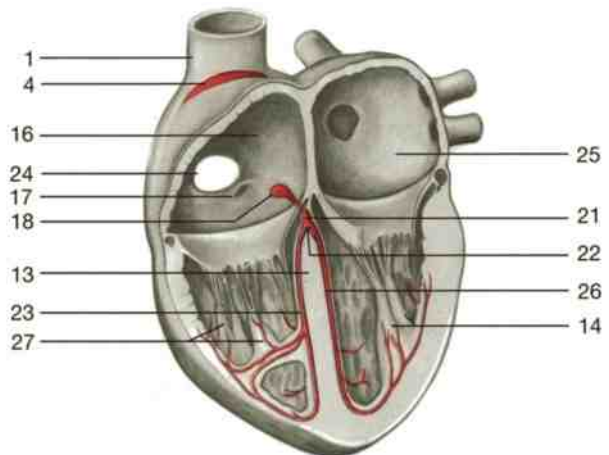


Left ventricle, dissection of left limb or bundle branch of conducting system (probes).

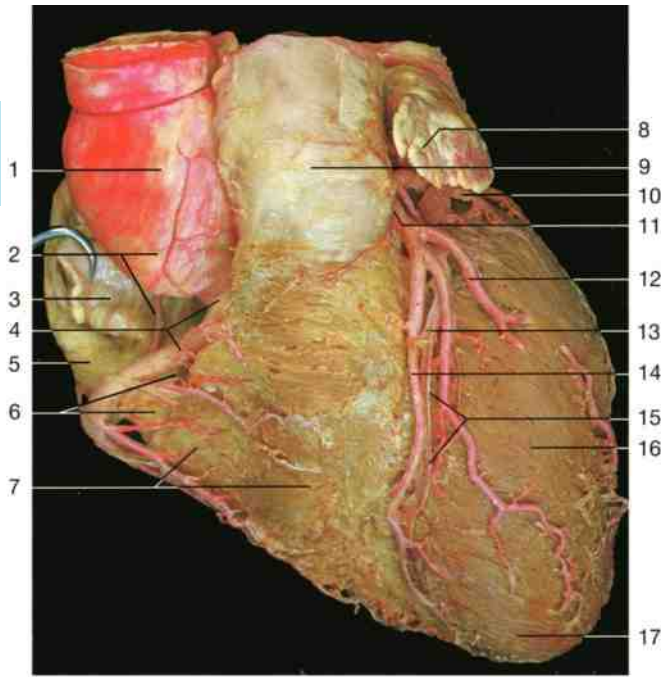
- 9 Aortic valve
- 10 Branches of left bundle branch
- 11 Purkinje fibers
- 12 Left auricle
- 13 Interventricular septum
- 14 Papillary muscles
- 15 Ascending aorta
- 16 Right atrium
- 17 Opening of coronary sinus
- 18 Atrioventricular node
- 19 Septal cusp of tricuspid valve
- 20 Pulmonary trunk
- 21 Atrioventricular bundle (bundle of His)
- 22 Bifurcation of atrioventricular bundle
- 23 Right bundle branch
- 24 Inferior vena cava
- 25 Left atrium
- 26 Left bundle branch
- 27 Papillary muscles with Purkinje fibers



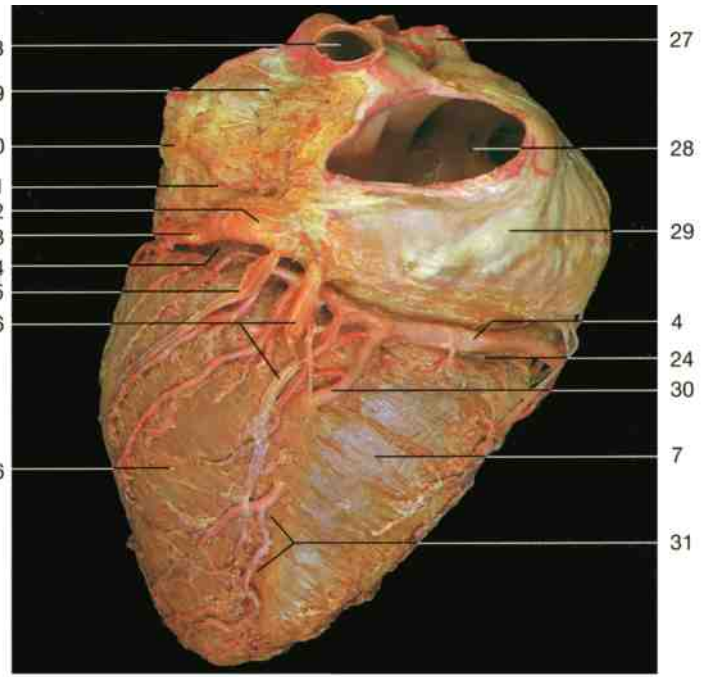
Right atrium, anterior wall, showing the location of the sinu-atrial node (arrows).



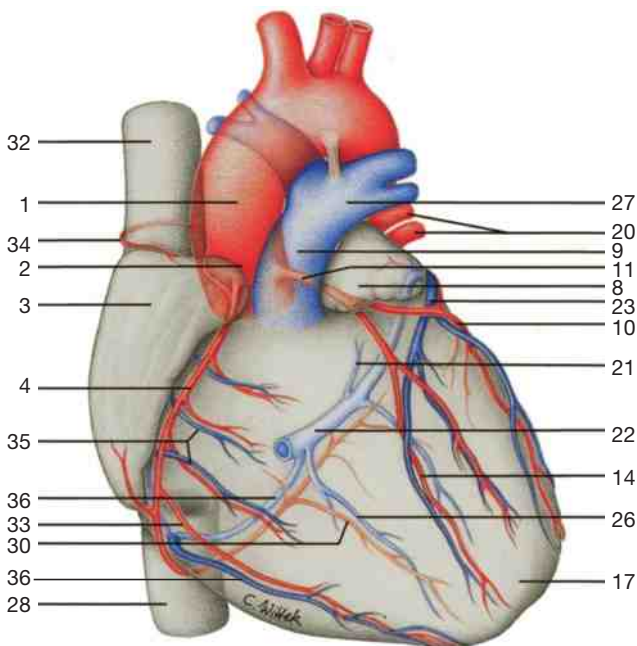
Conducting system of the heart (schematic drawing).



Coronary arteries (anterior aspect). The epicardium and subepicardial fatty tissue have been removed. The arteries have been injected with red resin from the aorta.

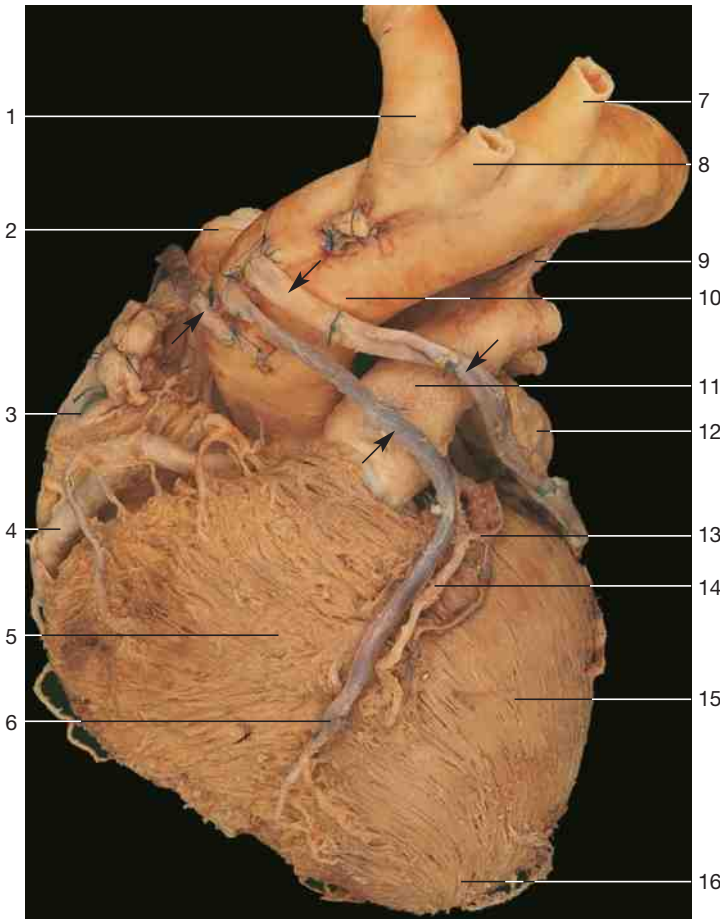


Right coronary artery and veins of the heart (dorsal aspect). The epicardium and subepicardial fatty tissue have been removed.



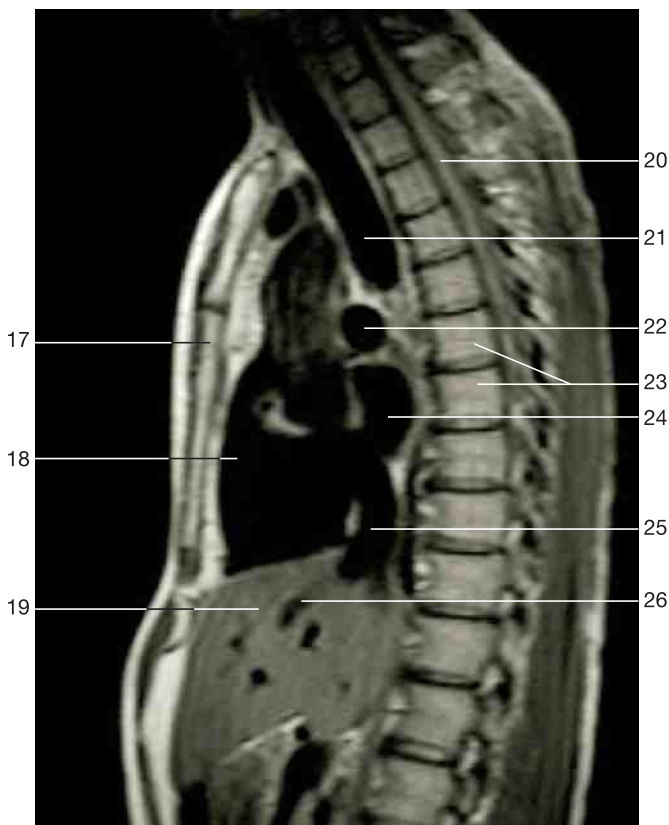Vessels of the heart. Coronary arteries (red) and veins (blue) of the heart (anterior aspect).

- 1 Ascending aorta
- 2 Aortic bulb and (in the above specimen) sinu-atrial branch of right coronary artery
- 3 Right auricle
- 4 Right coronary artery
- 5 Right atrium
- 6 Coronary sulcus
- 7 Right ventricle
- 8 Left auricle
- 9 Pulmonary trunk
- 10 Circumflex branch of left coronary artery
- 11 Left coronary artery
- 12 Diagonal branch of left artery
- 13 Great cardiac vein
- 14 Anterior interventricular artery
- 15 Anterior interventricular sulcus
- 16 Left ventricle
- 17 Apex of heart
- 18 Right pulmonary vein
- 19 Left atrium
- 20 Left pulmonary veins
- 21 Oblique vein of left atrium (Marshall's vein)
- 22 Coronary sinus
- 23 Great cardiac vein
- 24 Coronary sulcus (posterior portion)
- 25 Posterior vein of left ventricle
- 26 Middle cardiac vein
- 27 Left pulmonary artery
- 28 Inferior vena cava
- 29 Right atrium
- 30 Posterior interventricular branch of right coronary artery
- 31 Posterior interventricular sulcus
- 32 Superior vena cava
- 33 Right marginal branch
- 34 Branch of sinu-atrial node
- 35 Minimal cardiac veins
- 36 Small cardiac vein

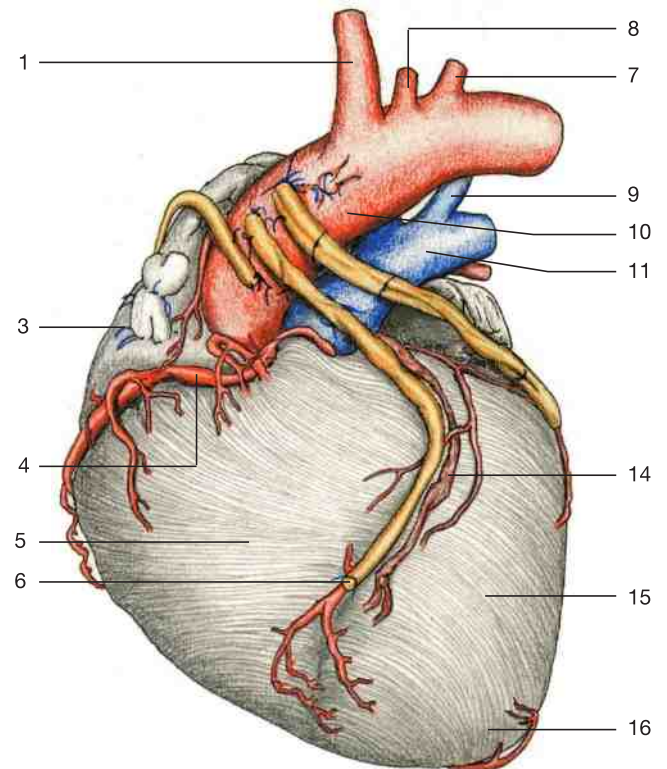


- 1 Brachiocephalic trunk
- 2 Superior vena cava
- 3 Right atrium
- 4 Right coronary artery
- 5 Right ventricle
- 6 Connection of one of the bypass vessels with the anterior interventricular artery
- 7 Left subclavian artery
- 8 Left common carotid artery
- 9 Ductus arteriosus (Botalli) (still open)
- 10 Ascending aorta with three bypass vessels implanted
- 11 Pulmonary trunk
- 12 Left atrium
- 13 Circumflex branch of left coronary artery
- 14 Anterior interventricular branch of left coronary artery
- 15 Left ventricle
- 16 Apex of heart
- 17 Sternum
- 18 Right ventricle
- 19 Liver
- 20 Spinal cord
- 21 Trachea
- 22 Aorta
- 23 Body of thoracic vertebrae
- 24 Pulmonary artery
- 25 Inferior vena cava
- 26 Hepatic vein

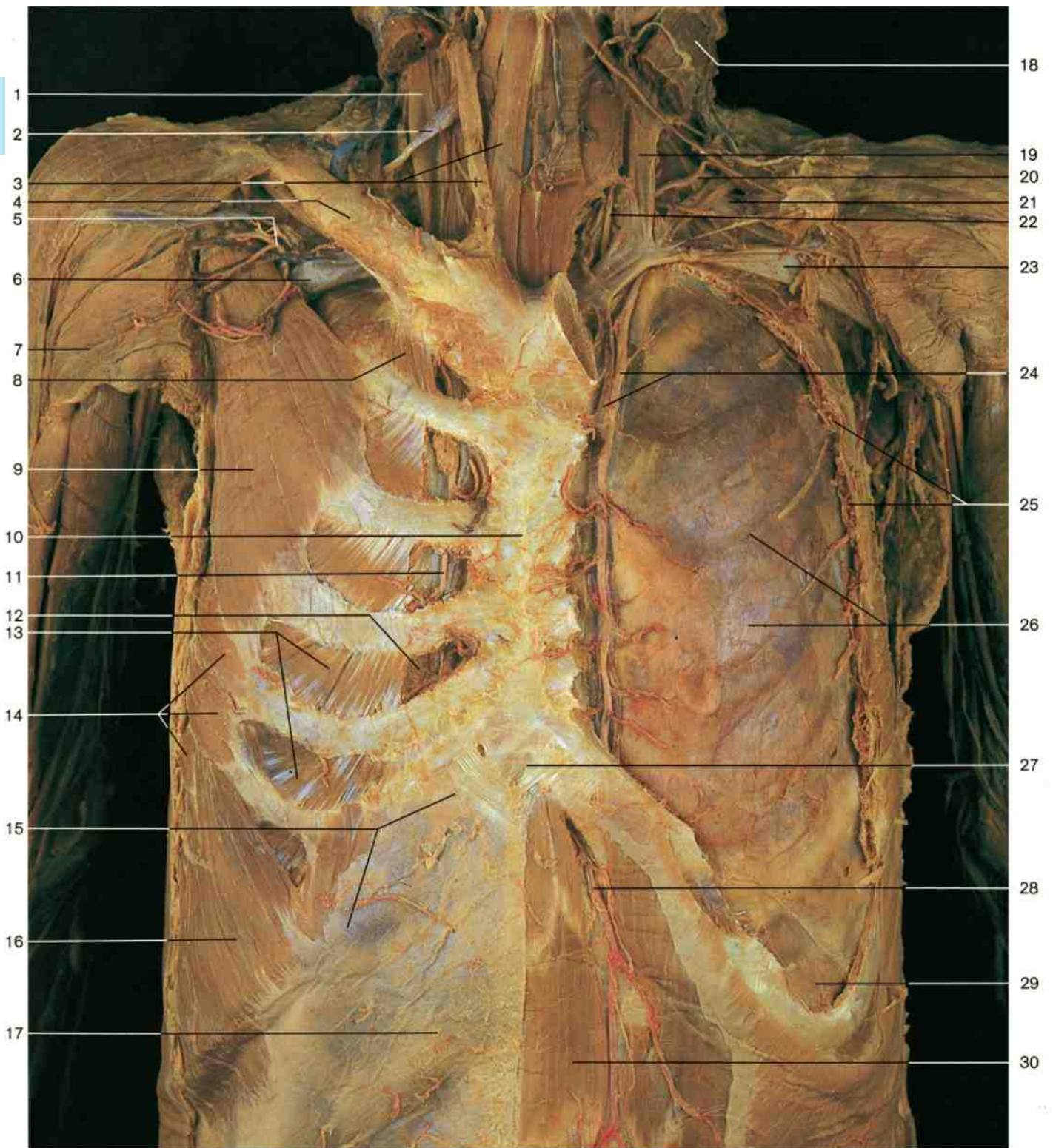
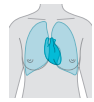
Heart, coronary vessels after implantation of three bypass vessels (anterior aspect). The ductus arteriosus (9) is still open.



Sagittal section through the thoracic cavity (MRI scan, courtesy of Prof. W. Bautz and R. Janka, M. D., University of Erlangen, Germany).

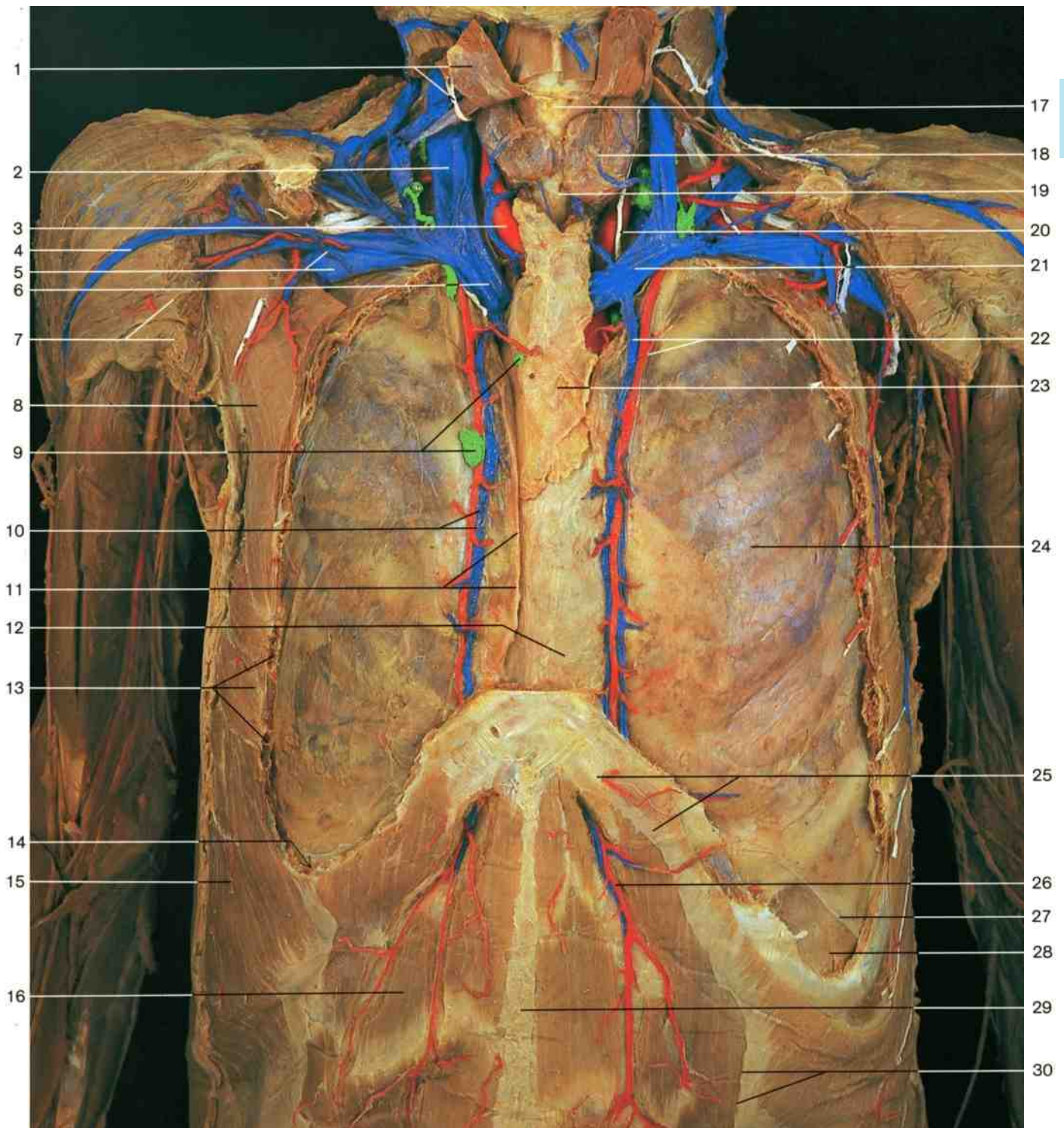
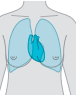


Heart, coronary vessels after implantation of three bypass vessels (yellow) (schematic drawing of the specimen above).



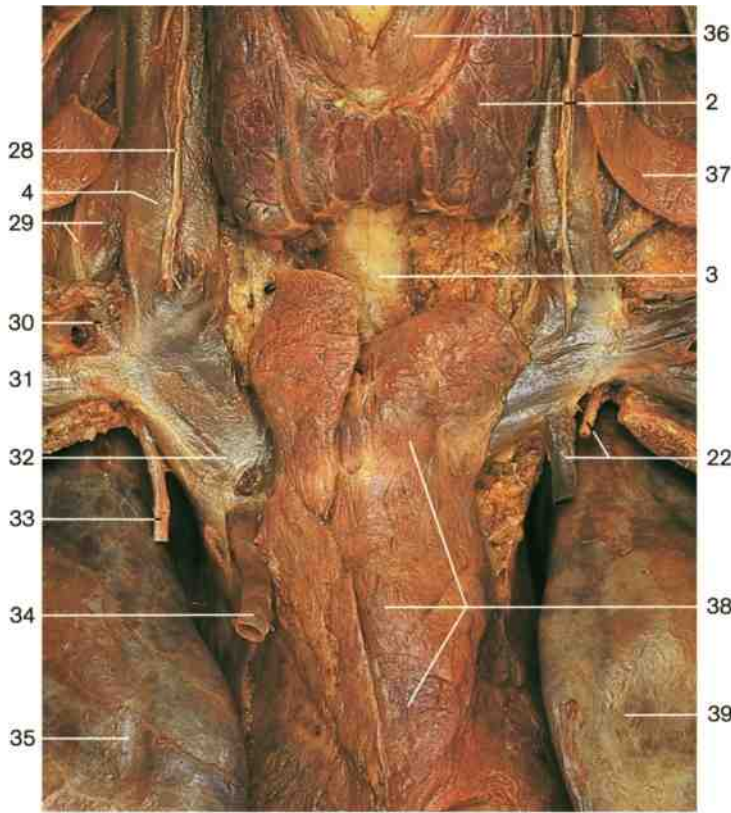
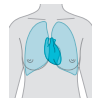
Thoracic organs (ventral aspect). The left clavicle and ribs have been partially removed, and the right intercostal spaces have been opened to show the internal thoracic vein and artery.

- | | | |
|--|---|---|
| 1 Right internal jugular vein | 11 Right internal thoracic artery and vein | 21 Brachial plexus |
| 2 Omohyoid muscle | 12 Fascicles of transversus thoracis muscle | 22 Vagus nerve |
| 3 Sternohyoid muscle and external jugular vein | 13 Internal intercostal muscles | 23 Left axillary vein |
| 4 Clavicle | 14 Serratus anterior muscle | 24 Left internal thoracic artery and vein |
| 5 Thoraco-acromial artery | 15 Costal margin | 25 Ribs and thoracic wall (cut) |
| 6 Right subclavian vein | 16 External abdominal oblique muscle | 26 Costal pleura |
| 7 Pectoralis major muscle | 17 Anterior sheath of rectus abdominis muscle | 27 Xiphoid process |
| 8 External intercostal muscle | 18 Sternocleidomastoid muscle | 28 Superior epigastric artery |
| 9 Pectoralis minor muscle | 19 Left internal jugular vein | 29 Diaphragm |
| 10 Body of sternum | 20 Transverse cervical artery | 30 Rectus abdominis muscle |



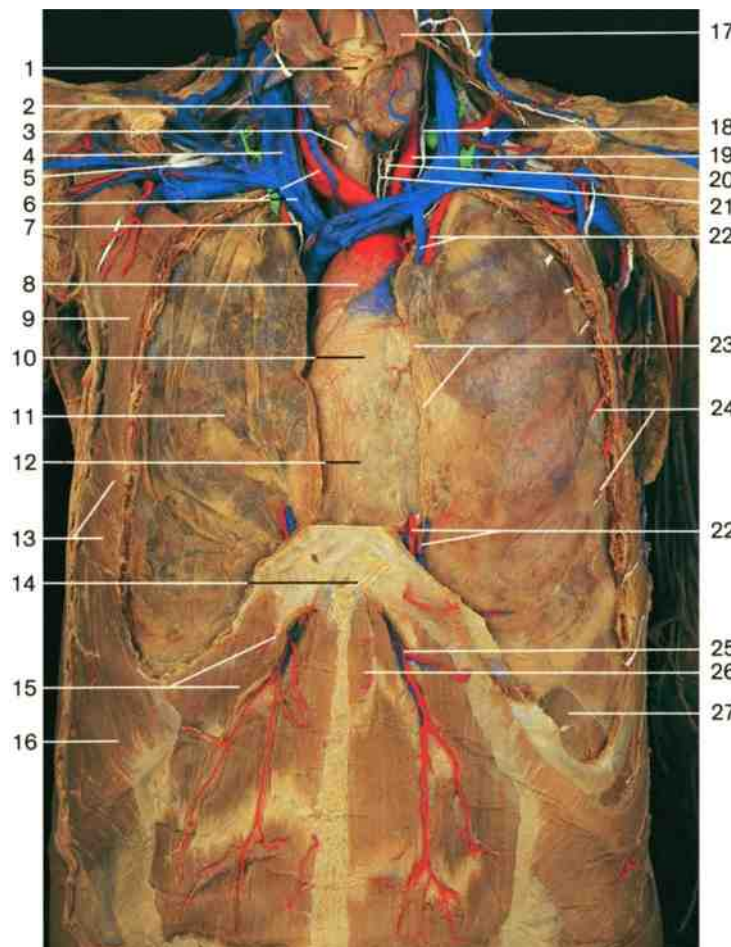
Thoracic organs, anterior mediastinum, and pleura (ventral aspect). Ribs, clavicle, and sternum have been partly removed. Red = arteries; blue = veins; green = lymph vessels and nodes.

- | | | |
|--|--|---|
| 1 Sternothyroid muscle and its nerve (a branch of the ansa cervicalis) | 11 Anterior margin of costal pleura | 21 Left brachiocephalic vein |
| 2 Right internal jugular vein | 12 Pericardium | 22 Left internal thoracic artery and vein |
| 3 Right common carotid artery | 13 Fifth and sixth ribs (divided) and serratus anterior muscle | 23 Thymus |
| 4 Cephalic vein | 14 Costodiaphragmatic recess | 24 Costal pleura |
| 5 Right subclavian vein | 15 External abdominal oblique muscle | 25 Costal margin |
| 6 Right brachiocephalic vein | 16 Rectus abdominis muscle | 26 Superior epigastric artery |
| 7 Pectoralis major muscle (divided) | 17 Larynx (thyroid cartilage) | 27 Margin of costal pleura |
| 8 Pectoralis minor muscle (divided) | 18 Thyroid gland | 28 Diaphragm |
| 9 Parasternal lymph nodes | 19 Trachea | 29 Linea alba |
| 10 Internal thoracic artery and vein | 20 Left vagus nerve | 30 Cut edge of anterior sheath of rectus abdominis muscle |

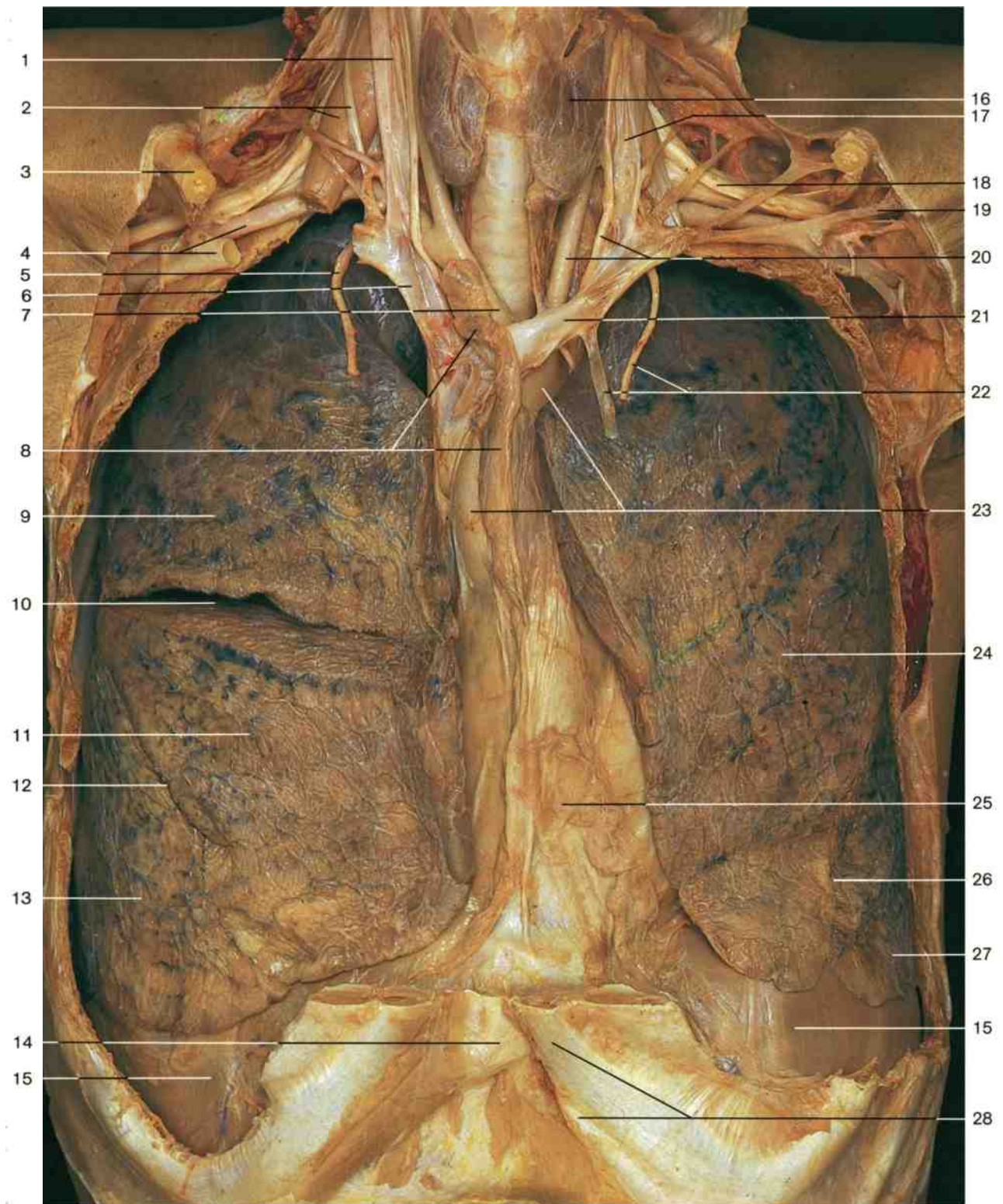


The **thymus** above the heart, showing its position and size.

- 1 Larynx (thyroid cartilage)
- 2 Thyroid gland
- 3 Trachea
- 4 Internal jugular vein
- 5 Brachial plexus
- 6 Right brachiocephalic vein and common carotid artery
- 7 Right phrenic nerve
- 8 Ascending aorta
- 9 Pectoralis minor muscle (divided)
- 10 Pulmonary trunk (covered by pericardium)
- 11 Costal pleura
- 12 Pericardium and heart
- 13 Serratus anterior muscle
- 14 Xiphoid process
- 15 Costal margin
- 16 External abdominal oblique muscle
- 17 Sternothyroid muscle (divided and reflected)
- 18 Vagus nerve
- 19 Left common carotid artery
- 20 Left sympathetic trunk
- 21 Left recurrent laryngeal nerve
- 22 Left internal thoracic artery and vein (divided)
- 23 Margin of costal pleura
- 24 Intercostal nerves and vessels
- 25 Superior epigastric artery
- 26 Rectus abdominis muscle
- 27 Diaphragm
- 28 Ansa cervicalis
- 29 Phrenic nerve and scalenus anterior muscle
- 30 External jugular vein (divided)
- 31 Right subclavian vein
- 32 Right brachiocephalic vein
- 33 Internal thoracic artery (divided)
- 34 Internal thoracic vein (divided)
- 35 Right lung
- 36 Cricothyroid muscle
- 37 Omohyoid muscle
- 38 Thymus
- 39 Left lung

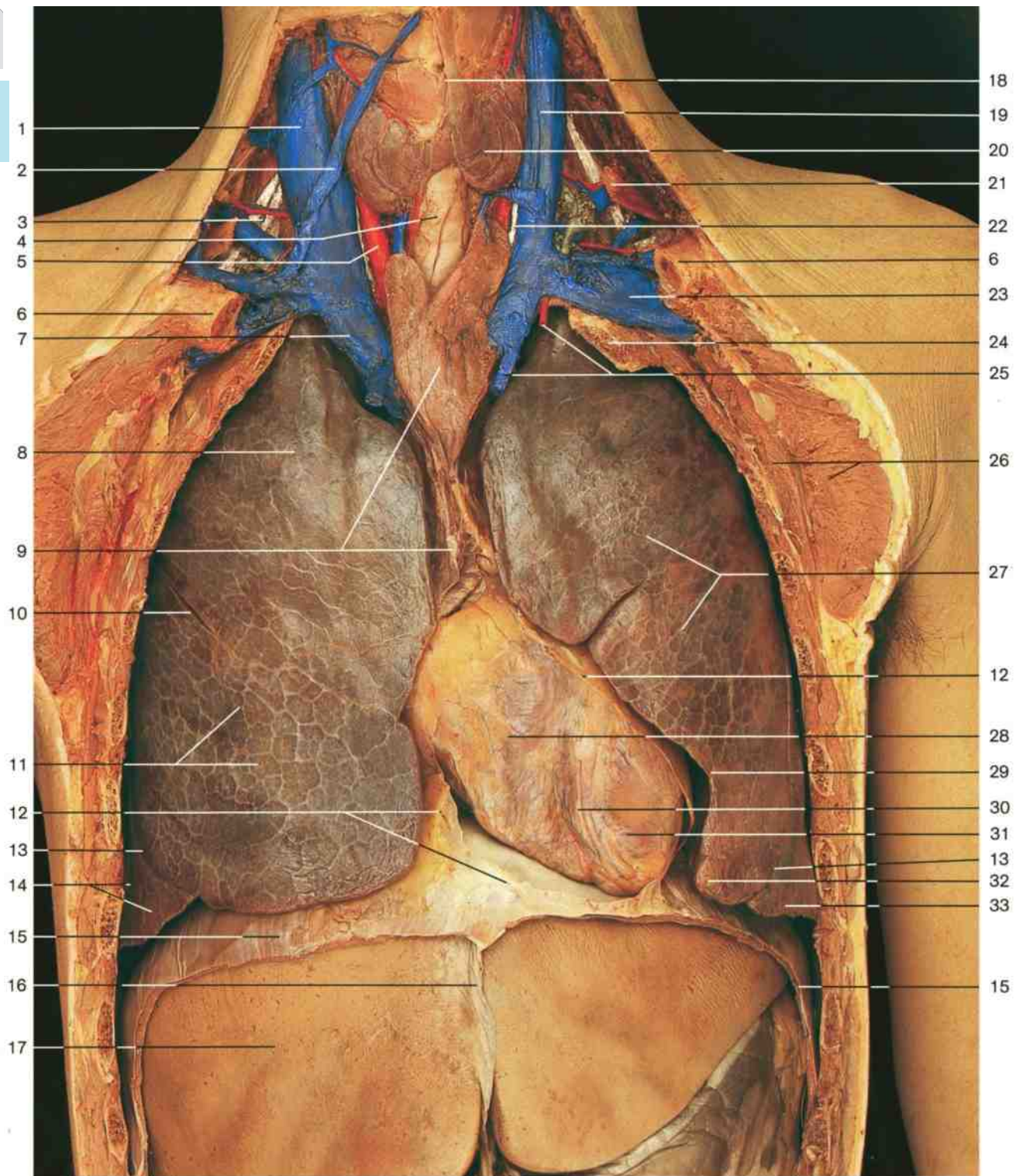
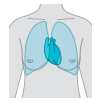


Thoracic organs (ventral aspect). The internal thoracic vessels have been removed, and the anterior margins of the pleura and lungs have been slightly reflected to display the anterior and middle mediastinum, including the heart and great vessels.



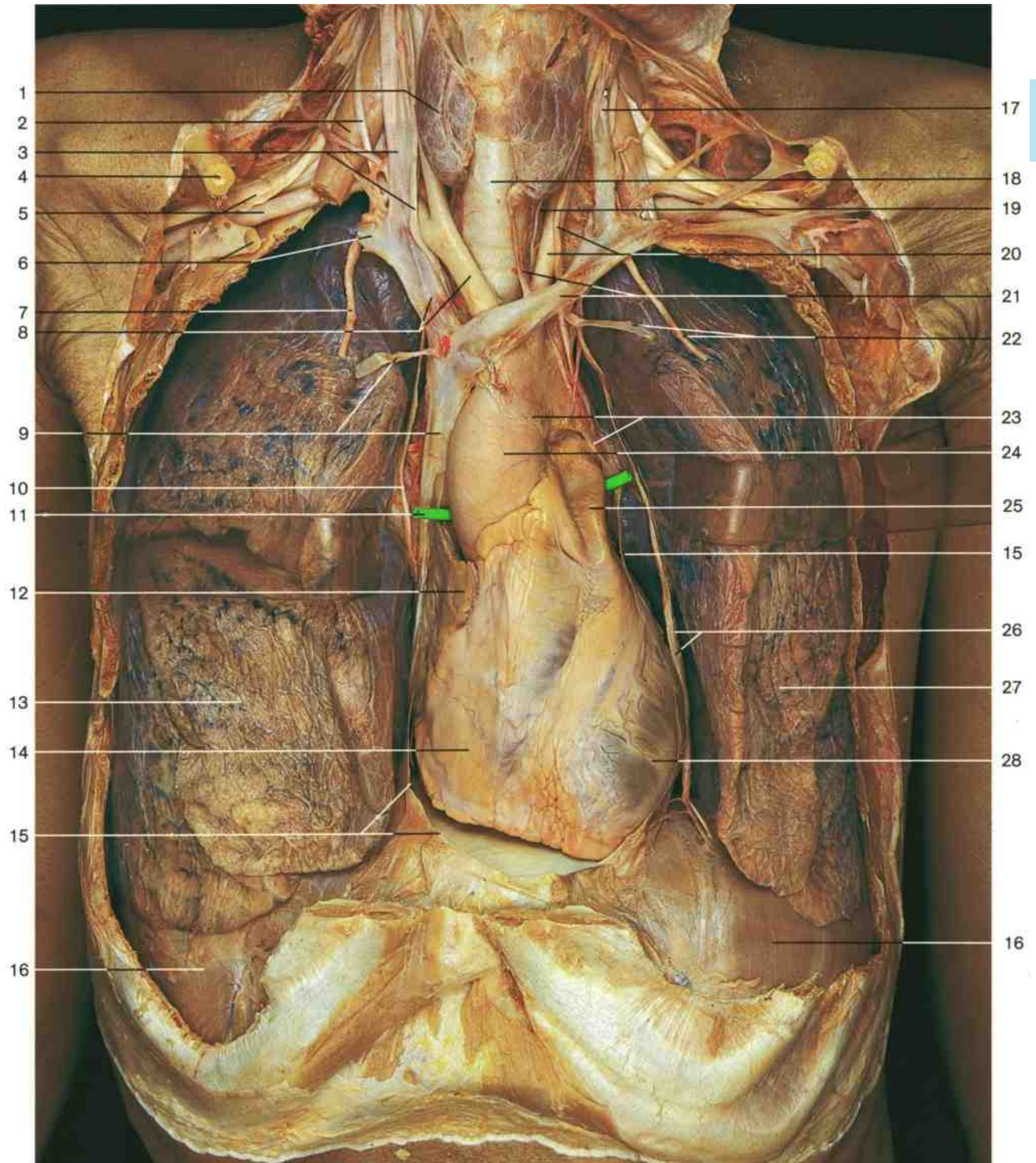
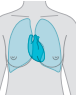Thoracic organs (ventral aspect). The pleura has been opened and the lungs exposed. Remnants of the thymus and pericardium are seen.

- | | | |
|--|----------------------------------|--|
| 1 Right internal jugular vein | 11 Middle lobe of right lung | 20 Left common carotid artery and vagus nerve |
| 2 Phrenic nerve and scalenus anterior muscle | 12 Oblique fissure of right lung | 21 Left brachiocephalic vein |
| 3 Clavicle (divided) | 13 Lower lobe of right lung | 22 Internal thoracic artery and vein (divided) |
| 4 Right subclavian artery and vein | 14 Xiphoid process | 23 Ascending aorta and aortic arch |
| 5 Internal thoracic artery | 15 Diaphragm | 24 Upper lobe of left lung |
| 6 Right brachiocephalic vein | 16 Thyroid gland | 25 Pericardium |
| 7 Brachiocephalic trunk | 17 Left internal jugular vein | 26 Oblique fissure of left lung |
| 8 Thymus (atrophic) | 18 Brachial plexus | 27 Lower lobe of left lung |
| 9 Upper lobe of right lung | 19 Left cephalic vein | 28 Costal margin |
| 10 Horizontal fissure of right lung (incomplete) | | |



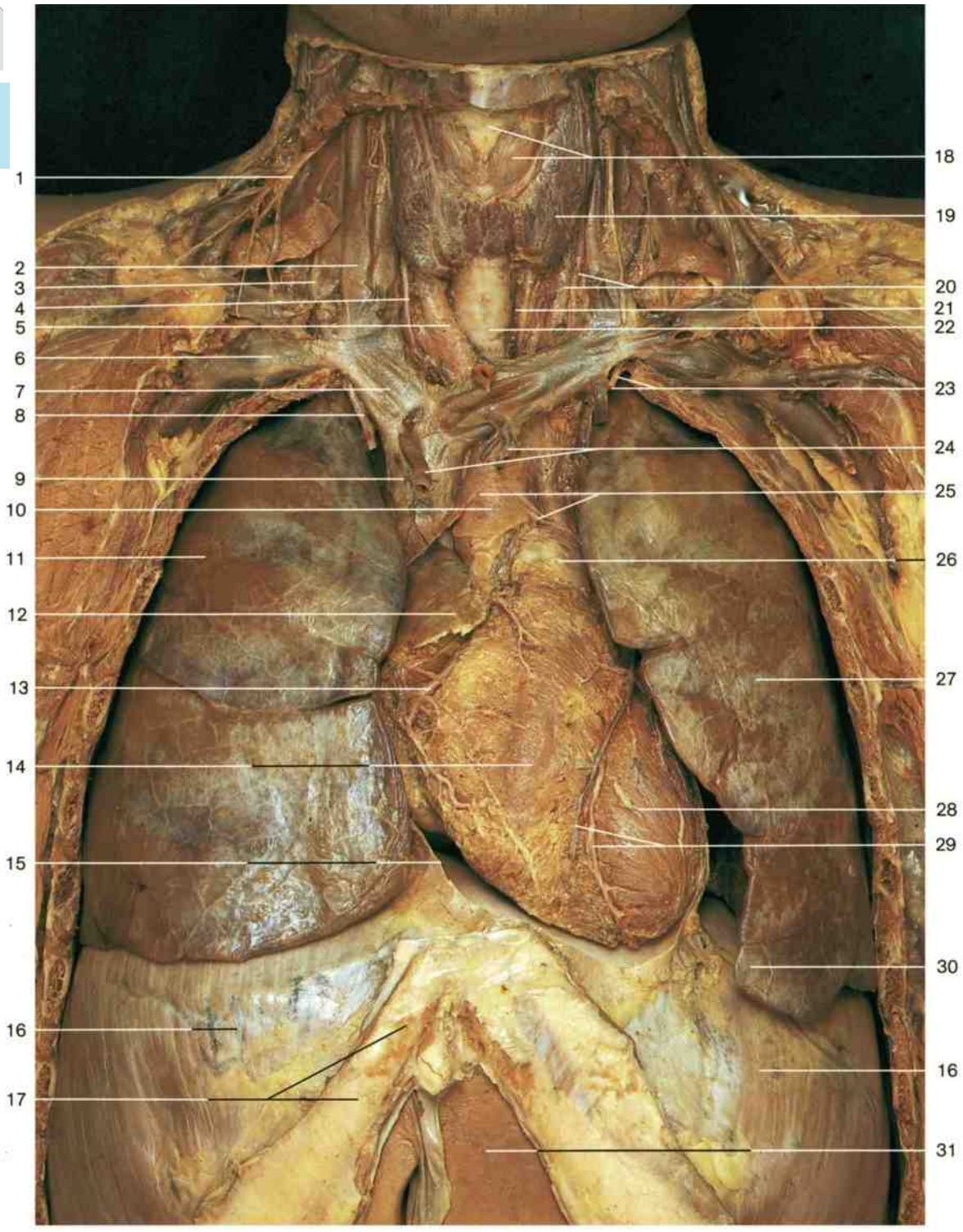
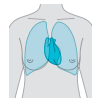Thoracic organs (ventral aspect). The thoracic wall, costal pleura, pericardium, and diaphragm have been partly removed.

- | | | |
|--|-------------------------------|--|
| 1 Internal jugular vein | 13 Oblique fissure of lung | 25 Internal thoracic artery and vein |
| 2 External jugular vein (displaced medially) | 14 Lower lobe of right lung | 26 Pectoralis major and pectoralis minor muscles (cut edges) |
| 3 Brachial plexus | 15 Diaphragm | 27 Upper lobe of left lung |
| 4 Trachea | 16 Falciform ligament | 28 Right ventricle |
| 5 Right common carotid artery | 17 Liver | 29 Cardiac notch of left lung |
| 6 Clavicle (divided) | 18 Location of larynx | 30 Interventricular sulcus of heart |
| 7 Right brachiocephalic vein | 19 Left internal jugular vein | 31 Left ventricle |
| 8 Upper lobe of right lung | 20 Thyroid gland | 32 Lingula |
| 9 Thymus (atrophic) | 21 Omohyoid muscle (divided) | 33 Lower lobe of left lung |
| 10 Horizontal fissure of right lung | 22 Vagus nerve | |
| 11 Middle lobe of right lung | 23 Left subclavian vein | |
| 12 Pericardium (cut edges) | 24 First rib (divided) | |



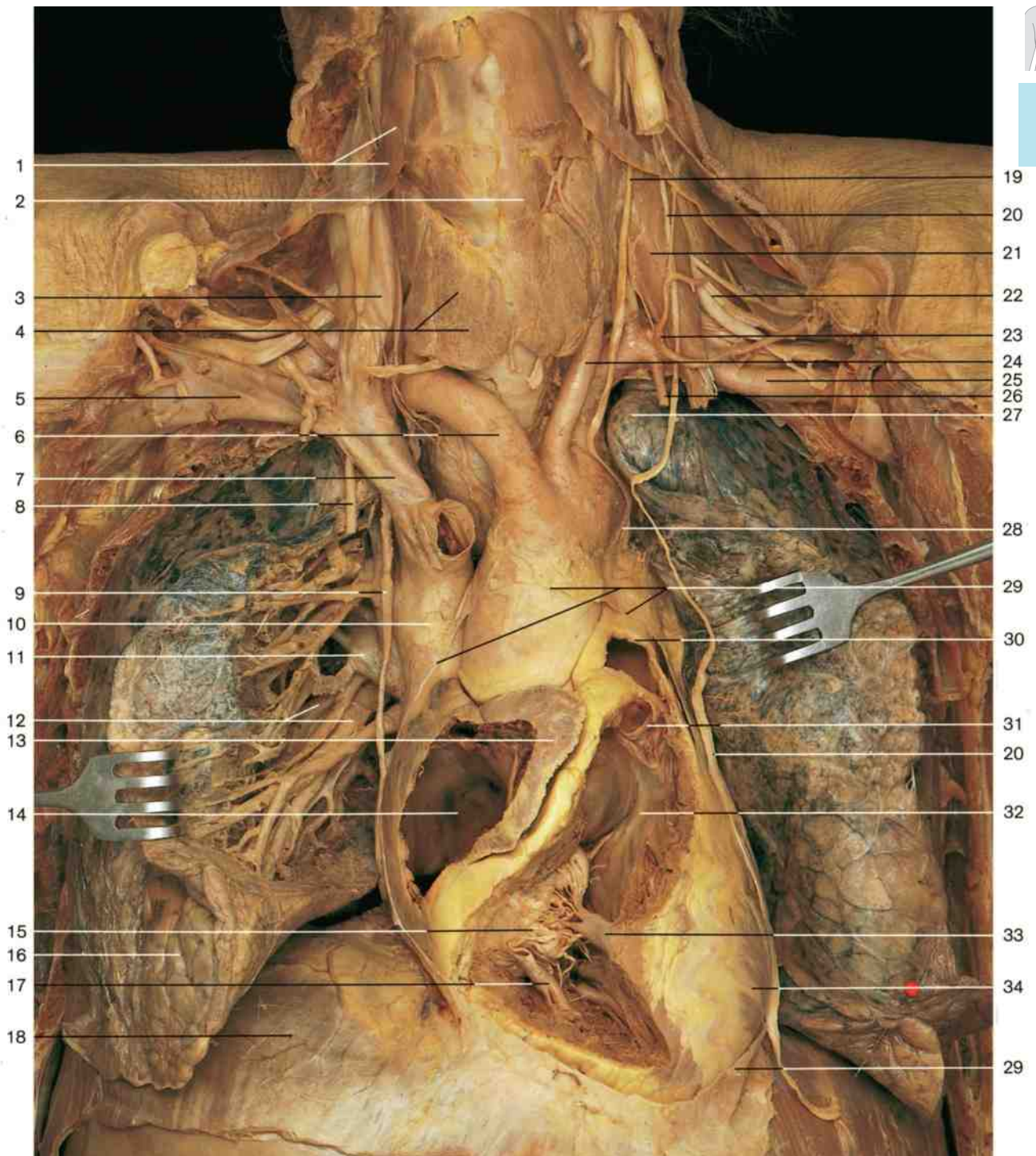
Thoracic organs (ventral aspect). Position of the heart and middle mediastinum. The anterior wall of the thorax, the costal pleura, and the pericardium have been removed and the lungs slightly reflected.

- | | | |
|--|---|--|
| 1 Thyroid gland | 11 Transverse pericardial sinus (probe) | 21 Left brachiocephalic vein and inferior thyroid vein |
| 2 Phrenic nerve and scalenus anterior muscle | 12 Right auricle | 22 Left internal thoracic artery and vein (divided) |
| 3 Vagus nerve and internal jugular vein | 13 Middle lobe of right lung | 23 Upper margin of pericardial sac |
| 4 Clavicle (divided) | 14 Right ventricle | 24 Ascending aorta |
| 5 Brachial plexus and subclavian artery | 15 Cut edge of pericardium | 25 Pulmonary trunk |
| 6 Subclavian vein | 16 Diaphragm | 26 Left phrenic nerve and left pericardiophrenic artery and vein |
| 7 Internal thoracic artery | 17 Internal jugular vein | 27 Upper lobe of left lung |
| 8 Brachiocephalic trunk and right brachiocephalic vein | 18 Trachea | 28 Left ventricle |
| 9 Superior vena cava and thymic vein | 19 Left recurrent laryngeal nerve | |
| 10 Right phrenic nerve | 20 Left common carotid artery and vagus nerve | |



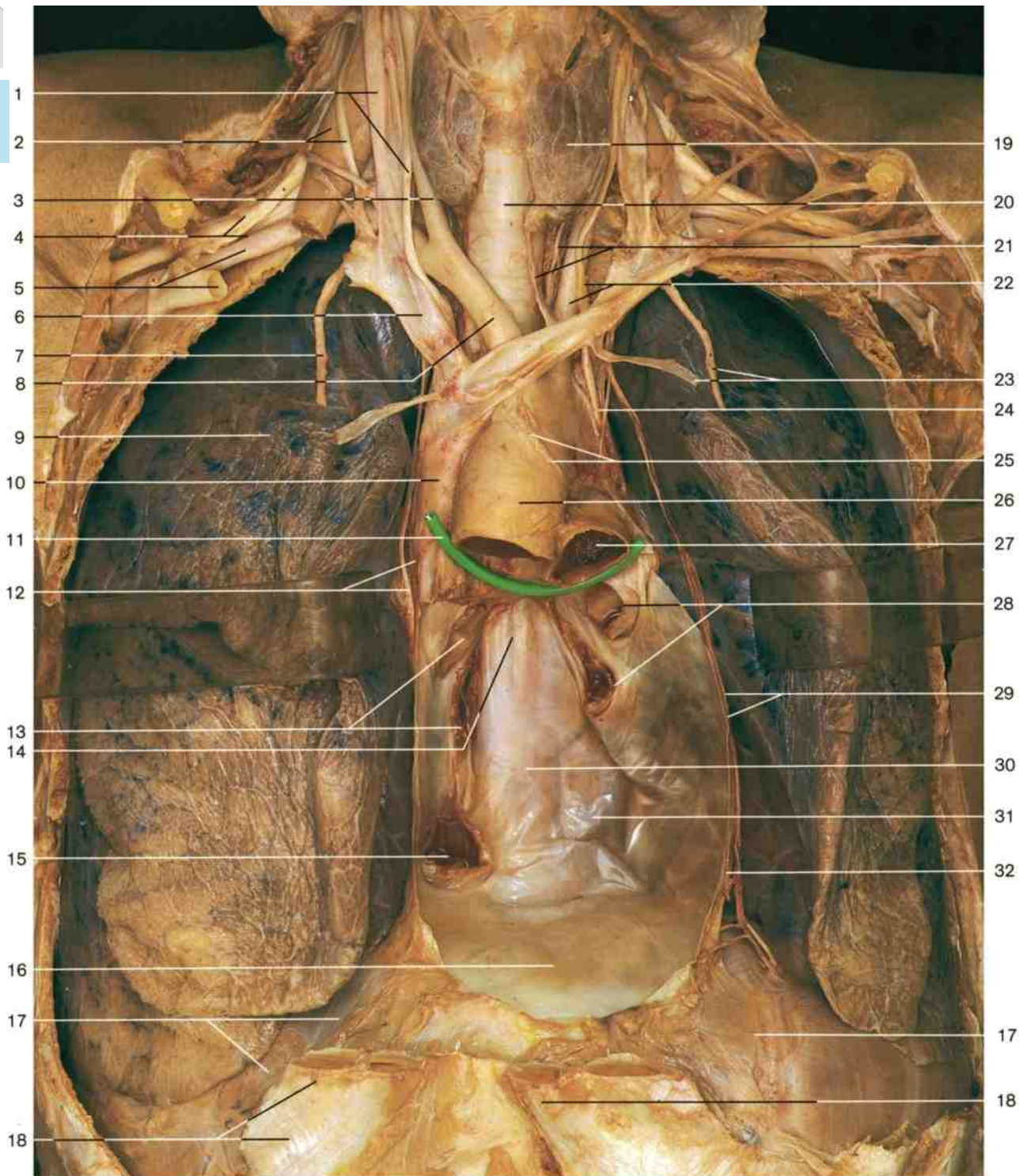
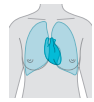
Thoracic organs (ventral aspect). Position of heart, dissection of coronary vessels in situ. The anterior wall of thorax, costal pleura, and pericardium have been removed.

- | | | |
|--------------------------------------|---|---|
| 1 Intermediate supraclavicular nerve | 13 Right coronary artery and small cardiac vein | 21 Left recurrent laryngeal nerve |
| 2 Internal jugular vein | 14 Right ventricle | 22 Trachea |
| 3 Right phrenic nerve | 15 Cut edge of pericardium | 23 Left internal thoracic artery and vein (divided) |
| 4 Right vagus nerve | 16 Diaphragm | 24 Thymic veins |
| 5 Right common carotid artery | 17 Costal margin | 25 Margin of pericardial sac |
| 6 Right subclavian vein | 18 Larynx (cricothyroid muscle and thyroid cartilage) | 26 Pulmonary trunk |
| 7 Right brachiocephalic vein | 19 Thyroid gland | 27 Left lung |
| 8 Right internal thoracic artery | 20 Left common carotid artery and left vagus nerve | 28 Left ventricle |
| 9 Superior vena cava | | 29 Anterior interventricular artery and vein |
| 10 Ascending aorta | | 30 Lingula |
| 11 Right lung | | 31 Liver |
| 12 Right atrium | | |



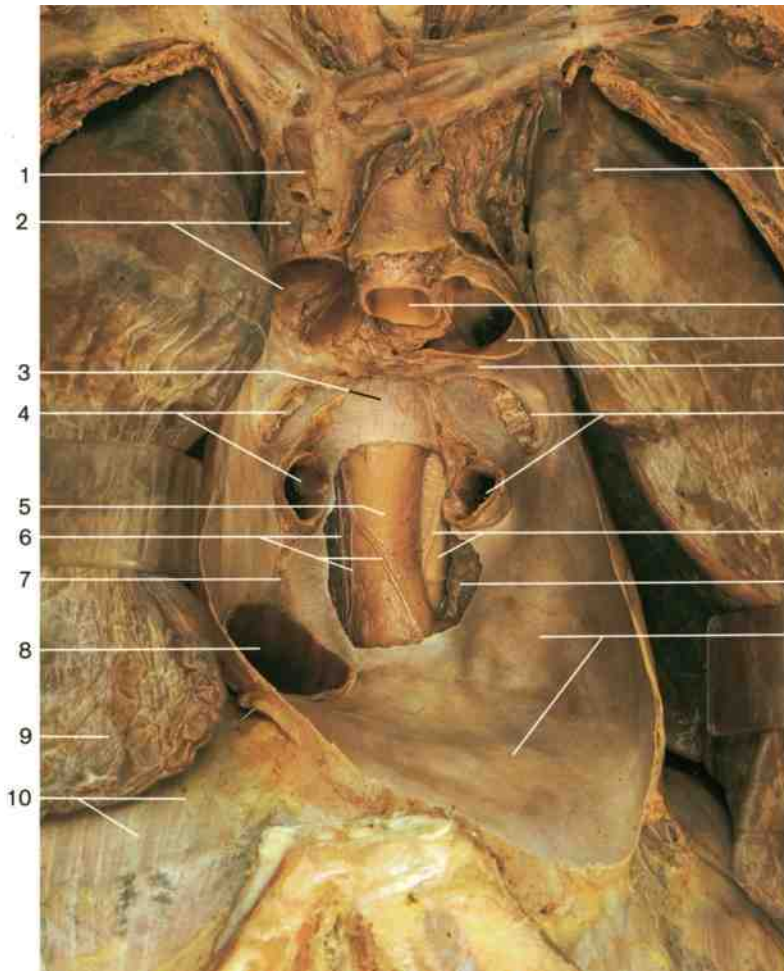
Thoracic organs (ventral aspect). Heart with valves in situ. Anterior wall of thorax, pleura, and anterior portion of pericardium have been removed. The right atrium and ventricle have been opened to show the right atrioventricular and pulmonary valves.

- | | | |
|-----------------------------------|---|-----------------------------------|
| 1 Omohyoid muscle | 13 Right auricle | 24 Left common carotid artery |
| 2 Pyramidal lobe of thyroid gland | 14 Right atrium | 25 Left subclavian artery |
| 3 Internal jugular vein | 15 Right atrioventricular (tricuspid) valve | 26 Left internal thoracic artery |
| 4 Thyroid gland | 16 Right lung | 27 Apex of left lung |
| 5 Right subclavian vein | 17 Posterior papillary muscle | 28 Left recurrent laryngeal nerve |
| 6 Brachiocephalic trunk | 18 Diaphragm | 29 Cut edge of pericardium |
| 7 Right brachiocephalic vein | 19 Left vagus nerve | 30 Pulmonary trunk (fenestrated) |
| 8 Right internal thoracic artery | 20 Left phrenic nerve | 31 Pulmonic valve |
| 9 Right phrenic nerve | 21 Scalenus anterior muscle | 32 Supraventricular crest |
| 10 Superior vena cava | 22 Brachial plexus | 33 Anterior papillary muscle |
| 11 Pulmonary vein | 23 Thyrocervical trunk | 34 Left ventricle |
| 12 Branches of pulmonary artery | | |



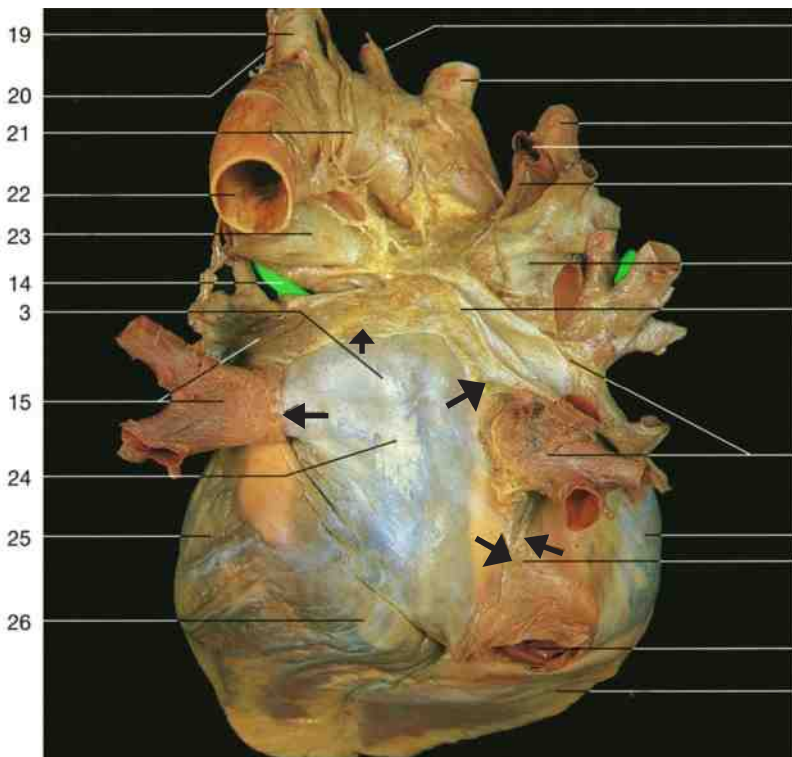
Thoracic organs (ventral aspect). Pericardium and mediastinum. Anterior wall of thorax and heart have been removed and the lungs slightly reflected. Note probe within transverse pericardial sinus.

- | | | |
|---|--|--|
| 1 Right internal jugular vein and right vagus nerve | 12 Right phrenic nerve and right pericardiophrenic artery and vein | 22 Left common carotid artery and left vagus nerve |
| 2 Right phrenic nerve and scalenus anterior muscle | 13 Right pulmonary veins | 23 Left internal thoracic artery and vein (divided) |
| 3 Right common carotid artery | 14 Oblique sinus of pericardium | 24 Vagus nerve at aortic arch |
| 4 Brachial plexus | 15 Inferior vena cava | 25 Cut edge of pericardium |
| 5 Right subclavian artery and vein | 16 Diaphragmatic part of pericardium | 26 Ascending aorta |
| 6 Right brachiocephalic vein | 17 Diaphragm | 27 Pulmonary trunk (divided) |
| 7 Right internal thoracic artery (divided) | 18 Costal margin | 28 Left pulmonary veins |
| 8 Brachiocephalic trunk | 19 Thyroid gland | 29 Left phrenic nerve and left pericardiophrenic artery and vein |
| 9 Upper lobe of right lung | 20 Trachea | 30 Contour of esophagus beneath pericardium |
| 10 Superior vena cava | 21 Left recurrent laryngeal nerve and inferior thyroid vein | 31 Contour of aorta beneath pericardium |
| 11 Transverse pericardial sinus (probe) | | 32 Pericardium (cut edge) |

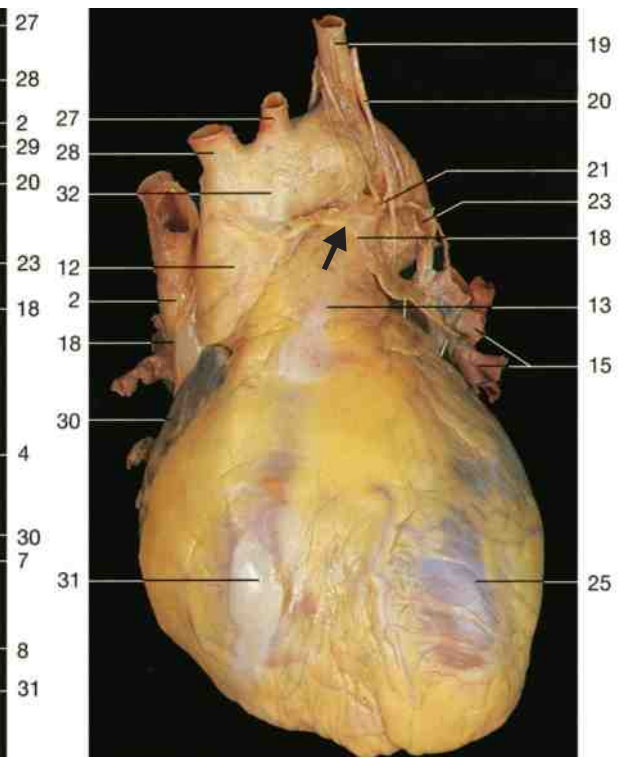


- 1 Internal thoracic vein
- 2 Superior vena cava
- 3 Oblique sinus of pericardium
- 4 Right pulmonary veins
- 5 Esophagus
- 6 Branches of right vagus nerve
- 7 Mesocardium
- 8 Inferior vena cava
- 9 Middle lobe of right lung
- 10 Diaphragm
- 11 Upper lobe of left lung
- 12 Ascending aorta
- 13 Pulmonary trunk
- 14 Transverse pericardial sinus
- 15 Left pulmonary veins
- 16 Descending aorta and left vagus nerve
- 17 Left lung (adjacent to pericardium)
- 18 Pericardium
- 19 Left subclavian artery
- 20 Vagus nerve
- 21 Left recurrent laryngeal nerve
- 22 Descending aorta
- 23 Pulmonary artery
- 24 Left atrium
- 25 Left ventricle
- 26 Coronary sinus
- 27 Left common carotid artery
- 28 Brachiocephalic trunk
- 29 Azygos arch
- 30 Right atrium
- 31 Right ventricle
- 32 Aortic arch

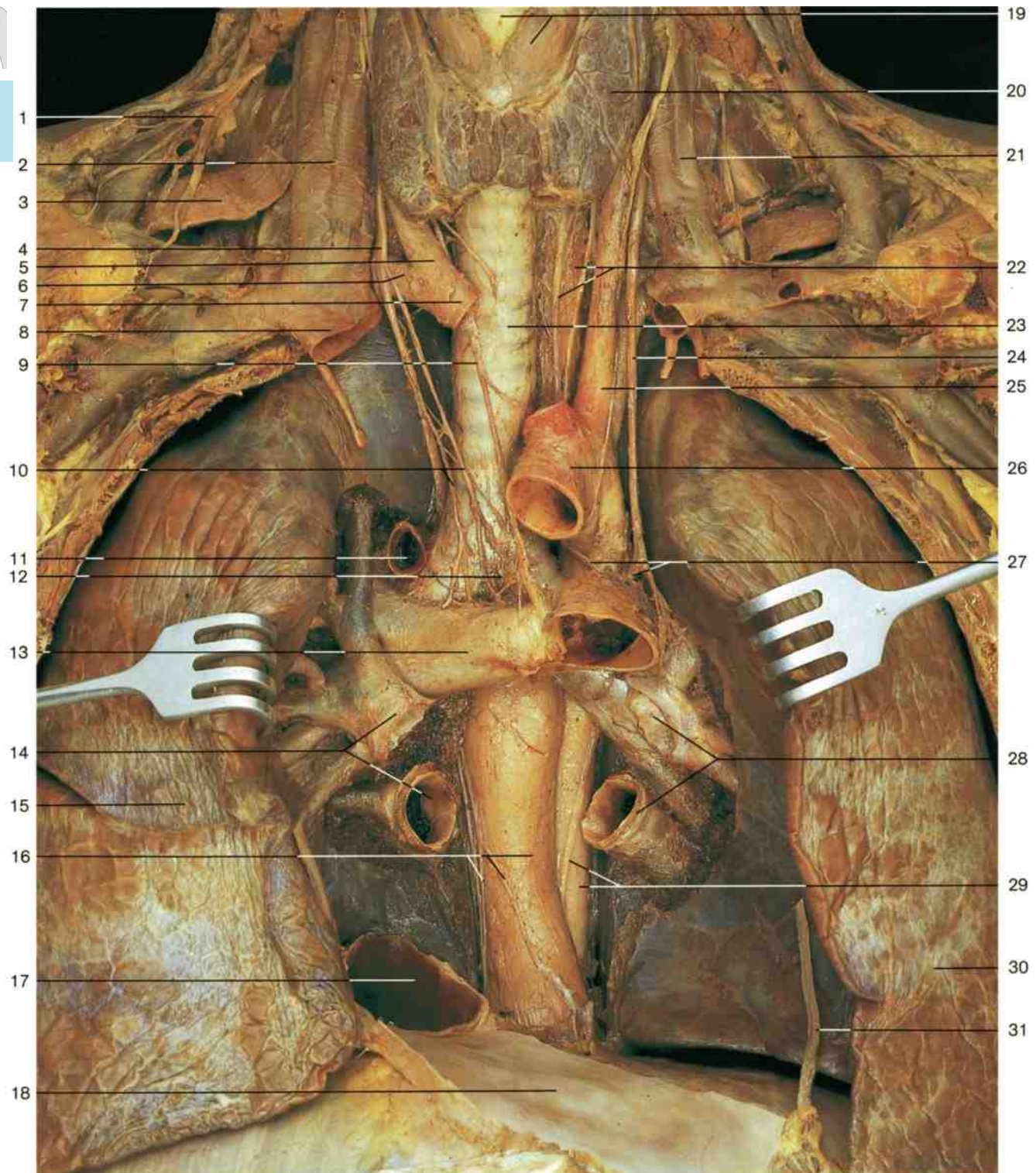
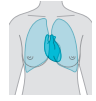
Pericardial sac (ventral aspect). The heart has been removed, and the posterior wall of the pericardium has been opened to show the adjacent esophagus and aorta.



Heart with epicardium (posterior aspect). Arrows: oblique sinus.

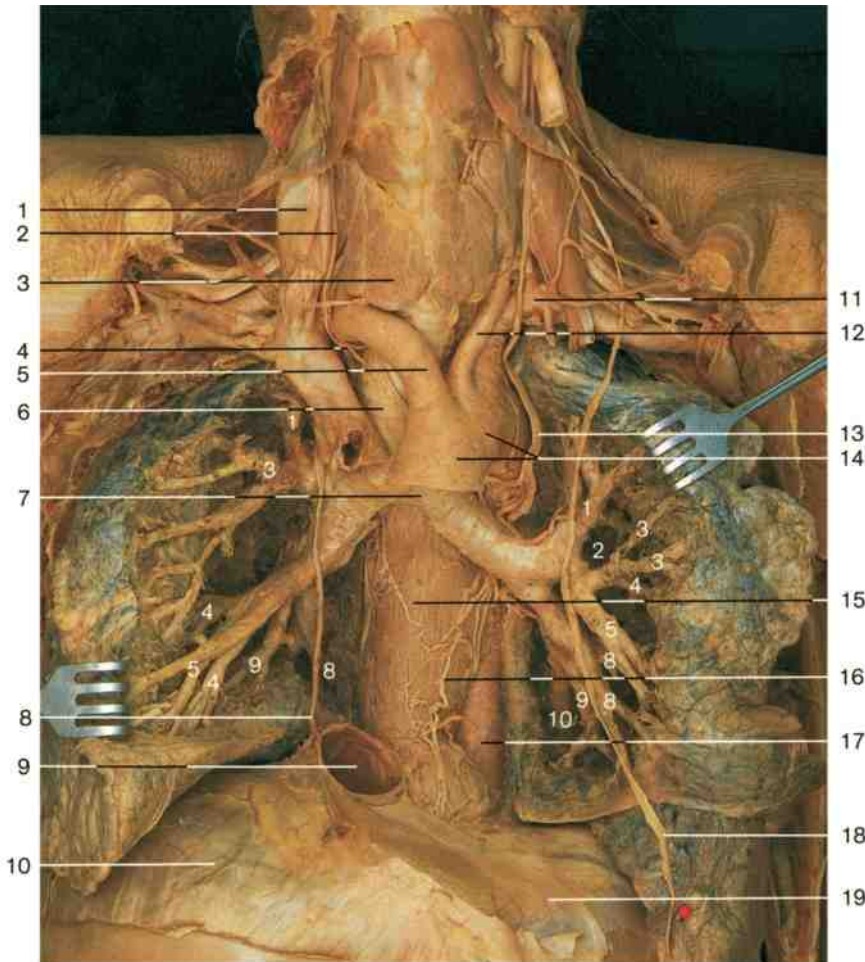
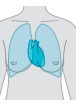

Heart with epicardium (anterior aspect). Arrow: pericardial reflection.



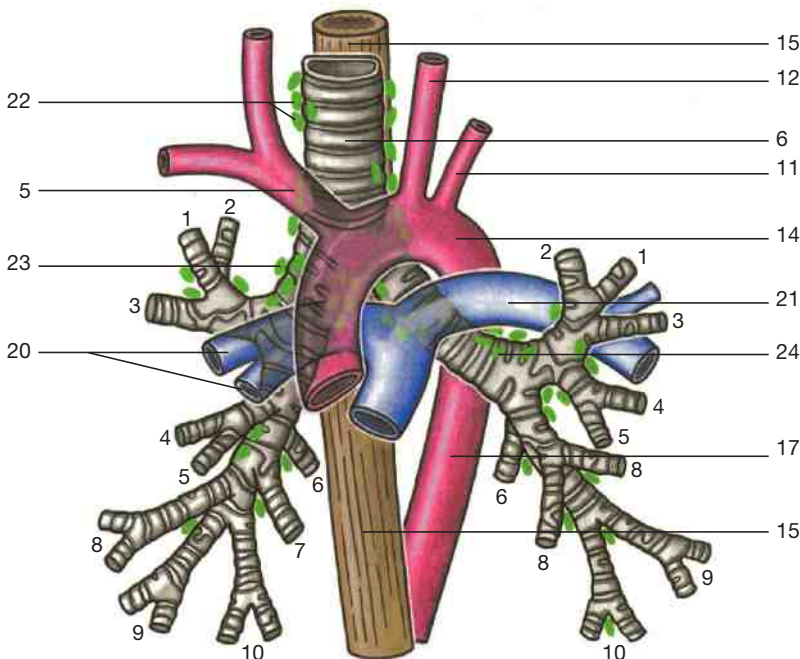
Mediastinal organs after removal of heart and pericardium (ventral aspect). Both lungs have been slightly reflected.

- | | | | | | |
|----|---|----|---|----|---|
| 1 | Supraclavicular nerves | 11 | Azygos arch (divided) | 22 | Esophagus and left recurrent laryngeal nerve |
| 2 | Internal jugular vein | 12 | Bifurcation of trachea | 23 | Trachea |
| 3 | Omohyoid muscle | 13 | Right pulmonary artery | 24 | Left vagus nerve |
| 4 | Right vagus nerve | 14 | Right pulmonary veins | 25 | Left common carotid artery |
| 5 | Right common carotid artery | 15 | Right lung | 26 | Aortic arch |
| 6 | Right subclavian artery | 16 | Esophagus and branches of right vagus nerve | 27 | Left recurrent laryngeal nerve branching off from vagus nerve |
| 7 | Brachiocephalic trunk | 17 | Inferior vena cava | 28 | Left pulmonary veins |
| 8 | Right brachiocephalic vein | 18 | Pericardium | 29 | Thoracic aorta and left vagus nerve |
| 9 | Superior cervical cardiac branch of vagus nerve | 19 | Larynx (thyroid cartilage, cricothyroid muscle) | 30 | Left lung |
| 10 | Inferior cervical cardiac branches of vagus nerve | 20 | Thyroid gland | 31 | Left phrenic nerve (divided) |
| | | 21 | Internal jugular vein | | |

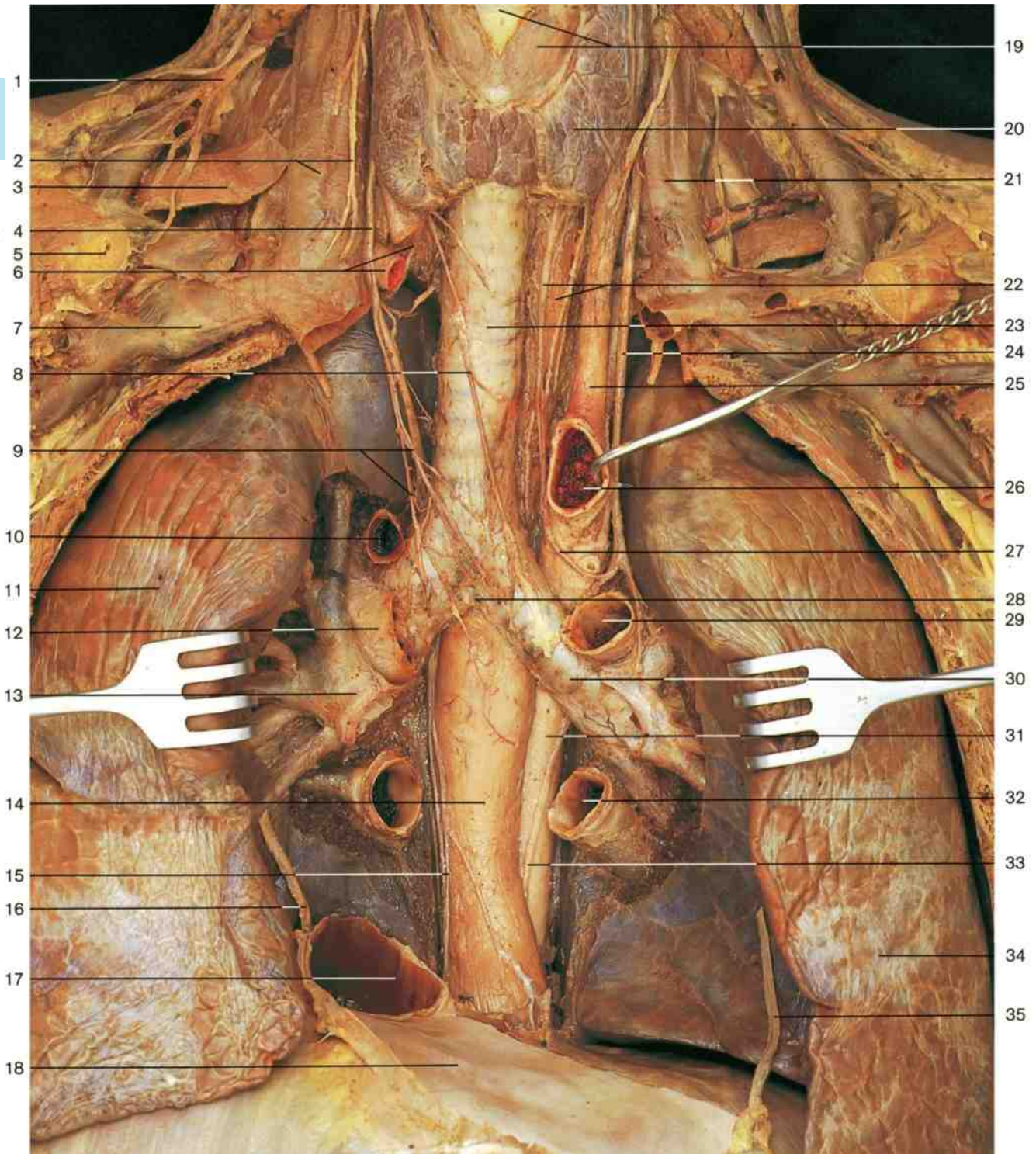
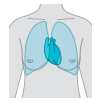


- 1 Internal jugular vein
- 2 Right vagus nerve
- 3 Thyroid gland
- 4 Right recurrent laryngeal nerve
- 5 Brachiocephalic trunk
- 6 Trachea
- 7 Bifurcation of trachea
- 8 Right phrenic nerve
- 9 Inferior vena cava
- 10 Diaphragm
- 11 Left subclavian artery
- 12 Left common carotid artery
- 13 Left vagus nerve
- 14 Aortic arch
- 15 Esophagus
- 16 Esophageal plexus
- 17 Thoracic aorta
- 18 Left phrenic nerve
- 19 Pericardium at the central tendon of diaphragm
- 20 Right pulmonary artery
- 21 Left pulmonary artery
- 22 Tracheal lymph nodes
- 23 Superior tracheobronchial lymph nodes
- 24 Bronchopulmonary lymph nodes

Bronchial tree in situ (ventral aspect). Heart and pericardium have been removed; the bronchi of the bronchopulmonary segments are dissected. 1–10 = numbers of segments (cf. p. 246 and 251).

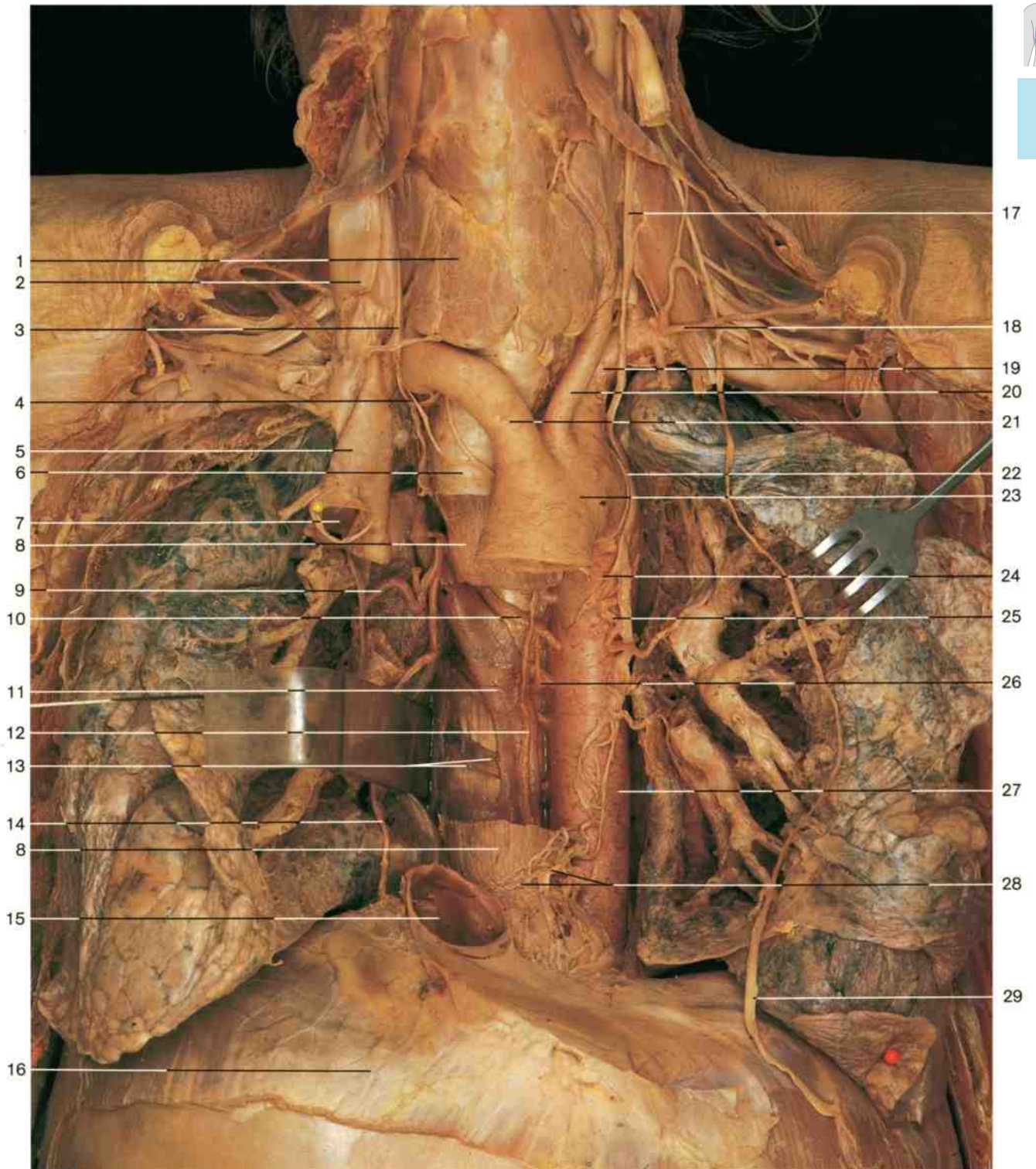


Relation of aorta, pulmonary trunk, and esophagus to trachea and bronchial tree (schematic drawing). 1–10 = numbers of segments (cf. p. 246 and 251).



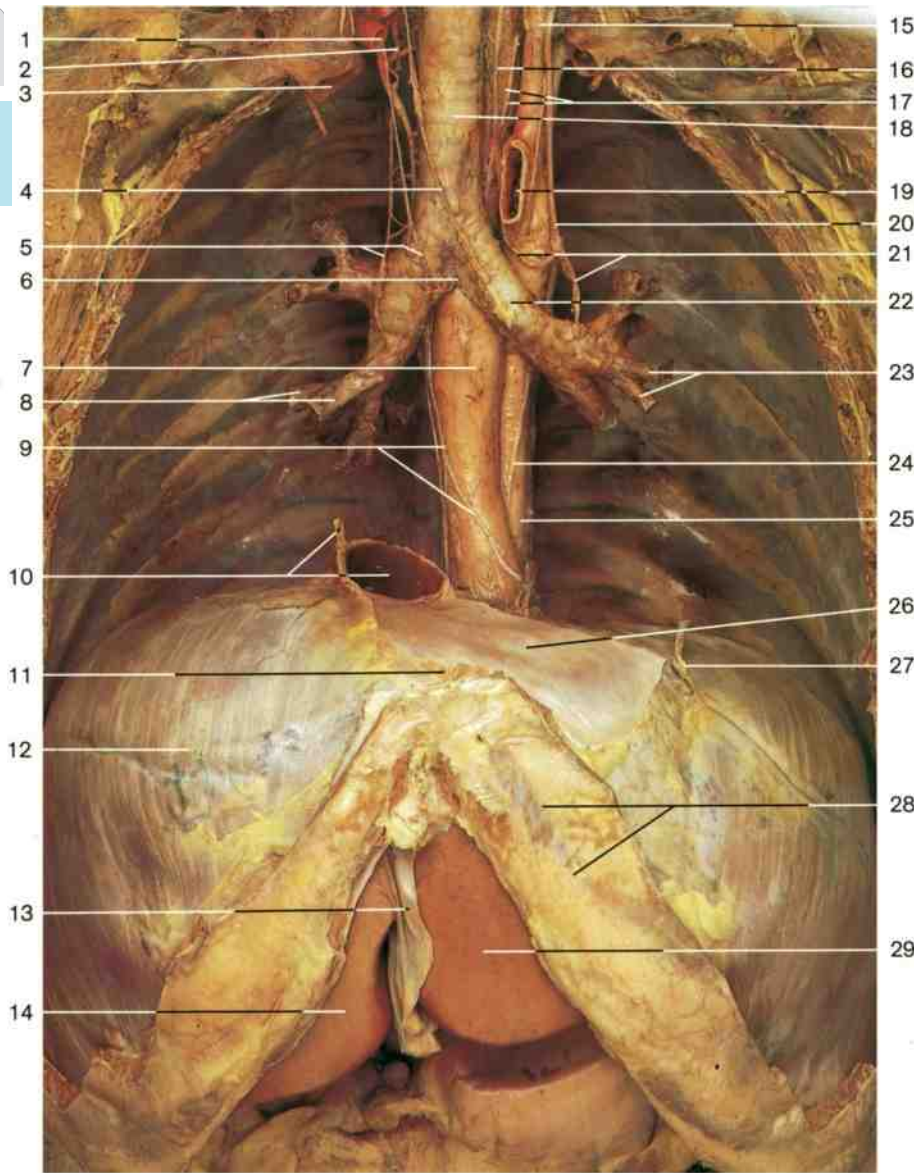
Mediastinal organs (ventral aspect). The heart with the pericardium has been removed, and the lungs and aortic arch have been slightly reflected to show the vagus nerves and their branches.

- | | | | | | |
|----|---|----|--|----|--------------------------------|
| 1 | Supraclavicular nerves | 12 | Right pulmonary artery | 24 | Left vagus nerve |
| 2 | Right internal jugular vein with ansa cervicalis | 13 | Right pulmonary veins | 25 | Left common carotid artery |
| 3 | Omohyoid muscle | 14 | Esophagus | 26 | Aortic arch |
| 4 | Right vagus nerve | 15 | Esophageal plexus | 27 | Left recurrent laryngeal nerve |
| 5 | Clavicle | 16 | Right phrenic nerve (divided) | 28 | Bifurcation of trachea |
| 6 | Right subclavian artery and recurrent laryngeal nerve | 17 | Inferior vena cava | 29 | Left pulmonary artery |
| 7 | Right subclavian vein | 18 | Pericardium covering the diaphragm | 30 | Left primary bronchus |
| 8 | Superior cervical cardiac branch of vagus nerve | 19 | Larynx (thyroid cartilage and cricothyroid muscle) | 31 | Descending aorta |
| 9 | Inferior cervical cardiac branch of vagus nerve | 20 | Thyroid gland | 32 | Left pulmonary veins |
| 10 | Azygos arch (divided) | 21 | Left internal jugular vein | 33 | Branch of left vagus nerve |
| 11 | Right lung | 22 | Esophagus and left recurrent laryngeal nerve | 34 | Left lung |
| | | 23 | Trachea | 35 | Left phrenic nerve (divided) |

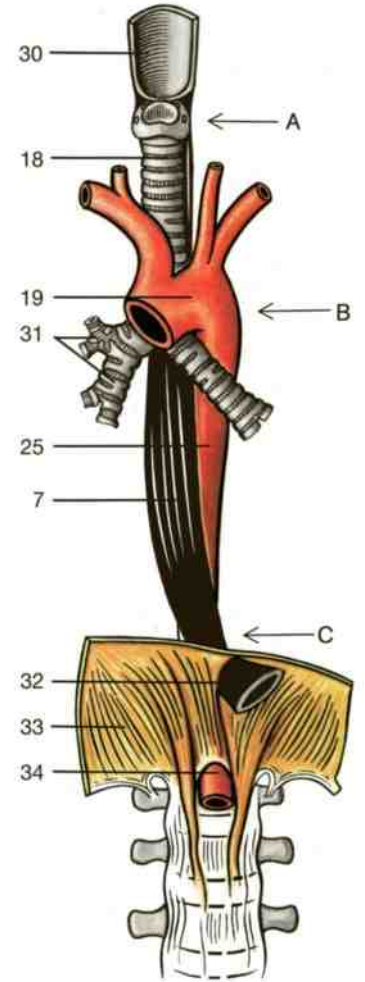


Mediastinal organs (ventral aspect). Heart and distal part of esophagus have been removed to display the vessels and nerves of the posterior mediastinum.

- | | | |
|--|---|-----------------------------------|
| 1 Thyroid gland | 11 Azygos vein | 21 Brachiocephalic trunk |
| 2 Right internal jugular vein | 12 Thoracic duct | 22 Left vagus nerve |
| 3 Right vagus nerve | 13 Posterior intercostal artery and vein (in front of the vertebral column) | 23 Aortic arch |
| 4 Point where right recurrent laryngeal nerve is branching off the vagus nerve | 14 Right phrenic nerve | 24 Left recurrent laryngeal nerve |
| 5 Right brachiocephalic vein | 15 Inferior vena cava | 25 Left bronchial artery |
| 6 Trachea | 16 Diaphragm | 26 Lymph node |
| 7 Left brachiocephalic vein (reflected) | 17 Left vagus nerve | 27 Thoracic aorta |
| 8 Esophagus | 18 Thyrocervical trunk | 28 Esophageal plexus |
| 9 Right bronchial artery | 19 Left subclavian artery | 29 Left phrenic nerve |
| 10 Posterior intercostal artery | 20 Left common carotid artery | |

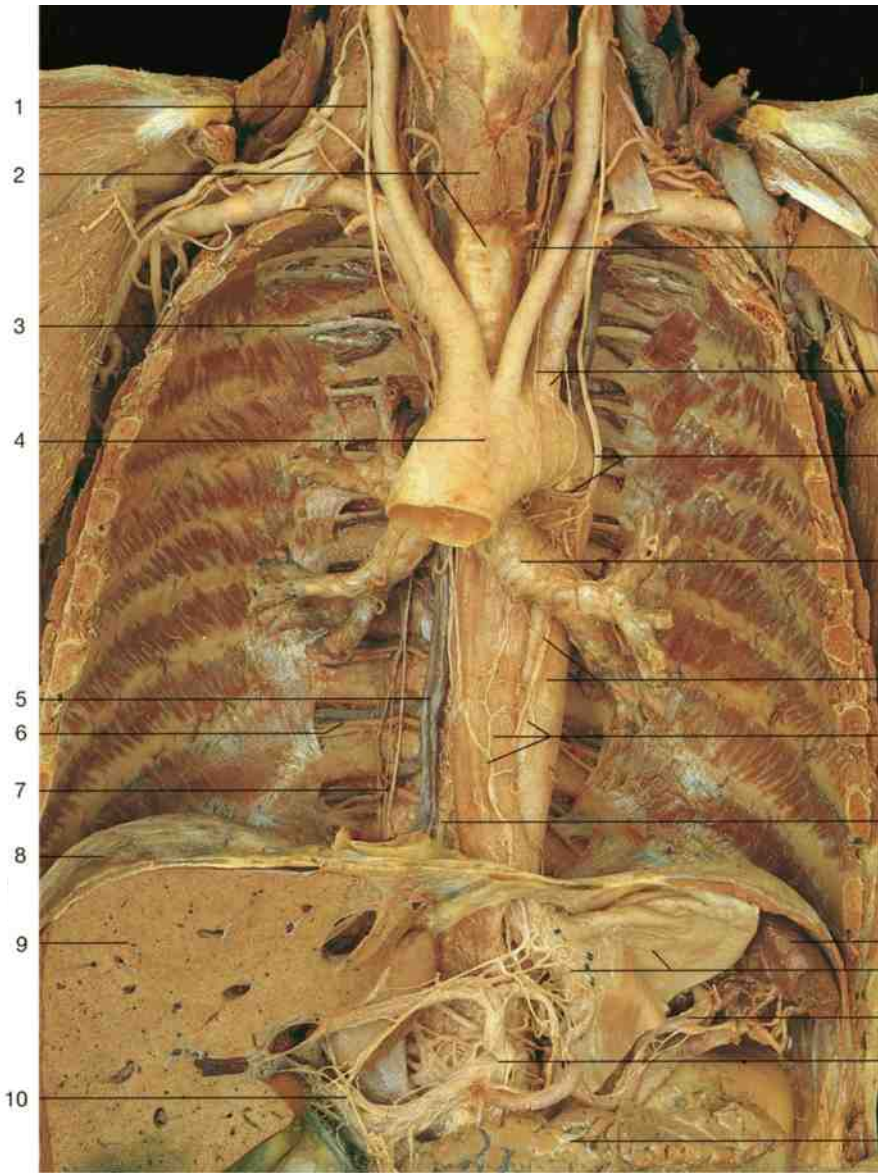


Diaphragm and organs of mediastinum (anterior aspect). Heart and lungs have been removed; the costal margin remains in place. Note the different courses of left and right vagus.

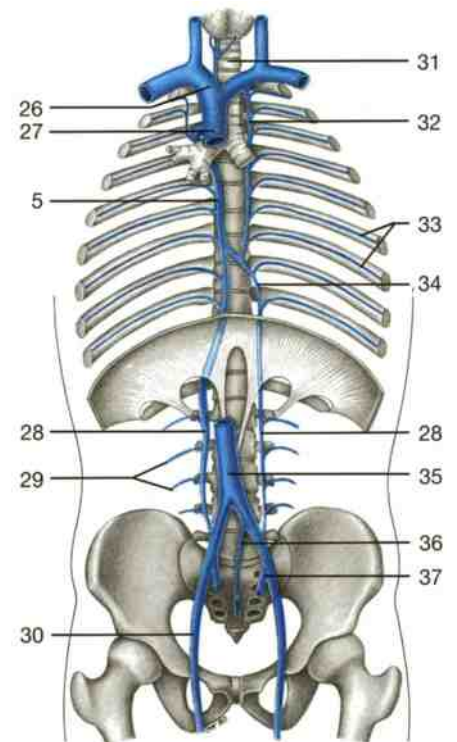


Organs of posterior mediastinum (ventral aspect, schematic drawing). Three regions in which the esophagus is narrowed are shown:
 A = termed upper sphincter (at the level of the cricoid cartilage);
 B = termed middle sphincter (at the level of the aortic arch);
 C = termed lower sphincter (at the level of the diaphragm).

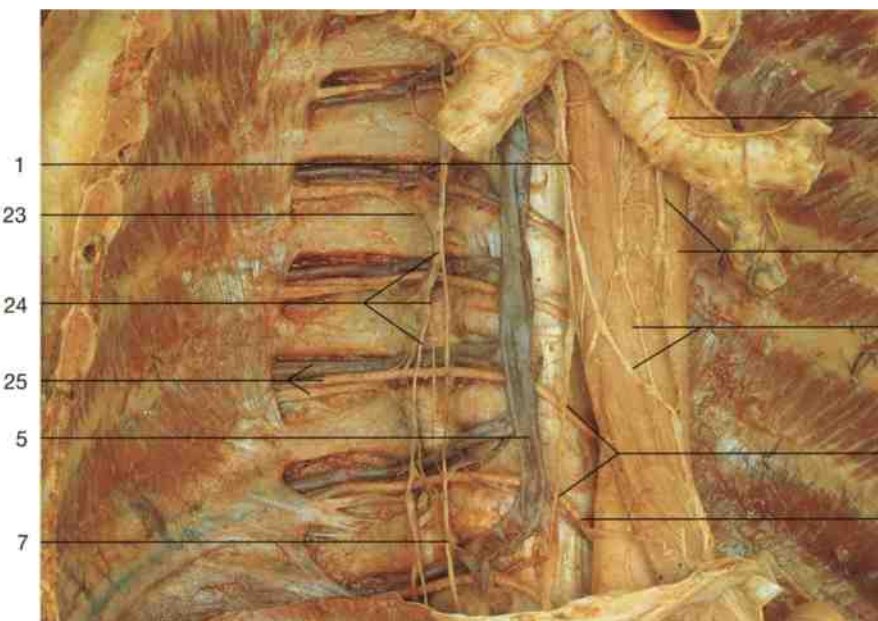
- | | | |
|---|---|---|
| 1 Right subclavian artery | 11 Sternal part of diaphragm | 23 Superior and inferior lingular bronchi |
| 2 Right recurrent laryngeal nerve | 12 Costal part of diaphragm | 24 Esophageal plexus of left vagus nerve |
| 3 Right brachiocephalic vein | 13 Falciform ligament of liver | 25 Descending aorta |
| 4 Superior cervical cardiac nerve | 14 Liver (quadrate lobe) | 26 Central tendon of diaphragm covered with pericardium |
| 5 Inferior cervical cardiac nerves and pulmonary branches | 15 Left common carotid artery | 27 Left phrenic nerve (divided) |
| 6 Bifurcation of trachea | 16 Left recurrent laryngeal nerve | 28 Costal margin |
| 7 Esophagus (thoracic part) | 17 Esophageal branches of left vagus nerve and esophagus | 29 Liver, left lobe |
| 8 Bronchi of lateral and medial segments of middle lobe | 18 Trachea | 30 Pharynx |
| 9 Esophageal plexus and branches of right vagus nerve | 19 Aortic arch | 31 Secondary bronchi |
| 10 Inferior vena cava and right phrenic nerve (cut) | 20 Left vagus nerve | 32 Esophagus (abdominal part) |
| | 21 Left recurrent laryngeal nerve with inferior cardiac nerve | 33 Diaphragm |
| | 22 Left primary bronchus | 34 Abdominal aorta |



Organs of posterior mediastinum (anterior aspect).

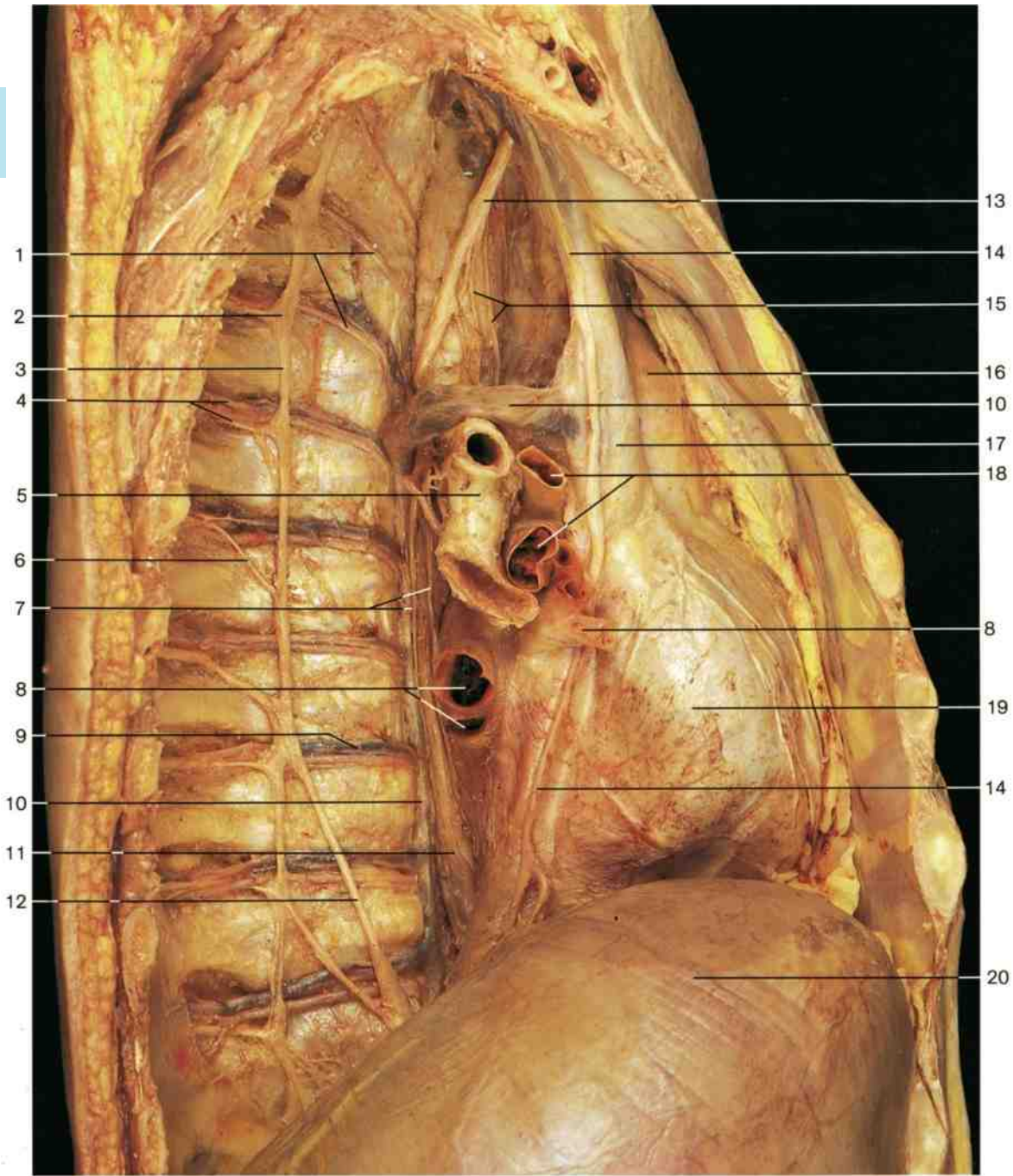
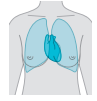


Veins of the posterior wall of thoracic and abdominal cavity (schematic drawing).



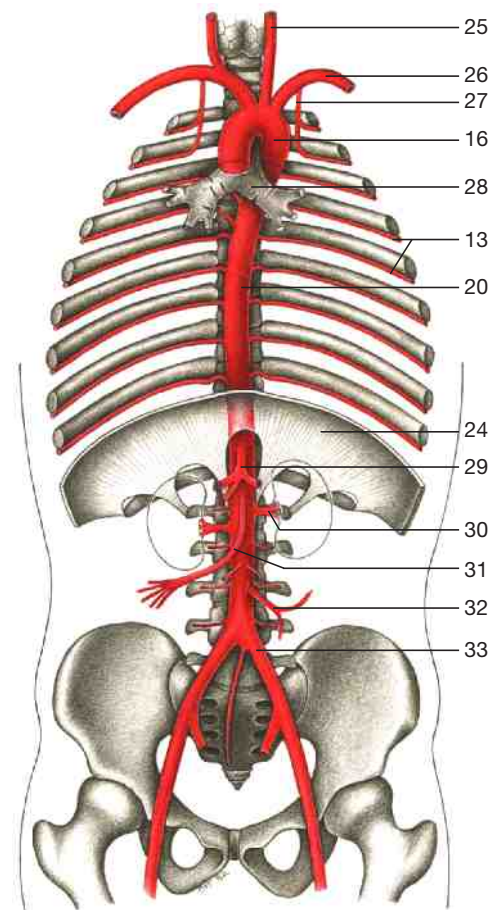
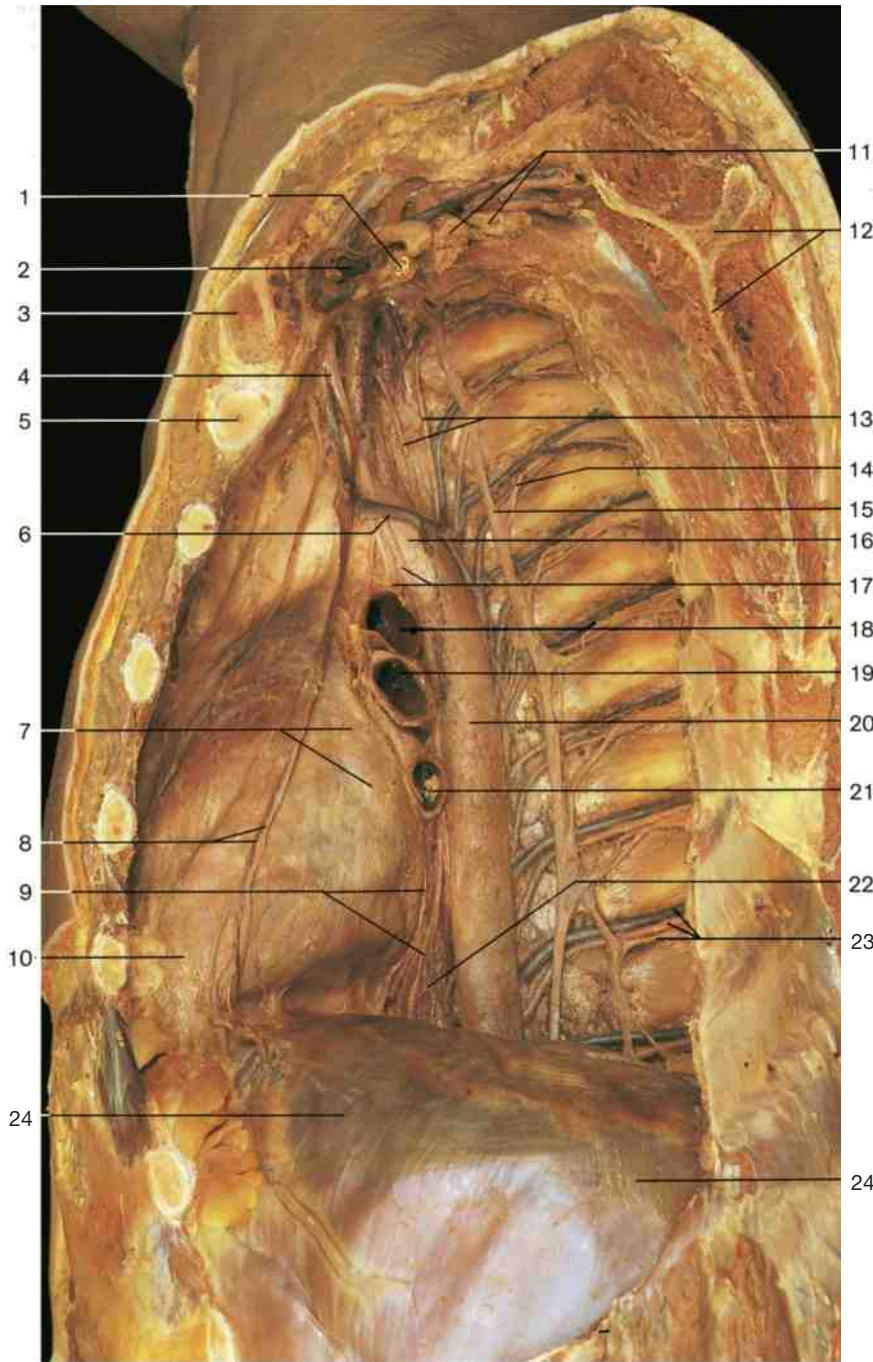
Inferior segment of posterior mediastinum (anterior aspect).

- 1 Right vagus nerve
- 2 Thyroid gland and trachea
- 3 Intercostal nerve
- 4 Aortic arch
- 5 Azygos vein
- 6 Posterior intercostal artery
- 7 Greater splanchnic nerve
- 8 Diaphragm
- 9 Liver
- 10 Proper hepatic artery and hepatic plexus
- 11 Left recurrent laryngeal nerve
- 12 Inferior cervical cardiac nerves
- 13 Left vagus nerve and left recurrent laryngeal nerve
- 14 Left primary bronchus
- 15 Thoracic aorta and left vagus nerve
- 16 Esophagus and esophageal plexus
- 17 Thoracic duct
- 18 Spleen
- 19 Anterior gastric plexus and stomach (divided)
- 20 Splenic artery and splenic plexus
- 21 Celiac trunk and celiac plexus
- 22 Pancreas
- 23 Ramus communicans
- 24 Sympathetic trunk and sympathetic ganglion
- 25 Posterior intercostal vein and artery and intercostal nerve
- 26 Right brachiocephalic vein
- 27 Superior vena cava
- 28 Ascending lumbar vein
- 29 Lumbar veins
- 30 Right external iliac vein
- 31 Trachea
- 32 Accessory hemiazygos vein
- 33 Posterior intercostal veins
- 34 Hemiazygos vein
- 35 Inferior vena cava
- 36 Median sacral vein
- 37 Internal iliac vein



Mediastinal organs (right lateral aspect). Right lung and pleura of right half of the thorax have been removed.

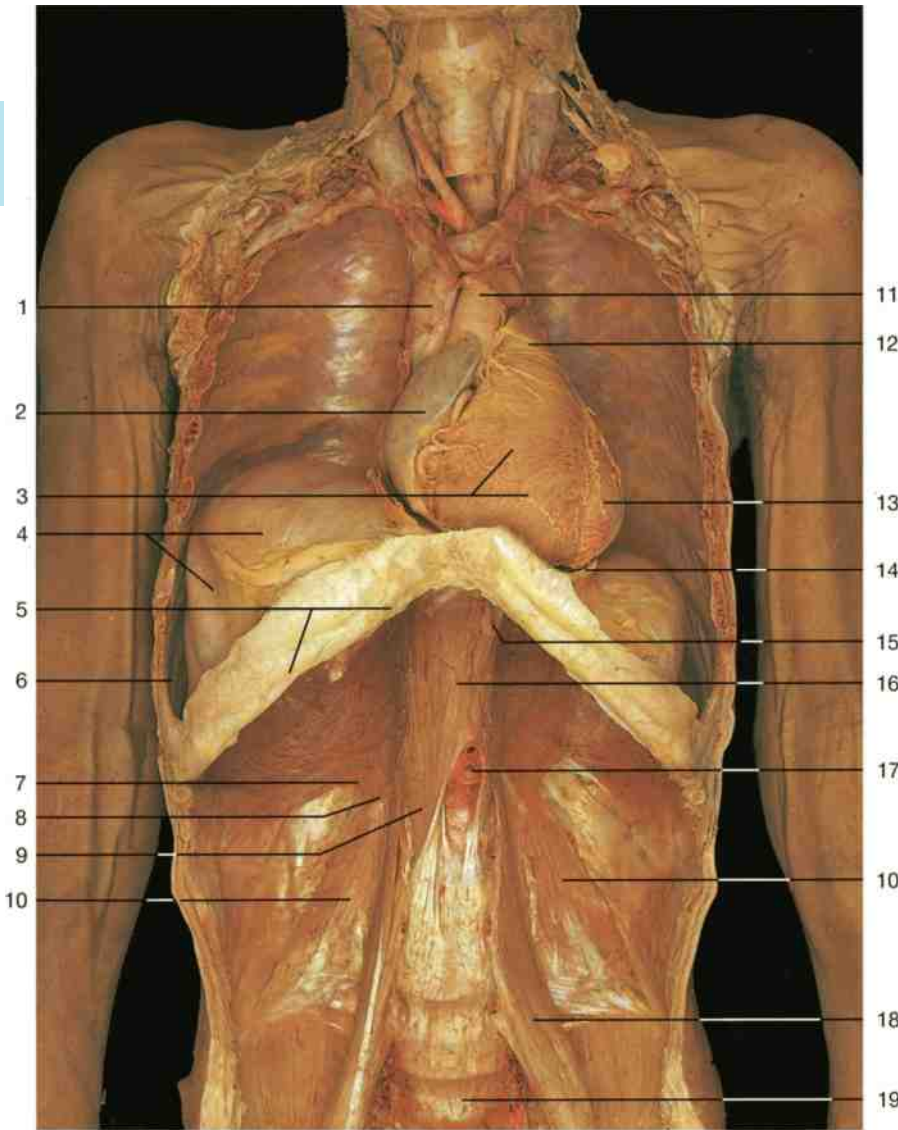
- | | | | | | |
|---|---|----|---|----|---|
| 1 | Posterior intercostal arteries | 7 | Esophageal plexus (branches of right vagus nerve) | 14 | Right phrenic nerve |
| 2 | Ganglion of sympathetic trunk | 8 | Pulmonary veins | 15 | Inferior cervical cardiac branches of vagus nerve |
| 3 | Sympathetic trunk | 9 | Posterior intercostal vein | 16 | Aortic arch |
| 4 | Vessels and nerves of the intercostal space (from above: posterior intercostal vein and artery and intercostal nerve) | 10 | Azygos vein | 17 | Superior vena cava |
| 5 | Right primary bronchus | 11 | Esophagus | 18 | Right pulmonary artery |
| 6 | Ramus communicans of sympathetic trunk | 12 | Greater splanchnic nerve | 19 | Heart with pericardium |
| | | 13 | Right vagus nerve | 20 | Diaphragm |



Main branches of descending aorta (schematic drawing).

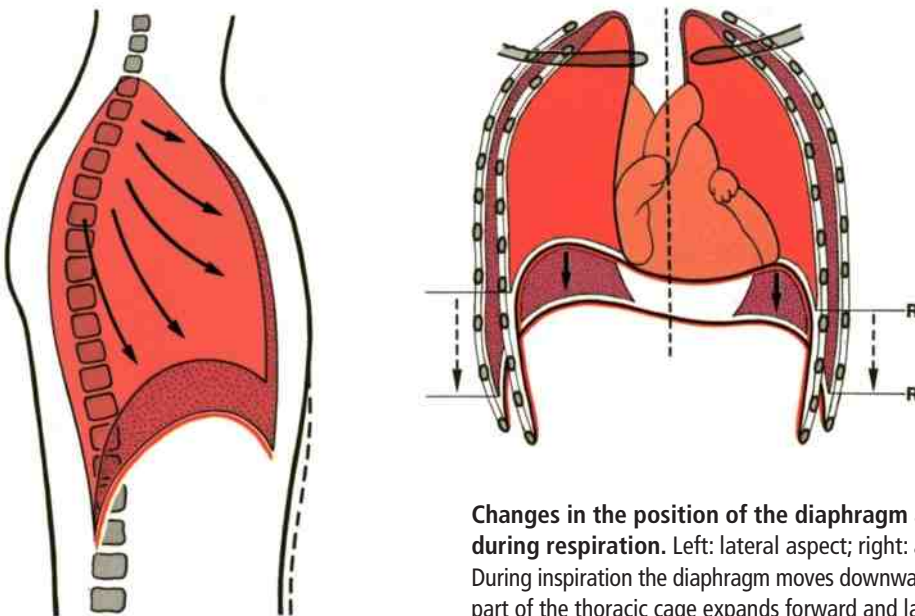
Organs of posterior and superior mediastinum (left lateral aspect).

- | | | |
|--|--|--|
| 1 Subclavian artery | 12 Scapula (divided) | 23 Posterior intercostal artery and vein and intercostal nerve |
| 2 Subclavian vein | 13 Posterior intercostal arteries | 24 Diaphragm |
| 3 Clavicle (divided) | 14 White ramus communicans of sympathetic trunk | 25 Common carotid artery |
| 4 Left vagus nerve | 15 Sympathetic trunk | 26 Subclavian artery |
| 5 First rib (divided) | 16 Aortic arch | 27 Highest intercostal artery |
| 6 Left superior intercostal vein | 17 Left vagus nerve and left recurrent laryngeal nerve | 28 Bifurcation of trachea |
| 7 Left atrium with pericardium | 18 Left pulmonary artery | 29 Celiac trunk |
| 8 Left phrenic nerve and pericardiophrenic artery and vein | 19 Left primary bronchus | 30 Renal artery |
| 9 Esophageal plexus (branches derived from left vagus nerve) | 20 Thoracic aorta | 31 Superior mesenteric artery |
| 10 Apex of heart with pericardium | 21 Pulmonary vein | 32 Inferior mesenteric artery |
| 11 Brachial plexus | 22 Esophagus (thoracic part) | 33 Common iliac artery |

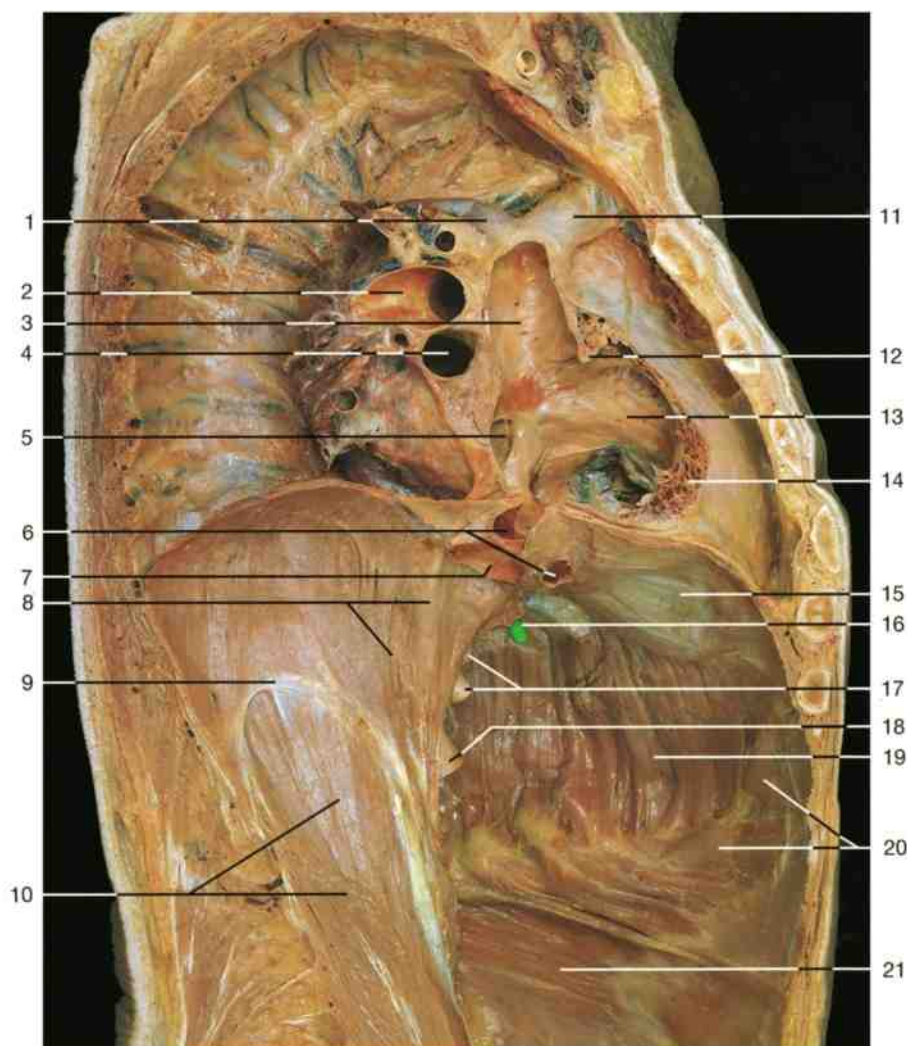


- 1 Superior vena cava
- 2 Right atrium
- 3 Right ventricle
- 4 Costal part of diaphragm
- 5 Costal margin
- 6 Position of costodiaphragmatic recess
- 7 Lateral arcuate ligament
- 8 Medial arcuate ligament
- 9 Right crus of lumbar part of diaphragm
- 10 Quadratus lumborum muscle
- 11 Ascending aorta
- 12 Pulmonary trunk
- 13 Left ventricle
- 14 Pericardium, diaphragm
- 15 Esophageal hiatus and abdominal part of esophagus (cut)
- 16 Lumbar part of diaphragm
- 17 Aortic hiatus
- 18 Psoas major muscle
- 19 Lumbar vertebra

Diaphragm in situ (anterior aspect). Anterior walls of thoracic and abdominal cavities have been removed. Natural position of the heart above the central tendon on the diaphragm is shown.

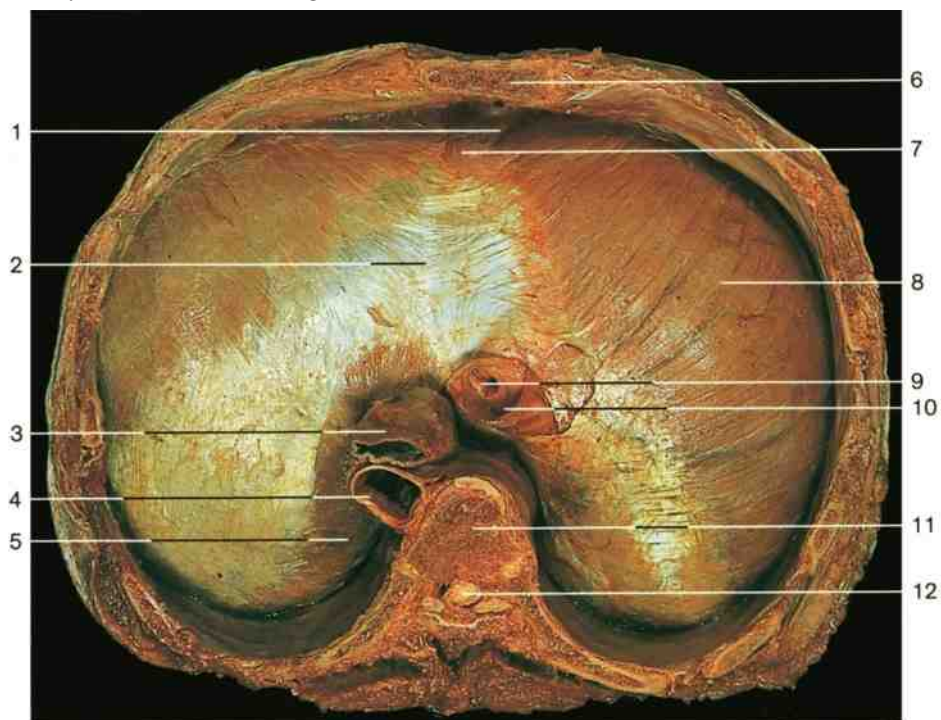


Changes in the position of the diaphragm and thoracic cage during respiration. Left: lateral aspect; right: anterior aspect. During inspiration the diaphragm moves downwards and the lower part of the thoracic cage expands forward and laterally, causing the costodiaphragmatic recess (R) to enlarge (cf. dotted arrows).



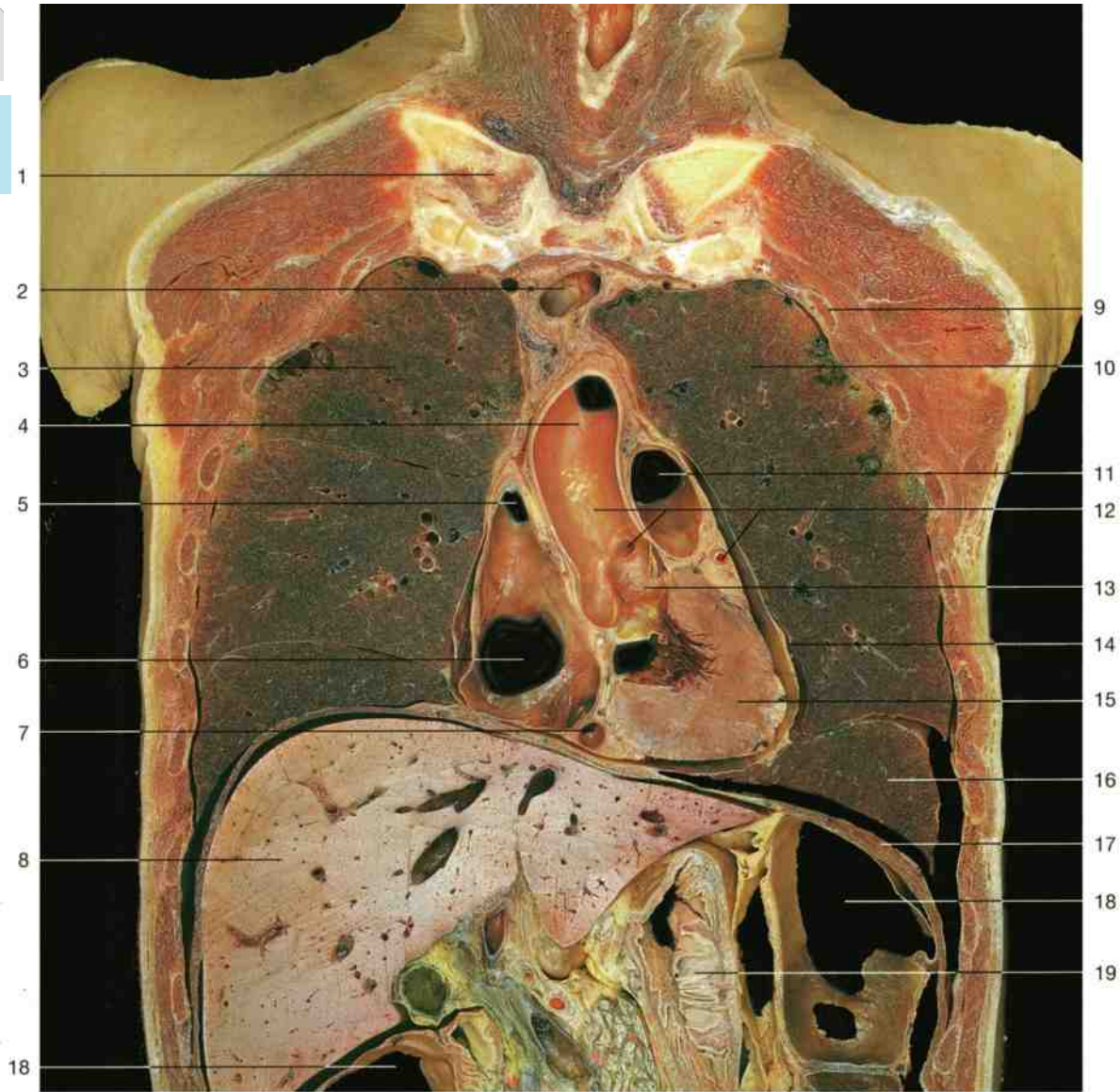
- 1 Azygos venous arch
- 2 Right pulmonary artery
- 3 Superior vena cava
- 4 Right pulmonary vein
- 5 Fossa ovalis
- 6 Hepatic veins
- 7 Inferior vena cava
- 8 Right crus of lumbar part of diaphragm
- 9 Medial arcuate ligament
- 10 Psoas major muscle
- 11 Left brachiocephalic vein
- 12 Terminal crista
- 13 Right atrium
- 14 Right auricle
- 15 Central tendon of diaphragm
- 16 Esophagus
- 17 Celiac trunk and superior mesenteric artery
- 18 Aorta
- 19 Costal part of diaphragm
- 20 Costal margin
- 21 Transversus abdominis muscle

Diaphragm. Paramedian section to the right of the median plane through thoracic and upper abdominal cavities. The plane passes through the superior and inferior vena cava just to the right of the vertebral bodies. Most of the heart remains in situ to the left of this plane (viewed from the right side).

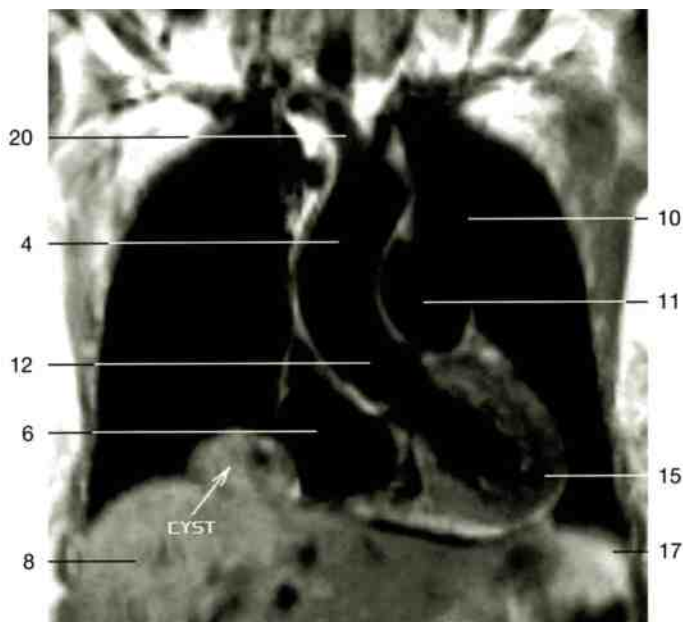


- 1 Sternocostal triangle
- 2 Central tendon (from above)
- 3 Esophagus
- 4 Aorta
- 5 Lumbar part of diaphragm
- 6 Sternum
- 7 Sternal part of diaphragm
- 8 Costal part of diaphragm
- 9 Entrance of hepatic veins
- 10 Inferior vena cava
- 11 Body of 9th thoracic vertebra
- 12 Spinal cord

Diaphragm (superior aspect). The pleura and pericardium have been removed.

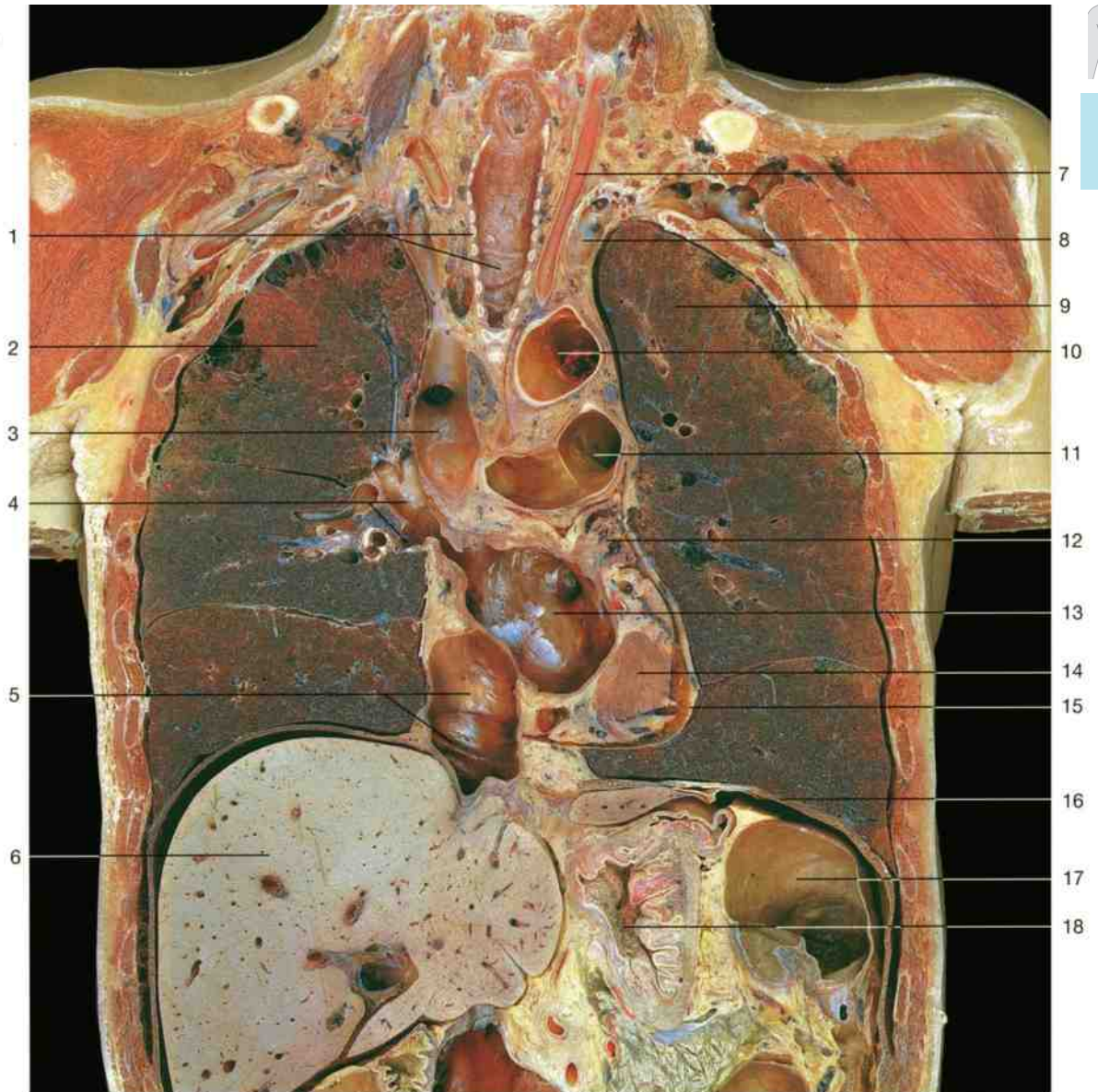


Coronal section through the thorax at the level of ascending aorta (anterior aspect).

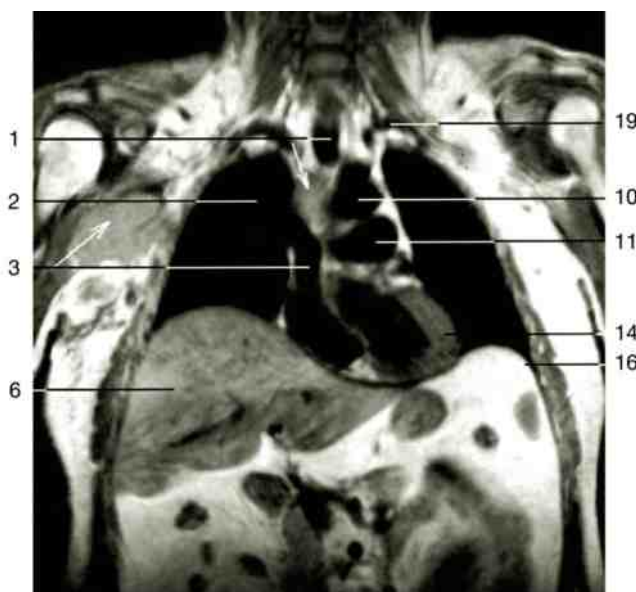

Coronal section through the thorax at the level of ascending aorta (MRI scan).

- 1 Clavicle
- 2 Left brachiocephalic vein
- 3 Upper lobe of right lung
- 4 Aortic arch
- 5 Superior vena cava
- 6 Right atrium (entrance of inferior vena cava)
- 7 Coronary sinus
- 8 Liver
- 9 Second rib
- 10 Upper lobe of left lung
- 11 Pulmonary trunk
- 12 Ascending aorta and left coronary artery
- 13 Aortic valve
- 14 Pericardium
- 15 Myocardium of left ventricle
- 16 Lower lobe of left lung
- 17 Diaphragm
- 18 Colic flexures
- 19 Stomach
- 20 Brachiocephalic trunk

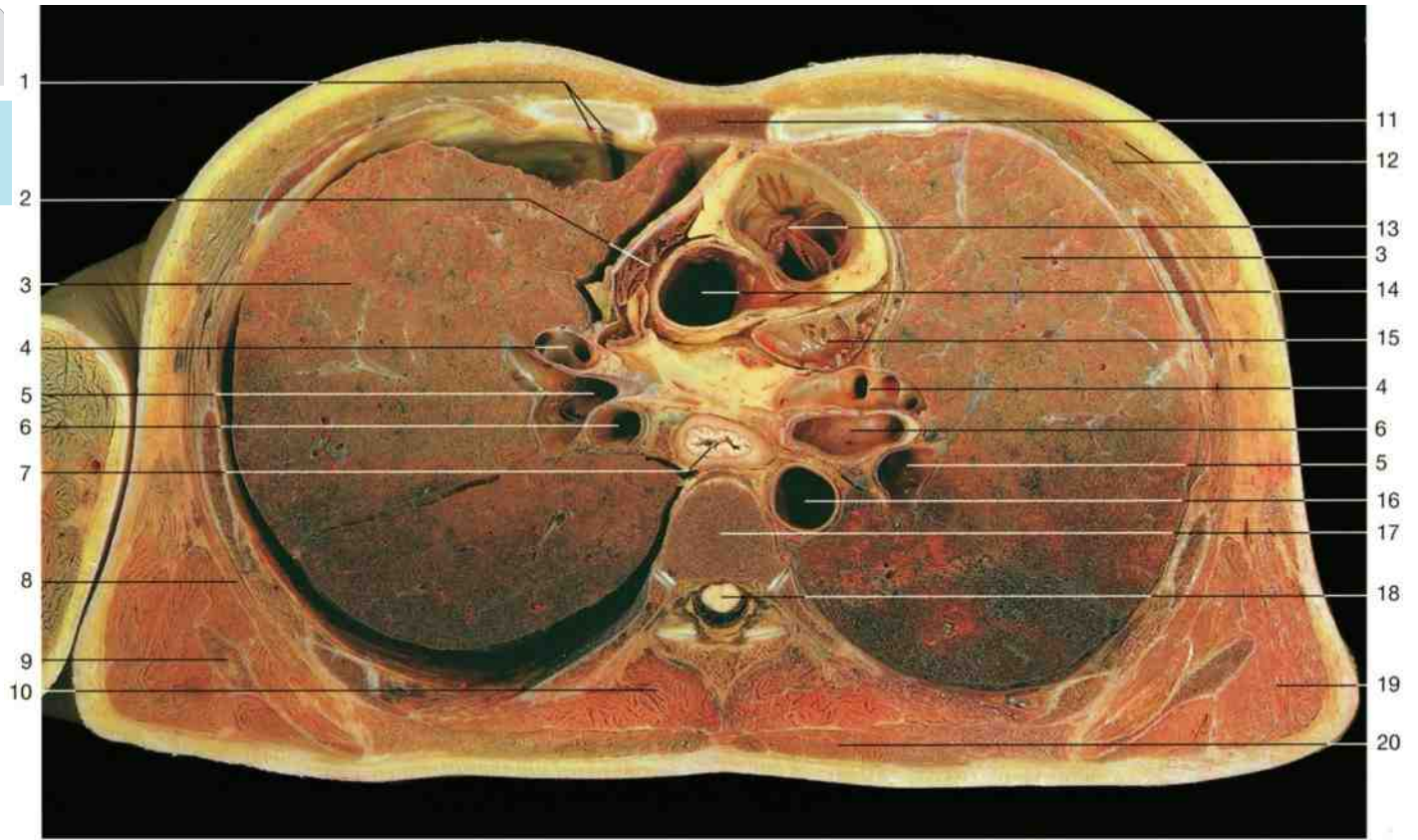
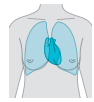


Coronal section through the thorax at the level of superior and inferior vena cava (anterior aspect).

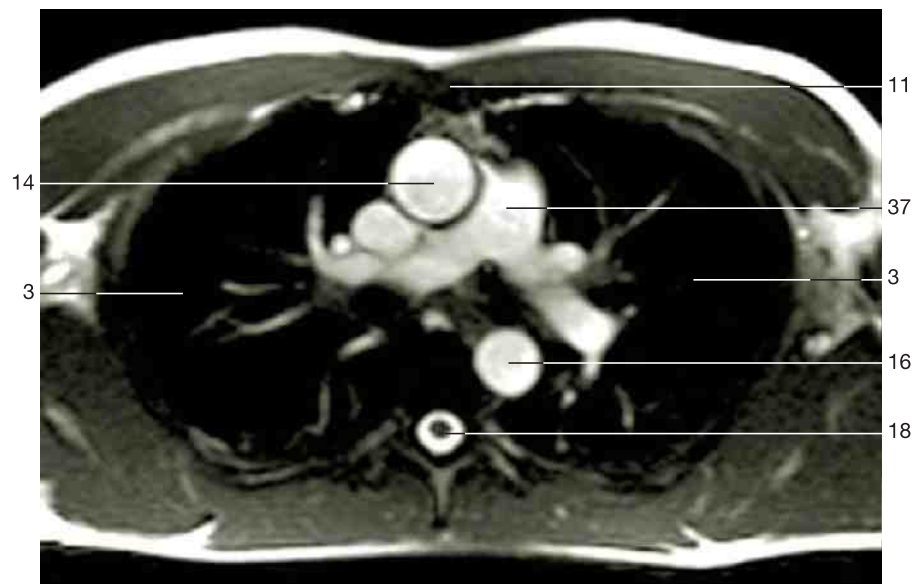


Coronal section through the thorax at the level of superior vena cava (MRI scan). Arrows = metastases of tumor.

- 1 Trachea
- 2 Upper lobe of right lung
- 3 Superior vena cava
- 4 Right pulmonary veins
- 5 Inferior vena cava and right atrium
- 6 Liver
- 7 Left common carotid artery
- 8 Left subclavian vein
- 9 Upper lobe of left lung
- 10 Aortic arch
- 11 Left pulmonary artery
- 12 Left auricle
- 13 Left atrium with orifices of pulmonary veins
- 14 Left ventricle (myocardium)
- 15 Pericardium
- 16 Diaphragm
- 17 Left colic flexure
- 18 Stomach
- 19 Left subclavian artery

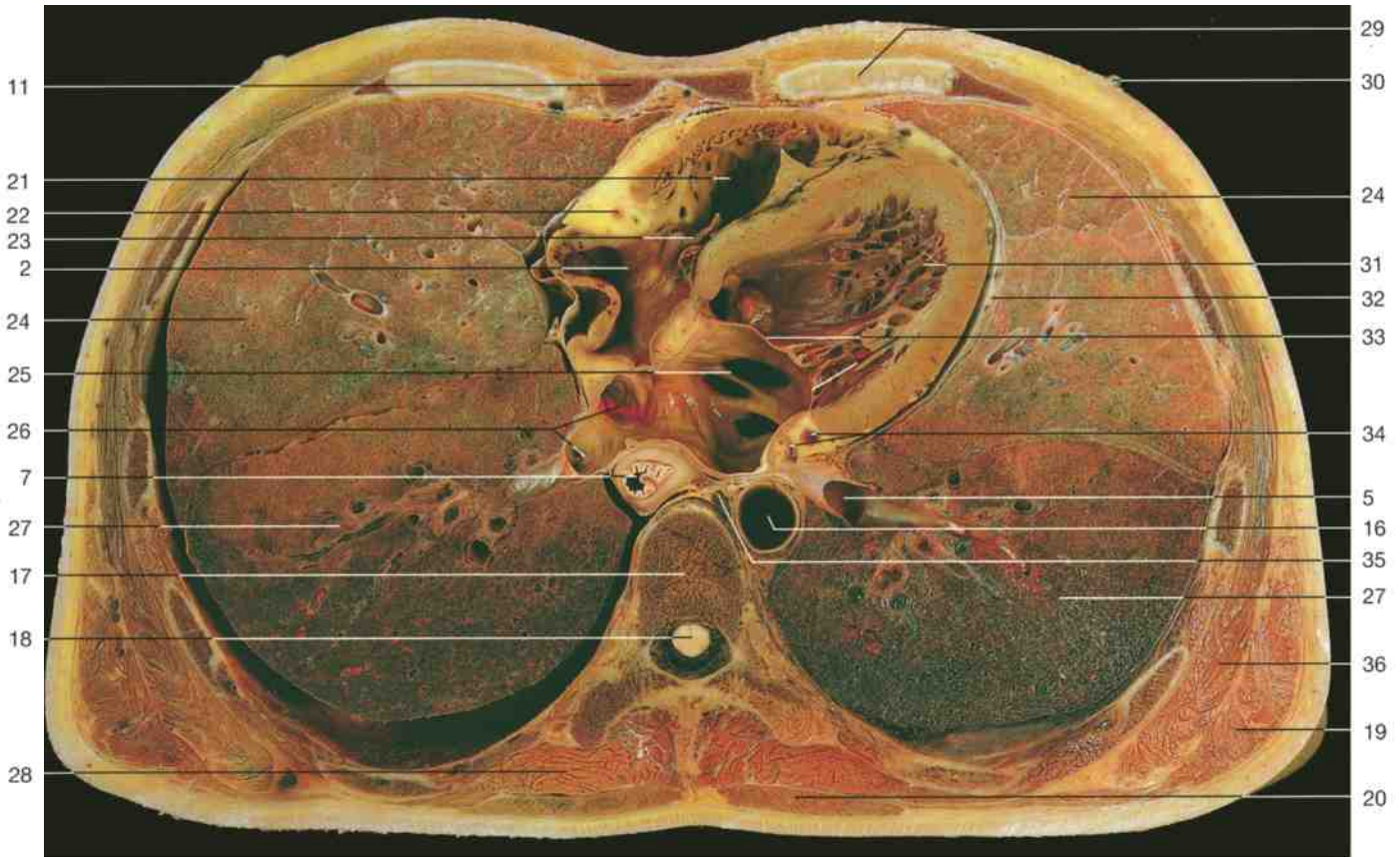

Horizontal section through the thorax at level 1 (from below).

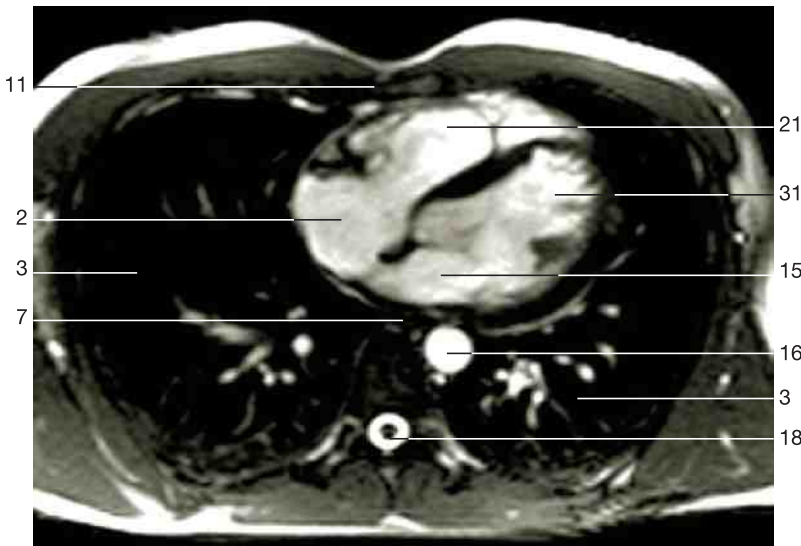


Horizontal section through the thorax at level 1 (from below). (MRI scan, courtesy of Prof. W. Bautz and R. Janka, M. D., University of Erlangen, Germany.)

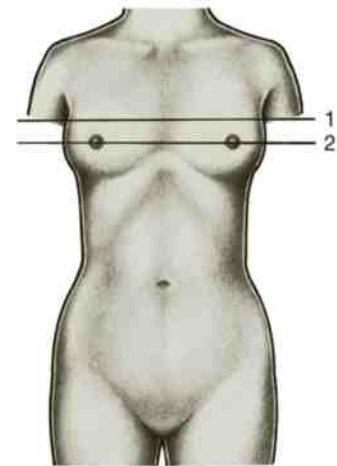
- | | |
|-------------------------------------|--|
| 1 Internal thoracic artery and vein | 12 Pectoralis major and minor muscles |
| 2 Right atrium | 13 Conus arteriosus (right ventricle), pulmonic valve |
| 3 Lung | 14 Ascending aorta and left coronary artery (only in upper figure) |
| 4 Pulmonary artery | 15 Left atrium |
| 5 Pulmonary vein | 16 Descending aorta |
| 6 Primary bronchus | 17 Thoracic vertebra |
| 7 Esophagus | 18 Spinal cord |
| 8 Serratus anterior muscle | 19 Latissimus dorsi muscle |
| 9 Scapula | 20 Trapezius muscle |
| 10 Longissimus thoracis muscle | |
| 11 Sternum | |



Horizontal section through the thorax at level 2 (from below).

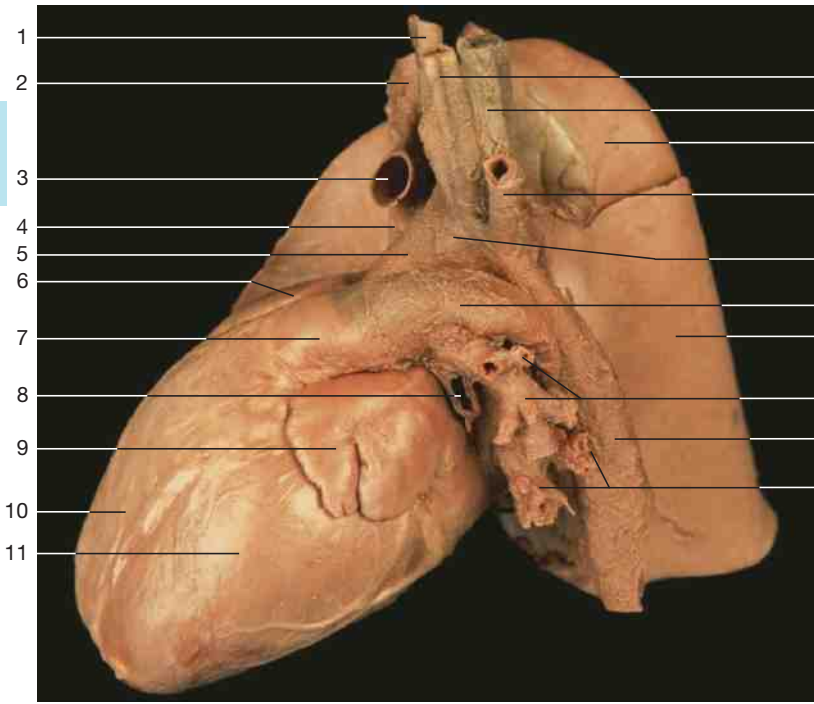
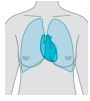

Horizontal section through the thorax at level 2 (from below). (MRI scan, courtesy of Prof. W. Bautz and R. Janka, M. D., University of Erlangen, Germany.)

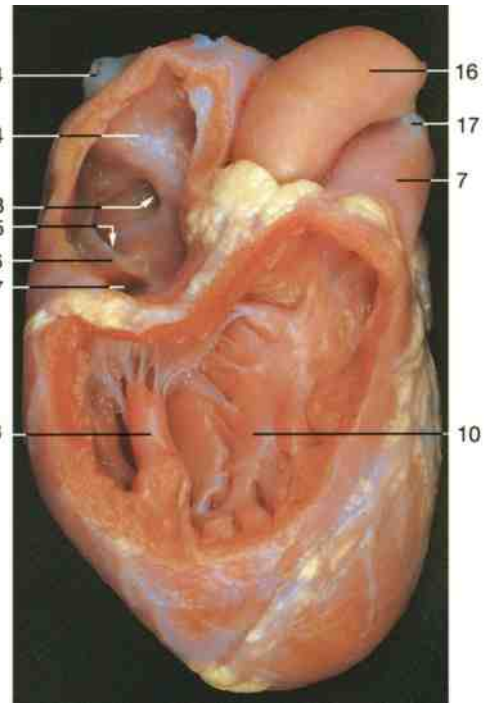


Levels of sections.

- | | |
|---------------------------------|--|
| 21 Right ventricle | 30 Nipple |
| 22 Right coronary artery | 31 Left ventricle |
| 23 Right atrioventricular valve | 32 Pericardium |
| 24 Lung (upper lobe) | 33 Left atrioventricular valve |
| 25 Left atrium | 34 Left coronary artery and coronary sinus |
| 26 Pulmonary veins | 35 Accessory hemiazygos vein |
| 27 Lung (lower lobe) | 36 Serratus anterior muscle |
| 28 Erector muscle of spine | 37 Pulmonary trunk |
| 29 Third costal cartilage | |



Heart and right lung of the fetus (viewed from left side). The left lung has been removed. Note the ductus arteriosus (Botalli).

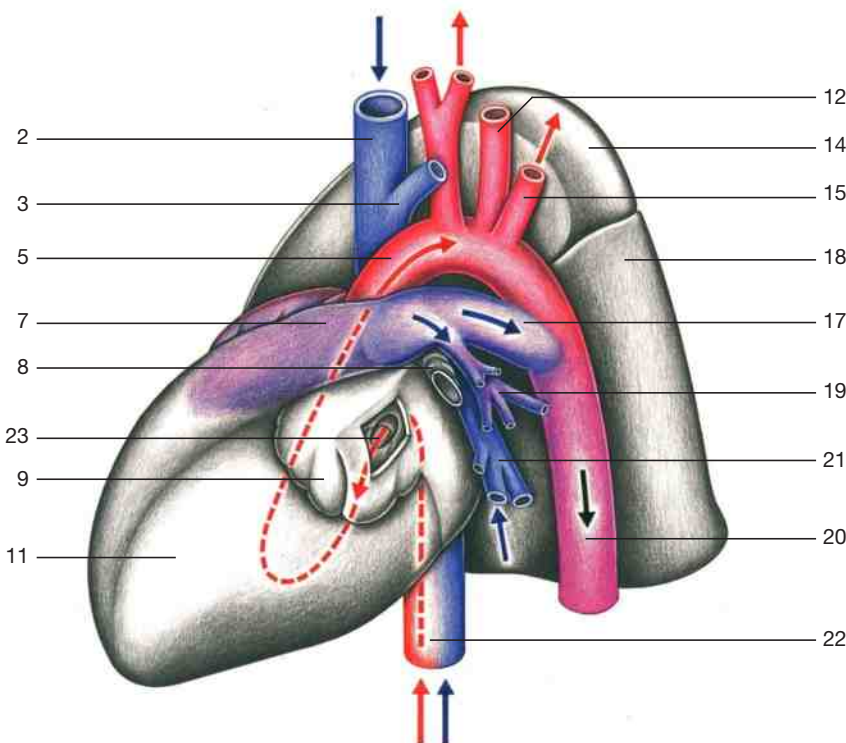


Heart of the fetus (anterior aspect). Right atrium and ventricle opened.

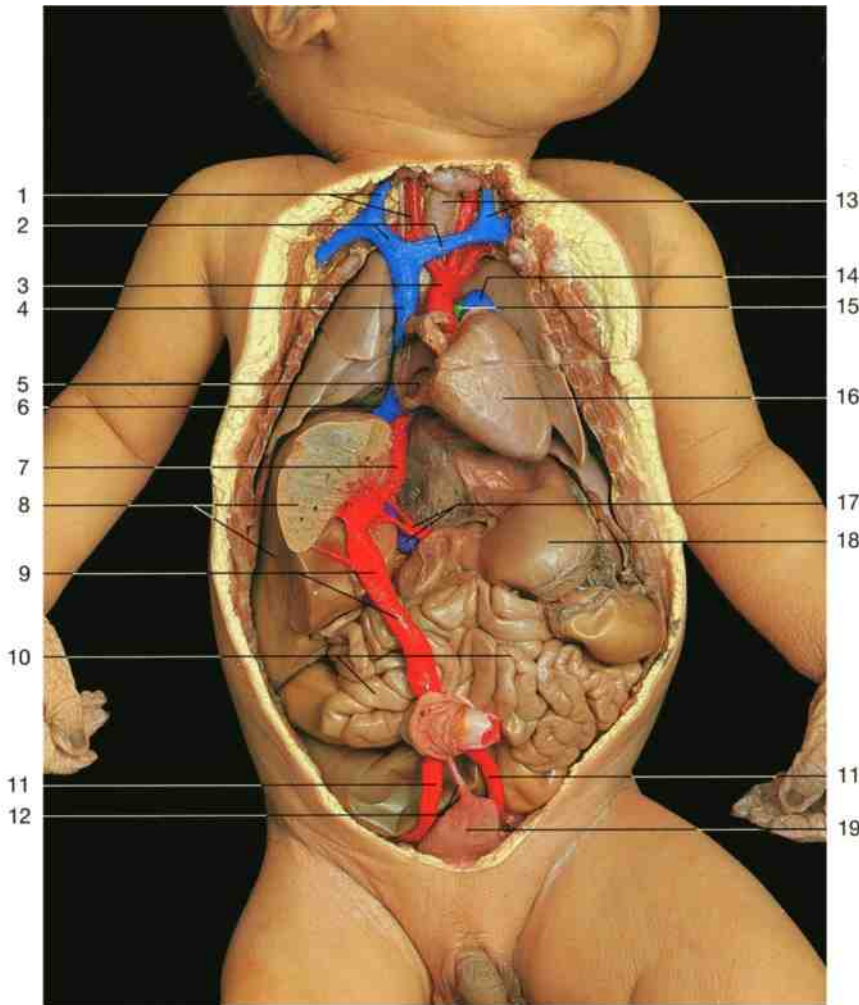
Shunts in the fetal circulation system

1. Ductus venosus (of Arantius)	between umbilical vein and inferior vena cava	bypass of liver circulation
2. Foramen ovale	between right and left atrium	bypass of pulmonary circulation
3. Ductus arteriosus (Botalli)	between pulmonary trunk and aorta	

- 1 Right common carotid artery
- 2 Right brachiocephalic vein
- 3 Left brachiocephalic vein
- 4 Superior vena cava
- 5 Ascending aorta
- 6 Right auricle
- 7 Pulmonary trunk
- 8 Left primary bronchus
- 9 Left auricle
- 10 Right ventricle
- 11 Left ventricle
- 12 Left common carotid artery
- 13 Trachea
- 14 Superior lobe of right lung
- 15 Left subclavian artery
- 16 Aortic arch
- 17 Ductus arteriosus (Botalli)
- 18 Inferior lobe of right lung
- 19 Left pulmonary artery with branches to the left lung
- 20 Descending aorta
- 21 Left pulmonary veins
- 22 Inferior vena cava
- 23 Foramen ovale
- 24 Right atrium
- 25 Opening of inferior vena cava
- 26 Valve of inferior vena cava (Eustachian valve)
- 27 Opening of coronary sinus
- 28 Anterior papillary muscle of right ventricle

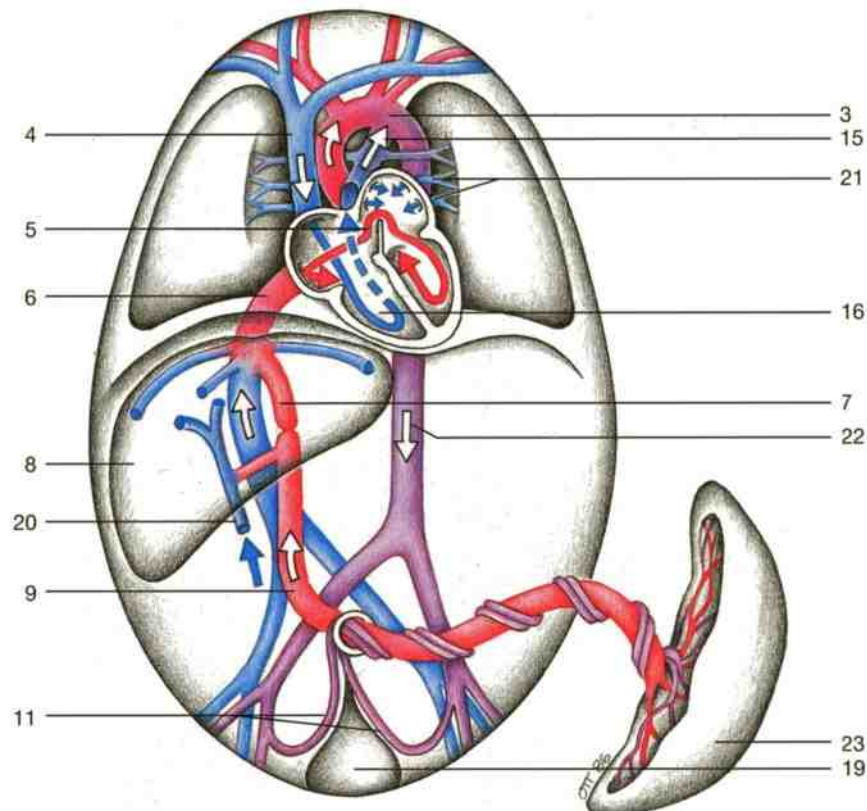


◁ **Heart of the fetus** (schematic drawing). Direction of blood flow indicated by arrows. Note the change in oxygenation of blood after ductus arteriosus entry into aorta.

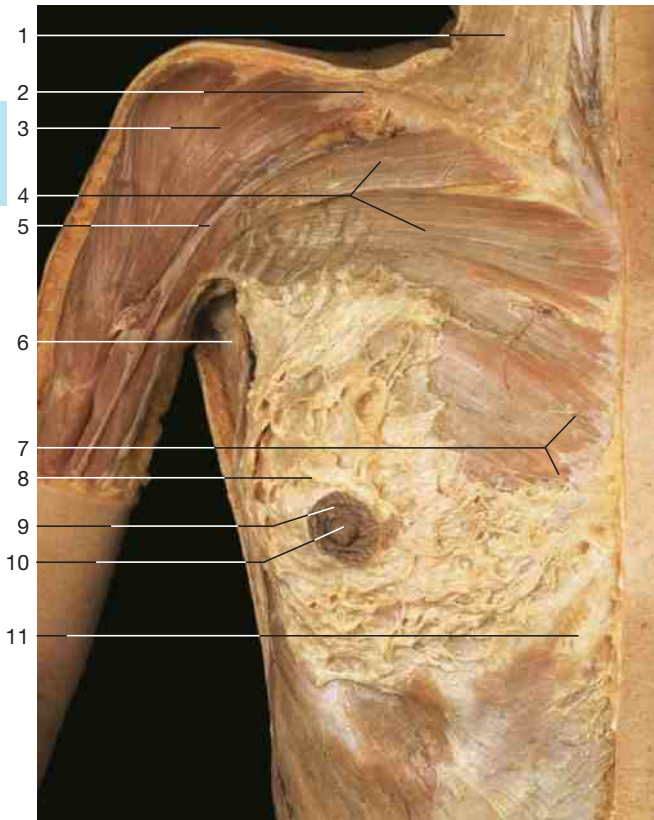


- 1 Internal jugular vein and right common carotid artery
- 2 Right and left brachiocephalic vein
- 3 Aortic arch
- 4 Superior vena cava
- 5 Foramen ovale
- 6 Inferior vena cava
- 7 Ductus venosus
- 8 Liver
- 9 Umbilical vein
- 10 Small intestine
- 11 Umbilical artery
- 12 Urachus
- 13 Trachea and left internal jugular vein
- 14 Left pulmonary artery
- 15 Ductus arteriosus (Botalli)
- 16 Right ventricle
- 17 Hepatic arteries (red) and portal vein (blue)
- 18 Stomach
- 19 Urinary bladder
- 20 Portal vein
- 21 Pulmonary veins
- 22 Descending aorta
- 23 Placenta

Thoracic and abdominal organs in the newborn (anterior aspect). The right atrium has been opened to show the foramen ovale. The left lobe of the liver has been removed.

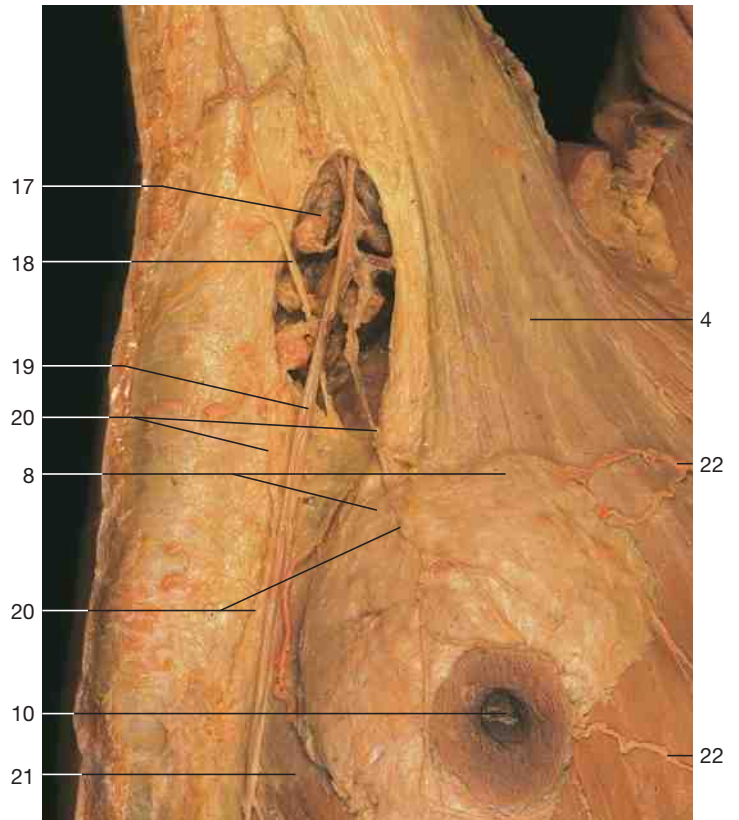


◁ Fetal circulatory system (schematic drawing). The oxygen gradient is indicated by color.



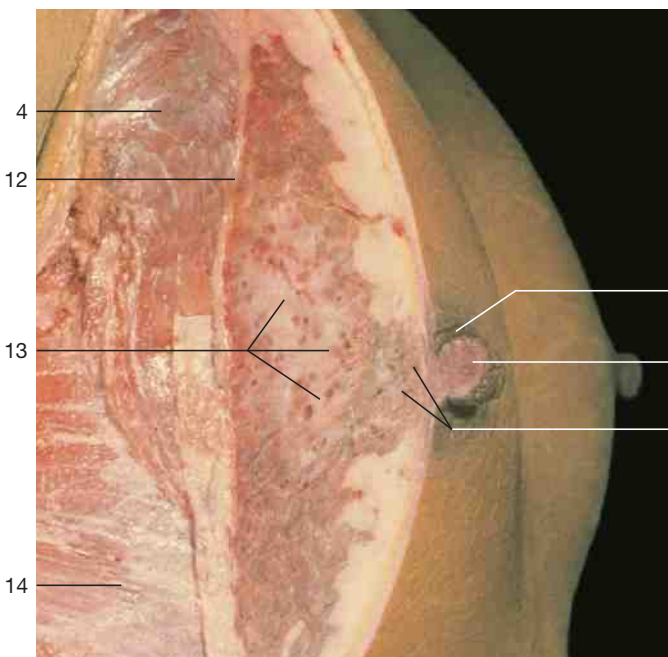
Dissection of mammary gland (anterior aspect).

- | | |
|---|---|
| 1 Platysma muscle | 8 Breast tissue |
| 2 Clavicle | 9 Areola |
| 3 Deltoid muscle | 10 Nipple (papilla) |
| 4 Pectoralis major muscle | 11 Costal margin |
| 5 Deltopectoral groove and cephalic vein | 12 Pectoral fascia |
| 6 Latissimus dorsi muscle | 13 Mammary gland |
| 7 Medial mammarian branches of intercostal nerves | 14 Serratus anterior muscle (insertion) |
| | 15 Lactiferous sinus |

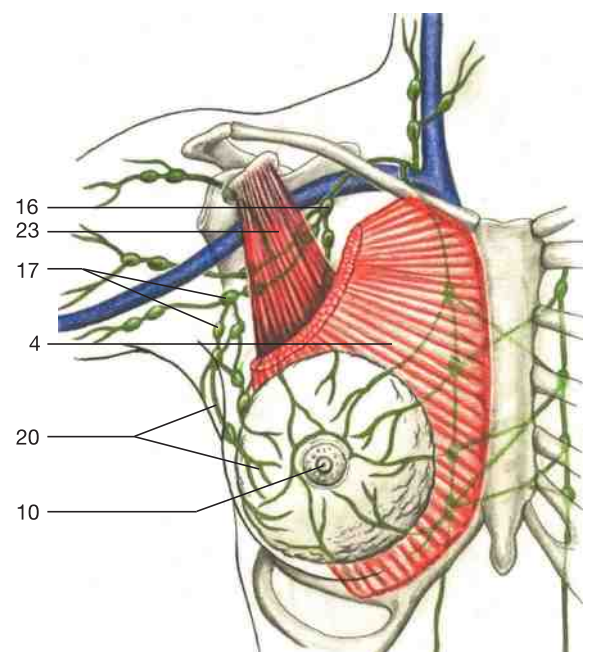


Dissection of mammary gland and axillary lymph nodes.

- | |
|--|
| 16 Apical lymph nodes |
| 17 Axillary lymph nodes |
| 18 Intercostobrachial nerve |
| 19 Lateral thoracic vein |
| 20 Lymph vessels |
| 21 Serratus anterior muscle |
| 22 Medial branches of intercostal arteries |
| 23 Pectoralis minor muscle |

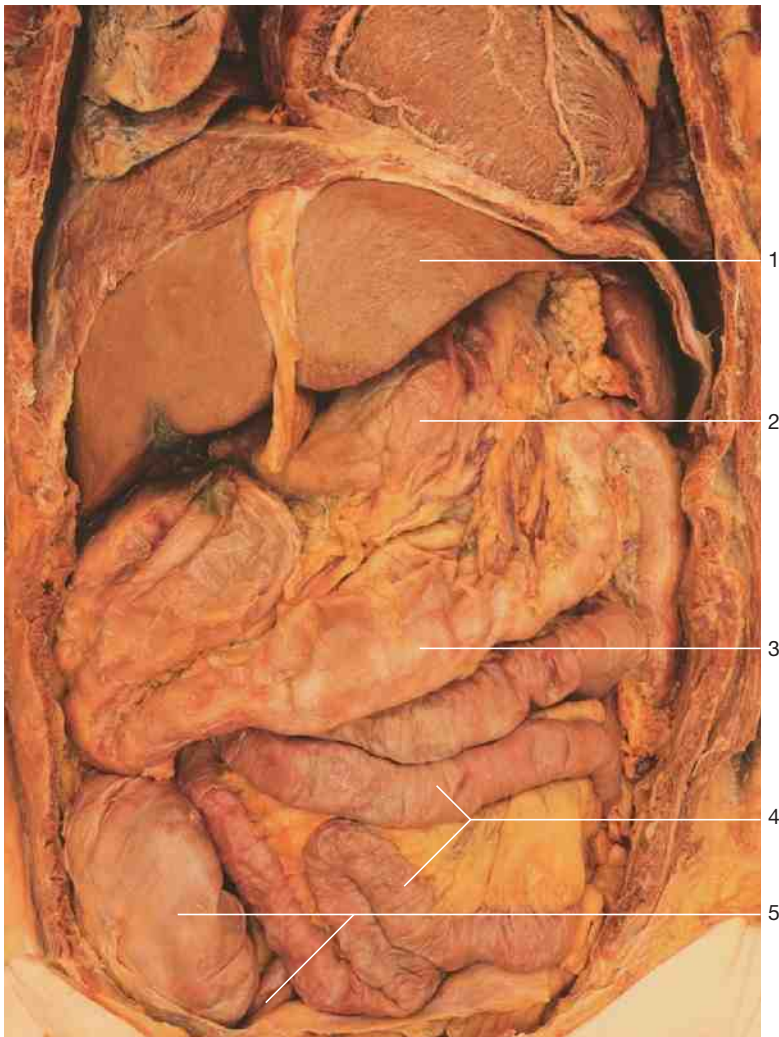
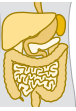

Mammary gland (sagittal section) of a pregnant female.



Lymphatics of the breast and axilla. Most lymph vessels drain into the axillary lymph nodes.

5 Abdominal Organs

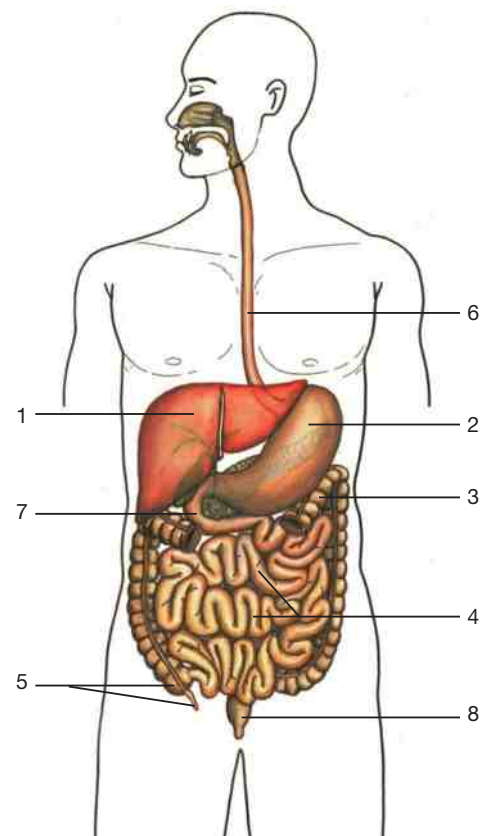


Abdominal organs in situ (anterior aspect). The greater omentum and part of the diaphragm have been removed. The heart is in contact with the diaphragm (from Lütjen-Drecoll, Rohen, *Innenansichten des menschlichen Körpers*, 2010).

The abdominal cavity located underneath the diaphragm contains the main organs of the digestive system (liver, spleen, stomach, intestine). The greater omentum partly fixed to the transverse colon covers the small intestine.

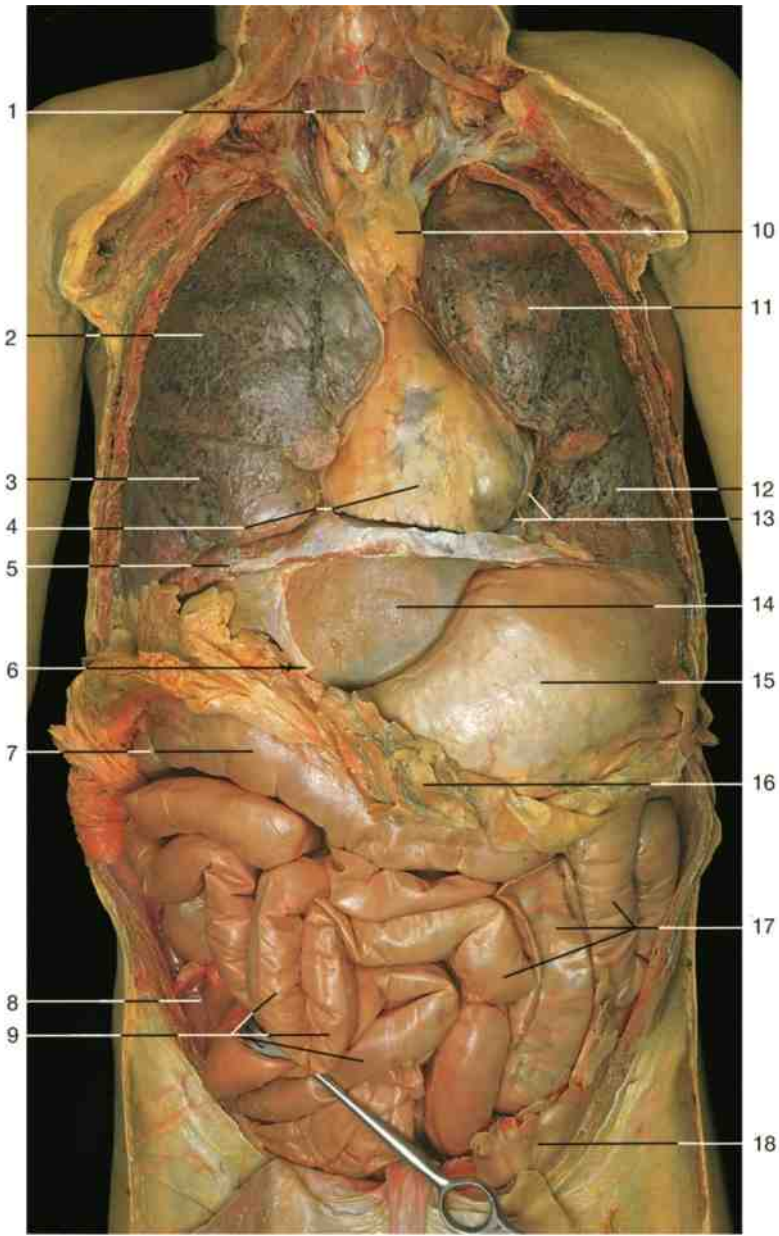
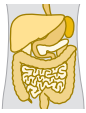The liver, stomach, and superior part of the duodenum are connected to the lesser omentum covering the omental bursa, the entrance of which is the epiploic foramen.

The hepatoduodenal ligament contains the portal vein, the common bile duct, and the hepatic arteries. The spleen is located dorsally underneath the diaphragm.



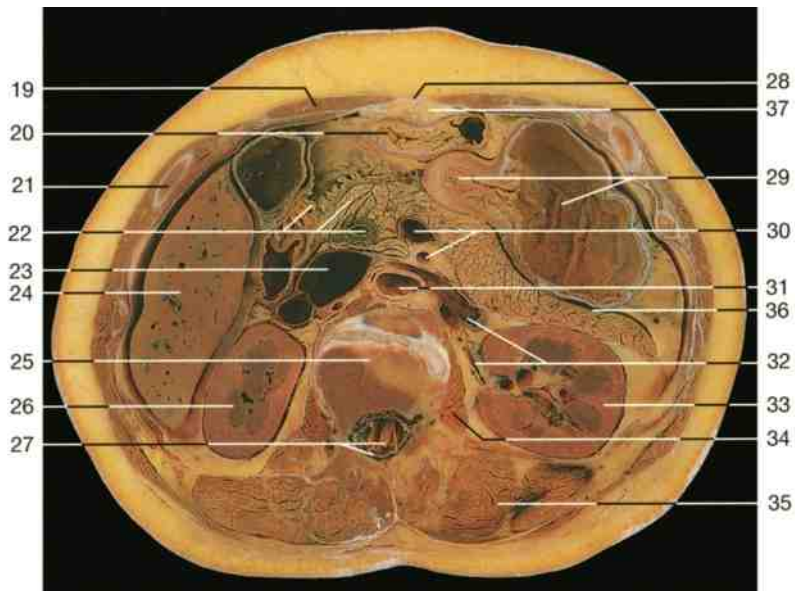
Organization of the digestive system (anterior aspect). Position of the abdominal organs.

- 1 Liver
- 2 Stomach
- 3 Transverse colon
- 4 Small intestine
- 5 Hindgut (cecum) with vermiform appendix
- 6 Esophagus
- 7 Duodenum
- 8 Rectum

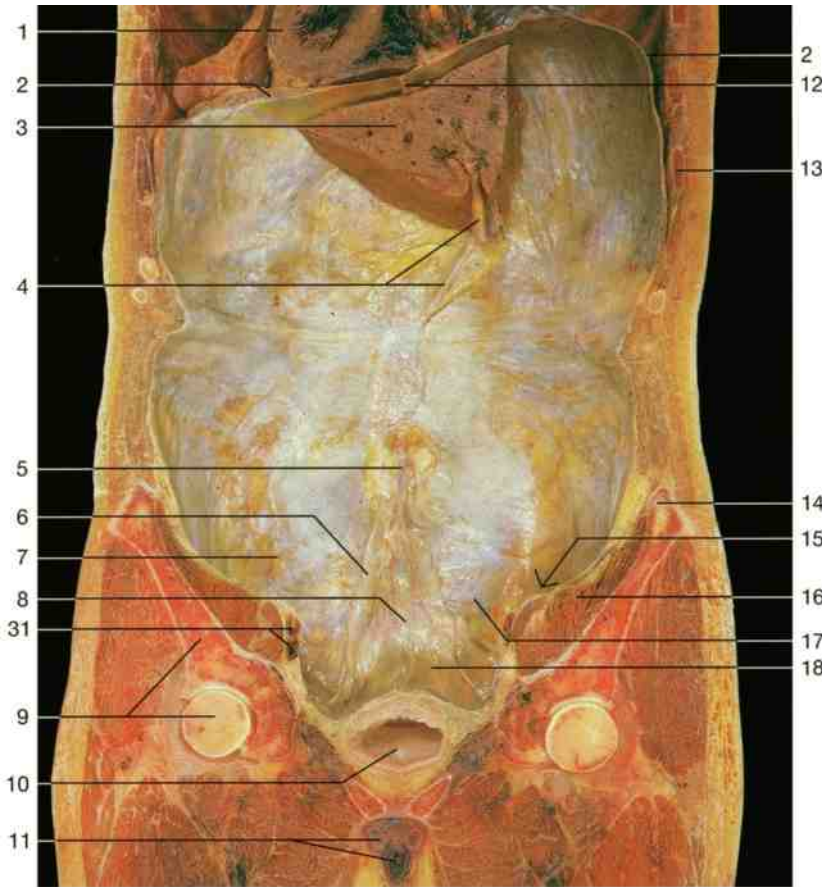
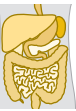

- 1 Thyroid gland
- 2 Upper lobe of right lung
- 3 Middle lobe of right lung
- 4 Heart
- 5 Diaphragm
- 6 Round ligament of liver (ligamentum teres)
- 7 Transverse colon
- 8 Cecum
- 9 Small intestine (ileum)
- 10 Thymus
- 11 Upper lobe of left lung
- 12 Lower lobe of left lung
- 13 Pericardium (cut edge)
- 14 Liver (left lobe)
- 15 Stomach
- 16 Greater omentum
- 17 Small intestine (jejunum)
- 18 Sigmoid colon
- 19 Rectus abdominis muscle
- 20 Small intestine (section)
- 21 Rib
- 22 Common bile duct, duodenum, and pancreas
- 23 Inferior vena cava
- 24 Liver
- 25 Body of second lumbar vertebra
- 26 Right kidney
- 27 Cauda equina and dura mater
- 28 Linea alba
- 29 Stomach and pylorus
- 30 Superior mesenteric artery and vein
- 31 Abdominal aorta
- 32 Left renal artery and vein
- 33 Left kidney
- 34 Psoas major muscle
- 35 Deep muscles of the back
- 36 Pancreas adjacent to lesser sac (omental bursa)
- 37 Falciform ligament with ligamentum teres

Abdominal organs in situ. The greater omentum has been partly removed or reflected.

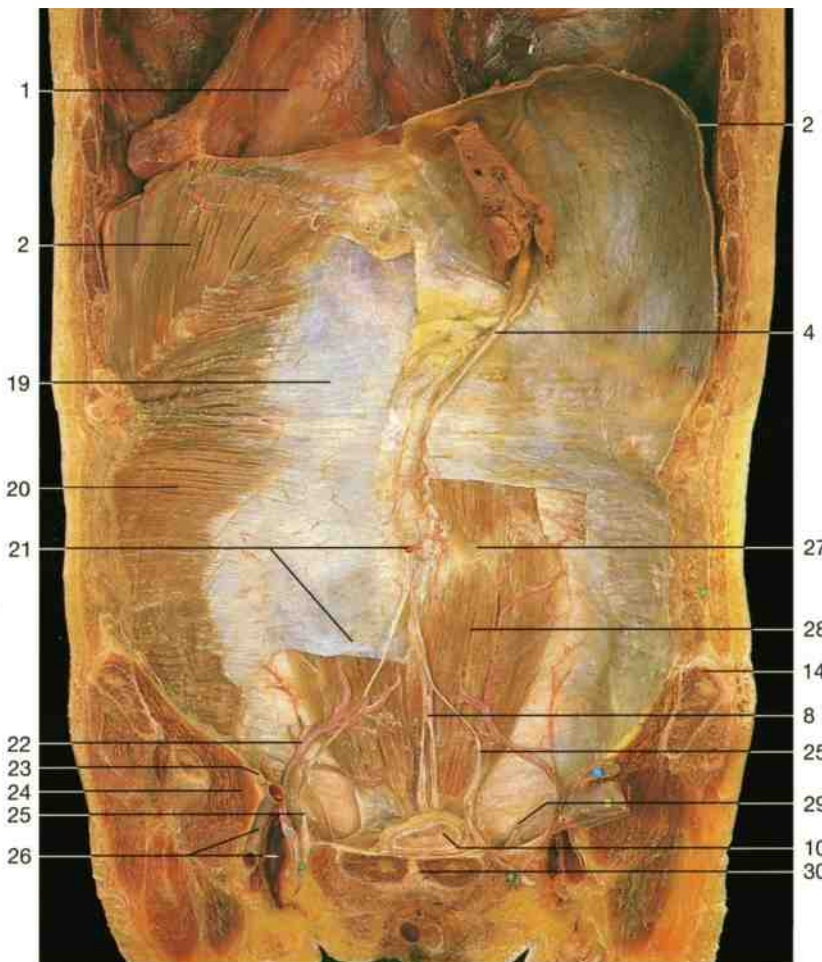

Transverse section through the abdominal cavity at the level of the second lumbar vertebra (from below).

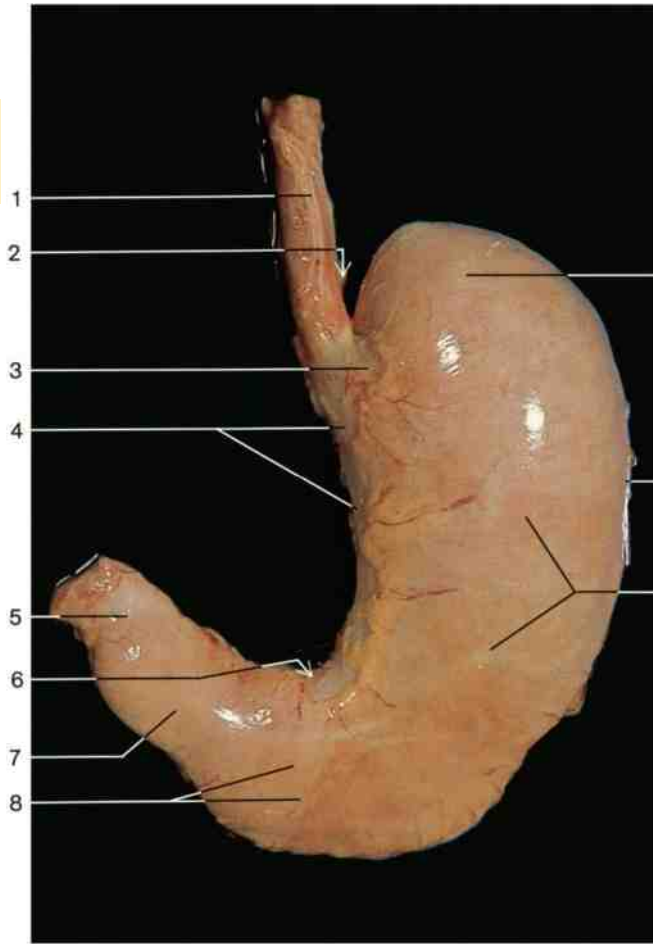


- 1 Left ventricle with pericardium
- 2 Diaphragm
- 3 Remnant of liver
- 4 Ligamentum teres (free margin of falciform ligament)
- 5 Site of umbilicus
- 6 Medial umbilical fold (containing the obliterated umbilical artery)
- 7 Lateral umbilical fold (containing inferior epigastric artery and vein)
- 8 Median umbilical fold (containing remnant of urachus)
- 9 Head of femur and pelvic bone
- 10 Urinary bladder
- 11 Root of penis
- 12 Falciform ligament of liver
- 13 Rib (divided)
- 14 Iliac crest (divided)
- 15 Site of deep inguinal ring and lateral inguinal fossa
- 16 Iliopsoas muscle (divided)
- 17 Medial inguinal fossa
- 18 Supravesical fossa
- 19 Posterior layer of rectus sheath
- 20 Transversus abdominis muscle
- 21 Umbilicus and arcuate line
- 22 Inferior epigastric artery
- 23 Femoral nerve
- 24 Iliopsoas muscle
- 25 Remnant of umbilical artery
- 26 Femoral artery and vein
- 27 Tendinous intersection of rectus abdominis muscle
- 28 Rectus abdominis muscle
- 29 Interfoveolar ligament
- 30 Pubic symphysis (divided)
- 31 External iliac artery and vein

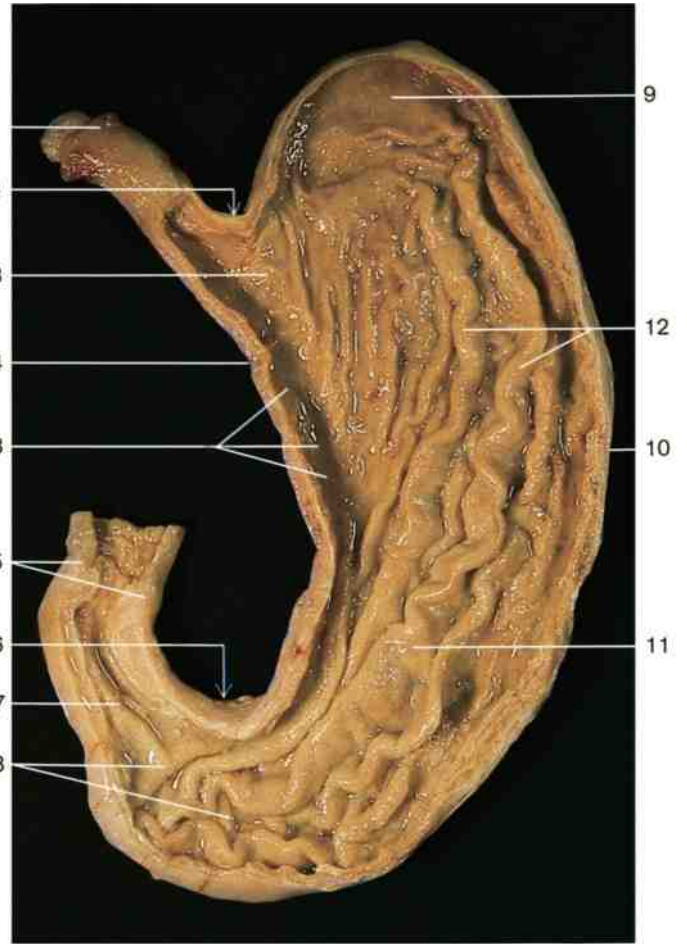
Anterior abdominal wall with pelvic cavity and thigh (frontal section, male) (internal aspect).



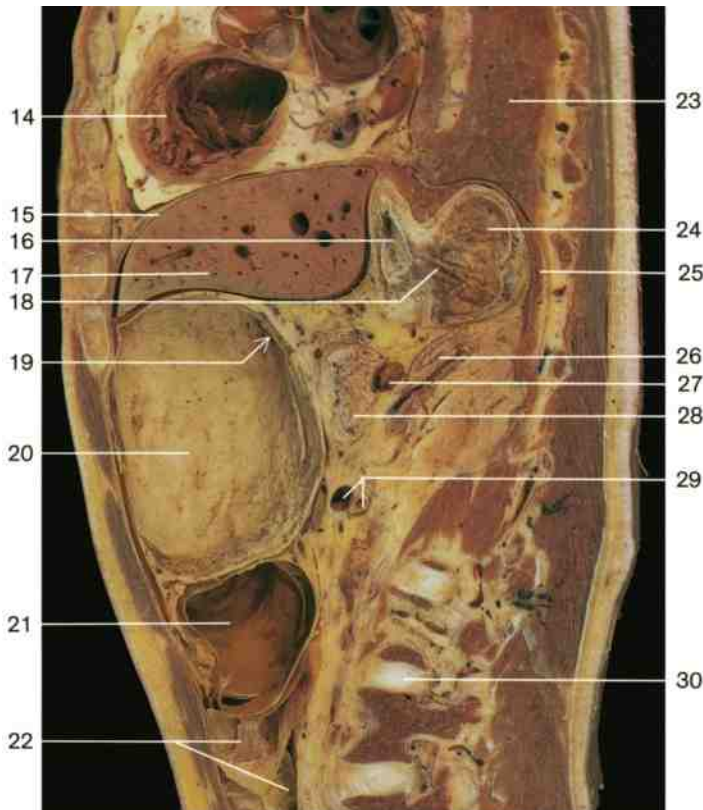
Anterior abdominal wall (male) (internal aspect). The peritoneum and parts of the posterior layer of rectus sheath have been removed. Dissection of inferior epigastric arteries and veins.



Stomach (ventral aspect).

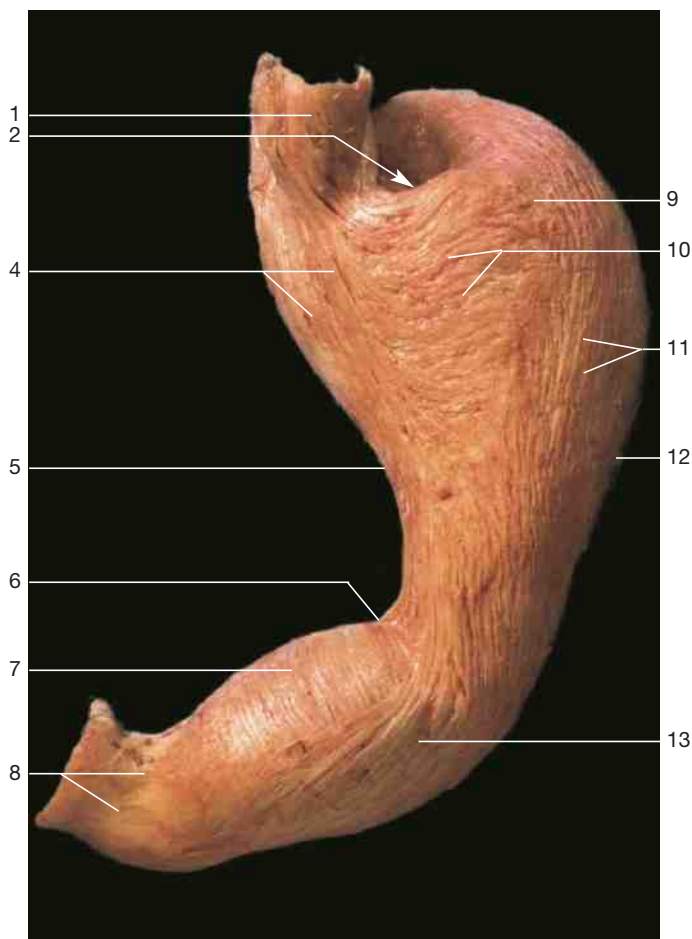
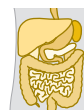

Mucosa of posterior wall of stomach (ventral aspect).

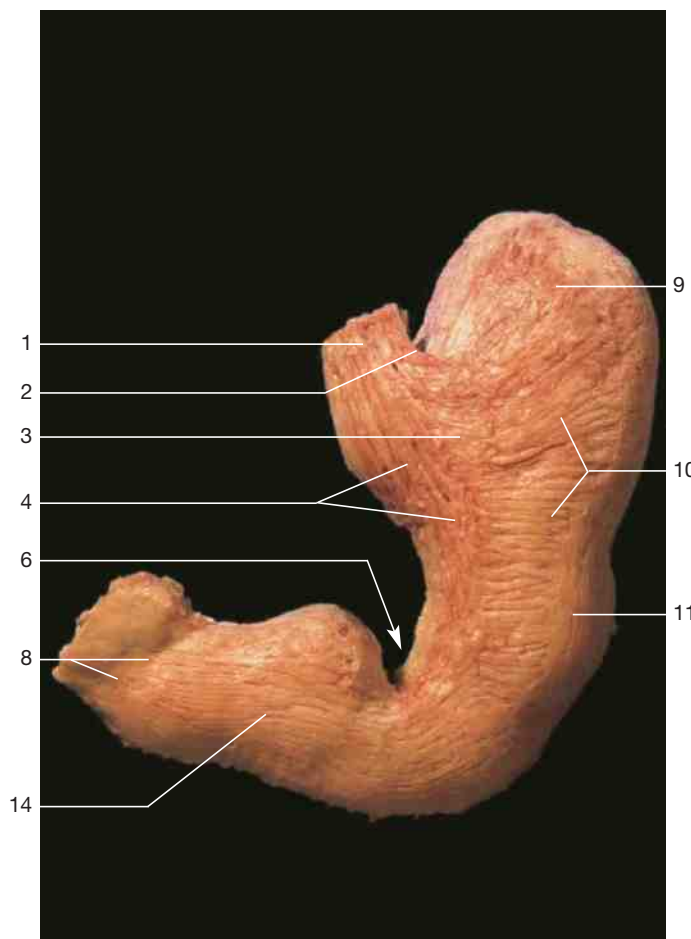


Position of the stomach. Parasagittal section through upper part of left abdominal cavity 3.5 cm lateral to median plane.

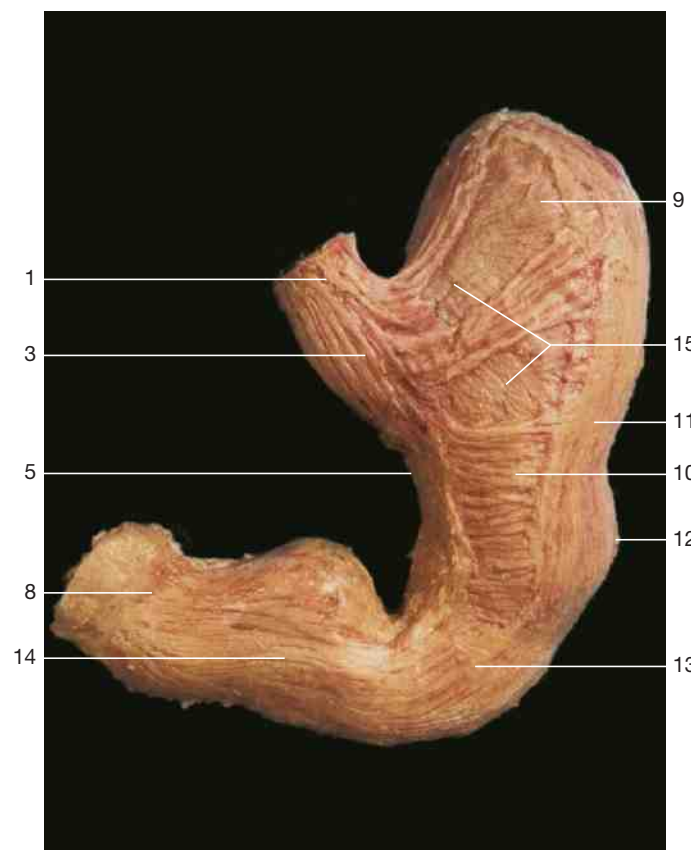
- 1 Esophagus
- 2 Cardial notch
- 3 Cardial part of stomach
- 4 Lesser curvature of stomach
- 5 Pyloric sphincter
- 6 Angular notch (incisura angularis)
- 7 Pyloric canal
- 8 Pyloric antrum
- 9 Fundus of stomach
- 10 Greater curvature of stomach
- 11 Body of stomach
- 12 Folds of mucous membrane (gastric rugae)
- 13 Gastric canal
- 14 Right ventricle of heart
- 15 Diaphragm (cut edge)
- 16 Abdominal portion of esophagus
- 17 Liver
- 18 Cardial part of stomach (cut edge)
- 19 Position of pyloric canal
- 20 Body of stomach
- 21 Transverse colon
- 22 Small intestine
- 23 Lung (cut edge)
- 24 Fundus of stomach (section)
- 25 Lumbar portion of diaphragm (cut edge)
- 26 Suprarenal gland
- 27 Splenic vein
- 28 Pancreas
- 29 Superior mesenteric artery and vein
- 30 Intervertebral disc



Muscular coat of stomach, outer layer (ventral aspect).

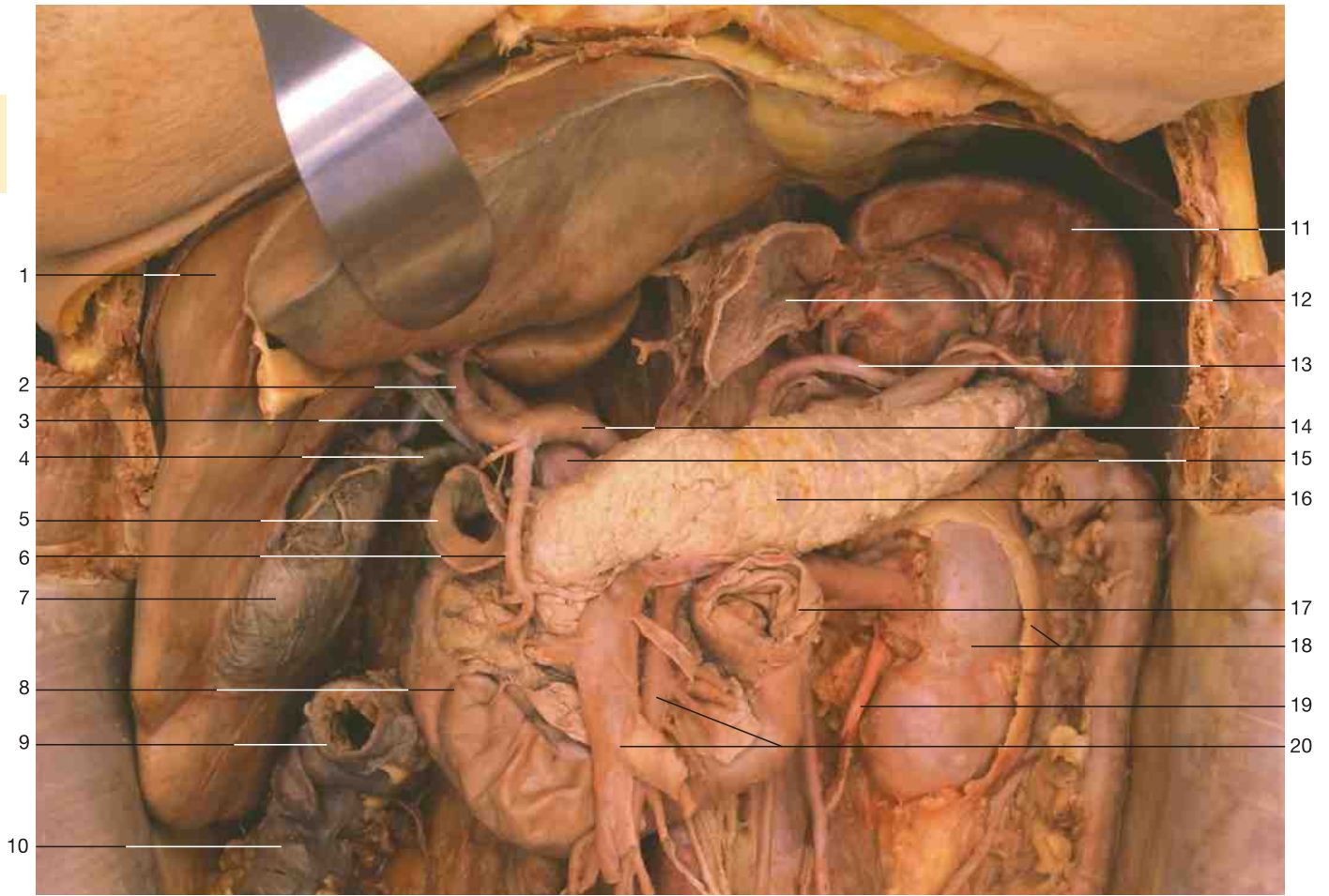
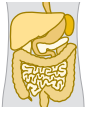

Muscular coat of stomach, middle layer (ventral aspect).

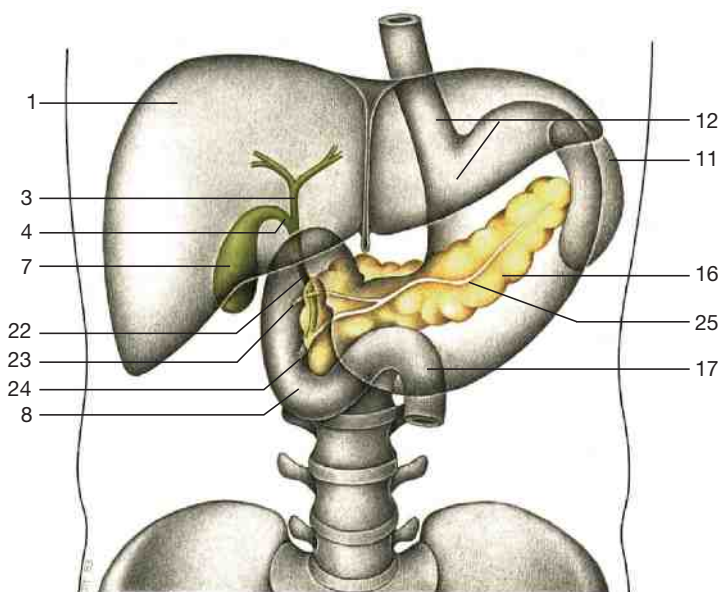


Muscular coat of stomach, inner layer (ventral aspect).

- 1 Esophagus (abdominal part)
- 2 Cardial notch
- 3 Cardial part of stomach
- 4 Longitudinal muscle layer at lesser curvature of stomach
- 5 Lesser curvature
- 6 Incisura angularis
- 7 Circular muscle layer of pyloric part of stomach
- 8 Pyloric sphincter muscle
- 9 Fundus of stomach
- 10 Circular muscle layer of fundus of stomach
- 11 Longitudinal muscle layer of greater curvature of stomach
- 12 Greater curvature of stomach
- 13 Longitudinal muscle layer (transition from body to pyloric part of stomach)
- 14 Pyloric part of stomach
- 15 Oblique muscle fibers

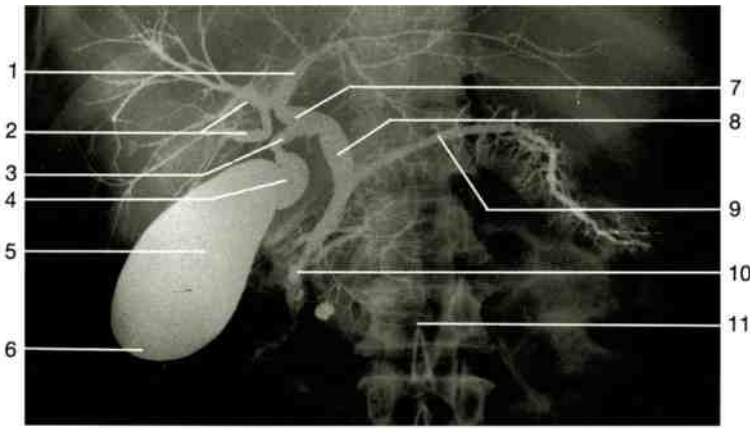
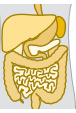

Upper abdominal organs. Pancreas, duodenum, and left kidney are shown. Stomach and transverse colon have been removed, liver elevated; superior mesenteric vein is slightly enlarged.



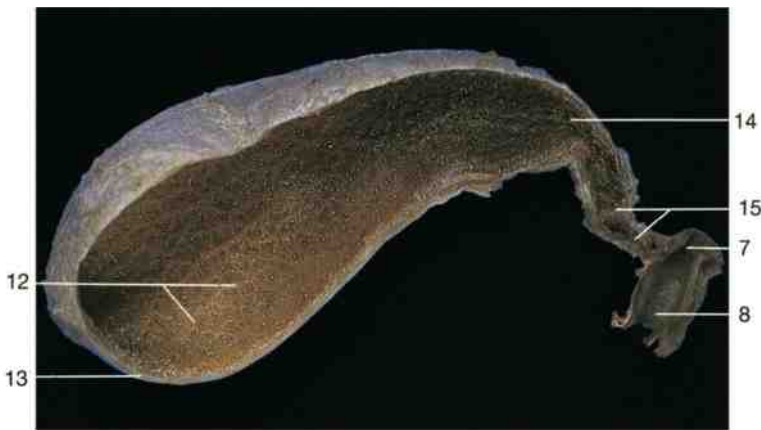
Pancreas, duodenum, and extrahepatic bile ducts (anterior aspect, schematic drawing).

- 1 Liver
- 2 Hepatic artery proper
- 3 Hepatic duct
- 4 Cystic duct
- 5 Pylorus
- 6 Gastroduodenal artery
- 7 Gallbladder
- 8 Duodenum
- 9 Transverse colon (cut)
- 10 Ascending colon
- 11 Spleen
- 12 Cardia
- 13 Splenic artery
- 14 Common hepatic artery
- 15 Portal vein
- 16 Pancreas (body)
- 17 Duodenojejunal flexure
- 18 Kidney (with capsula adiposa)
- 19 Ureter
- 20 Superior mesenteric artery and vein
- 21 Aorta (abdominal part)
- 22 Common bile duct
- 23 Lesser duodenal papilla
- 24 Greater duodenal papilla
- 25 Pancreatic duct




Radiograph of biliary ducts, gallbladder, and pancreatic duct (antero-posterior view).

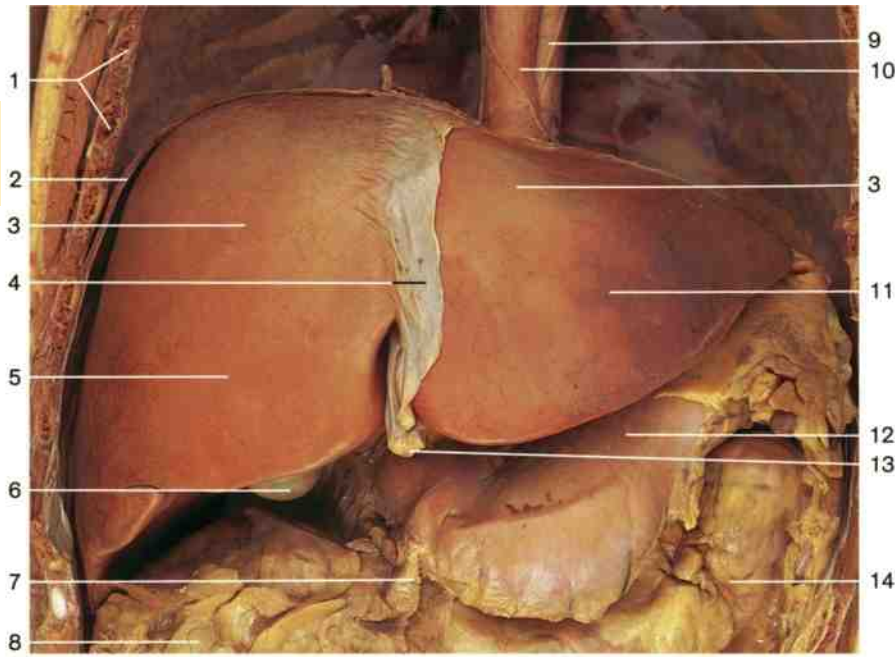
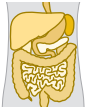- 1 Left hepatic duct
- 2 Right hepatic duct
- 3 Cystic duct
- 4 Neck of gallbladder
- 5 Body of gallbladder
- 6 Fundus of gallbladder
- 7 Common hepatic duct
- 8 Common bile duct
- 9 Pancreatic duct
- 10 Greater duodenal papilla
- 11 Second lumbar vertebra
- 12 Folds of mucous membrane of gallbladder
- 13 Muscular coat of gallbladder
- 14 Neck of gallbladder (opened)
- 15 Cystic duct with spiral fold
- 16 Lesser duodenal papilla
- 17 Accessory pancreatic duct
- 18 Uncinate process
- 19 Plica circularis of duodenum (Kerkring's fold)
- 20 Head of pancreas
- 21 Body of pancreas
- 22 Tail of pancreas
- 23 Descending part of duodenum
- 24 Incisure of pancreas



Isolated gallbladder and cystic duct (anterior aspect).
The gallbladder has been opened to display the mucous membrane.

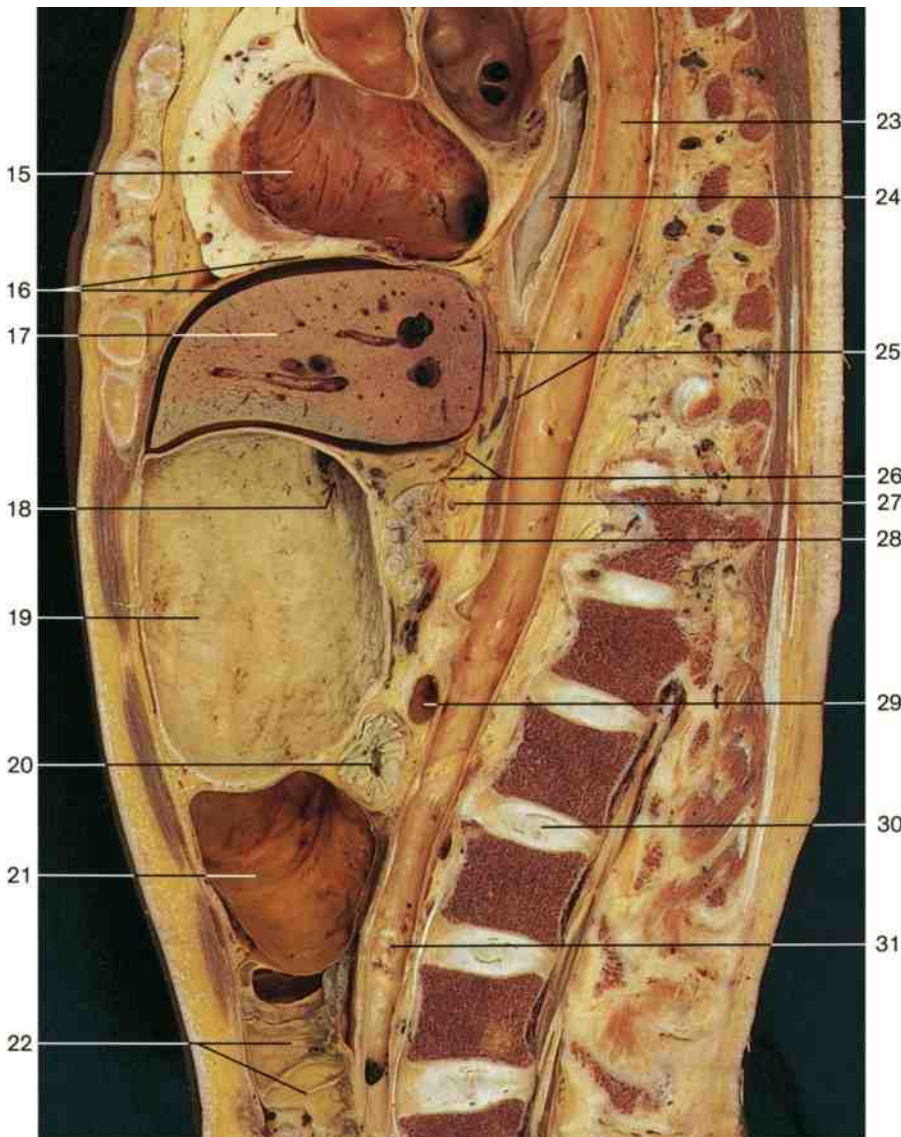


Pancreas with descending part of duodenum (posterior aspect). The duodenum was opened to display the duodenal papillae. Pancreatic duct has been dissected, the common bile duct has been divided. The sphincter of Oddi is shown.

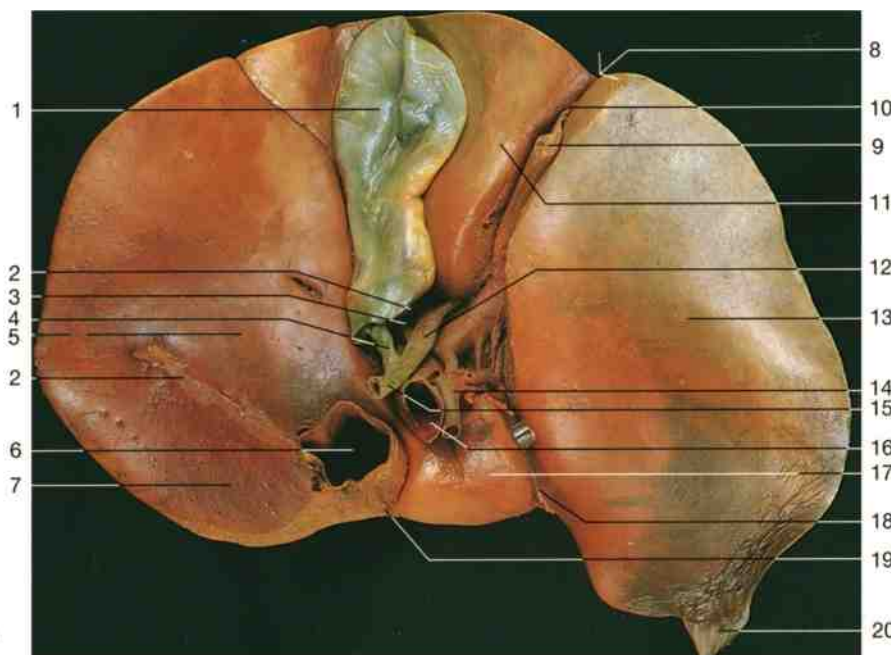


Liver in situ (ventral aspect). Part of the diaphragm has been removed.

- 1 Ribs (cut edges)
- 2 Diaphragm
- 3 Diaphragmatic surface of liver
- 4 Falciform ligament of liver
- 5 Right lobe of liver
- 6 Fundus of gallbladder
- 7 Gastrocolic ligament
- 8 Greater omentum
- 9 Aorta
- 10 Esophagus
- 11 Left lobe of liver
- 12 Stomach
- 13 Ligamentum teres
- 14 Transverse colon
- 15 Right atrium of heart
- 16 Central tendon and sternal portion of diaphragm
- 17 Liver (cut edge)
- 18 Entrance to duodenum (pylorus)
- 19 Stomach
- 20 Duodenum
- 21 Transverse colon (divided, dilated)
- 22 Small intestine
- 23 Thoracic aorta (longitudinally divided)
- 24 Esophagus (longitudinally divided)
- 25 Esophageal hiatus of diaphragm
- 26 Omental bursa (lesser sac)
- 27 Splenic artery
- 28 Pancreas
- 29 Left renal vein
- 30 Intervertebral disc
- 31 Abdominal aorta (longitudinally divided)

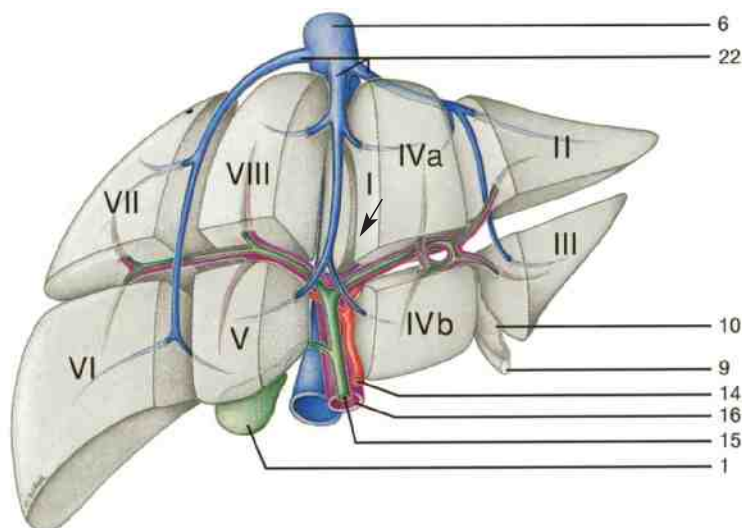


Liver in situ. Parasagittal section through the left side of the abdomen 2 cm lateral to median plane.

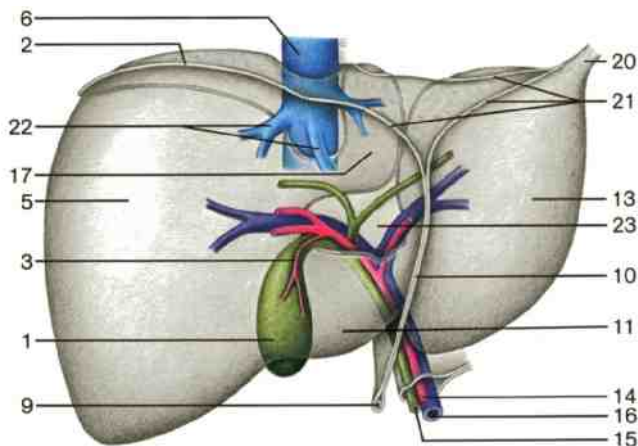


- 1 Fundus of gallbladder
- 2 Peritoneum (cut edges)
- 3 Cystic artery
- 4 Cystic duct
- 5 Right lobe of liver
- 6 Inferior vena cava
- 7 Bare area of liver
- 8 Notch for ligamentum teres and falciform ligament
- 9 Ligamentum teres
- 10 Falciform ligament of liver
- 11 Quadrate lobe of liver
- 12 Common hepatic duct
- 13 Left lobe of liver
- 14 Hepatic artery proper
- 15 Common bile duct
- 16 Portal vein
- 17 Caudate lobe of liver
- 18 Ligamentum venosum
- 19 Ligament of inferior vena cava
- 20 Appendix fibrosa (left triangular ligament)
- 21 Coronary ligament of liver
- 22 Hepatic veins
- 23 Porta hepatis

Liver (inferior aspect). Dissection of porta hepatis. Gallbladder partly collapsed. Ventral margin of liver above.

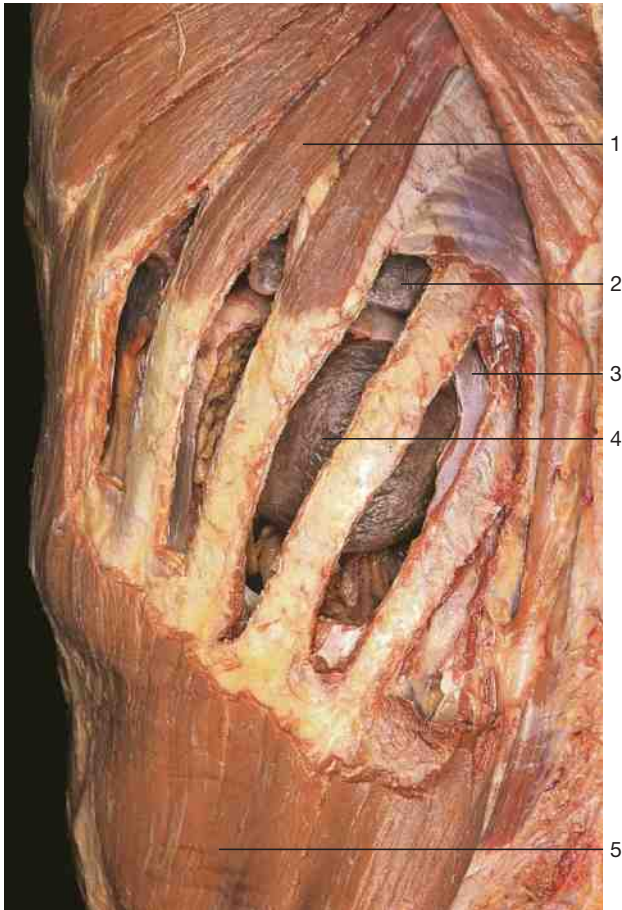


Segmentation of the liver (anterior aspect). Liver segments indicated by Roman numerals.



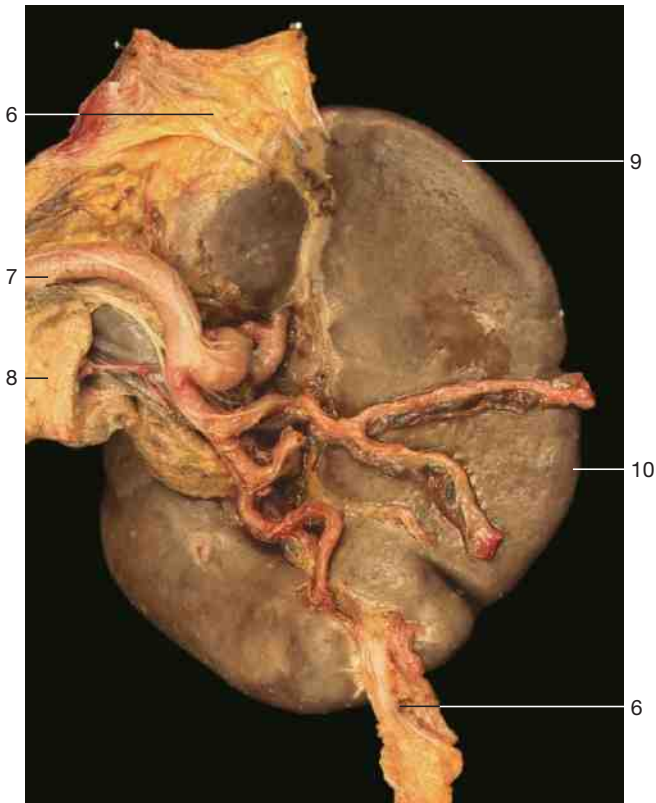
Liver (ventral aspect) (transparent drawing illustrating margins of peritoneal folds).

It should be noted that the anatomical left and right lobes of the liver do not reflect the internal distribution of the hepatic artery, portal vein, and biliary ducts. With these structures, used as criteria, the left lobe includes both the caudate and quadrate lobes, and thus the line dividing the liver into left and right functional lobes passes through the gallbladder and inferior vena cava. The three main hepatic veins drain segments of the liver that have no visible external markings.

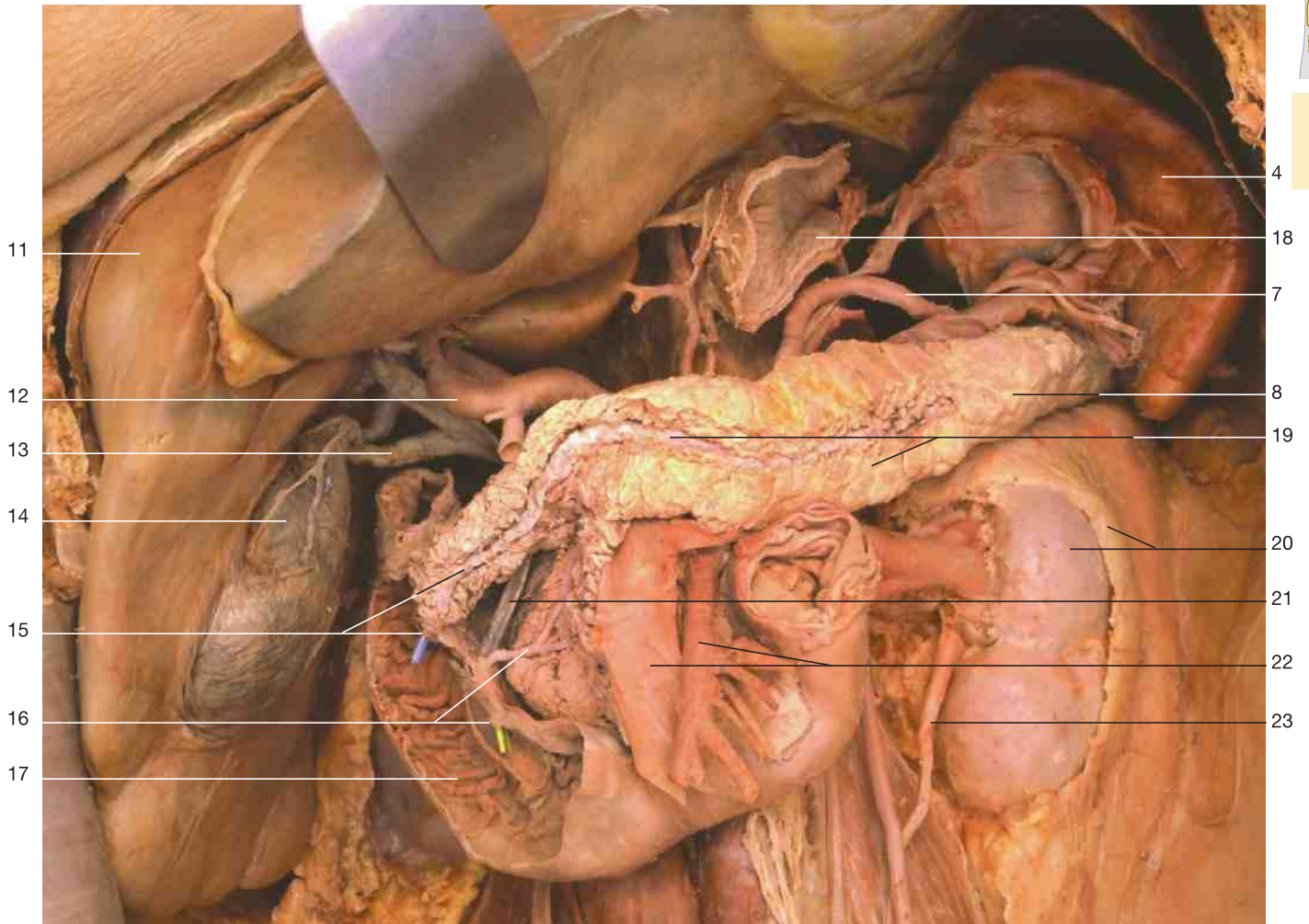


- 1 Serratus anterior muscle
- 2 Left lung
- 3 Diaphragm
- 4 Spleen
- 5 External abdominal oblique muscle
- 6 Gastrosplenic ligament
- 7 Splenic artery
- 8 Pancreas tail
- 9 Superior margin of spleen
- 10 Anterior border of spleen
- 11 Liver
- 12 Hepatic artery proper
- 13 Cystic duct
- 14 Gallbladder
- 15 Lesser duodenal papilla (probe)
- 16 Greater duodenal papilla (probe)
- 17 Duodenum (fenestrated)
- 18 Cardia
- 19 Pancreas and pancreatic duct
- 20 Kidney (with capsula adiposa, capsular fat, adipose tissue)
- 21 Common bile duct
- 22 Superior mesenteric artery and vein
- 23 Ureter
- 24 Aorta with celiac trunk
- 25 Suprarenal gland
- 26 Inferior mesenteric vein

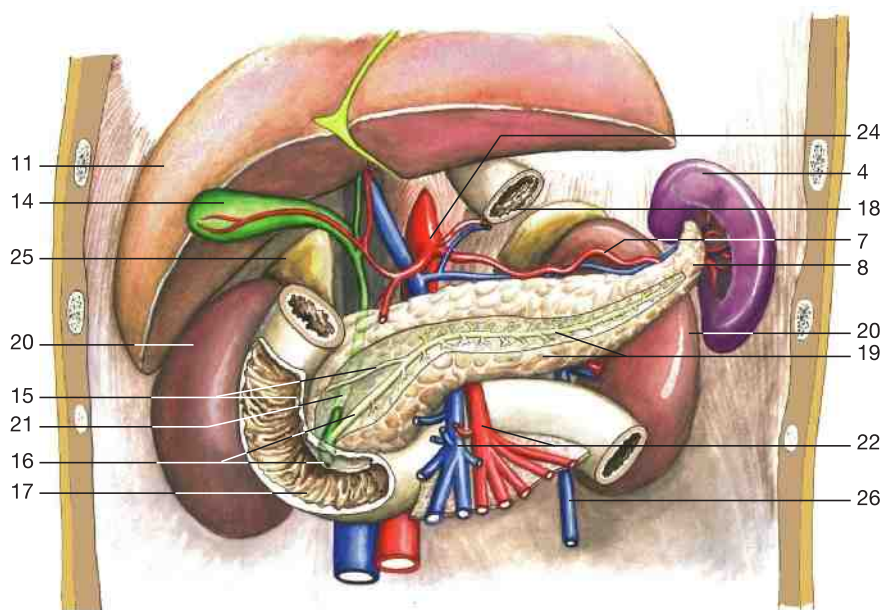
Location of the spleen in situ (left-lateral aspect).
Intercostal spaces and diaphragm have been fenestrated.



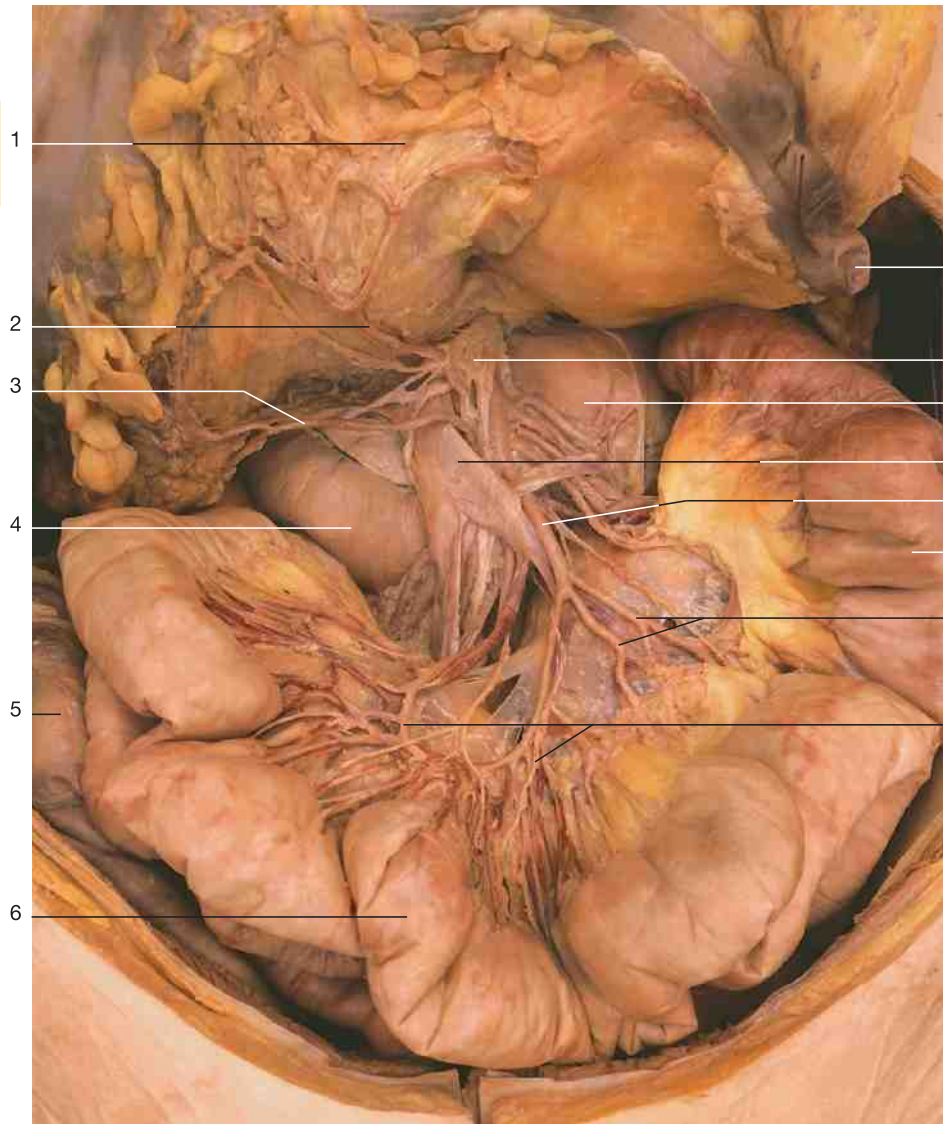
Spleen (visceral surface), hilum of spleen with vessels, nerves, and ligaments.



Upper abdominal organs (anterior aspect). Stomach and transverse colon have been removed, the duodenum fenestrated. The liver has been elevated to show the extrahepatic bile ducts. In this case the accessory pancreatic duct represents the main excretory duct of the pancreas.

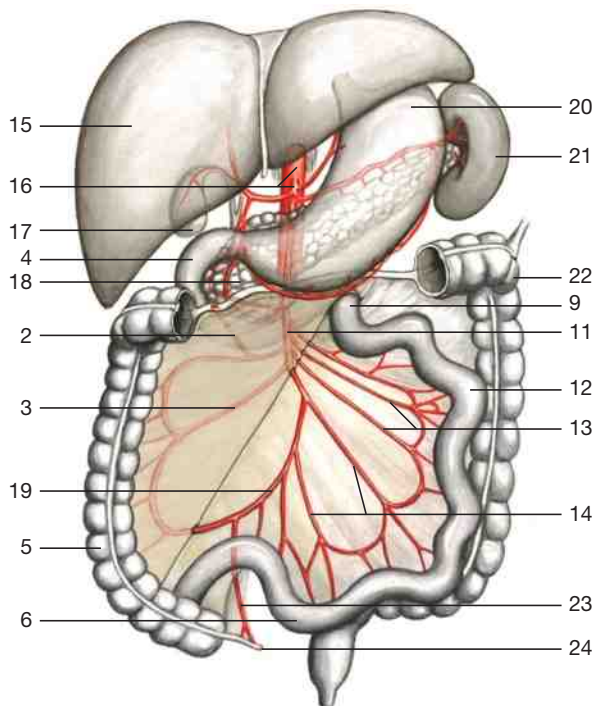


Upper abdominal organs (anterior aspect). The schematic drawing shows the most common situation of the pancreatic ducts.

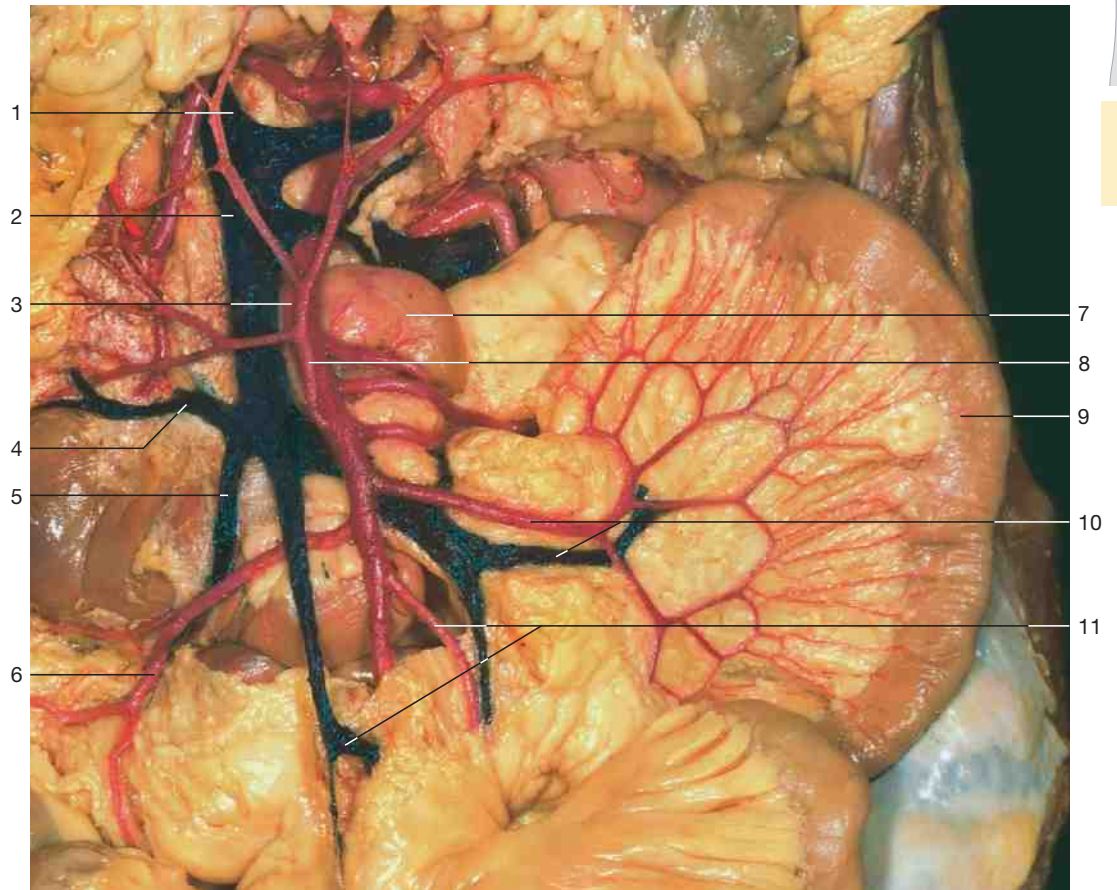


- 1 Greater omentum
- 2 Middle colic artery
- 3 Right colic artery
- 4 Duodenum
- 5 Ascending colon
- 6 Ileum
- 7 Transverse colon
- 8 Celiac ganglion
- 9 Duodenojejunal flexure
- 10 Superior mesenteric vein
- 11 Superior mesenteric artery
- 12 Jejunum
- 13 Jejunal arteries
- 14 Ileal arteries
- 15 Liver
- 16 Celiac trunk and abdominal aorta
- 17 Gallbladder
- 18 Pancreas
- 19 Ileocolic artery
- 20 Stomach
- 21 Spleen
- 22 Left colic flexure
- 23 Appendicular artery
- 24 Vermiform appendix

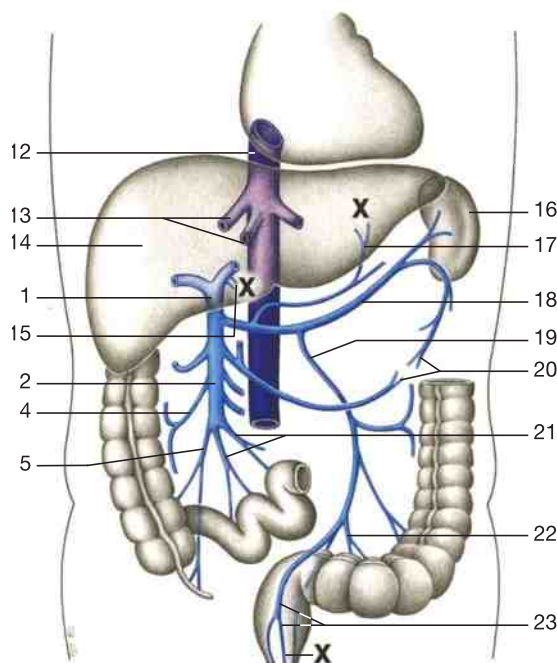
Vessels of abdominal organs, dissection of superior mesenteric artery and vein. Greater omentum and transverse colon are reflected.



Main branches of superior mesenteric artery (schematic drawing).

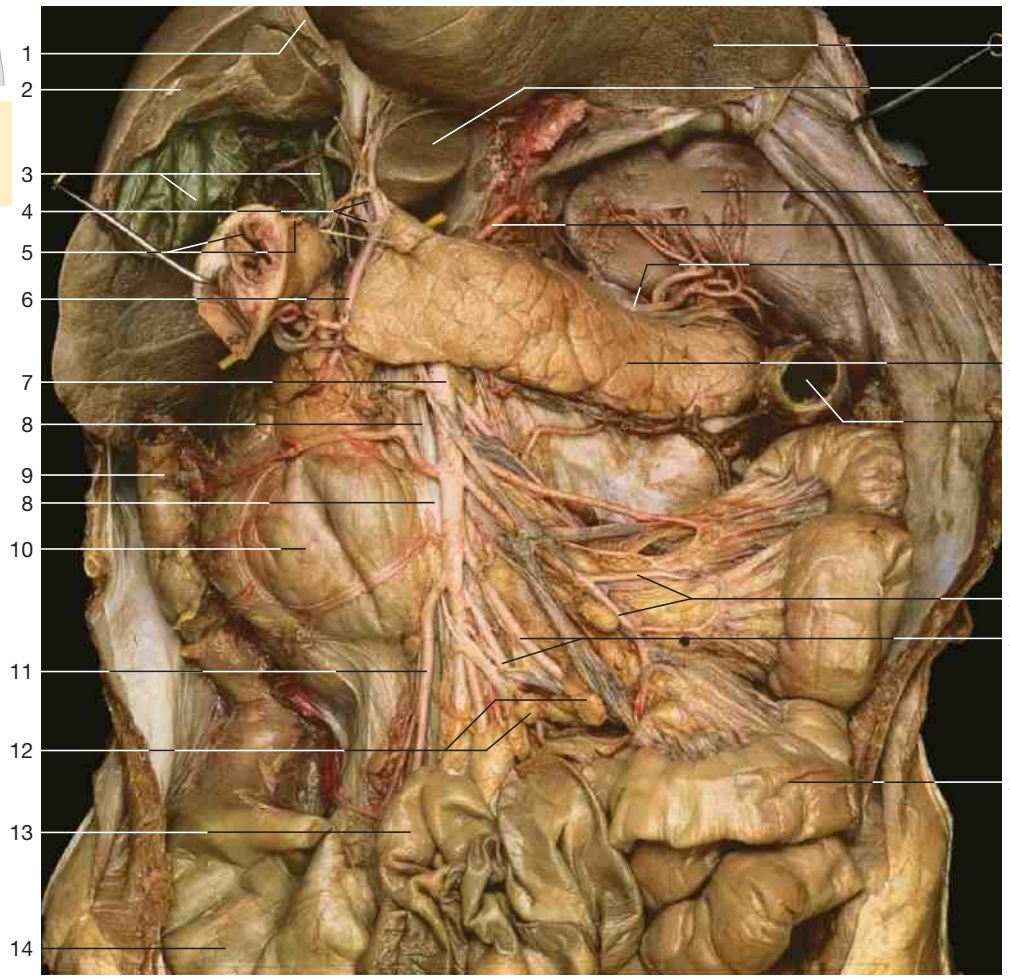
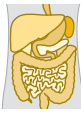

Tributaries of portal vein (blue) and branches of superior mesenteric artery (red) (anterior aspect).



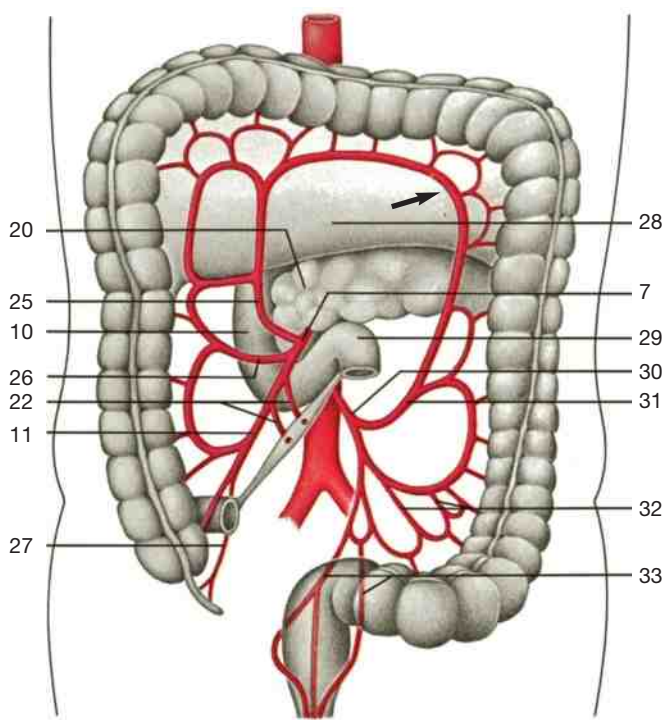
Main tributaries of portal vein (blue).
Inferior vena cava = violet; X = sites of portocaval anastomoses.

- 1 Portal vein
- 2 Superior mesenteric vein
- 3 Superior mesenteric artery
- 4 Right colic vein
- 5 Ileocolic vein
- 6 Ileocolic artery
- 7 Duodenojejunal flexure
- 8 Middle colic artery
- 9 Jejunum
- 10 Jejunal arteries and veins
- 11 Ileal arteries and veins
- 12 Inferior vena cava
- 13 Hepatic veins
- 14 Liver
- 15 Para-umbilical veins (located within the ligamentum teres)
- 16 Spleen
- 17 Left gastric vein with esophageal branches
- 18 Splenic vein
- 19 Inferior mesenteric vein
- 20 Gastro-omental veins
- 21 Ileal veins
- 22 Sigmoid veins
- 23 Superior rectal vein

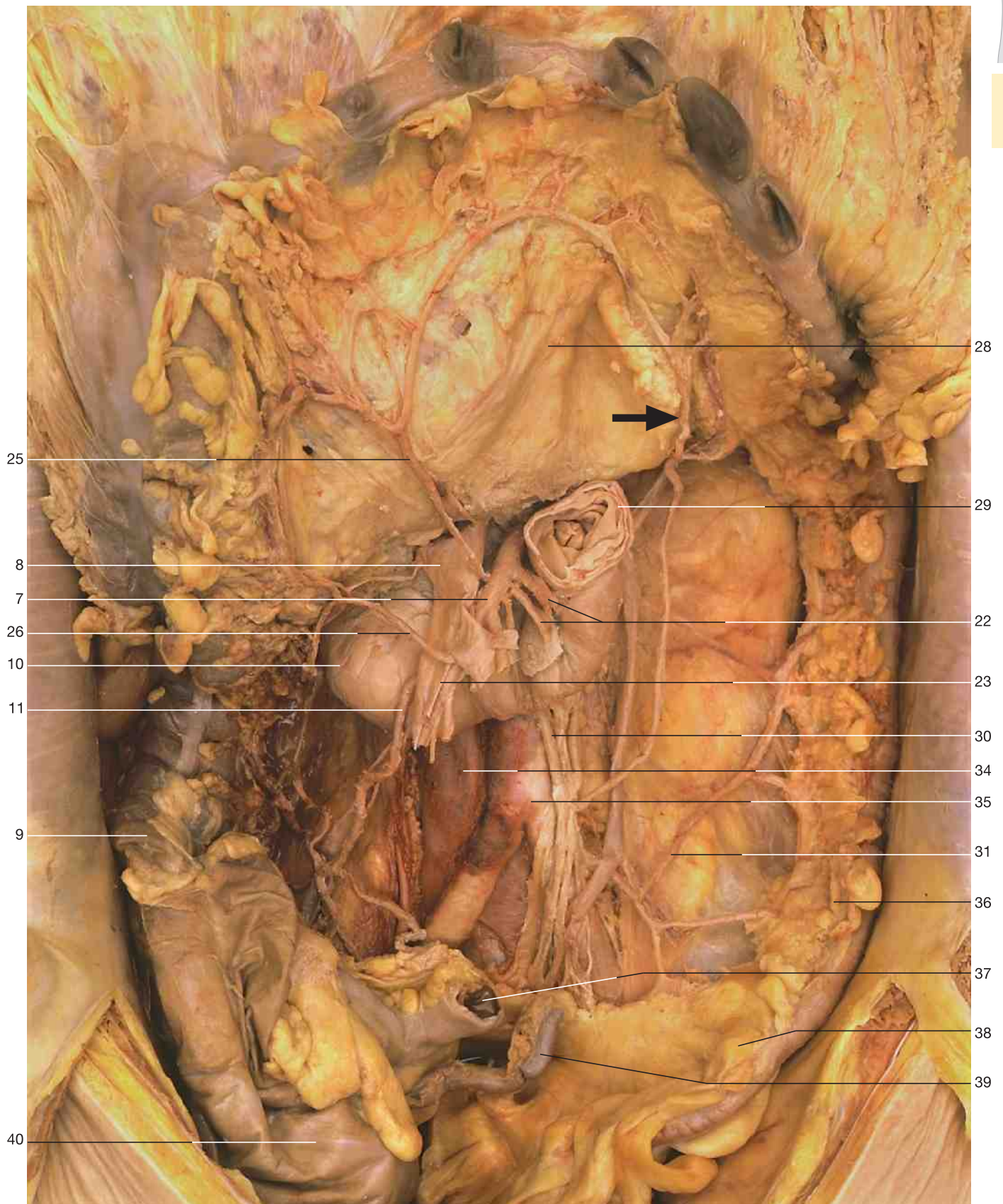


- 1 Ligamentum teres
- 2 Liver
- 3 Gallbladder and common bile duct
- 4 Hepatic artery proper and portal vein
- 5 Right gastric artery and pylorus
- 6 Gastroduodenal artery
- 7 Superior mesenteric artery
- 8 Superior mesenteric vein
- 9 Ascending colon
- 10 Duodenum
- 11 Ileocolic artery
- 12 Lymph nodes
- 13 Ileum
- 14 Cecum
- 15 Left lobe of liver
- 16 Caudate lobe of liver
- 17 Spleen
- 18 Left gastric artery
- 19 Splenic artery
- 20 Pancreas
- 21 Left colic flexure (cut)
- 22 Jejunal arteries
- 23 Ileal arteries
- 24 Jejunum
- 25 Middle colic artery
- 26 Right colic artery
- 27 Appendicular artery
- 28 Transverse mesocolon
- 29 Duodenojejunal flexure
- 30 Inferior mesenteric artery
- 31 Left colic artery
- 32 Sigmoid arteries
- 33 Superior rectal artery
- 34 Inferior vena cava
- 35 Abdominal aorta
- 36 Descending colon
- 37 Ileum
- 38 Sigmoid colon
- 39 Vermiform appendix
- 40 Cecum

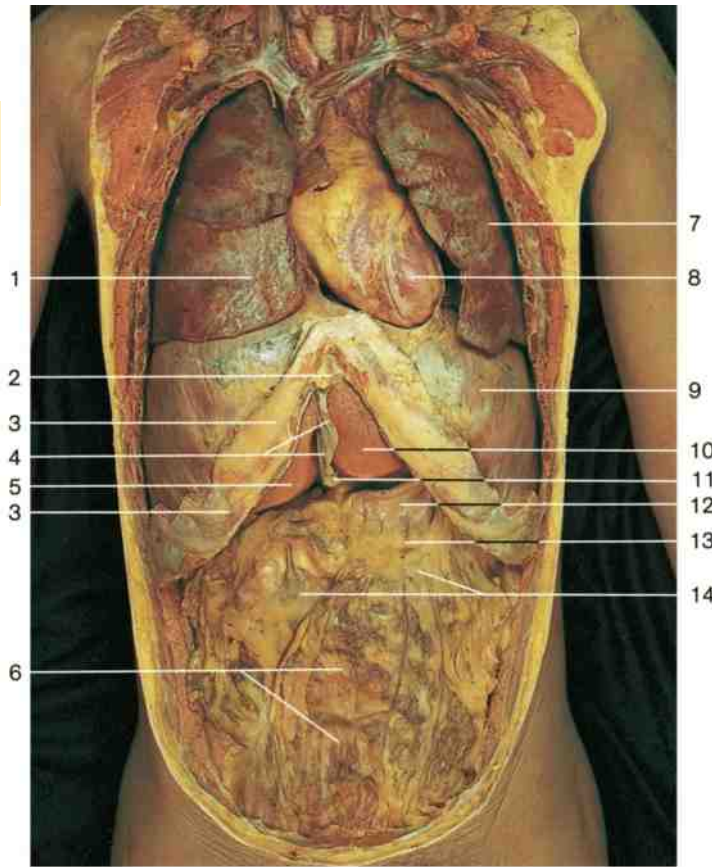
Superior mesenteric artery in relation to pancreas and duodenum. Stomach and transverse colon have been removed and the liver elevated. Note the location of the spleen. A yellow probe is inserted through the omental foramen.



Main branches of superior and inferior mesenteric arteries (schematic drawing). Arrow = Riolan's anastomosis.

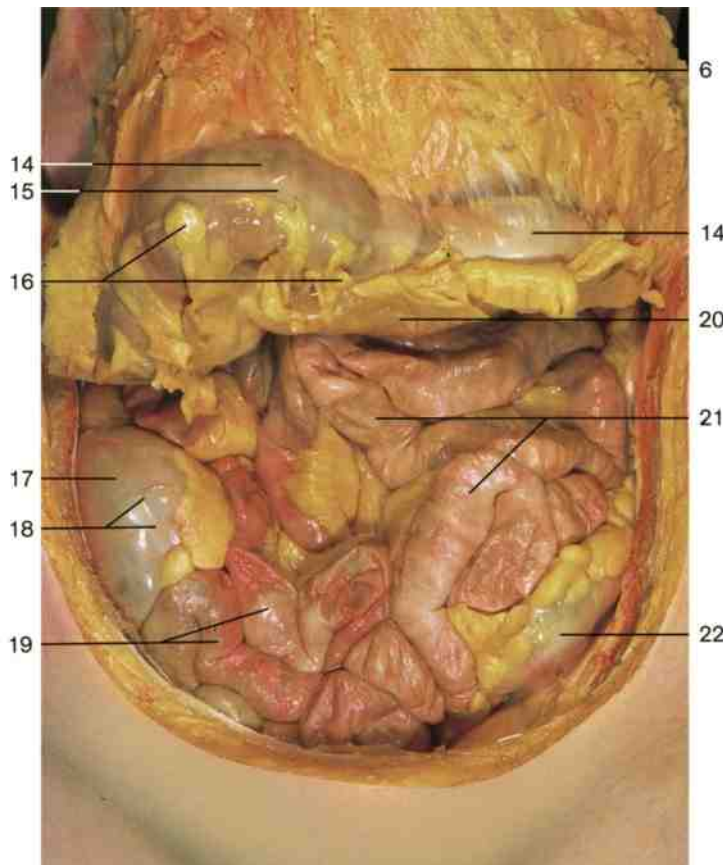


Vessels of the retroperitoneal organs. Direction of the inferior mesenteric artery and its anastomosis with the middle colic artery (arrow = Riolan's anastomosis). Greater omentum and transverse colon have been reflected, the intestine partly removed. The normally retroceally located vermiform appendix has been replaced anteriorly. The right common iliac artery is partly obstructed by a blood thrombus.

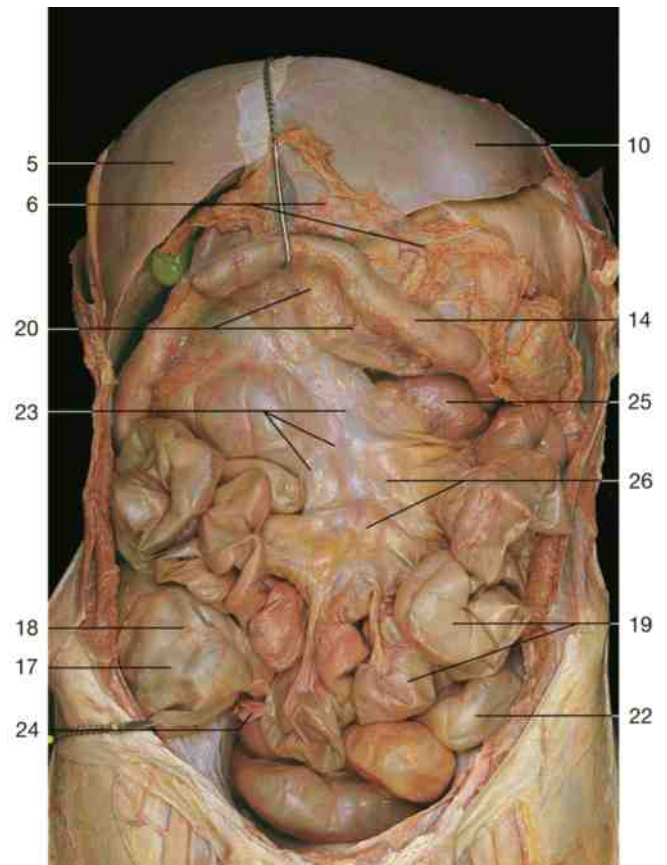


- 1 Middle lobe of right lung
- 2 Xiphoid process
- 3 Costal margin
- 4 Falciform ligament of liver
- 5 Quadrate lobe of liver
- 6 Greater omentum
- 7 Upper lobe of left lung
- 8 Heart
- 9 Diaphragm
- 10 Left lobe of liver
- 11 Ligamentum teres
- 12 Stomach
- 13 Gastrocolic ligament
- 14 Transverse colon
- 15 Taenia coli
- 16 Appendices epiploicae
- 17 Cecum
- 18 Taenia coli
- 19 Ileum
- 20 Transverse mesocolon
- 21 Jejunum
- 22 Sigmoid colon
- 23 Position of root of mesentery
- 24 Vermiform appendix
- 25 Duodenojejunal flexure
- 26 Mesentery

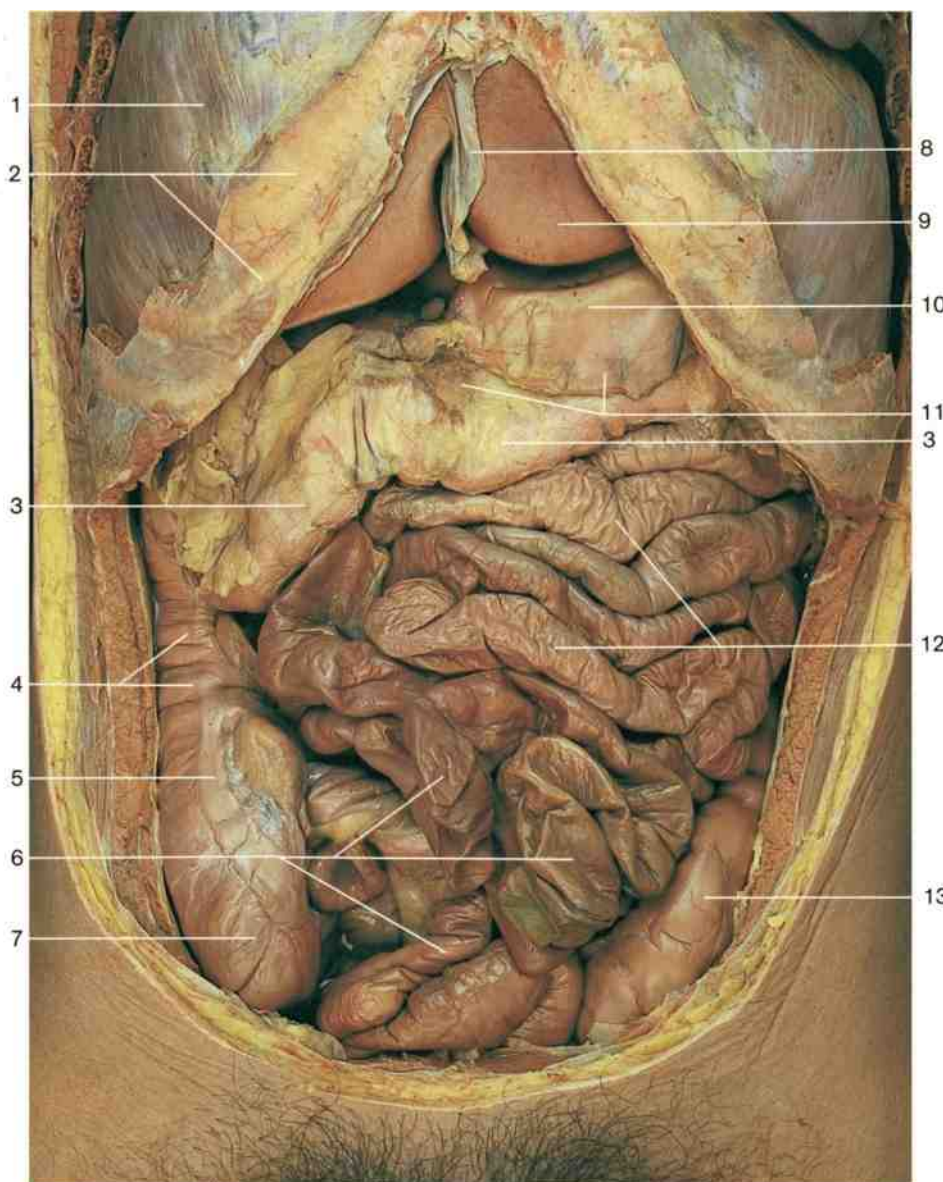
Abdominal organs. The anterior thoracic and abdominal walls have been removed.



Abdominal organs (anterior aspect). The greater omentum, which is fixed to the transverse colon, has been raised.

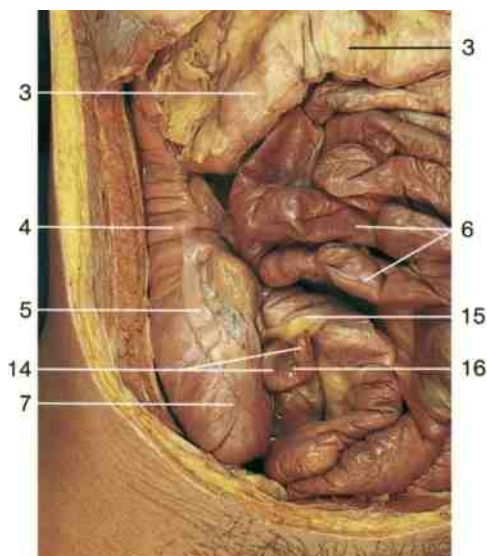


Abdominal organs (anterior aspect). The transverse colon has been reflected.

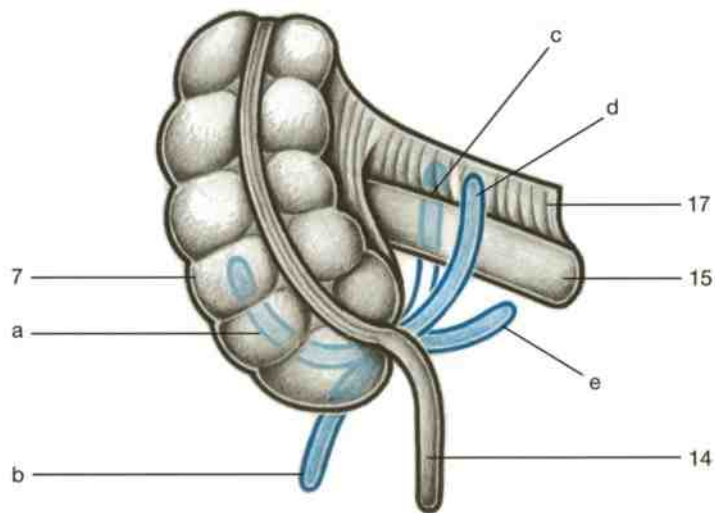


- 1 Diaphragm
- 2 Costal margin
- 3 Transverse colon
- 4 Ascending colon with haustra
- 5 Free taenia of cecum
- 6 Ileum
- 7 Cecum
- 8 Falciform ligament of liver
- 9 Liver
- 10 Stomach
- 11 Gastrocolic ligament
- 12 Jejunum
- 13 Sigmoid colon
- 14 Vermiform appendix
- 15 Terminal ileum
- 16 Meso-appendix
- 17 Mesentery

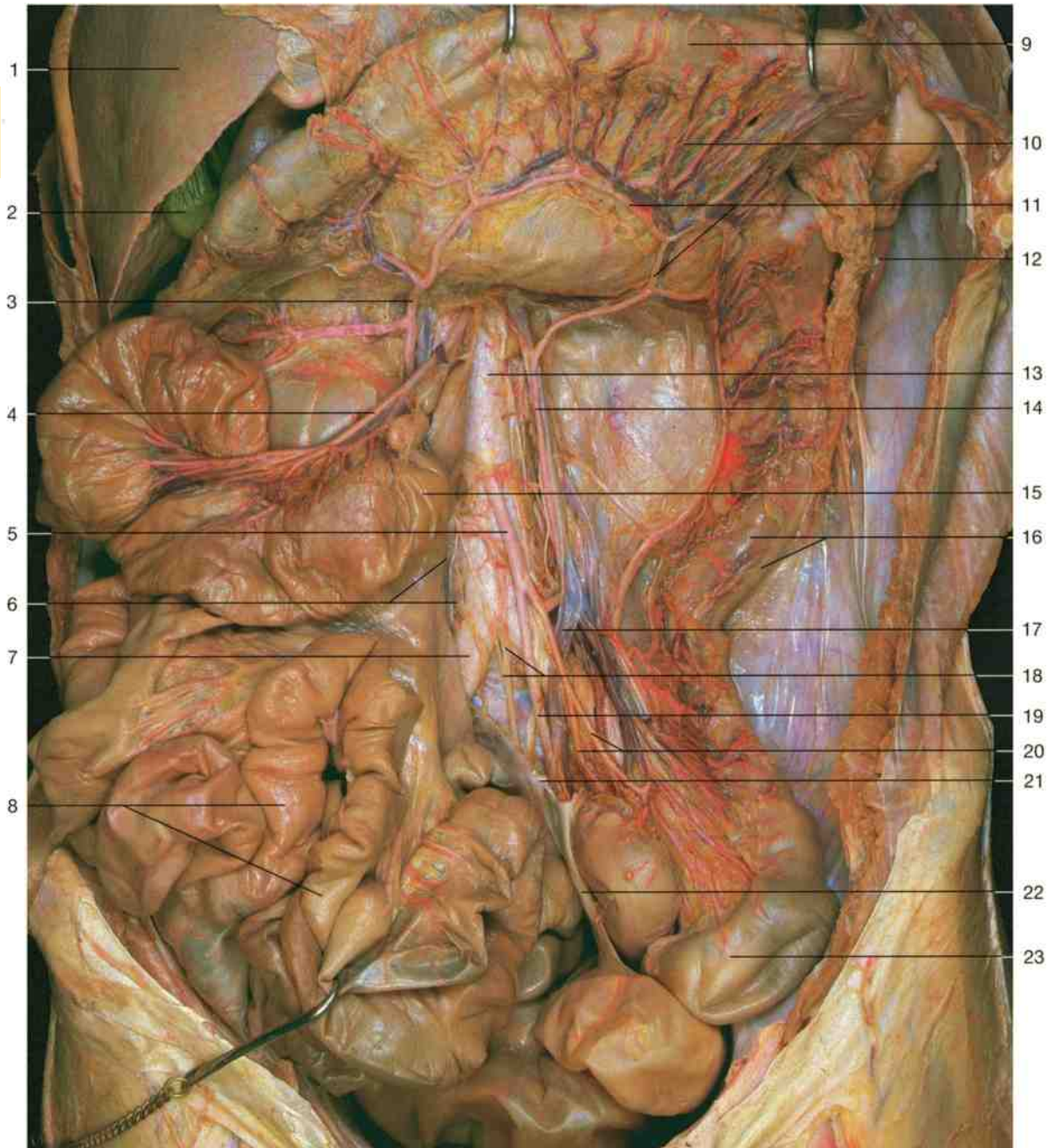Abdominal organs in situ. The greater omentum has been removed.



Ascending colon, cecum, and vermiform appendix (detail of the preceding figure).

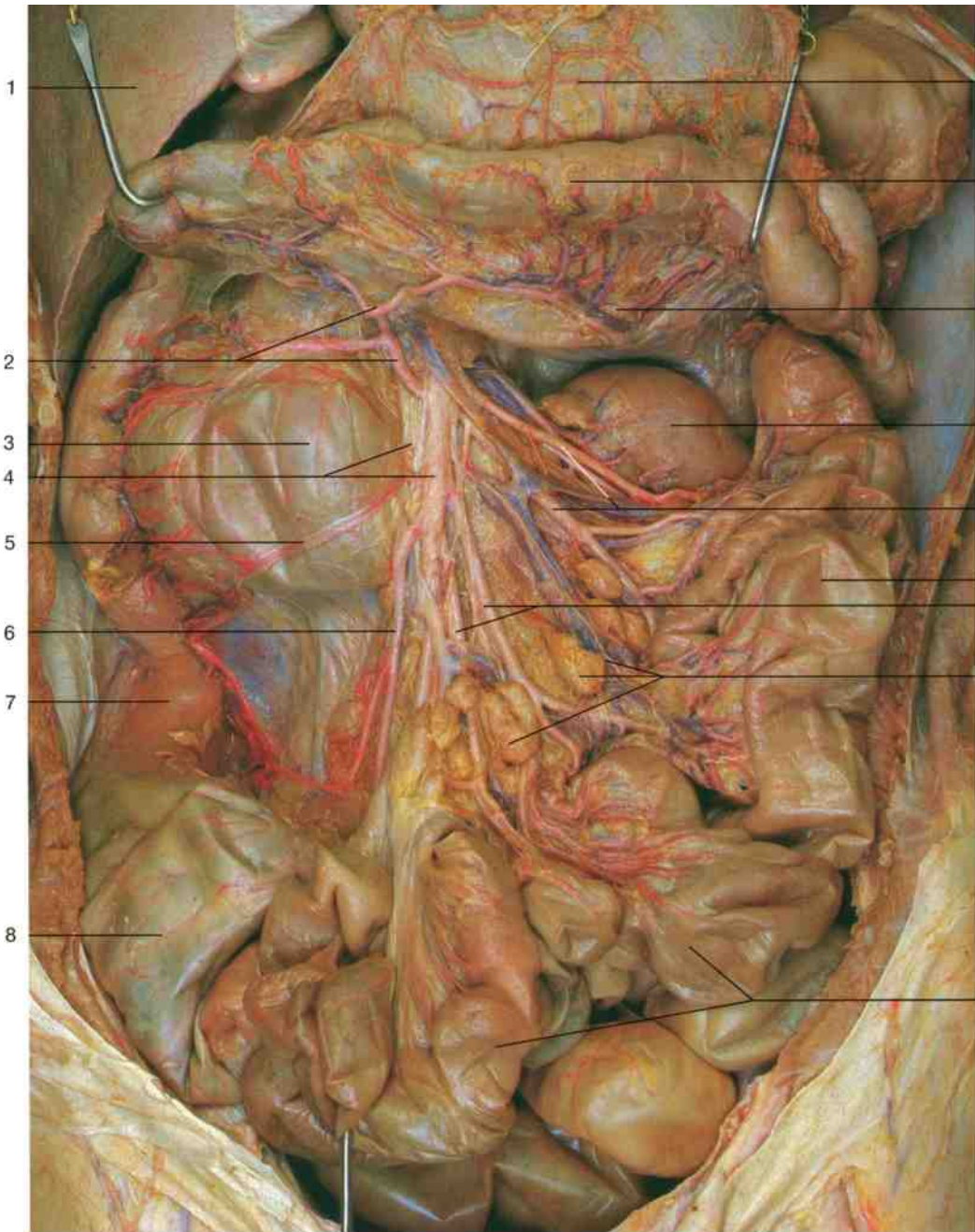


Variations in the position of the vermiform appendix.
 a = retrocecal; b = paracolic; c = retro-ileal; d = pre-ileal;
 e = subcecal.



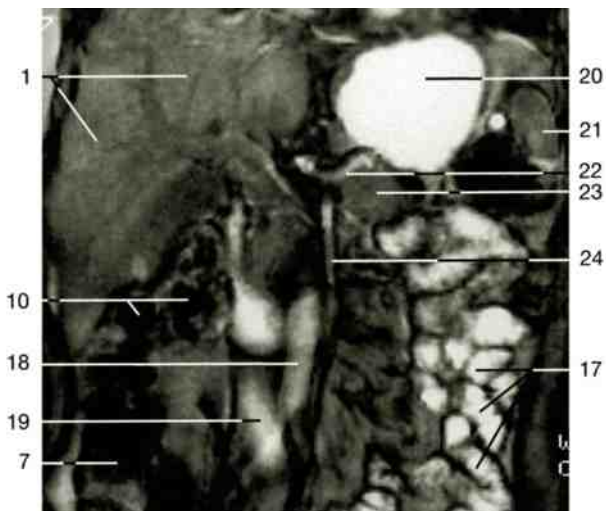
Abdominal organs. Dissection of inferior mesenteric artery and autonomic plexus. The transverse colon with mesocolon has been raised and the small intestine reflected.

- | | |
|---|--|
| 1 Liver | 12 Spleen |
| 2 Gallbladder | 13 Abdominal aorta |
| 3 Middle colic artery | 14 Left colic artery |
| 4 Jejunal artery | 15 Duodenojejunal flexure |
| 5 Inferior mesenteric artery | 16 Descending colon (free taenia of colon) |
| 6 Sympathetic nerves and ganglia | 17 Inferior mesenteric vein |
| 7 Right common iliac artery | 18 Superior hypogastric plexus |
| 8 Small intestine (ileum) | 19 Superior rectal artery |
| 9 Transverse colon (reflected) | 20 Sigmoid arteries |
| 10 Transverse mesocolon | 21 Peritoneum (cut edge) |
| 11 Anastomosis between middle and left colic artery | 22 Sigmoid mesocolon |
| | 23 Sigmoid colon |

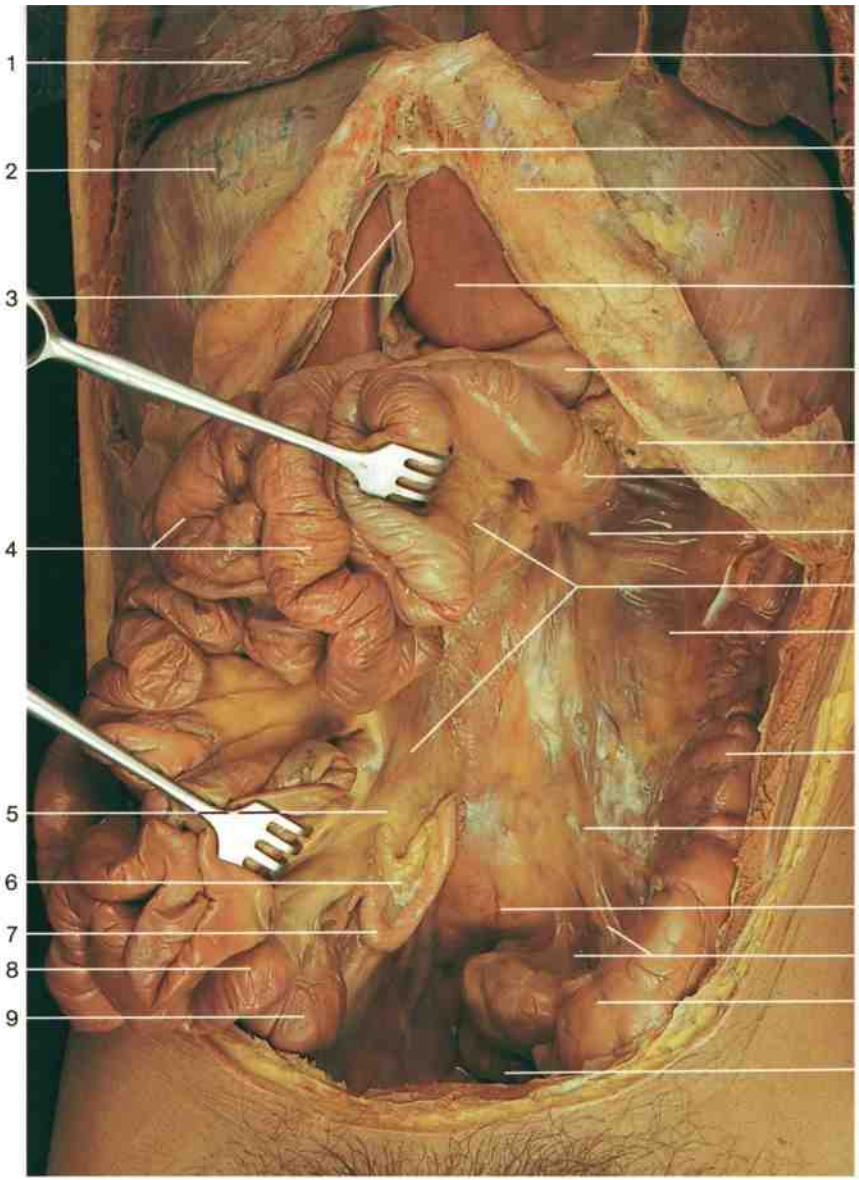


- 1 Liver
- 2 Middle colic artery
- 3 Horizontal part of duodenum (extended)
- 4 Superior mesenteric artery and vein
- 5 Right colic artery
- 6 Ileocolic artery
- 7 Ascending colon
- 8 Cecum
- 9 Greater omentum (reflected)
- 10 Transverse colon
- 11 Transverse mesocolon
- 12 Duodenojejunal flexure
- 13 Jejunal arteries
- 14 Jejunum
- 15 Ileal arteries
- 16 Mesenteric lymph nodes and lymph vessels
- 17 Ileum
- 18 Abdominal aorta
- 19 Inferior vena cava
- 20 Stomach
- 21 Spleen
- 22 Splenic artery
- 23 Head of pancreas
- 24 Superior mesenteric artery

Abdominal organs. Superior mesenteric artery. Mesenteric lymph nodes. Transverse colon reflected.

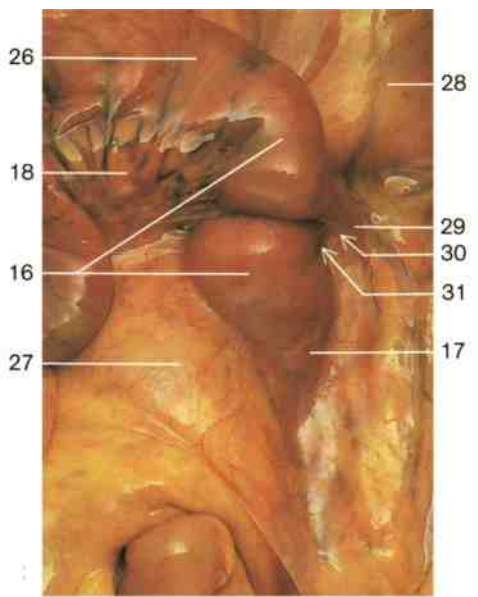


Frontal section through the abdominal cavity (MRI scan; the intestinal tract and vessels are filled with a paramagnetic substance [Gadolinium]; courtesy of Dr. W. Rödl, Erlangen, Germany).

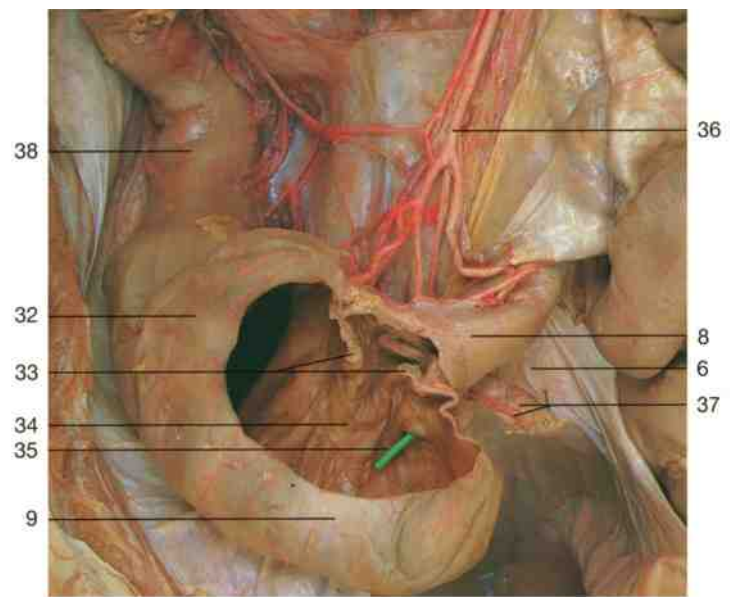


- 1 Lung
- 2 Diaphragm
- 3 Falciform ligament of liver
- 4 Jejunum
- 5 Ileoceleal fold
- 6 Meso-appendix
- 7 Vermiform appendix
- 8 Ileoceleal junction
- 9 Cecum
- 10 Pericardial sac
- 11 Xiphoid process
- 12 Costal margin
- 13 Liver
- 14 Stomach
- 15 Transverse colon
- 16 Duodenojejunal flexure
- 17 Inferior duodenal fold
- 18 Mesentery
- 19 Position of left kidney
- 20 Descending colon
- 21 Position of left common iliac artery
- 22 Sacral promontory
- 23 Sigmoid mesocolon
- 24 Sigmoid colon
- 25 Rectum
- 26 Beginning of jejunum
- 27 Peritoneum of posterior abdominal wall
- 28 Transverse mesocolon
- 29 Superior duodenal fold
- 30 Superior duodenal recess
- 31 Retroduodenal recess
- 32 Free taenia of ascending colon
- 33 Ileoceleal valve
- 34 Frenulum of ileocecal valve
- 35 Orifice of vermiform appendix (probe)
- 36 Ileocolic artery
- 37 Vermiform appendix with appendicular artery
- 38 Ascending colon

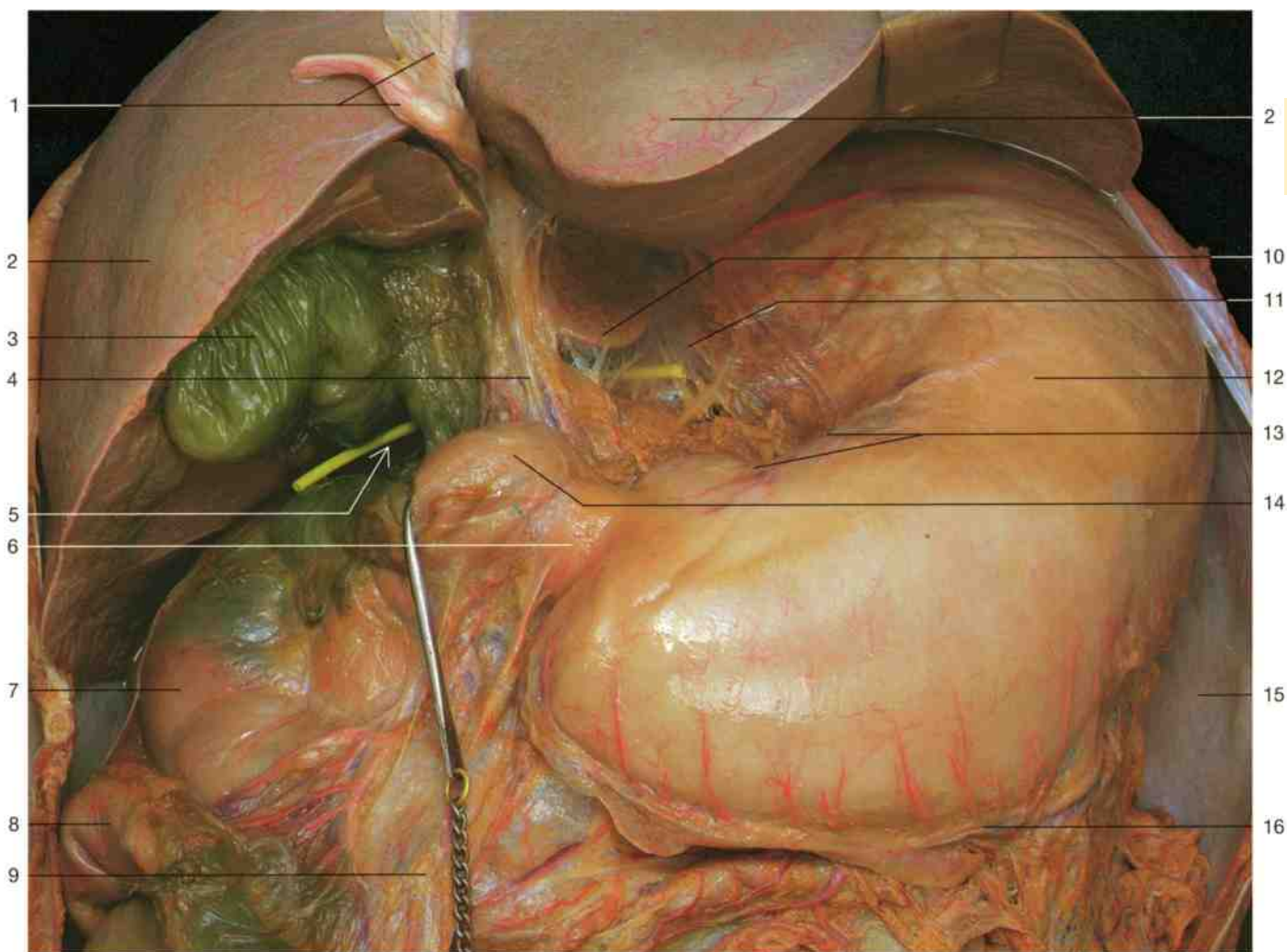
Abdominal cavity. Mesenteries. The small intestine has been reflected laterally to demonstrate the mesentery.



Duodenojejunal flexure (enlargement of preceding figure).

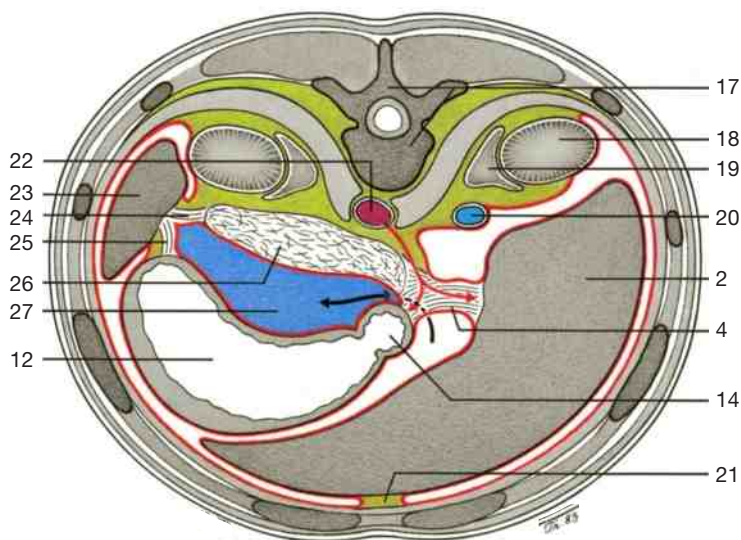


Ileocecal valve (ventral aspect). The cecum and terminal part of the ileum have been opened.

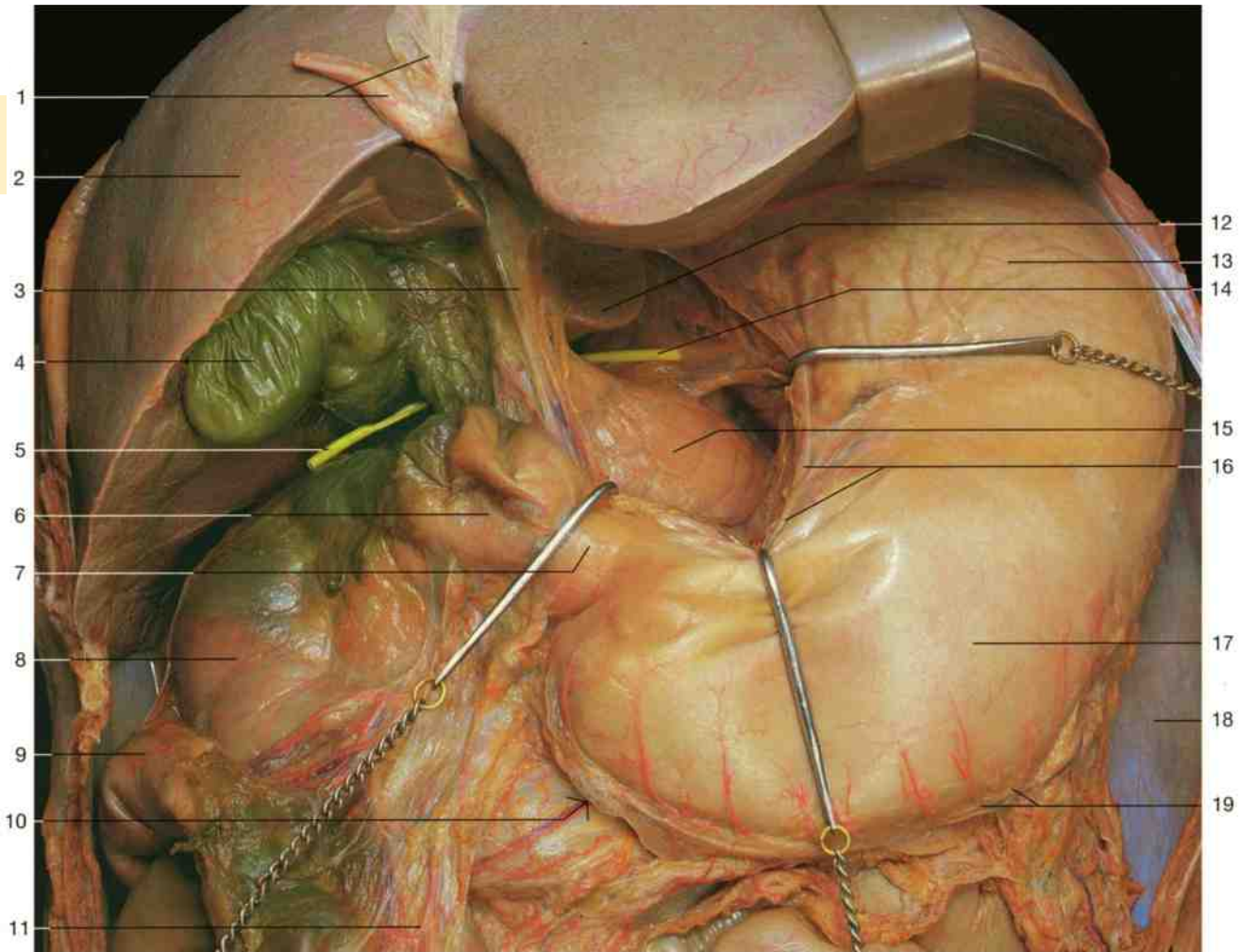


Upper abdominal organs (anterior aspect). Thorax and anterior part of diaphragm have been removed and the liver raised to display the lesser omentum. A probe has been inserted into the epiploic foramen and lesser sac.

- 1 Falciform ligament and ligamentum teres
- 2 Liver
- 3 Gallbladder (fundus)
- 4 Hepatoduodenal ligament
- 5 Epiploic foramen (probe)
- 6 Pylorus
- 7 Descending part of duodenum
- 8 Right colic flexure
- 9 Gastrocolic ligament
- 10 Caudate lobe of liver (behind lesser omentum)
- 11 Lesser omentum
- 12 Stomach
- 13 Lesser curvature of stomach
- 14 Superior part of duodenum
- 15 Diaphragm
- 16 Greater curvature of stomach with gastro-omental vessels
- 17 Twelfth thoracic vertebra
- 18 Right kidney
- 19 Right suprarenal gland
- 20 Inferior vena cava
- 21 Falciform ligament of liver
- 22 Abdominal aorta
- 23 Spleen
- 24 Lienorenal ligament
- 25 Gastrosplenic ligament
- 26 Pancreas
- 27 Lesser sac (omental bursa)

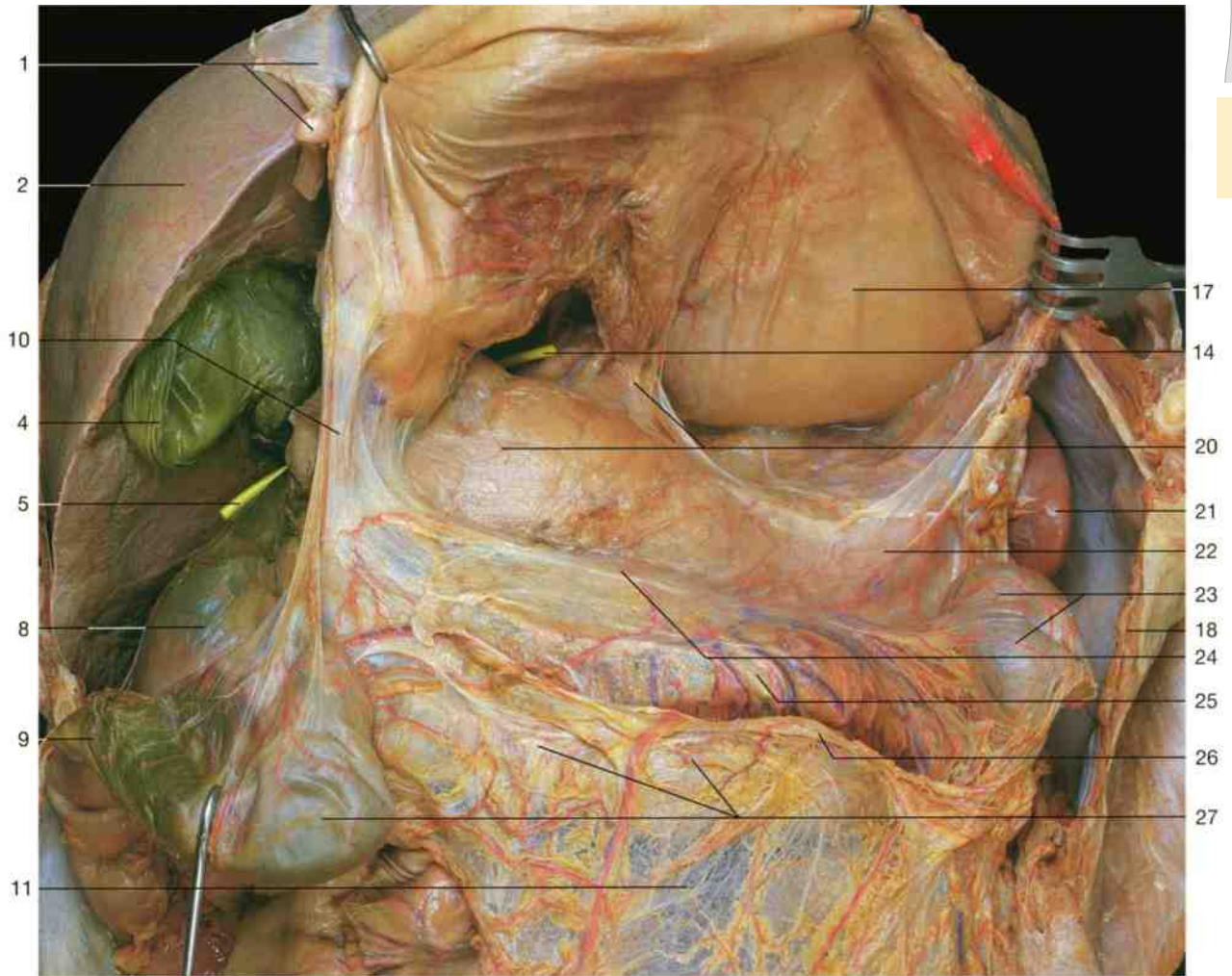
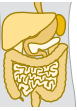

Horizontal section through the lesser sac above the level of epiploic foramen (black arrow). Viewed from above. Red arrows: routes of the arterial branches of celiac trunk to liver, stomach, duodenum, and pancreas (posterior aspect).

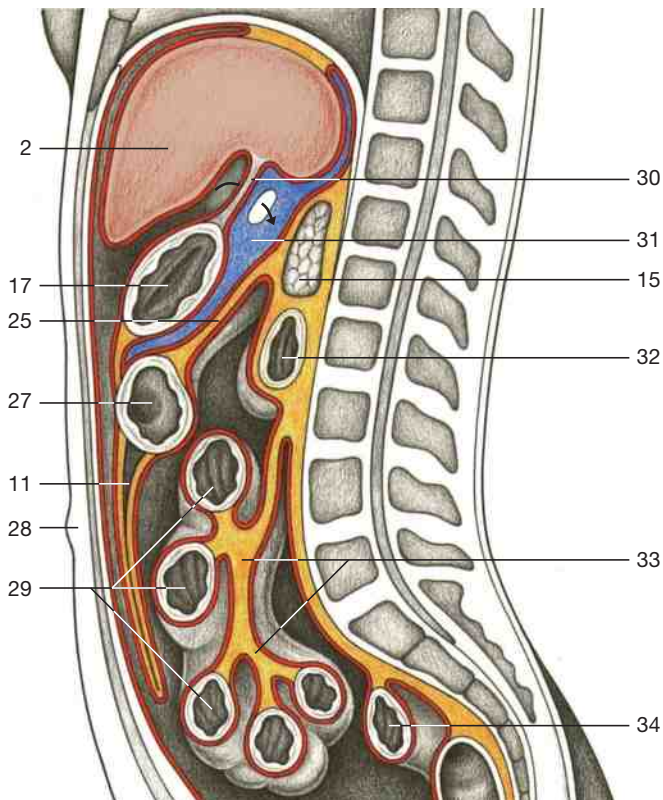


Upper abdominal organs (anterior aspect). Lesser sac. Lesser omentum partly removed, liver and stomach slightly reflected.

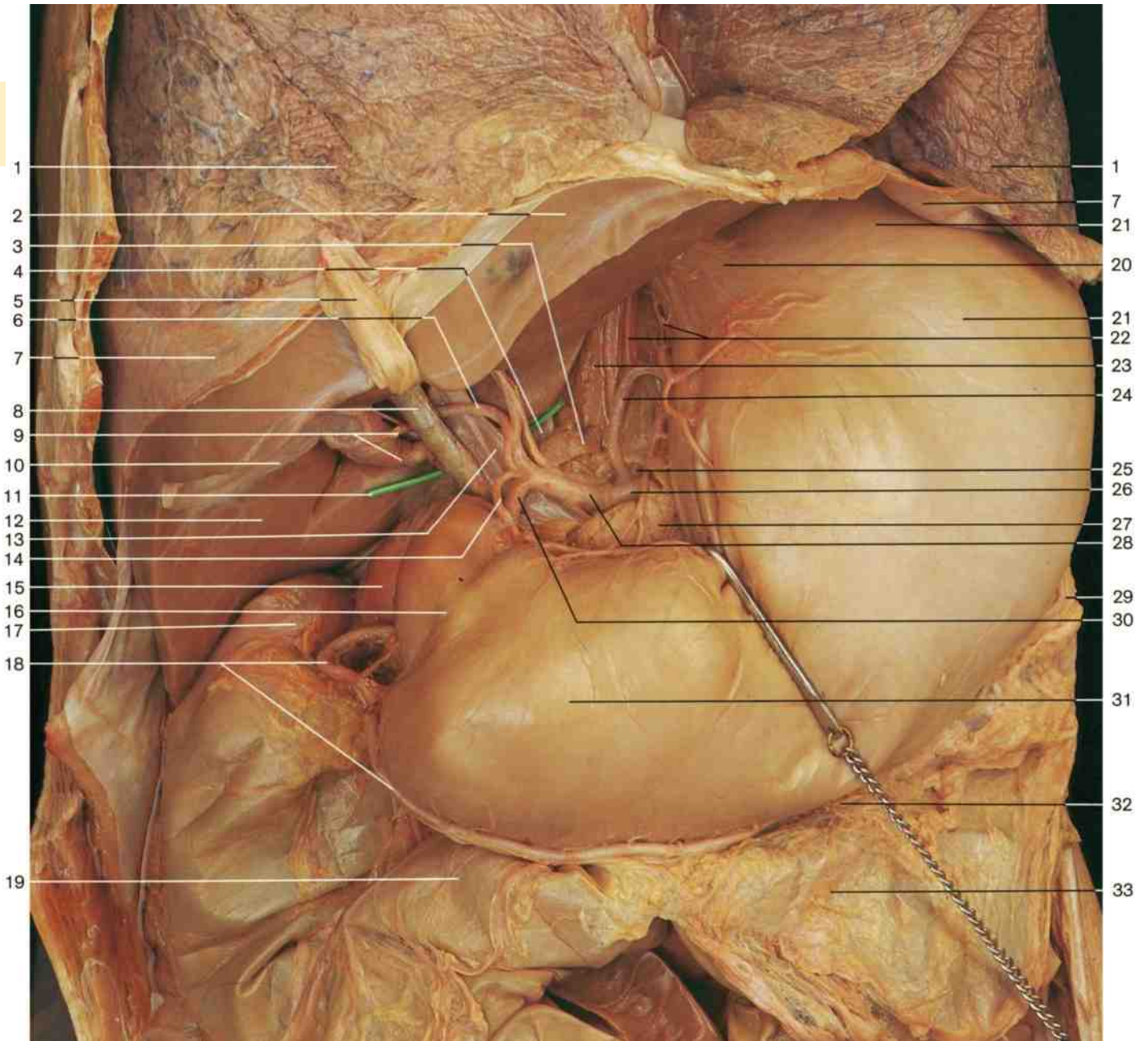
- | | |
|---|--|
| 1 Falciform ligament and ligamentum teres | 18 Diaphragm |
| 2 Liver | 19 Greater curvature with gastro-omental vessels |
| 3 Hepatoduodenal ligament | 20 Head of pancreas and gastropancreatic fold |
| 4 Gallbladder | 21 Spleen |
| 5 Probe within the epiploic foramen | 22 Tail of pancreas |
| 6 Superior part of duodenum | 23 Left colic flexure |
| 7 Pylorus | 24 Root of transverse mesocolon |
| 8 Descending part of duodenum | 25 Transverse mesocolon |
| 9 Right colic flexure | 26 Gastrocolic ligament (cut edge) |
| 10 Gastrocolic ligament | 27 Transverse colon |
| 11 Greater omentum | 28 Umbilicus |
| 12 Caudate lobe of liver | 29 Small intestine |
| 13 Fundus of stomach | 30 Lesser omentum |
| 14 Probe at the level of the vestibule of lesser sac (through epiploic foramen) | 31 Lesser sac (omental bursa) |
| 15 Head of pancreas | 32 Duodenum |
| 16 Lesser curvature of stomach | 33 Mesentery |
| 17 Body of stomach | 34 Sigmoid colon |



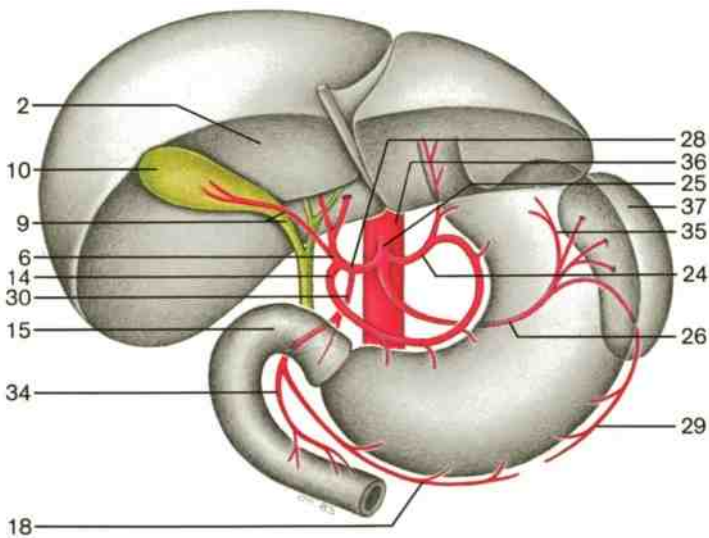
Upper abdominal organs (anterior aspect). Lesser sac. The gastrocolic ligament has been divided and the whole stomach raised to display the posterior wall of the lesser sac.



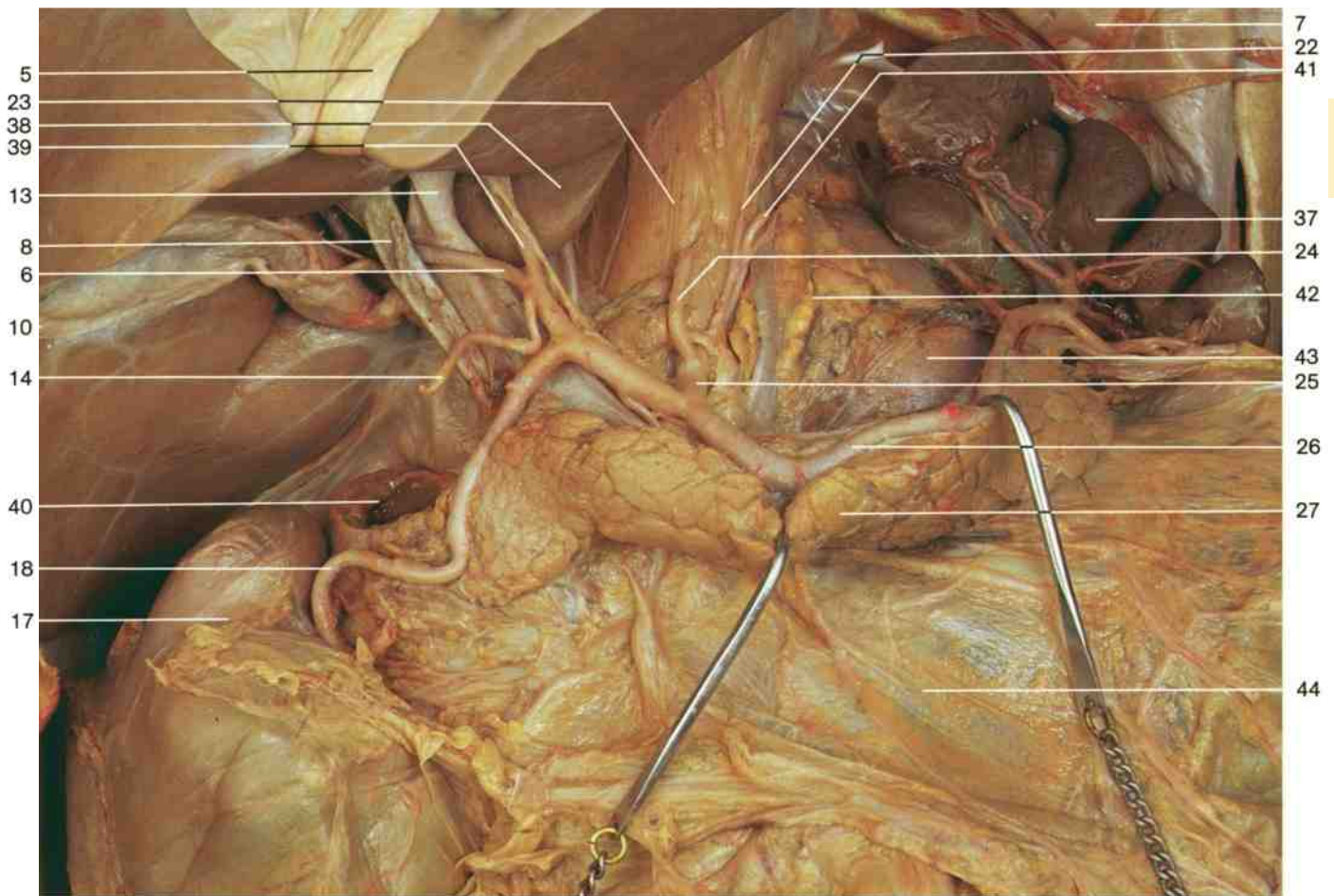
Midsagittal section through abdominal cavity, demonstrating the site of lesser sac (blue). (Schematic drawing.) The epiploic foramen, entrance to the lesser sac, is indicated by an arrow. Red = peritoneum.



Arteries of upper abdominal organs (anterior aspect). Dissection of celiac trunk. The lesser omentum has been removed and the lesser curvature of the stomach reflected to display the branches of the celiac trunk. The probe is situated within the epiploic foramen.



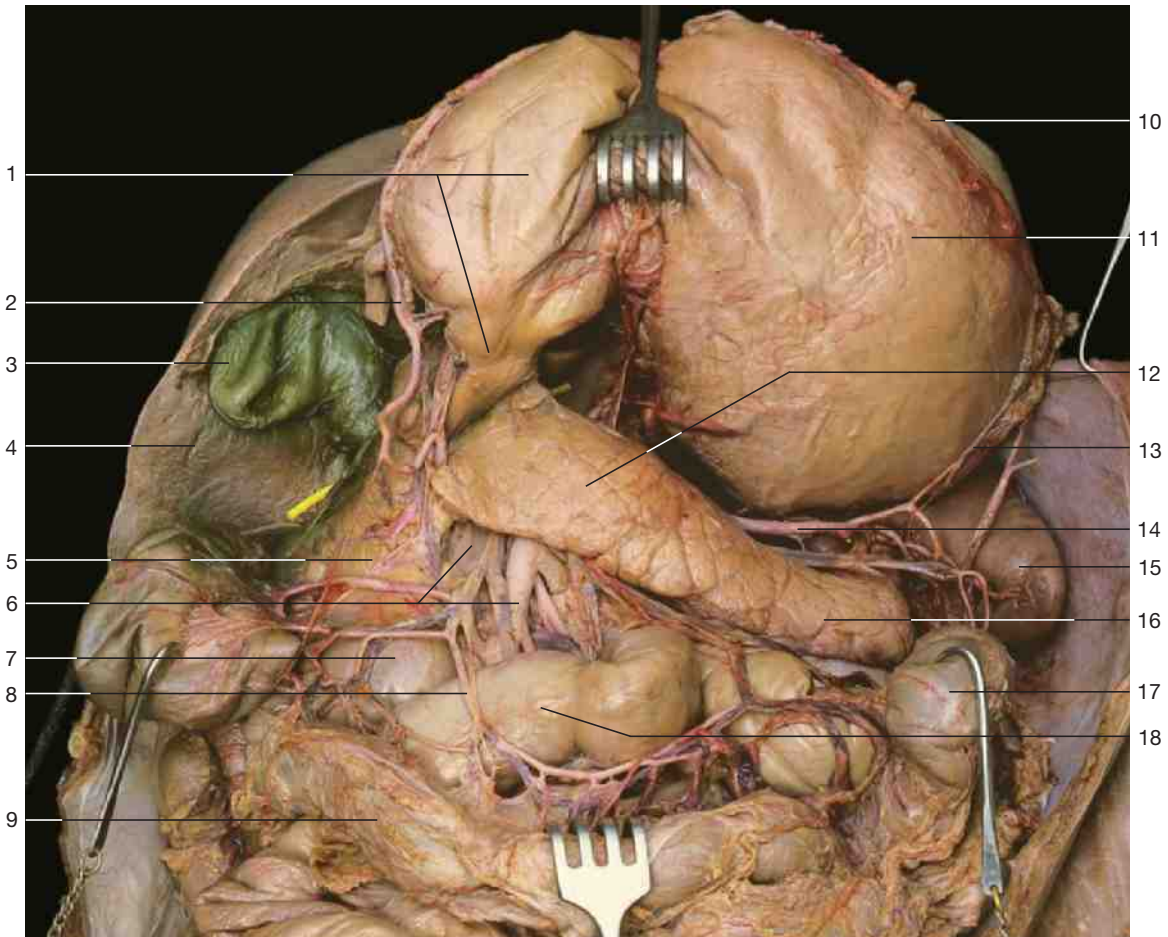
Branches of celiac trunk (schematic drawing).



Arteries of upper abdominal organs (anterior aspect). Branches of celiac trunk; blood supply of liver, pancreas, and spleen.

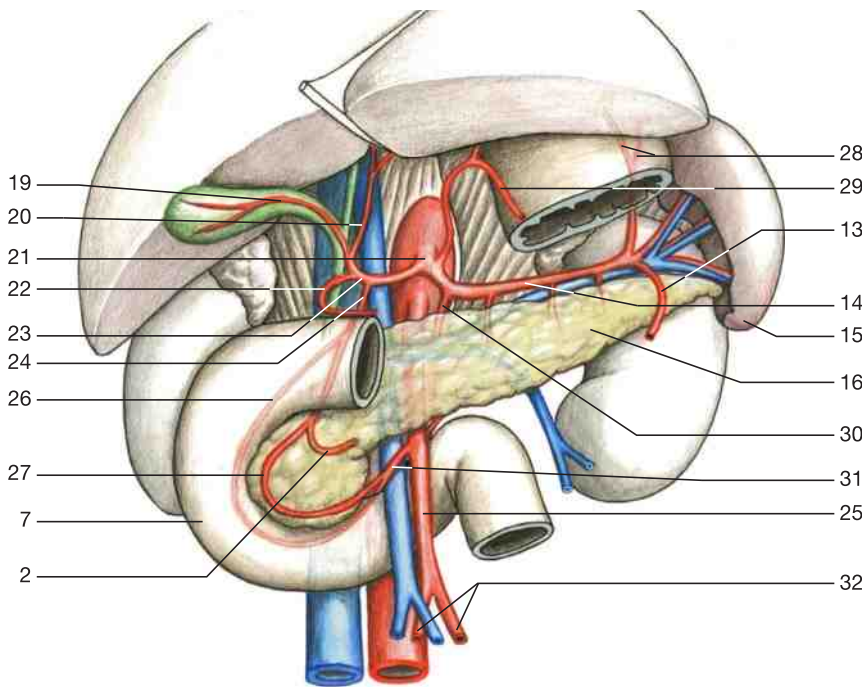
The stomach, superior part of duodenum, and celiac ganglion have been removed to reveal the anterior aspect of the posterior wall of the lesser sac (omental bursa) and the vessels and ducts of the hepatoduodenal ligament. The pancreas has been slightly reflected anteriorly.

- | | |
|--|---|
| 1 Lung | 23 Lumbar part of diaphragm |
| 2 Liver (visceral surface) | 24 Left gastric artery |
| 3 Lymph node | 25 Celiac trunk |
| 4 Inferior vena cava | 26 Splenic artery |
| 5 Ligamentum teres (reflected) | 27 Pancreas |
| 6 Right branch of hepatic artery proper | 28 Common hepatic artery |
| 7 Diaphragm | 29 Left gastro-omental (gastro-epiploic) artery |
| 8 Common hepatic duct (dilated) | 30 Gastroduodenal artery |
| 9 Cystic duct and artery | 31 Pyloric part of stomach |
| 10 Gallbladder | 32 Greater curvature of stomach |
| 11 Probe in epiploic foramen | 33 Gastrocolic ligament |
| 12 Right lobe of liver | 34 Superior pancreaticoduodenal artery |
| 13 Portal vein | 35 Short gastric arteries |
| 14 Right gastric artery | 36 Aorta |
| 15 Duodenum | 37 Spleen |
| 16 Pylorus | 38 Caudate lobe of liver |
| 17 Right colic flexure | 39 Left branch of hepatic artery proper |
| 18 Right gastro-omental (gastro-epiploic) artery | 40 Descending part of duodenum (cut) |
| 19 Transverse colon | 41 Left inferior phrenic artery |
| 20 Abdominal part of esophagus (cardiac part of stomach) | 42 Suprarenal gland |
| 21 Fundus of stomach | 43 Kidney |
| 22 Esophageal branches of left gastric artery | 44 Transverse mesocolon |

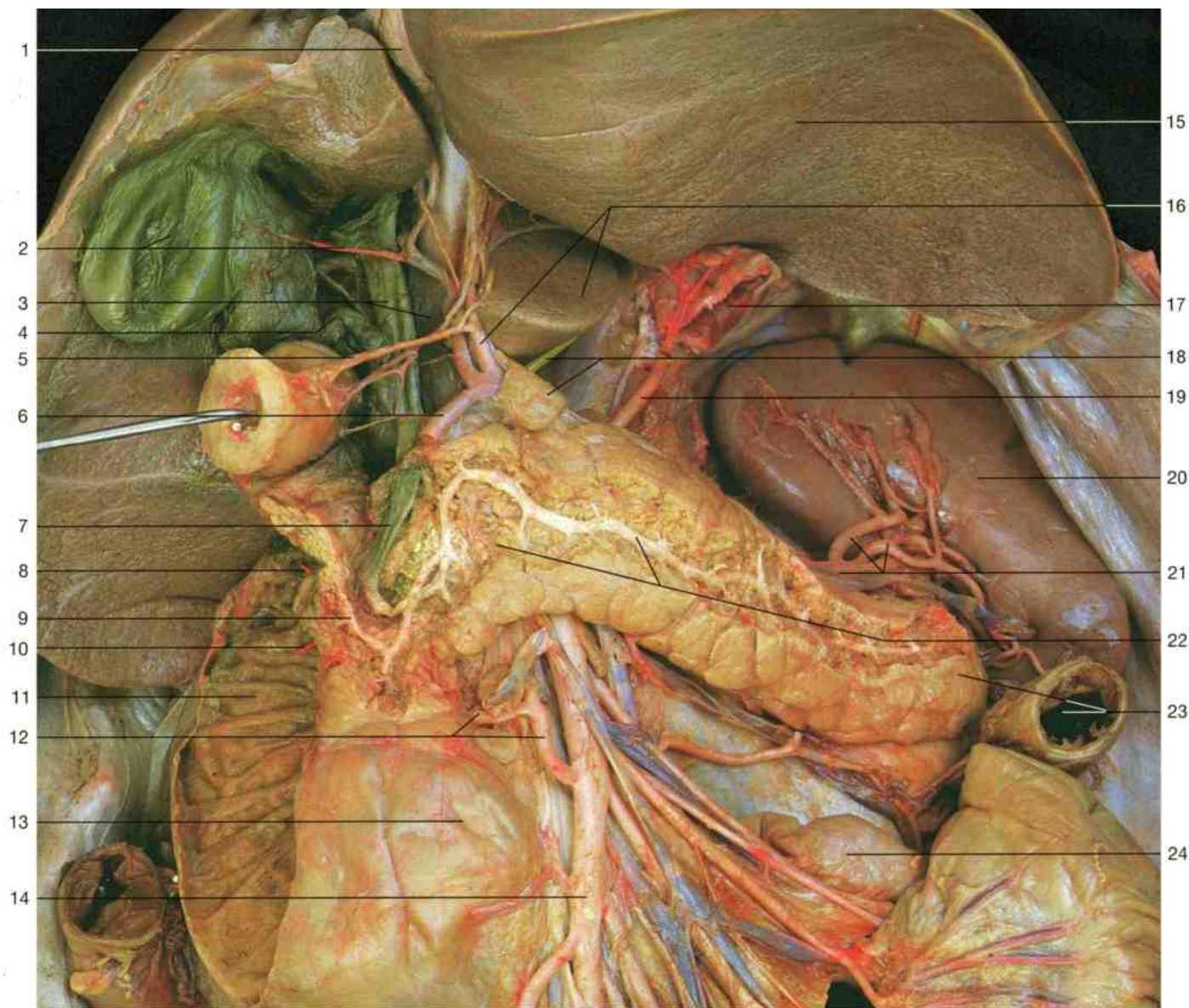


Posterior abdominal wall with pancreas and extrahepatic bile ducts in situ (anterior aspect). The gastrocolic ligament has been divided, the transverse colon and the stomach replaced to display the pancreas and superior mesenteric vessels.

- 1 Stomach (pyloric part) and pylorus
- 2 Right gastro-omental (gastro-epiploic) artery
- 3 Fundus of gallbladder
- 4 Liver (right lobe)
- 5 Head of pancreas
- 6 Superior mesenteric artery and vein
- 7 Duodenum
- 8 Middle colic artery
- 9 Transverse colon
- 10 Greater curvature of stomach (remnants of gastrocolic ligament)
- 11 Body of stomach
- 12 Body of pancreas
- 13 Left gastro-omental (gastro-epiploic) artery
- 14 Splenic artery
- 15 Spleen
- 16 Tail of pancreas
- 17 Left colic flexure
- 18 Jejunum
- 19 Cystic artery
- 20 Hepatic artery proper
- 21 Celiac trunk
- 22 Right gastric artery
- 23 Common hepatic artery
- 24 Gastroduodenal artery
- 25 Superior mesenteric artery
- 26 Superior posterior pancreaticoduodenal artery
- 27 Superior anterior pancreaticoduodenal artery
- 28 Short gastric arteries
- 29 Left gastric artery
- 30 Posterior pancreatic branch of splenic artery
- 31 Inferior pancreaticoduodenal artery
- 32 Jejunal arteries

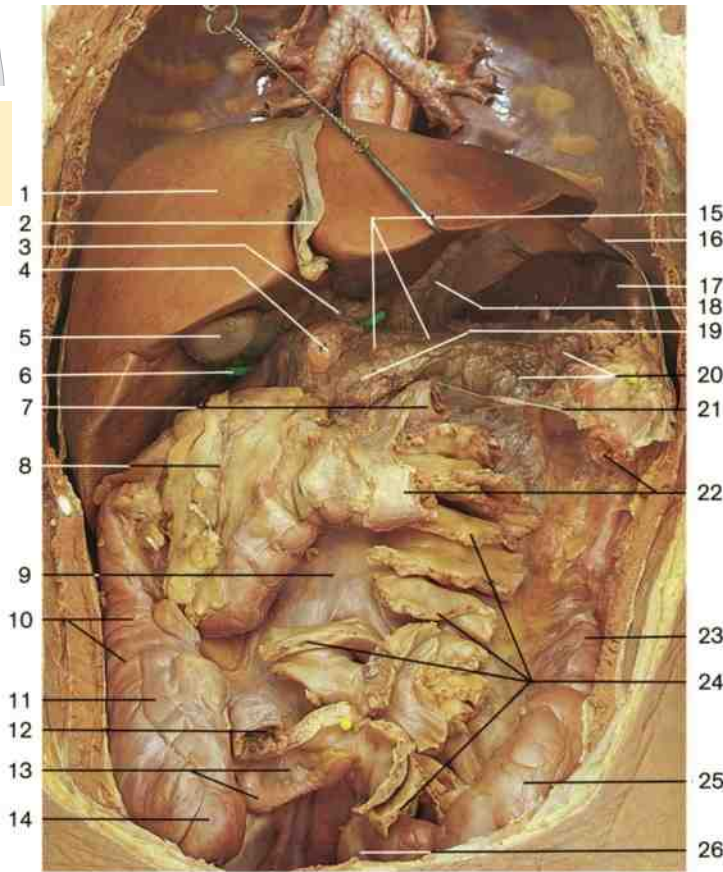


Blood supply of upper abdominal organs (branches of the celiac trunk and superior mesenteric artery). (Schematic drawing.)



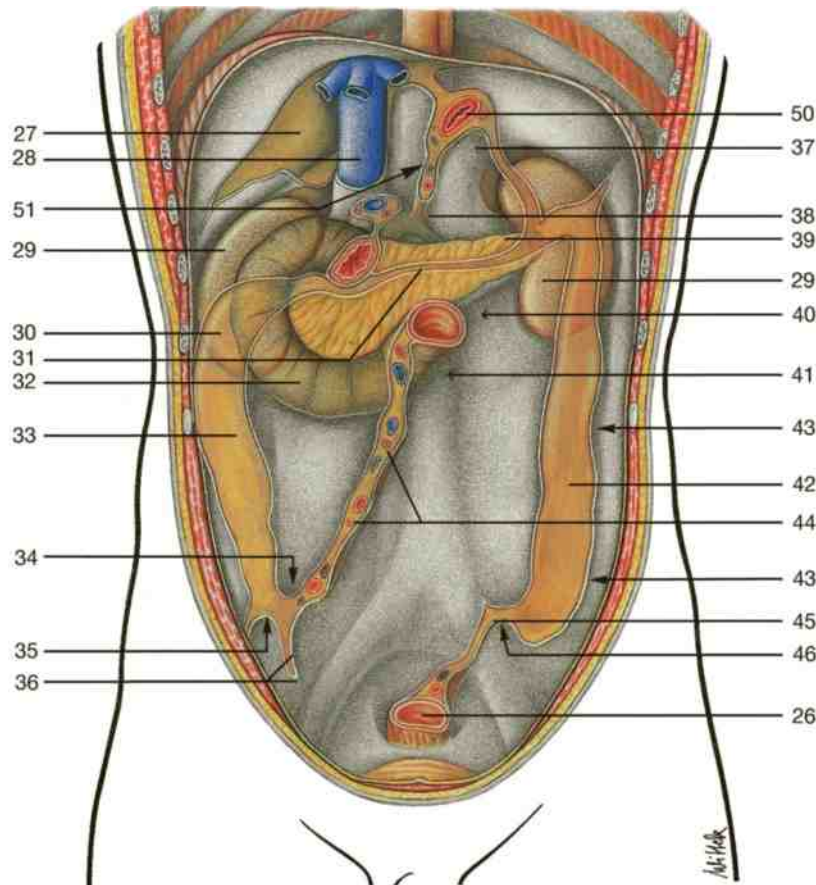
Posterior abdominal wall with duodenum, pancreas, and spleen (anterior aspect). Dissection of pancreatic and common bile duct. The stomach has been removed, the liver raised, and the duodenum anteriorly opened.

- | | |
|--|--|
| 1 Ligamentum teres | 13 Horizontal part of duodenum (distended) |
| 2 Gallbladder and cystic artery | 14 Superior mesenteric artery |
| 3 Common hepatic duct and portal vein | 15 Liver (left lobe) |
| 4 Cystic duct | 16 Caudate lobe of liver and hepatic artery proper |
| 5 Right gastric artery (pylorus with superior part of duodenum, cut and reflected) | 17 Abdominal part of esophagus (cut) |
| 6 Gastroduodenal artery | 18 Probe in epiploic foramen and lymph node |
| 7 Common bile duct | 19 Left gastric artery |
| 8 Probe within the minor duodenal papilla | 20 Spleen |
| 9 Accessory pancreatic duct | 21 Splenic vein and branches of splenic artery |
| 10 Probe within the major duodenal papilla | 22 Main pancreatic duct and head of pancreas |
| 11 Descending part of duodenum (opened) | 23 Left colic flexure and tail of pancreas |
| 12 Middle colic artery and inferior pancreaticoduodenal artery | 24 Duodenojejunal flexure |

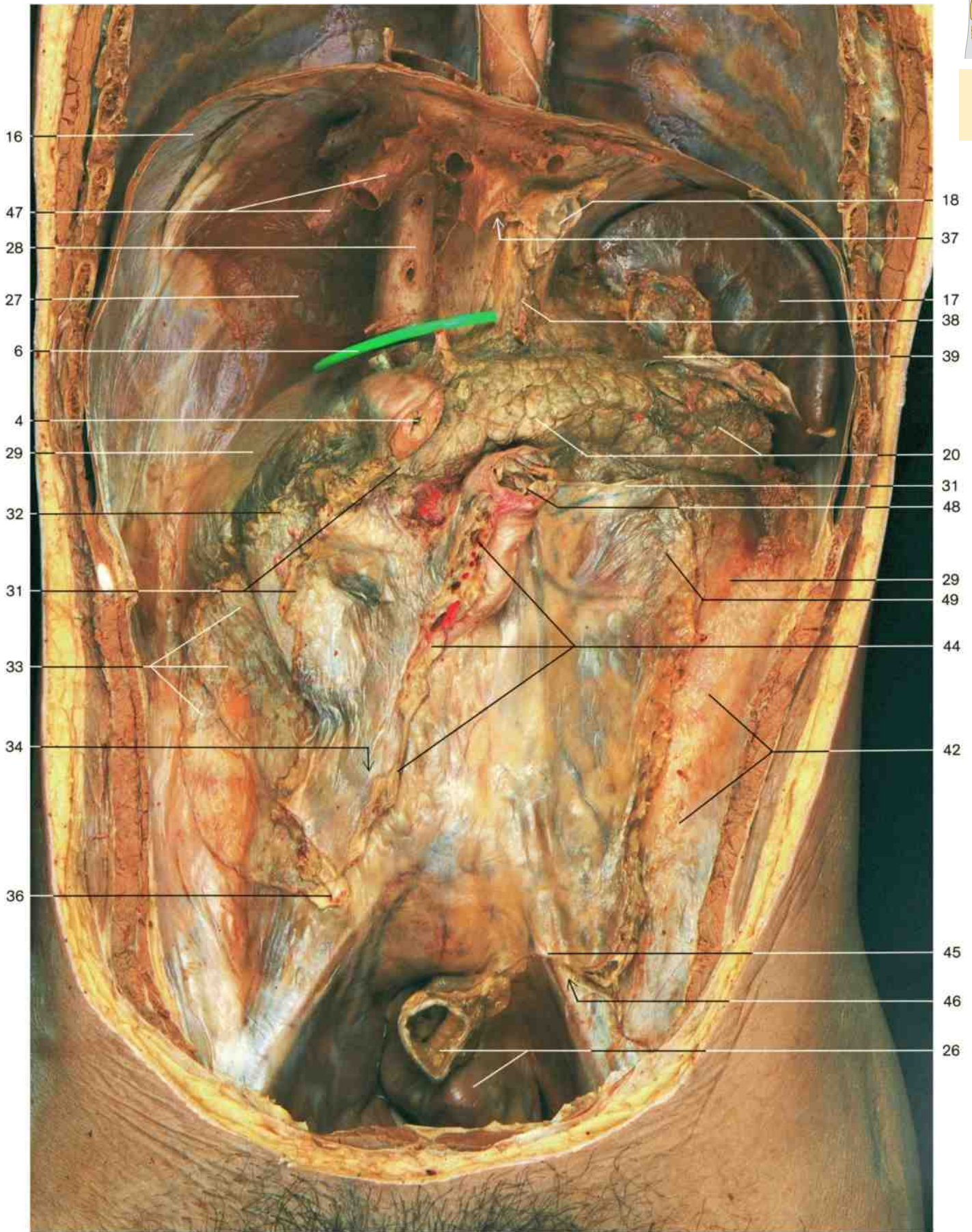


Abdominal cavity after removal of stomach, jejunum, ileum, and part of the transverse colon. Liver has been slightly raised.

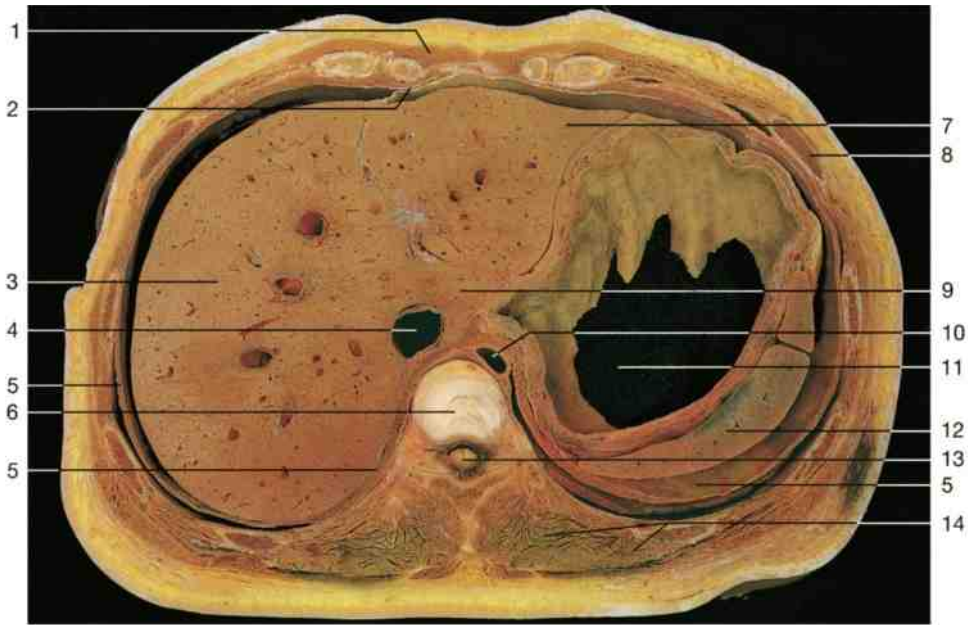
- 1 Liver
- 2 Falciform ligament
- 3 Hepatoduodenal ligament
- 4 Pylorus (divided)
- 5 Gallbladder
- 6 Probe within the epiploic foramen
- 7 Duodenojejunal flexure (divided)
- 8 Greater omentum
- 9 Root of mesentery
- 10 Ascending colon
- 11 Free colic taenia
- 12 End of ileum (divided)
- 13 Vermiform appendix with meso-appendix
- 14 Cecum
- 15 Pancreas and site of lesser sac
- 16 Diaphragm
- 17 Spleen
- 18 Cardia (part of stomach, divided)
- 19 Head of pancreas
- 20 Body and tail of pancreas
- 21 Transverse mesocolon
- 22 Transverse colon (divided)
- 23 Descending colon
- 24 Cut edge of mesentery
- 25 Sigmoid colon
- 26 Rectum
- 27 Attachment of bare area of liver
- 28 Inferior vena cava
- 29 Kidney
- 30 Attachment of right colic flexure
- 31 Root of transverse mesocolon
- 32 Junction between descending and horizontal parts of duodenum
- 33 Bare surface for ascending colon
- 34 Ileocecal recess
- 35 Retrocecal recess
- 36 Root of meso-appendix
- 37 Superior recess
- 38 Isthmus (opening)
- 39 Splenic recess
- 40 Superior duodenal recess
- 41 Inferior duodenal recess
- 42 Bare surface for descending colon
- 43 Paracolic recesses
- 44 Root of mesentery
- 45 Root of mesosigmoid
- 46 Intersigmoid recess
- 47 Hepatic veins
- 48 Duodenojejunal flexure
- 49 Attachment of left colic flexure
- 50 Esophagus
- 51 Entrance to lesser sac through the epiploic foramen



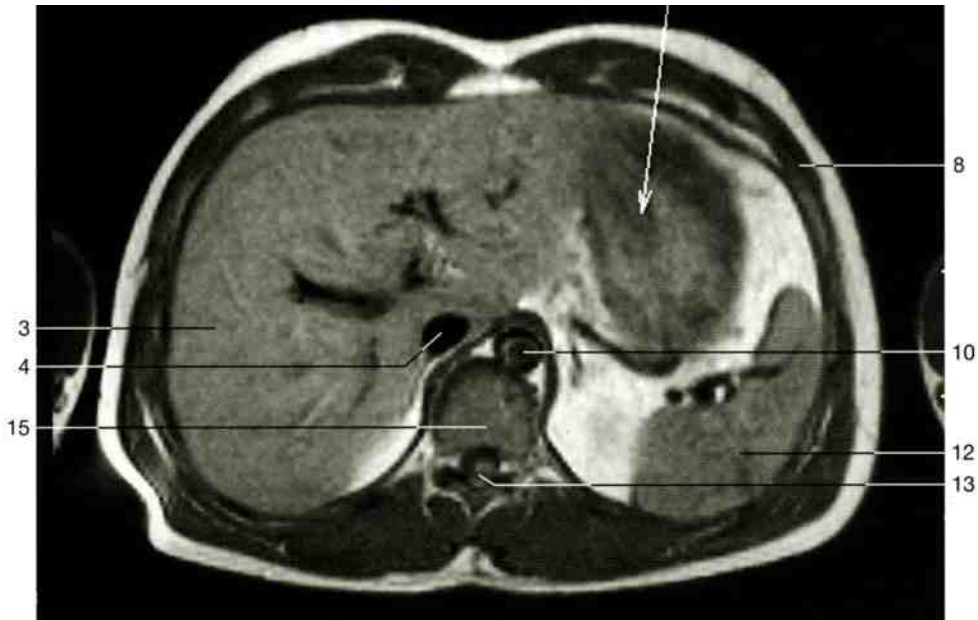Peritoneal reflections from organs and the position of root of mesentery and peritoneal recesses on the posterior abdominal wall (schematic drawing).



Peritoneal recesses on the posterior abdominal wall. The liver, stomach, jejunum, ileum, and colon have been removed. The duodenum, pancreas, and spleen have been left in place.

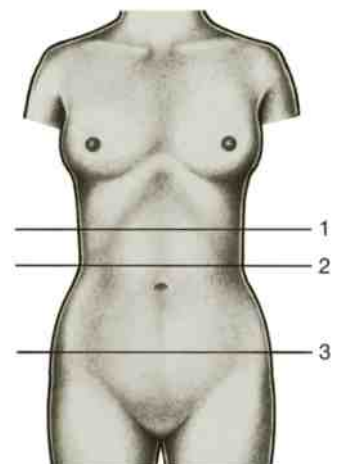


Horizontal section through the abdominal cavity at level 1 (from below).

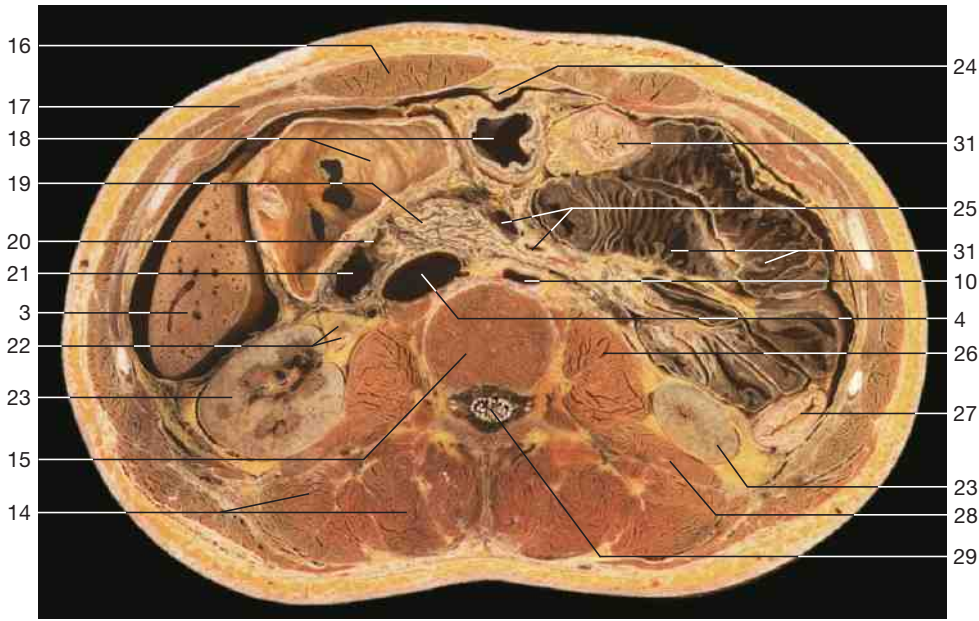


Horizontal section through the abdominal cavity (MRI scan, corresponding to level 1). Arrow: stomach.

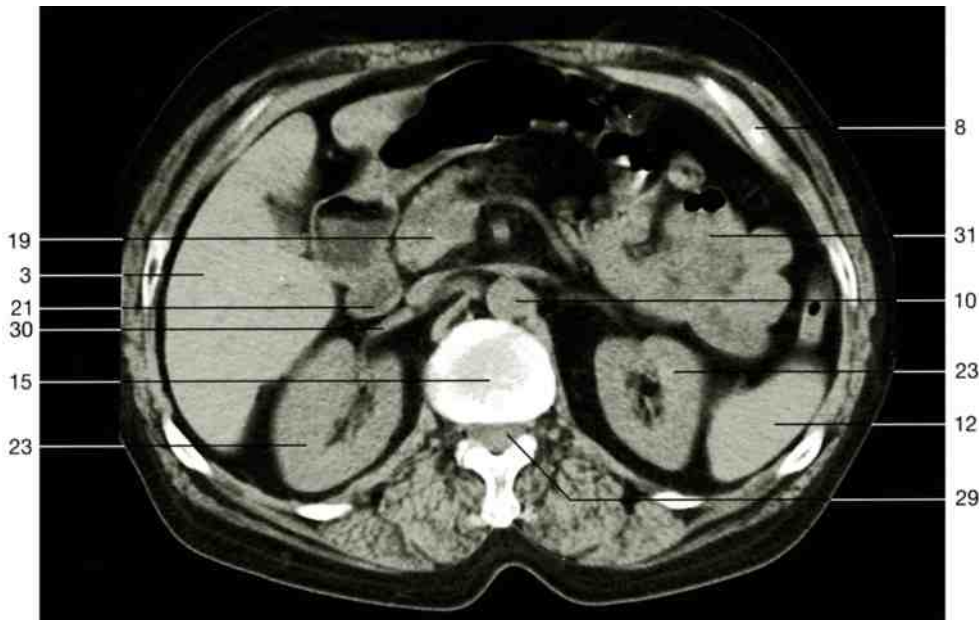
- | | |
|---|--|
| 1 Rectus abdominis muscle | 20 Greater duodenal papilla |
| 2 Falciform ligament | 21 Duodenum |
| 3 Liver (right lobe) | 22 Suprarenal gland and ureter |
| 4 Inferior vena cava | 23 Kidney |
| 5 Diaphragm | 24 Round ligament of liver |
| 6 Intervertebral disc | 25 Superior mesenteric artery and vein |
| 7 Liver (left lobe) | 26 Psoas major muscle |
| 8 Rib | 27 Descending colon |
| 9 Liver (caudate lobe) | 28 Quadratus lumborum muscle |
| 10 Abdominal (descending) aorta | 29 Cauda equina |
| 11 Stomach | 30 Right renal vein |
| 12 Spleen | 31 Small intestine |
| 13 Spinal cord | 32 Iliacus muscle |
| 14 Longissimus and iliocostalis muscles | 33 Ilium |
| 15 Body of vertebra | 34 Ileocecal valve |
| 16 Rectus abdominis muscle | 35 Cecum |
| 17 External abdominal oblique muscle | 36 Common iliac artery and vein |
| 18 Transverse colon | 37 Gluteus medius muscle |
| 19 Head of pancreas | 38 Vertebral canal and dura mater |



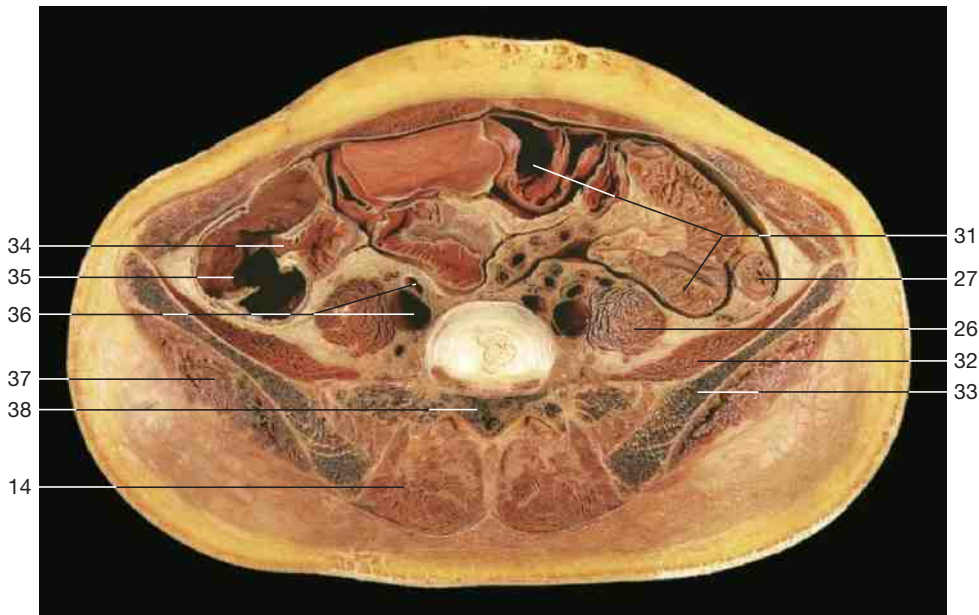
Levels of sections.



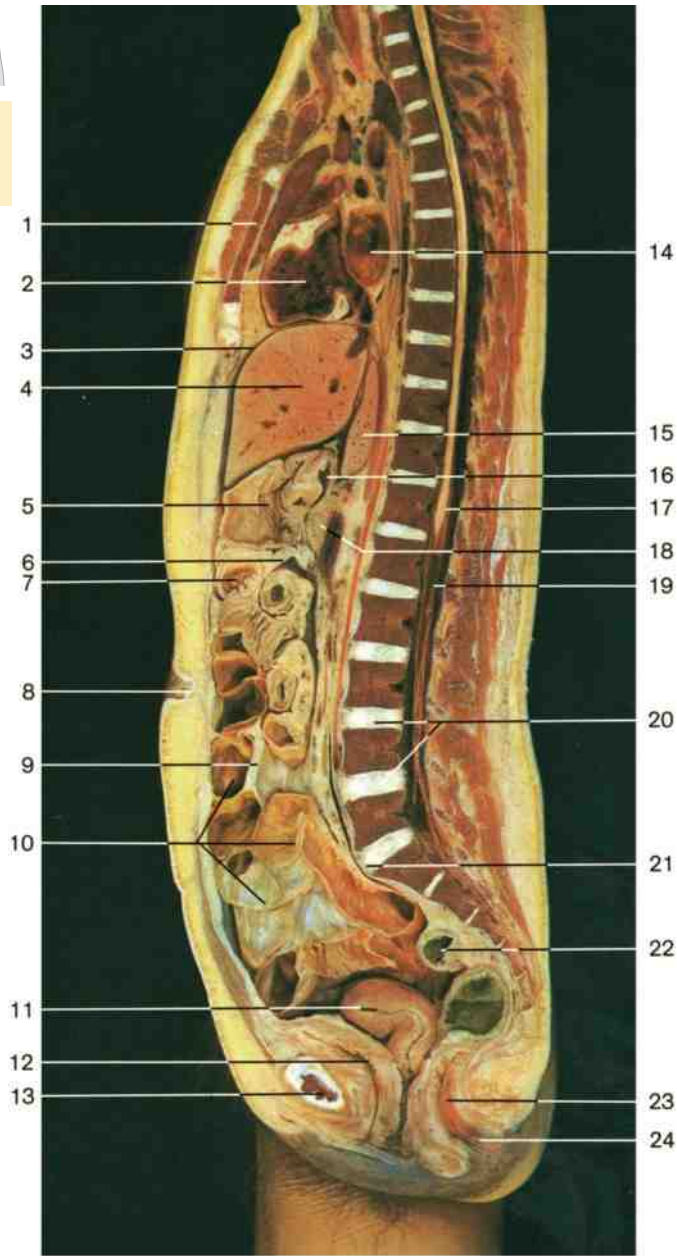
Horizontal section through the abdominal cavity at the level of greater duodenal papilla (from below).



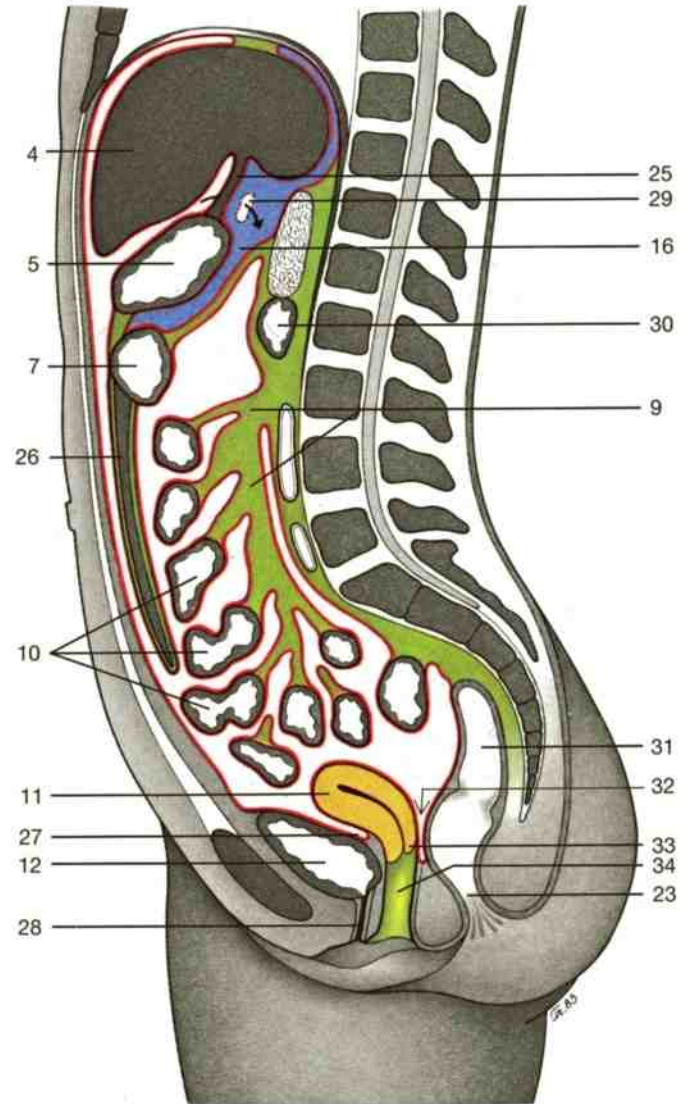
Horizontal section through the abdominal cavity (CT scan, corresponding to level 2).



Horizontal section through the abdominal cavity at level 3 (from below).

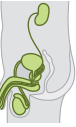

Midsagittal section through the trunk (female).

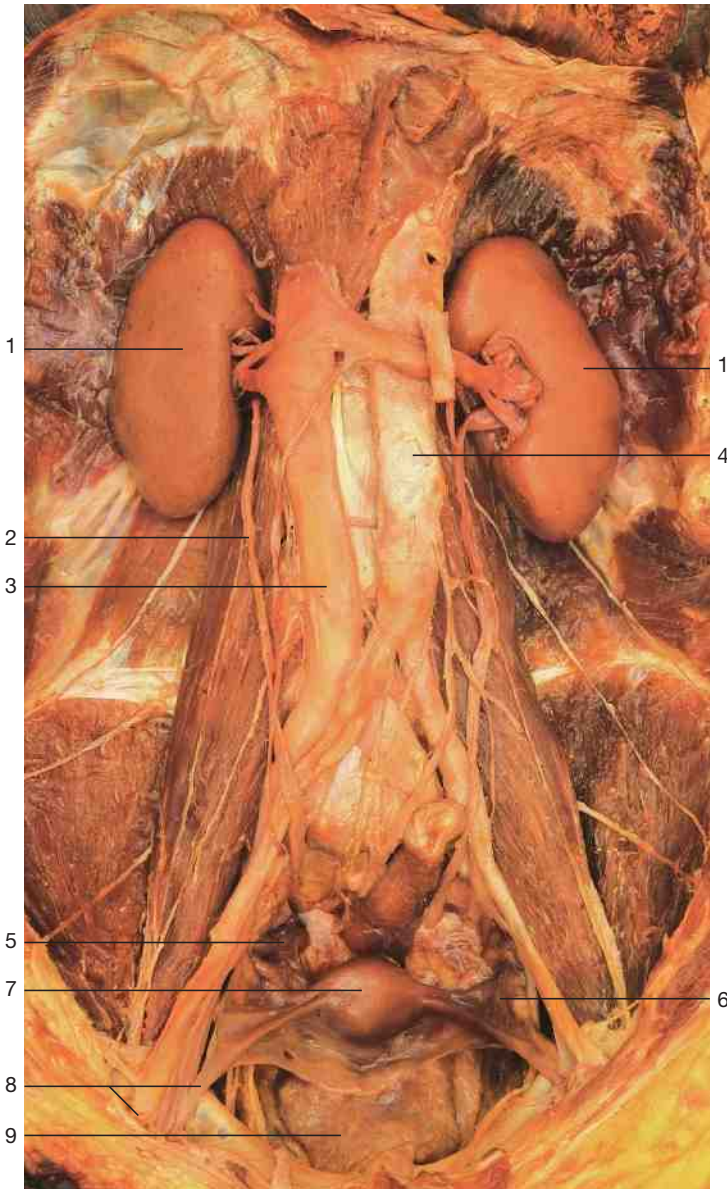


Midsagittal section through the trunk (female).
(Schematic drawing.) Blue = omental bursa; red = peritoneum.

- | | | |
|----------------------------|--|--|
| 1 Sternum | 13 Pubic symphysis | 24 Anus |
| 2 Right ventricle of heart | 14 Left atrium of heart | 25 Lesser omentum |
| 3 Diaphragm | 15 Caudate lobe of liver | 26 Greater omentum |
| 4 Liver | 16 Omental bursa or lesser sac | 27 Vesico-uterine pouch |
| 5 Stomach | 17 Conus medullaris | 28 Urethra |
| 6 Transverse mesocolon | 18 Pancreas | 29 Epiploic (omental) foramen |
| 7 Transverse colon | 19 Cauda equina | 30 Duodenum |
| 8 Umbilicus | 20 Intervertebral discs
(lumbar vertebral column) | 31 Rectum |
| 9 Mesentery | 21 Sacral promontory | 32 Recto-uterine pouch |
| 10 Small intestine | 22 Sigmoid colon | 33 Vaginal part of
cervix of uterus |
| 11 Uterus | 23 Anal canal | 34 Vagina |



6 Retroperitoneal Organs



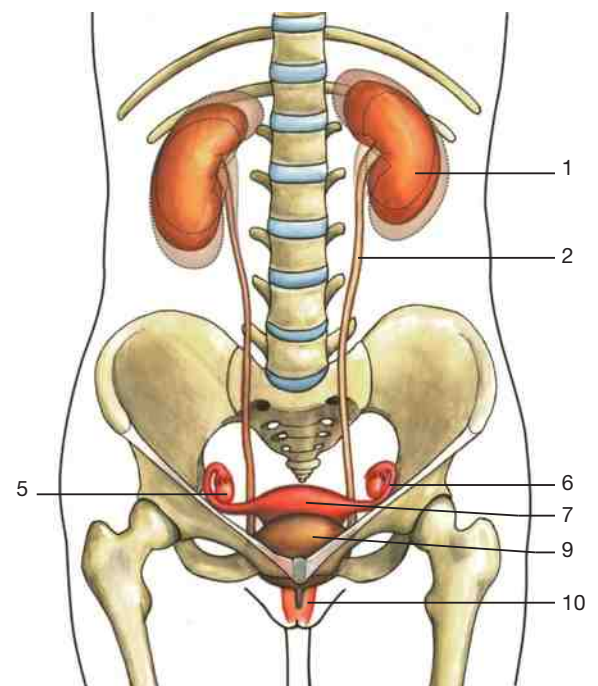
Retroperitoneal organs of the female (anterior aspect). View of the female pelvis showing uterus with uterine ligaments, ovary, and urinary bladder (from Lütjen-Drecoll, Rohen, *Innenansichten des menschlichen Körpers*, 2010).

- 1 Kidney
- 2 Ureter
- 3 Inferior vena cava
- 4 Abdominal aorta
- 5 Ovary
- 6 Uterine tube
- 7 Uterus
- 8 Round ligament and inguinal canal
- 9 Urinary bladder
- 10 Vagina

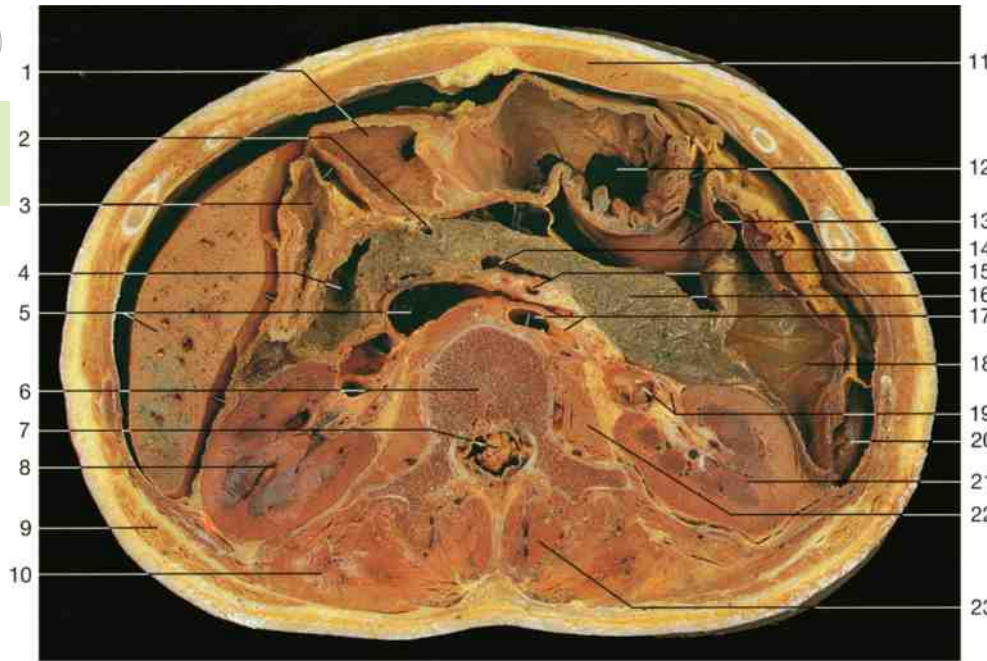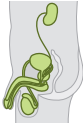The organs of the urinary system (kidney, ureter, and, in the female, genital organs) are located together with vessels and nerves (aorta, inferior vena cava, plexus solaris, etc.) within the retroperitoneal space.

The upper part of the kidneys reaches the level of the margin of the lung. During respiration, the kidneys move slightly within their fasciae of Gerota. Parallel with the vertebral column, the ureter runs towards the urinary bladder. The great center of the autonomic nervous system, the solar plexus (celiac ganglion, etc.), is located in front of the abdominal aorta.

The genital organs of the female (uterus, uterine tube, ovary) are located within the pelvic cavity. In the male, the testis has moved out of the abdominal cavity and penetrated the inguinal canal to be finally located within the extragenital organs.

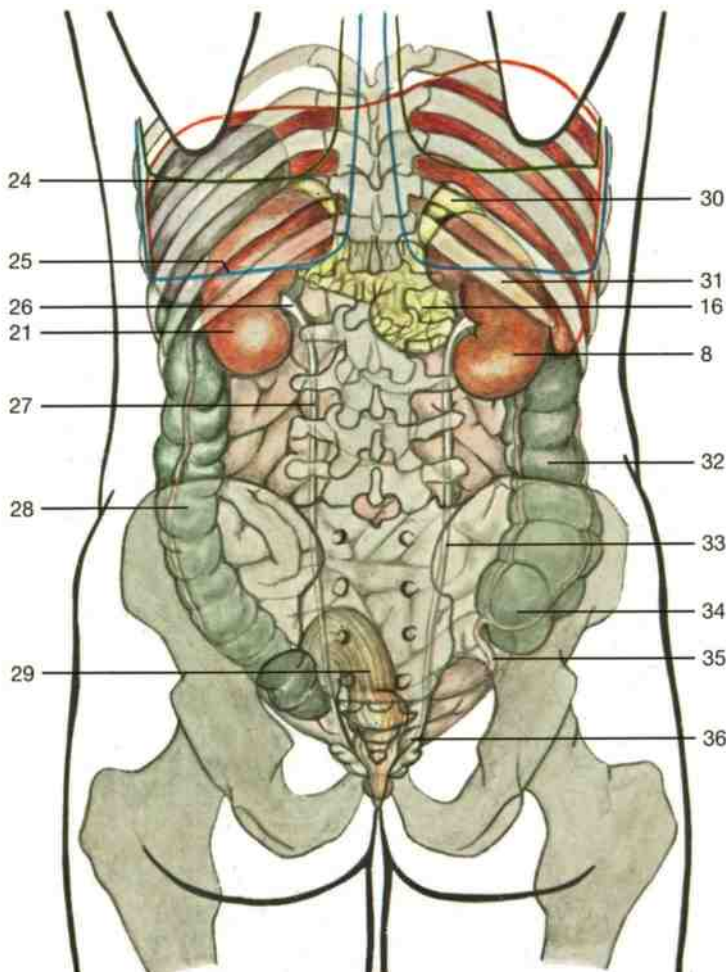


Position of kidneys, urinary and genital organs in the female (anterior aspect, schematic drawing). The excursions of the kidneys with the respiratory movements of the diaphragm are indicated.

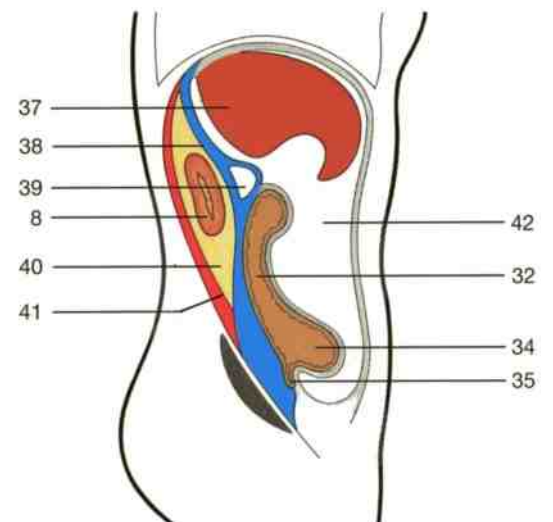


Horizontal section through the abdominal cavity at the level of the first lumbar vertebra (from below).

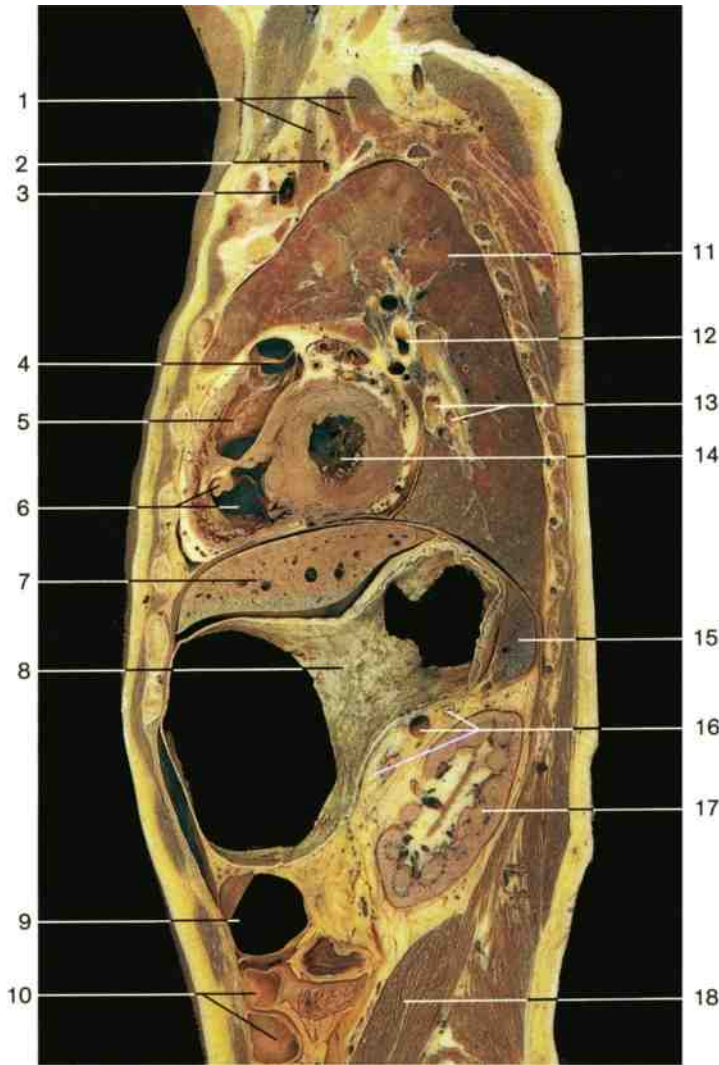
- 1 Pyloric antrum
- 2 Gastroduodenal artery
- 3 Descending part of duodenum
- 4 Vestibule of lesser sac
- 5 Inferior vena cava and liver
- 6 Body of first lumbar vertebra
- 7 Cauda equina
- 8 Right kidney
- 9 Latissimus dorsi muscle
- 10 Iliocostalis muscle
- 11 Rectus abdominis muscle
- 12 Stomach
- 13 Lesser sac
- 14 Splenic vein
- 15 Superior mesenteric artery
- 16 Pancreas
- 17 Aorta and left renal artery
- 18 Transverse colon
- 19 Renal artery and vein
- 20 Spleen
- 21 Left kidney
- 22 Psoas major muscle
- 23 Multifidus muscle
- 24 Margin of lung
- 25 Margin of pleura
- 26 Renal pelvis
- 27 Left ureter
- 28 Descending colon
- 29 Rectum
- 30 Right suprarenal gland
- 31 Twelfth rib
- 32 Ascending colon
- 33 Right ureter
- 34 Cecum
- 35 Vermiform appendix
- 36 Urinary bladder
- 37 Liver
- 38 Anterior layer of renal fascia
- 39 Duodenum
- 40 Perirenal fatty tissue
- 41 Posterior layer of renal fascia
- 42 Abdominal cavity



Positions of urinary organs (posterior aspect, schematic drawing). Notice that the upper part of the kidney reaches the level of the margin of pleura and lung.

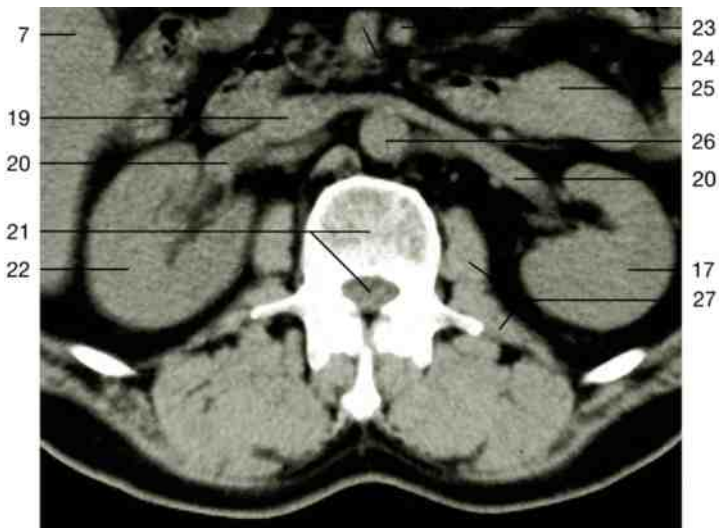

Retroperitoneal tissue, position of the right kidney (schematic drawing). Yellow = adipose capsule of kidney.

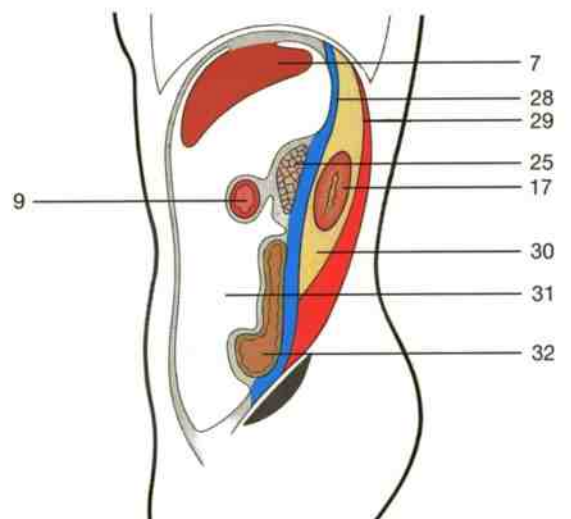


- 1 Scalenus anterior, medius, and posterior muscles
- 2 Left subclavian artery
- 3 Left subclavian vein
- 4 Pulmonic valve
- 5 Arterial cone
- 6 Right ventricle of heart
- 7 Liver
- 8 Stomach
- 9 Transverse colon
- 10 Small intestine
- 11 Left lung
- 12 Left main bronchus
- 13 Branches of pulmonary vein
- 14 Left ventricle of heart
- 15 Spleen
- 16 Splenic artery and vein and pancreas
- 17 Left kidney
- 18 Psoas major muscle
- 19 Inferior vena cava
- 20 Renal vein
- 21 Body of twelfth thoracic vertebra and vertebral canal
- 22 Right kidney
- 23 Superior mesenteric artery
- 24 Superior mesenteric vein
- 25 Pancreas
- 26 Abdominal aorta
- 27 Left psoas major and quadratus lumborum muscles
- 28 Anterior layer of renal fascia } of Gerota
- 29 Posterior layer of renal fascia }
- 30 Perirenal fatty tissue
- 31 Abdominal cavity
- 32 Descending and sigmoid colon

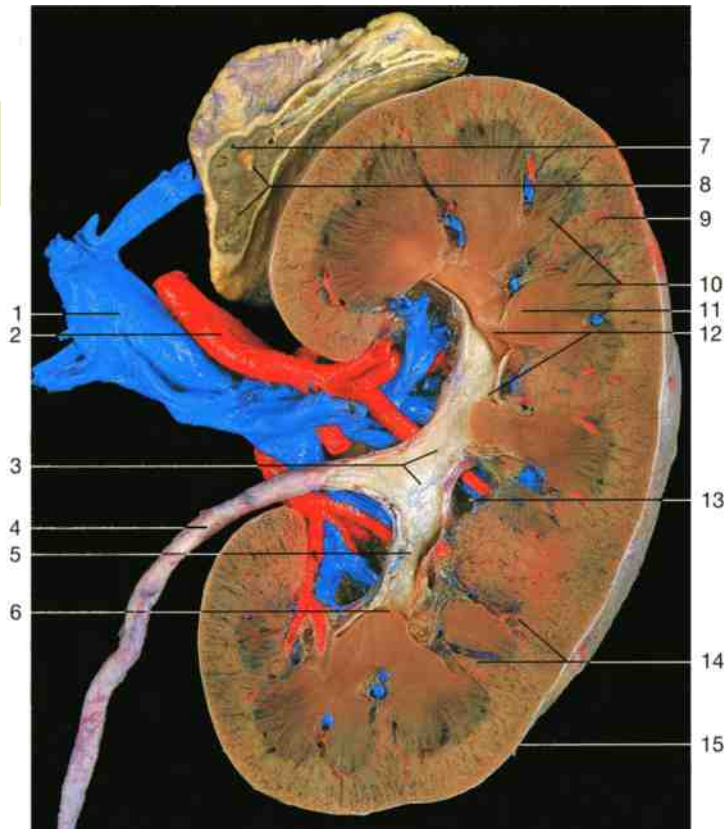
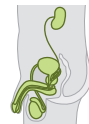Parasagittal section through the thoracic and abdominal cavities at the level of the left kidney (5.5 cm left of median plane).



Horizontal section through the retroperitoneal region at the level of 12th thoracic vertebra (CT scan, from below).

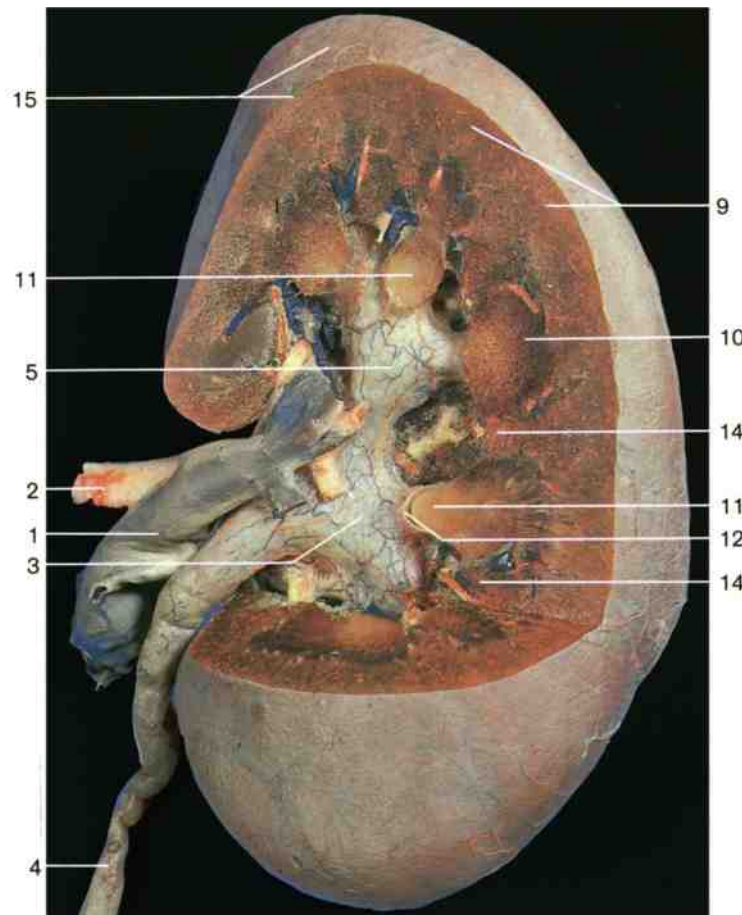


Retroperitoneal tissue, position of the left kidney (schematic drawing).



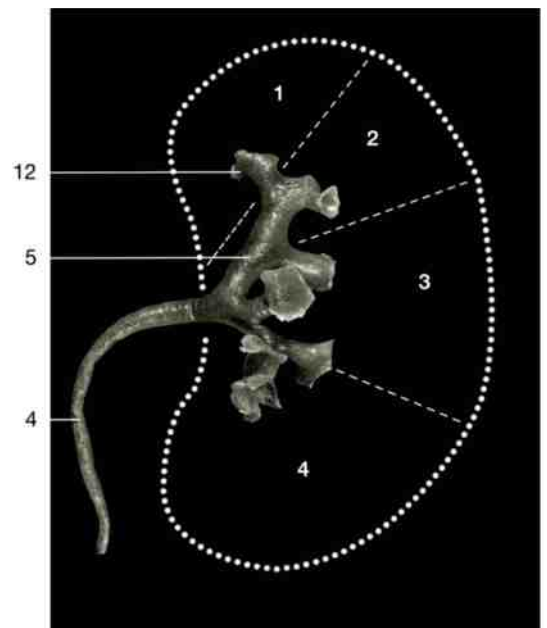
- 1 Renal vein
- 2 Renal artery
- 3 Renal pelvis
- 4 Abdominal part of ureter
- 5 Major renal calyx
- 6 Cribriform area of renal papilla
- 7 Cortex of suprarenal gland
- 8 Medulla of suprarenal gland
- 9 Cortex of kidney
- 10 Medulla of kidney
- 11 Renal papilla
- 12 Minor renal calyx
- 13 Renal sinus
- 14 Renal columns
- 15 Fibrous capsule of kidney

Coronal section through right kidney and suprarenal gland (posterior aspect). The renal pelvis has been opened and the fatty tissue removed to display the renal vessels.

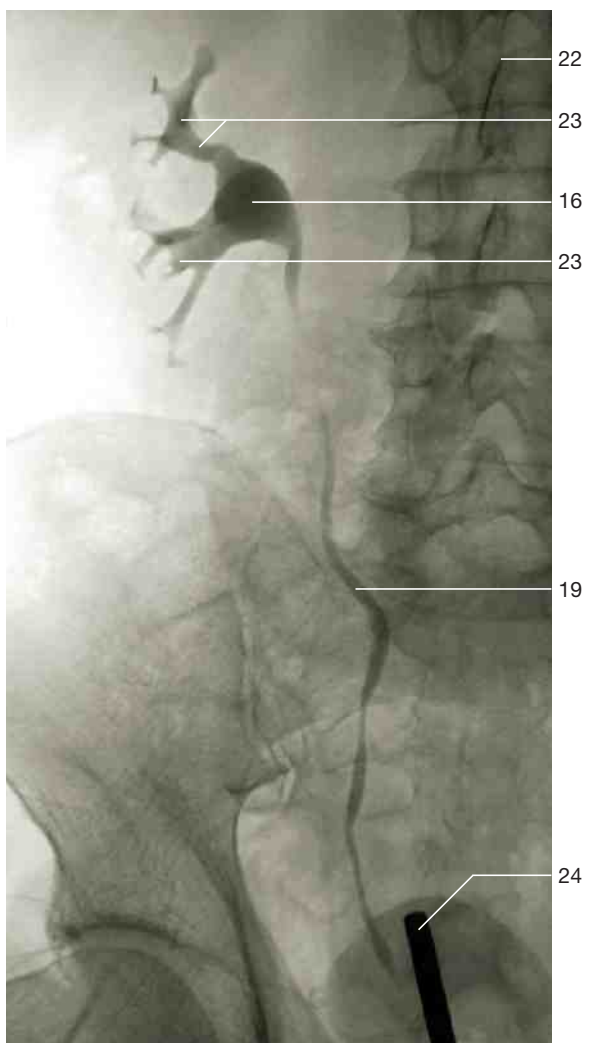
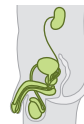

Right kidney (posterior aspect). Partial coronal section to expose internal aspect of the kidney.

Each kidney can be divided into five segments supplied by individual interlobar arteries known as end arteries. Thus, obstruction leads to infarcts marking the trace of segment borders. The anterior kidney surface reveals four segments; the posterior, only three (Nos. 1, 4, and 5).

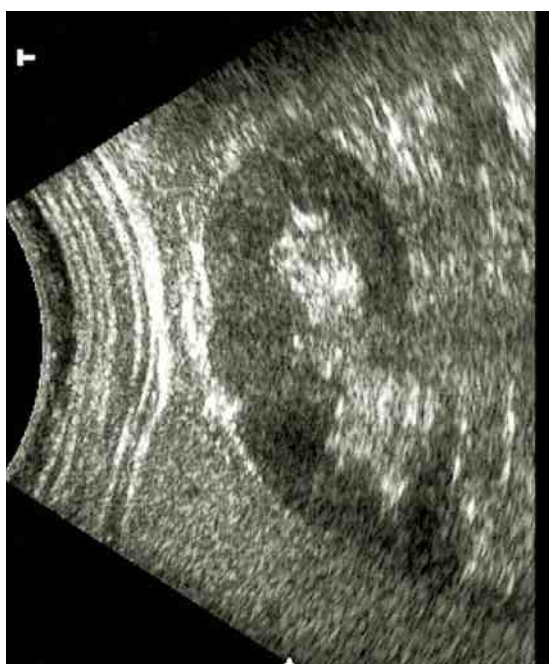

Cast of renal pelvis and calices.
1-4 = Renal segments on anterior surface.

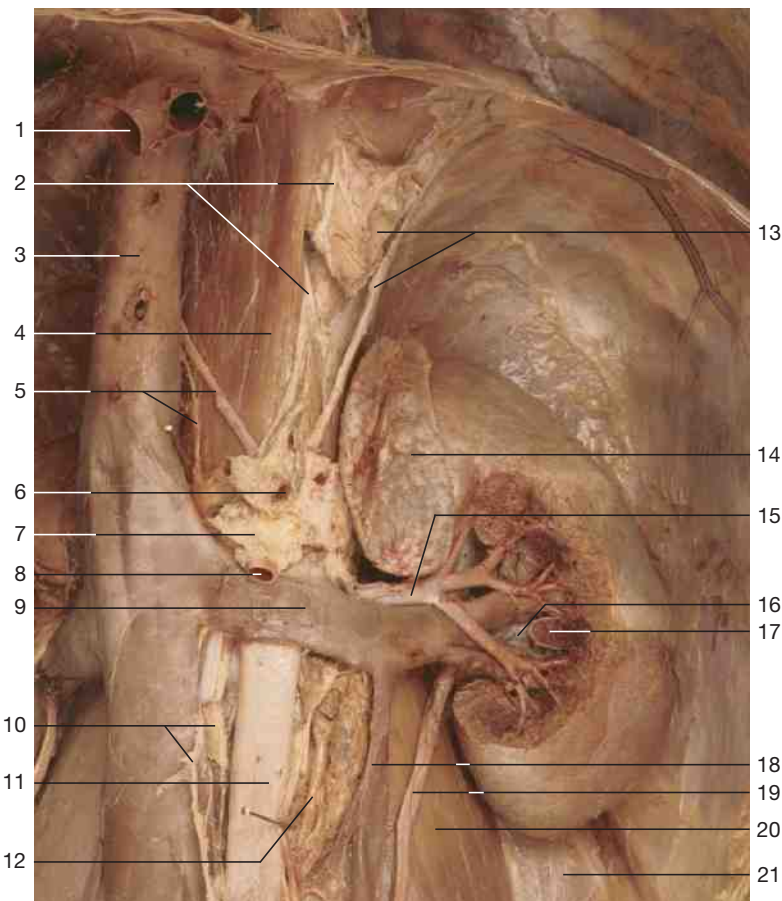


- 1 Hepatic vein
- 2 Anterior and posterior vagal trunk
- 3 Inferior vena cava
- 4 Lumbar part of diaphragm
- 5 Right greater and lesser splanchnic nerves
- 6 Celiac trunk
- 7 Celiac ganglion and plexus
- 8 Superior mesenteric artery
- 9 Left renal vein
- 10 Right sympathetic trunk and ganglion
- 11 Abdominal aorta
- 12 Left sympathetic trunk
- 13 Esophagus (cut),
left greater splanchnic nerve
- 14 Left suprarenal gland
- 15 Left renal artery
- 16 Renal pelvis
- 17 Renal papilla with minor calyx
- 18 Left testicular vein
- 19 Ureter
- 20 Psoas major muscle
- 21 Quadratus lumborum muscle
- 22 Lumbar vertebra (L₂)
- 23 Renal calyx
- 24 Catheter

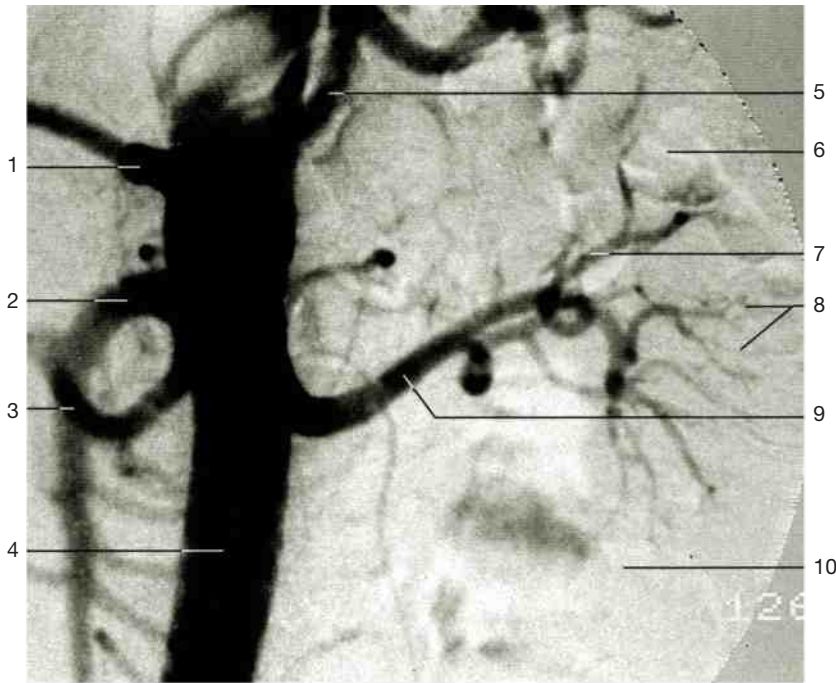
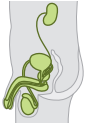Renal pelvis with calices and ureter (X-ray, retrograde injection; by courtesy of Prof. Herrlinger, Fürth, Germany).



Right kidney (ultrasound image; by courtesy of Prof. Herrlinger, Fürth, Germany).

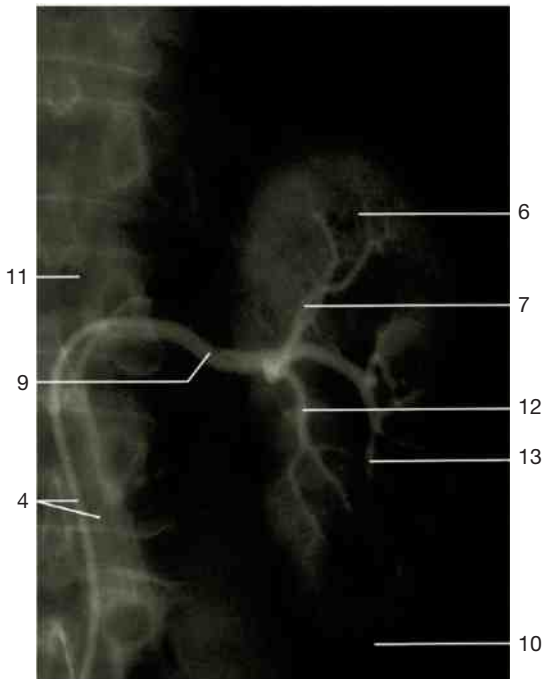


Left kidney and suprarenal gland in situ. The anterior cortical layer of the kidney has been removed to display the renal pelvis and papillae.

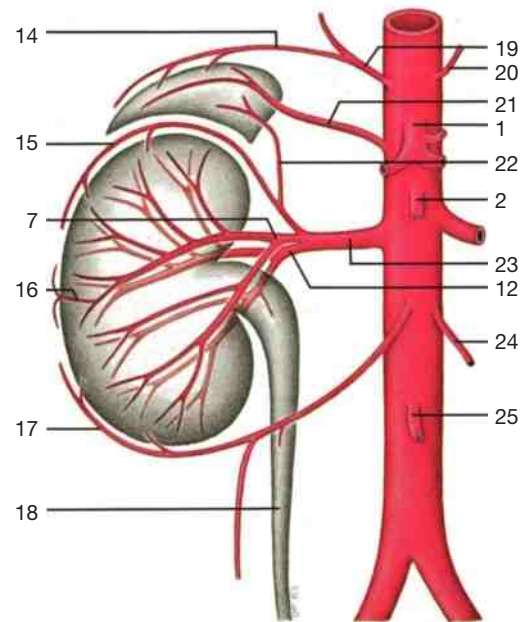


Abdominal aorta (subtraction angiography).

- 1 Celiac trunk
- 2 Superior mesenteric artery
- 3 Middle colic artery
- 4 Abdominal aorta (with catheter)
- 5 Splenic artery
- 6 Upper pole of kidney
- 7 Anterior branch of renal artery
- 8 Interlobular arteries
- 9 Left renal artery
- 10 Lower pole of kidney
- 11 Body of first lumbar vertebra
- 12 Posterior branch of renal artery
- 13 Anterior inferior segmental artery
- 14 Superior suprarenal artery
- 15 Upper capsular artery
- 16 Perforating artery
- 17 Lower capsular artery
- 18 Ureter
- 19 Right inferior phrenic artery
- 20 Left inferior phrenic artery
- 21 Middle suprarenal artery
- 22 Inferior suprarenal artery
- 23 Renal artery
- 24 Left testicular (or ovarian) artery
- 25 Inferior mesenteric artery



Left kidney (arteriography).

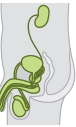

Arteries of kidney and suprarenal gland (schematic drawing).

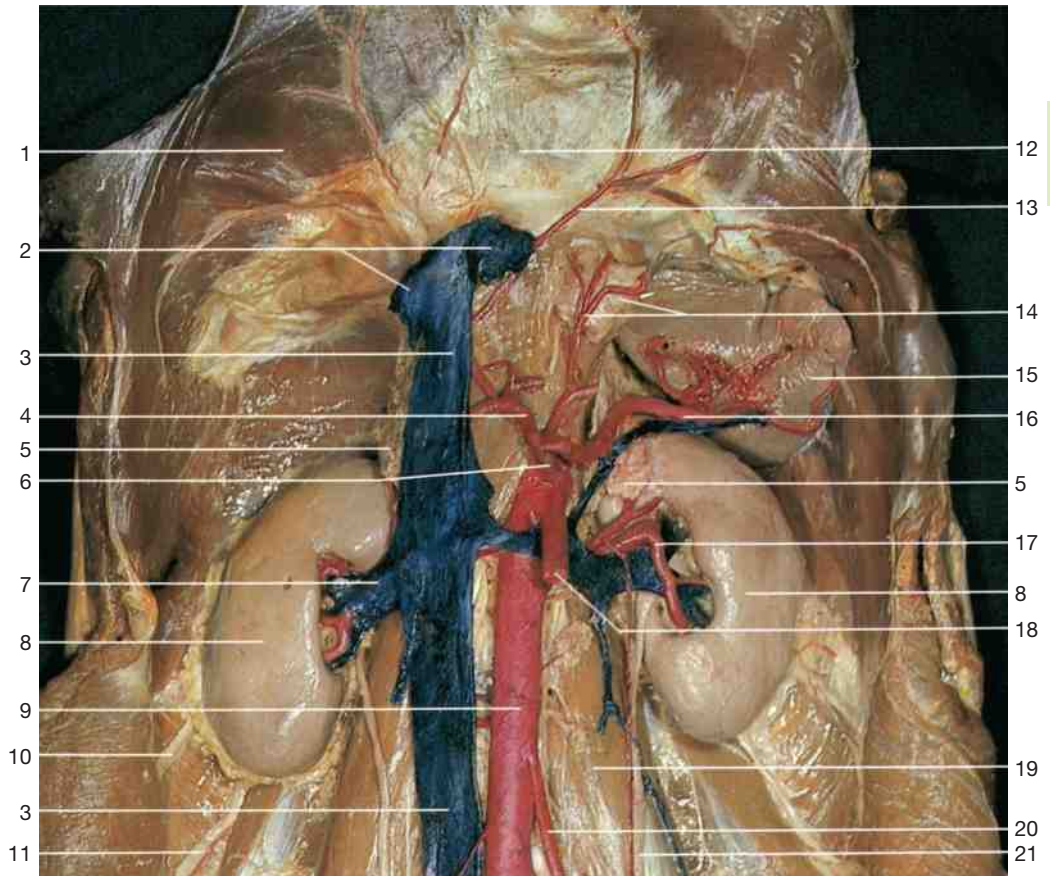
The kidneys are perfused by app. 1.500–1.800 l of blood per day via the renal arteries. Out of more than 1.2 million renal corpuscles (glomeruli), 1% of this volume (id 150–180 l) is filtered as a cell free fluid. In the tubular system, 99% of this fluid, together with useful substances like glucose and

ions, are reabsorbed. Only 1–1.5 l of urine containing waste material is excreted.

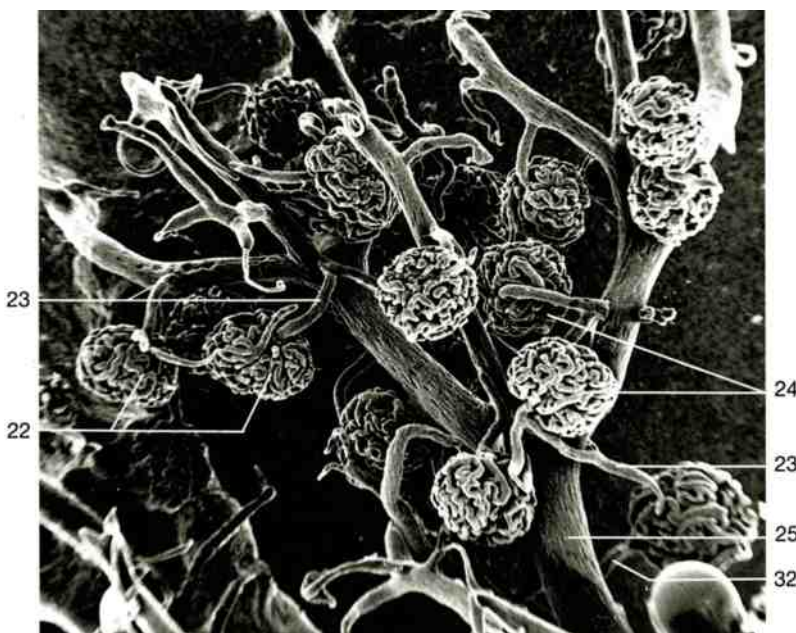
Diseases of the renal vascular system may impair the filtering process and thereby the composition of the blood.



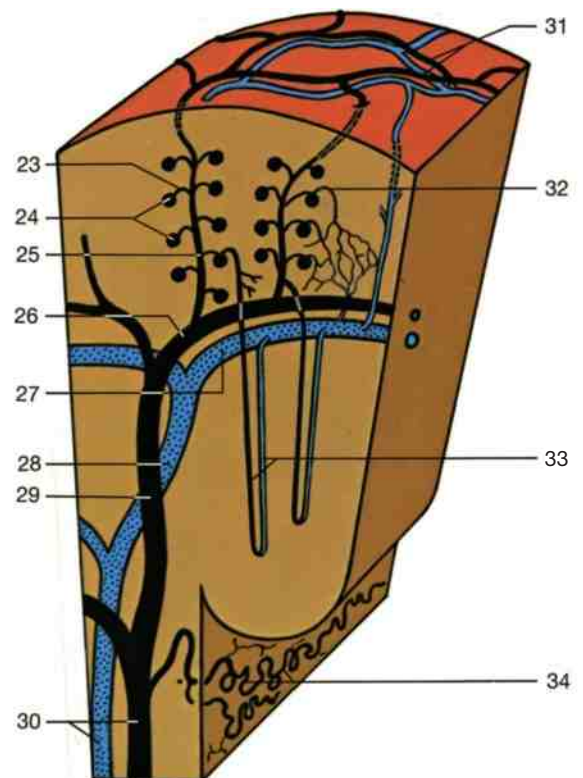
- 1 Diaphragm
- 2 Hepatic veins
- 3 Inferior vena cava
- 4 Common hepatic artery
- 5 Suprarenal gland
- 6 Celiac trunk
- 7 Right renal vein
- 8 Kidney
- 9 Abdominal aorta
- 10 Subcostal nerve
- 11 Iliohypogastric nerve
- 12 Central tendon of diaphragm
- 13 Inferior phrenic artery
- 14 Cardiac part of stomach
- 15 Spleen
- 16 Splenic artery
- 17 Superior renal artery
- 18 Superior mesenteric artery
- 19 Psoas major muscle
- 20 Inferior mesenteric artery
- 21 Ureter
- 22 Glomerulus
- 23 Afferent arteriole of glomerulus
- 24 Glomeruli
- 25 Radiating cortical artery
- 26 Subcortical or arcuate artery
- 27 Subcortical or arcuate vein
- 28 Interlobular vein
- 29 Interlobular artery
- 30 Interlobar artery and vein
- 31 Vessels of renal capsule
- 32 Efferent arteriole of glomerulus
- 33 Vasa recta of renal medulla
- 34 Spiral arteries of renal pelvis



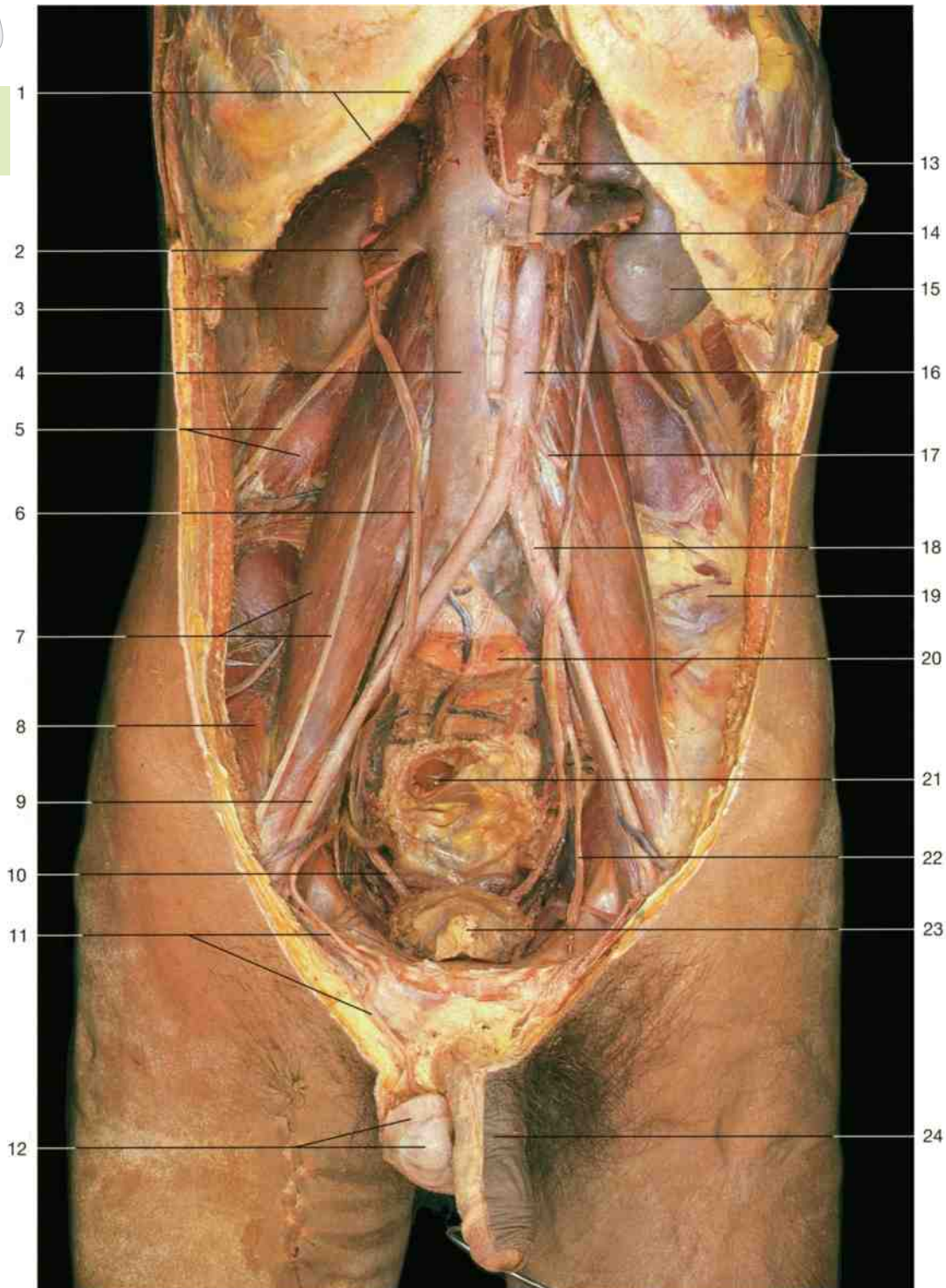
Retroperitoneal organs, kidneys, and suprarenal glands in situ (anterior aspect).
Red = arteries; blue = veins.



Glomeruli (210×). Scanning electron micrograph showing glomeruli and associated arteries.

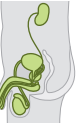


Architecture of vascular system of kidney (schematic drawing).



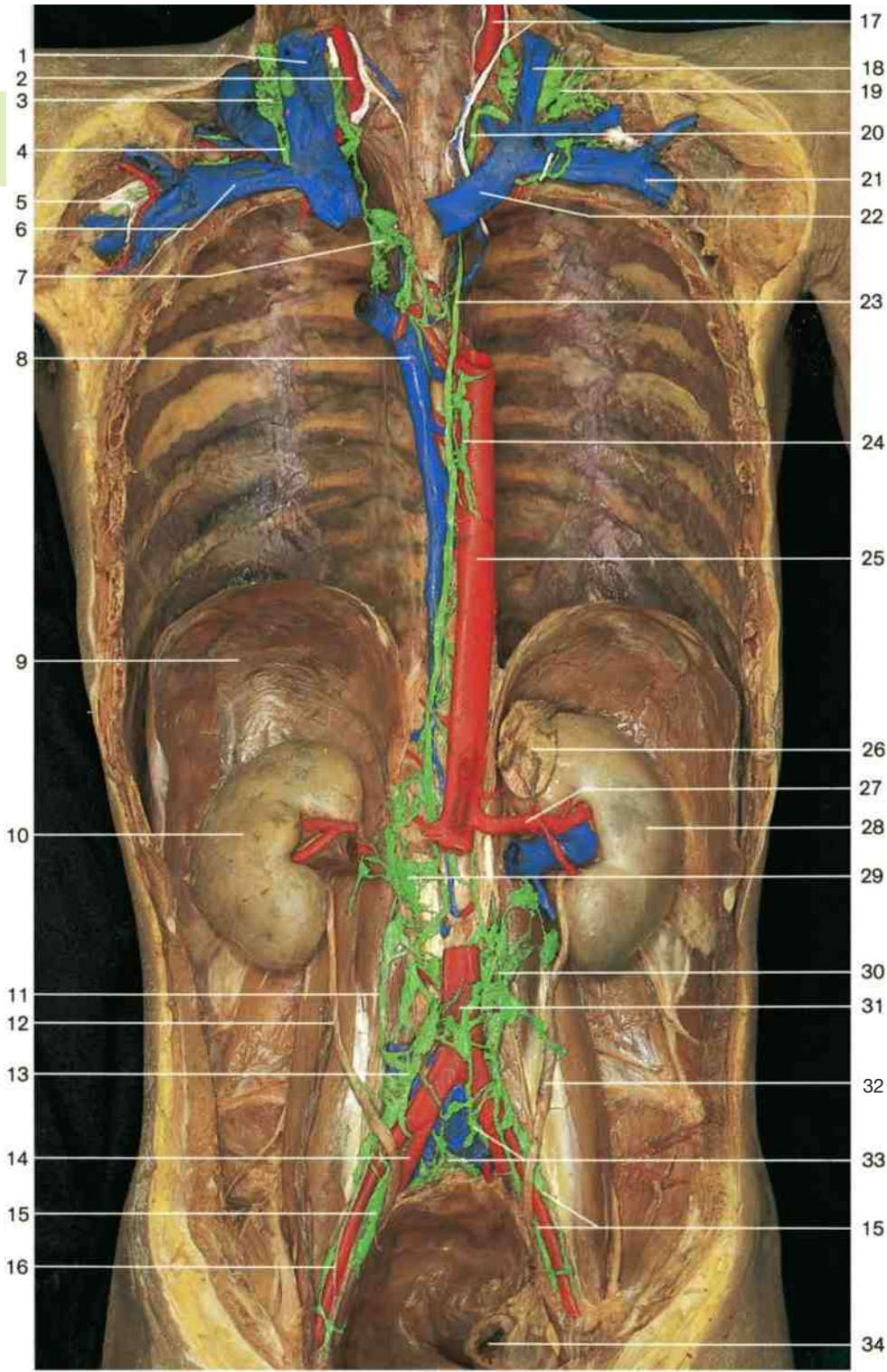
Retroperitoneal organs, urinary system in the male (anterior aspect). The peritoneum has been removed.

- | | | |
|---|-------------------------------|-------------------------------|
| 1 Costal arch | 8 Iliacus muscle | 17 Inferior mesenteric artery |
| 2 Right renal vein | 9 External iliac artery | 18 Common iliac artery |
| 3 Right kidney | 10 Ureter (pelvic part) | 19 Iliac crest |
| 4 Inferior vena cava | 11 Ductus deferens | 20 Sacral promontory |
| 5 Iliohypogastric nerve and quadratus lumborum muscle | 12 Testis and epididymis | 21 Rectum (cut) |
| 6 Ureter (abdominal part) | 13 Celiac trunk | 22 Medial umbilical ligament |
| 7 Psoas major muscle and genitofemoral nerve | 14 Superior mesenteric artery | 23 Urinary bladder |
| | 15 Left kidney | 24 Penis |
| | 16 Abdominal aorta | |



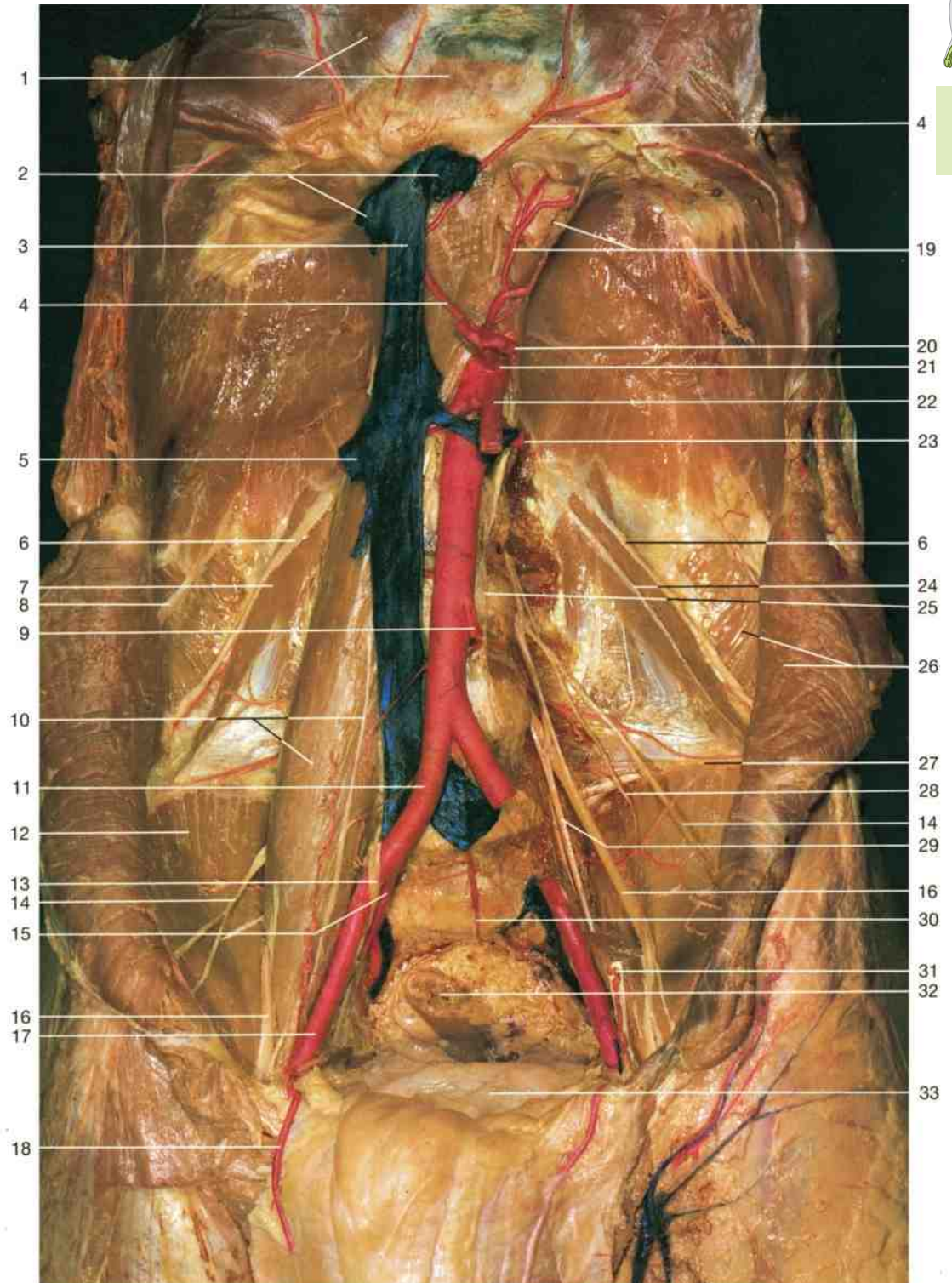
Retroperitoneal organs, urinary system in situ (anterior aspect). The peritoneum has been removed. Note the autonomic plexus and ganglia at the abdominal aorta.

- | | | | |
|------------------------------|----------------------------|-------------------------------------|---|
| 1 Diaphragm | 7 Right spermatic vein | 11 Abdominal aorta | 16 Ilio-inguinal nerve |
| 2 Inferior vena cava | 8 Psoas major muscle | 12 Splenic artery | 17 Superior hypogastric plexus and ganglion |
| 3 Suprarenal gland | 9 Spleen | 13 Celiac trunk and celiac ganglion | 18 Left common iliac artery |
| 4 Kidney | 10 Cardiac part of stomach | 14 Renal artery and vein | 19 Sigmoid colon |
| 5 Superior mesenteric artery | | 15 Left spermatic vein | |
| 6 Ureter | | | |



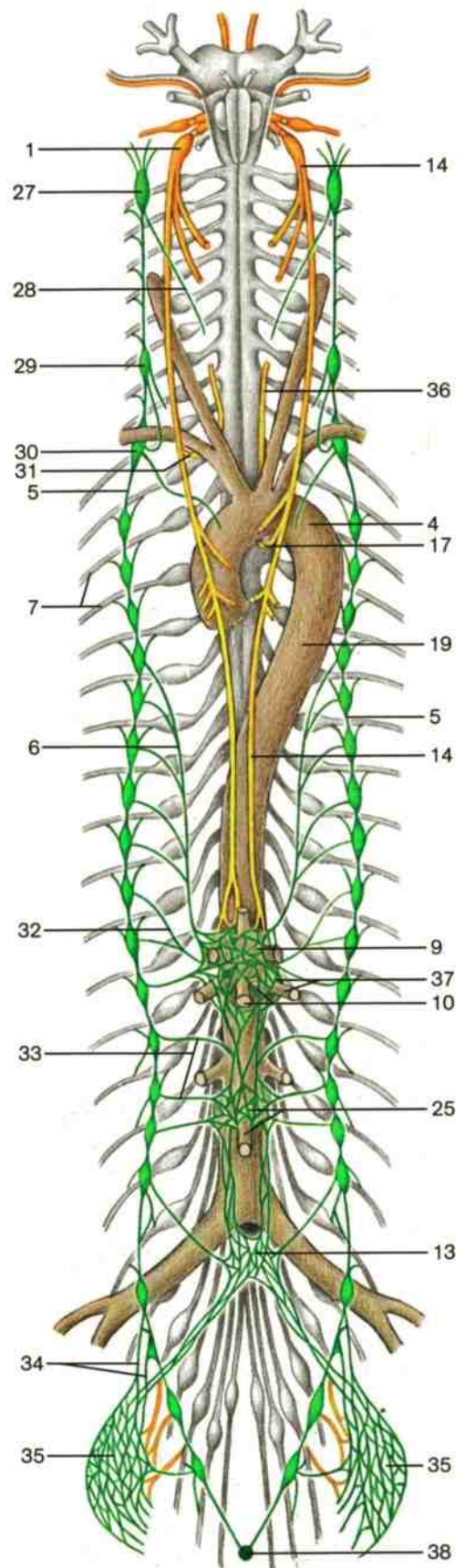
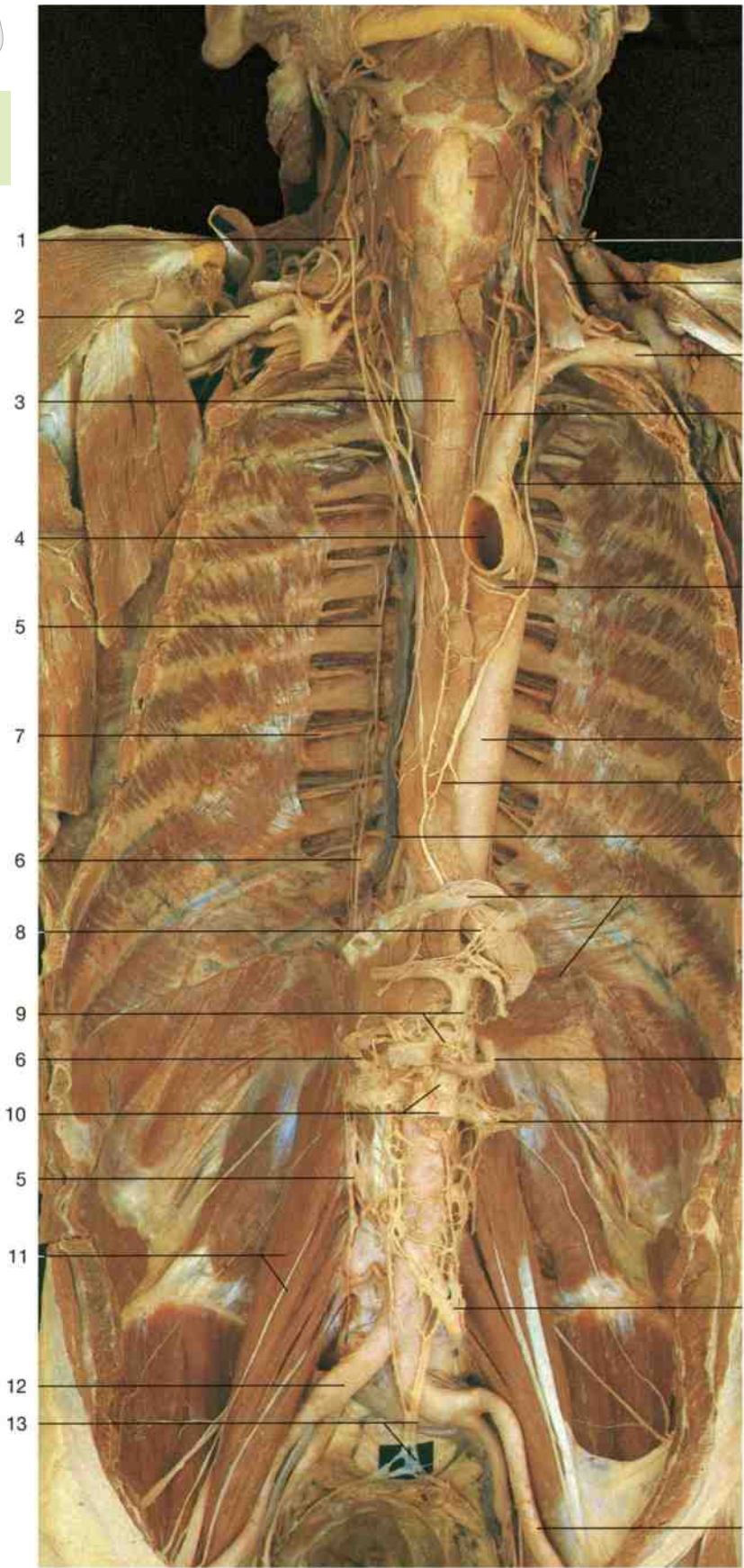
Lymph vessels and lymph nodes of the posterior wall of thoracic and abdominal cavities (anterior aspect). Green = lymph vessels and nodes; blue = veins; red = arteries; white = nerves.

- | | | | |
|---|--|--|-----------------------|
| 1 Internal jugular vein | 9 Diaphragm | 18 Internal jugular vein | 27 Left renal artery |
| 2 Right common carotid artery and right vagus nerve | 10 Right kidney | 19 Deep cervical lymph nodes | 28 Left kidney |
| 3 Jugulo-omohyoid lymph node | 11 Right lumbar trunk | 20 Thoracic duct entering left jugular angle | 29 Cisterna chyli |
| 4 Right lymphatic duct | 12 Right ureter | 21 Left subclavian vein | 30 Lumbar lymph nodes |
| 5 Subclavian trunk | 13 Common iliac lymph nodes | 22 Left brachiocephalic vein | 31 Abdominal aorta |
| 6 Right subclavian vein | 14 Right internal iliac artery | 23 Thoracic duct | 32 Left ureter |
| 7 Bronchomediastinal trunk | 15 External iliac lymph nodes | 24 Mediastinal lymph nodes | 33 Sacral lymph nodes |
| 8 Azygos vein | 16 Right external iliac artery | 25 Thoracic aorta | 34 Rectum (cut edge) |
| | 17 Left common carotid artery and left vagus nerve | 26 Left suprarenal gland | |



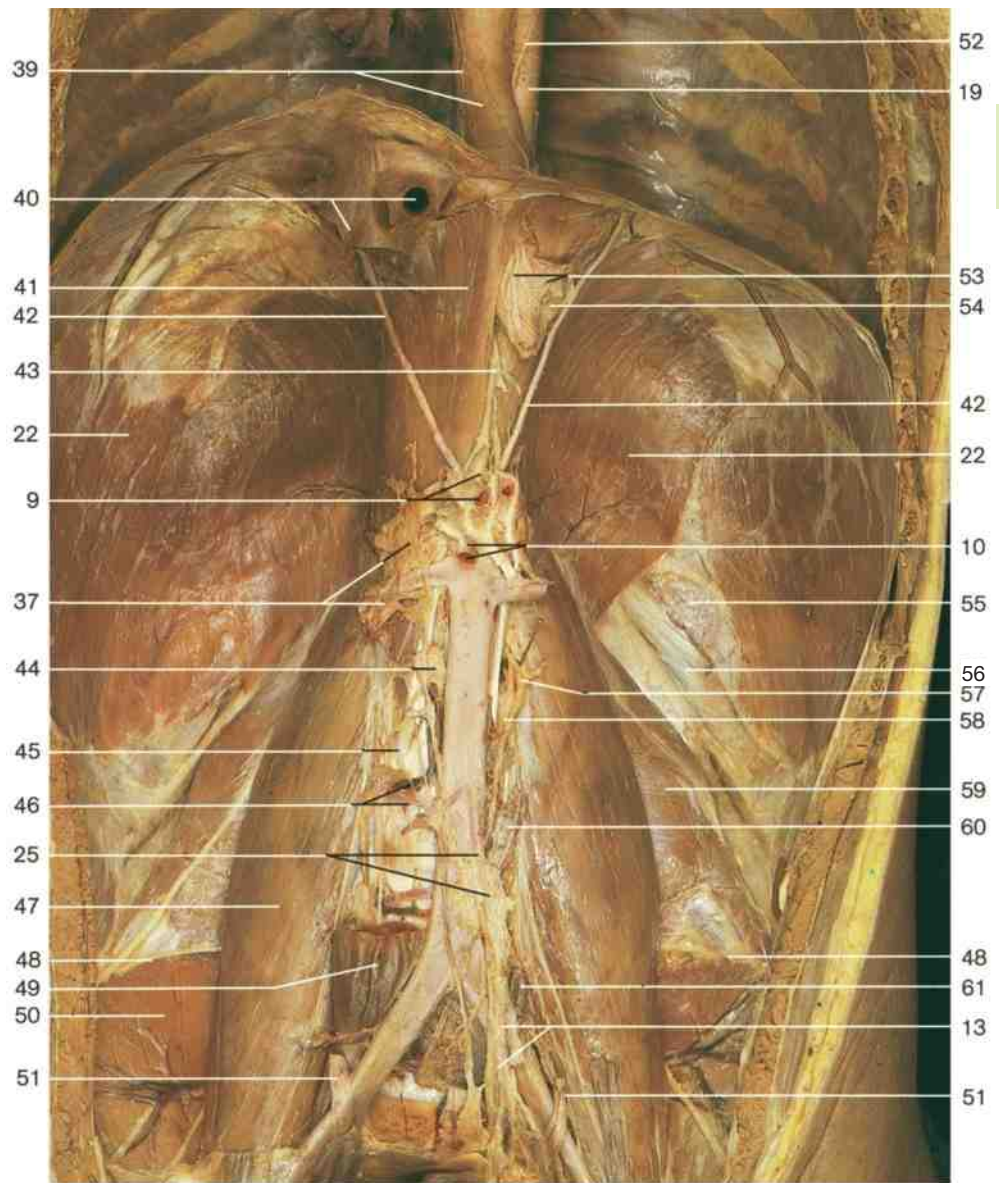
Vessels and nerves of posterior abdominal wall (anterior aspect). Part of the left psoas major muscle has been removed to display the lumbar plexus. Red = arteries; blue = veins.

- | | | | |
|---|---|---------------------------------|---|
| 1 Diaphragm | 11 Common iliac artery | 20 Splenic artery | 31 Psoas major muscle (divided) with supplying artery |
| 2 Hepatic veins | 12 Iliacus muscle | 21 Celiac trunk | 32 Rectum (cut) |
| 3 Inferior vena cava | 13 Right ureter (divided) | 22 Superior mesenteric artery | 33 Urinary bladder |
| 4 Inferior phrenic artery | 14 Lateral femoral cutaneous nerve | 23 Left renal artery | |
| 5 Right renal vein | 15 Internal iliac artery | 24 Ilio-inguinal nerve | |
| 6 Iliohypogastric nerve | 16 Femoral nerve | 25 Sympathetic trunk | |
| 7 Quadratus lumborum muscle | 17 External iliac artery | 26 Transversus abdominis muscle | |
| 8 Subcostal nerve | 18 Inferior epigastric artery | 27 Iliac crest | |
| 9 Inferior mesenteric artery | 19 Cardiac part of stomach and esophageal branches of left gastric artery | 28 Left genitofemoral nerve | |
| 10 Right genitofemoral nerve and psoas major muscle | | 29 Left obturator nerve | |
| | | 30 Median sacral artery | |



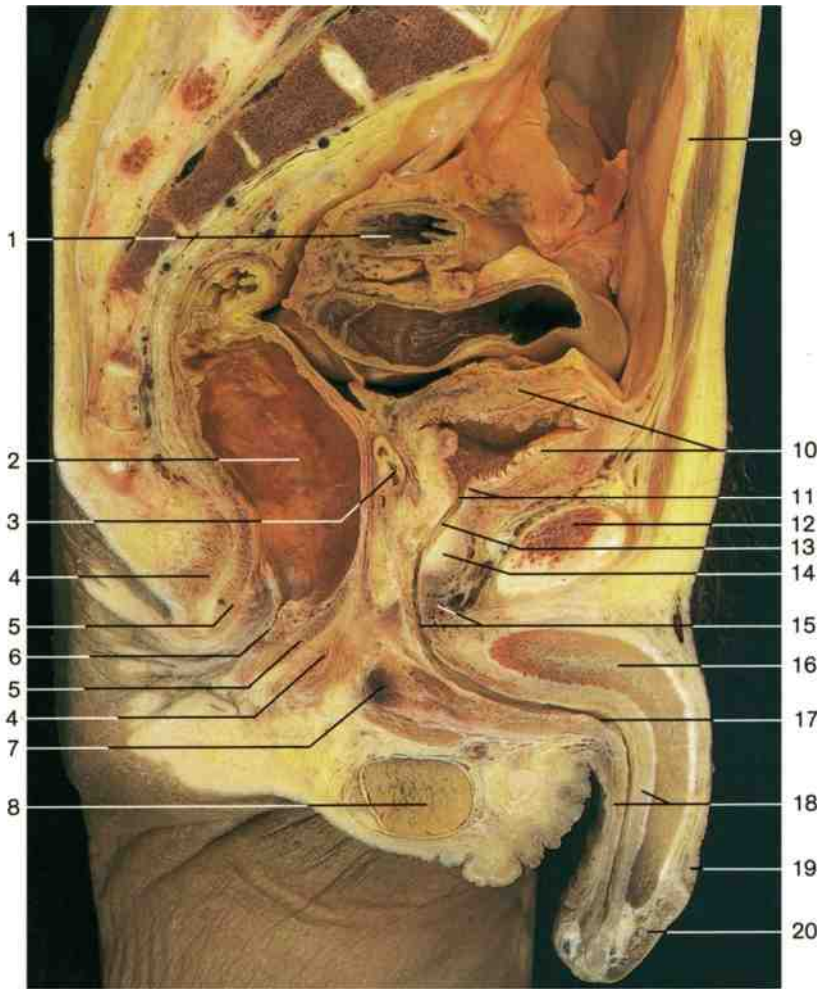
Posterior wall of thoracic and abdominal cavities with sympathetic trunk, vagus nerve, and autonomic ganglia (anterior aspect). Thoracic and abdominal organs removed, except for the esophagus and aorta.

Organization of autonomic nervous system (after Mattuschka). (Schematic drawing.) Yellow = parasympathetic nerves; green = sympathetic nerves.



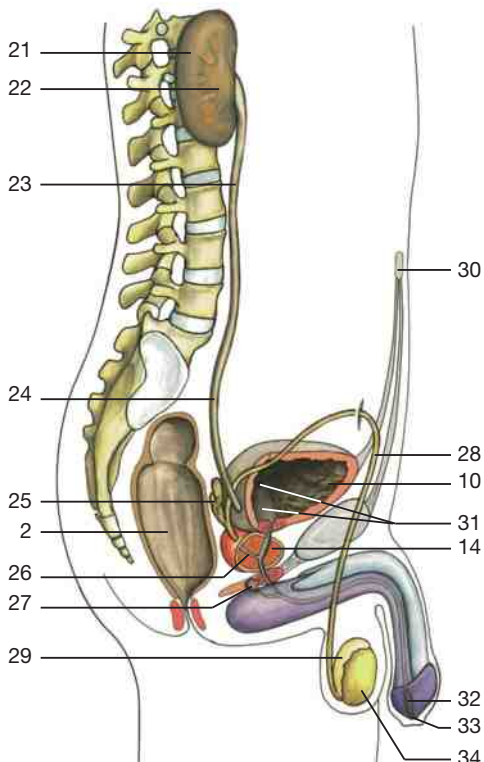
Ganglia and plexus of the autonomic nervous system within the retroperitoneal space (anterior aspect). The kidneys and the inferior vena cava with its tributaries have been removed.

- | | | | |
|---|--|---|--|
| 1 Right vagus nerve | 16 Left subclavian artery | 31 Right recurrent laryngeal nerve | 46 Lumbar artery and vein |
| 2 Right subclavian artery | 17 Left recurrent laryngeal nerve | 32 Lesser splanchnic nerve | 47 Psoas major muscle |
| 3 Esophagus | 18 Inferior cervical cardiac nerve | 33 Lumbar splanchnic nerves | 48 Iliac crest |
| 4 Aortic arch | 19 Thoracic aorta | 34 Sacral splanchnic nerves | 49 Inferior vena cava |
| 5 Sympathetic trunk | 20 Esophageal plexus | 35 Inferior hypogastric ganglion and plexus | 50 Iliacus muscle |
| 6 Greater splanchnic nerve | 21 Azygos vein | 36 Left recurrent laryngeal nerve | 51 Ureter |
| 7 Intercostal nerve | 22 Diaphragm | 37 Aorticorenal plexus and renal artery | 52 Left vagus nerve forming the esophageal plexus |
| 8 Abdominal part of esophagus and vagal trunk | 23 Splenic artery | 38 Ganglion impar | 53 Left vagus nerve forming the gastric plexus |
| 9 Celiac trunk with celiac ganglion | 24 Left renal artery and plexus | 39 Esophagus with branches of vagus nerve | 54 Esophagus continuing into the cardiac part of stomach |
| 10 Superior mesenteric artery and ganglion | 25 Inferior mesenteric ganglion and artery | 40 Hepatic veins | 55 Lumbo-costal triangle |
| 11 Psoas major muscle and genitofemoral nerve | 26 Left external iliac artery | 41 Right crus of diaphragm | 56 Position of twelfth rib |
| 12 Common iliac artery | 27 Superior cervical ganglion of sympathetic trunk | 42 Inferior phrenic artery | 57 Left lumbar lymph trunk |
| 13 Superior hypogastric plexus and ganglion | 28 Superior cardiac branch of sympathetic trunk | 43 Right vagus nerve entering the celiac ganglion | 58 Ganglion of sympathetic trunk |
| 14 Left vagus nerve | 29 Middle cervical ganglion of sympathetic trunk | 44 Right lumbar lymph trunk | 59 Quadratus lumborum muscle |
| 15 Brachial plexus | 30 Inferior cervical ganglion of sympathetic trunk | 45 Lumbar part of right sympathetic trunk | 60 Lumbar part of left sympathetic trunk |
| | | | 61 Iliac lymph vessels |



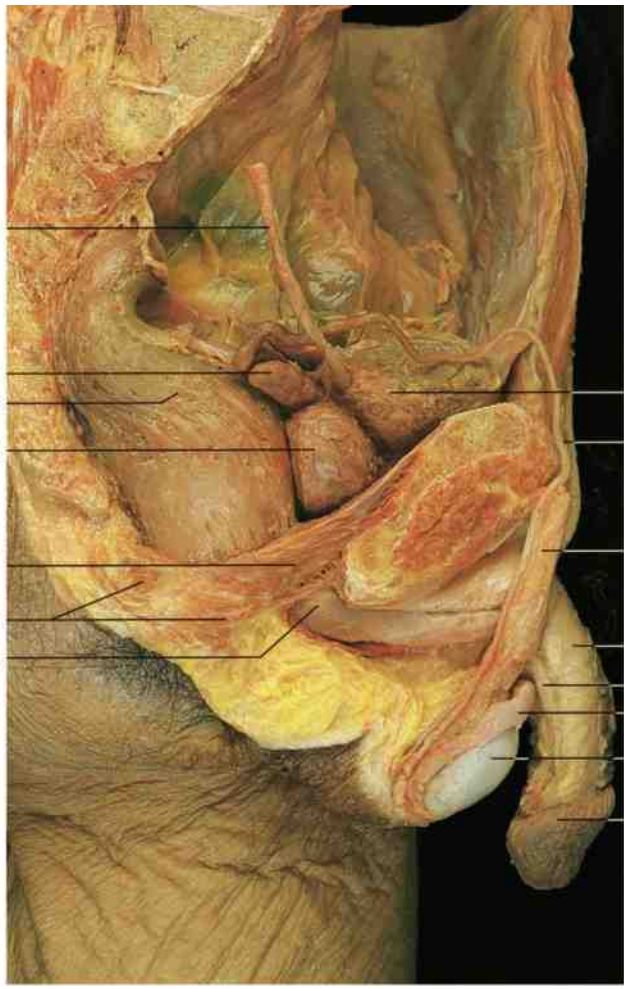
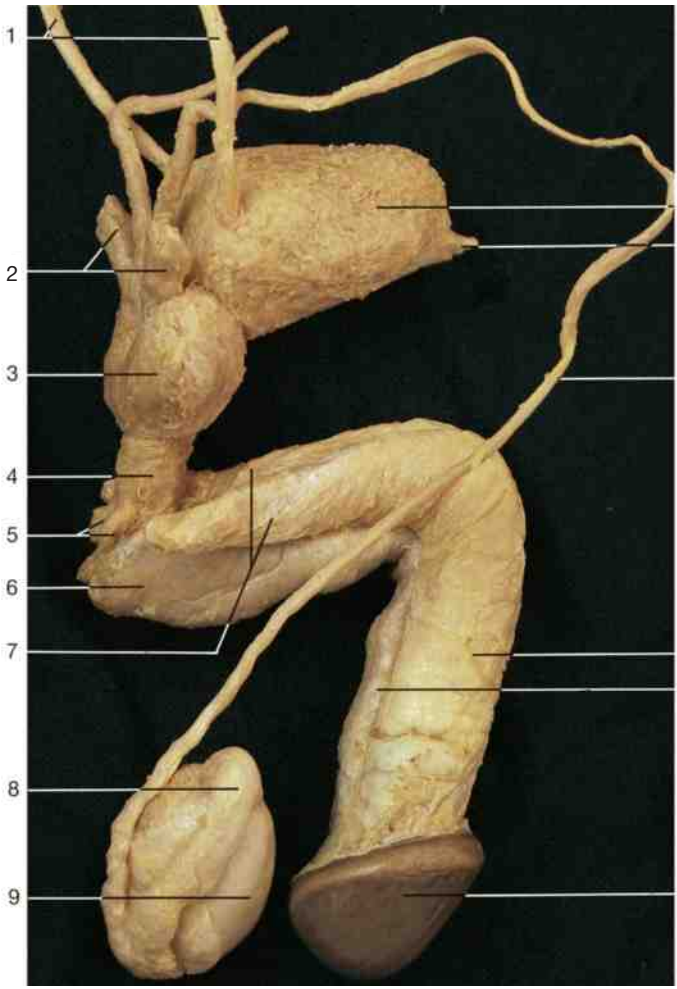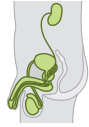- 1 Sigmoid colon
- 2 Ampulla of rectum
- 3 Ampulla of ductus deferens
- 4 External anal sphincter muscle
- 5 Internal anal sphincter muscle
- 6 Anal canal
- 7 Bulb of penis
- 8 Testis (cut surface)
- 9 Median umbilical ligament
- 10 Urinary bladder
- 11 Internal urethral orifice and sphincter
- 12 Pubic symphysis
- 13 Prostatic part of urethra
- 14 Prostate gland
- 15 Membranous part of urethra and external urethral sphincter
- 16 Corpus cavernosum of penis
- 17 Spongy urethra
- 18 Corpus spongiosum of penis
- 19 Foreskin or prepuce
- 20 Glans penis
- 21 Kidney
- 22 Renal pelvis
- 23 Abdominal part of ureter
- 24 Pelvic part of ureter
- 25 Seminal vesicle
- 26 Ejaculatory duct
- 27 Bulbo-urethral or Cowper's gland
- 28 Ductus deferens
- 29 Epididymis
- 30 Umbilicus
- 31 Trigone of bladder and ureteric orifice
- 32 Navicular fossa of urethra
- 33 External urethral orifice
- 34 Testis

Male urogenital system, midsagittal section through the pelvis.



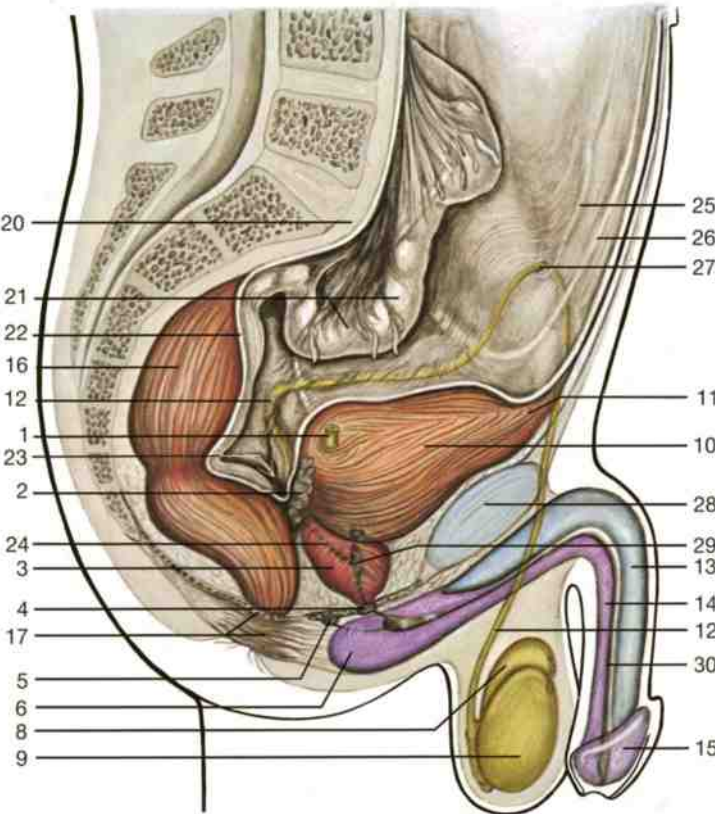
Male urogenital system (schematic drawing).

The **prostate** is located between the bladder and urogenital diaphragm. The penis includes the **urethra** and thus serves for both ejaculation and micturition. The internal (involuntary) and external (voluntary) urethral sphincters are widely separated. The **ureter**, having crossed the ductus deferens, enters the urinary bladder at its base. The peritoneum is reflected off of the posterior surface of the bladder and onto the rectum, thus forming the rectovesical pouch.



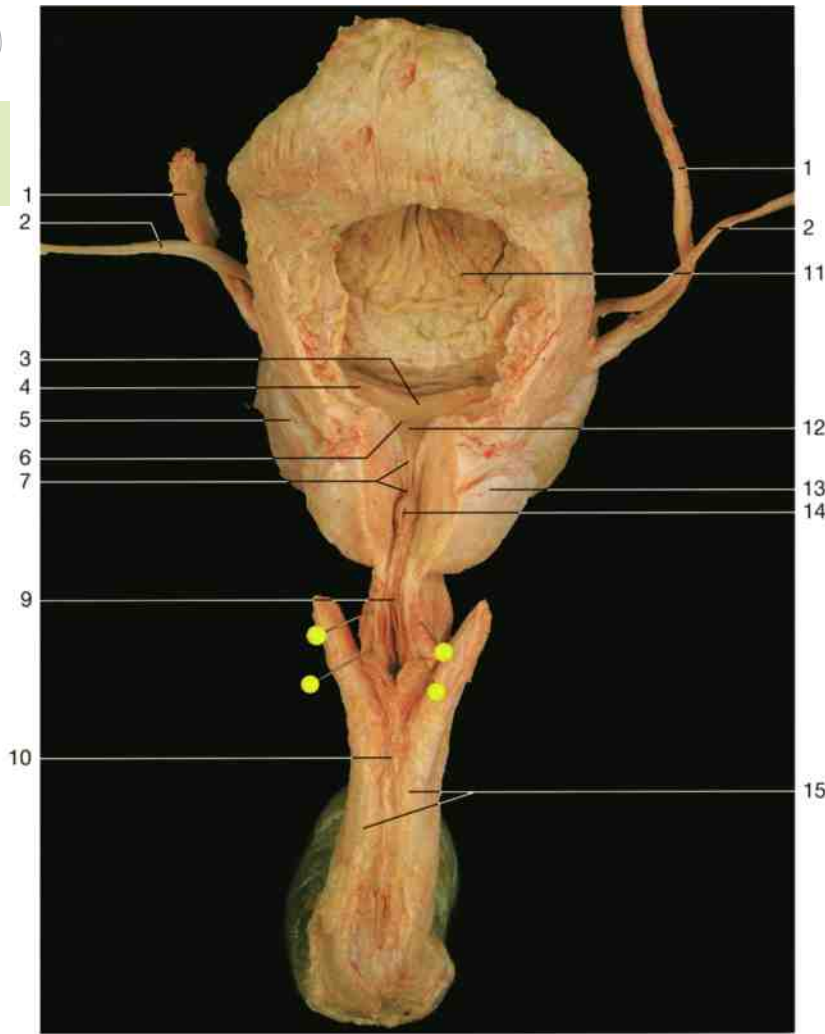
Male genital organs, isolated (right lateral aspect).

Male genital organs in situ (right lateral aspect).



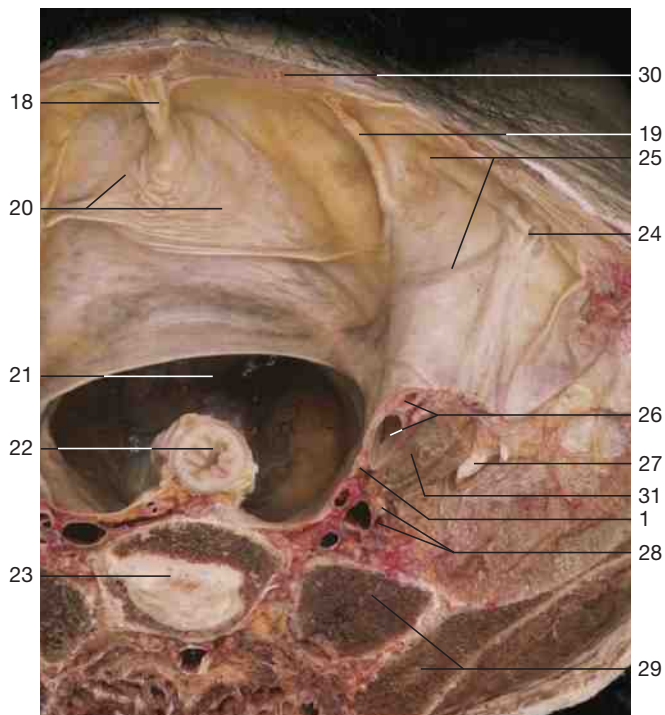
Positions of male genital organs (right lateral aspect). (Schematic drawing.)

- 1 Ureter
- 2 Seminal vesicle
- 3 Prostate gland
- 4 Urogenital diaphragm and membranous part of urethra
- 5 Bulbo-urethral or Cowper's gland
- 6 Bulb of penis
- 7 Left and right crus penis
- 8 Epididymis
- 9 Testis
- 10 Urinary bladder
- 11 Apex of urinary bladder
- 12 Ductus deferens
- 13 Corpus cavernosum of penis
- 14 Corpus spongiosum of penis
- 15 Glans penis
- 16 Ampulla of rectum
- 17 Levator ani muscle
- 18 Anal canal and external anal sphincter muscle
- 19 Spermatic cord (cut)
- 20 Sacral promontory
- 21 Sigmoid colon
- 22 Peritoneum (cut edge)
- 23 Rectovesical pouch
- 24 Ejaculatory duct
- 25 Lateral umbilical fold
- 26 Medial umbilical fold
- 27 Deep inguinal ring and ductus deferens
- 28 Pubic symphysis
- 29 Prostatic part of urethra
- 30 Spongy urethra

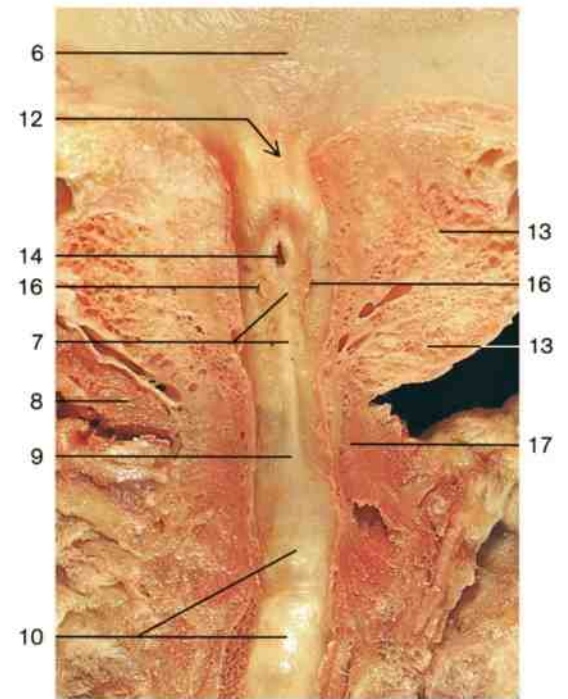


- 1 Ureter
- 2 Ductus deferens
- 3 Interureteric fold
- 4 Ureteric orifice
- 5 Seminal vesicle
- 6 Trigone of bladder
- 7 Prostatic urethra with seminal colliculus and urethral crest
- 8 Deep transverse perineal muscle
- 9 Membranous urethra
- 10 Spongy urethra
- 11 Mucous membrane of urinary bladder
- 12 Internal urethral orifice and uvula of bladder
- 13 Prostate
- 14 Prostatic utricle
- 15 Right and left corpus cavernosum of penis
- 16 Ejaculatory duct
- 17 Sphincter urethrae muscle
- 18 Median umbilical fold with remnant of urachus
- 19 Medial umbilical fold with remnant of umbilical artery
- 20 Urinary bladder
- 21 Rectovesical pouch
- 22 Rectum
- 23 Sacrum
- 24 Deep iliac circumflex artery
- 25 Deep inguinal ring and ductus deferens
- 26 External iliac artery and vein
- 27 Femoral nerve
- 28 Obturator nerve and internal iliac artery
- 29 Ilium and sacrum
- 30 Inferior epigastric artery
- 31 Iliopsoas muscle

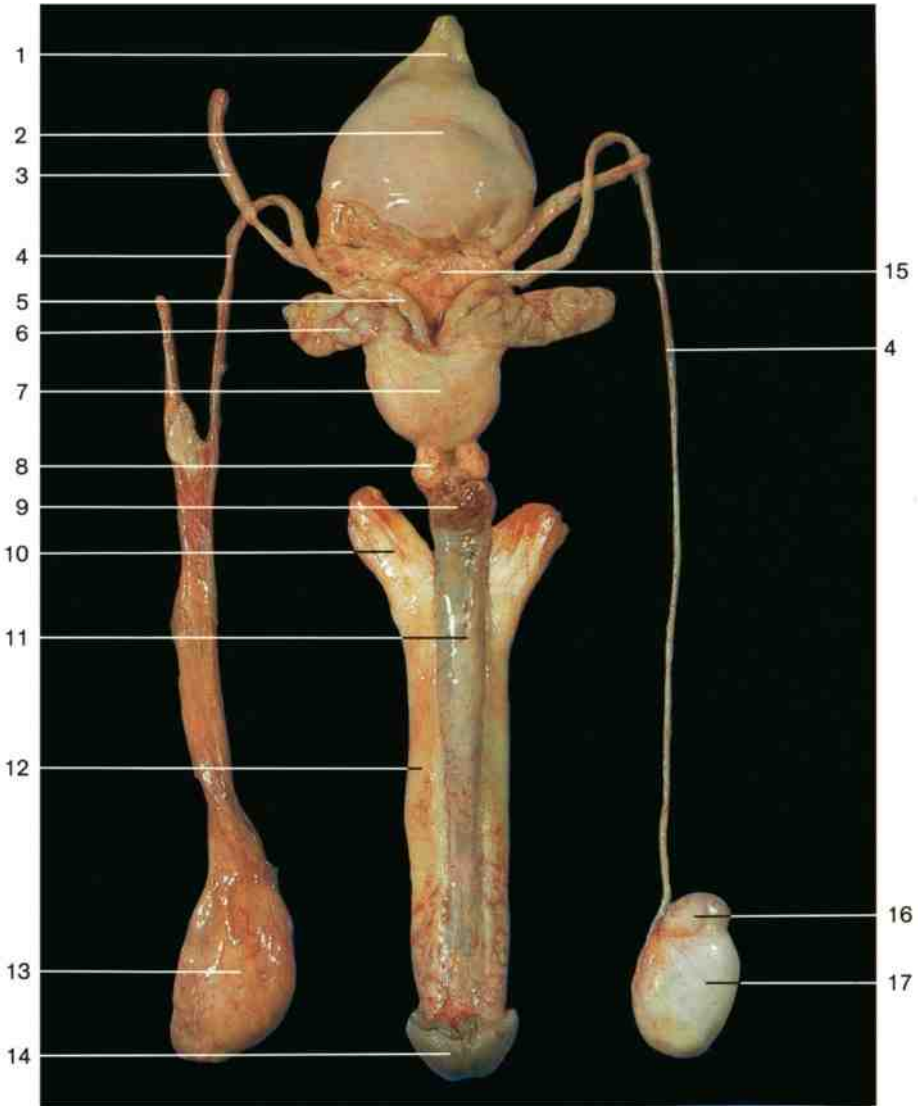
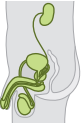Male urogenital organs, isolated (anterior aspect). Urinary bladder, prostate, and urethra have been opened. The urinary bladder is contracted.



Pelvic cavity in the male (viewed from above).

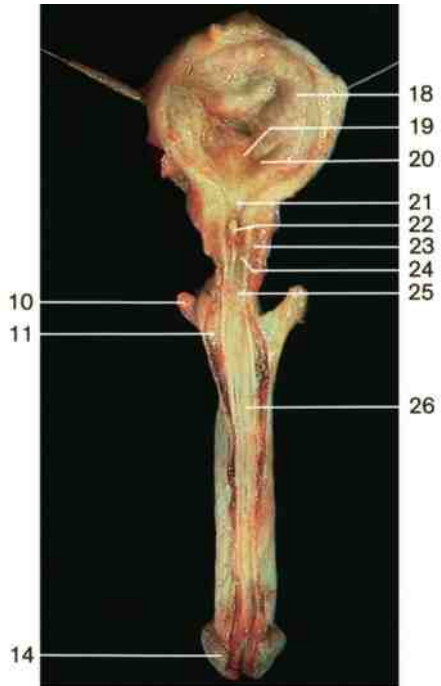


Posterior half of male urethra and prostate in continuity with neck of bladder (anterior aspect).

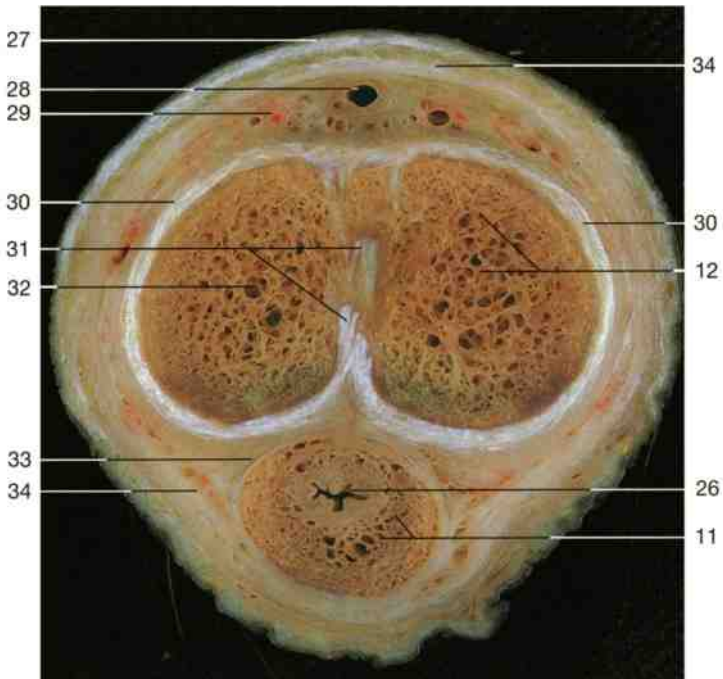


- 1 Apex of urinary bladder with urachus
- 2 Urinary bladder
- 3 Ureter
- 4 Ductus deferens
- 5 Ampulla of ductus deferens
- 6 Seminal vesicle
- 7 Prostate
- 8 Bulbo-urethral or Cowper's gland
- 9 Bulb of penis
- 10 Crus penis
- 11 Corpus spongiosum of penis
- 12 Corpus cavernosum of penis
- 13 Testis and epididymis with coverings
- 14 Glans penis
- 15 Fundus of bladder
- 16 Head of epididymis
- 17 Testis
- 18 Mucous membrane of bladder
- 19 Trigone of bladder
- 20 Ureteric orifice
- 21 Internal urethral orifice
- 22 Seminal colliculus
- 23 Prostate
- 24 Prostatic urethra
- 25 Membranous urethra
- 26 Spongy (penile) urethra
- 27 Skin of penis
- 28 Deep dorsal vein of penis (unpaired)
- 29 Dorsal artery of penis (paired)
- 30 Tunica albuginea of corpora cavernosa
- 31 Septum of penis
- 32 Deep artery of penis
- 33 Tunica albuginea of corpus spongiosum
- 34 Deep fascia of penis

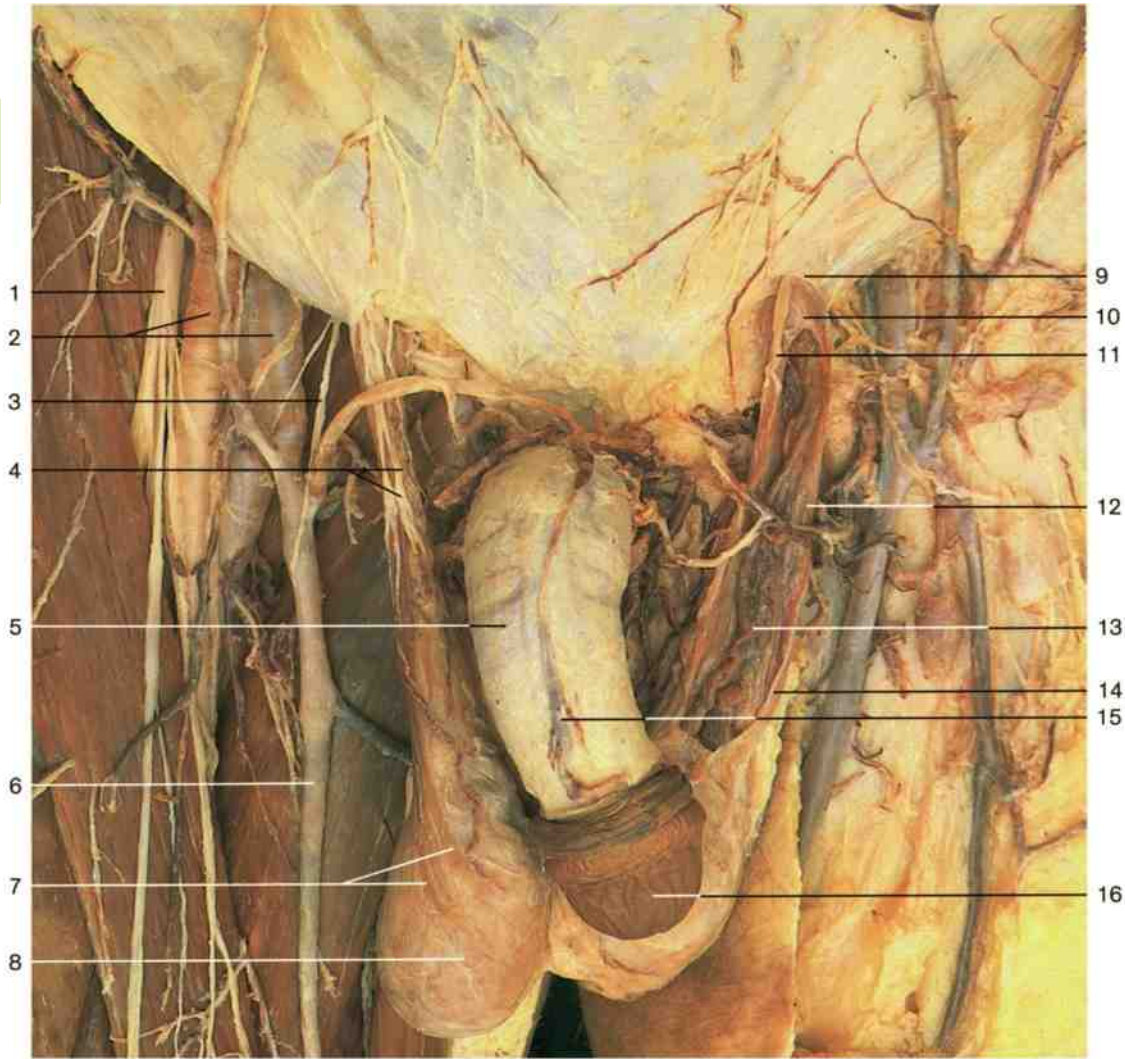
Male genital organs, isolated (posterior aspect).



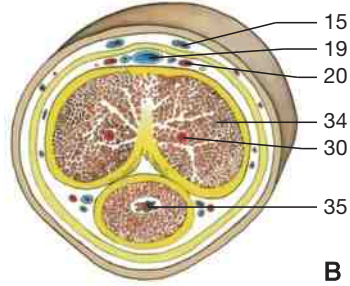
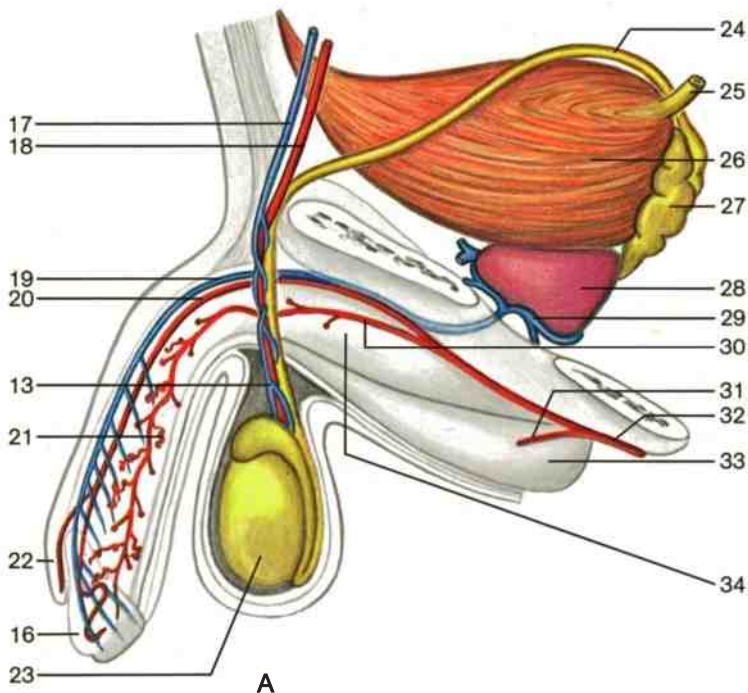
Urinary bladder, urethra, and penis (anterior aspect, opened longitudinally).



Cross section of penis (inferior aspect).

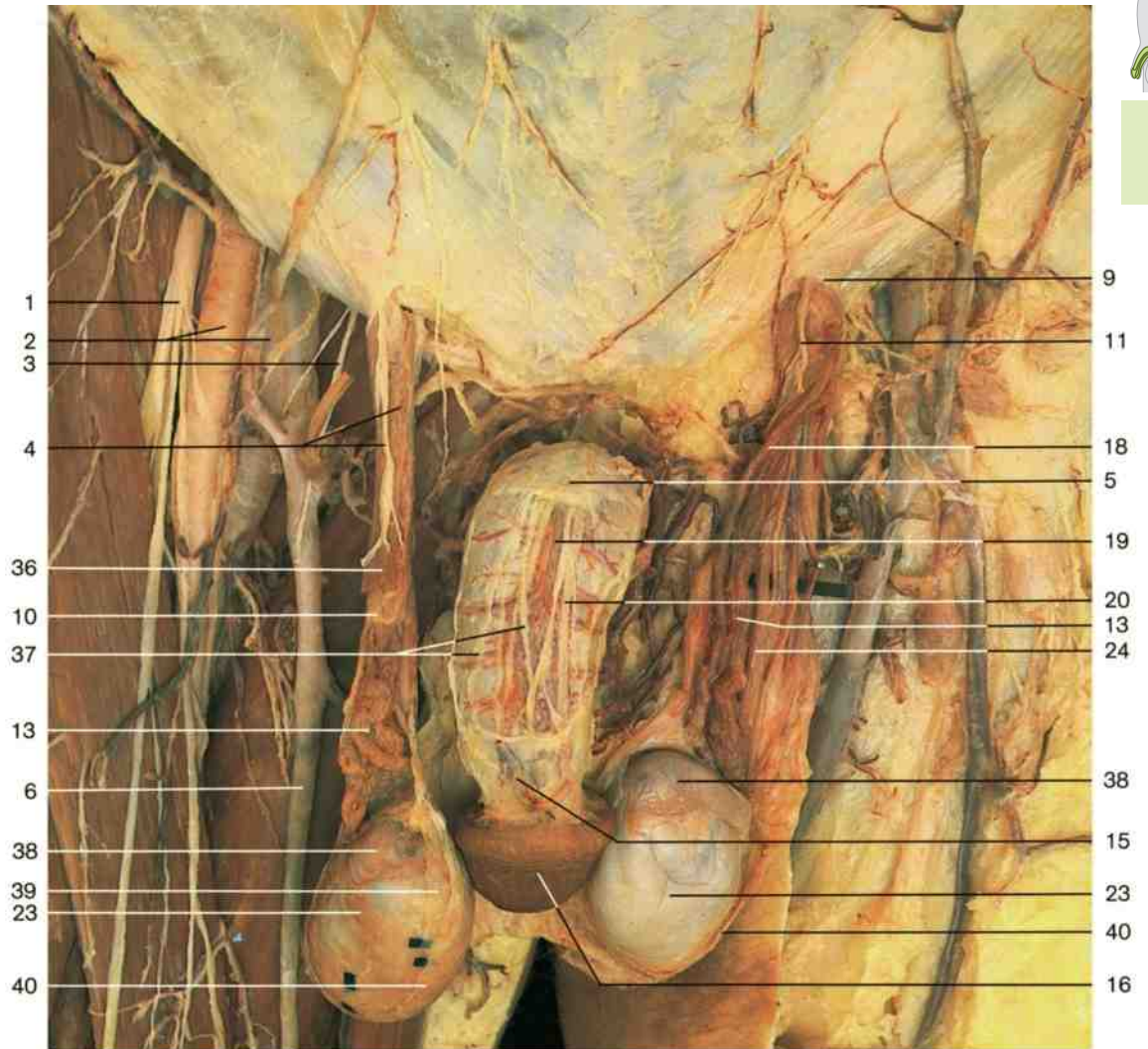


Male external genital organs with penis, testis, and spermatic cord, superficial layers (anterior aspect).



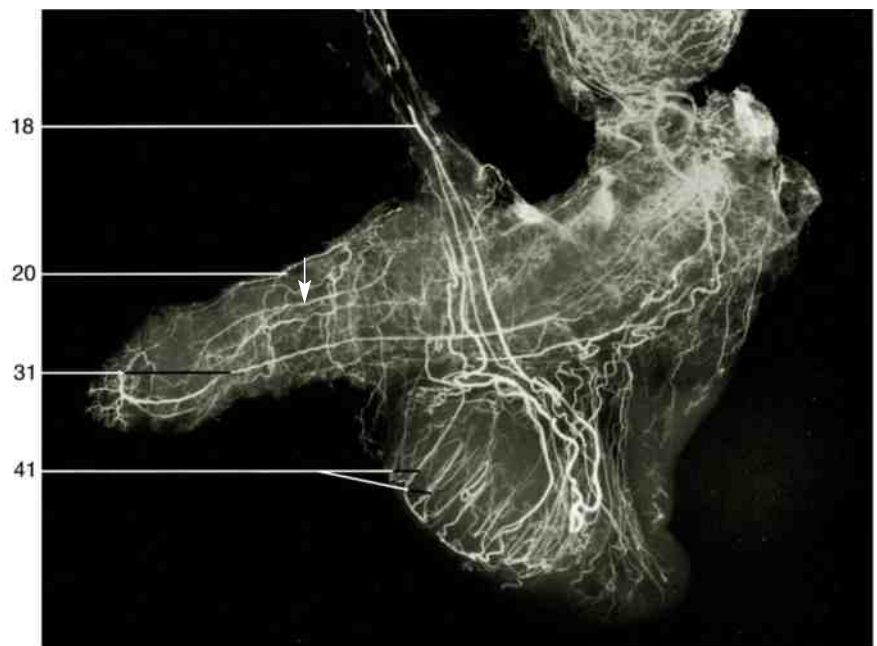
Vessels of male genital organs (schematic drawing).
A = lateral aspect; B = cross section of penis.

- 1 Femoral nerve
- 2 Femoral artery and vein
- 3 Femoral branch of genitofemoral nerve
- 4 Spermatic cord with genital branch of genitofemoral nerve
- 5 Penis with deep fascia
- 6 Great saphenous vein
- 7 Cremaster muscle
- 8 Testis with cremaster muscle
- 9 Superficial inguinal ring
- 10 Internal spermatic fascia (cut edge)
- 11 Ilio-inguinal nerve
- 12 Left spermatic cord
- 13 Pampiniform venous plexus
- 14 External spermatic fascia
- 15 Superficial dorsal vein of penis

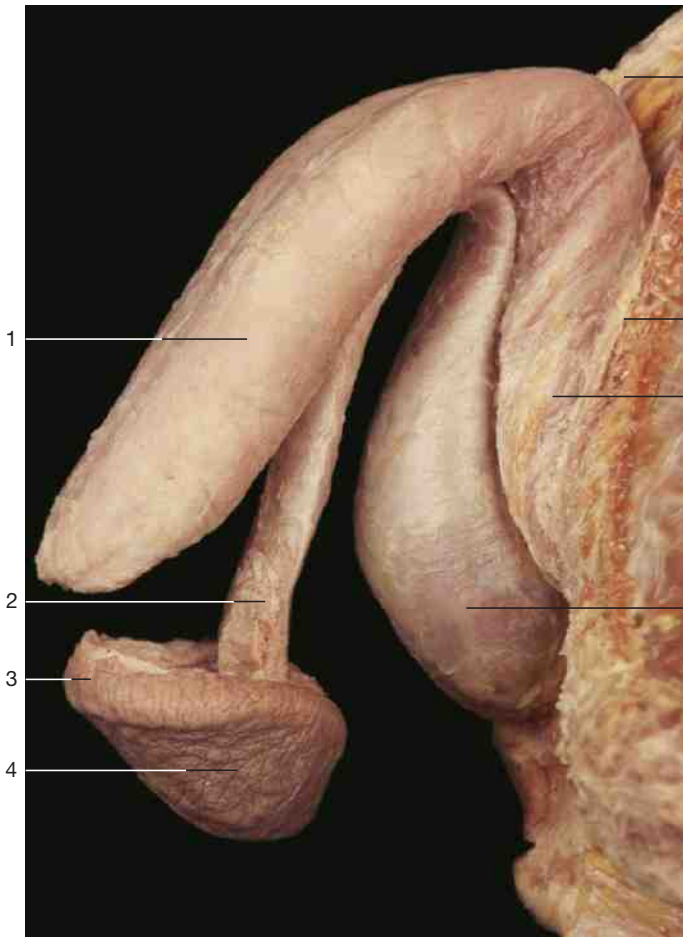


Male external genital organs with penis, testis, and spermatic cord, deeper layers (anterior aspect). The deep fascia of the penis has been opened to display the dorsal nerves and vessels.

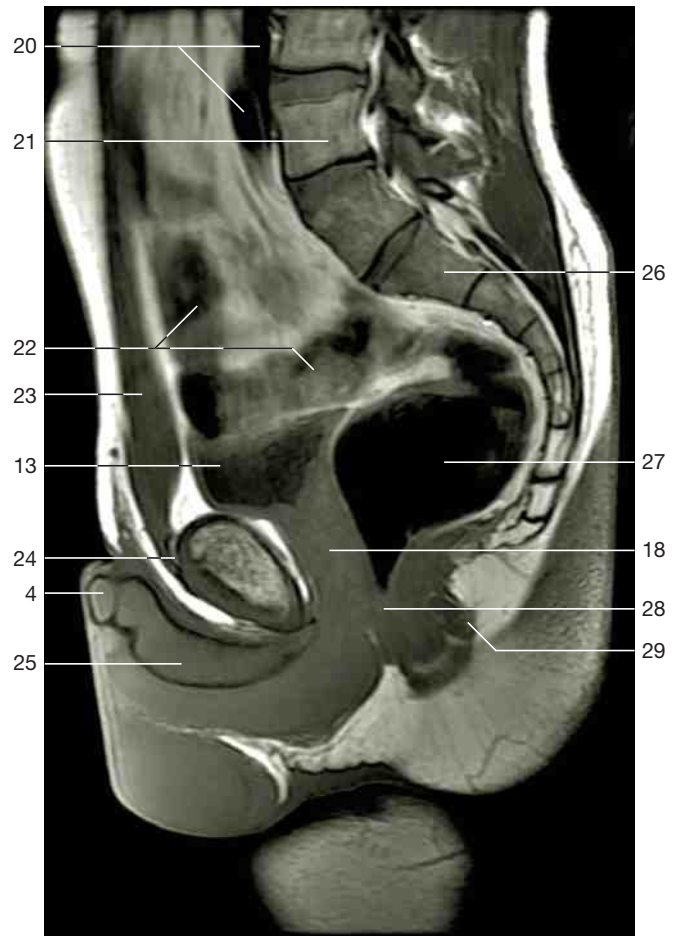- 16 Glans penis
- 17 Testicular vein
- 18 Testicular artery
- 19 Deep dorsal vein of penis
- 20 Dorsal artery of penis
- 21 Helicine arteries
- 22 Prepuce
- 23 Testis with tunica albuginea
- 24 Ductus deferens
- 25 Ureter
- 26 Urinary bladder
- 27 Seminal vesicle
- 28 Prostate
- 29 Vesicoprostatic venous plexus
- 30 Deep artery of penis
- 31 Artery of bulb of penis
- 32 Internal pudendal artery
- 33 Corpus spongiosum of penis
- 34 Corpus cavernosum of penis
- 35 Urethra
- 36 Cremasteric fascia with cremaster muscle
- 37 Dorsal nerve of penis
- 38 Epididymis
- 39 Tunica vaginalis (visceral layer)
- 40 Tunica vaginalis (parietal layer)
- 41 Testis with vascular loops



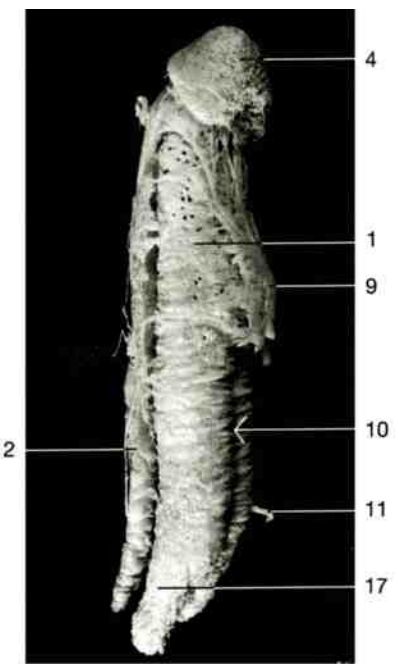
Male genital organs (arteriography, lateral aspect). Arrow = helicine artery.



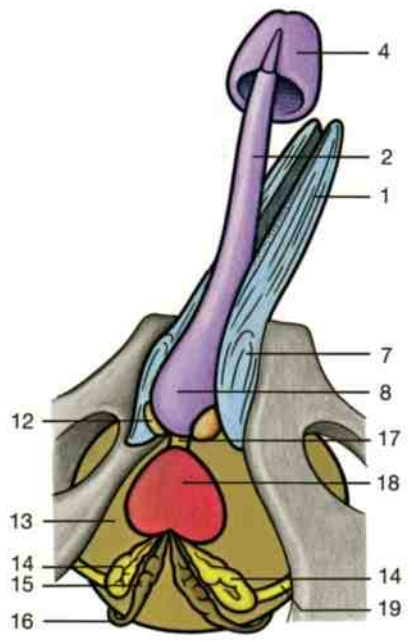
Male external genital organs (lateral aspect). The corpus spongiosum of the penis with the glans penis has been isolated and reflected.



Sagittal section of the pelvic cavity with the male genital organs (MRI scan; from Heuck et al., MRT-Atlas, 2009).

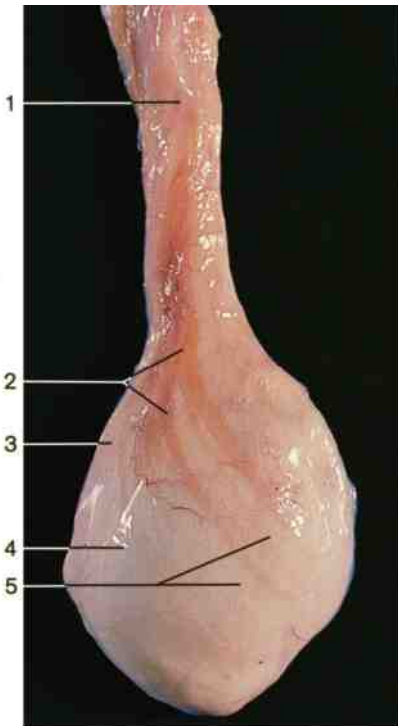


Resin cast of erected penis.



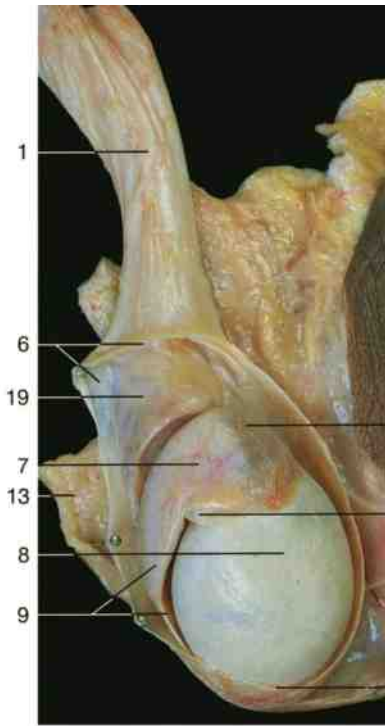
Male external genital organs and accessory glands (schematic drawing).

- 1 Corpus cavernosum of penis
- 2 Corpus spongiosum of penis
- 3 Corona of glans penis
- 4 Glans penis
- 5 Suspensory ligament of penis
- 6 Inferior pubic ramus
- 7 Crus penis
- 8 Bulb of penis
- 9 Deep dorsal vein of penis
- 10 Septum pectiniforme
- 11 Dorsal artery of penis
- 12 Bulbo-urethral or Cowper's gland
- 13 Urinary bladder
- 14 Seminal vesicle
- 15 Ampulla of ductus deferens
- 16 Ductus deferens
- 17 Membranous urethra
- 18 Prostate
- 19 Ureter
- 20 Common iliac artery and vein
- 21 Fifth lumbar vertebral body
- 22 Intestinal loops
- 23 Rectus abdominis muscle
- 24 Pubic symphysis
- 25 Root of penis
- 26 Sacral bone
- 27 Ampulla of rectum
- 28 Anal canal
- 29 External anal sphincter muscle



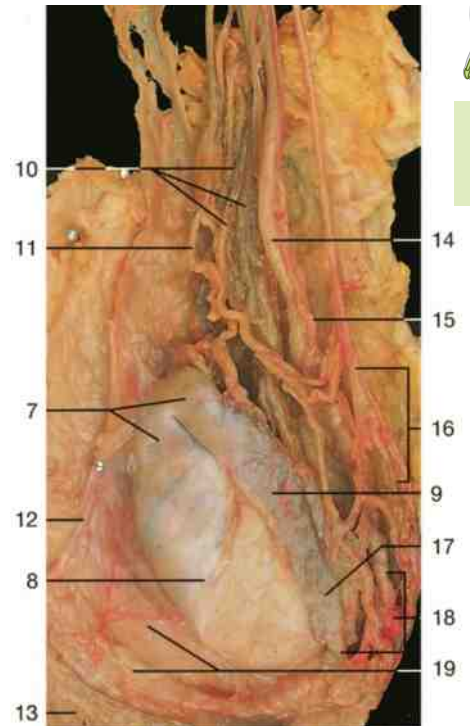
Testis and epididymis with investing layers (lateral aspect).

- 1 Spermatic cord covered with cremasteric fascia
- 2 Cremaster muscle
- 3 Position of epididymis
- 4 Internal spermatic fascia
- 5 Position of testis
- 6 Internal spermatic fascia with adjacent investing layers of testis (cut surface)
- 7 Head of epididymis



Testis and epididymis (lateral aspect). The tunica vaginalis has been opened.

- 8 Testis with tunica vaginalis (visceral layer)
- 9 Body of epididymis
- 10 Pampiniform venous plexus (anterior veins)
- 11 Testicular artery
- 12 Tunica vaginalis (parietal layer, cut edge)
- 13 Skin and dartos muscle (reflected)

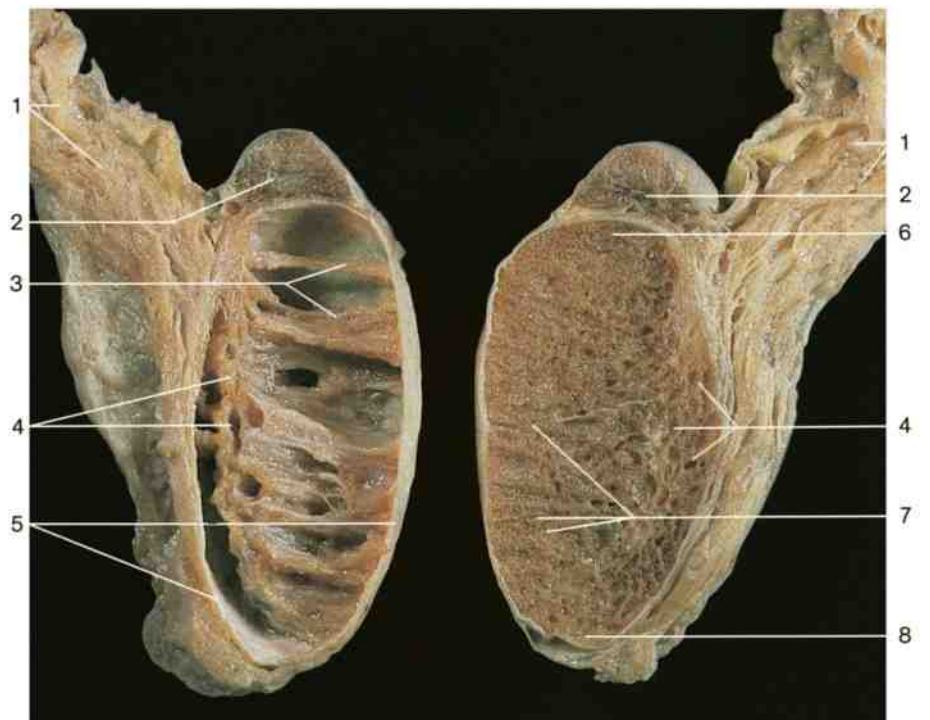


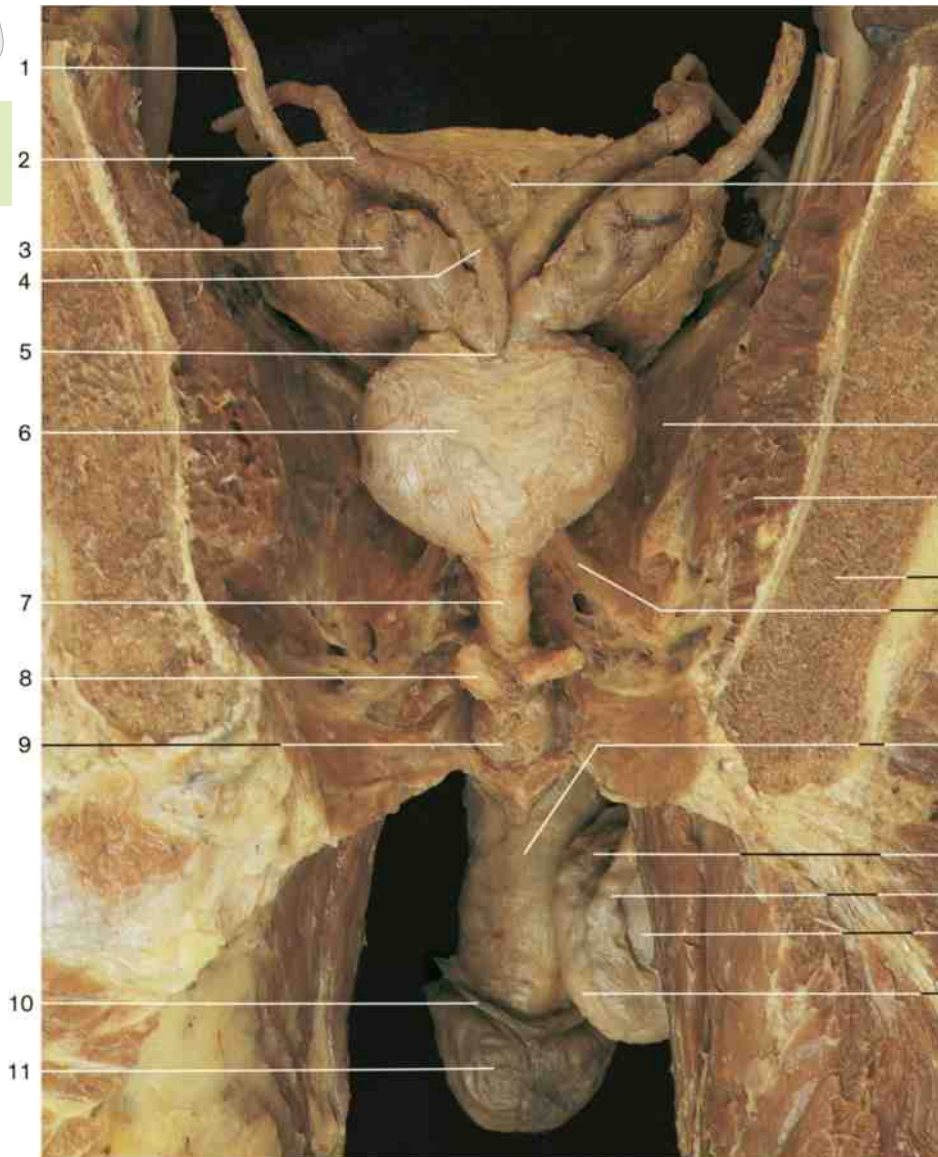
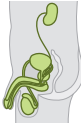Testis, epididymis, and spermatic cord (left side, posterolateral aspect). Dissection of spermatic cord and ductus deferens.

- 15 Artery of ductus deferens
- 16 Posterior veins of pampiniform plexus
- 17 Tail of epididymis
- 18 Transition of epididymal duct to ductus deferens and venous plexus
- 19 Parietal layer of tunica vaginalis
- 20 Appendix of epididymis
- 21 Appendix of testis
- 22 Gubernaculum testis

Longitudinal section through testis and epididymis. The left figure shows the testicular septa after removal of the seminiferous tubules.

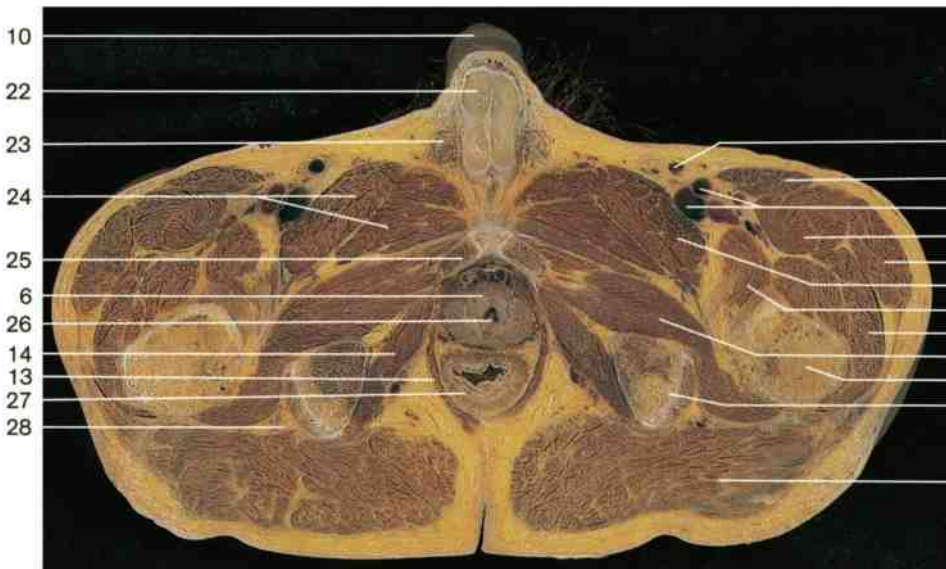- 1 Spermatic cord (cut surface)
- 2 Head of epididymis (cut surface)
- 3 Septa of testis
- 4 Mediastinum testis
- 5 Tunica albuginea
- 6 Superior pole of testis
- 7 Convoluted seminiferous tubules
- 8 Inferior pole of testis



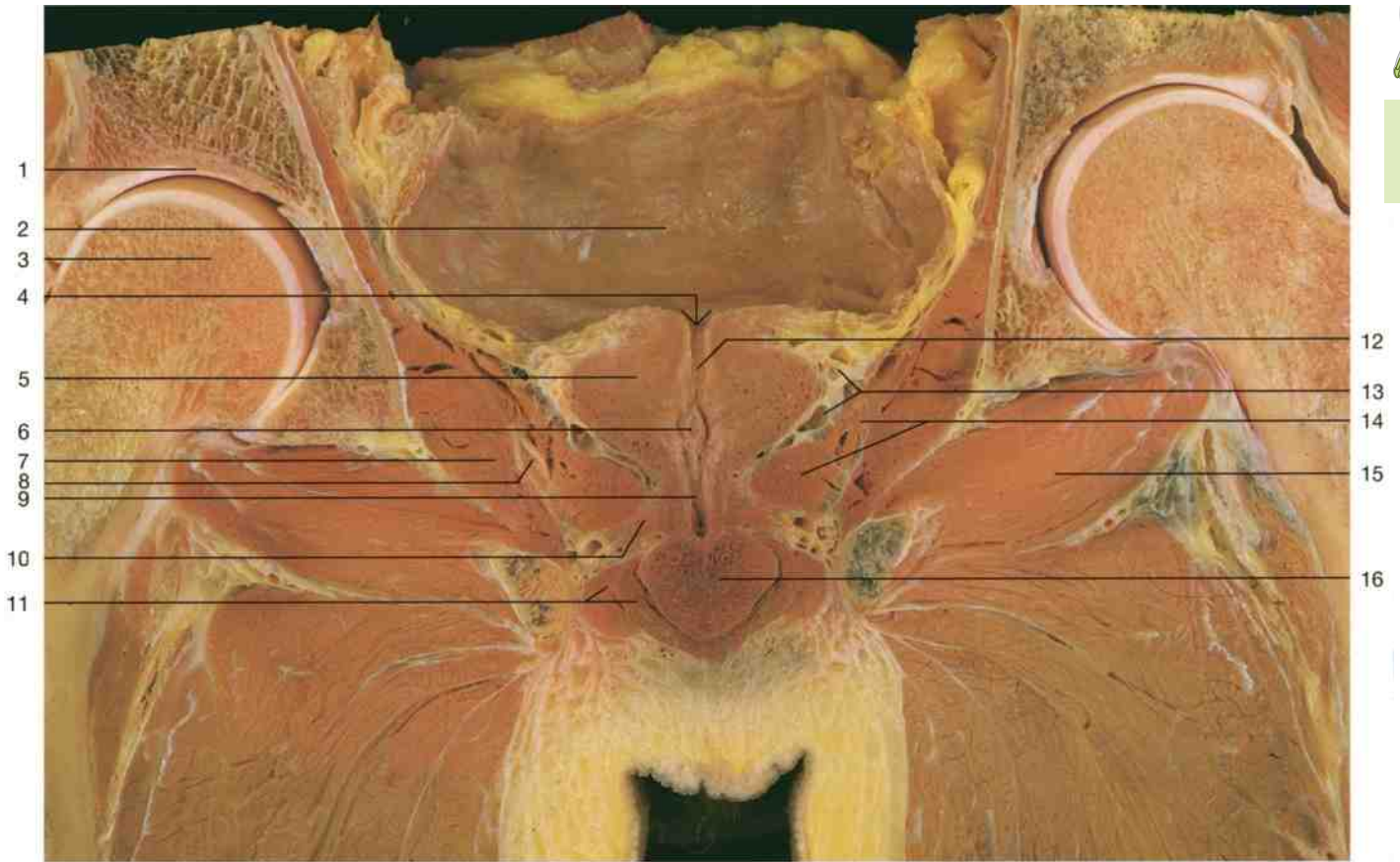


- 1 Ureter
- 2 Ductus deferens
- 3 Seminal vesicle
- 4 Ampulla of ductus deferens
- 5 Ejaculatory duct (proximal portion)
- 6 Prostate
- 7 Membranous urethra
- 8 Bulbo-urethral or Cowper's gland
- 9 Bulb of penis
- 10 Penis
- 11 Glans penis
- 12 Urinary bladder
- 13 Levator ani muscle
- 14 Obturator internus muscle
- 15 Pelvic bone (cut edge)
- 16 Puboprostatic ligament
- 17 Corpus spongiosum of penis
- 18 Head of epididymis
- 19 Beginning of ductus deferens
- 20 Testis
- 21 Tail of epididymis
- 22 Corpus cavernosum of penis
- 23 Spermatic cord
- 24 Pectineus and adductor muscles
- 25 Pubic bone
- 26 Prostatic part of urethra (seminal colliculus)
- 27 Rectum
- 28 Sciatic nerve
- 29 Great saphenous vein
- 30 Sartorius muscle
- 31 Femoral artery and vein
- 32 Rectus femoris muscle
- 33 Tensor fasciae latae muscle
- 34 Pectineus muscle
- 35 Iliopsoas muscle
- 36 Vastus lateralis muscle
- 37 Obturator externus muscle
- 38 Femur
- 39 Ischial tuberosity
- 40 Gluteus maximus muscle

Accessory glands of male genital organs in situ. Coronal section through the pelvic cavity. Posterior aspect of urinary bladder, prostate, and seminal vesicles.

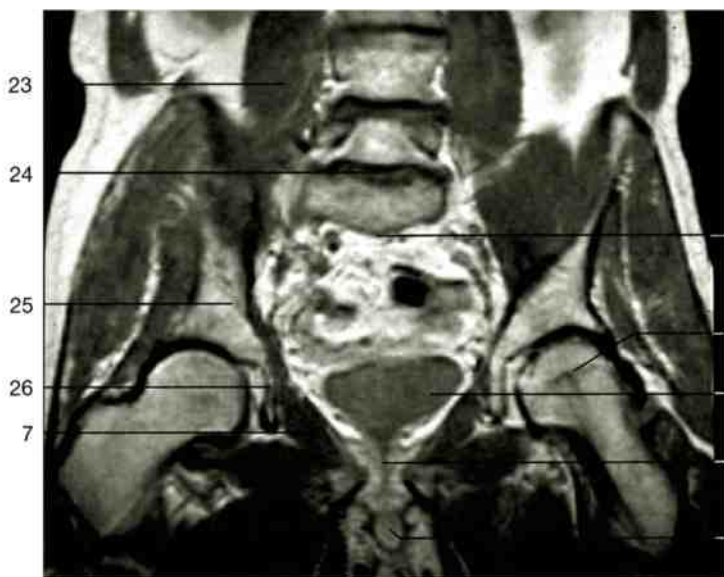

Horizontal section through pelvic cavity at the level of prostate.

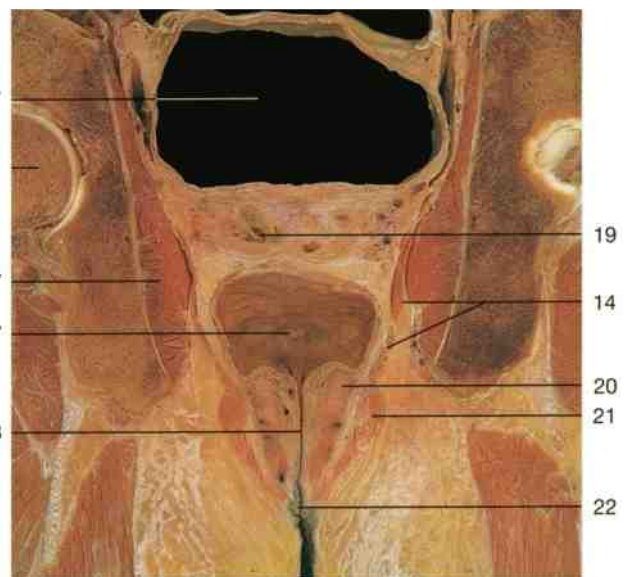

Coronal section through pelvic cavity at the level of prostate and hip joint (anterior aspect).

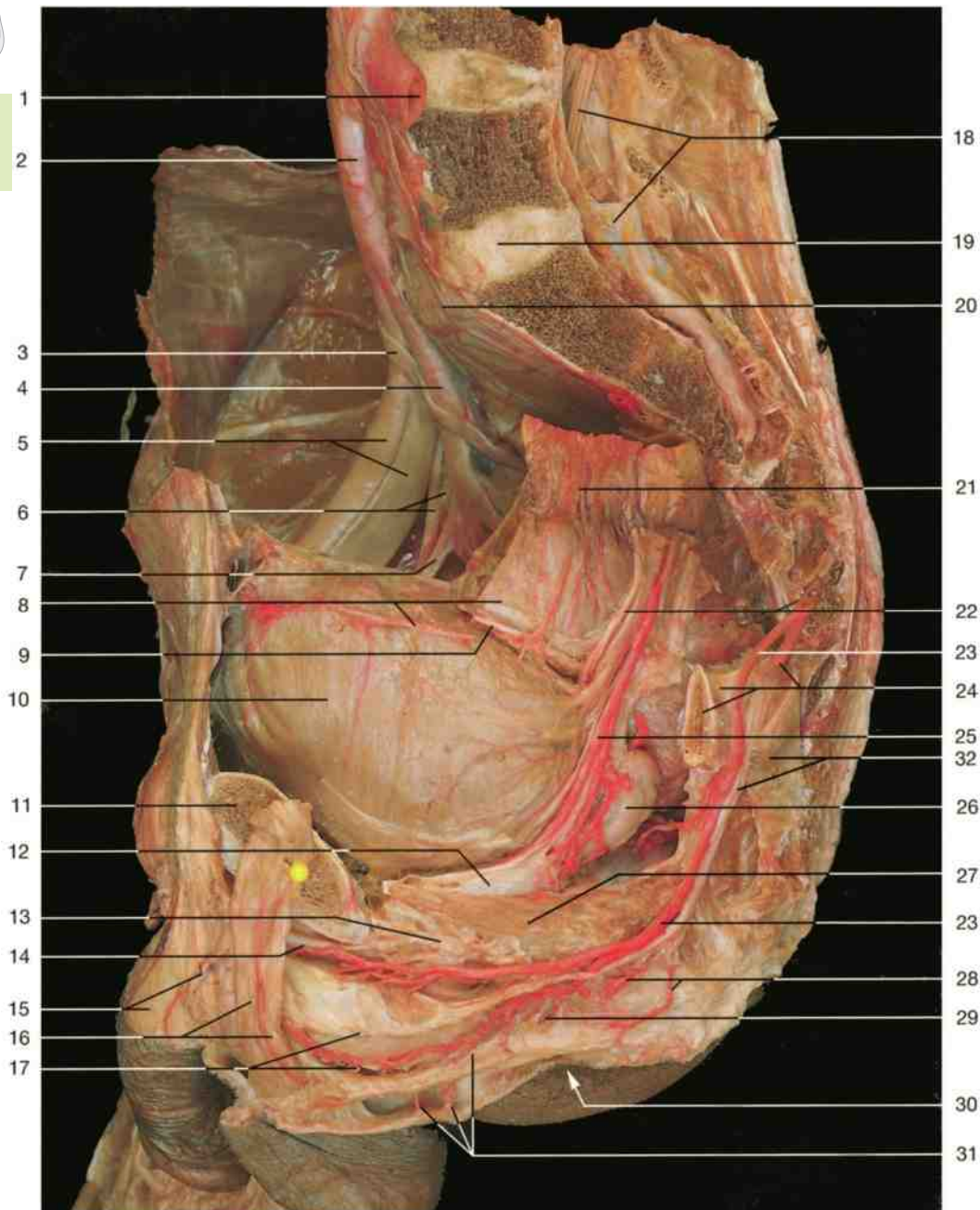
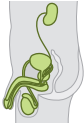- | | | |
|-----------------------------|---|--------------------------------------|
| 1 Acetabulum of hip joint | 10 Deep transverse perineus muscle | 19 Seminal vesicle |
| 2 Urinary bladder | 11 Crus penis and ischiocavernosus muscle | 20 Internal anal sphincter muscle |
| 3 Head of femur | 12 Prostatic part of urethra | 21 External anal sphincter muscle |
| 4 Internal urethral orifice | 13 Prostatic plexus | 22 Anus |
| 5 Prostate | 14 Levator ani muscle | 23 Psoas major muscle |
| 6 Seminal colliculus | 15 Obturator externus muscle | 24 Intervertebral disc |
| 7 Obturator internus muscle | 16 Bulb of penis | 25 Ilium |
| 8 Ischiorectal fossa | 17 Ampulla of rectum | 26 Ligament of the head of the femur |
| 9 Membranous urethra | 18 Anal canal | 27 Sacral promontory |



Coronal section through pelvic cavity (MRI scan).

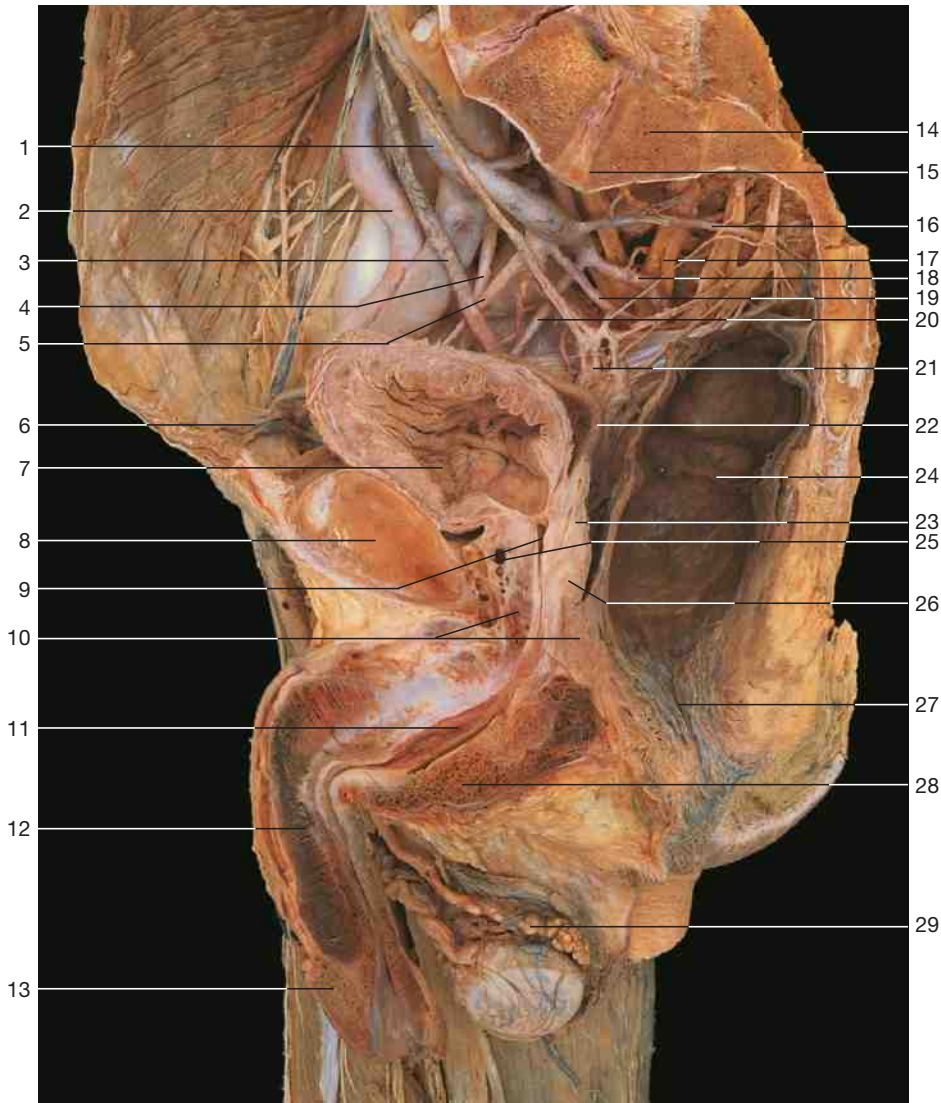
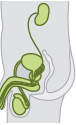

Coronal section through anal canal.



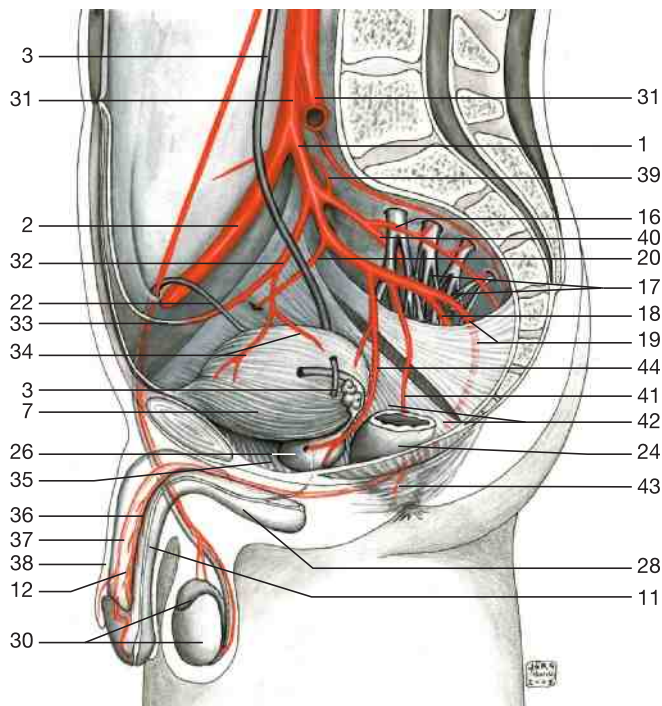
Pelvic cavity in the male (right half of parasagittal section). The arteries have been injected with red resin. The parietal layer of peritoneum has been removed. The urinary bladder is filled to a great extent.

- | | | | |
|----|--|----|--|
| 1 | Left common iliac artery | 18 | Cauda equina and dura mater (divided) |
| 2 | Right common iliac artery | 19 | Intervertebral disc between fifth lumbar vertebra and sacrum |
| 3 | Right ureter | 20 | Sacral promontory |
| 4 | Right internal iliac artery | 21 | Mesosigmoid |
| 5 | Right external iliac artery and vein | 22 | Left ureter |
| 6 | Right obturator artery and nerve | 23 | Left internal pudendal artery |
| 7 | Umbilical artery | 24 | Ischial spine (cut), sacrospinal ligament, inferior gluteal artery |
| 8 | Sigmoid and superior vesical artery | 25 | Left inferior vesical artery |
| 9 | Left ductus deferens | 26 | Seminal vesicle |
| 10 | Urinary bladder | 27 | Levator ani muscle |
| 11 | Pubic bone (cut) | 28 | Branches of inferior rectal artery |
| 12 | Prostate | 29 | Perineal artery |
| 13 | Vesicoprostatic venous plexus | 30 | Anus |
| 14 | Deep dorsal vein of penis and dorsal artery of penis | 31 | Posterior scrotal branches |
| 15 | Penis and superficial dorsal vein | 32 | Pudendal nerve and sacrotuberous ligament |
| 16 | Spermatic cord and testicular artery | | |
| 17 | Bulb of penis and deep artery of penis | | |

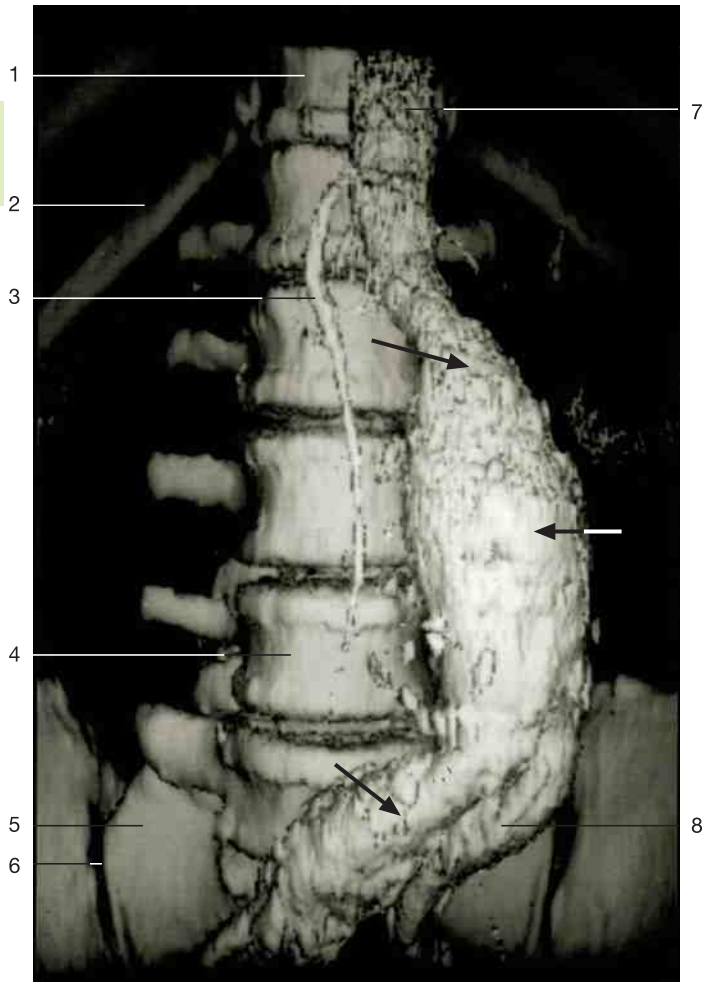


Vessels of the pelvic cavity in the male (medial aspect, midsagittal section). The gluteus maximus muscle has been removed.

- 1 Internal iliac artery
- 2 External iliac artery
- 3 Ureter
- 4 Obturator nerve
- 5 Umbilical artery
- 6 Anulus inguinalis profundus (deep inguinal ring)
- 7 Urinary bladder (vesica urinaria)
- 8 Symphysis
- 9 Prostatic part of urethra
- 10 Sphincter muscle of urethra
- 11 Urethra (spongy part)
- 12 Cavernous body of penis
- 13 Glans penis
- 14 Sacrum
- 15 Promontory
- 16 Lateral sacral artery
- 17 Plexus sacralis
- 18 Inferior gluteal artery
- 19 Internal pudendal artery
- 20 Obturator artery
- 21 Inferior hypogastric plexus
- 22 Ductus deferens
- 23 Seminal vesicle (vesicula seminalis)
- 24 Rectum
- 25 Prostatic venous plexus
- 26 Prostate
- 27 Anal canal
- 28 Spongy part of penis
- 29 Pampiniform plexus
- 30 Testis and epididymis
- 31 Common iliac artery
- 32 Umbilical artery
- 33 Medial umbilical ligament
- 34 Branches of superior vesical artery
- 35 Urogenital diaphragm
- 36 Deep artery of penis
- 37 Dorsal artery of penis
- 38 Penis
- 39 Iliolumbar artery
- 40 Superior gluteal artery
- 41 Middle rectal artery
- 42 Levator ani muscle
- 43 Inferior rectal artery
- 44 Inferior vesical artery

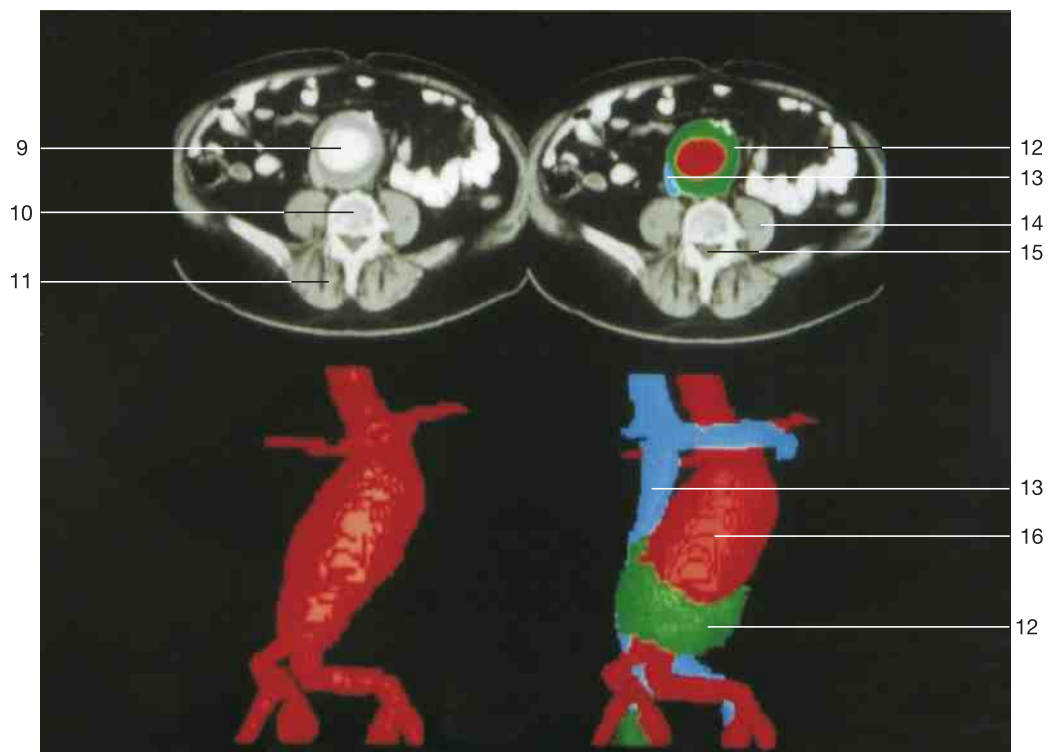


Main branches of internal iliac artery in the male (schematic drawing).

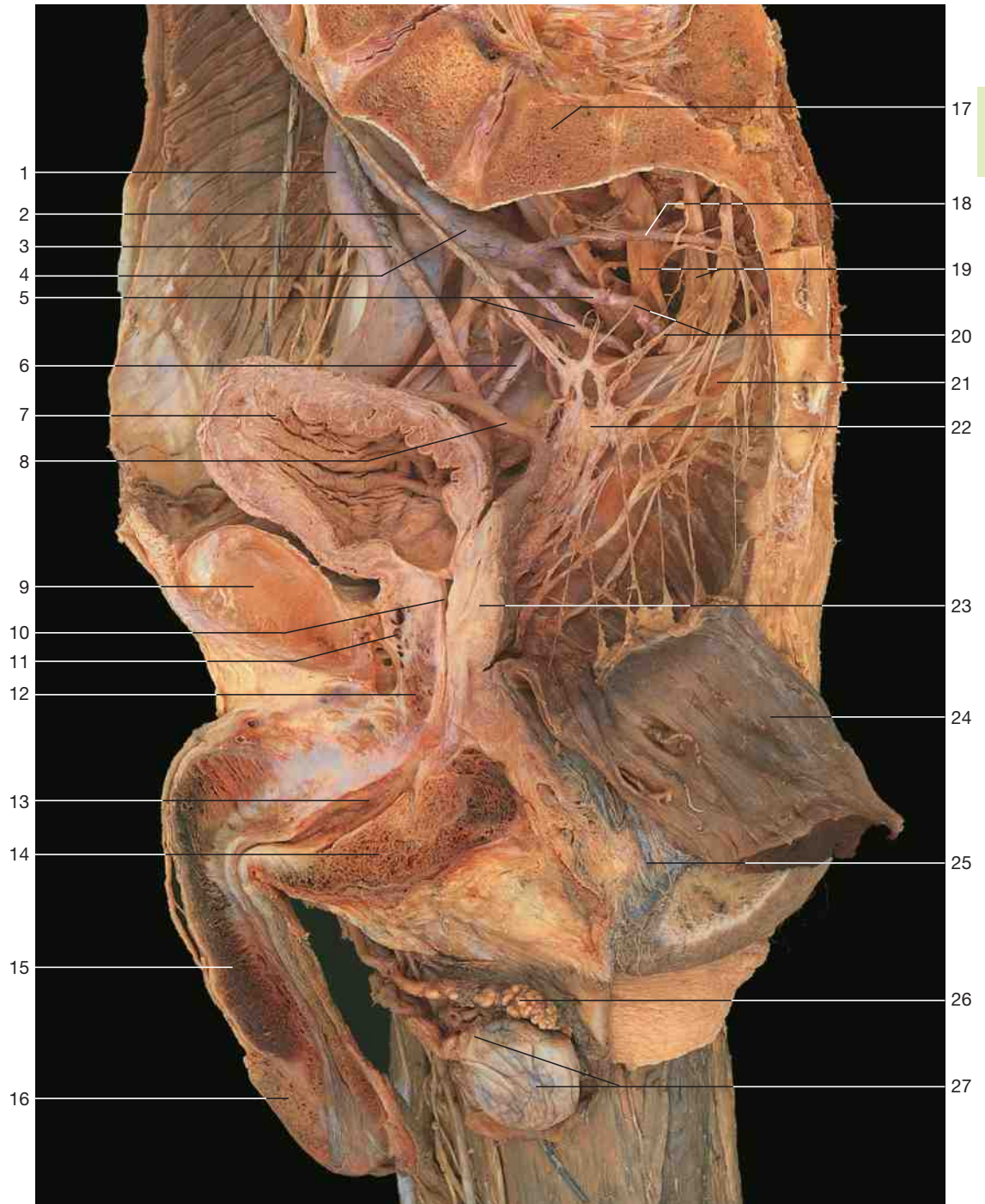


- 1 Twelfth thoracic vertebra (T₁₂)
- 2 Twelfth rib (rib XII)
- 3 Inferior mesenteric artery
- 4 Fourth lumbar vertebra (L₄)
- 5 Sacrum
- 6 Sacro-iliac articulation
- 7 Aorta (abdominal part)
- 8 Left common iliac artery (included into the aneurysm)
- 9 Aorta with aneurysm
- 10 Body of lumbar vertebra
- 11 Intrinsic muscles of the back
- 12 Thrombotic part of the aneurysm (green)
- 13 Inferior vena cava (compressed, blue)
- 14 Iliopsoas muscle
- 15 Vertebral canal
- 16 Aneurysm of the aorta (red)

Abdominal part of the aorta showing an infrarenal aneurysm with involvement of both iliac arteries (arrows)
 (3-D reconstruction, courtesy of Prof. H. Rupprecht and Dr. M. Rexer, Klinikum Fürth, Germany).

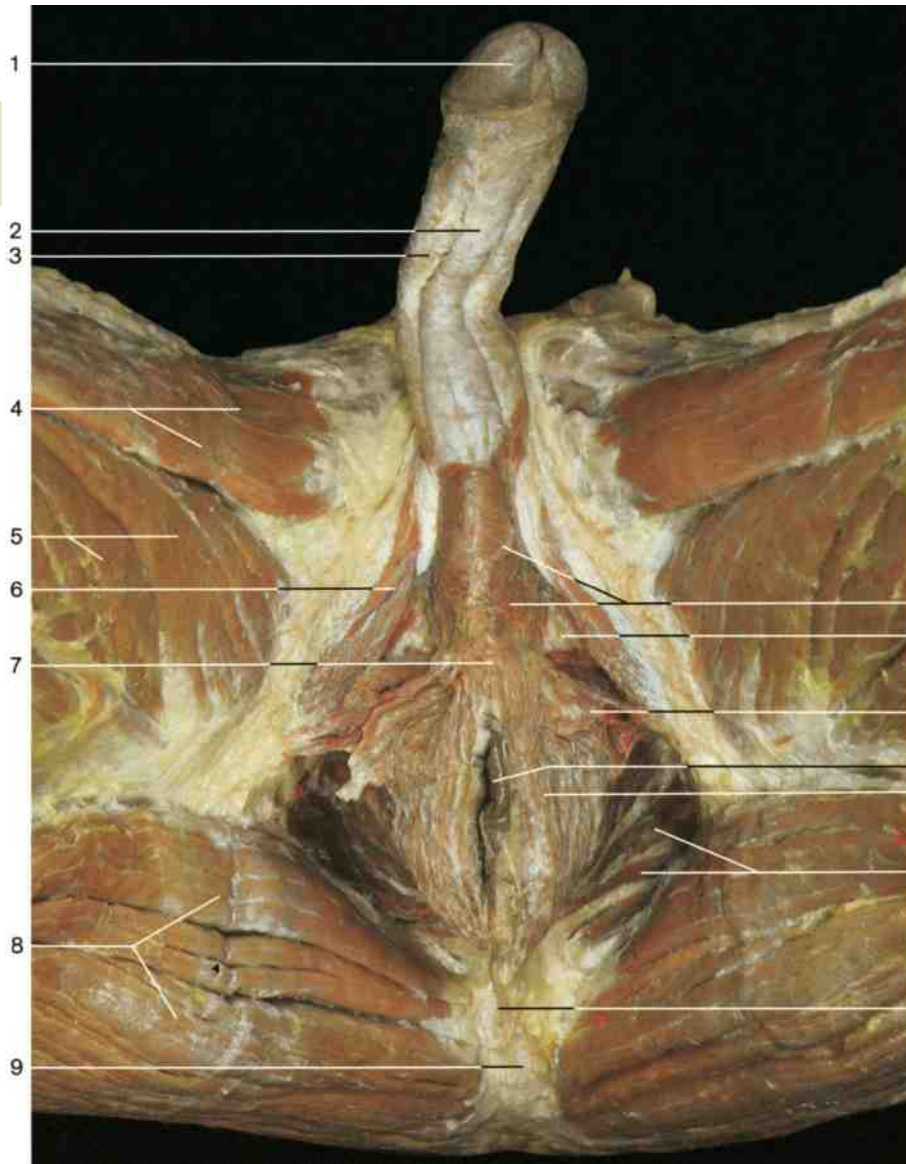
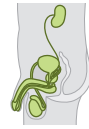

Abdominal part of the aorta with an aneurysm, after injection of contrast medium.
 Above = horizontal sections through the abdominal cavity, showing different contrast medium concentrations within the aorta and the aneurysm; below = 3-D reconstruction of the aneurysm; red = aorta; green = thrombotic areas; blue = vein (vena cava inferior, partly compressed).



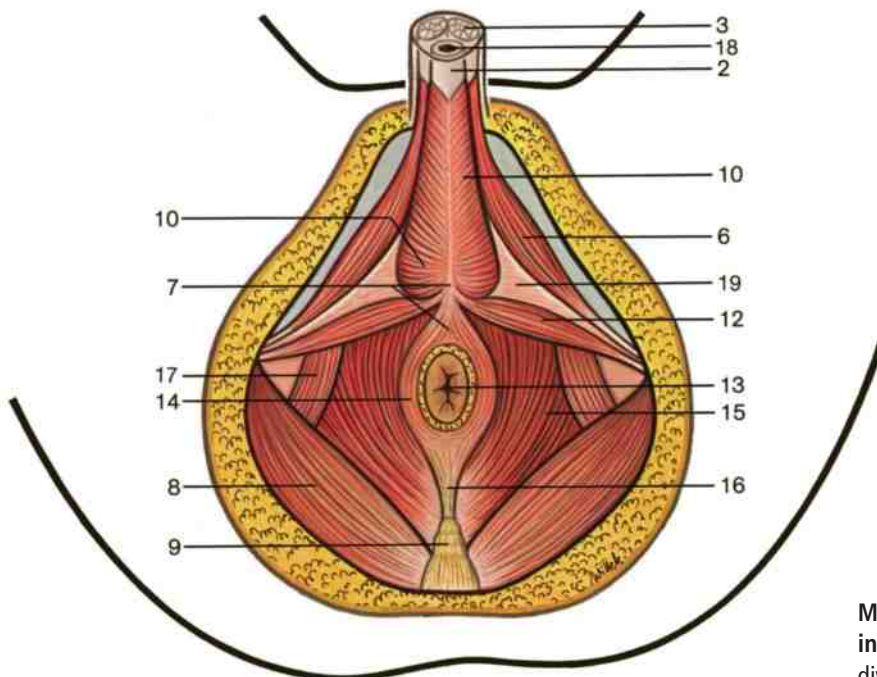
Vessels and nerves of the pelvic cavity in the male (medial aspect, midsagittal section). Rectum reflected to display the inferior hypogastric plexus.

- | | | |
|--|------------------------------|---|
| 1 External iliac artery | 10 Prostatic part of urethra | 20 Pelvic splanchnic nerves (nervi erigentes) |
| 2 Right hypogastric nerve | 11 Prostatic venous plexus | 21 Levator ani muscle |
| 3 Ureter | 12 Sphincter urethrae muscle | 22 Inferior hypogastric plexus (pelvic plexus) |
| 4 Internal iliac artery | 13 Spongy part of urethra | 23 Prostate |
| 5 Inferior gluteal artery and internal pudendal artery | 14 Corpus spongiosum penis | 24 Rectum (reflected) |
| 6 Obturator artery | 15 Corpus cavernosum penis | 25 Anal canal and external anal sphincter |
| 7 Urinary bladder | 16 Glans penis | 26 Pampiniform plexus continuous with testicular vein |
| 8 Ductus deferens | 17 Sacrum | 27 Testis and epididymis |
| 9 Symphysis pubica | 18 Lateral sacral artery | |
| | 19 Sacral plexus | |

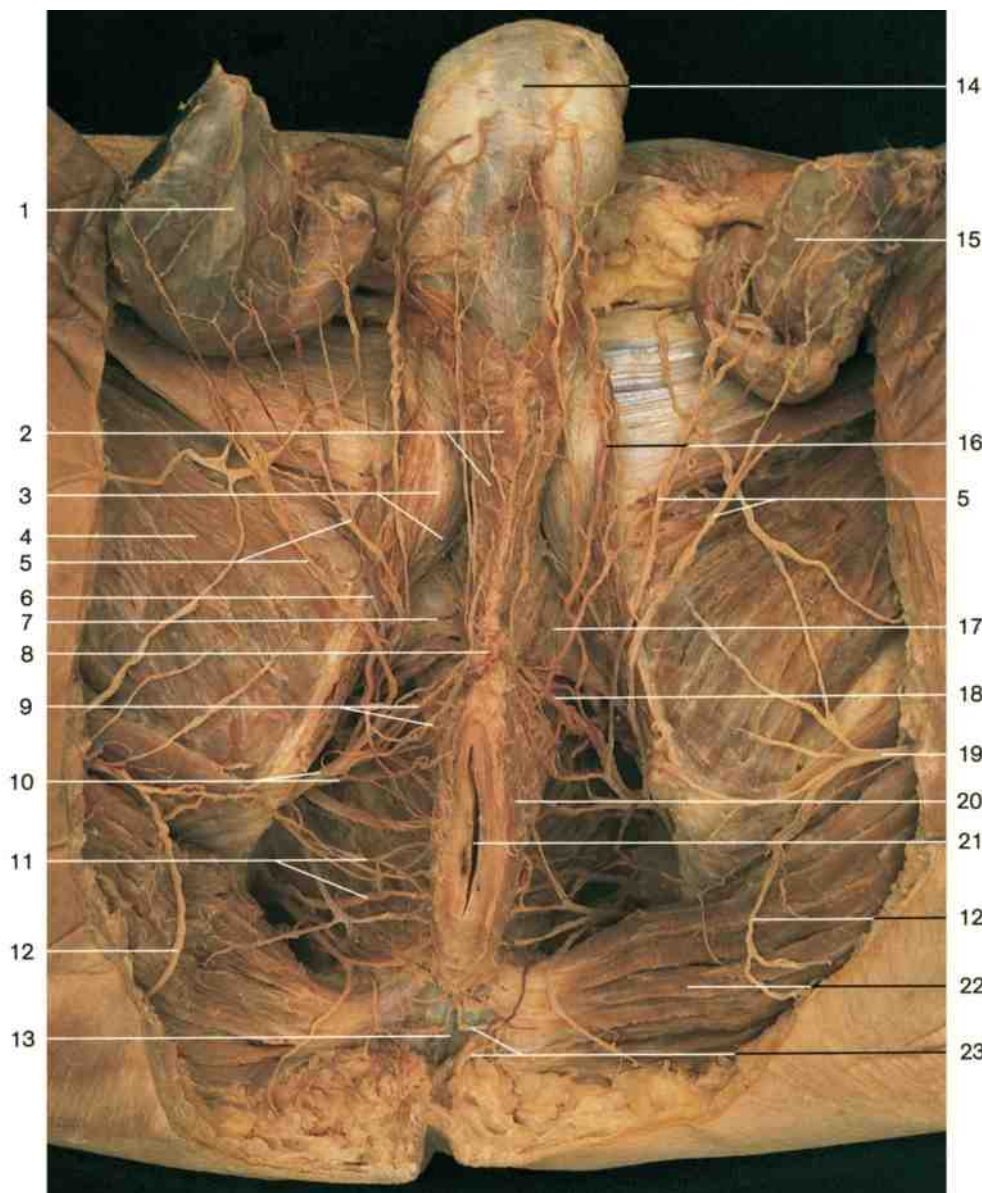


- 1 Glans penis
- 2 Corpus spongiosum of penis
- 3 Corpus cavernosum of penis
- 4 Gracilis muscle
- 5 Adductor muscles
- 6 Ischiocavernosus muscle overlying crus of penis
- 7 Perineal body
- 8 Gluteus maximus muscle
- 9 Coccyx
- 10 Bulbospongiosus muscle
- 11 Deep transverse perineus muscle covered by inferior fascia of urogenital diaphragm
- 12 Superficial transverse perineus muscle
- 13 Anus
- 14 External anal sphincter muscle
- 15 Levator ani muscle
- 16 Anococcygeal ligament
- 17 Obturator internus muscle
- 18 Urethra
- 19 Deep transverse perineus muscle

Muscles of urogenital and pelvic diaphragms in the male (from below).

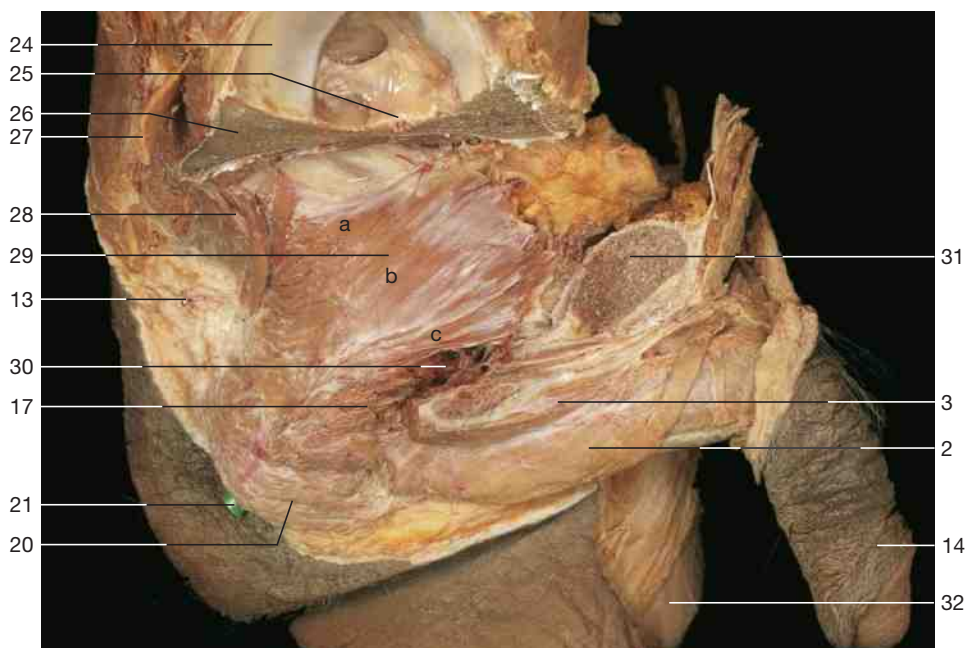


Muscles of urogenital and pelvic diaphragms in the male (from below). The penis has been divided (schematic drawing).

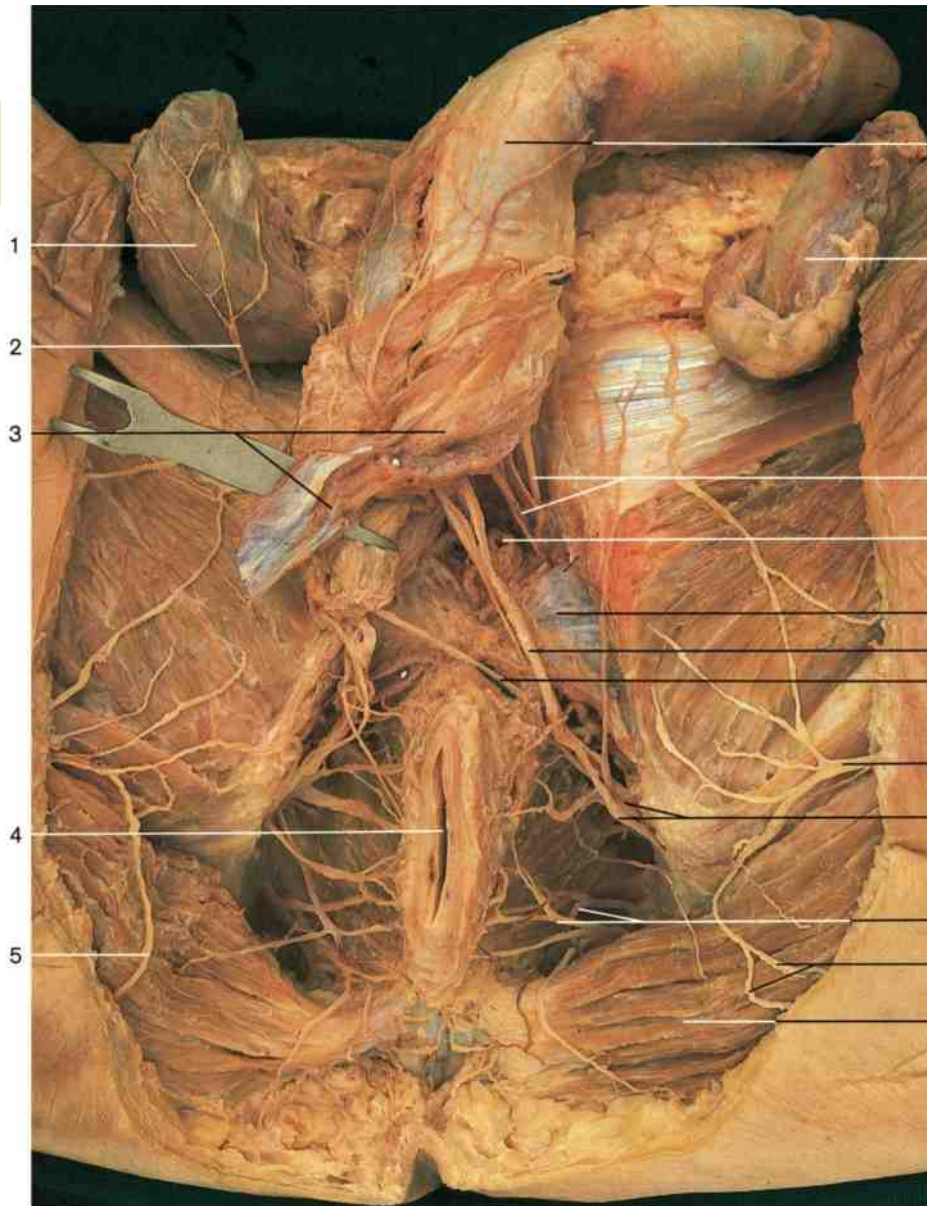


- 1 Right testis (reflected laterally and upward)
- 2 Bulbospongiosus muscle
- 3 Ischiocavernosus muscle
- 4 Adductor magnus muscle
- 5 Posterior scrotal nerves and superficial perineal arteries
- 6 Posterior scrotal artery and vein
- 7 Right artery of bulb of penis
- 8 Perineal body
- 9 Perineal branches of pudendal nerve
- 10 Pudendal nerve and internal pudendal artery
- 11 Inferior rectal arteries and nerves
- 12 Inferior cluneal nerve
- 13 Coccyx (location)
- 14 Penis
- 15 Left testis (reflected laterally)
- 16 Left posterior scrotal artery
- 17 Deep transverse perineal muscle
- 18 Left artery of bulb of penis
- 19 Posterior femoral cutaneous nerve
- 20 External anal sphincter muscle
- 21 Anus
- 22 Gluteus maximus muscle
- 23 Anococcygeal nerves
- 24 Acetabulum (femur removed)
- 25 Ligament of femoral head
- 26 Body of ischium (cut)
- 27 Sciatic nerve
- 28 Coccygeus muscle
- 29 Levator ani muscle
 - a iliococcygeus muscle
 - b pubococcygeus muscle
 - c puborectalis muscle
- 30 Prostatic venous plexus
- 31 Body of pubis
- 32 Testis

Urogenital diaphragm and external genital organs in the male with vessels and nerves (from below). The testes have been reflected laterally.

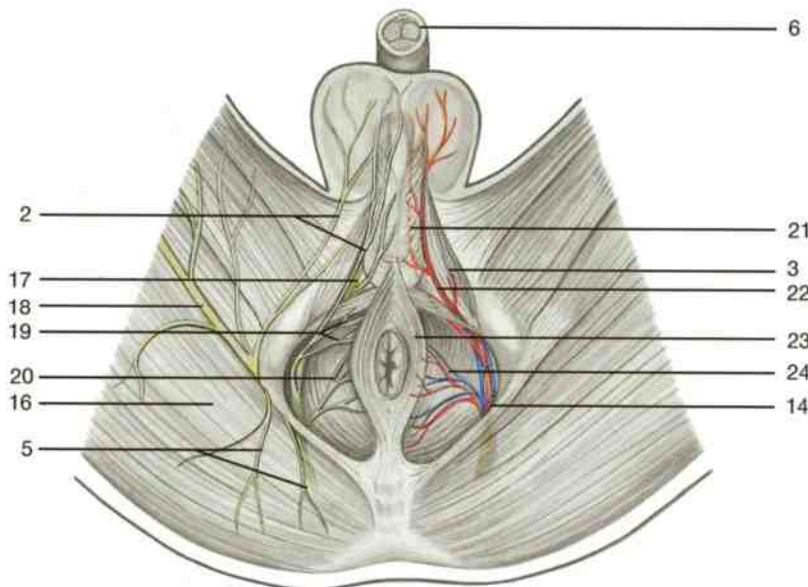


Pelvic diaphragm and external genital organs in the male. The right half of the pelvis including the obturator internus muscle and femur have been removed to display the right half of the levator ani muscle.



- 1 Right testis (reflected)
- 2 Posterior scrotal nerves
- 3 Left crus penis with ischiocavernosus muscle
- 4 Anus
- 5 Inferior cluneal nerves
- 6 Penis
- 7 Left testis (reflected)
- 8 Dorsal artery and nerve of penis
- 9 Urethra
- 10 Deep transverse perineus muscle
- 11 Perineal branch of pudendal nerve
- 12 Artery of bulb of penis (reflected)
- 13 Branch of posterior femoral cutaneous nerve
- 14 Internal pudendal artery and pudendal nerve
- 15 Inferior rectal arteries and nerves
- 16 Gluteus maximus muscle
- 17 Dorsal nerve of penis
- 18 Posterior femoral cutaneous nerve
- 19 Perineal branches of pudendal nerve
- 20 Inferior rectal nerves
- 21 Bulbospongiosus muscle (inside: dorsal artery of penis)
- 22 Perineal artery
- 23 External anal sphincter muscle
- 24 Inferior rectal artery and veins

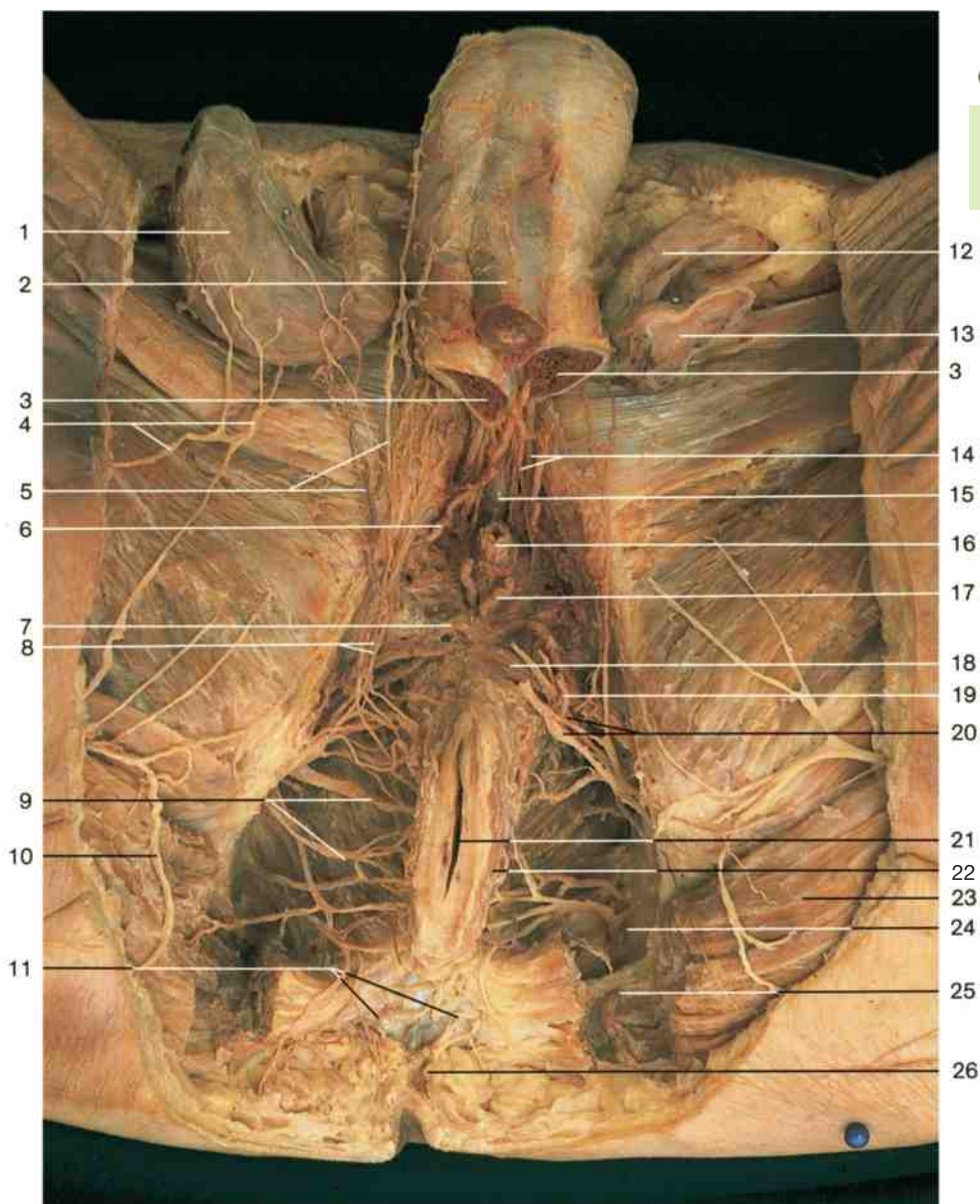
Urogenital diaphragm and external genital organs in the male (from below). The left crus penis has been isolated and reflected laterally together with the bulb of the penis. The urethra has been cut.



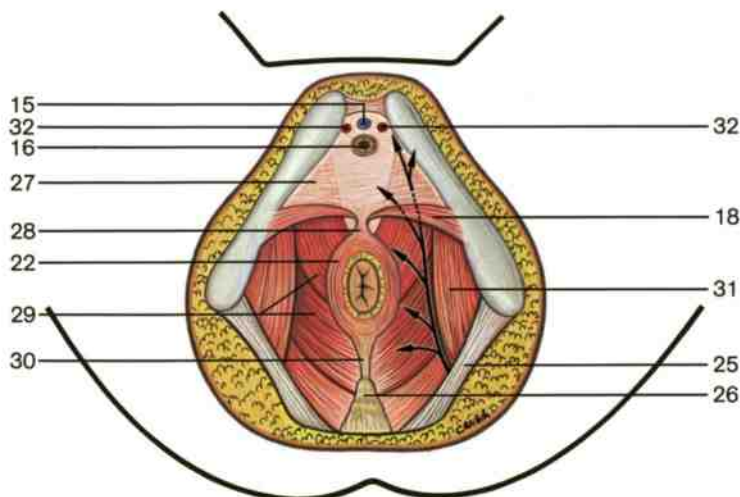
Urogenital and anal region in the male (from below). Right side: nerves; left side: arteries and veins.



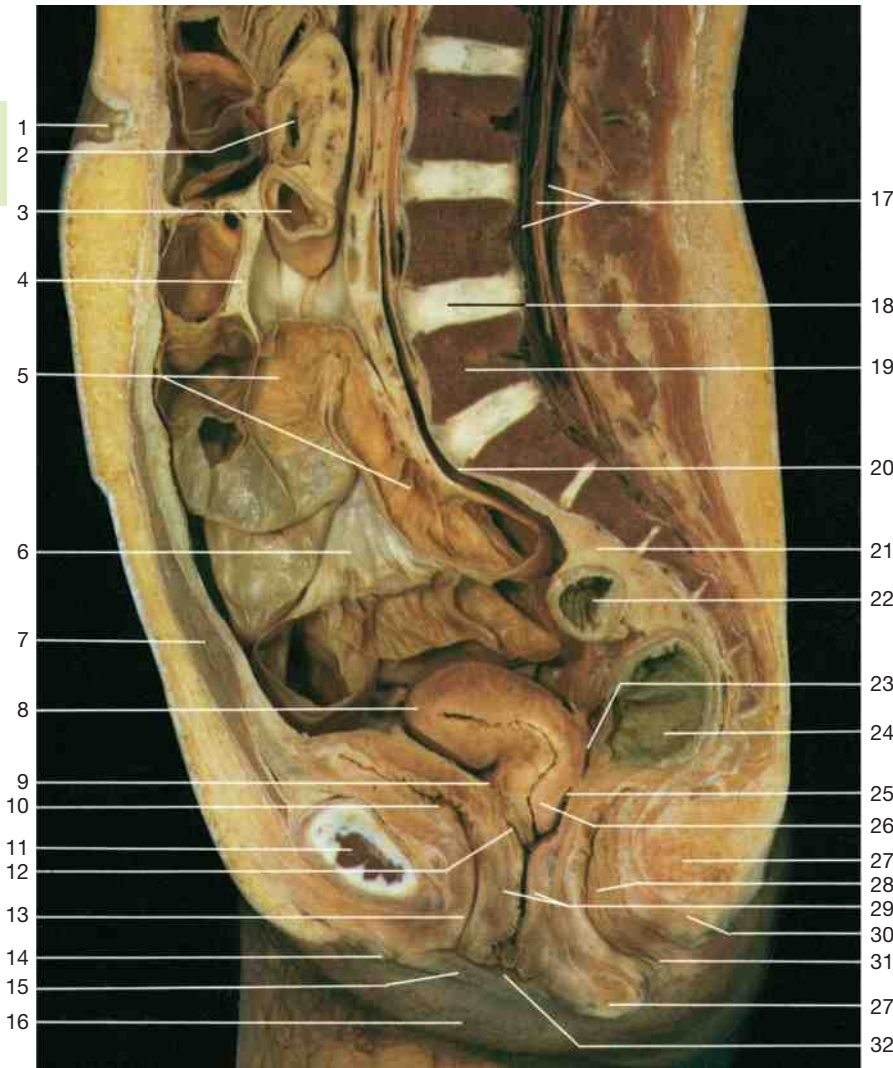
- 1 Right testis (reflected)
- 2 Corpus spongiosum of penis
- 3 Corpus cavernosum of penis
- 4 Perineal branch of posterior femoral cutaneous nerve
- 5 Posterior scrotal arteries and nerves
- 6 Deep artery of penis
- 7 Deep transverse perineal muscle
- 8 Right perineal nerves
- 9 Inferior rectal nerves
- 10 Inferior cluneal nerve
- 11 Anococcygeal nerves
- 12 Left spermatic cord
- 13 Left testis (cut surface)
- 14 Dorsal artery and nerve of penis
- 15 Deep dorsal vein of penis
- 16 Urethra (cut)
- 17 Artery of bulb of penis
- 18 Superficial transverse perineus muscle
- 19 Left artery of bulb of penis
- 20 Perineal branch of pudendal nerve
- 21 Anus
- 22 External anal sphincter muscle
- 23 Gluteus maximus muscle
- 24 Internal pudendal artery and pudendal nerve
- 25 Sacrotuberous ligament
- 26 Coccyx
- 27 Urogenital diaphragm (deep transverse perineus muscle)
- 28 Tendinous center of perineum (perineal body)
- 29 Levator ani muscle
- 30 Anococcygeal ligament
- 31 Obturator internus muscle
- 32 Dorsal artery of penis



Urogenital diaphragm and external genital organs in the male (from below). The root of the penis has been cut. Dissection of the urogenital diaphragm.

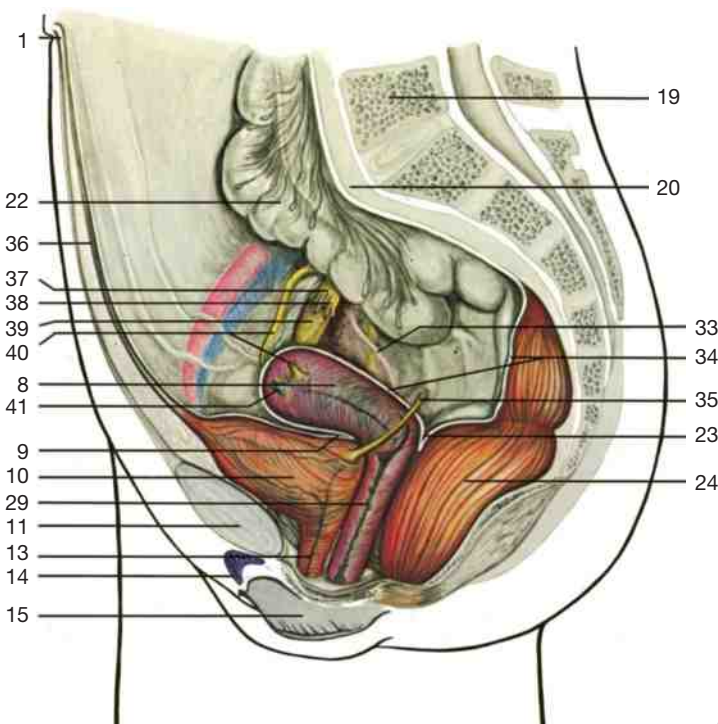


Urogenital and pelvic diaphragms in the male (from below). The penis has been removed. The arrows indicate the course of vessels and nerves (schematic drawing).

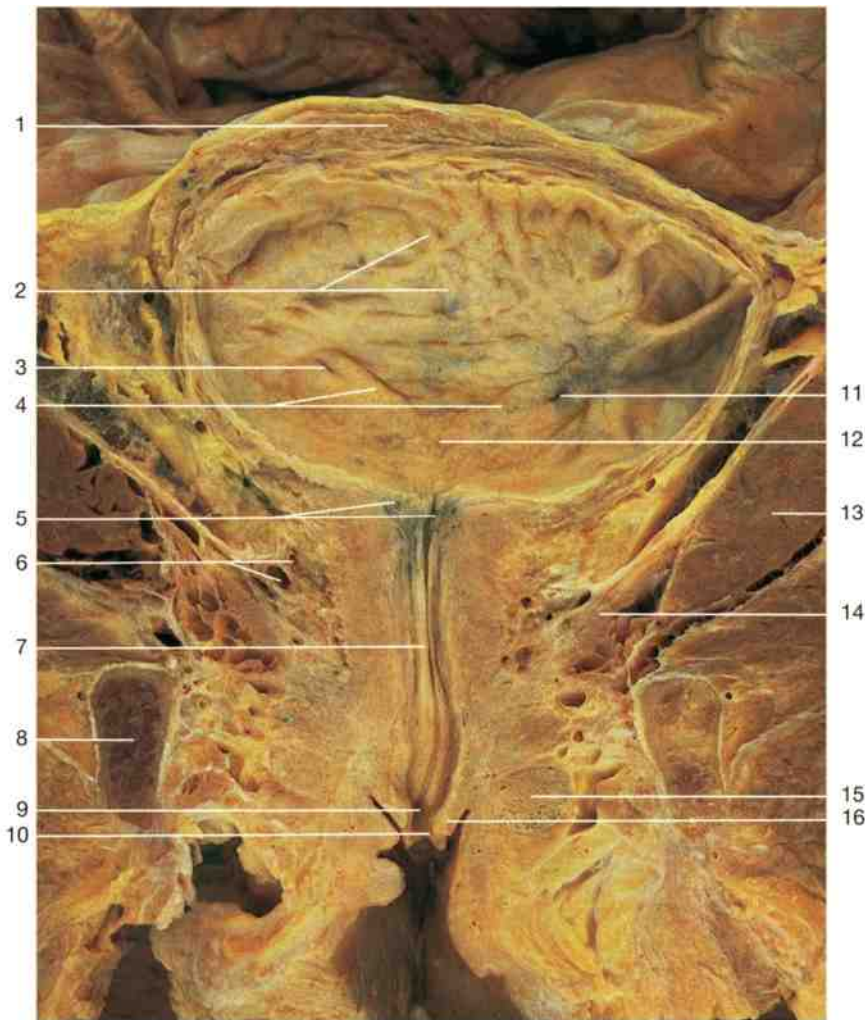


- 1 Umbilicus
- 2 Duodenum
- 3 Ascending part of duodenum
- 4 Root of mesentery
- 5 Small intestine
- 6 Mesentery
- 7 Rectus abdominis muscle
- 8 Uterus
- 9 Vesico-uterine pouch
- 10 Urinary bladder (collapsed)
- 11 Pubic symphysis
- 12 Anterior fornix of vagina
- 13 Urethra
- 14 Clitoris
- 15 Labium minus
- 16 Labium majus
- 17 Vertebral canal with cauda equina
- 18 Intervertebral disc
- 19 Body of fifth lumbar vertebra
- 20 Sacral promontory
- 21 Mesosigmoid
- 22 Sigmoid colon
- 23 Recto-uterine pouch (of Douglas)
- 24 Ampulla of rectum
- 25 Posterior fornix of vagina
- 26 Cervix of uterus
- 27 External anal sphincter muscle
- 28 Anal canal
- 29 Vagina
- 30 Internal anal sphincter muscle
- 31 Anus
- 32 Hymen
- 33 Left ureter
- 34 Peritoneum (cut edge)
- 35 Right ureter (divided)
- 36 Median umbilical fold with urachus
- 37 Infundibulum of uterine tube
- 38 Fimbriae of uterine tube
- 39 Ovary
- 40 Uterine tube (isthmus)
- 41 Round ligament of uterus

Female urogenital system, midsagittal section through the trunk. The urinary bladder is empty, position and shape of the uterus are normal.

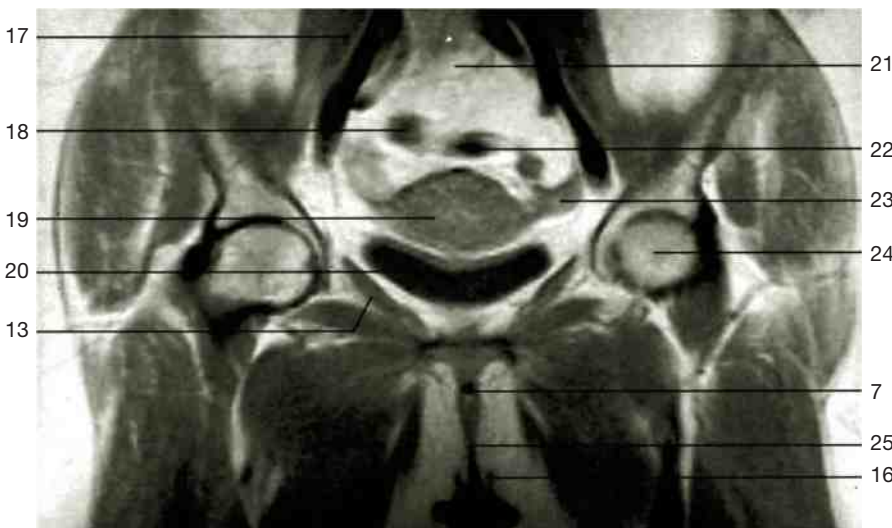


Positions of female genital organs (medial aspect, schematic drawing).



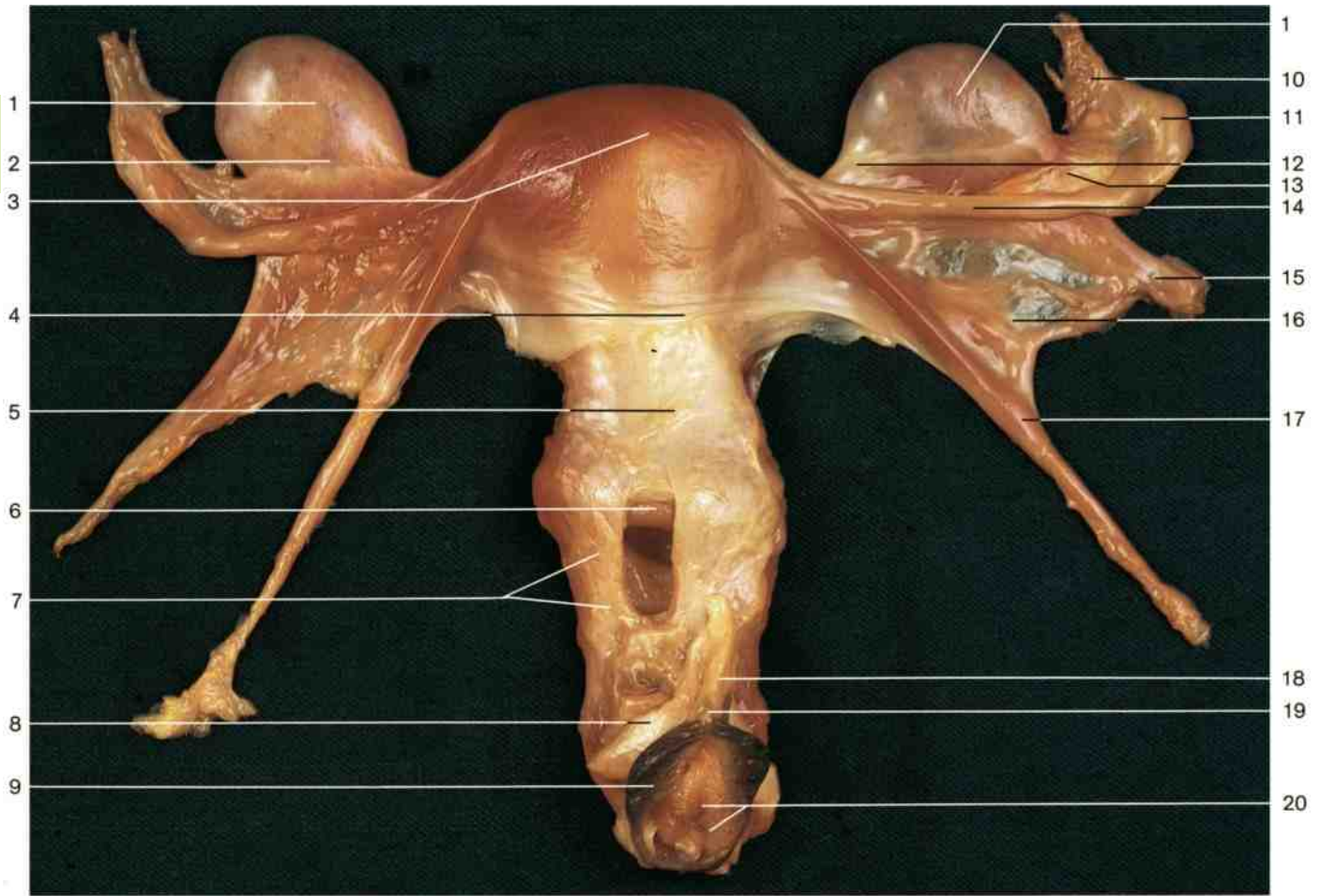
- 1 Muscular coat of urinary bladder
- 2 Folds of mucous membrane of urinary bladder
- 3 Right ureteric orifice
- 4 Interureteric fold
- 5 Internal urethral orifice
- 6 Vesico-uterine venous plexus
- 7 Urethra
- 8 Pubic bone (cut edge)
- 9 External urethral orifice
- 10 Vestibule of vagina
- 11 Left ureteric orifice
- 12 Trigone of bladder
- 13 Obturator internus muscle
- 14 Levator ani muscle
- 15 Bulb of the vestibule
- 16 Left labium minus
- 17 Psoas major muscle
- 18 Ampulla of rectum
- 19 Uterus
- 20 Urinary bladder
- 21 Promontory
- 22 Sigmoid colon
- 23 Uterine tube
- 24 Head of femur
- 25 Vagina

Coronal section through the female urinary bladder and urethra (anterior aspect).

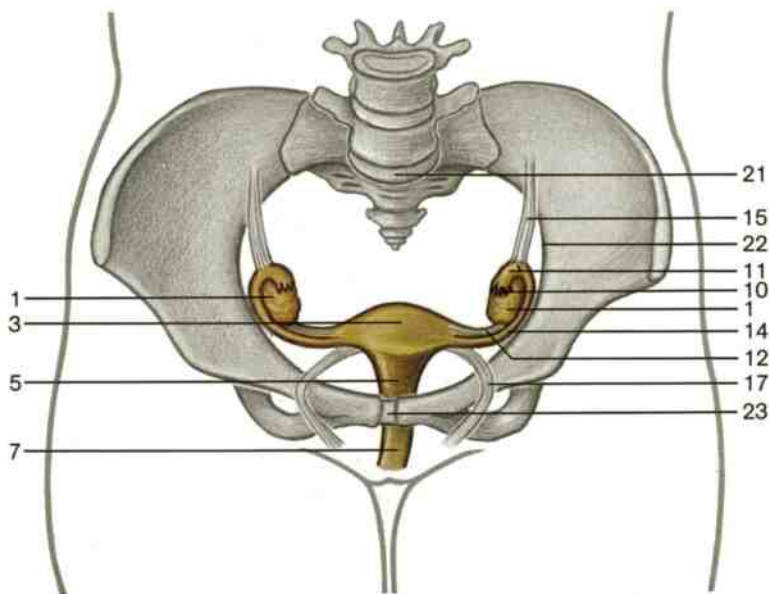


The urogenital system of the female differs greatly from that of the male. During embryonal development, the uterus and ovary remain within the pelvic cavity where, after puberty, the ovulation takes place. Therefore, the urinary system remains functionally separated from the genital organs in the female.

Coronal section through the pelvic cavity of the female (MRI scan).

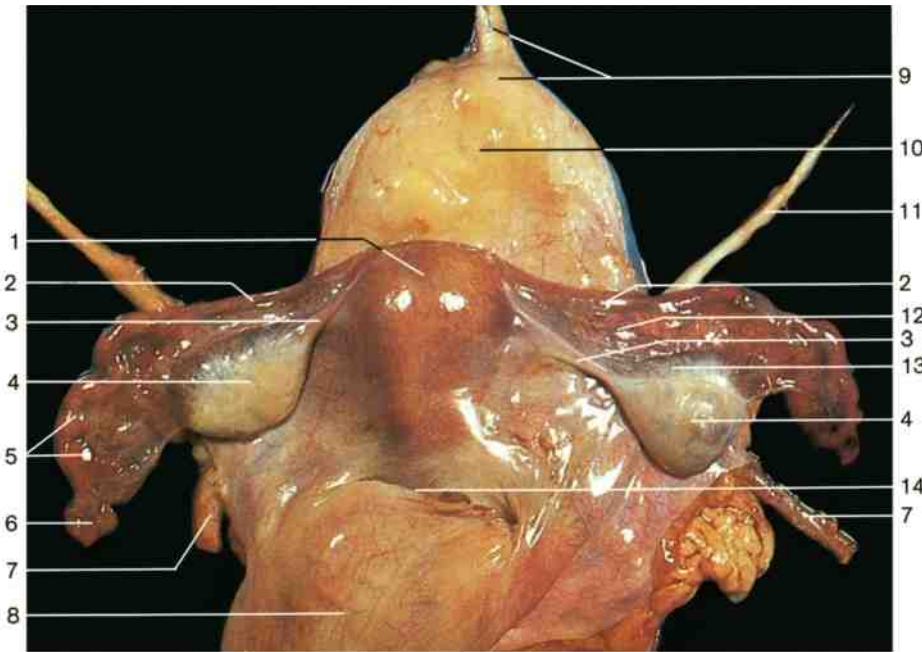


Female genital organs, isolated (anterior aspect). The anterior wall of the vagina has been opened to display the vaginal portion of the cervix.



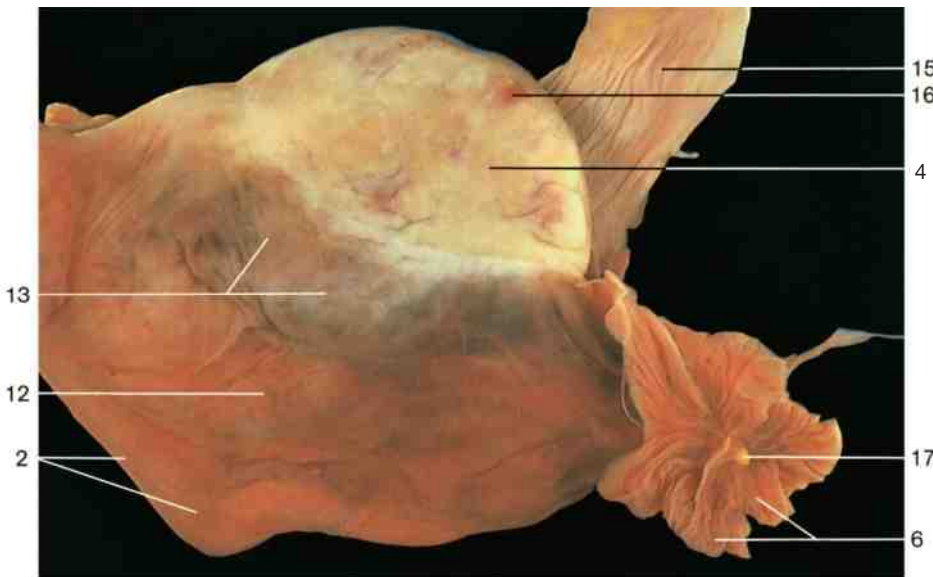
Female internal genital organs (schematic drawing).

- 1 Ovary
- 2 Mesovarium
- 3 Fundus of uterus
- 4 Vesico-uterine pouch
- 5 Cervix of uterus
- 6 Vaginal portion of cervix
- 7 Vagina
- 8 Crus of clitoris
- 9 Labium minus
- 10 Fimbriae of uterine tube
- 11 Infundibulum of uterine tube
- 12 Ligament of the ovary
- 13 Mesosalpinx
- 14 Uterine tube
- 15 Suspensory ligament of ovary (caudally displaced)
- 16 Broad ligament of uterus
- 17 Round ligament of uterus
- 18 Corpus cavernosum of clitoris
- 19 Glans of clitoris
- 20 Hymen, vaginal orifice
- 21 Promontory
- 22 Linea terminalis of pelvis
- 23 Pubic symphysis

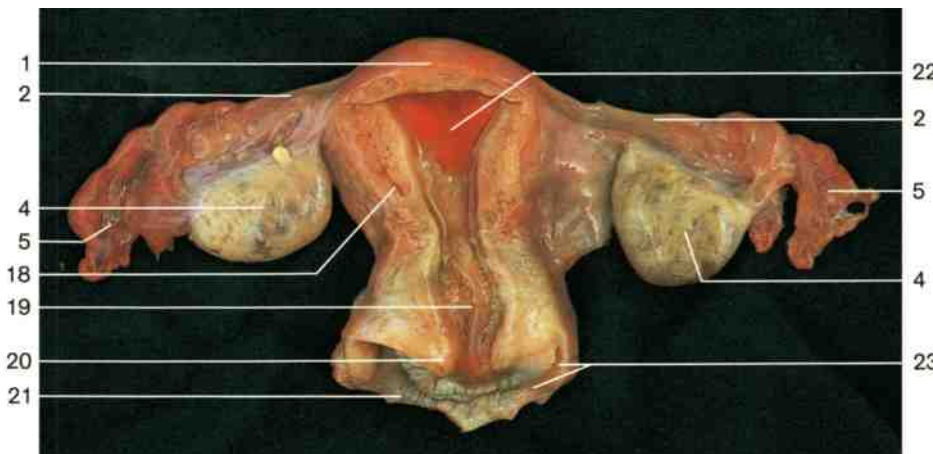


- 1 Fundus of uterus
- 2 Uterine tube
- 3 Ligament of the ovary
- 4 Ovary
- 5 Infundibulum of uterine tube
- 6 Fimbriae of uterine tube
- 7 Ureter
- 8 Rectum
- 9 Apex of urinary bladder and median umbilical ligament
- 10 Urinary bladder
- 11 Round ligament of uterus
- 12 Mesosalpinx
- 13 Mesovarium
- 14 Recto-uterine pouch (of Douglas)
- 15 Suspensory ligament of ovary
- 16 Scarring of ovary (following ovulation)
- 17 Abdominal opening of uterine tube
- 18 Body of uterus
- 19 Cervical canal
- 20 Vaginal portion of cervix of uterus (congestion)
- 21 Vagina
- 22 Mucous membrane of uterus
- 23 Anterior fornix of vagina

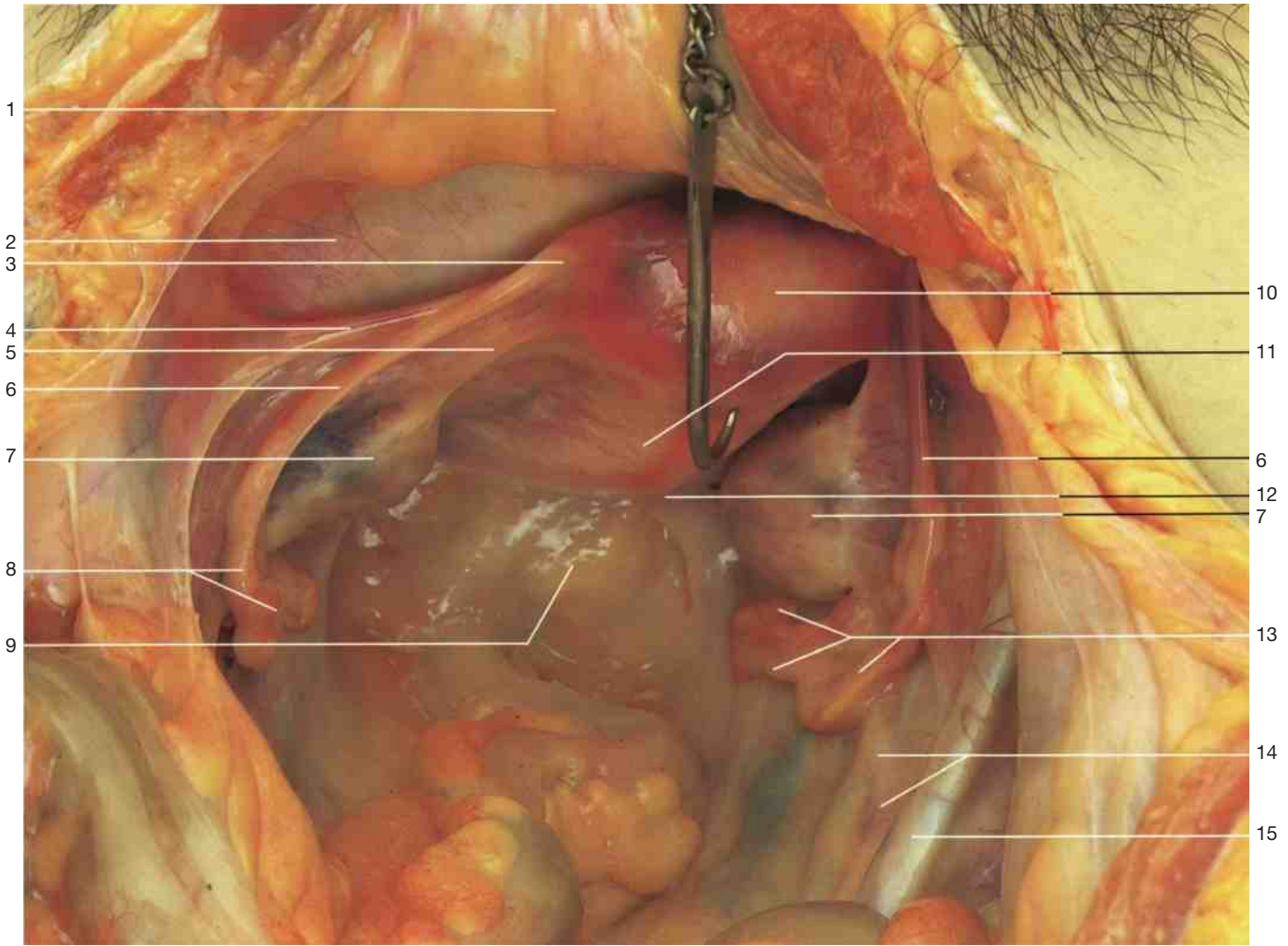
Female genital organs, isolated (supero-posterior aspect).



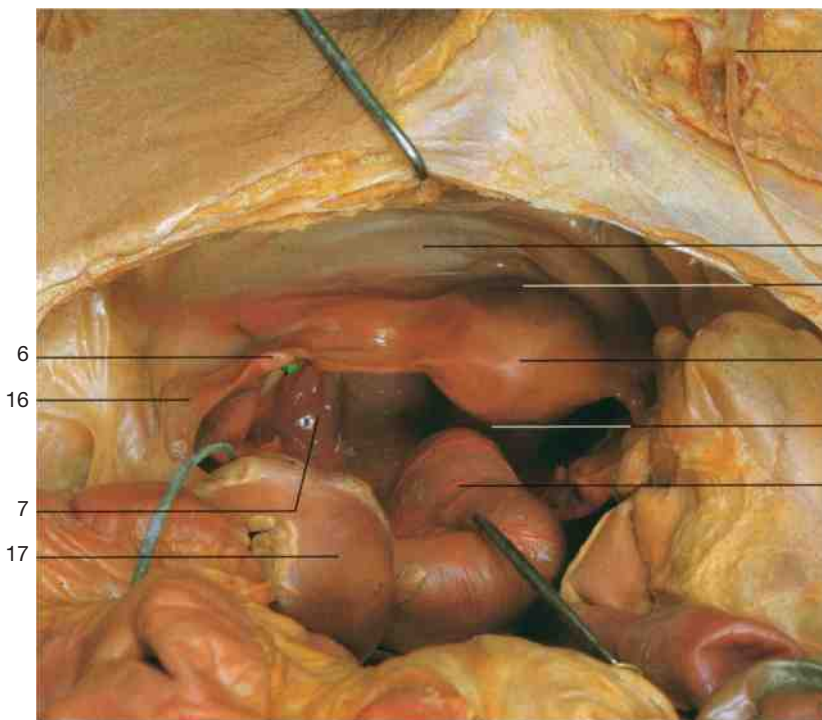
Right ovary and uterine tube, isolated (supero-posterior aspect). The fimbriae of the uterine tube have been reflected to show the abdominal ostium.



Uterus and related organs (posterior aspect). The posterior wall of the uterus has been opened.

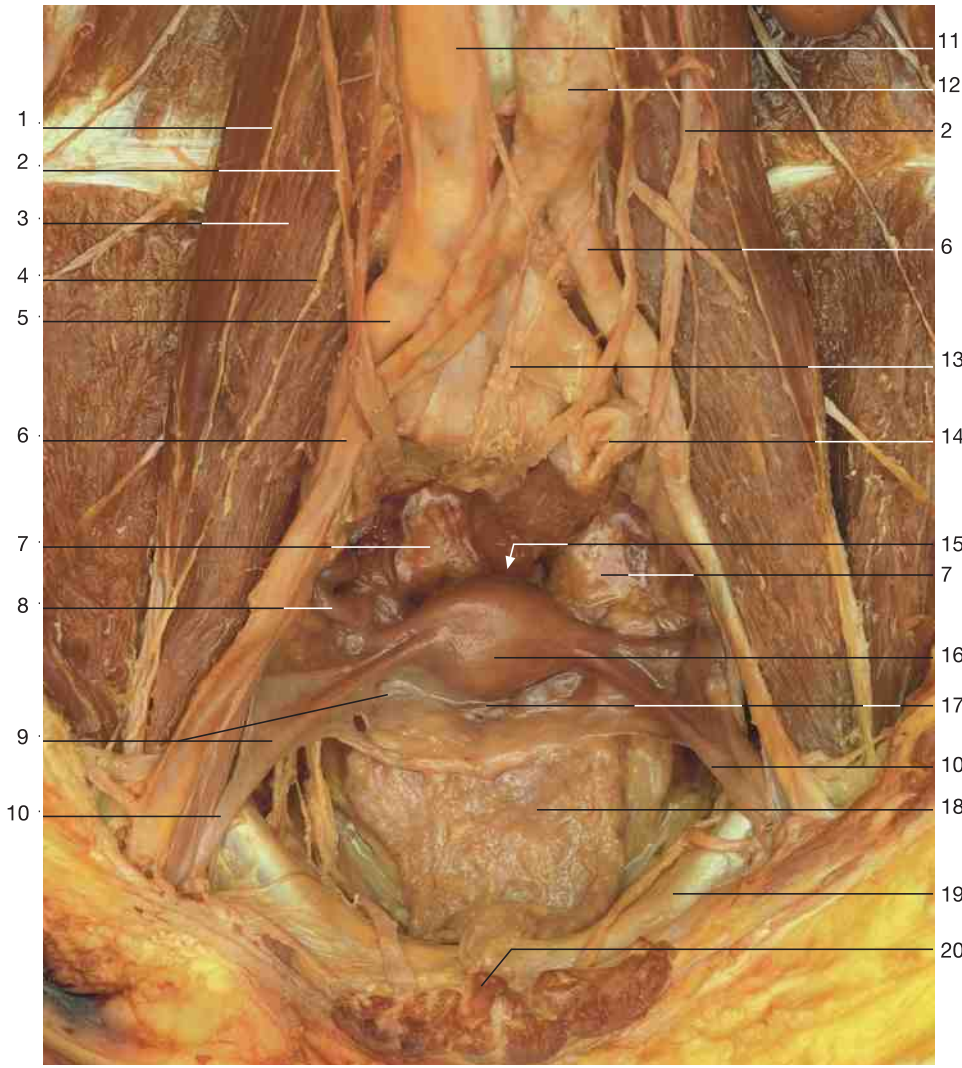


Female internal genital organs. Pelvic cavity (seen from above). The uterus has been reflected to the right.



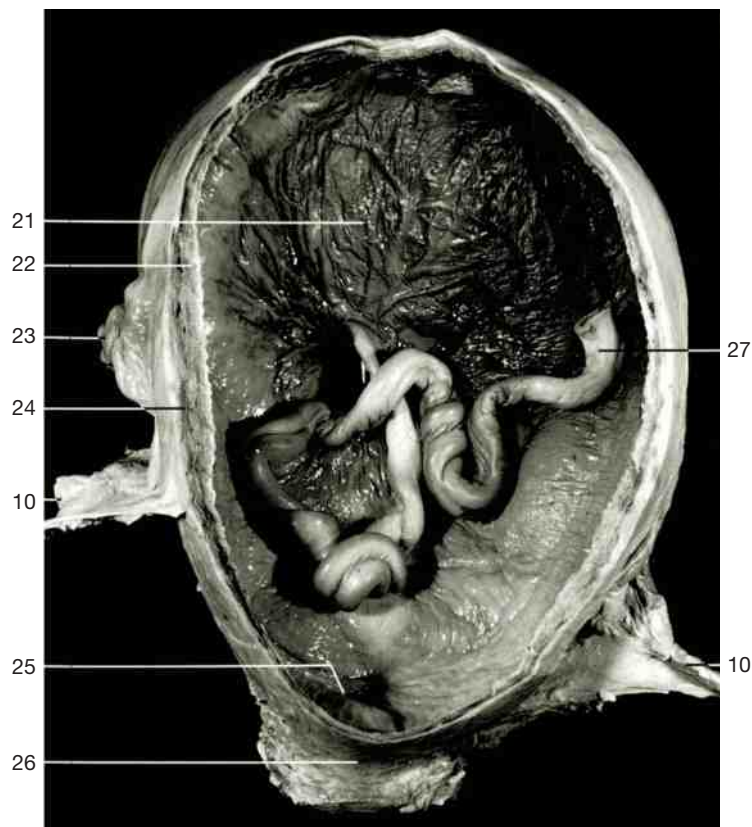
- 1 Median umbilical fold with urachus
- 2 Urinary bladder
- 3 Insertion of uterine tube at fundus of uterus
- 4 Round ligament of uterus
- 5 Ligament of ovary
- 6 Uterine tube (isthmus)
- 7 Ovary
- 8 Ampulla of uterine tube
- 9 Rectum
- 10 Uterus
- 11 Vagina
- 12 Recto-uterine pouch (of Douglas)
- 13 Fimbriae of uterine tube
- 14 Suspensory ligament of ovary
- 15 Right common iliac artery (covered by peritoneum)
- 16 Mesosalpinx
- 17 Sigmoid colon
- 18 Saphenous opening
- 19 Vesico-uterine pouch

Female internal genital organs. Pelvic cavity (seen from above).

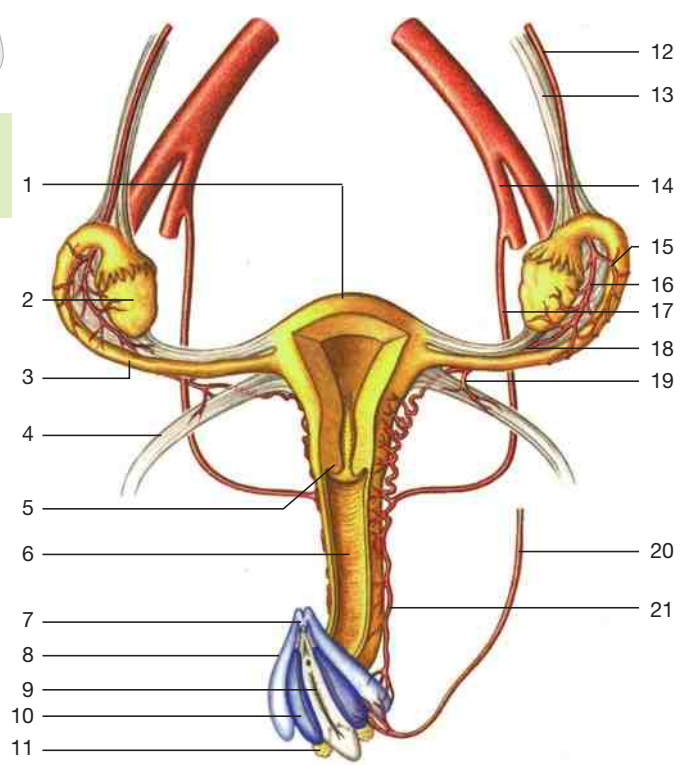
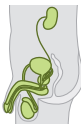

- 1 Ilio-inguinal nerve
- 2 Ureter
- 3 Psoas major muscle
- 4 Genitofemoral nerve
- 5 Common iliac vein
- 6 Common iliac artery
- 7 Ovary
- 8 Uterine tube
- 9 Peritoneum
- 10 Round ligament of uterus
- 11 Inferior vena cava
- 12 Abdominal aorta
- 13 Superior hypogastric plexus
- 14 Rectum
- 15 Recto-uterine pouch (of Douglas)
- 16 Uterus
- 17 Vesico-uterine pouch
- 18 Urinary bladder
- 19 Iliac crest
- 20 Pubic symphysis
- 21 Placenta
- 22 Amnion and chorion
- 23 Adnexa of uterus (uterine tube and ovaries)
- 24 Myometrium
- 25 Internal orifice of uterus
- 26 Cervix of uterus
- 27 Umbilical cord

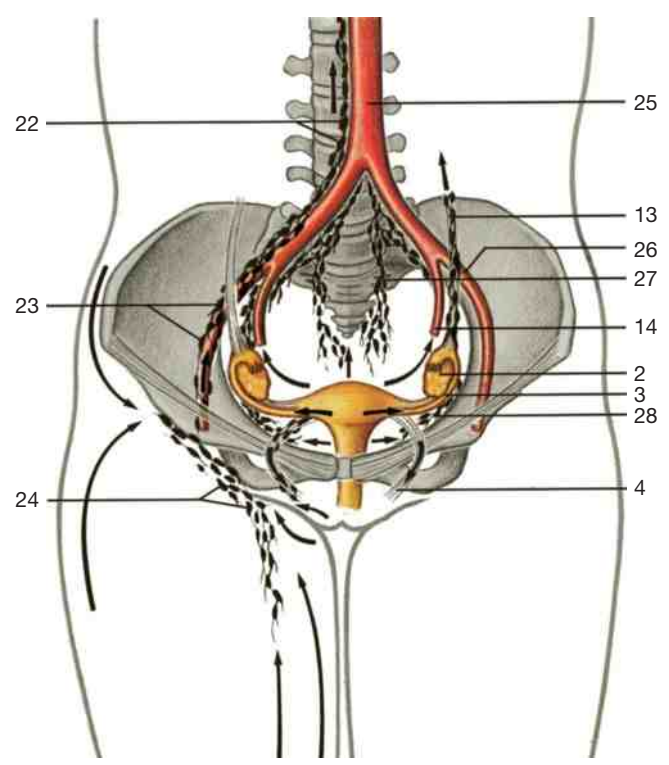
View of the female pelvis showing uterus and related organs (superior aspect).



Fullterm uterus with placenta (anterior aspect).
The anterior wall of the uterus has been removed to show the location of the placenta.

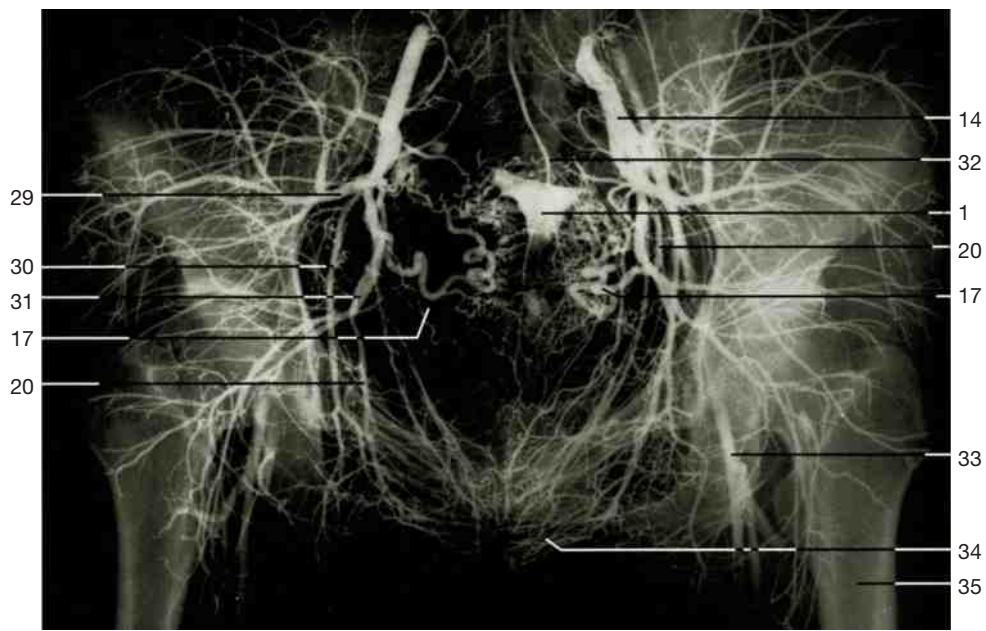

Arteries of female genital organs (schematic drawing).

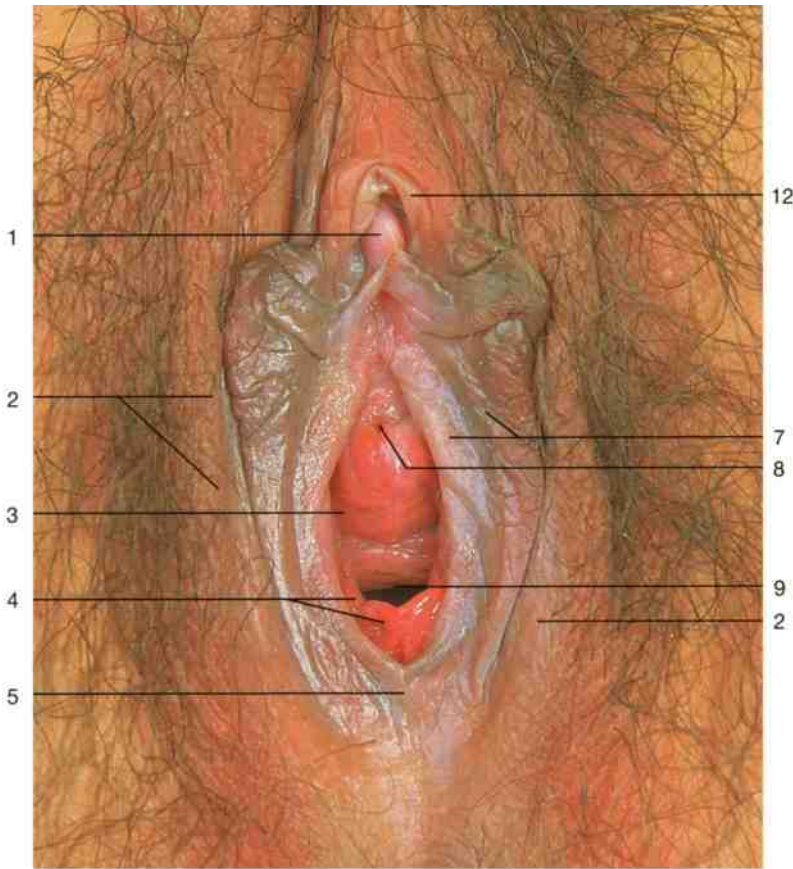


Main drainage routes of lymph vessels of uterus and its adnexa (indicated by arrows). (Schematic drawing.)
Red = arteries; black = lymph vessels and nodes.

- | | | | |
|---------------------------------------|-------------------------------------|-------------------------------|-------------------------------|
| 1 Uterus | 10 Bulb of vestibule | 19 Artery of round ligament | 28 Internal iliac lymph nodes |
| 2 Ovary | 11 Greater vestibular gland | 20 Internal pudendal artery | 29 Superior gluteal artery |
| 3 Uterine tube | 12 Ovarian artery | 21 Vaginal artery | 30 Obturator artery |
| 4 Round ligament of uterus | 13 Suspensory ligament of ovary | 22 Lumbar lymph nodes | 31 Inferior gluteal artery |
| 5 Vaginal portion of cervix of uterus | 14 Internal iliac artery | 23 External iliac lymph nodes | 32 Middle sacral artery |
| 6 Vagina | 15 Tubal branch of ovarian artery | 24 Inguinal lymph nodes | 33 Femoral artery |
| 7 Clitoris | 16 Ovarian branch of ovarian artery | 25 Abdominal aorta | 34 Vessels of labium majus |
| 8 Corpus cavernosum of clitoris | 17 Uterine artery | 26 External iliac artery | 35 Femur |
| 9 Vaginal orifice | 18 Ovarian branch of uterine artery | 27 Sacral lymph nodes | |

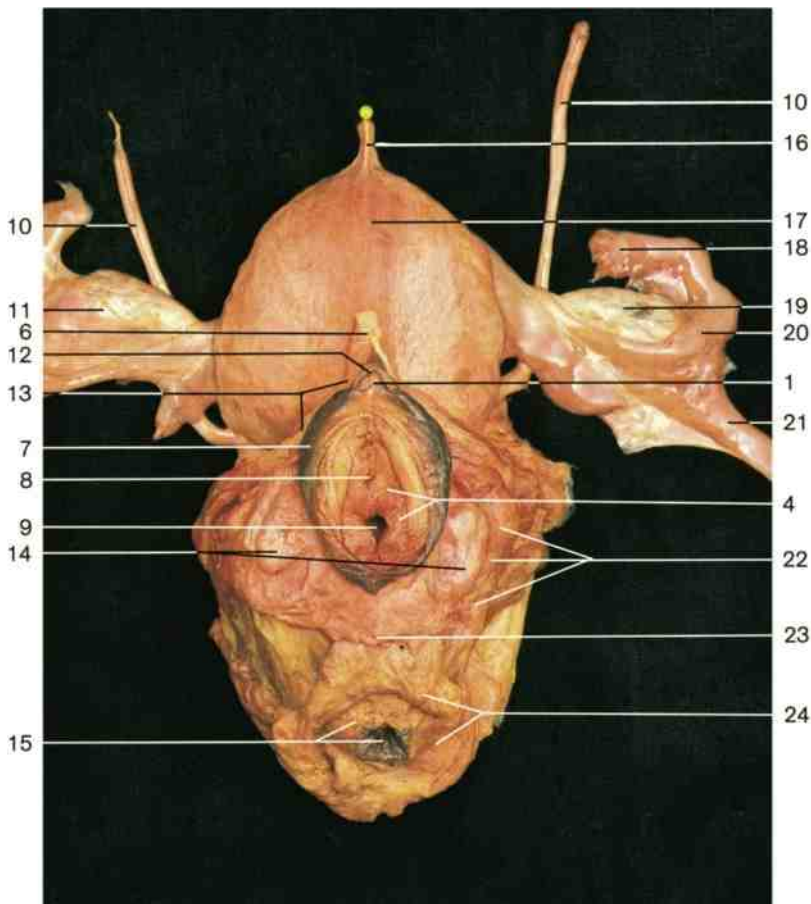


Pelvic vessels in the female (arteriography, antero-posterior view).

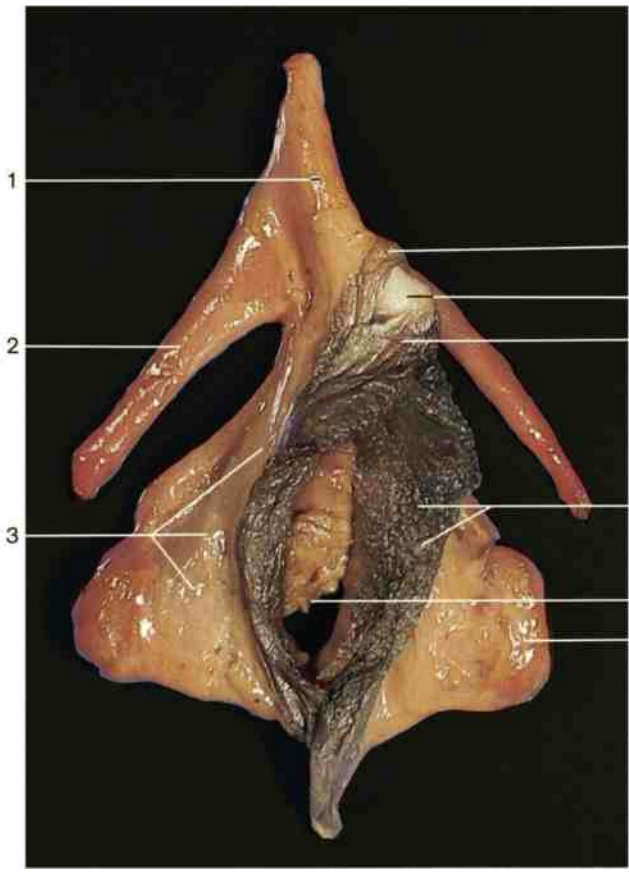


- 1 Glans of clitoris
- 2 Labium majus
- 3 Vestibule of vagina
- 4 Hymen
- 5 Posterior labial commissure
- 6 Body of clitoris
- 7 Labium minus
- 8 External orifice of urethra
- 9 Vaginal orifice
- 10 Ureter
- 11 Adnexa of uterus
- 12 Prepuce of clitoris
- 13 Crus of clitoris
- 14 Greater vestibular glands
- 15 Anus and internal anal sphincter muscle
- 16 Median umbilical ligament containing urachus
- 17 Urinary bladder
- 18 Infundibulum of uterine tube
- 19 Ovary
- 20 Ampulla of uterine tube
- 21 Suspensory ligament of the ovary
- 22 Bulbospongiosus muscle and bulb of vestibule
- 23 Central tendon of perineum (perineal body)
- 24 External anal sphincter muscle

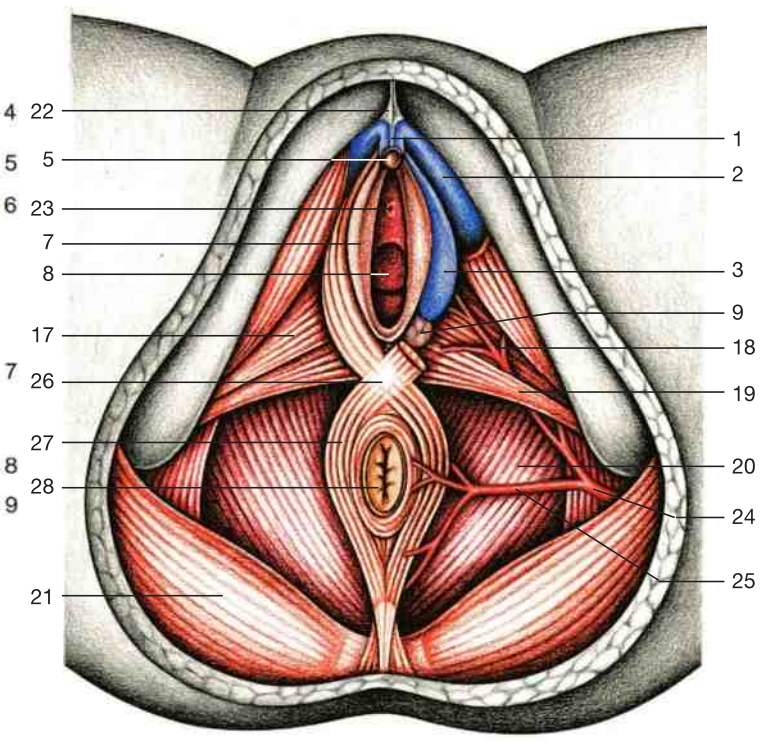
Female external genital organs (anterior aspect). Labia reflected.



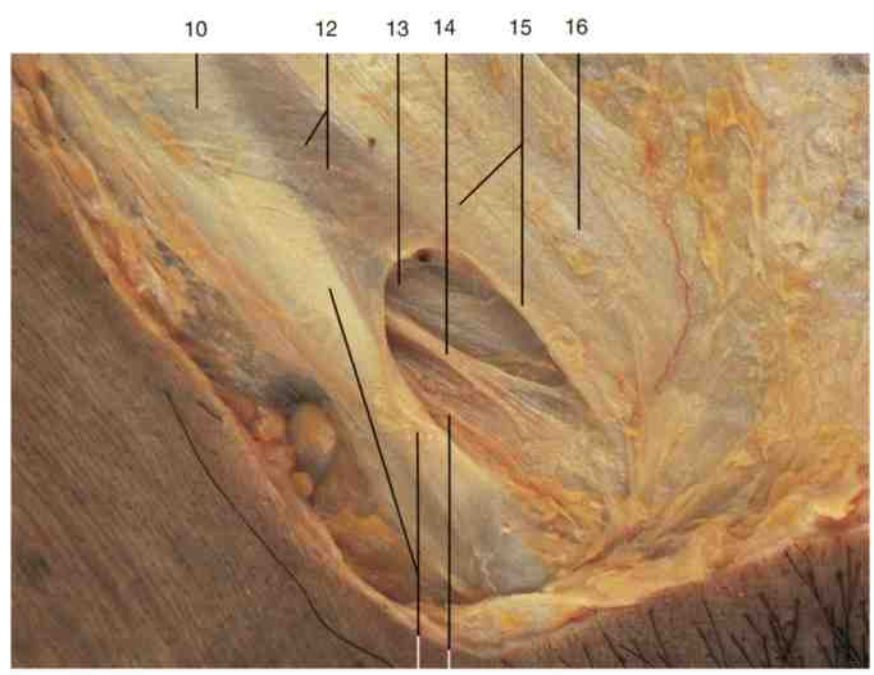
Female external genital organs in relation to internal genital organs and urinary system, isolated (anterior aspect).



Cavernous tissue of female external genital organs, isolated (anterior aspect).

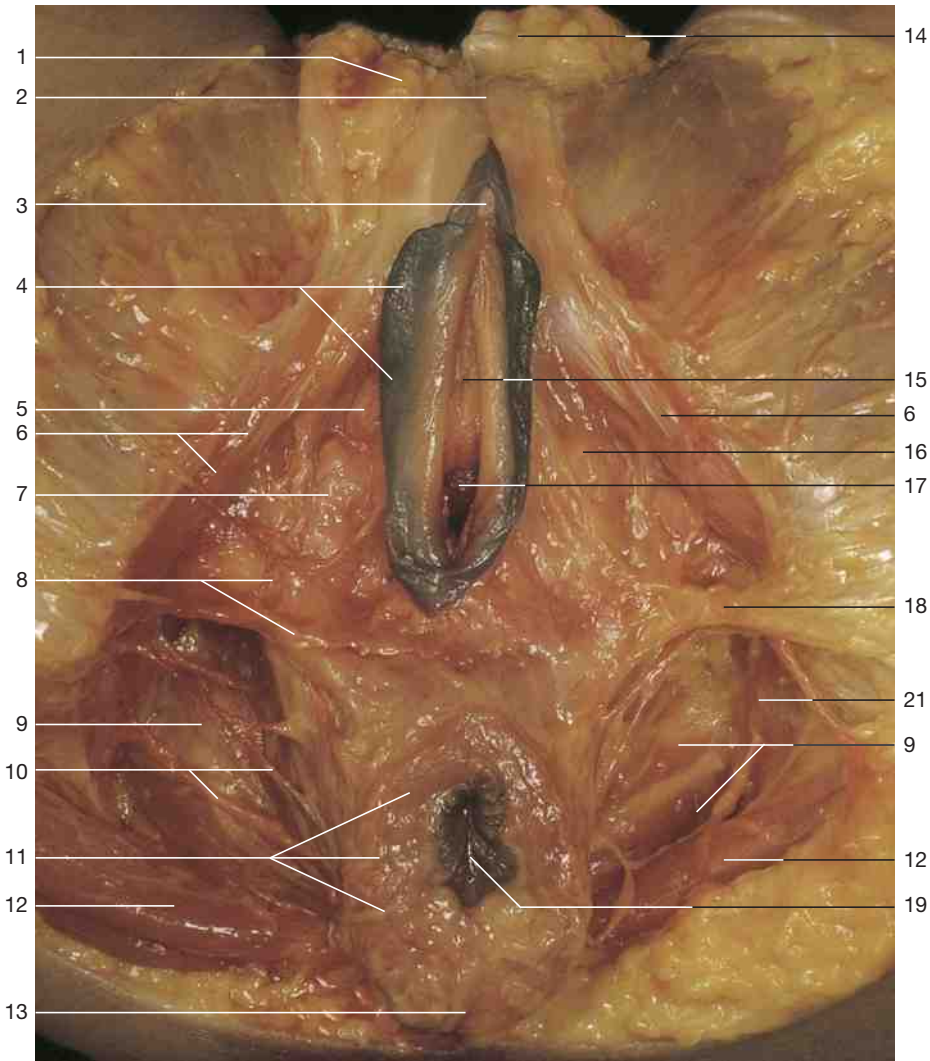


Urogenital and pelvic diaphragms (anterior aspect, schematic drawing). Blue = cavernous tissue of clitoris and bulb of vestibule.

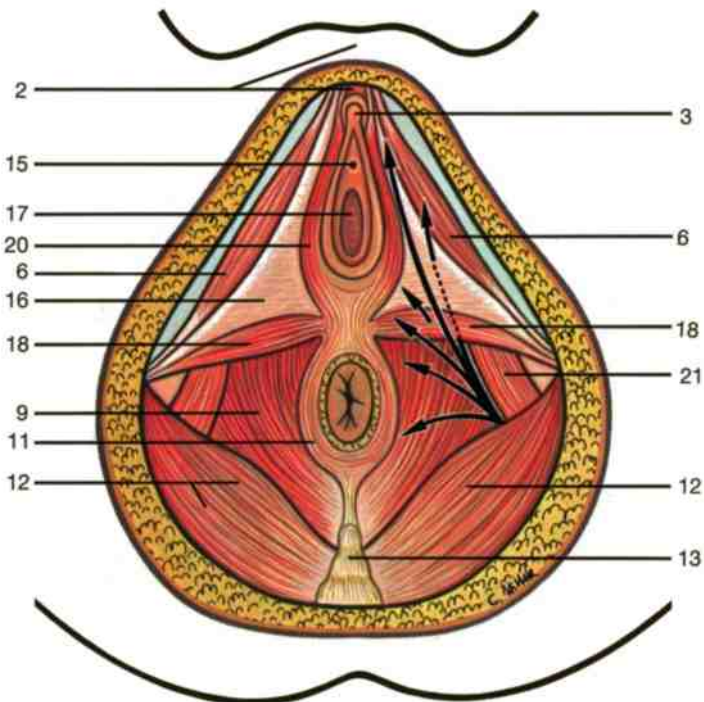


Inguinal canal and round ligament of uterus in situ (right side, ventral aspect).

- 1 Body of clitoris
- 2 Crus of clitoris
- 3 Bulb of vestibule
- 4 Prepuce of clitoris
- 5 Glans of clitoris
- 6 Frenulum of clitoris
- 7 Labium minus
- 8 Vaginal orifice
- 9 Greater vestibular gland
- 10 Lateral crus of superficial inguinal ring
- 11 Ilio-inguinal nerve
- 12 Intercrural fibers
- 13 Superficial inguinal ring
- 14 Round ligament of uterus
- 15 Medial crus of superficial inguinal ring
- 16 Aponeurosis of external abdominal oblique muscle
- 17 Deep transverse perineal muscle with fascia
- 18 Deep artery of clitoris
- 19 Superficial transverse perineus muscle
- 20 Levator ani muscle
- 21 Gluteus maximus muscle
- 22 Suspensory ligament of clitoris
- 23 External orifice of urethra
- 24 Internal pudendal artery
- 25 Inferior rectal artery
- 26 Perineal body
- 27 External anal sphincter muscle
- 28 Anus

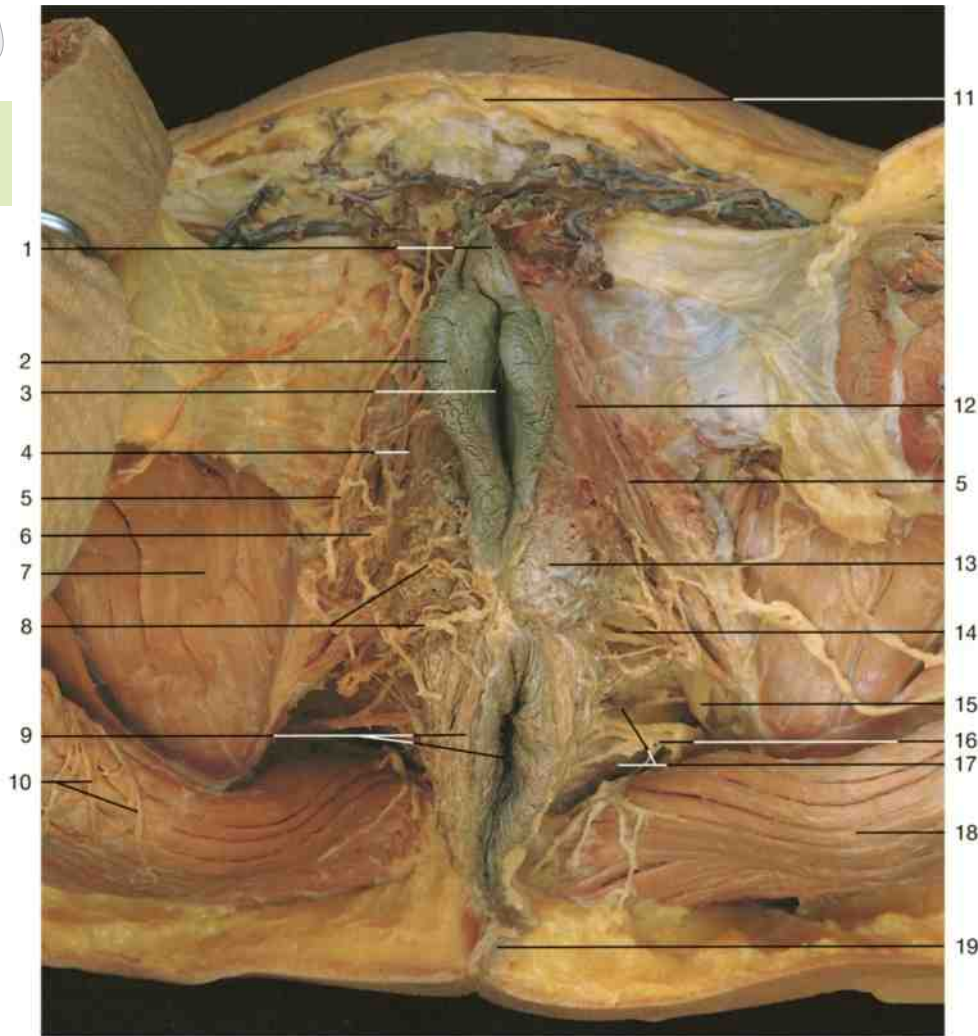


Urogenital diaphragm and external genital organs in the female, superficial layer (from below).

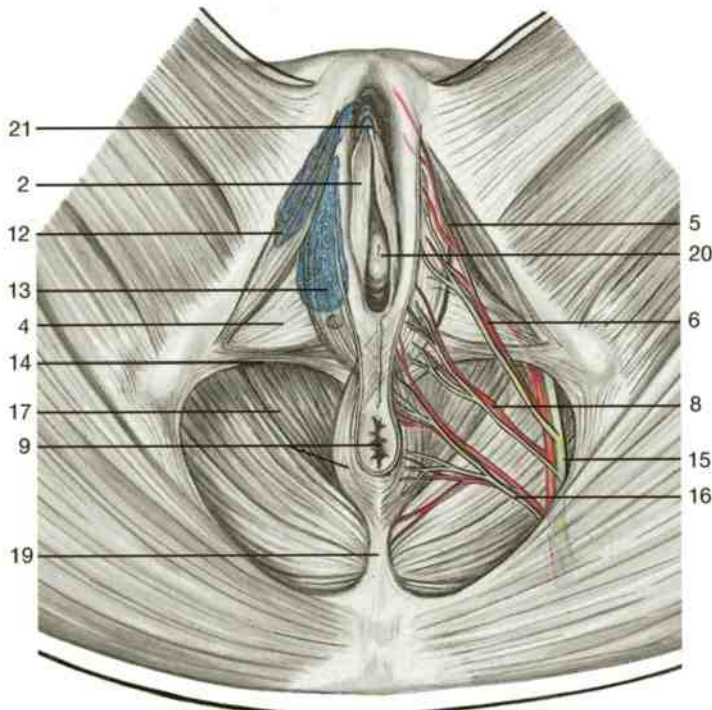


Muscles of pelvic and urogenital diaphragms in the female (from below, schematic drawing).

- 1 Fatty tissue encasing round ligament
- 2 Position of pubic symphysis
- 3 Clitoris
- 4 Labium minus
- 5 Bulb of vestibule
- 6 Ischiocavernosus muscle
- 7 Greater vestibular gland
- 8 Perineal branches of pudendal nerve
- 9 Levator ani muscle
- 10 Inferior rectal nerves
- 11 External anal sphincter muscle
- 12 Gluteus maximus muscle
- 13 Coccyx
- 14 Fatty tissue of mons pubis
- 15 External orifice of urethra
- 16 Urogenital diaphragm with fascia of deep transverse perineus muscle
- 17 Vaginal orifice
- 18 Superficial transverse perineal muscle
- 19 Anus
- 20 Bulbospongiosus muscle
- 21 Obturator internus muscle

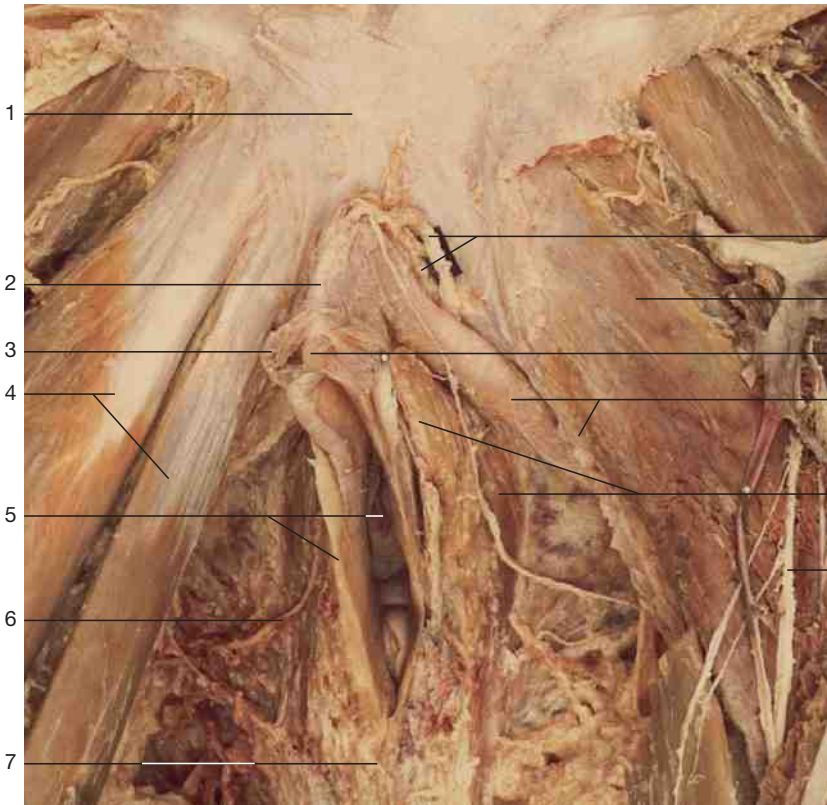


Urogenital diaphragm and external genital organs in the female, superficial layer (from below). On the right side the bulb of vestibule has been removed.



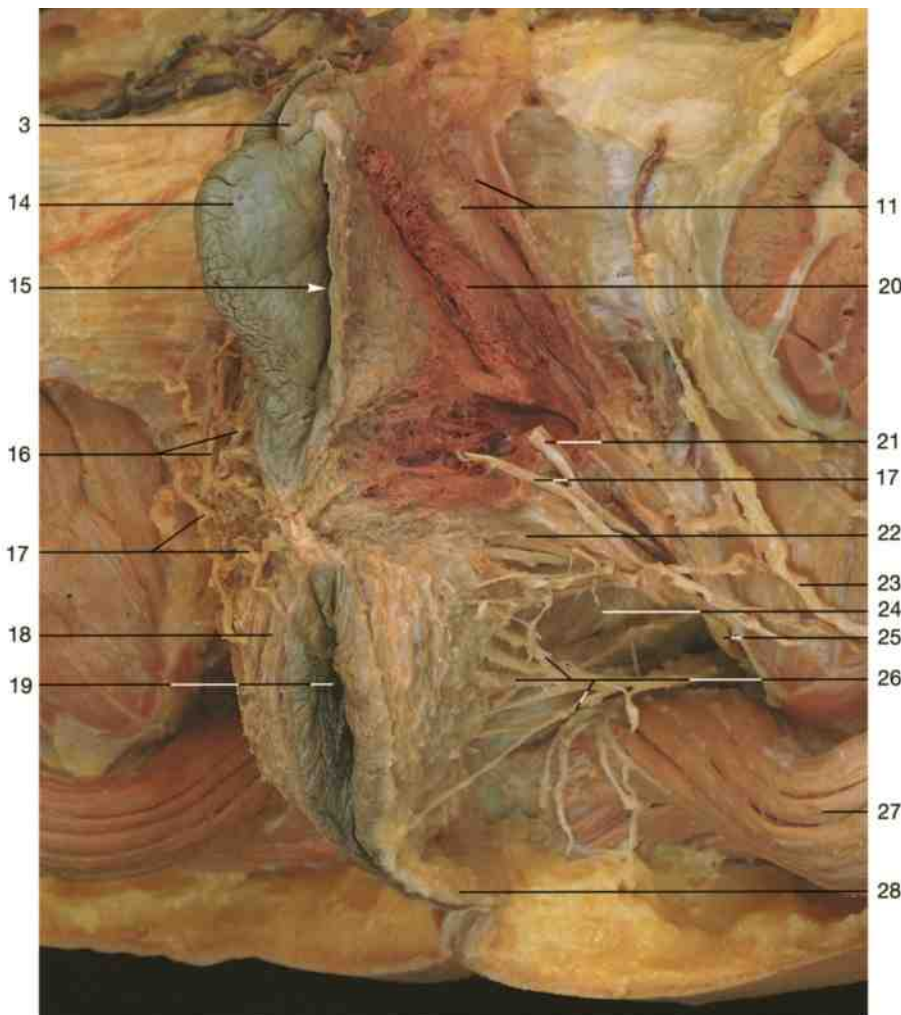
- 1 Prepuce of clitoris
- 2 Labium minus
- 3 Vaginal orifice
- 4 Deep transverse perineus muscle
- 5 Dorsal nerve of clitoris
- 6 Posterior labial nerves
- 7 Great adductor muscle
- 8 Perineal branches of pudendal nerve
- 9 Anus and external anal sphincter muscle
- 10 Inferior cluneal nerves
- 11 Mons pubis
- 12 Crus of clitoris with ischiocavernosus muscle
- 13 Bulb of vestibule
- 14 Superficial transverse perineus muscle
- 15 Pudendal nerve and internal pudendal artery
- 16 Inferior rectal nerves
- 17 Levator ani muscle
- 18 Gluteus maximus muscle
- 19 Anococcygeal ligament
- 20 External urethral orifice
- 21 Glans of clitoris

External female genital organs. Position of arteries and nerves; bulb of vestibule in blue (schematic drawing).

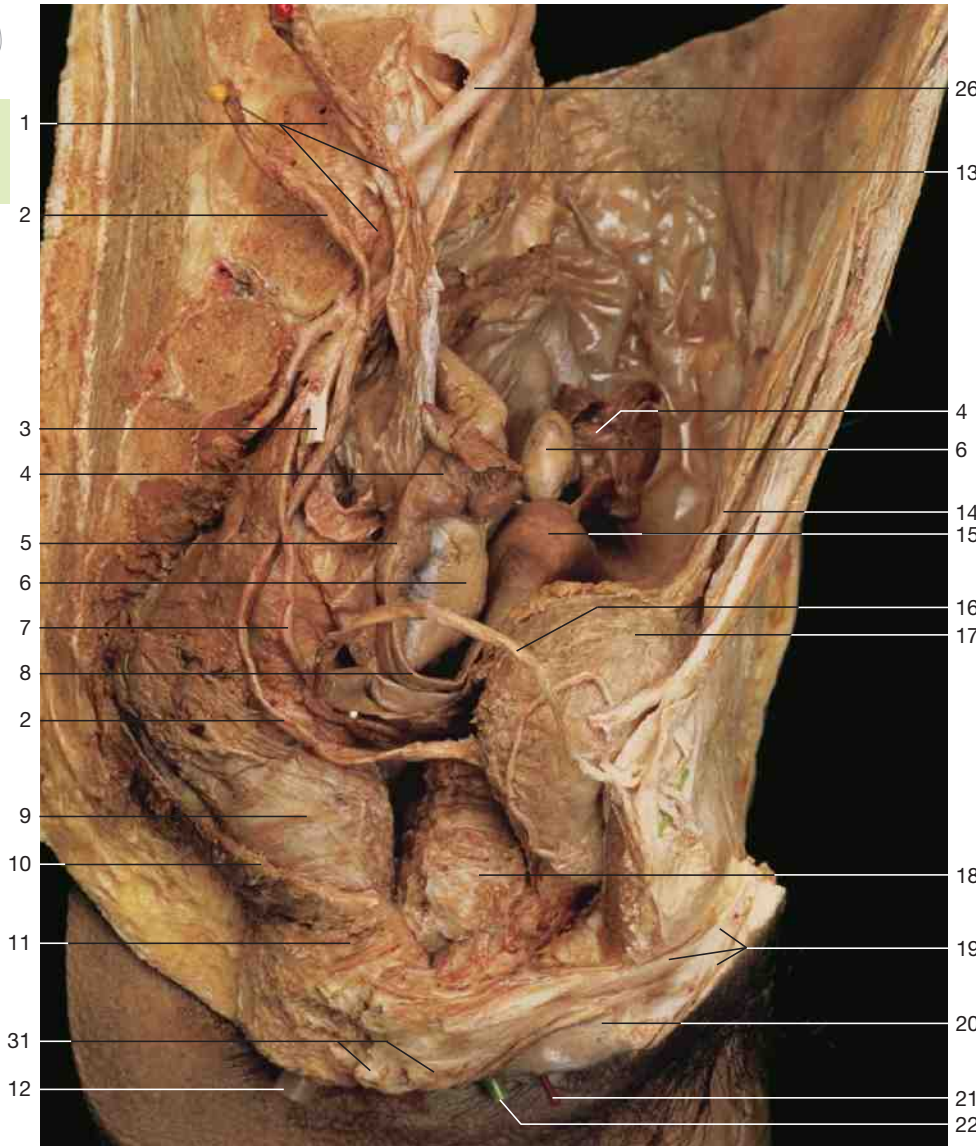


- 1 Position of pubic symphysis
- 2 Body of clitoris
- 3 Prepuce of clitoris
- 4 Adductor longus and gracilis muscles
- 5 External orifice of vagina and labium minus
- 6 Posterior labial nerve
- 7 Perineal body
- 8 Deep artery of clitoris and dorsal nerve of clitoris
- 9 Adductor brevis muscle
- 10 Glans of clitoris
- 11 Crus of clitoris and ischiocavernosus muscle
- 12 Bulb of vestibule and bulbospongiosus muscle
- 13 Anterior branch of obturator nerve
- 14 Labium minus
- 15 Vaginal orifice
- 16 Posterior labial nerves
- 17 Branches of pudendal nerve
- 18 External sphincter of anus
- 19 Anus
- 20 Bulb of vestibule (divided)
- 21 Dorsal artery of clitoris
- 22 Superficial transverse perineus muscle
- 23 Perineal branch of posterior femoral cutaneous nerve
- 24 Levator ani muscle
- 25 Pudendal nerve and internal pudendal artery
- 26 Inferior rectal nerves
- 27 Gluteus maximus muscle
- 28 Anococcygeal ligament

External genital organs in the female (inferior aspect). The clitoris has been dissected and slightly reflected to the right. The prepuce of clitoris has been divided to display the glans.



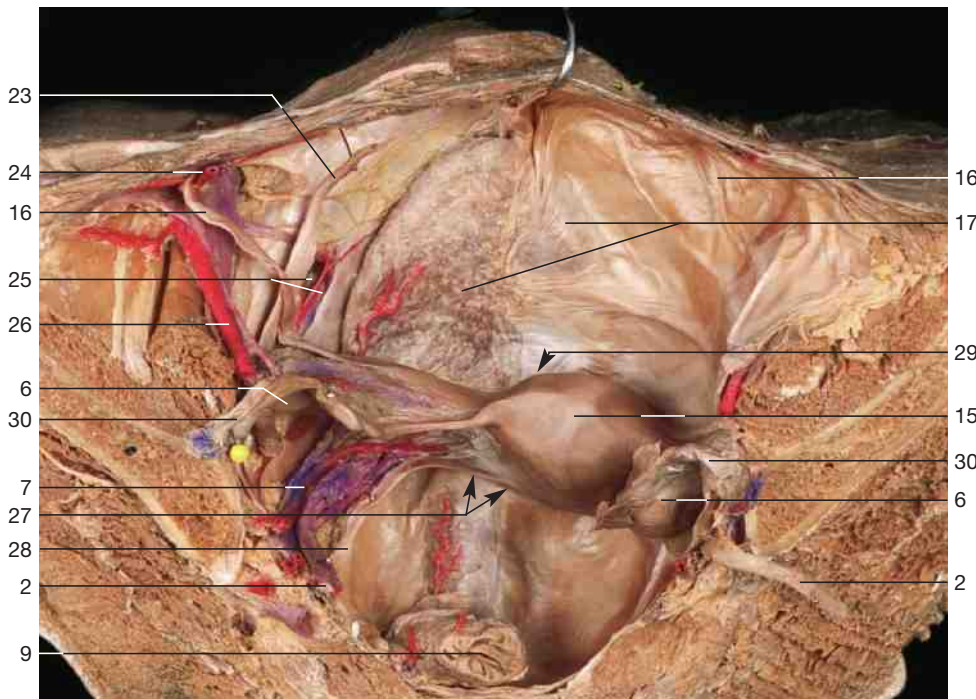
Urogenital diaphragm and external genital organs in the female (latero-inferior aspect). The bulb of vestibule has partly been removed; the left labium minus was cut away.



- 1
- 2
- 3
- 4
- 5
- 6
- 7
- 8
- 2
- 9
- 10
- 11
- 31
- 12

- 1 Body of fifth lumbar vertebra, suspensory ligament of ovary, and sacral promontory
- 2 Ureter
- 3 Medial umbilical ligament (remnant of umbilical artery) (cut)
- 4 Infundibulum of uterine tube
- 5 Ampulla of uterine tube
- 6 Ovary
- 7 Uterine artery
- 8 Uterine tube
- 9 Rectum
- 10 Levator ani muscle (pelvic diaphragm – cut edge)
- 11 External anal sphincter muscle
- 12 Anus (probe)
- 13 Internal iliac artery
- 14 Remnant of urachus (median umbilical ligament)
- 15 Uterus
- 16 Round ligament of uterus
- 17 Urinary bladder
- 18 Vagina
- 19 Clitoris
- 20 Labium minus
- 21 External orifice of urethra (red probe)
- 22 Vaginal orifice (green probe)
- 23 Lateral umbilical ligament
- 24 Inferior epigastric artery
- 25 Obturator artery, vein, and nerve
- 26 External iliac artery
- 27 Recto-uterine pouch (of Douglas)
- 28 Recto-uterine fold
- 29 Vesico-uterine pouch
- 30 Suspensory ligament of ovary
- 31 Greater vestibular gland and bulb of the vestibule

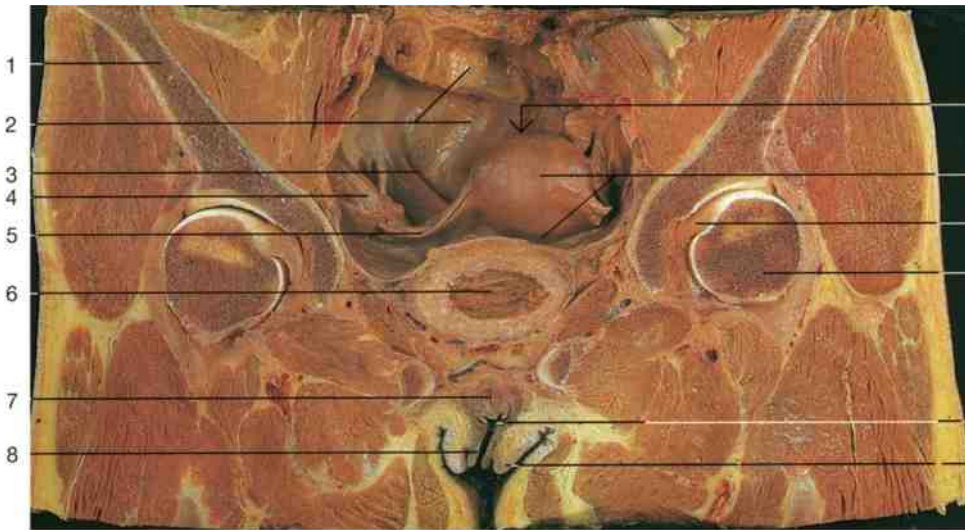Pelvic cavity in the female, internal genital organs in situ (lateral aspect). Right half of the pelvis and sacrum have been removed.



- 23
- 24
- 16
- 25
- 26
- 6
- 30
- 7
- 27
- 28
- 2
- 9

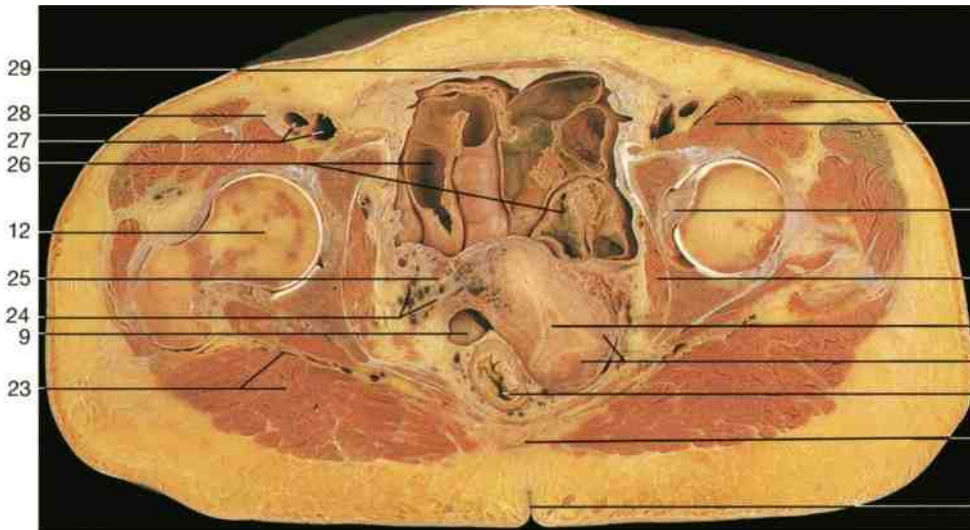
- 16
- 17
- 29
- 15
- 30
- 6
- 2

Pelvic cavity in the female, internal genital organs in situ (seen from above). The peritoneum at the left half of pelvic cavity has been removed to display uterine tube, vessels, and nerves.

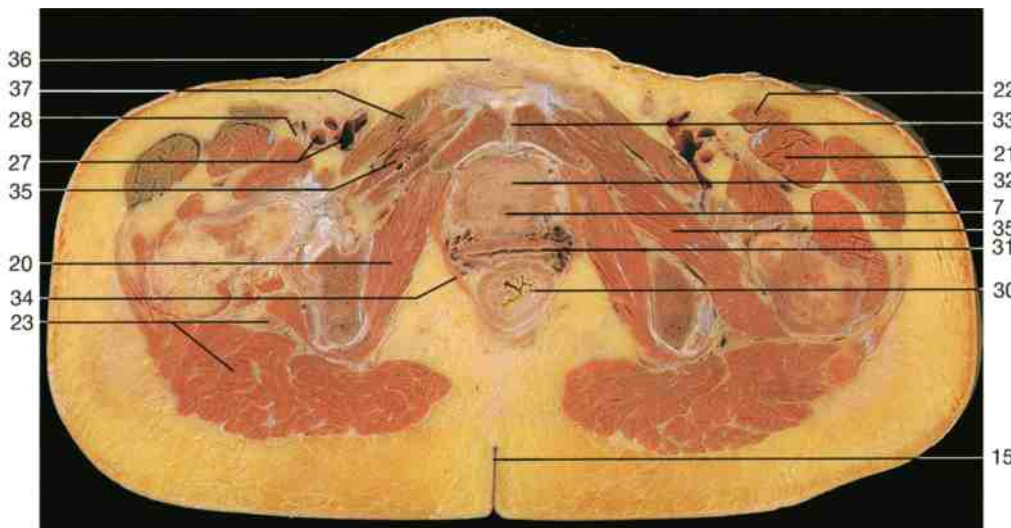


Coronal section through the pelvic cavity of the female (cf. MRI scan on p. 355).

- 1 Ilium
- 2 Rectum
- 3 Recto-uterine fold
- 4 Ovary
- 5 Uterine tube
- 6 Urinary bladder
- 7 Urethra
- 8 Labium minus
- 9 Recto-uterine pouch of Douglas
- 10 Uterus (utero-vesical pouch)
- 11 Ligament of the head of the femur
- 12 Head of femur
- 13 Vestibule of vagina
- 14 Labium majus
- 15 Anal cleft
- 16 Coccyx
- 17 Rectum
- 18 Myometrium of uterus
- 19 Uterine cavity
- 20 Obturator internus muscle
- 21 Iliopsoas muscle
- 22 Sartorius muscle
- 23 Sciatic nerve and gluteus maximus muscle
- 24 Uterine venous plexus
- 25 Broad ligament
- 26 Small intestine
- 27 Femoral artery and vein
- 28 Femoral nerve
- 29 Pyramidalis muscle
- 30 Rectum (anal canal)
- 31 Vagina
- 32 Urethral sphincter muscle (base of urinary bladder)
- 33 Pubic symphysis
- 34 Levator ani muscle
- 35 Obturator externus muscle
- 36 Mons pubis
- 37 Pectineus muscle



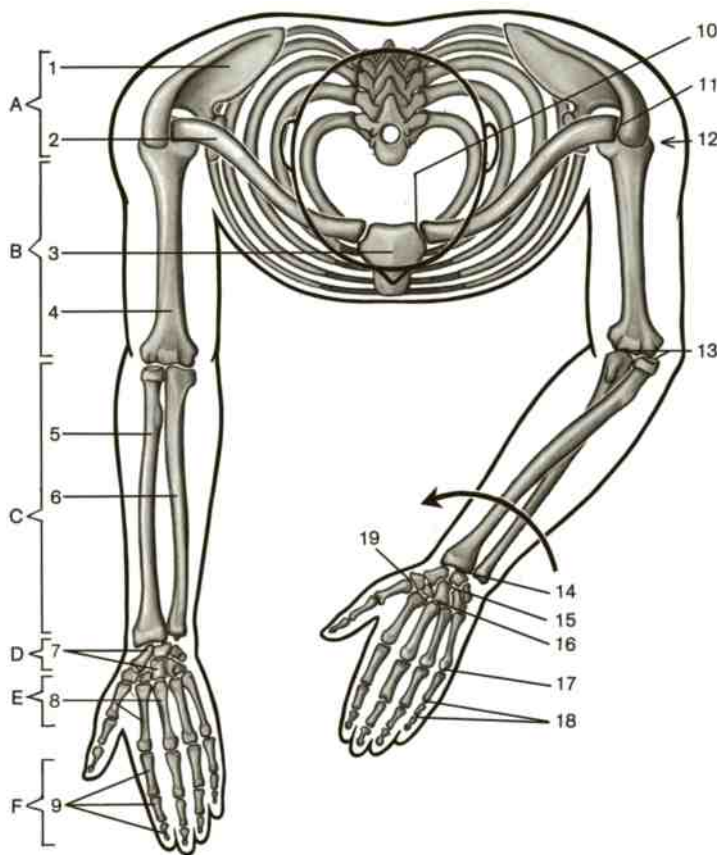
Horizontal section through the pelvic cavity of the female at level of uterus (from below). The uterus is retroverted to the left.



Horizontal section through the pelvic cavity of the female at level of the urethral sphincter and vagina (from below).



7 Upper Limb



A = Shoulder girdle
 B = Arm
 C = Forearm
 D = Wrist
 E = Palm of hand
 F = Finger

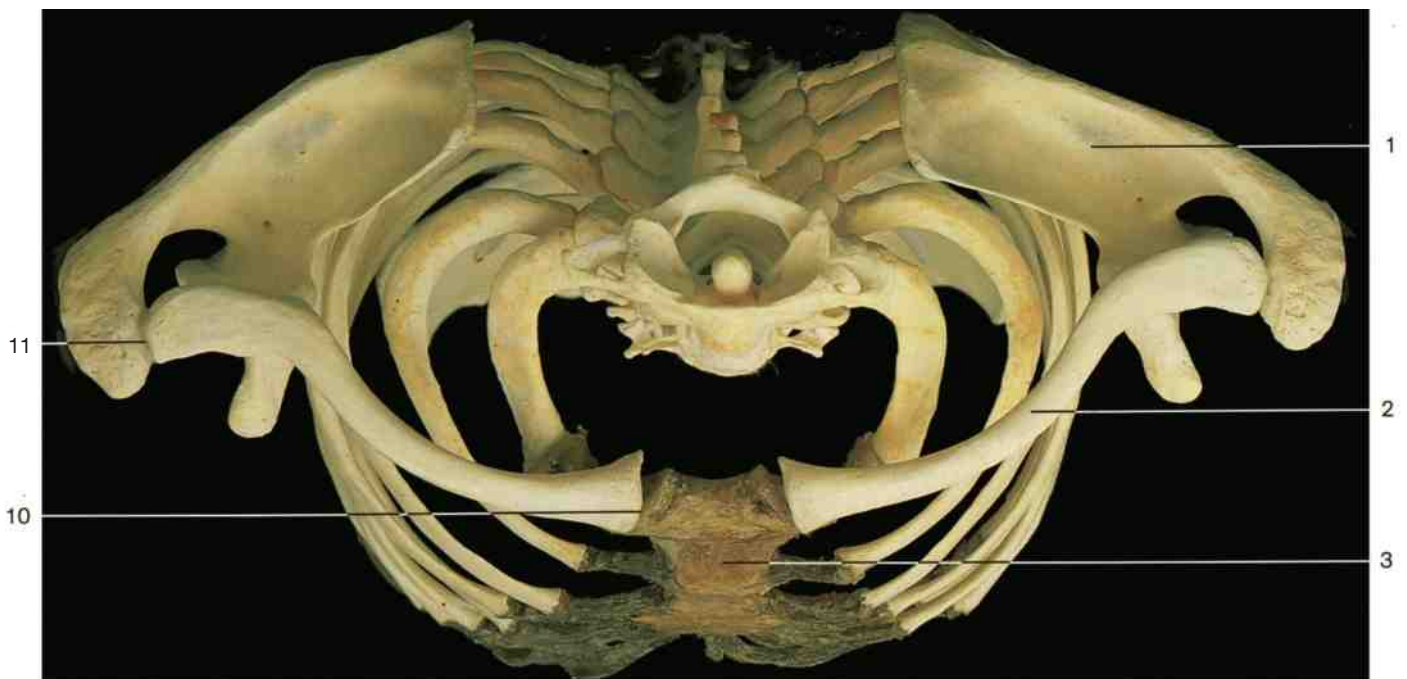
Bones

- 1 Scapula
- 2 Clavicle
- 3 Sternum
- 4 Humerus
- 5 Radius
- 6 Ulna
- 7 Carpals bones
- 8 Metacarpal bones
- 9 Phalanges

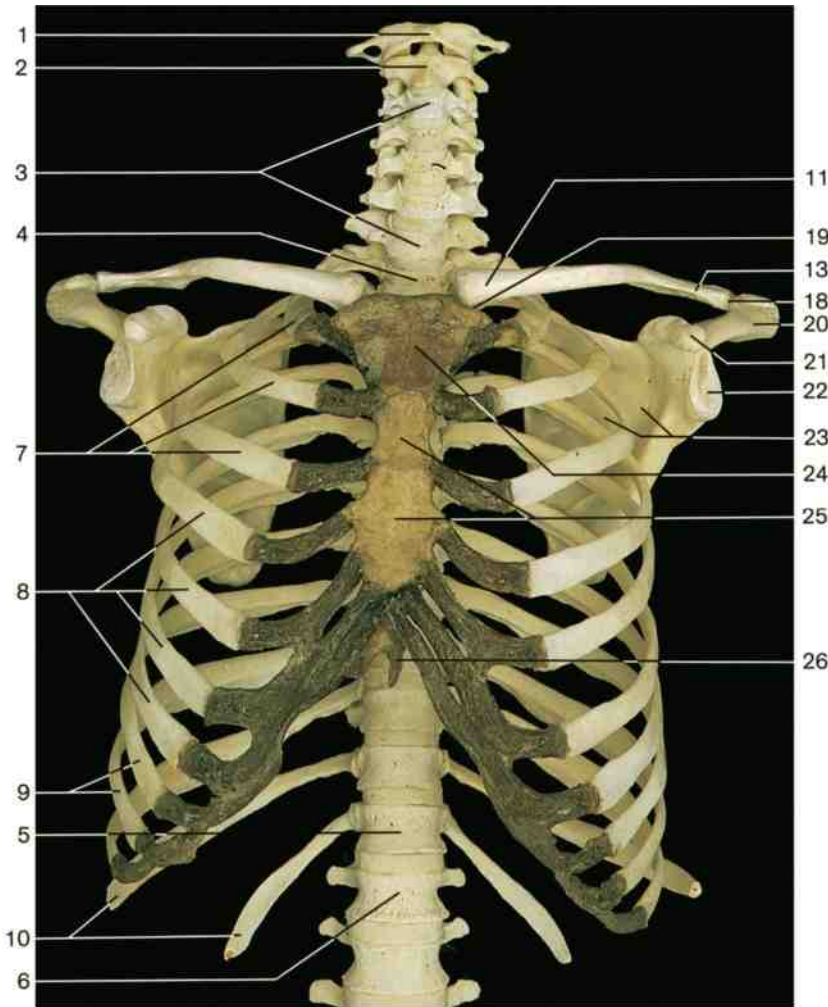
Joints

- 10 Sternoclavicular joint
- 11 Acromioclavicular joint
- 12 Shoulder joint
- 13 Elbow joint
- 14 Wrist joint
- 15 Midcarpal joint
- 16 Carpometacarpal joint
- 17 Metacarpophalangeal joint
- 18 Interphalangeal joints of the hand
- 19 Carpometacarpal joint of thumb

Organization of shoulder girdle and upper limb (superior aspect). The two positions of the forearm essential to manual skills in the human, supination (right arm) and pronation (left arm), are shown.



Bones of shoulder girdle articulated with the thorax (superior aspect).



Vertebral column

- 1 Atlas
- 2 Axis
- 3 Third–seventh cervical vertebrae
- 4 First thoracic vertebra
- 5 Twelfth thoracic vertebra
- 6 First lumbar vertebra

Ribs

- 7 First–third ribs } True ribs
- 8 Fourth–seventh ribs }
- 9 Eighth–tenth ribs } False ribs
- 10 Eleventh and twelfth ribs } (floating ribs)

Clavicle

- 11 Sternal end
- 12 Articular facet for sternum
- 13 Acromial end
- 14 Articular facet for acromion
- 15 Impression for costoclavicular ligament
- 16 Conoid tubercle
- 17 Trapezoid line
- 18 Site of acromioclavicular joint
- 19 Site of sternoclavicular joint

Scapula

- 20 Acromion
- 21 Coracoid process
- 22 Glenoid cavity
- 23 Costal surface

Sternum

- 24 Manubrium
- 25 Body
- 26 Xiphoid process

Skeleton of shoulder girdle and thorax (anterior aspect).
The cartilaginous parts of the ribs appear dark brown.

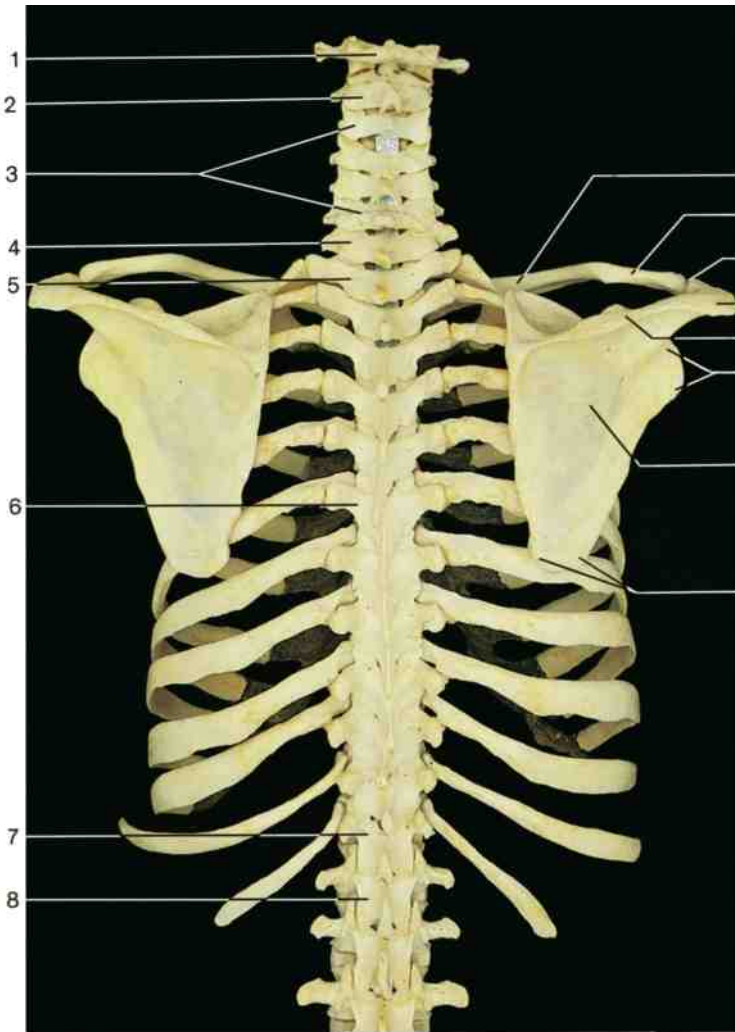


Right clavicle (superior aspect).

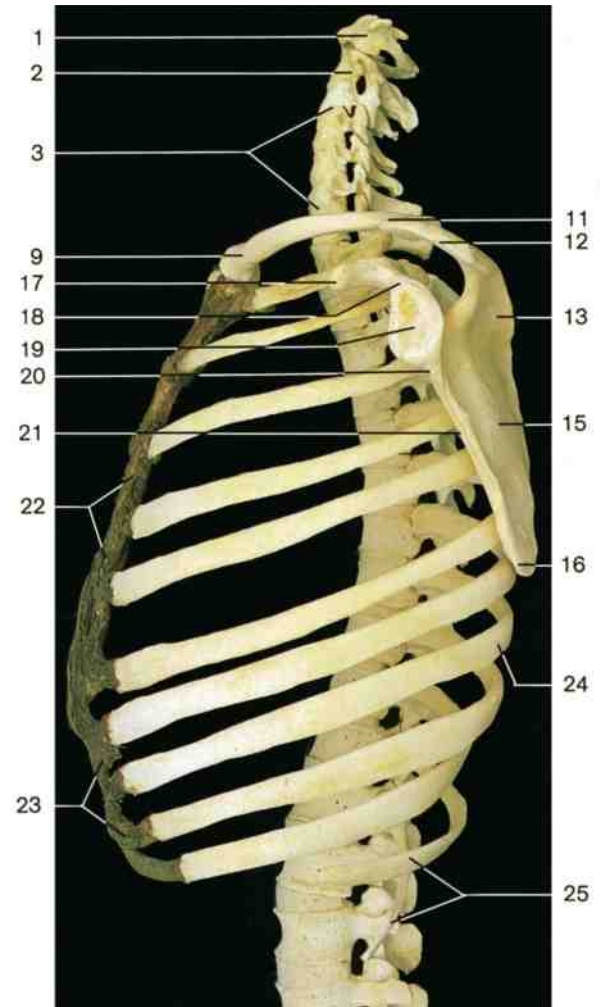


Right clavicle (inferior aspect).

Because of the human body's upright posture, the upper limb has developed a high degree of mobility. The shoulder girdle is to a great extent movable in the thorax and is connected with the trunk only by the sternoclavicular joint. A further characteristic of the forearm is the capacity for rotation (i.e., pronation and supination).



Skeleton of shoulder girdle and thorax (posterior aspect).



Skeleton of shoulder girdle and thorax (lateral aspect).

Vertebral column

- 1 Atlas
- 2 Axis
- 3 Third–sixth cervical vertebrae
- 4 Seventh vertebra (vertebra prominens)
- 5 First thoracic vertebra
- 6 Sixth thoracic vertebra
- 7 Twelfth thoracic vertebra
- 8 First lumbar vertebra

Clavicle

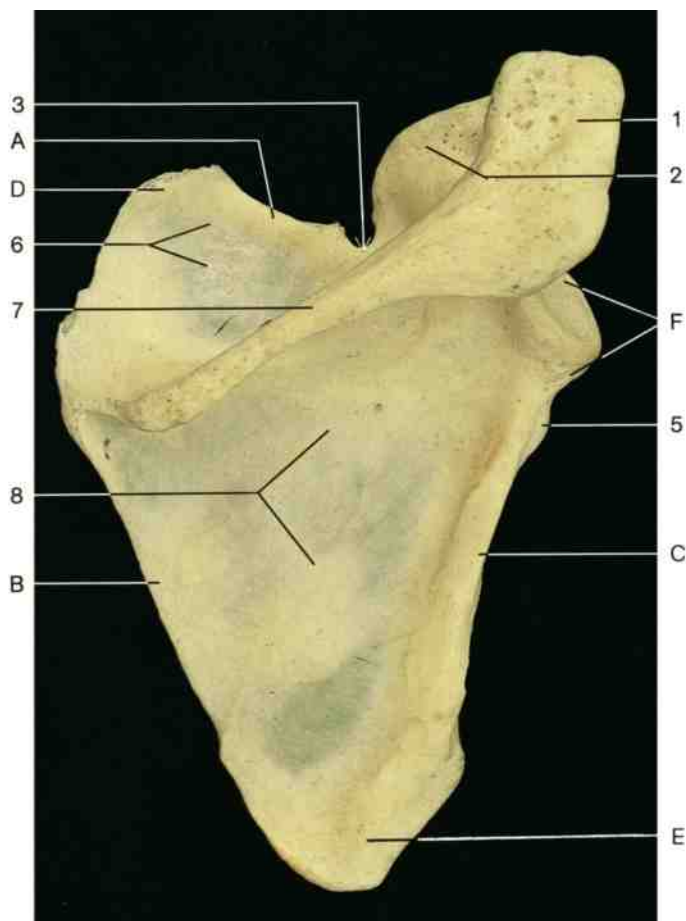
- 9 Sternal end
- 10 Acromial end
- 11 Site of acromioclavicular joint

Scapula

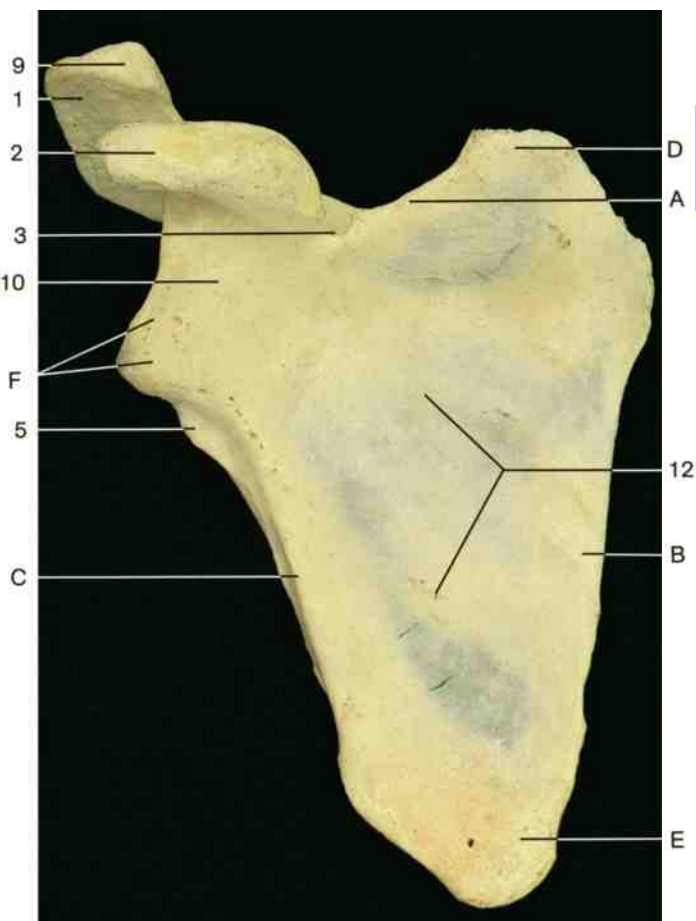
- 12 Acromion
- 13 Spine of scapula
- 14 Lateral angle
- 15 Posterior surface
- 16 Inferior angle
- 17 Coracoid process
- 18 Supraglenoid tubercle
- 19 Glenoid cavity
- 20 Infraglenoid tubercle
- 21 Lateral margin

Thorax

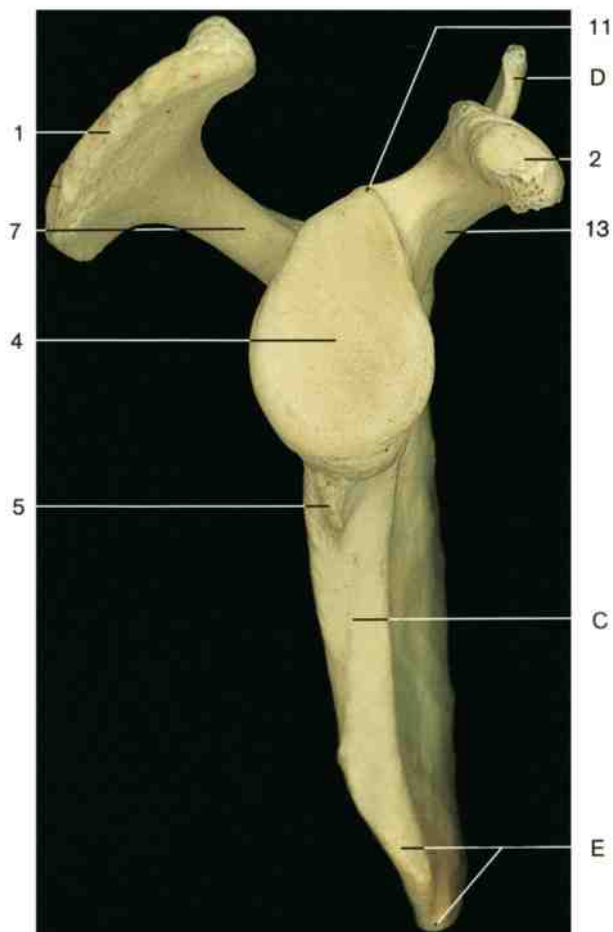
- 22 Body of sternum
- 23 Costal arch
- 24 Angle of ribs
- 25 Floating ribs



Right scapula (posterior aspect).



Right scapula (anterior aspect, costal surface).

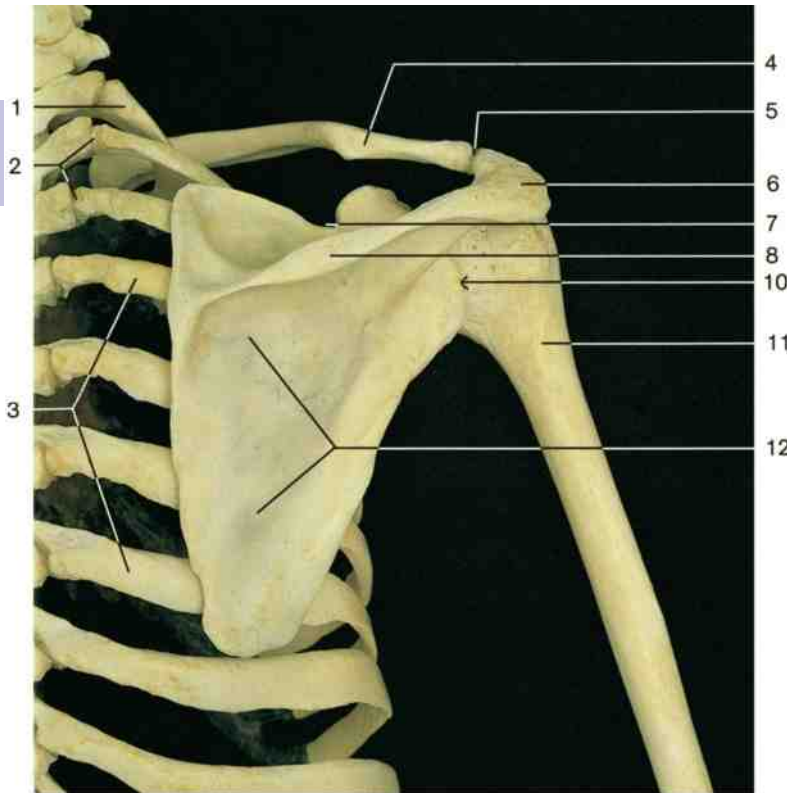


Right scapula (lateral aspect).

Scapula

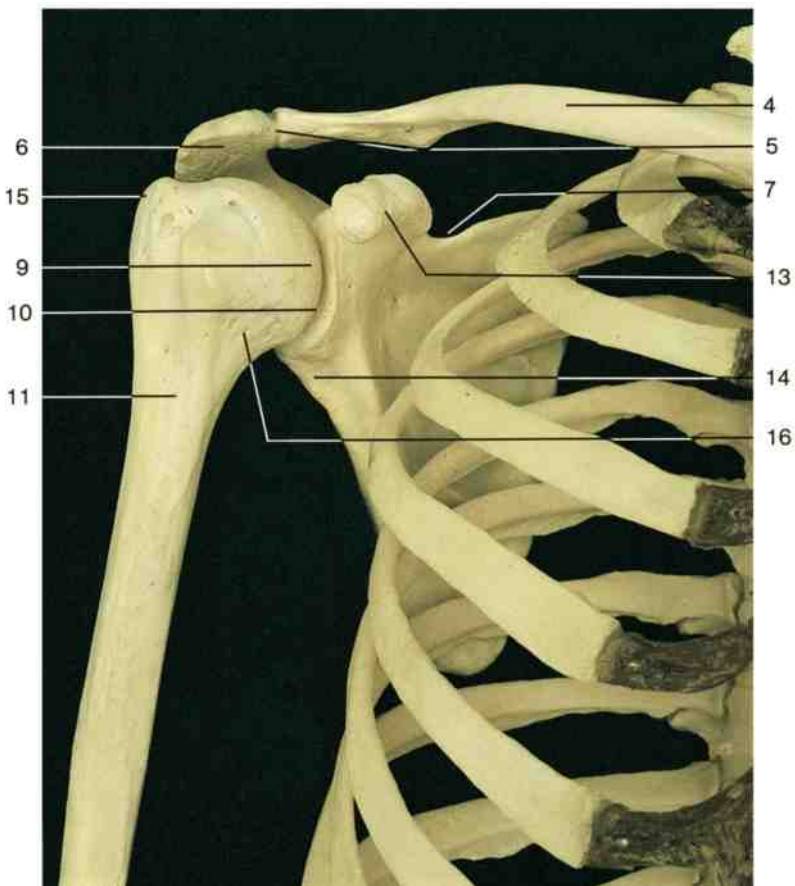
- A = superior border
- B = medial border
- C = lateral border
- D = superior angle
- E = inferior angle
- F = lateral angle

- 1 Acromion
- 2 Coracoid process
- 3 Scapular notch
- 4 Glenoid cavity
- 5 Infraglenoid tubercle
- 6 Supraspinous fossa
- 7 Spine
- 8 Infraspinous fossa
- 9 Articular facet for acromion
- 10 Neck
- 11 Supraglenoid tubercle
- 12 Costal (anterior) surface
- 13 Base of coracoid process




- 1 First rib
- 2 Position of costotransverse joints
- 3 Fourth–seventh ribs
- 4 Clavicle
- 5 Position of acromioclavicular joint
- 6 Acromion
- 7 Scapular notch
- 8 Spine of scapula
- 9 Head of humerus
- 10 Glenoid cavity
- 11 Surgical neck of humerus
- 12 Posterior surface of scapula
- 13 Coracoid process
- 14 Infraglenoid tubercle
- 15 Greater tubercle of humerus
- 16 Anatomical neck of humerus

Bones of shoulder joint (posterior aspect).




Bones of shoulder joint (anterior aspect).



Right humerus (anterior aspect).



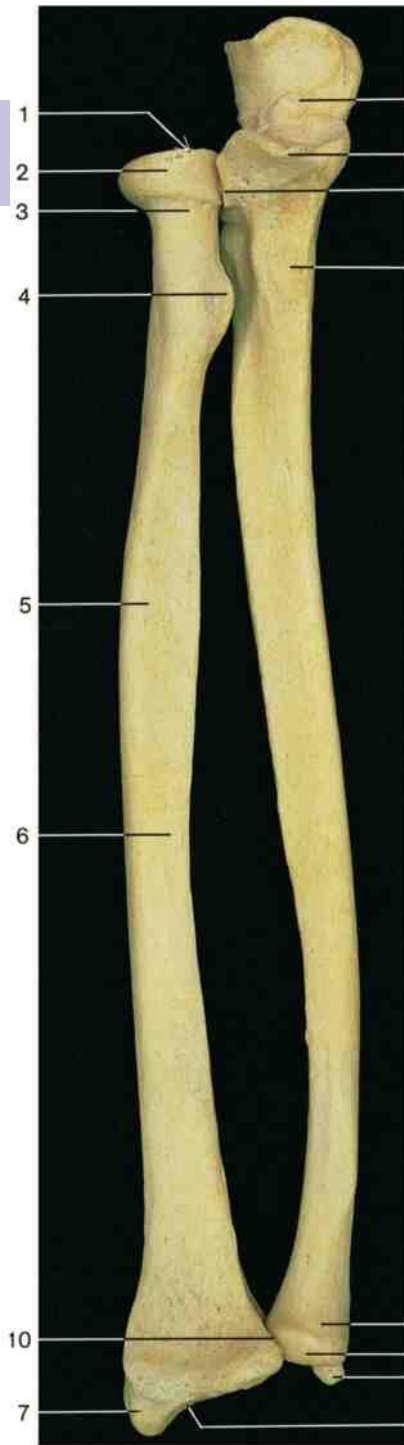
Right humerus (medial aspect).



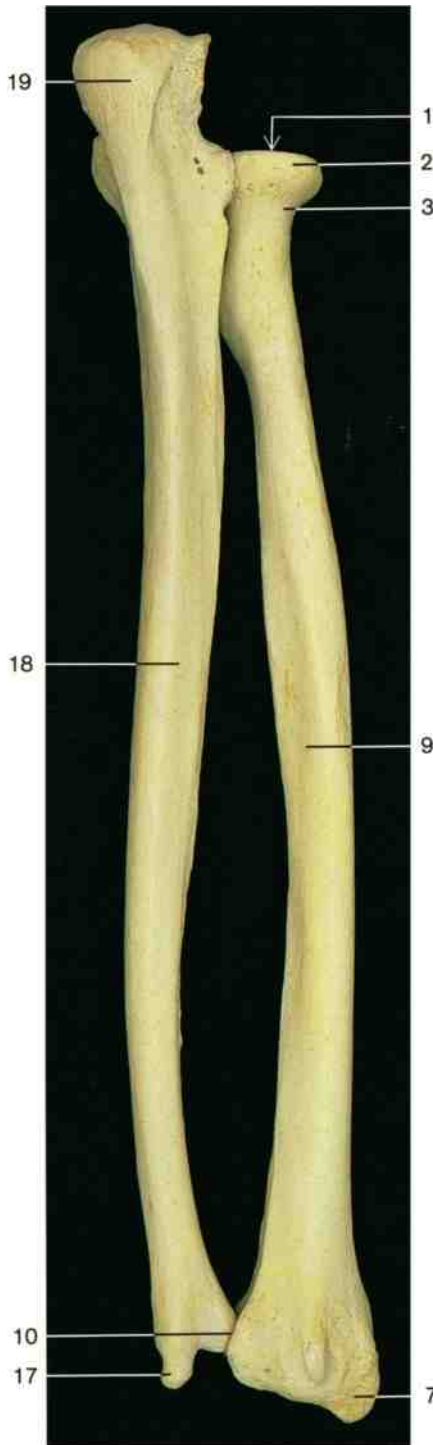
Right humerus (posterior aspect).

Humerus

- | | | | |
|-----------------------------|-------------------------------|-------------------------------|----------------------------|
| 1 Greater tubercle | 7 Deltoid tuberosity | 13 Head | 19 Trochlea |
| 2 Lesser tubercle | 8 Anterolateral surface | 14 Anatomical neck | 20 Posterior surface |
| 3 Crest of lesser tubercle | 9 Lateral supracondylar ridge | 15 Anteromedial surface | 21 Groove for ulnar nerve |
| 4 Crest of greater tubercle | 10 Radial fossa | 16 Medial supracondylar ridge | 22 Groove for radial nerve |
| 5 Intertubercular sulcus | 11 Lateral epicondyle | 17 Coronoid fossa | 23 Olecranon fossa |
| 6 Surgical neck | 12 Capitulum | 18 Medial epicondyle | |



Bones of right forearm, radius, and ulna (anterior aspect).



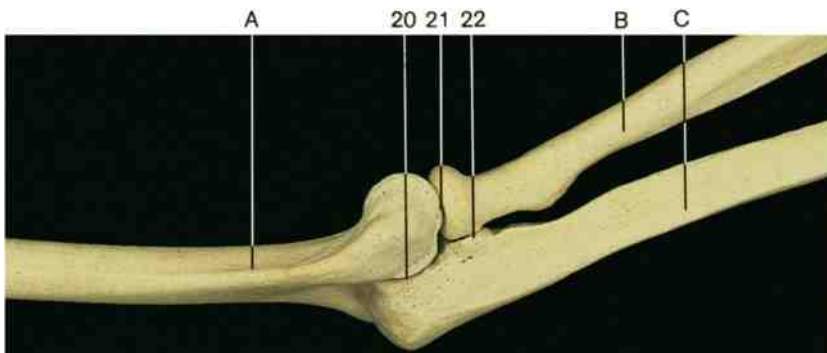
Bones of right forearm, radius, and ulna (posterior aspect).

Radius

- 1 Head
- 2 Articular circumference
- 3 Neck
- 4 Radial tuberosity
- 5 Shaft
- 6 Anterior surface
- 7 Styloid process
- 8 Articular surface
- 9 Posterior surface
- 10 Ulnar notch

Ulna

- 11 Trochlear notch
- 12 Coronoid process
- 13 Radial notch
- 14 Ulnar tuberosity
- 15 Head
- 16 Articular circumference
- 17 Styloid process
- 18 Posterior surface
- 19 Olecranon

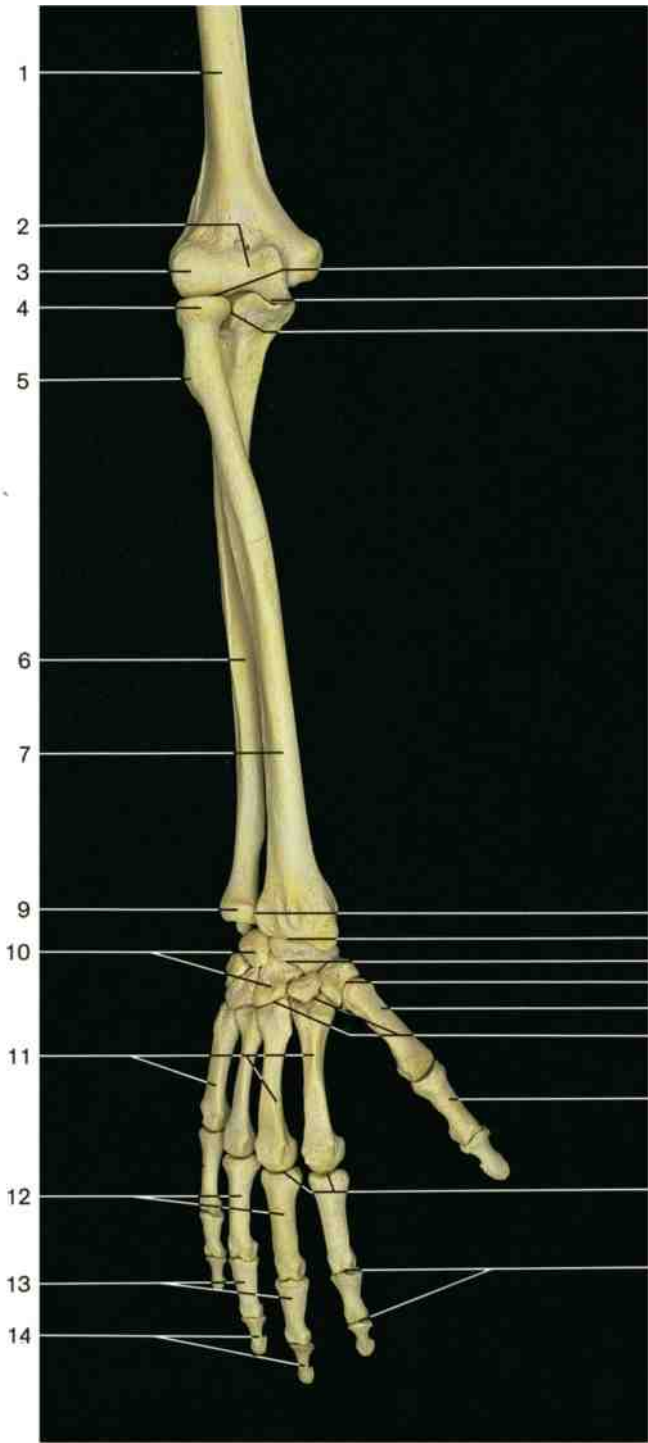


Bones of right elbow joint (lateral aspect).

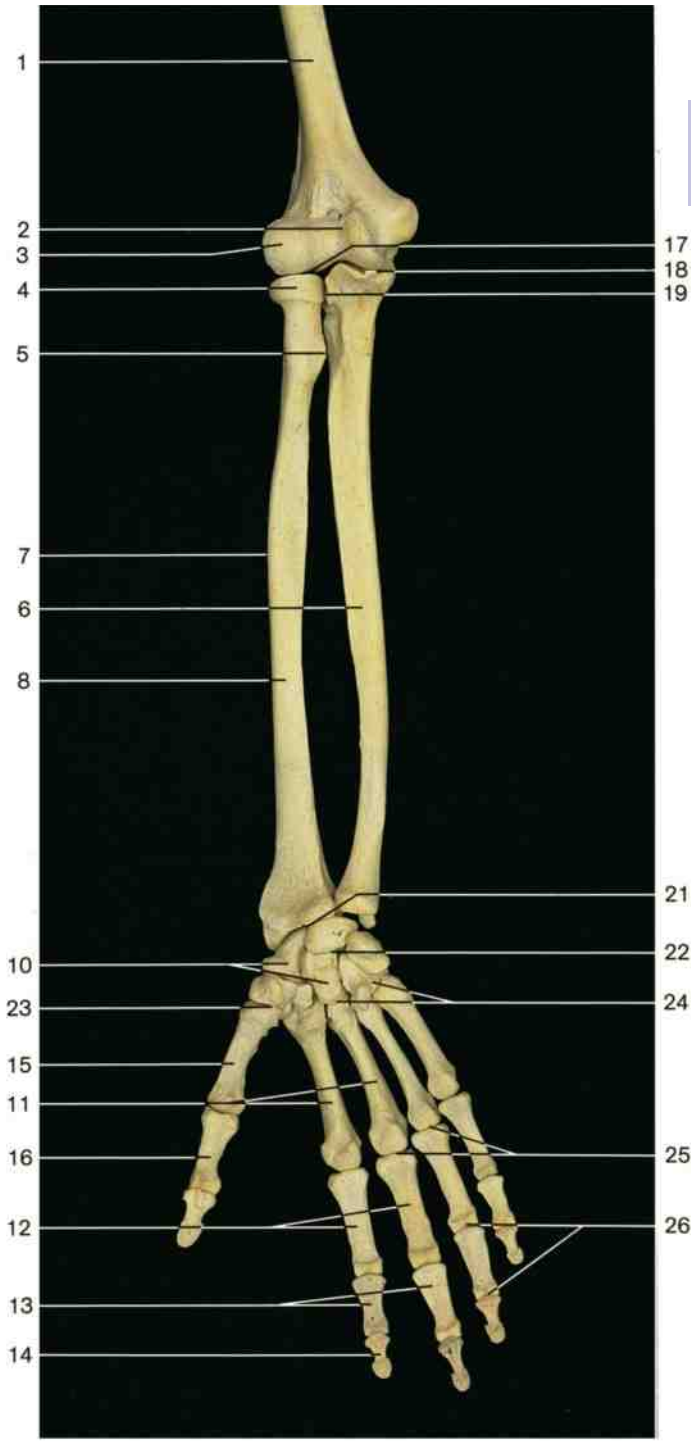
Articulations at the right elbow

- 20 Site of humero-ulnar joint
- 21 Site of humero-radial joint
- 22 Site of proximal radio-ulnar joint

- A = humerus
- B = radius
- C = ulna



Skeleton of right forearm and hand in pronation.



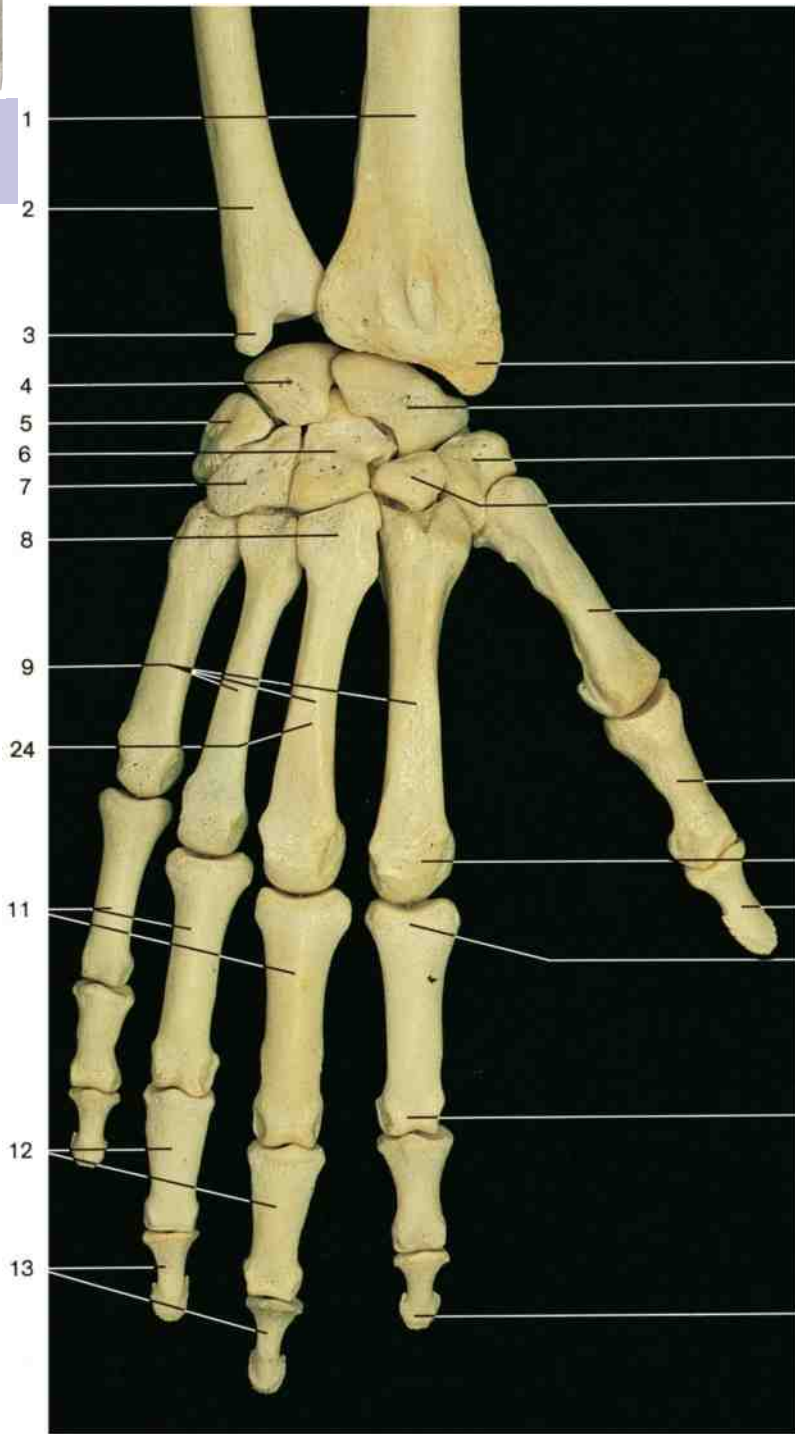
Skeleton of right forearm and hand in supination.

- 1 Humerus
- 2 Trochlea of humerus
- 3 Capitulum of humerus
- 4 Articular circumference of radius
- 5 Radial tuberosity
- 6 Anterior surface of ulna
- 7 Posterior surface of radius
- 8 Anterior surface of radius

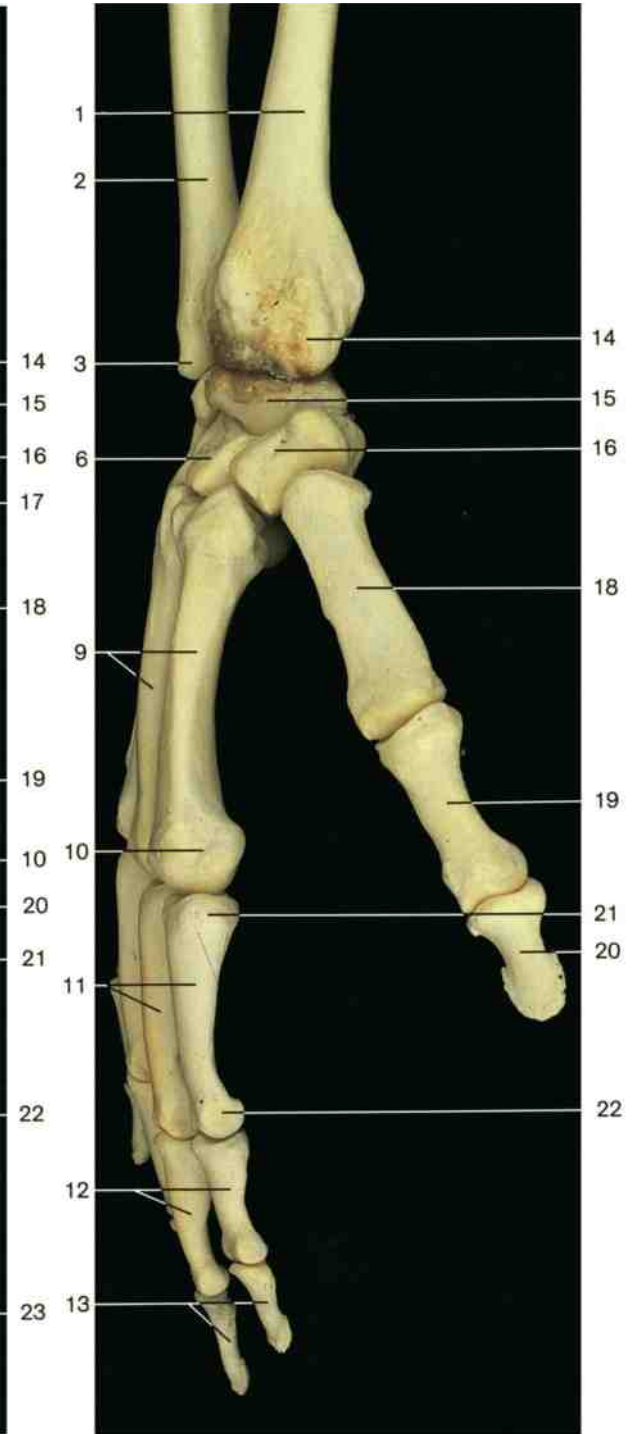
- 9 Articular circumference of ulna
- 10 Carpals bones
- 11 Metacarpal bones
- 12 Proximal phalanges
- 13 Middle phalanges
- 14 Distal phalanges
- 15 Metacarpal bone of thumb
- 16 Proximal phalanx of thumb

Sites of joints

- 17 Humeroradial joint
- 18 Humero-ulnar joint
- 19 Proximal radio-ulnar joint
- 20 Distal radio-ulnar joint
- 21 Wrist joint
- 22 Midcarpal joint
- 23 Carpometacarpal joint of thumb
- 24 Carpometacarpal joints
- 25 Metacarpophalangeal joints
- 26 Interphalangeal joints of the hand

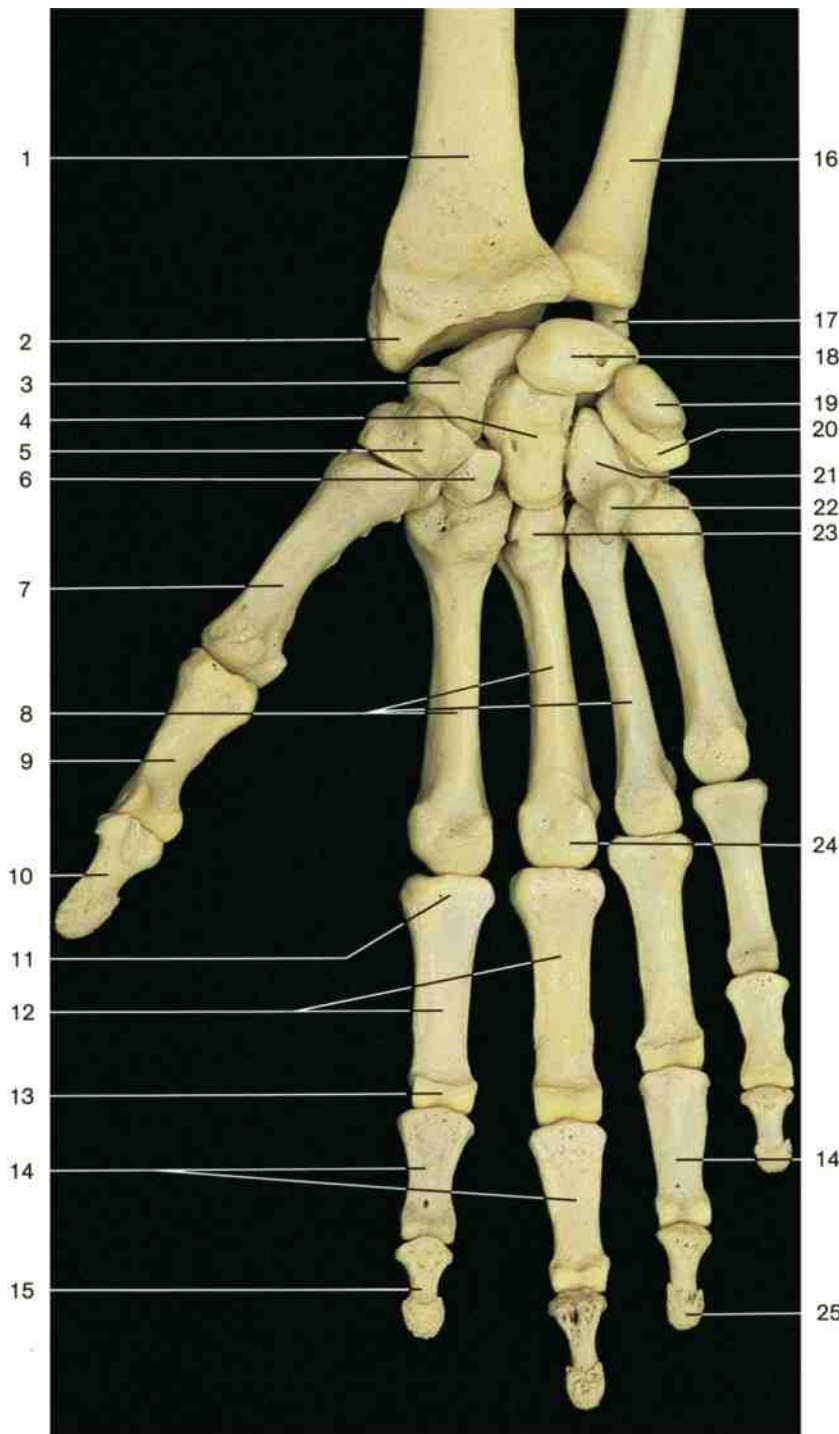


Skeleton of right wrist and hand (dorsal aspect).



Skeleton of right wrist and hand (medial aspect).

- | | | | | |
|---------------------------|---------------------------------|------------------------------------|----------------|------------------------------------|
| 1 Radius | 8 Base of third metacarpal bone | 15 Scaphoid bone | } Carpal bones | 22 Head of second proximal phalanx |
| 2 Ulna | 9 Metacarpal bones | 16 Trapezium bone | | 23 Tuberosity of distal phalanx |
| 3 Styloid process of ulna | 10 Head of metacarpal bone | 17 Trapezoid bone | | 24 Body of third metacarpal bone |
| 4 Lunate bone | 11 Proximal phalanges of hand | 18 Metacarpal bone of thumb | | |
| 5 Triquetrum bone | 12 Middle phalanges of hand | 19 Proximal phalanx of thumb | | |
| 6 Capitate bone | 13 Distal phalanges of hand | 20 Distal phalanx of thumb | | |
| 7 Hamate bone | 14 Styloid process of radius | 21 Base of second proximal phalanx | | |

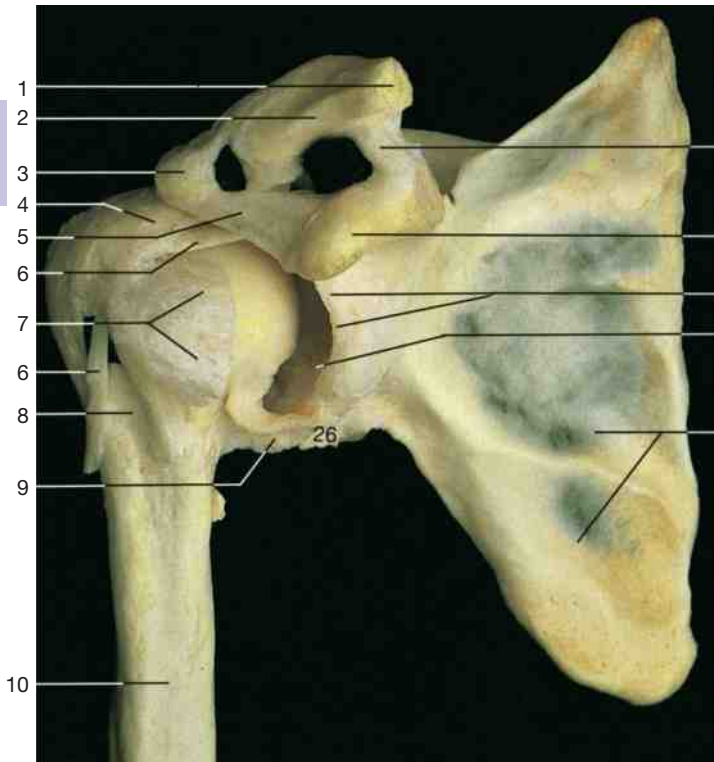


- 1 Radius
- 2 Styloid process of radius
- 3 Scaphoid bone
- 4 Capitate bone
- 5 Trapezium
- 6 Trapezoid bone
- 7 First metacarpal bone
- 8 Second to fourth metacarpal bones
- 9 Proximal phalanx of thumb
- 10 Distal phalanx of thumb
- 11 Base of second proximal phalanx
- 12 Proximal phalanges
- 13 Head of second proximal phalanx
- 14 Middle phalanges
- 15 Distal phalanx
- 16 Ulna
- 17 Styloid process of ulna
- 18 Lunate bone
- 19 Pisiform bone
- 20 Triquetral bone
- 21 Hamate bone
- 22 Hamulus or hook of hamate bone
- 23 Base of third metacarpal bone
- 24 Head of metacarpal bone
- 25 Tuberosity of distal phalanx

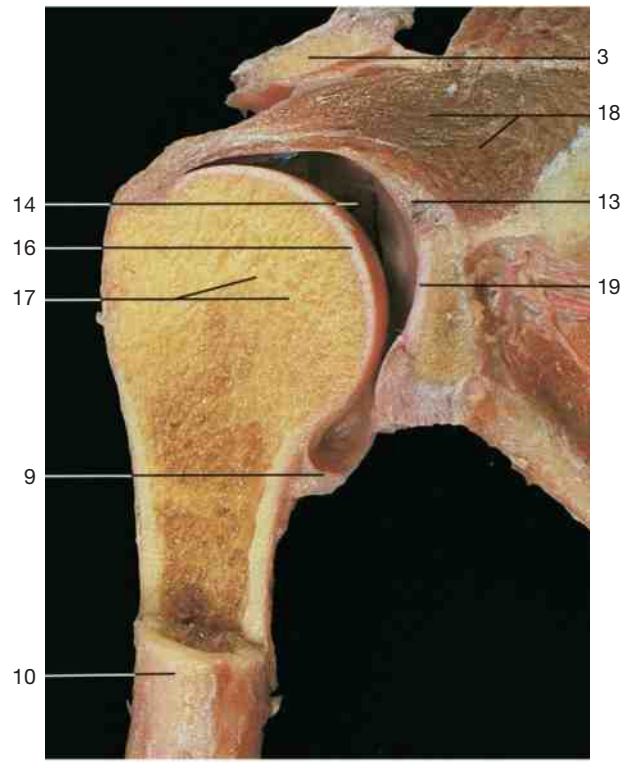
Skeleton of right wrist and hand (palmar aspect).

The human hand is one of the most admirable structures of the human body. The carpometacarpal joint of the thumb, a saddle joint, enjoys wide mobility so that the thumb can come into contact with all other fingers, thus enabling the hand to become an instrument for grasping and psychologic expression. During evolution, these newly developed functions

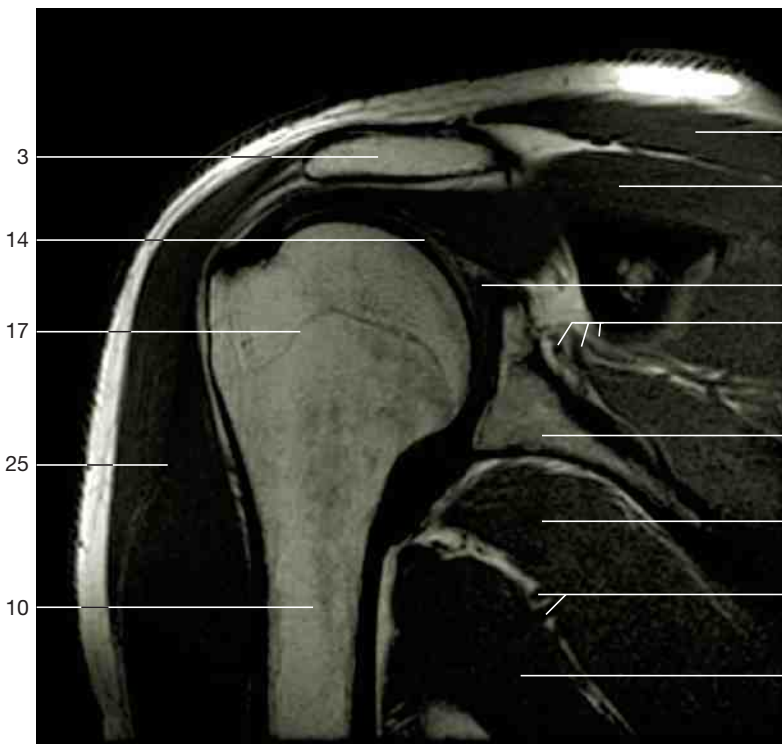appeared after the erect posture of the human body was achieved. An inevitable prerequisite for the development of human cultures is not only the differentiation of the brain but also the development of an organ capable of realizing its ideas: the human hand.



Right shoulder joint. The anterior part of the articular capsule has been removed and the head of the humerus has been slightly rotated outward to show the cavity of the joint.

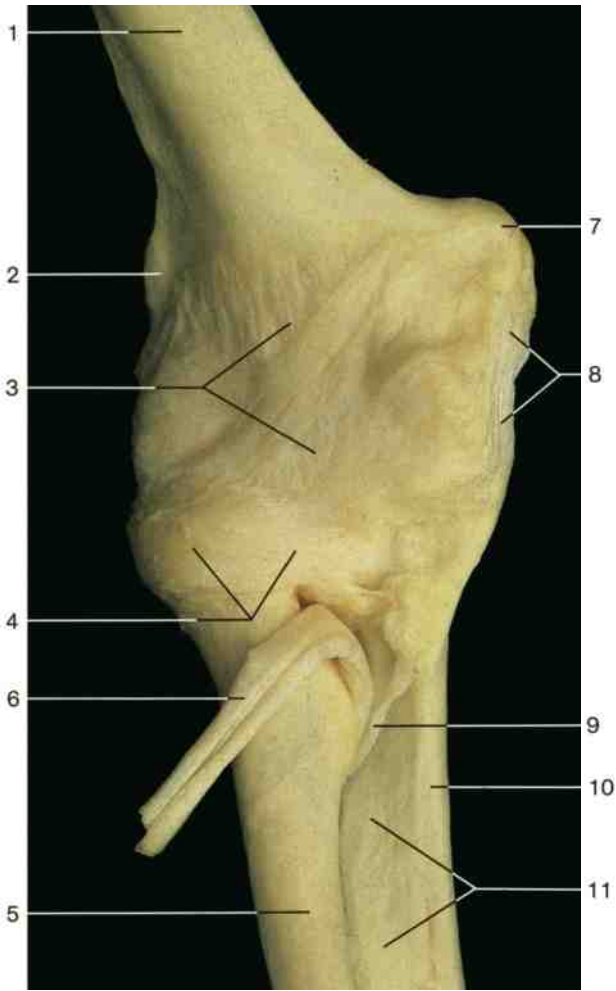


Coronal section of the right shoulder joint (anterior aspect).

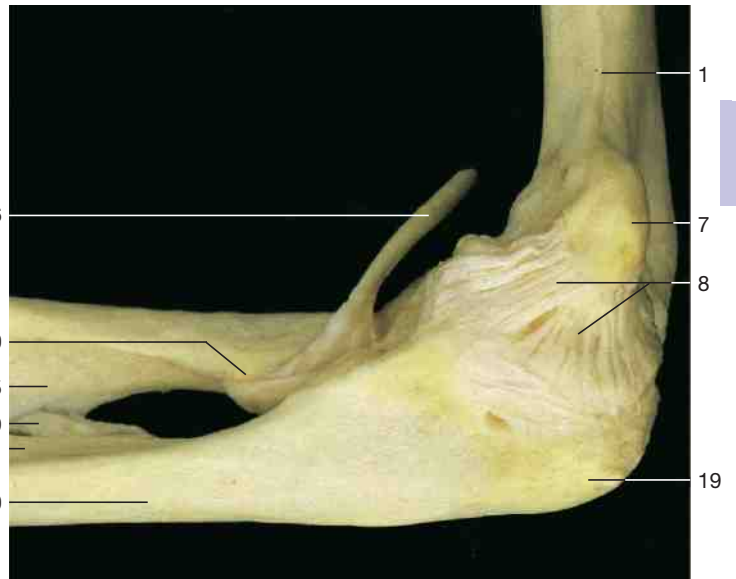


Coronal section of the right shoulder joint (MRI scan; from Heuck et al., MRT-Atlas, 2009).

- 1 Acromial end of clavicle
- 2 Acromioclavicular joint
- 3 Acromion
- 4 Tendon of supraspinatus muscle (attached to the articular capsule)
- 5 Coraco-acromial ligament
- 6 Tendon of long head of biceps brachii muscle
- 7 Tendon of subscapularis muscle (attached to the articular capsule)
- 8 Intertubercular sulcus
- 9 Articular capsule of shoulder joint
- 10 Humerus
- 11 Trapezoid ligament
- 12 Coracoid process
- 13 Glenoid labrum
- 14 Shoulder joint (joint cavity)
- 15 Scapula
- 16 Head of humerus
- 17 Epiphysial line
- 18 Supraspinatus muscle
- 19 Glenoid cavity
- 20 Trapezius muscle
- 21 Suprascapular artery, vein, and nerve
- 22 Teres major muscle
- 23 Circumflexa scapular artery and vein
- 24 Latissimus dorsi muscle
- 25 Deltoid muscle
- 26 Tendon of long head of triceps brachii muscle

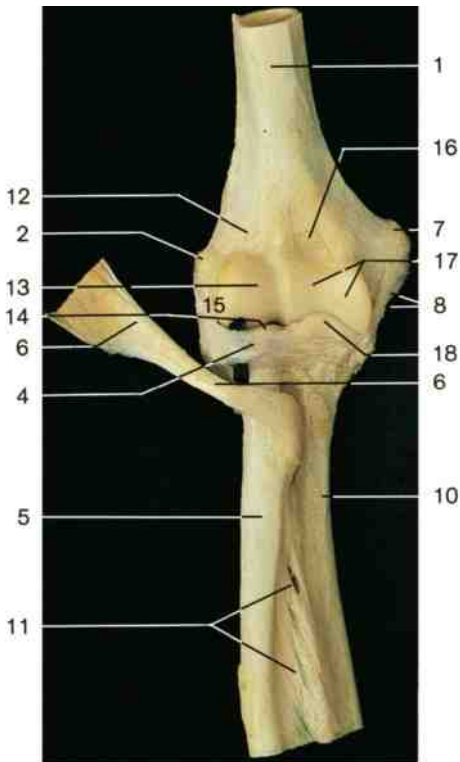


Ligaments of the elbow joint (anterior aspect).

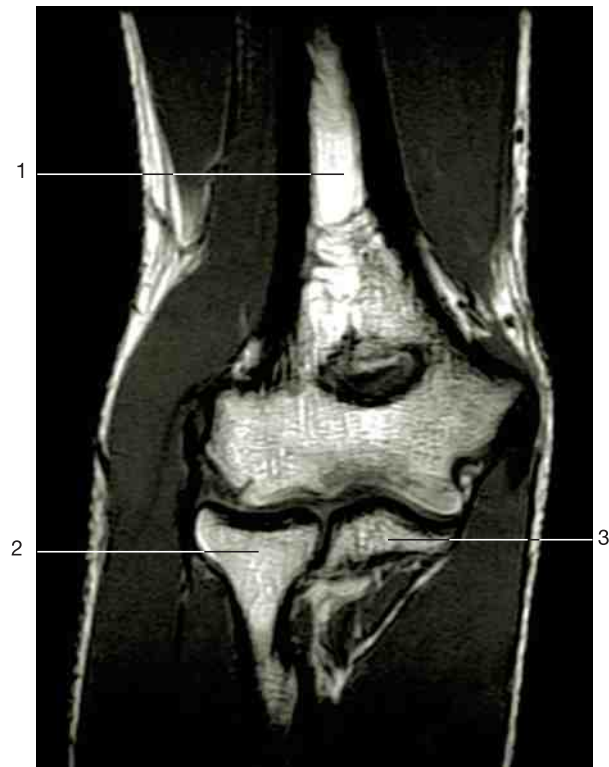

Elbow joint with collateral ligaments (medial aspect).

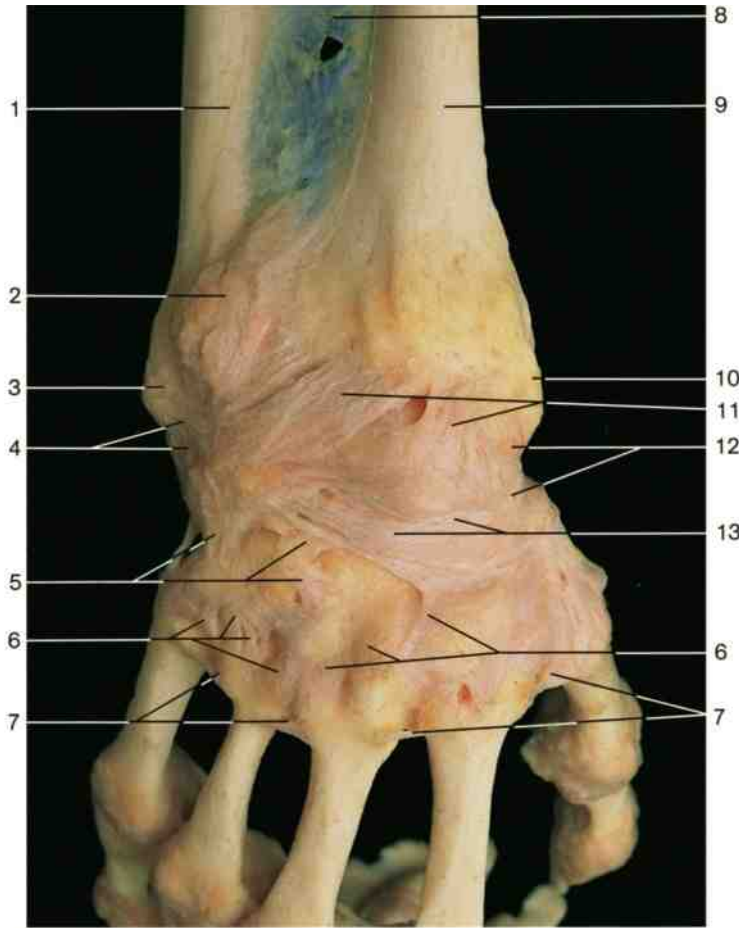
- | | |
|---|-------------------------------|
| 1 Humerus | 11 Interosseous membrane |
| 2 Lateral epicondyle of humerus | 12 Radial fossa |
| 3 Articular capsule | 13 Capitulum of humerus |
| 4 Anular ligament of proximal radio-ulnar joint | 14 Head of radius |
| 5 Radius | 15 Radial collateral ligament |
| 6 Tendon of biceps brachii muscle | 16 Coronoid fossa |
| 7 Medial epicondyle of humerus | 17 Trochlea of humerus |
| 8 Ulnar collateral ligament | 18 Coronoid process of ulna |
| 9 Oblique chord | 19 Olecranon |
| 10 Ulna | 20 Radial tuberosity |



Elbow joint with ligaments (anterior aspect). Articular capsule has been removed to show the anular ligament.

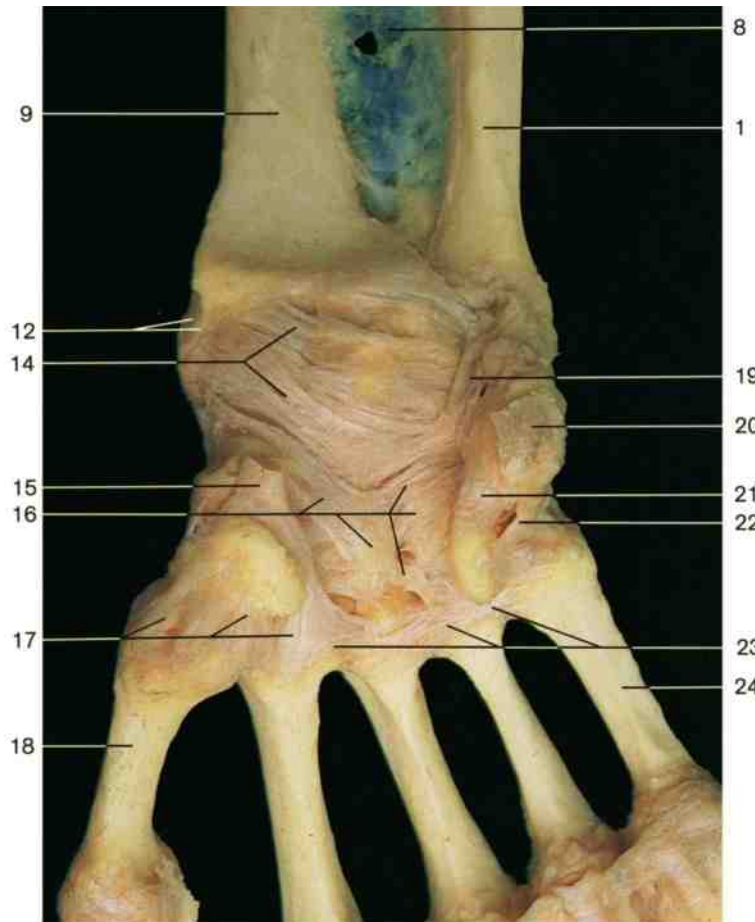


Coronal section of the elbow joint (MRI scan, courtesy of Prof. Dr. A. Heuck, Munich).

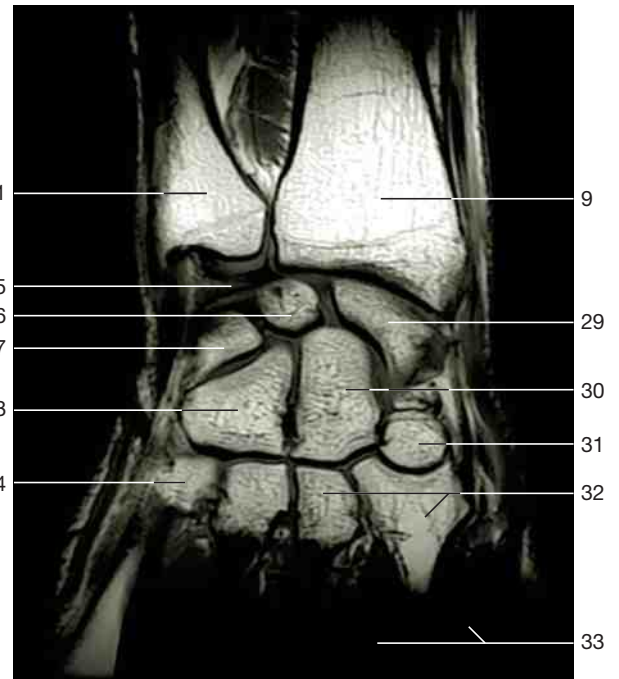


Ligaments of hand and wrist (dorsal aspect).

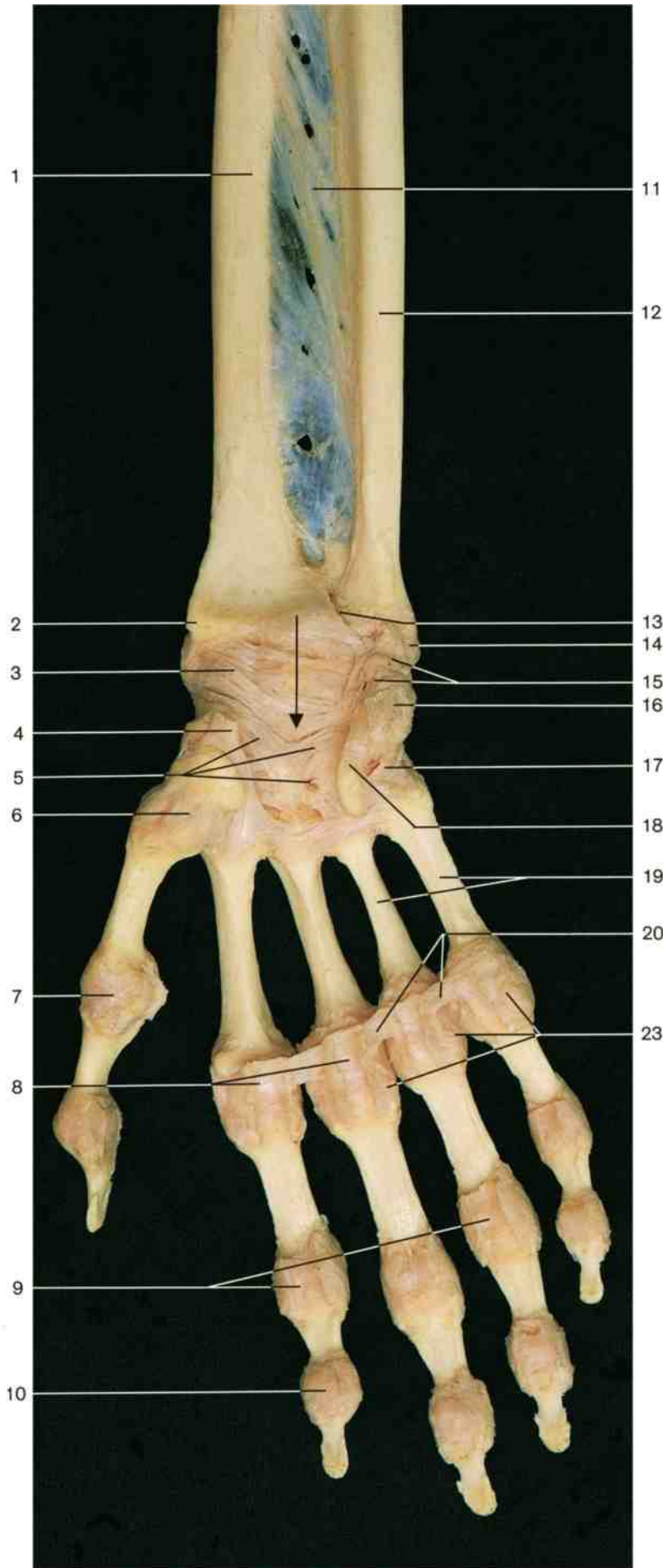
- 1 Ulna
- 2 Exostosis (pathological)
- 3 Head of ulna
- 4 Ulnar carpal collateral ligament
- 5 Deep intercarpal ligaments
- 6 Dorsal carpometacarpal ligaments
- 7 Dorsal metacarpal ligaments
- 8 Interosseous membrane
- 9 Radius
- 10 Styloid process of radius
- 11 Dorsal radiocarpal ligament
- 12 Radial collateral ligament
- 13 Articular capsule and dorsal intercarpal ligaments
- 14 Palmar radiocarpal ligament
- 15 Tendon of flexor carpi radialis muscle (cut)
- 16 Radiating carpal ligament
- 17 Palmar carpometacarpal ligaments
- 18 First metacarpal bone
- 19 Palmar ulnocarpal ligament
- 20 Tendon of flexor carpi ulnaris muscle (cut)
- 21 Pisohamate ligament
- 22 Pisometacarpal ligament
- 23 Palmar metacarpal ligaments
- 24 Fifth metacarpal bone
- 25 Articular disc (ulnocarpal)
- 26 Lunate bone
- 27 Triquetral bone
- 28 Hamate bone
- 29 Scaphoid bone (navicular)
- 30 Capitate bone
- 31 Trapezoid bone
- 32 Second and third metacarpal bones
- 33 Dorsal interosseus muscles



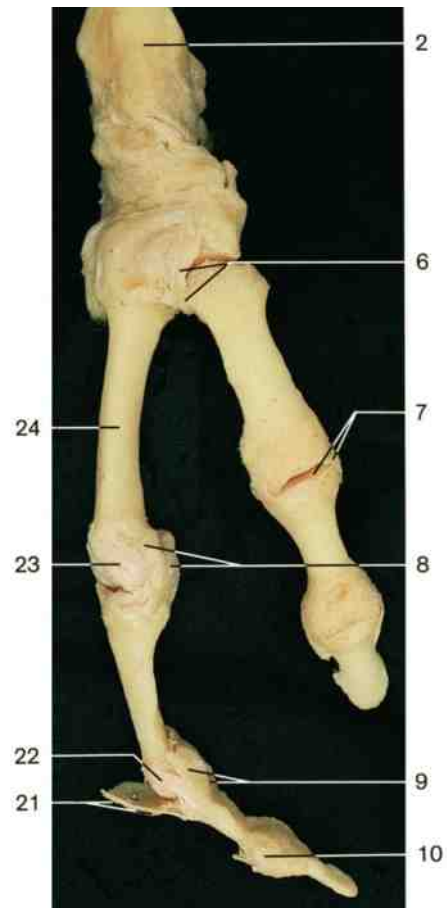
Ligaments of hand and wrist (palmar aspect).



Coronal section of the hand and wrist (MRI scan; from Heuck et al., MRT-Atlas, 2009). Note the location of the wrist joint.

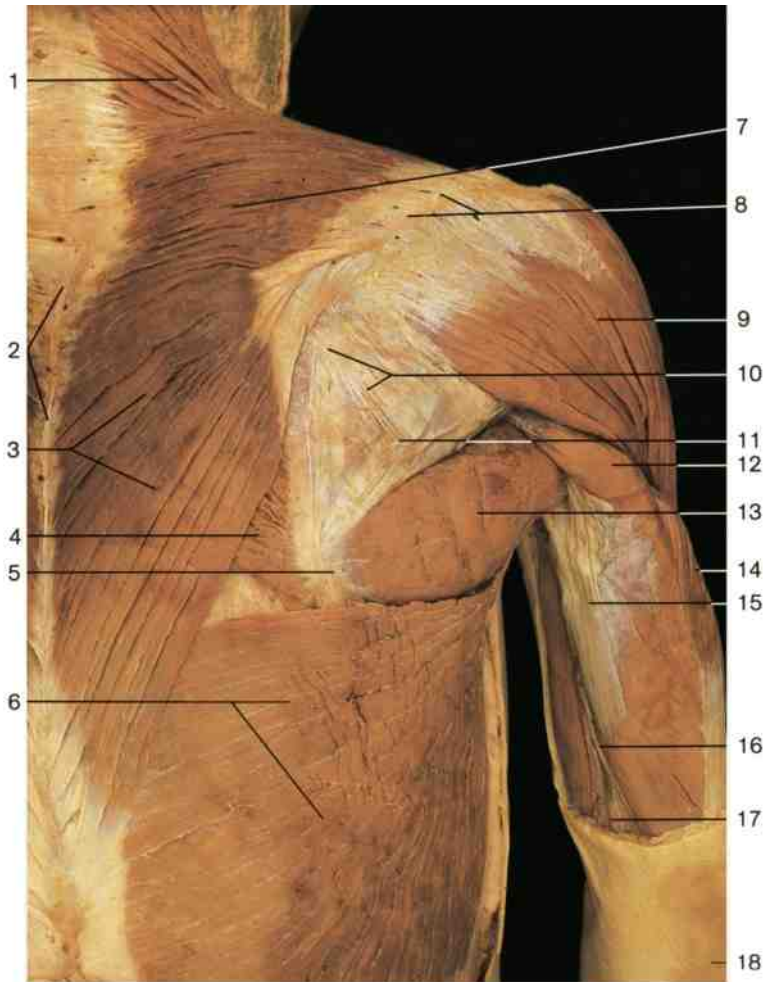


- 1 Radius
- 2 Styloid process of radius
- 3 Palmar radiocarpal ligament
- 4 Tendon of flexor carpi radialis muscle (cut)
- 5 Radiating carpal ligament
- 6 Articular capsule of carpometacarpal joint of thumb
- 7 Articular capsule of metacarpophalangeal joint of thumb
- 8 Palmar ligaments and articular capsule of metacarpophalangeal joints
- 9 Palmar ligaments and articular capsule of interphalangeal joints
- 10 Articular capsule
- 11 Interosseous membrane
- 12 Ulna
- 13 Distal radio-ulnar joint
- 14 Styloid process of ulna
- 15 Palmar ulnocarpal ligament
- 16 Pisiform bone with tendon of flexor carpi ulnaris muscle
- 17 Pisometacarpal ligament
- 18 Pisohamate ligament
- 19 Metacarpal bone
- 20 Deep transverse metacarpal ligament
- 21 Tendons of extensor muscles and articular capsule
- 22 Collateral ligament of interphalangeal joint
- 23 Collateral ligaments of metacarpophalangeal joints
- 24 Second metacarpal bone



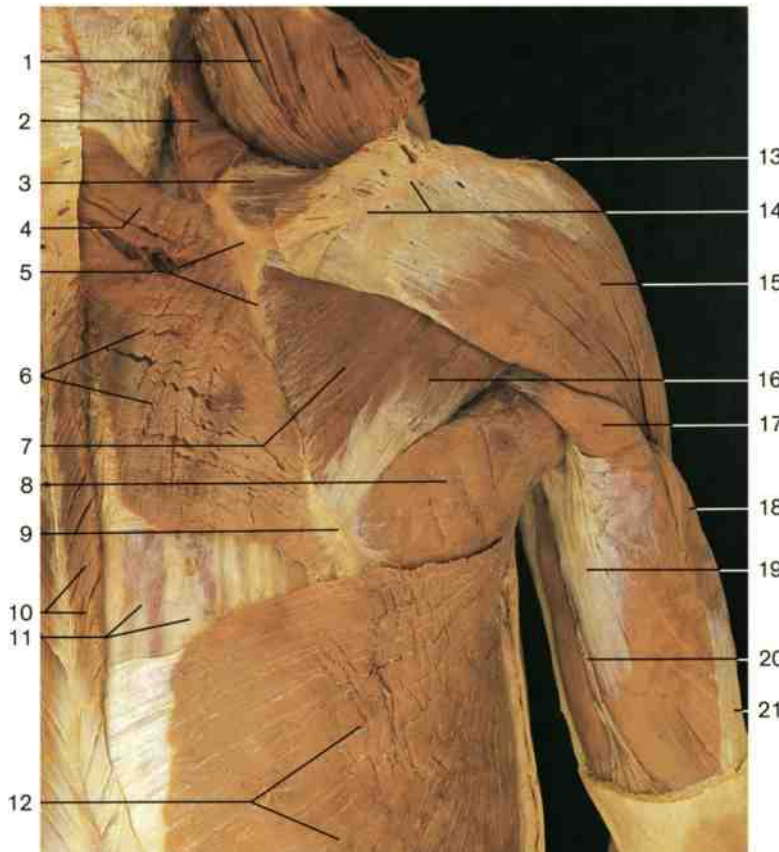
Ligaments of right forearm, hand, and fingers (palmar aspect).
The arrow indicates the location of the carpal tunnel.

Ligaments of fingers
(lateral aspect).



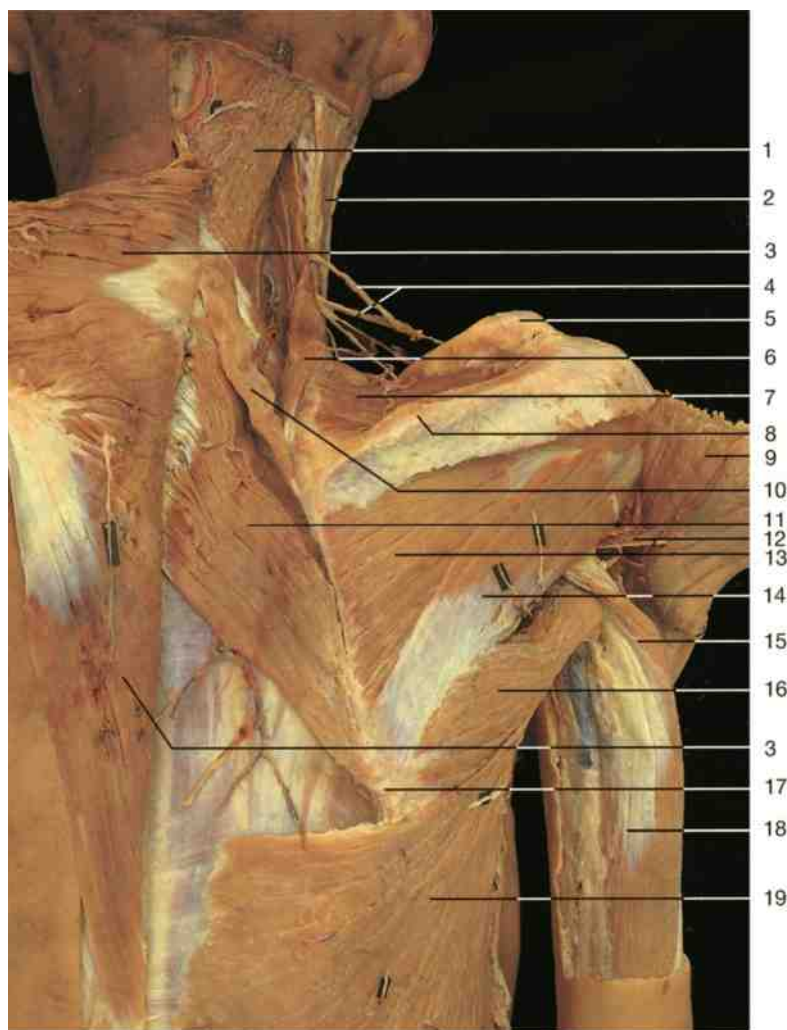
- 1 Descending fibers of trapezius muscle
- 2 Spinous processes of thoracic vertebrae
- 3 Ascending fibers of trapezius muscle
- 4 Rhomboid major muscle
- 5 Inferior angle of scapula
- 6 Latissimus dorsi muscle
- 7 Transverse fibers of trapezius muscle
- 8 Spine of scapula
- 9 Posterior fibers of deltoid muscle
- 10 Infraspinatus muscle and infraspinous fascia
- 11 Teres minor muscle and fascia
- 12 Long head of triceps brachii muscle
- 13 Teres major muscle
- 14 Lateral head of triceps brachii muscle
- 15 Medial head of triceps brachii muscle
- 16 Medial intermuscular septum
- 17 Ulnar nerve
- 18 Olecranon

Muscles of shoulder and arm, superficial layer (right side, dorsal aspect).



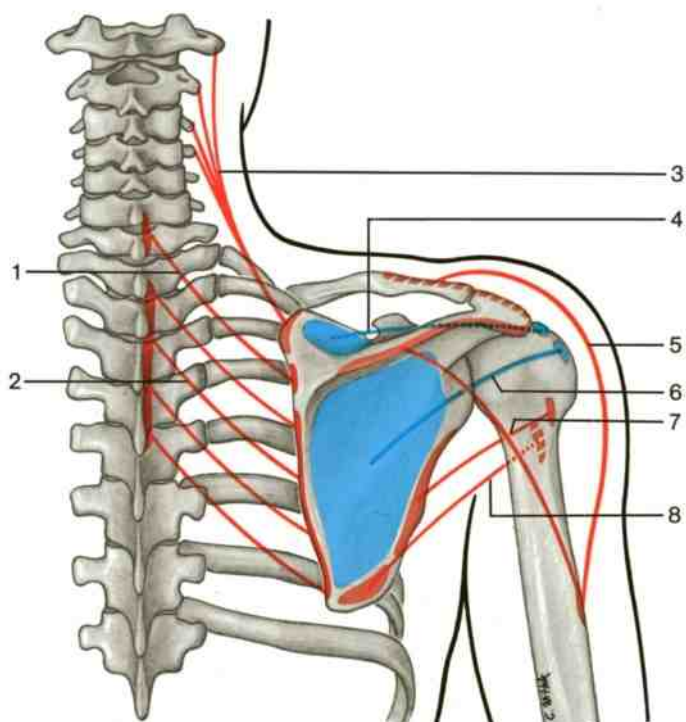
- 1 Trapezius muscle (reflected)
- 2 Levator scapulae muscle
- 3 Supraspinatus muscle
- 4 Rhomboid minor muscle
- 5 Medial border of scapula
- 6 Rhomboid major muscle
- 7 Infraspinatus muscle
- 8 Teres major muscle
- 9 Inferior angle of scapula
- 10 Cut edge of trapezius muscle
- 11 Intrinsic muscles of back with fascia
- 12 Latissimus dorsi muscle
- 13 Acromion
- 14 Spine of scapula
- 15 Deltoid muscle
- 16 Teres minor muscle
- 17 Long head of triceps brachii muscle
- 18 Lateral head of triceps brachii muscle
- 19 Medial head of triceps brachii muscle
- 20 Medial intermuscular septum
- 21 Tendon of triceps brachii muscle

Muscles of shoulder and arm, deeper layer (right side, dorsal aspect). The trapezius muscle has been cut near its origin at the vertebral column and reflected upward.



- 1 Splenius capitis muscle
- 2 Sternocleidomastoid muscle
- 3 Trapezius muscle (reflected)
- 4 Lateral supraclavicular nerves
- 5 Clavicle
- 6 Levator scapulae muscle
- 7 Supraspinatus muscle
- 8 Spine of scapula
- 9 Deltoid muscle (reflected)
- 10 Rhomboid minor muscle
- 11 Rhomboid major muscle
- 12 Axillary nerve and posterior circumflex humeral artery
- 13 Infraspinatus muscle
- 14 Teres minor muscle
- 15 Long head of triceps brachii muscle
- 16 Teres major muscle
- 17 Inferior angle of scapula
- 18 Triceps brachii muscle
- 19 Latissimus dorsi muscle

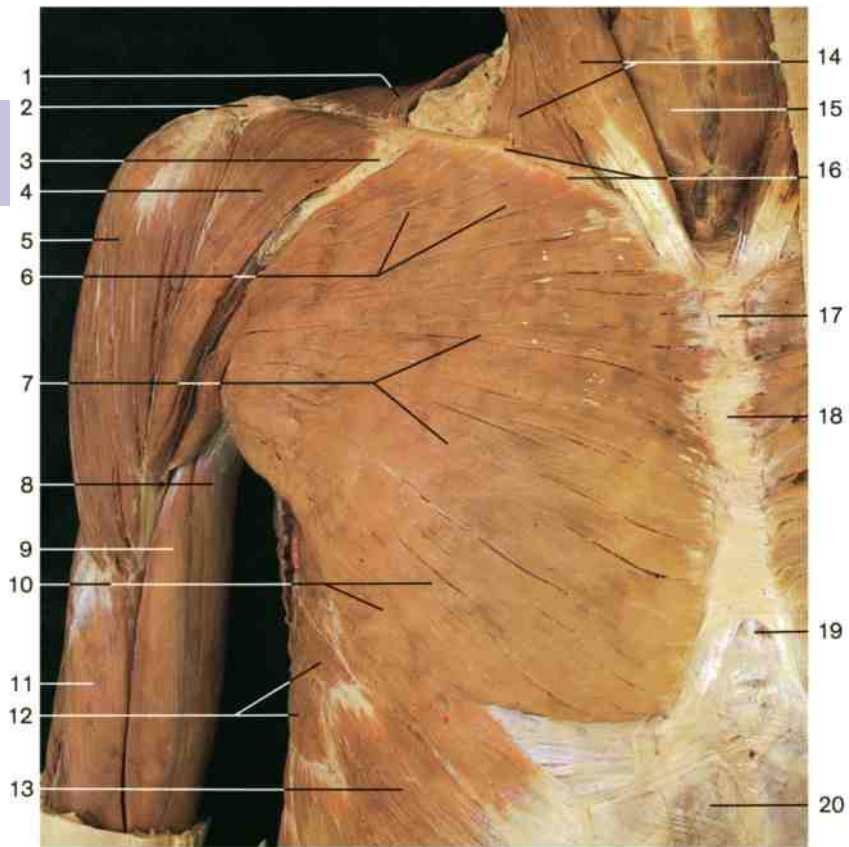
Muscles of shoulder and arm, deeper layer (right side, dorsal aspect). The trapezius and deltoid muscles have been divided and reflected.



Shoulder muscles, schematic diagram illustrating the course of the main muscles of the dorsal aspect of the shoulder.

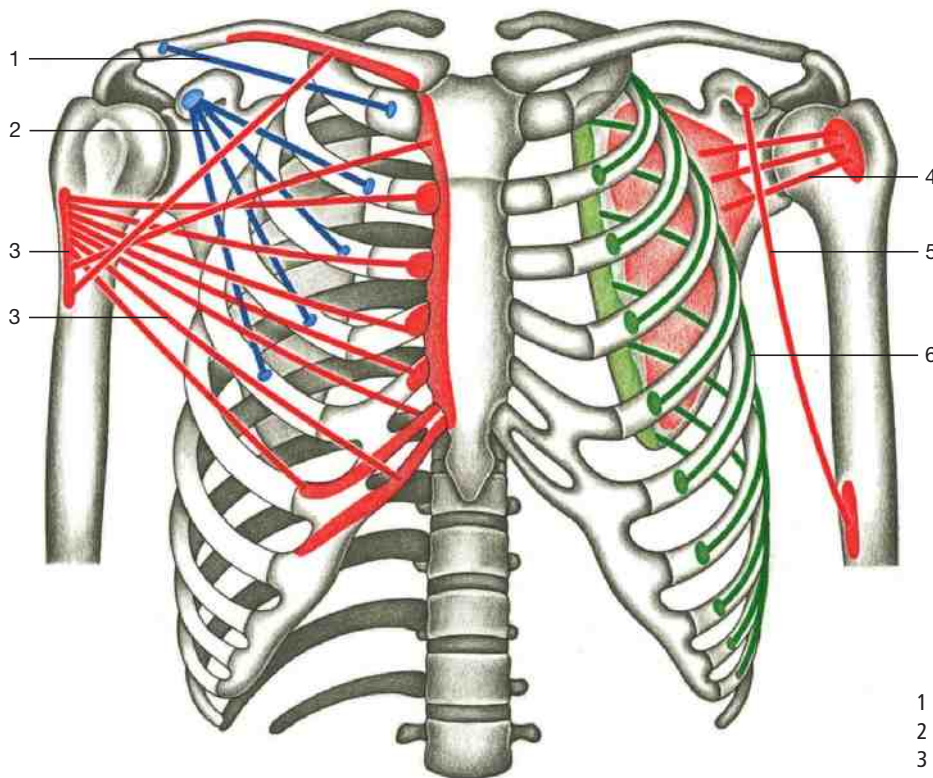


- 1 Rhomboid minor muscle (red)
- 2 Rhomboid major muscle (red)
- 3 Levator scapulae muscle (red)
- 4 Supraspinatus muscle (blue)
- 5 Deltoid muscle (red)
- 6 Infraspinatus muscle (blue)
- 7 Teres minor muscle (red)
- 8 Teres major muscle (red)



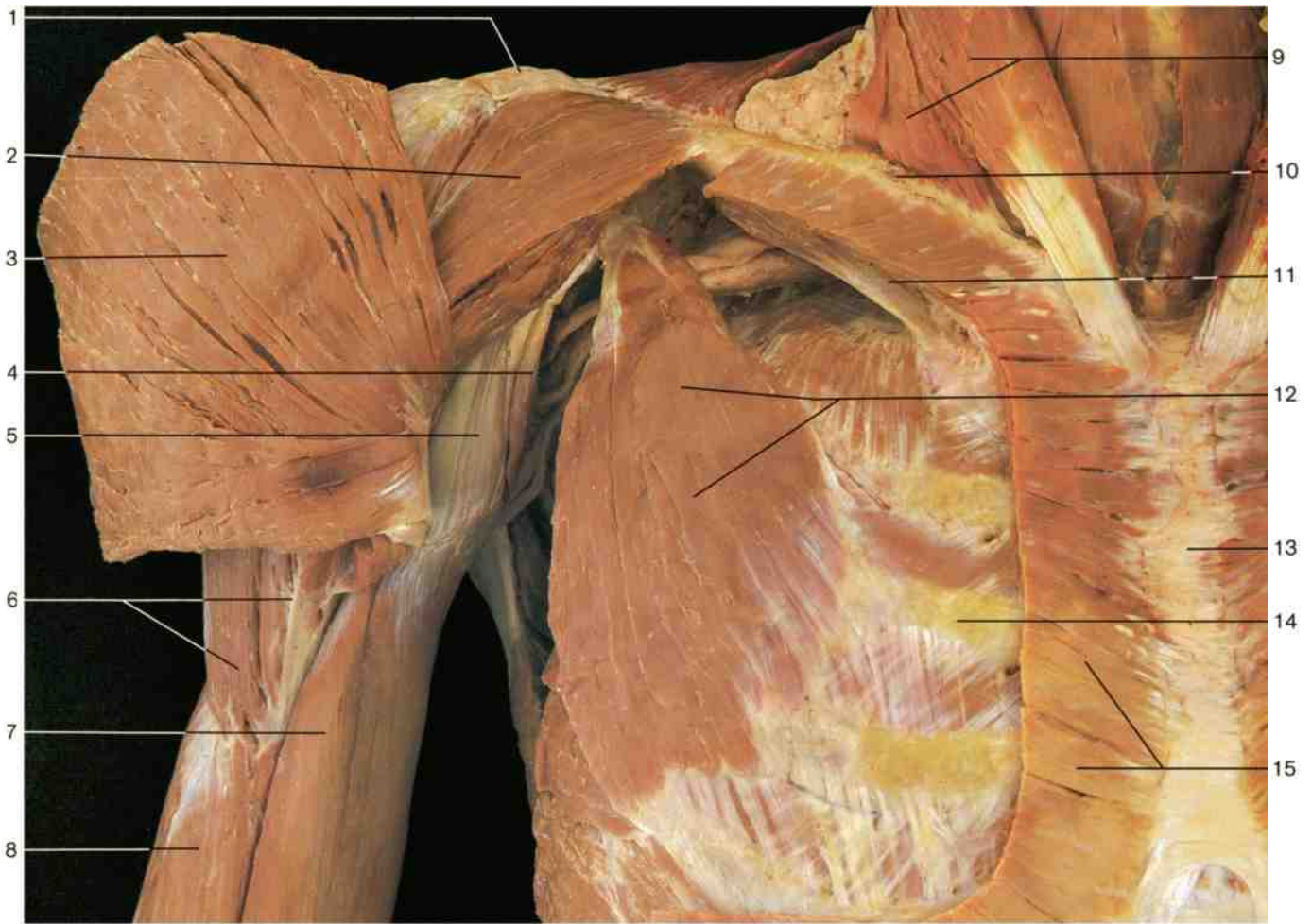
- 1 Trapezius muscle
- 2 Acromion
- 3 Deltopectoral triangle
- 4 Clavicular part of deltoid muscle (anterior fibers)
- 5 Acromial part of deltoid muscle (central fibers)
- 6 Clavicular part of pectoralis major muscle
- 7 Sternocostal part of pectoralis major muscle
- 8 Short head of biceps brachii muscle
- 9 Long head of biceps brachii muscle
- 10 Abdominal part of pectoralis major muscle
- 11 Brachialis muscle
- 12 Serratus anterior muscle
- 13 External abdominal oblique muscle
- 14 Sternocleidomastoid muscle
- 15 Infrahyoid muscles
- 16 Clavicle
- 17 Manubrium sterni
- 18 Body of sternum
- 19 Xiphoid process
- 20 Anterior layer of sheath of rectus abdominis muscle

Shoulder, arm, and pectoral muscles, superficial layer (ventral aspect).

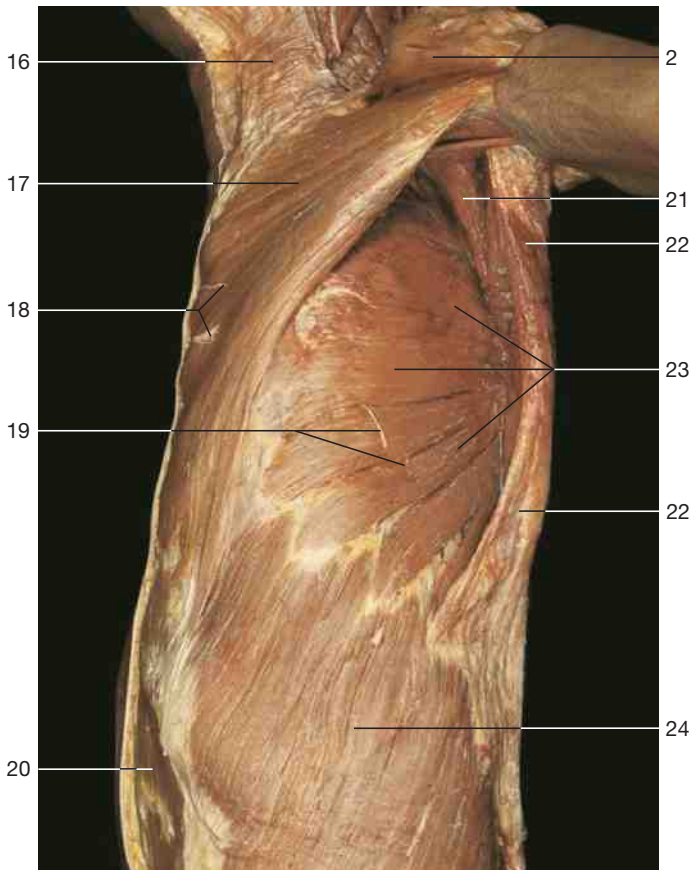


- 1 Subclavius muscle (blue)
- 2 Pectoralis minor muscle (blue)
- 3 Pectoralis major muscle (red)
- 4 Subscapularis muscle (red)
- 5 Coracobrachialis muscle (red)
- 6 Serratus anterior muscle (green)

Arrangement of pectoral and shoulder muscles (ventral aspect).
(Schematic drawing.)




Shoulder, arm, and pectoral muscles, deep layer (ventral aspect).

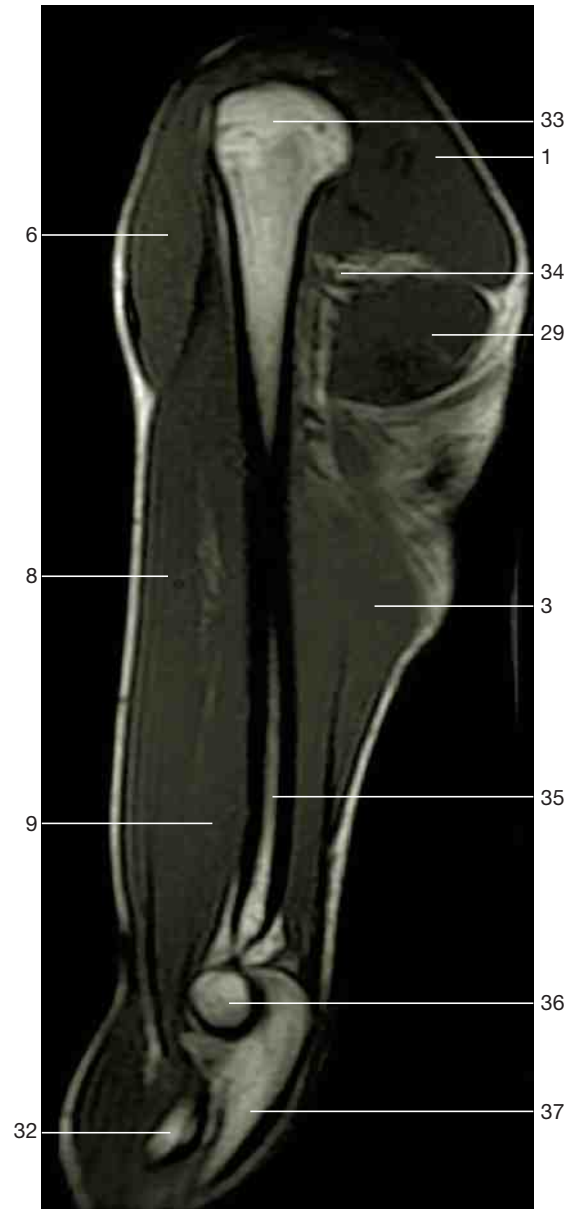

- 1 Acromion
- 2 Clavicular part of deltoid muscle
- 3 Pectoralis major muscle (reflected)
- 4 Coracobrachialis muscle
- 5 Short head of biceps brachii muscle
- 6 Deltoid muscle (insertion on humerus)
- 7 Long head of biceps brachii muscle
- 8 Brachialis muscle
- 9 Sternocleidomastoid muscle
- 10 Clavicle
- 11 Subclavius muscle
- 12 Pectoralis minor muscle
- 13 Sternum
- 14 Third rib
- 15 Pectoralis major muscle
- 16 Platysma muscle
- 17 Pectoralis major muscle forming the anterior axillary fold
- 18 Anterior cutaneous branches of intercostal nerves
- 19 Lateral cutaneous branches of intercostal nerves
- 20 Rectus abdominis muscle
- 21 Subscapularis muscle
- 22 Latissimus dorsi muscle forming the posterior axillary fold
- 23 Serratus anterior muscle forming the medial wall of the axilla
- 24 External abdominal oblique muscle

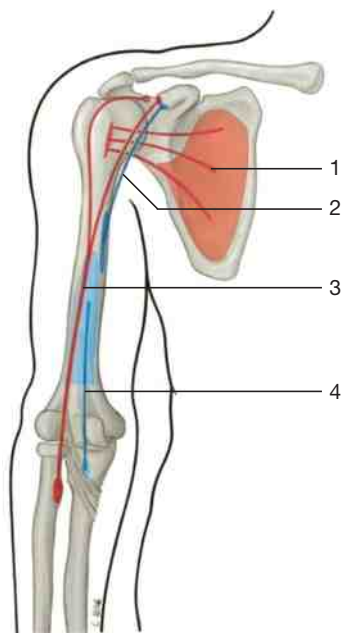
Axillary fossa and serratus anterior muscle (left side, lateral aspect).



Muscles of the right arm (lateral aspect).

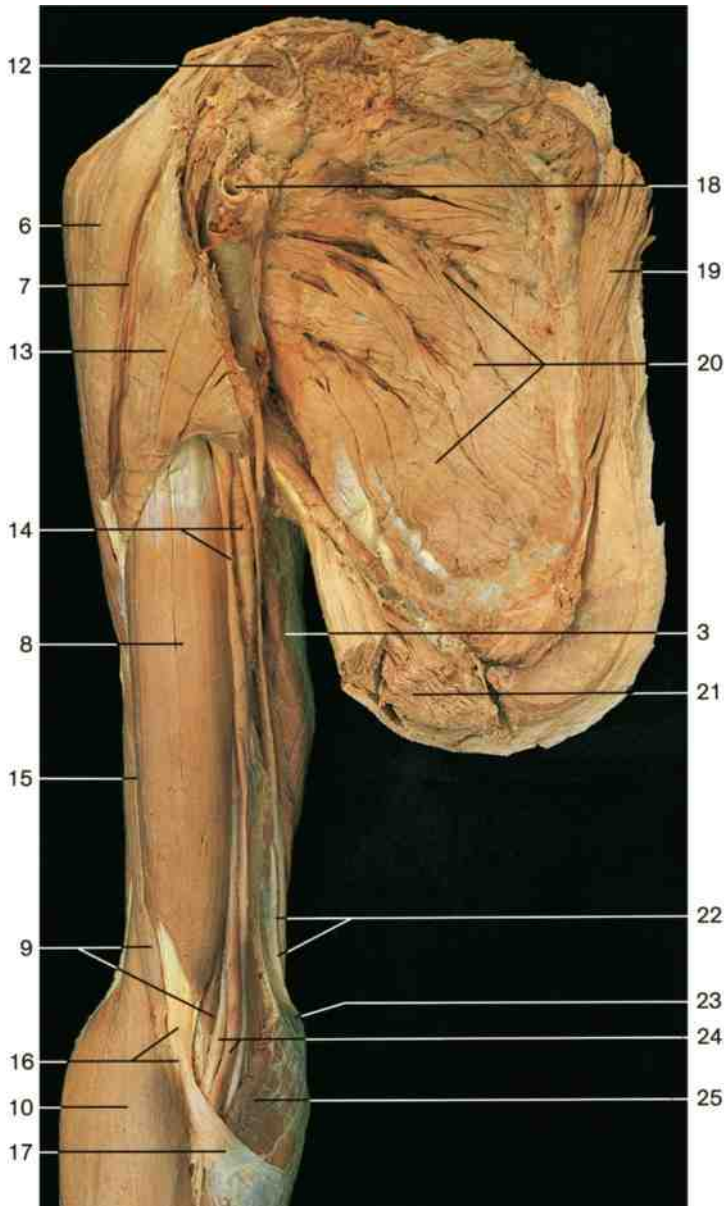


Sagittal section of the right arm (MRI scan; from Heuck et al., MRT-Atlas, 2009).

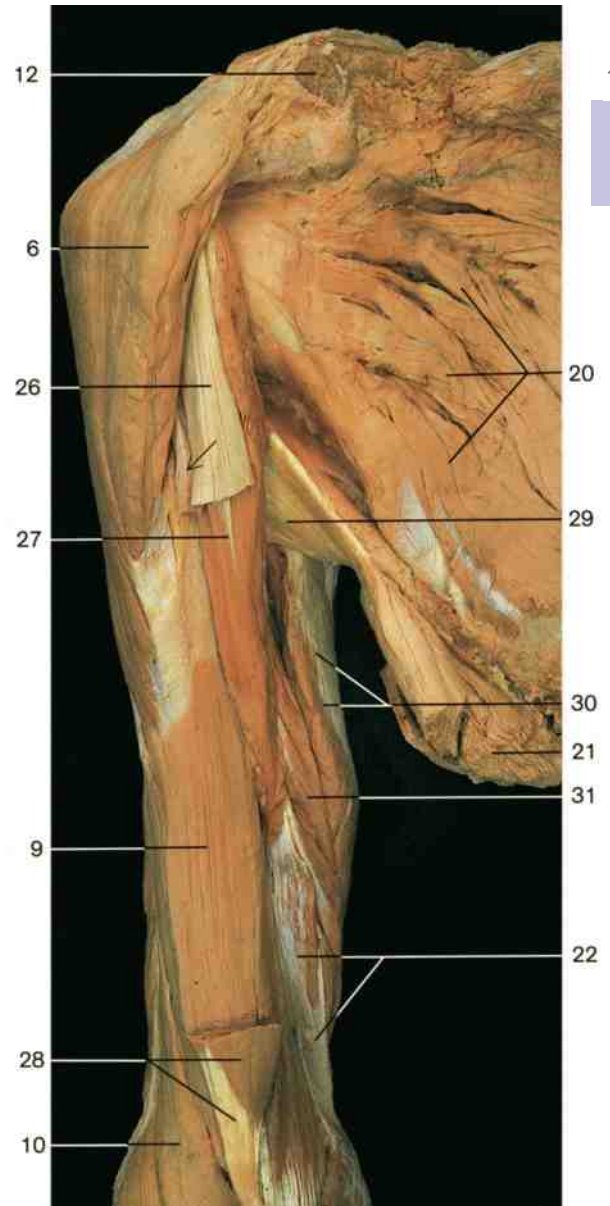


Position and course of flexors of arm (schematic drawing).

- 1 Subscapularis muscle (red)
- 2 Coracobrachialis muscle (blue)
- 3 Biceps brachii muscle (red)
- 4 Brachialis muscle (blue)



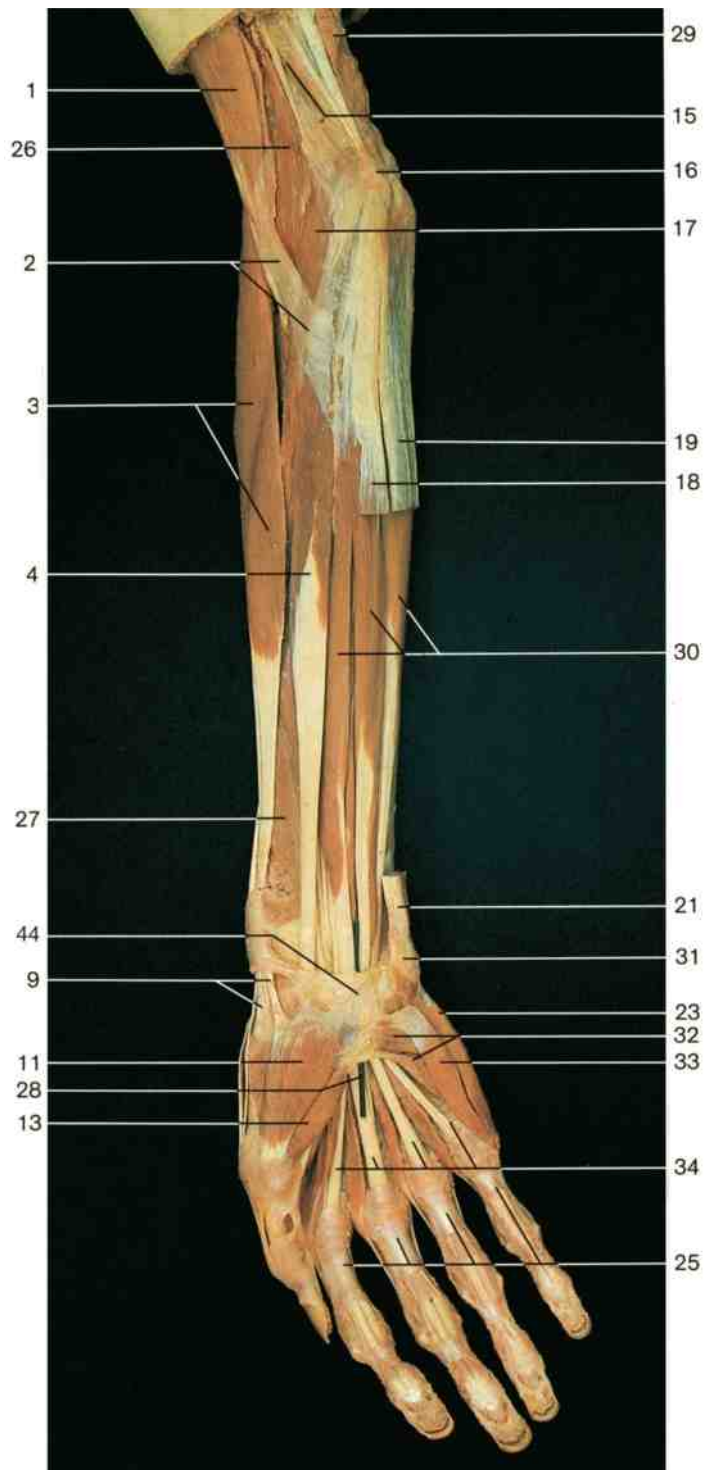
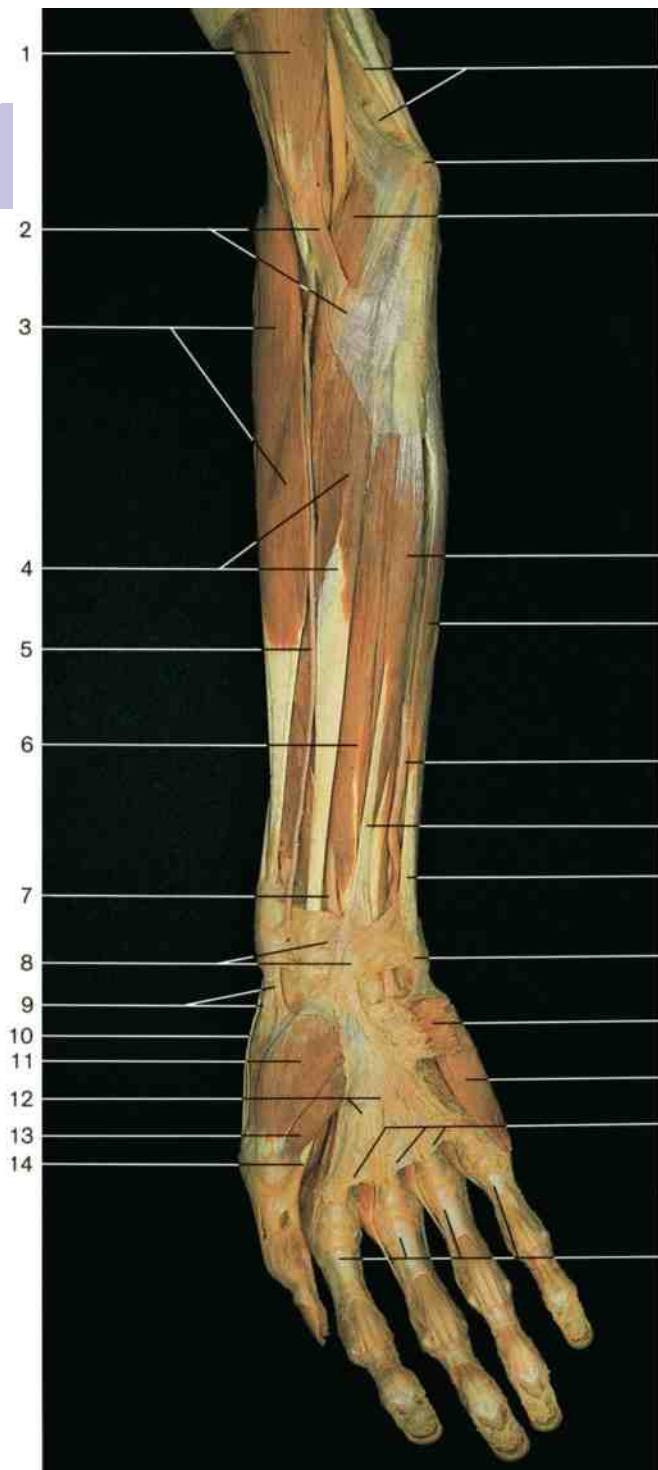
Muscles of the right arm (ventral aspect). The arm with the scapula and attached muscles has been removed from the trunk.



Muscles of the right arm (ventral aspect). Part of the biceps brachii muscle has been removed. Arrow: tendon of long head of biceps brachii muscle.

- 1 Acromial part of deltoid muscle (central fibers)
- 2 Scapular part of deltoid muscle (posterior fibers)
- 3 Triceps brachii muscle
- 4 Tendon of triceps brachii muscle
- 5 Olecranon
- 6 Clavicular part of deltoid muscle (anterior fibers)
- 7 Deltopectoral groove
- 8 Biceps brachii muscle
- 9 Brachialis muscle
- 10 Brachioradialis muscle
- 11 Extensor carpi radialis longus muscle
- 12 Clavicle (divided)
- 13 Pectoralis major muscle
- 14 Medial intermuscular septum with vessels and nerves
- 15 Lateral intermuscular septum
- 16 Tendon of biceps brachii muscle
- 17 Bicipital aponeurosis
- 18 Axillary artery
- 19 Rhomboid major muscle

- 20 Subscapularis muscle
- 21 Latissimus dorsi muscle (divided)
- 22 Medial intermuscular septum
- 23 Medial epicondyle of humerus
- 24 Brachial artery and median nerve
- 25 Pronator teres muscle
- 26 Tendon of short head of biceps brachii muscle
- 27 Coracobrachialis muscle
- 28 Distal part of biceps brachii muscle
- 29 Teres major muscle
- 30 Long head of triceps brachii muscle
- 31 Medial head of triceps brachii muscle
- 32 Radius
- 33 Head of humerus
- 34 Axillary nerve
- 35 Humerus
- 36 Trochlea
- 37 Ulna

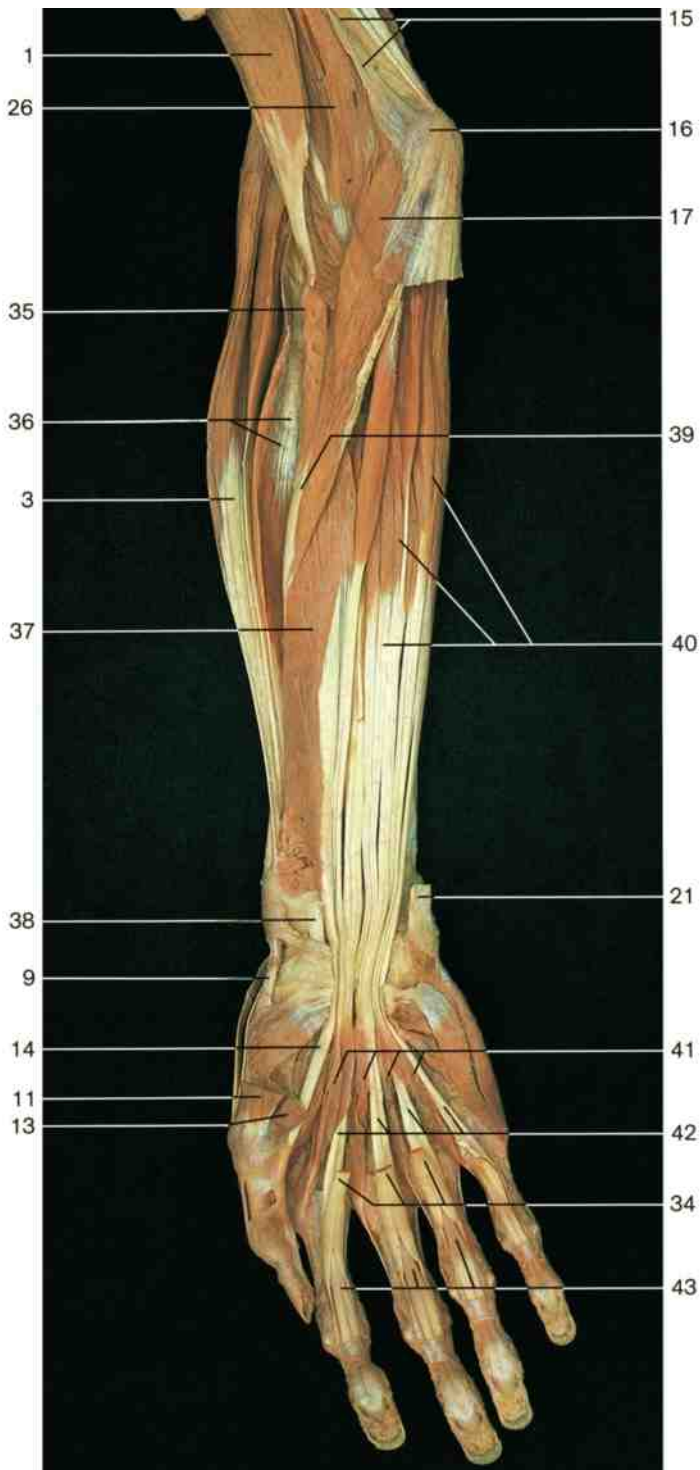


Flexor muscles of forearm and hand, superficial layer (ventral aspect).

Flexor muscles of forearm and hand, superficial layer (ventral aspect). The palmaris longus and flexor carpi ulnaris muscles have been removed.

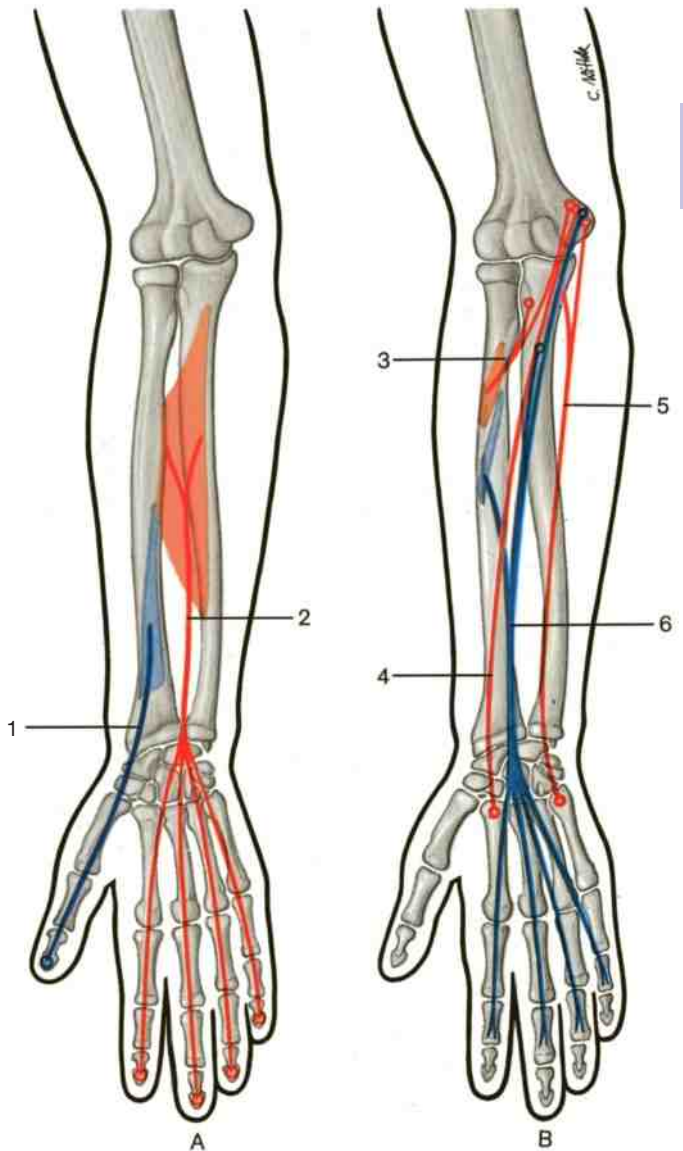
- 1 Biceps brachii muscle
- 2 Bicipital aponeurosis
- 3 Brachioradialis muscle
- 4 Flexor carpi radialis muscle
- 5 Radial artery
- 6 Flexor digitorum superficialis muscle
- 7 Median nerve
- 8 Antebrachial fascia and tendon of palmaris longus muscle
- 9 Tendon of abductor pollicis longus muscle
- 10 Tendon of extensor pollicis brevis muscle
- 11 Abductor pollicis brevis muscle

- 12 Palmar aponeurosis
- 13 Superficial head of flexor pollicis brevis muscle
- 14 Tendon of flexor pollicis longus muscle
- 15 Medial intermuscular septum
- 16 Medial epicondyle of humerus
- 17 Humeral head of pronator teres muscle
- 18 Palmaris longus muscle
- 19 Flexor carpi ulnaris muscle
- 20 Ulnar artery
- 21 Tendon of flexor carpi ulnaris muscle
- 22 Palmaris brevis muscle



Flexor muscles of forearm and hand, middle layer (ventral aspect). The palmaris longus, flexor carpi radialis, and ulnaris muscles have been removed. The flexor retinaculum has been divided.

- 23 Abductor digiti minimi muscle
- 24 Transverse fasciculi of palmar aponeurosis
- 25 Digital fibrous sheaths of tendons of flexor digitorum muscle
- 26 Brachialis muscle
- 27 Flexor pollicis longus muscle
- 28 Carpal tunnel (canalis carpi, probe)
- 29 Triceps brachii muscle
- 30 Flexor digitorum superficialis muscle
- 31 Pisiform bone
- 32 Opponens digiti minimi muscle
- 33 Flexor digiti minimi brevis muscle
- 34 Tendons of flexor digitorum superficialis muscle



Position of flexors of fingers and hand (schematic drawing).

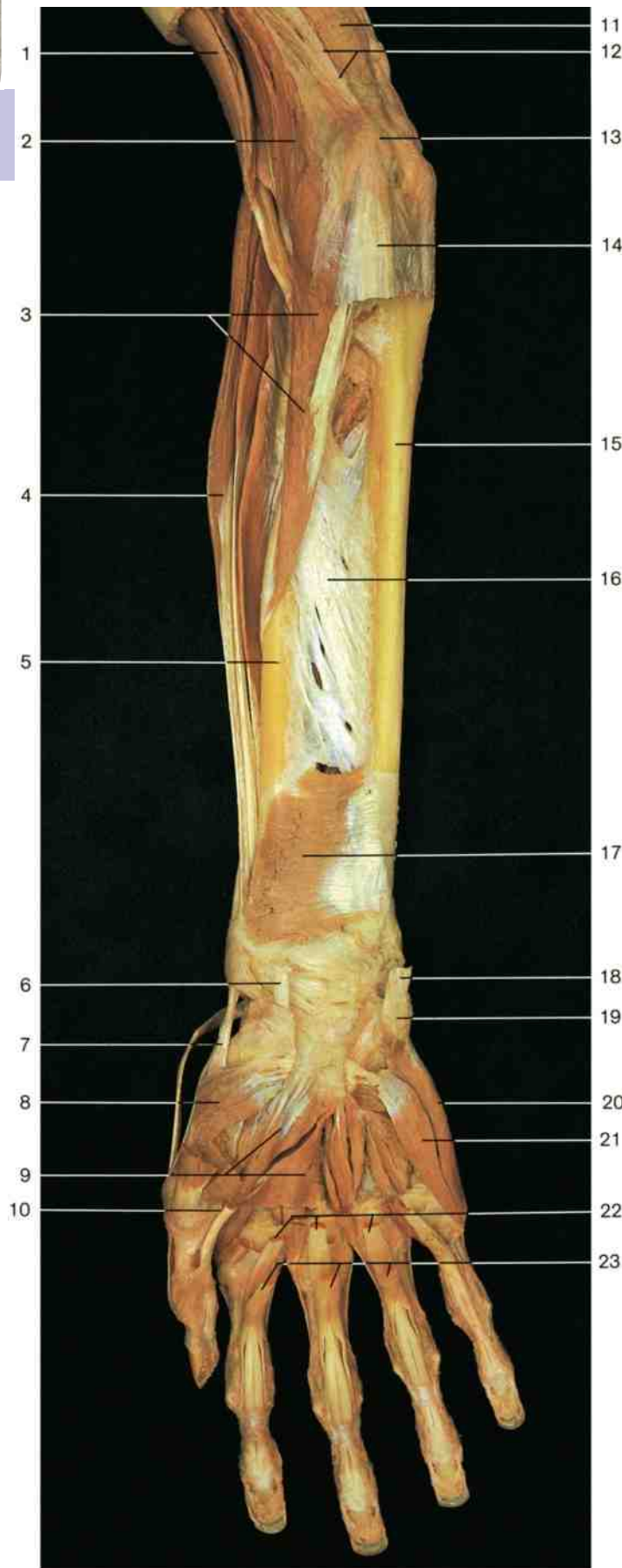
A Deep layer

- 1 Flexor pollicis longus muscle (blue)
- 2 Flexor digitorum profundus muscle (red)

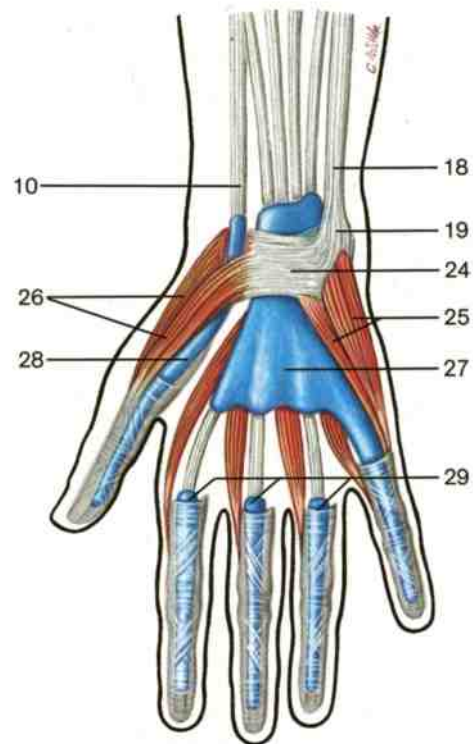
B Superficial layer

- 3 Pronator teres muscle (red)
- 4 Flexor carpi radialis muscle (red)
- 5 Flexor carpi ulnaris muscle (red)
- 6 Flexor digitorum superficialis muscle (blue)

- 35 Supinator muscle
- 36 Extensor carpi radialis brevis muscle
- 37 Flexor pollicis longus muscle
- 38 Tendon of flexor carpi radialis muscle
- 39 Pronator teres muscle (insertion of radius)
- 40 Flexor digitorum profundus muscle
- 41 Lumbrical muscles
- 42 Tendons of flexor digitorum profundus muscle
- 43 Tendons of flexor digitorum profundus muscle having passed through the divided tendons of the flexor digitorum superficialis muscle
- 44 Flexor retinaculum

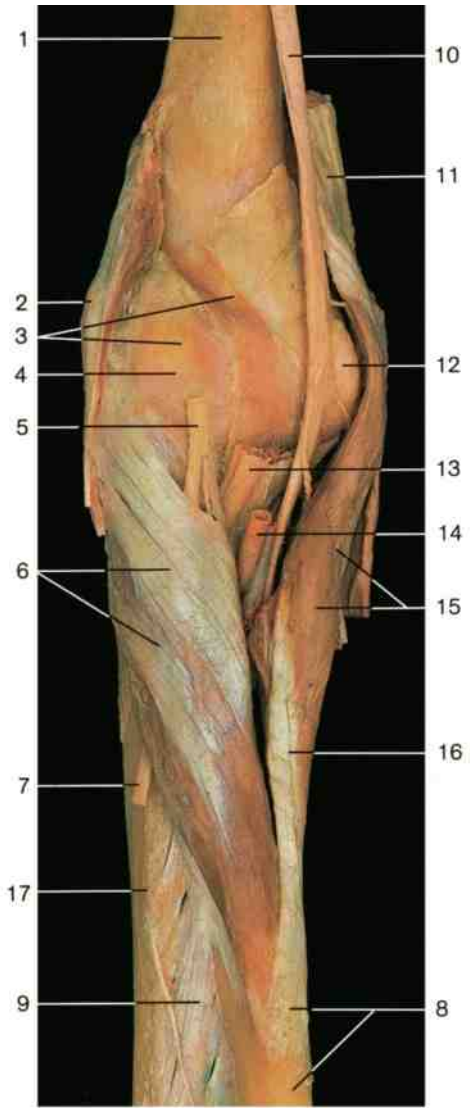


- 1 Biceps brachii muscle
- 2 Brachialis muscle
- 3 Pronator teres muscle
- 4 Brachioradialis muscle
- 5 Radius
- 6 Tendon of flexor carpi radialis muscle
- 7 Tendon of abductor pollicis longus muscle
- 8 Opponens pollicis muscle
- 9 Adductor pollicis muscle
- 10 Tendon of flexor pollicis longus muscle
- 11 Triceps brachii muscle
- 12 Medial intermuscular septum
- 13 Medial epicondyle of humerus
- 14 Common flexor mass (divided)
- 15 Ulna
- 16 Interosseous membrane
- 17 Pronator quadratus muscle
- 18 Tendon of flexor carpi ulnaris muscle
- 19 Pisiform bone
- 20 Abductor digiti minimi muscle
- 21 Flexor digiti minimi brevis muscle
- 22 Tendons of flexor digitorum profundus muscle
- 23 Tendons of flexor digitorum superficialis muscle
- 24 Flexor retinaculum
- 25 Hypothenar muscles
- 26 Thenar muscles
- 27 Common synovial sheath of flexor tendons
- 28 Synovial sheath of tendon of flexor pollicis longus muscle
- 29 Digital synovial sheaths of flexor tendons



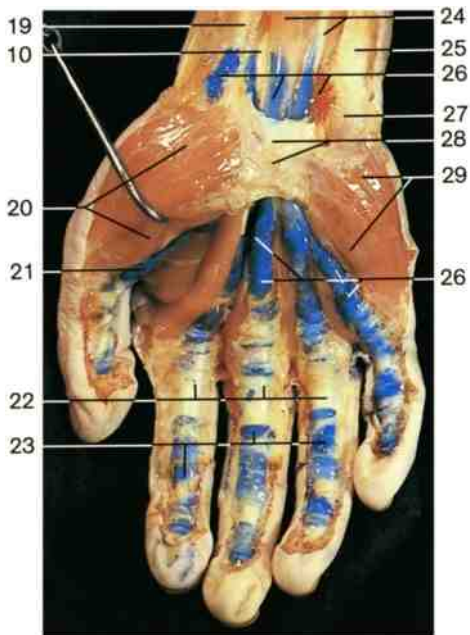
Flexor muscles of forearm and hand, deep layer (ventral aspect). All flexors have been removed to display the pronator quadratus and pronator teres muscles together with the interosseous membrane. Forearm in supination.

Synovial sheaths of flexor tendons (palmar aspect of right hand, semischematic drawing).

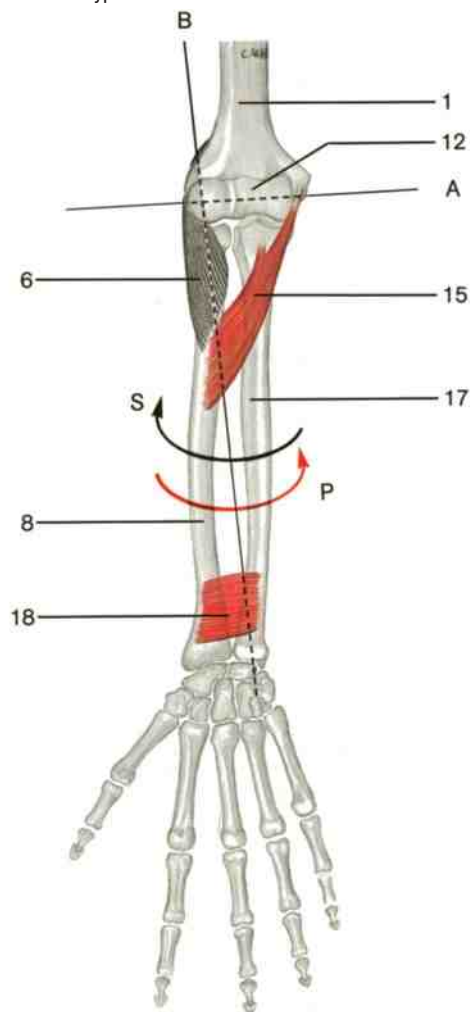


Right supinator and elbow joint (ventral aspect). Forearm in pronation.

- 1 Humerus
- 2 Lateral epicondyle of humerus
- 3 Articular capsule
- 4 Position of capitulum of humerus
- 5 Deep branch of radial nerve
- 6 Supinator muscle
- 7 Entrance of deep branch of radial nerve to extensor muscles
- 8 Radius and insertion of pronator teres muscle
- 9 Interosseous membrane
- 10 Median nerve
- 11 Triceps brachii muscle
- 12 Trochlea of humerus
- 13 Tendon of biceps brachii muscle
- 14 Brachial artery
- 15 Pronator teres muscle
- 16 Tendon of pronator teres muscle
- 17 Ulna
- 18 Pronator quadratus muscle
- 19 Tendon of flexor carpi radialis muscle
- 20 Thenar muscles
- 21 Synovial sheath of tendon of flexor pollicis longus muscle
- 22 Fibrous sheath of flexor tendons
- 23 Digital synovial sheath of flexor tendons
- 24 Flexor digitorum superficialis muscle
- 25 Tendon of flexor carpi ulnaris muscle
- 26 Common synovial sheath of flexor tendons
- 27 Position of pisiform bone
- 28 Flexor retinaculum
- 29 Hypothenar muscles

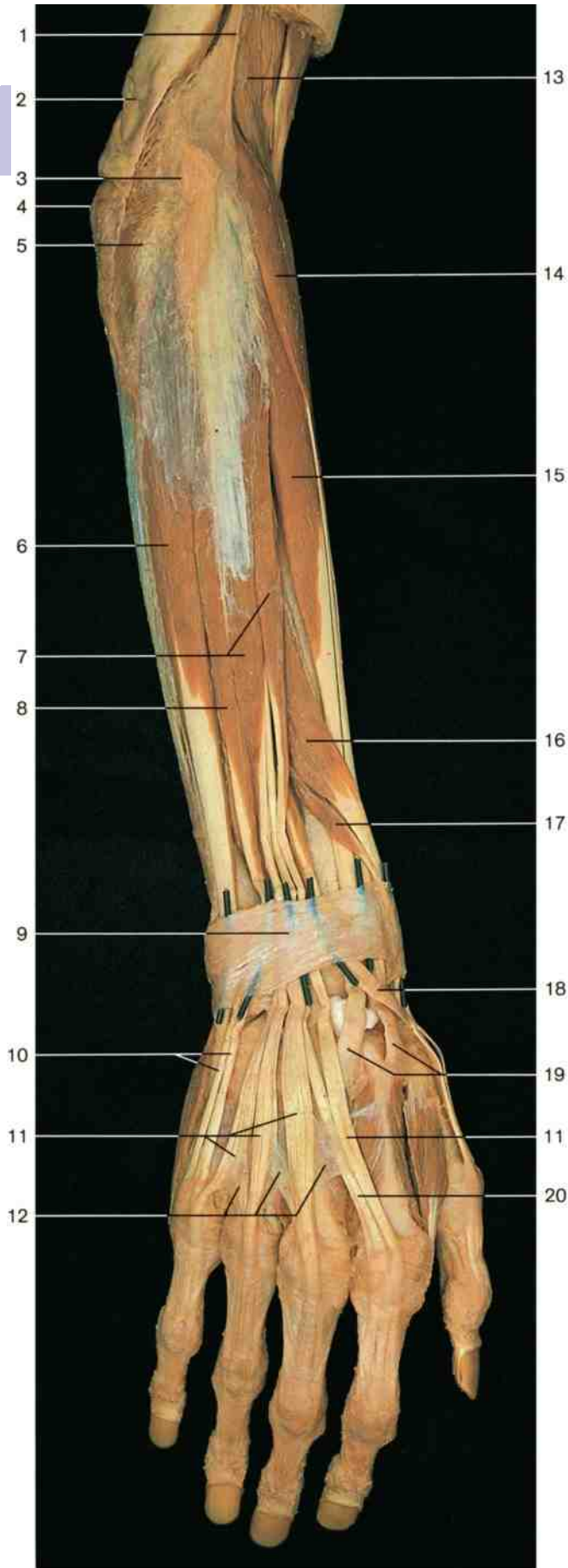


Synovial sheaths of flexor tendons (palmar aspect of right hand). Blue PVA solution has been injected into the sheaths.

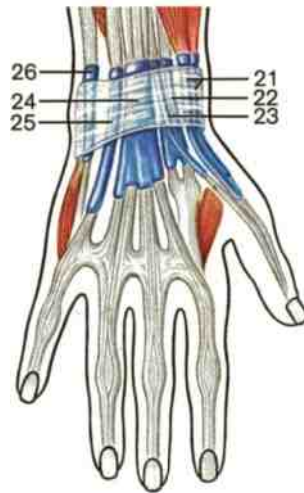


A = axis of flexion and extension
 B = axis of rotation
 Arrows:
 S = supination
 P = pronation

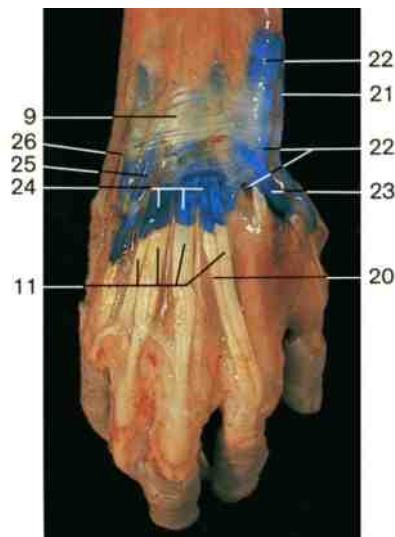
Diagram illustrating the two axes of the elbow joint.



- 1 Lateral intermuscular septum
- 2 Tendon of triceps brachii muscle
- 3 Lateral epicondyle of humerus
- 4 Olecranon
- 5 Anconeus muscle
- 6 Extensor carpi ulnaris muscle
- 7 Extensor digitorum muscle
- 8 Extensor digiti minimi muscle
- 9 Extensor retinaculum
- 10 Tendons of extensor digiti minimi muscle
- 11 Tendons of extensor digitorum muscle
- 12 Intertendinous connections
- 13 Brachioradialis muscle
- 14 Extensor carpi radialis longus muscle
- 15 Extensor carpi radialis brevis muscle
- 16 Abductor pollicis longus muscle
- 17 Extensor pollicis brevis muscle
- 18 Tendon of extensor pollicis longus muscle
- 19 Tendons of both extensor carpi radialis longus and extensor carpi radialis brevis muscles
- 20 Tendon of extensor indicis muscle
- 21 First tunnel: Abductor pollicis longus muscle, extensor pollicis brevis muscle
- 22 Second tunnel: Extensor carpi radialis longus and brevis muscles
- 23 Third tunnel: Extensor pollicis longus muscle
- 24 Fourth tunnel: Extensor digitorum muscle, extensor indicis muscle
- 25 Fifth tunnel: Extensor digiti minimi muscle
- 26 Sixth tunnel: Extensor carpi ulnaris muscle

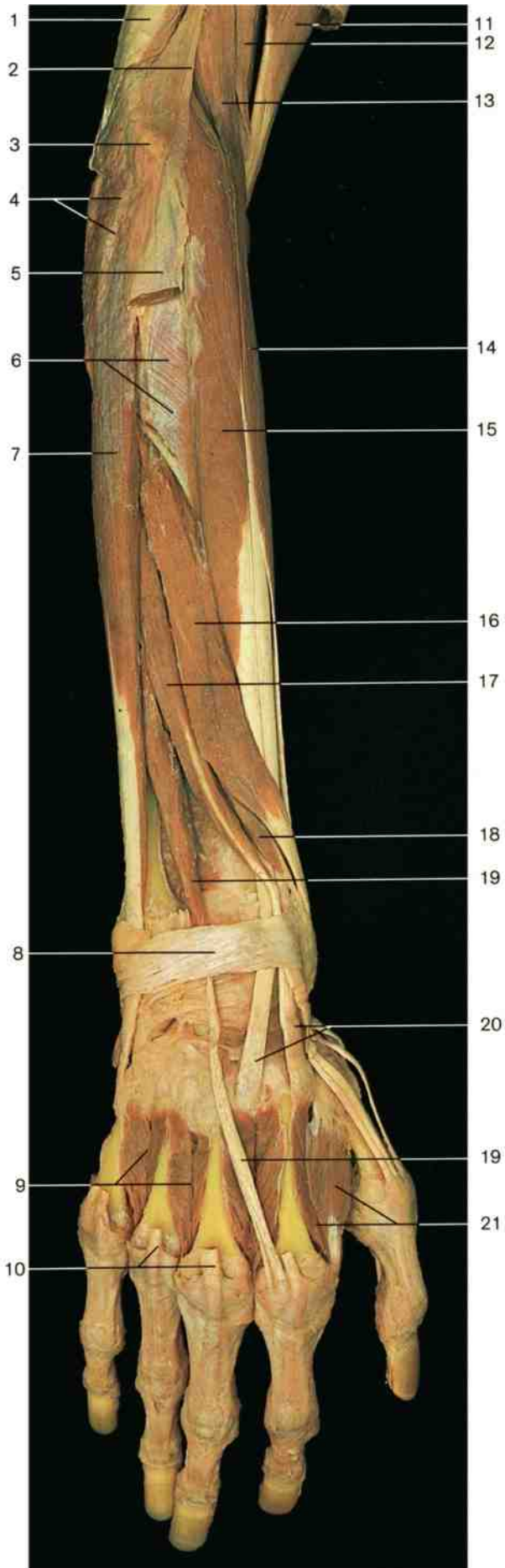


Synovial sheaths of extensor tendons on the back of the right wrist (indicated in blue). Notice the six tunnels for the passage of the extensor tendons beneath the extensor retinaculum (schematic drawing).

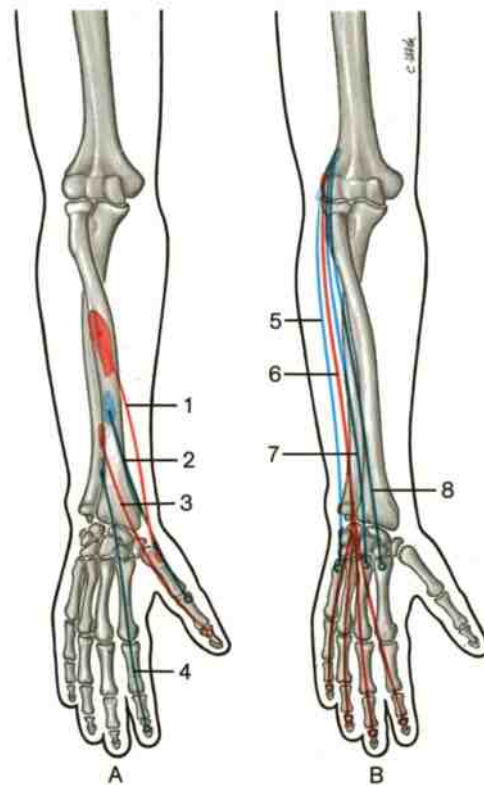


Synovial sheaths of extensor tendons. The sheaths have been injected with blue gelatin.

Extensor muscles of forearm and hand, superficial layer (dorsal aspect). Tunnels for extensor tendons indicated by probes.



- 1 Triceps brachii muscle
- 2 Lateral intermuscular septum
- 3 Lateral epicondyle of humerus
- 4 Anconeus muscle
- 5 Extensor digitorum and extensor digiti minimi muscles (cut)
- 6 Supinator muscle
- 7 Extensor carpi ulnaris muscle
- 8 Extensor retinaculum
- 9 Third and fourth dorsal interosseous muscles
- 10 Tendons of extensor digitorum muscle (cut)
- 11 Biceps brachii muscle
- 12 Brachialis muscle
- 13 Brachioradialis muscle
- 14 Extensor carpi radialis longus muscle
- 15 Extensor carpi radialis brevis muscle
- 16 Abductor pollicis longus muscle
- 17 Extensor pollicis longus muscle
- 18 Extensor pollicis brevis muscle
- 19 Extensor indicis muscle
- 20 Tendons of the extensor carpi radialis longus and extensor carpi radialis brevis muscles
- 21 First dorsal interosseous muscle



Position of extensor muscles of forearm and hand (schematic drawing).

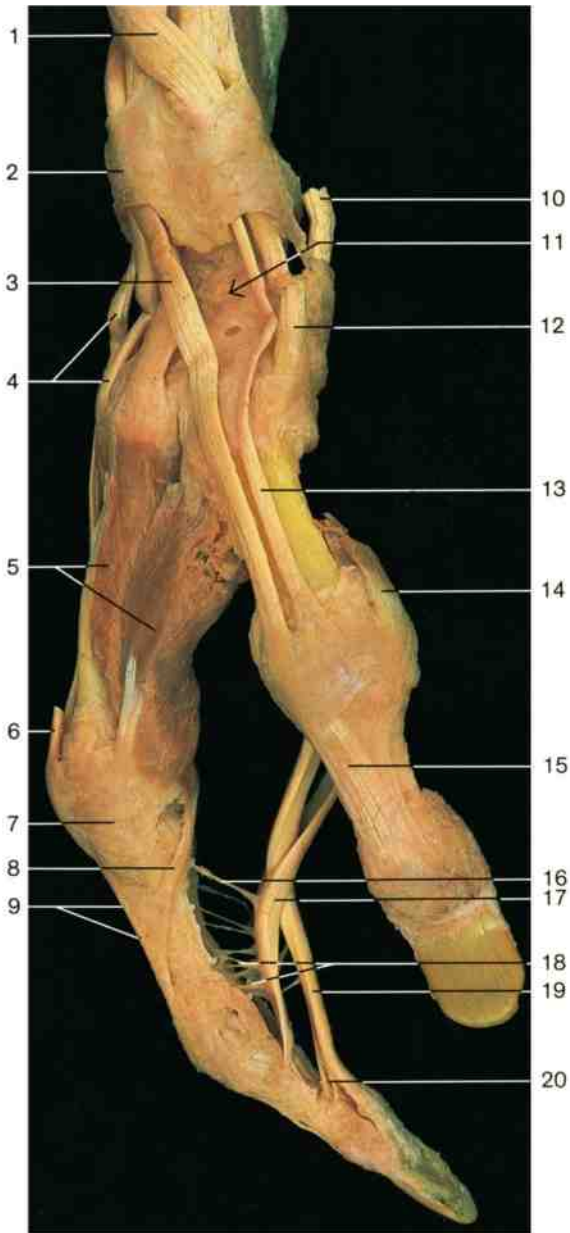
A Extensors of thumb

- 1 Abductor pollicis longus muscle (red)
- 2 Extensor pollicis brevis muscle (blue)
- 3 Extensor pollicis longus muscle (red)
- 4 Extensor indicis muscle (blue)

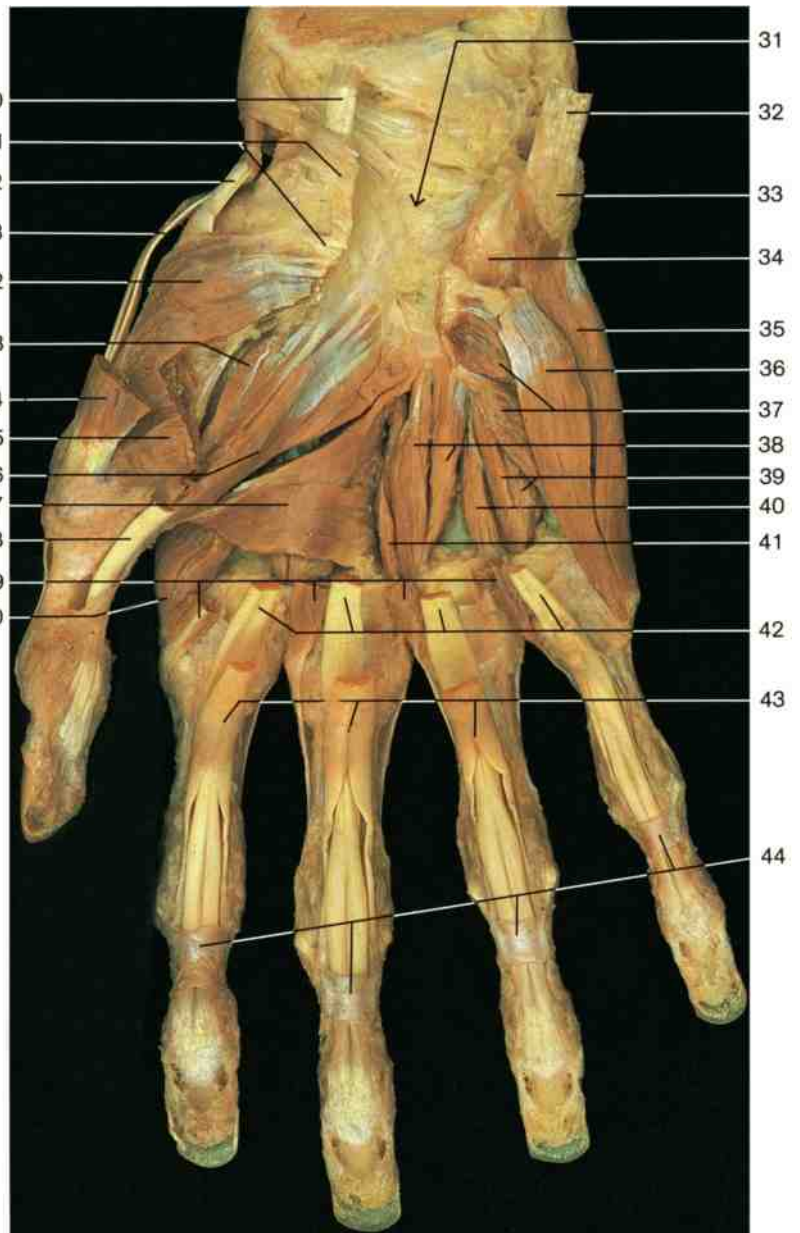
B Extensors of fingers and hand

- 5 Extensor carpi ulnaris muscle (blue)
- 6 Extensor digitorum muscle (red)
- 7 Extensor carpi radialis brevis muscle (blue)
- 8 Extensor carpi radialis longus muscle (blue)

Extensor muscles of forearm and hand, deep layer (dorsal aspect).

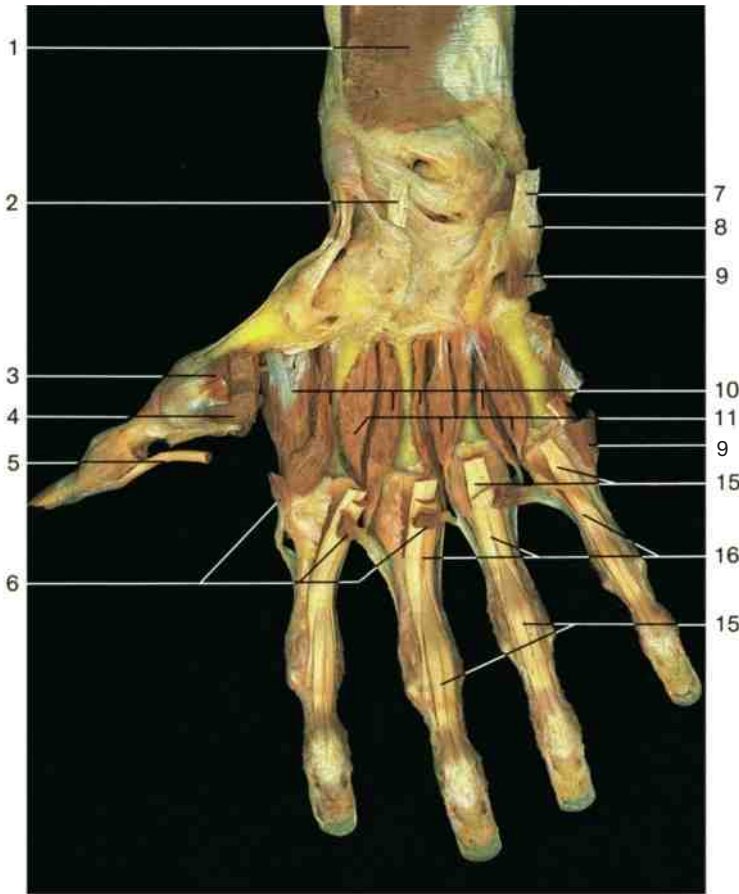


Muscles of thumb and index finger (medial aspect). The tendons of the extensor muscles of the thumb and the insertion of the flexor tendons of the index finger are displayed.

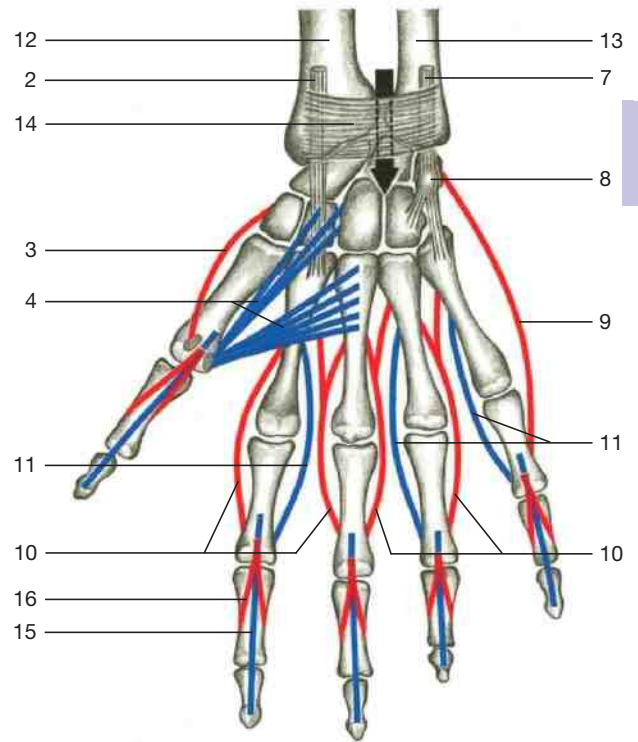


Muscles of right hand (palmar aspect). The tendons of the flexor muscles and parts of the thumb muscles have been removed. The carpal tunnel has been opened.

- | | | |
|--|---|--|
| <ul style="list-style-type: none"> 1 Tendons of extensor pollicis brevis and abductor pollicis longus muscle 2 Extensor retinaculum 3 Tendon of extensor pollicis longus muscle 4 Tendons of extensor carpi radialis longus and brevis muscles 5 First dorsal interosseous muscle 6 Tendon of extensor digitorum muscle for index finger 7 Location of metacarpophalangeal joint 8 Tendon of lumbrical muscle 9 Extensor expansion of index finger 10 Tendon of flexor carpi radialis muscle (cut) 11 Anatomical snuffbox 12 Tendon of abductor pollicis longus muscle 13 Tendon of extensor pollicis brevis muscle 14 Tendon of abductor pollicis brevis muscle | <ul style="list-style-type: none"> 15 Extensor expansion of extensor of thumb 16 Vinculum longum 17 Tendons of flexor digitorum superficialis muscle dividing to allow passage of deep tendons 18 Vincula of flexor tendons 19 Tendon of flexor digitorum profundus muscle 20 Vinculum breve 21 Radial carpal eminence (cut edge of flexor retinaculum) 22 Opponens pollicis muscle 23 Deep head of flexor pollicis brevis muscle 24 Abductor pollicis brevis muscle (cut) 25 Superficial head of flexor pollicis brevis muscle (cut) 26 Oblique head of adductor pollicis muscle 27 Transverse head of adductor pollicis muscle 28 Tendon of flexor pollicis longus muscle (cut) | <ul style="list-style-type: none"> 29 Lumbrical muscles (cut) 30 First dorsal interosseous muscle 31 Position of carpal tunnel 32 Tendon of flexor carpi ulnaris muscle 33 Location of pisiform bone 34 Hook of hamate bone 35 Abductor digiti minimi muscle 36 Flexor digiti minimi brevis muscle 37 Opponens digiti minimi muscle 38 Second palmar interosseous muscle 39 Third palmar interosseous muscle 40 Fourth dorsal interosseous muscle 41 Third dorsal interosseous muscle 42 Tendon of flexor digitorum profundus muscle (cut) 43 Tendons of flexor digitorum superficialis muscle (cut) 44 Fibrous flexor sheaths |
|--|---|--|

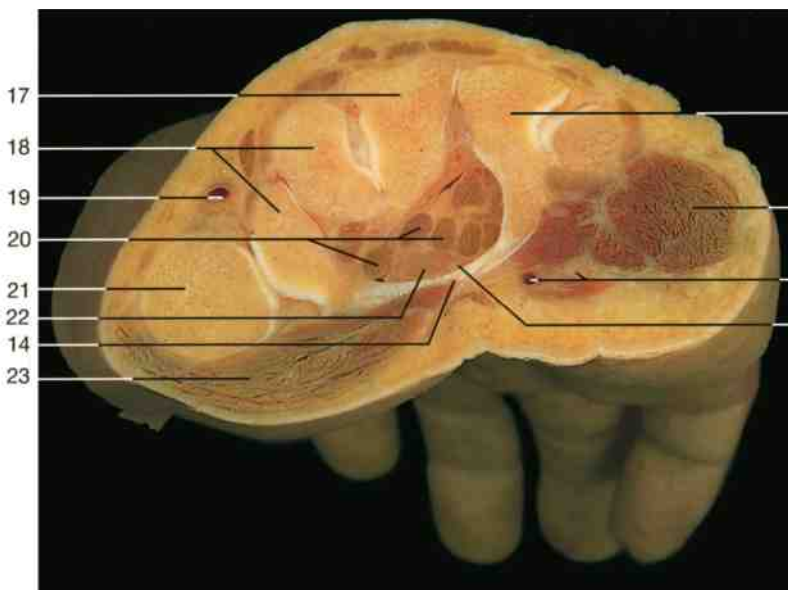


Muscles of right hand, deep layer (palmar aspect). The thenar and hypothenar muscles have been removed to display the interosseous muscles.



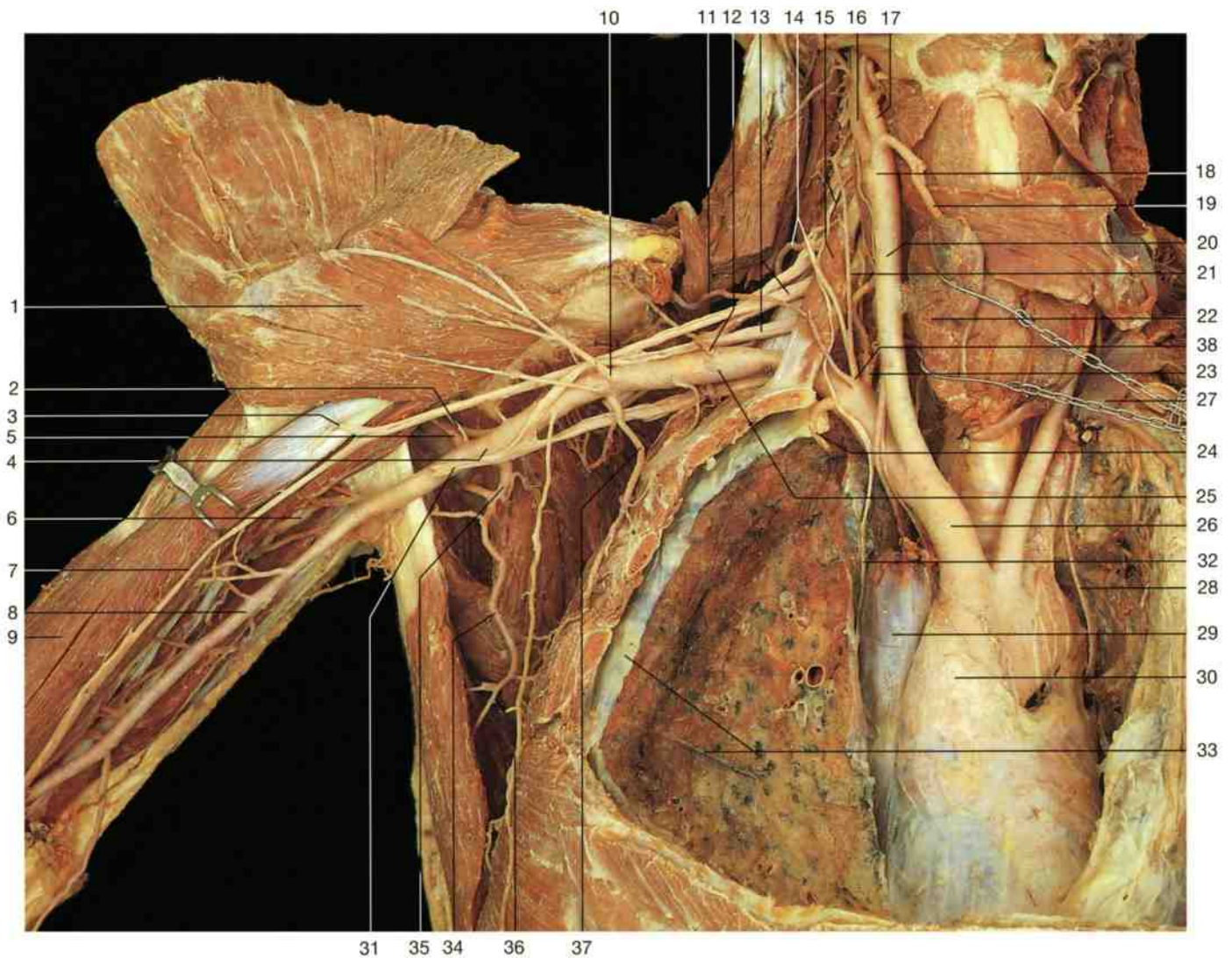
Actions of interosseous muscles in abduction and adduction of fingers (palmar aspect, schematic drawing). Arrow: carpal tunnel.

Red = abduction (dorsal interosseous, abductor digiti minimi, and abductor pollicis brevis muscles)
 Blue = adduction (palmar interosseous muscles, adductor pollicis muscle)



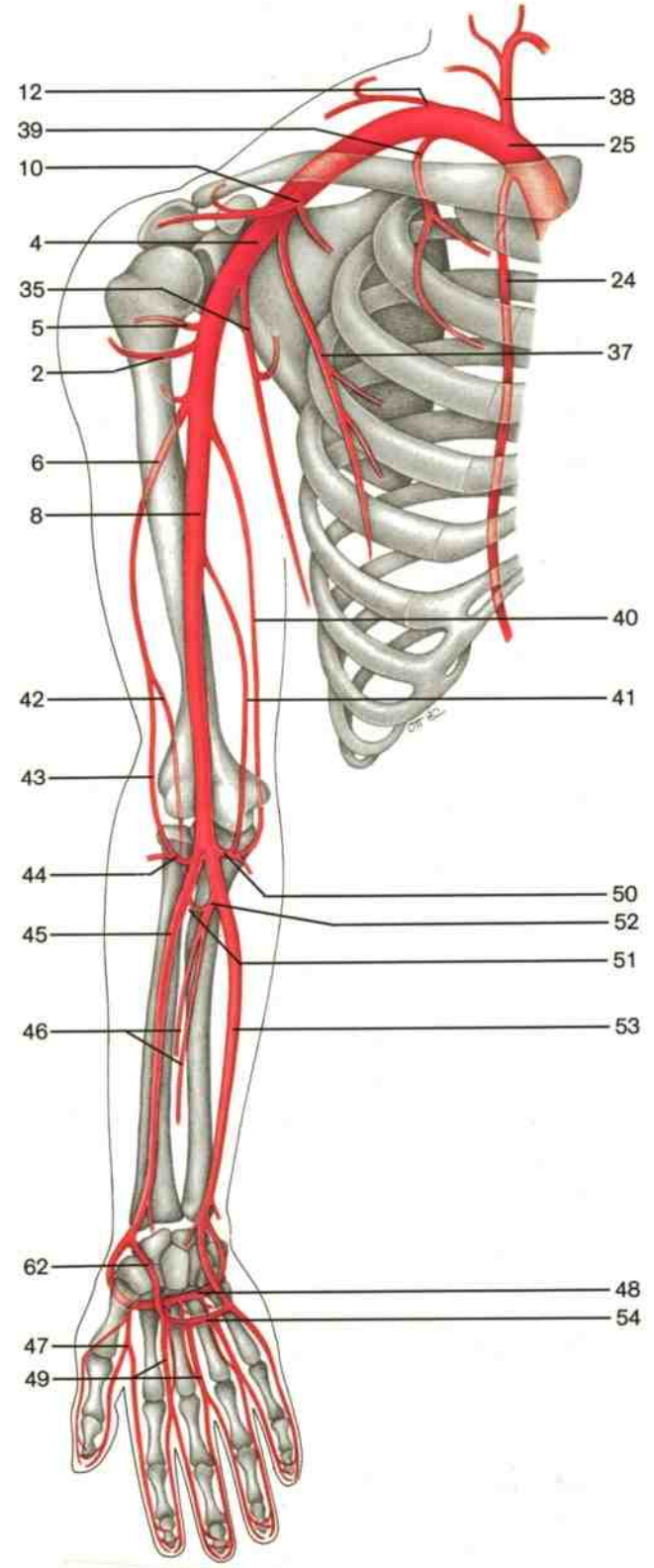
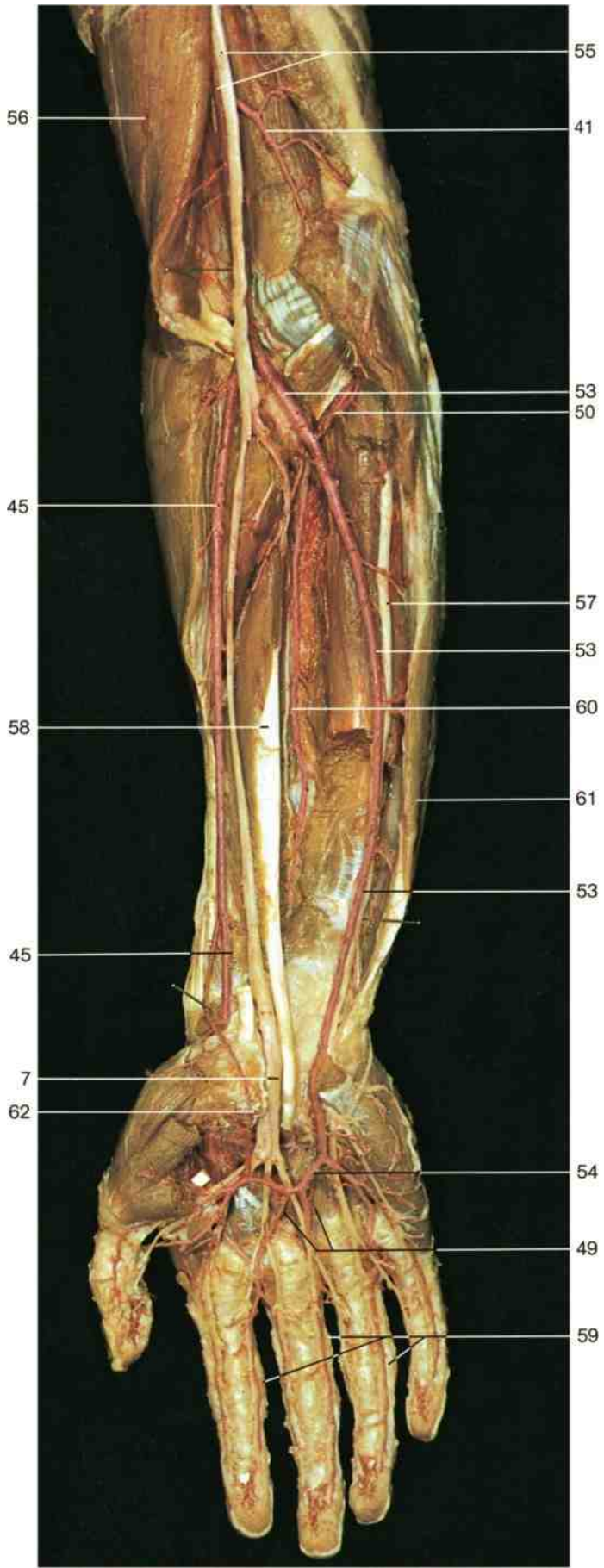
Transverse section through the right hand, showing the carpal tunnel (canalis carpi).

- 1 Pronator quadratus muscle
- 2 Tendon of flexor carpi radialis muscle
- 3 Abductor pollicis brevis muscle (divided)
- 4 Adductor pollicis muscle (divided)
- 5 Tendon of flexor pollicis longus muscle
- 6 Lumbrical muscles (cut)
- 7 Tendon of flexor carpi ulnaris muscle
- 8 Pisiform bone
- 9 Abductor digiti minimi muscle (divided)
- 10 Dorsal interosseous muscles
- 11 Palmar interosseous muscles
- 12 Radius
- 13 Ulna
- 14 Flexor retinaculum
- 15 Tendons of flexor digitorum profundus muscle
- 16 Tendons of flexor digitorum superficialis muscle
- 17 Capitate bone
- 18 Trapezium bone and trapezoid bone
- 19 Radial artery
- 20 Tendon of flexor muscles
- 21 First metacarpal bone
- 22 Median nerve
- 23 Thenar muscles
- 24 Hamate bone
- 25 Hypothenar muscles
- 26 Ulnar artery and nerve
- 27 Carpal tunnel (canalis carpi)



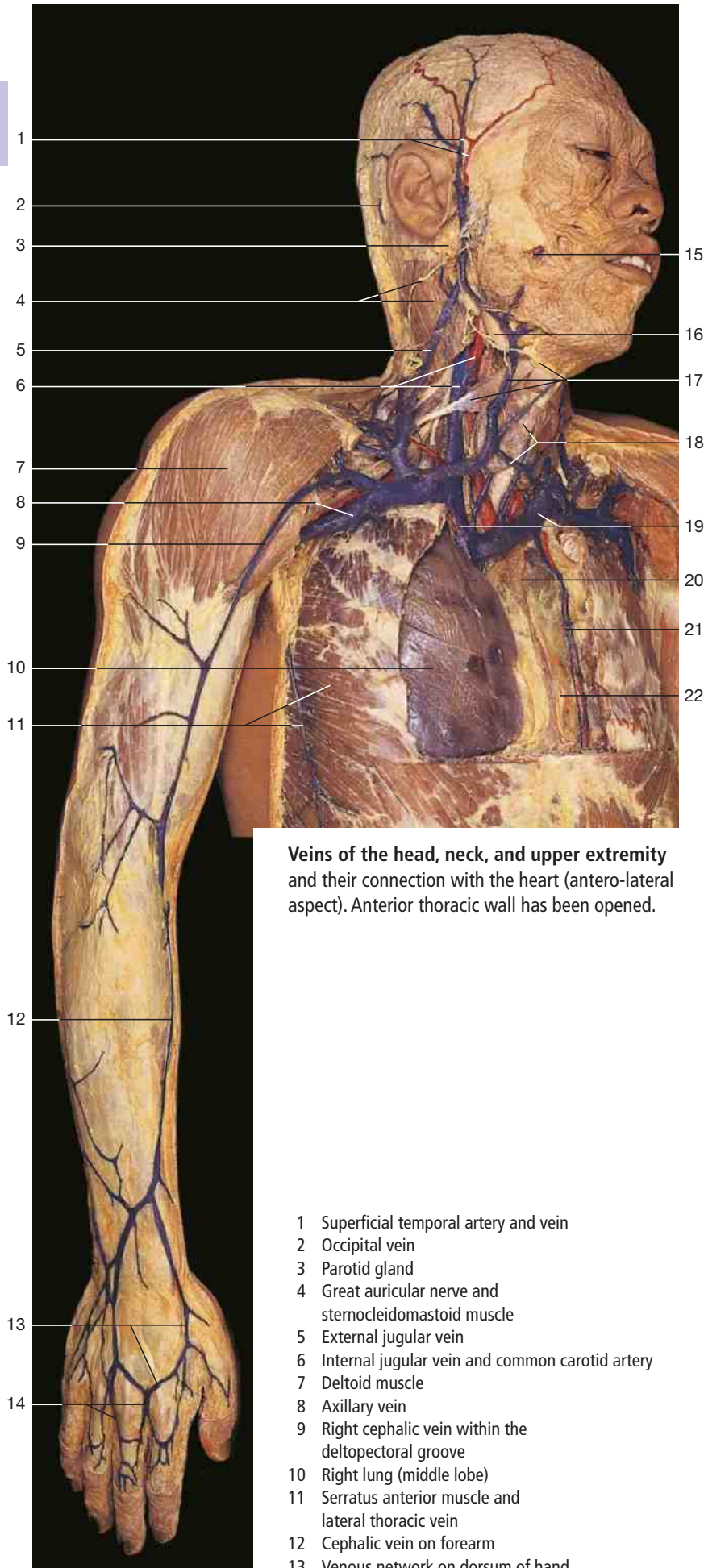
Main branches of right subclavian and axillary arteries (anterior aspect). Pectoralis muscles have been reflected, clavicle and anterior wall of thorax removed, and right lung divided. Left lung with pleura and thyroid gland have been reflected laterally to display aortic arch and common carotid artery with their branches.

- | | | |
|---|--|---|
| 1 Pectoralis minor muscle (reflected) | 22 Thyroid gland | 43 Radial collateral artery |
| 2 Anterior circumflex humeral artery | 23 Inferior thyroid artery | 44 Radial recurrent artery |
| 3 Musculocutaneous nerve (divided) | 24 Internal thoracic artery | 45 Radial artery |
| 4 Axillary artery | 25 Right subclavian artery | 46 Anterior and posterior interosseous arteries |
| 5 Posterior circumflex humeral artery | 26 Brachiocephalic trunk | 47 Princeps pollicis artery |
| 6 Profunda brachii artery | 27 Left brachiocephalic vein (divided) | 48 Deep palmar arch |
| 7 Median nerve (var.) | 28 Left vagus nerve | 49 Common palmar digital arteries |
| 8 Brachial artery | 29 Superior vena cava (divided) | 50 Ulnar recurrent artery |
| 9 Biceps brachii muscle | 30 Ascending aorta | 51 Recurrent interosseous artery |
| 10 Thoraco-acromial artery | 31 Median nerve (divided) | 52 Common interosseous artery |
| 11 Suprascapular artery | 32 Phrenic nerve | 53 Ulnar artery |
| 12 Descending scapular artery | 33 Right lung (divided) and pulmonary pleura | 54 Superficial palmar arch |
| 13 Brachial plexus (middle trunk) | 34 Thoracodorsal artery | 55 Median nerve and brachial artery |
| 14 Transverse cervical artery | 35 Subscapular artery | 56 Biceps brachii muscle |
| 15 Scalenus anterior muscle and phrenic nerve | 36 Lateral mammary branches (variant) | 57 Ulnar nerve |
| 16 Right internal carotid artery | 37 Lateral thoracic artery | 58 Flexor pollicis longus muscle |
| 17 Right external carotid artery | 38 Thyrocervical trunk | 59 Palmar digital arteries |
| 18 Carotid sinus | 39 Superior thoracic artery | 60 Anterior interosseous artery |
| 19 Superior thyroid artery | 40 Superior ulnar collateral artery | 61 Flexor carpi ulnaris muscle |
| 20 Right common carotid artery | 41 Inferior ulnar collateral artery | 62 Superficial palmar branch of radial artery |
| 21 Ascending cervical artery | 42 Middle collateral artery | |



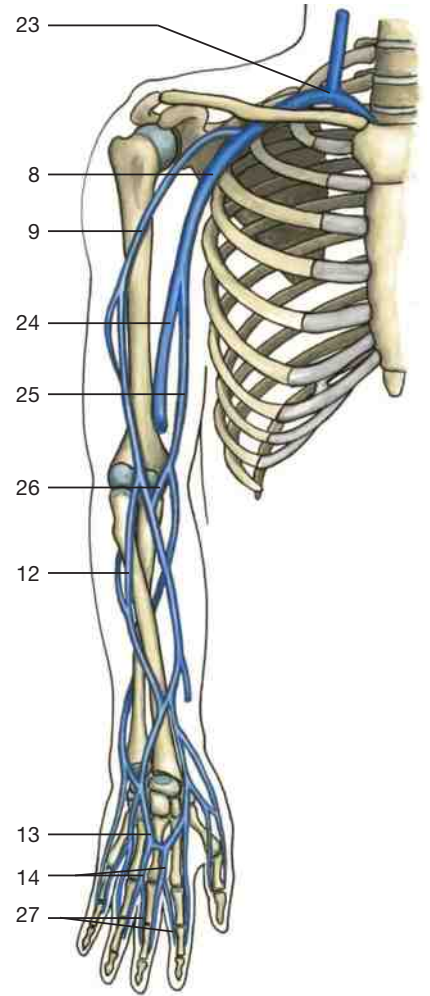
Arteries of the upper limb (schematic drawing).

Dissection of the arteries of forearm and hand.
 The superficial flexor muscles have been removed, the carpal tunnel opened, and the flexor retinaculum cut. The arteries have been filled with colored resin.



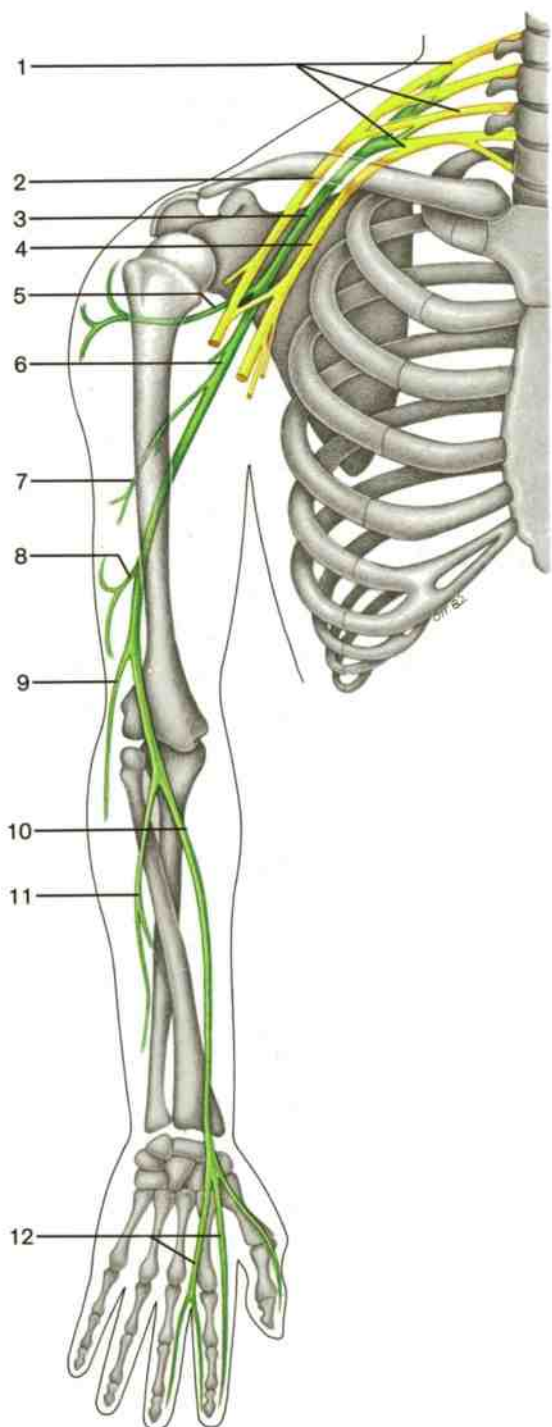
Veins of the head, neck, and upper extremity and their connection with the heart (antero-lateral aspect). Anterior thoracic wall has been opened.

- 1 Superficial temporal artery and vein
- 2 Occipital vein
- 3 Parotid gland
- 4 Great auricular nerve and sternocleidomastoid muscle
- 5 External jugular vein
- 6 Internal jugular vein and common carotid artery
- 7 Deltoid muscle
- 8 Axillary vein
- 9 Right cephalic vein within the deltopectoral groove
- 10 Right lung (middle lobe)
- 11 Serratus anterior muscle and lateral thoracic vein
- 12 Cephalic vein on forearm
- 13 Venous network on dorsum of hand
- 15 Facial artery and vein
- 16 Submandibular gland
- 17 Anterior jugular vein, hyoid bone, and omohyoid muscle
- 18 Jugular venous arch and thyroid gland
- 19 Right and left brachiocephalic veins
- 20 Retrosternal body (remnant of thymus gland)
- 21 Internal thoracic artery and vein
- 22 Heart with pericardium



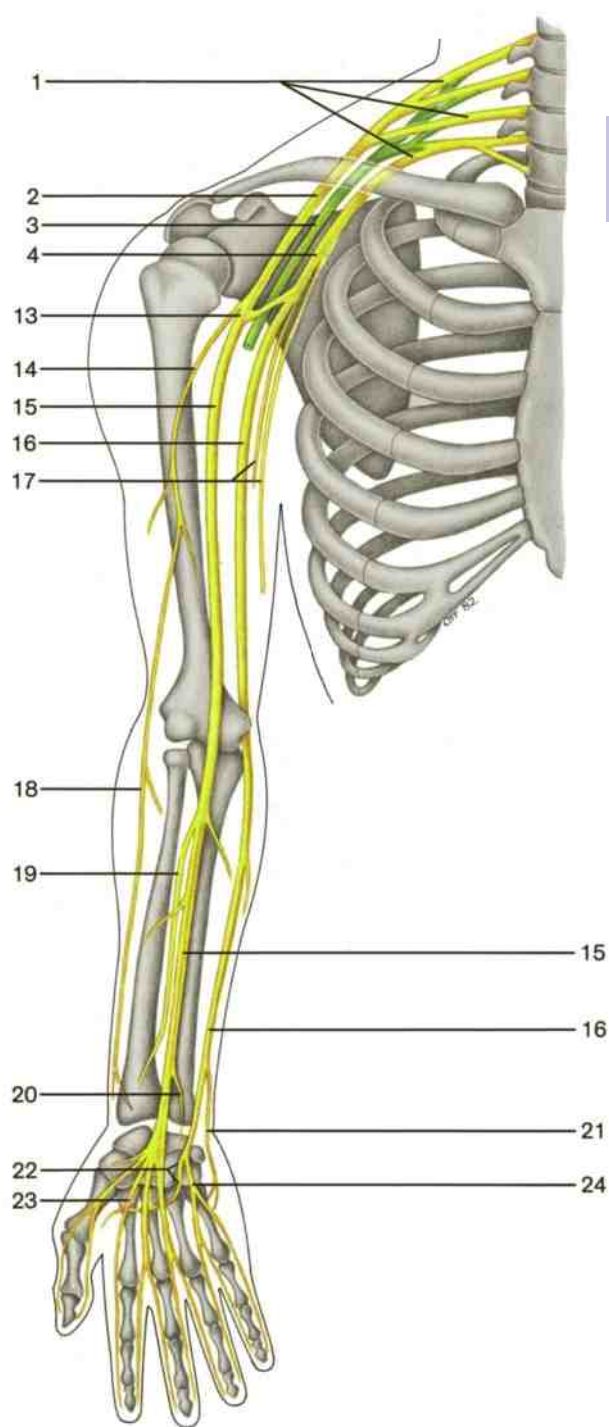
Superficial veins of upper limb (schematic drawing).

- 14 Dorsal metacarpal veins
- 23 Right venous angle
- 24 Brachial vein
- 25 Basilic vein
- 26 Median cubital vein
- 27 Digital veins



Main branches of radial nerve (schematic drawing). Posterior divisions of trunks and posterior cord and its branches are indicated in green.

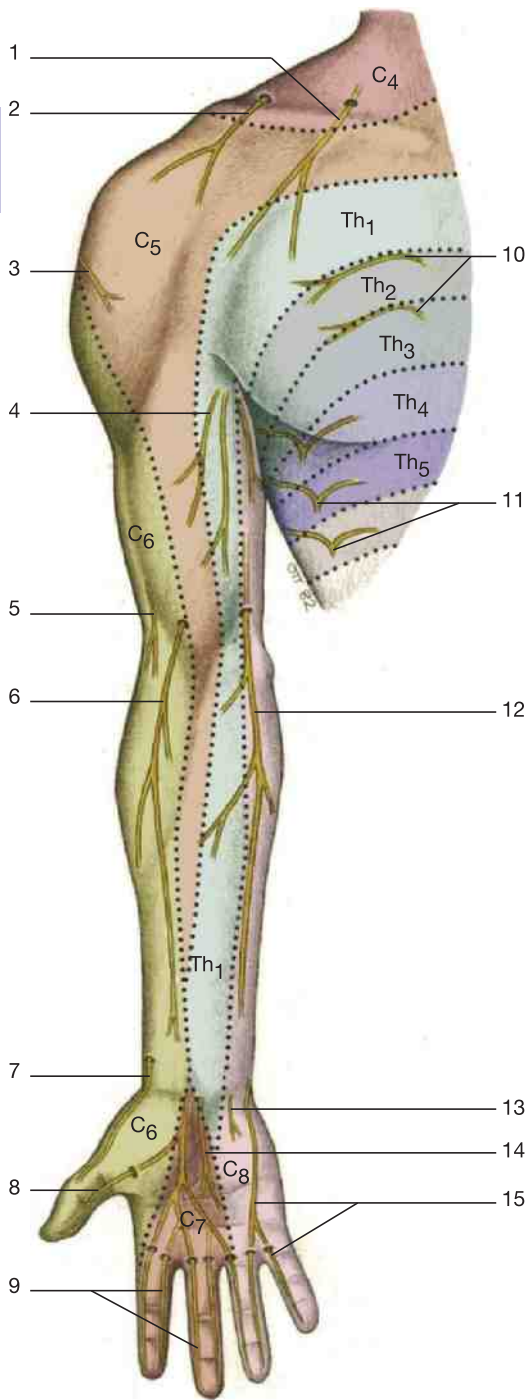
- 1 Brachial plexus
- 2 Lateral cord of brachial plexus
- 3 Posterior cord of brachial plexus
- 4 Medial cord of brachial plexus
- 5 Axillary nerve
- 6 Radial nerve
- 7 Posterior cutaneous nerve of arm
- 8 Lower lateral cutaneous nerve of arm
- 9 Posterior cutaneous nerve of forearm
- 10 Superficial branch of radial nerve
- 11 Deep branch of radial nerve
- 12 Dorsal digital nerves



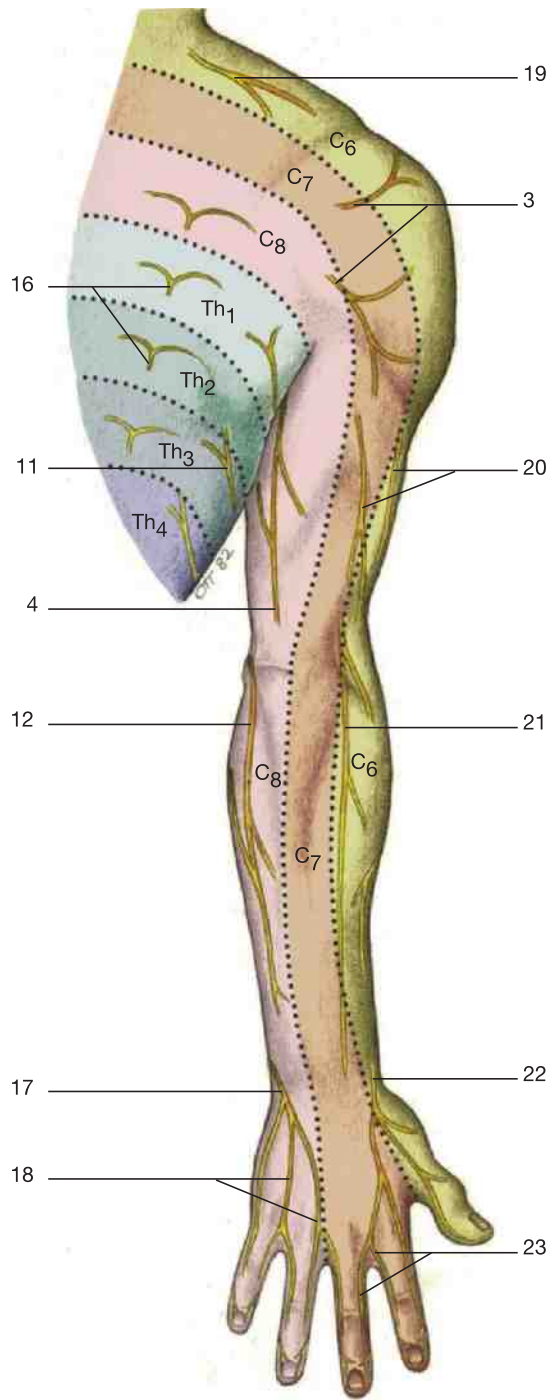
Main branches of musculocutaneous, median, and ulnar nerves (schematic drawing). Anterior divisions of the trunks and all the components arising from them are indicated in yellow.

- 13 Roots of median nerve
- 14 Musculocutaneous nerve
- 15 Median nerve
- 16 Ulnar nerve
- 17 Medial cutaneous nerves of arm and forearm
- 18 Lateral cutaneous nerve of forearm
- 19 Anterior interosseous nerve
- 20 Palmar branch of median nerve
- 21 Dorsal branch of ulnar nerve
- 22 Deep branch of ulnar nerve
- 23 Common palmar digital nerves of median nerve
- 24 Superficial branch of ulnar nerve





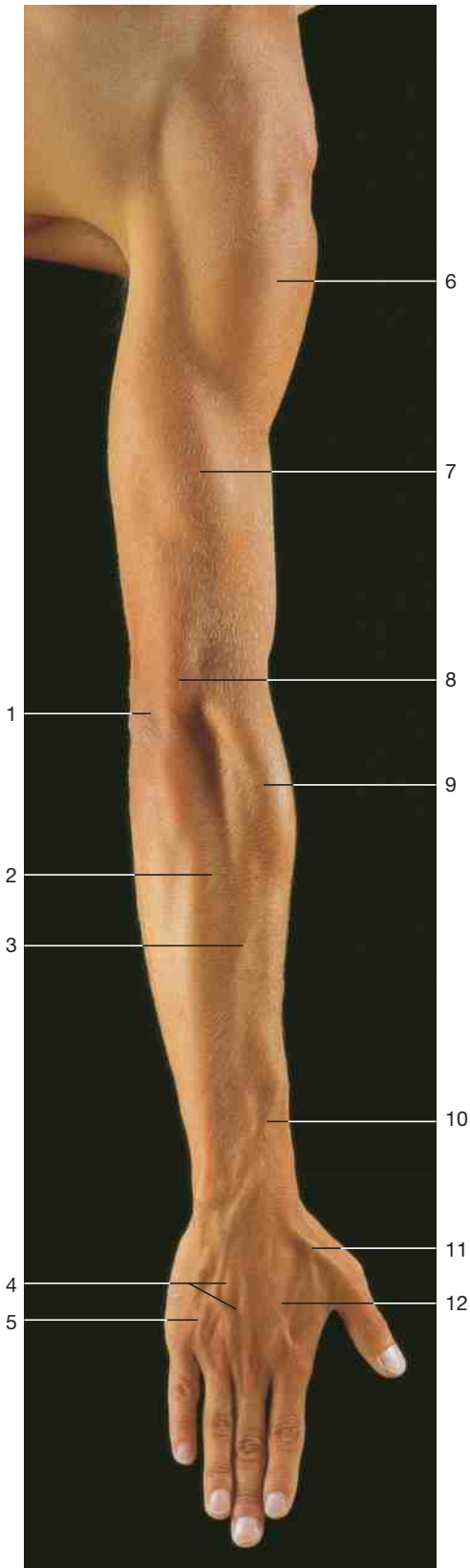
Cutaneous nerves of the right upper limb
(ventral aspect, schematic drawing).



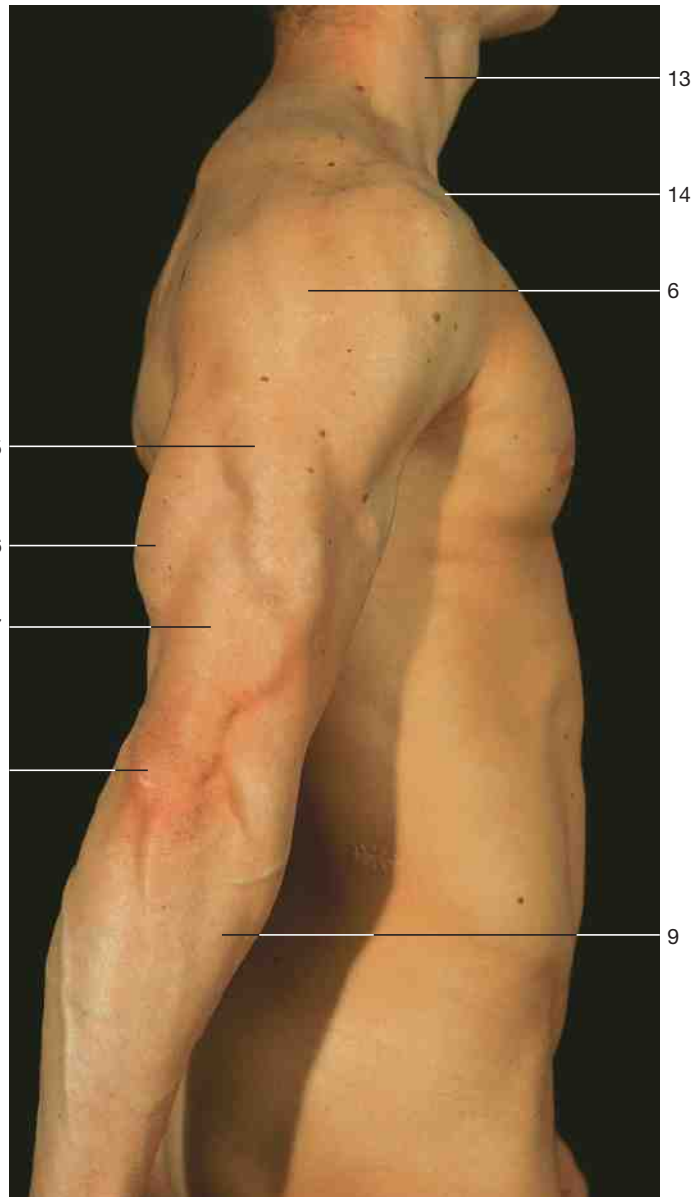
Cutaneous nerves of the right upper limb
(dorsal aspect, schematic drawing).

- 1 Medial supraclavicular nerve
- 2 Intermediate supraclavicular nerve
- 3 Upper lateral cutaneous nerve of arm
- 4 Terminal branches of intercostobrachial nerves
- 5 Lower lateral cutaneous nerve of arm
- 6 Lateral cutaneous nerve of forearm
- 7 Terminal branch of superficial branch of radial nerve
- 8 Palmar digital nerve of thumb (branch of median nerve)
- 9 Palmar digital branches of median nerve
- 10 Anterior cutaneous branches of intercostal nerves
- 11 Lateral cutaneous branches of intercostal nerves
- 12 Medial cutaneous nerve of forearm

- 13 Palmar cutaneous branch of ulnar nerve
 - 14 Palmar branch of median nerve
 - 15 Palmar digital branches of ulnar nerve
 - 16 Cutaneous branches of dorsal rami of spinal nerves
 - 17 Dorsal branch of ulnar nerve
 - 18 Dorsal digital nerves
 - 19 Posterior supraclavicular nerve
 - 20 Posterior cutaneous nerve of arm
 - 21 Posterior cutaneous nerve of forearm
 - 22 Superficial branch
 - 23 Dorsal digital branches
- } from radial nerve

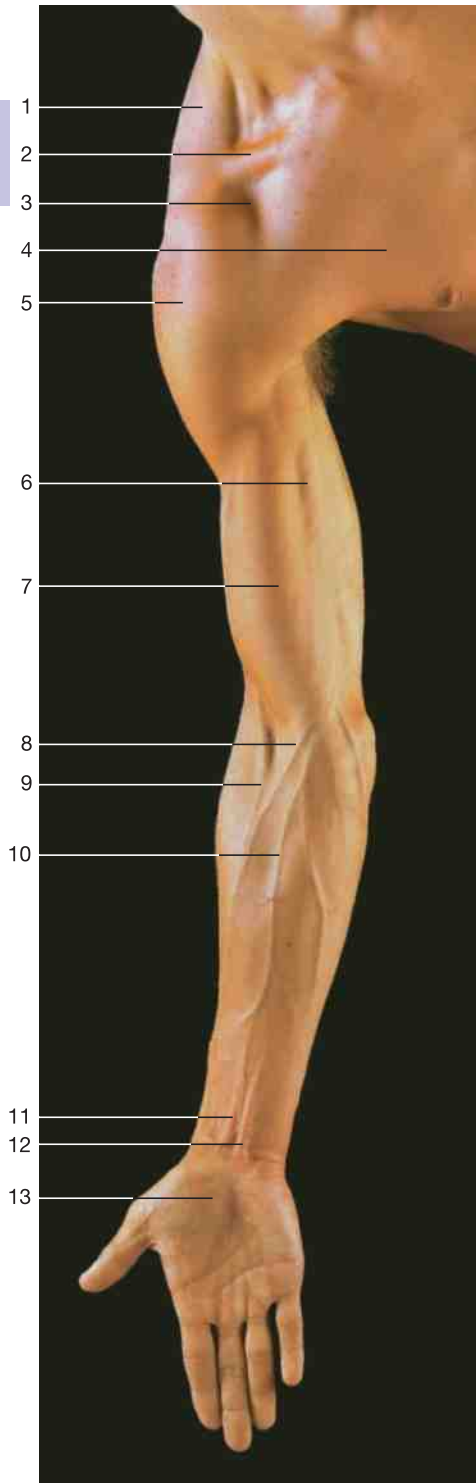


Surface anatomy of the right arm and hand (posterior aspect).

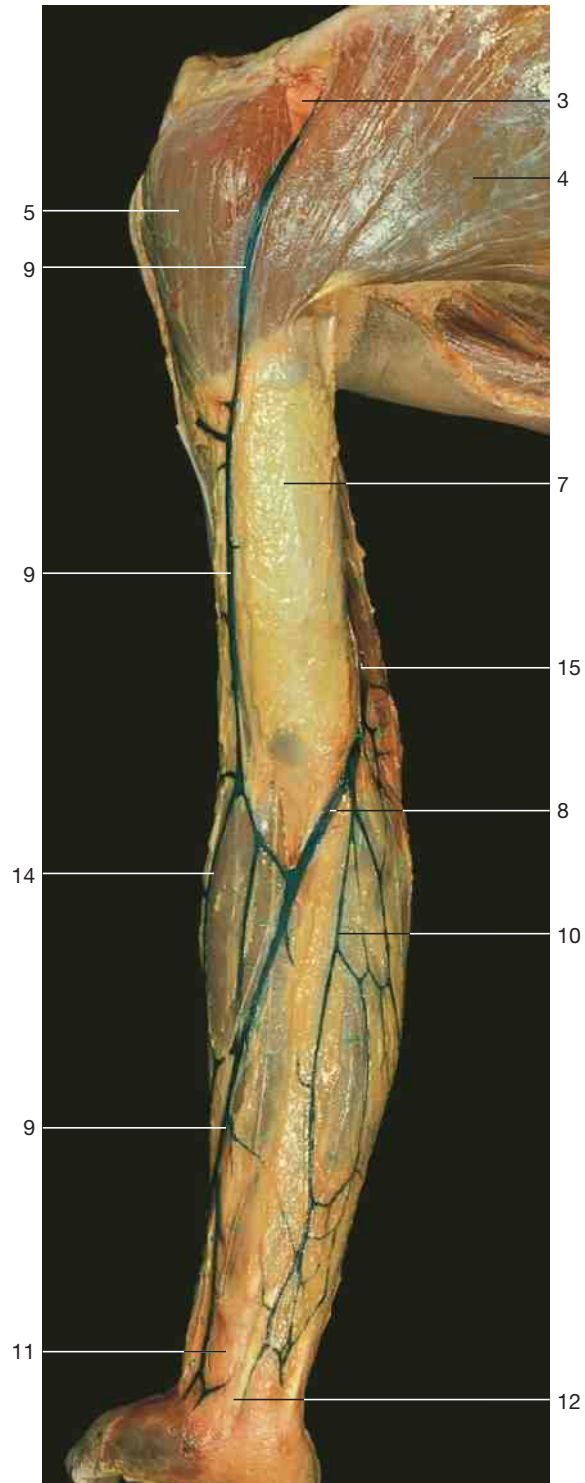


Surface anatomy of the right arm (lateral aspect).
Triceps brachii muscle is strongly contracted.

- | | |
|--|--|
| 1 Olecranon | 11 Tendon of abductor pollicis longus muscle |
| 2 Extensor muscles of forearm | 12 Tendon of extensor indicis muscle |
| 3 Accessory cephalic vein | 13 Sternocleidomastoid muscle |
| 4 Tendons of extensor digitorum muscle | 14 Clavicle |
| 5 Dorsal venous network of hand | 15 Lateral head of triceps brachii muscle |
| 6 Deltoid muscle | 16 Medial head of triceps brachii muscle |
| 7 Triceps brachii muscle | 17 Tendon of triceps brachii muscle |
| 8 Lateral epicondyle of humerus | |
| 9 Brachioradialis muscle | |
| 10 Cephalic vein | |



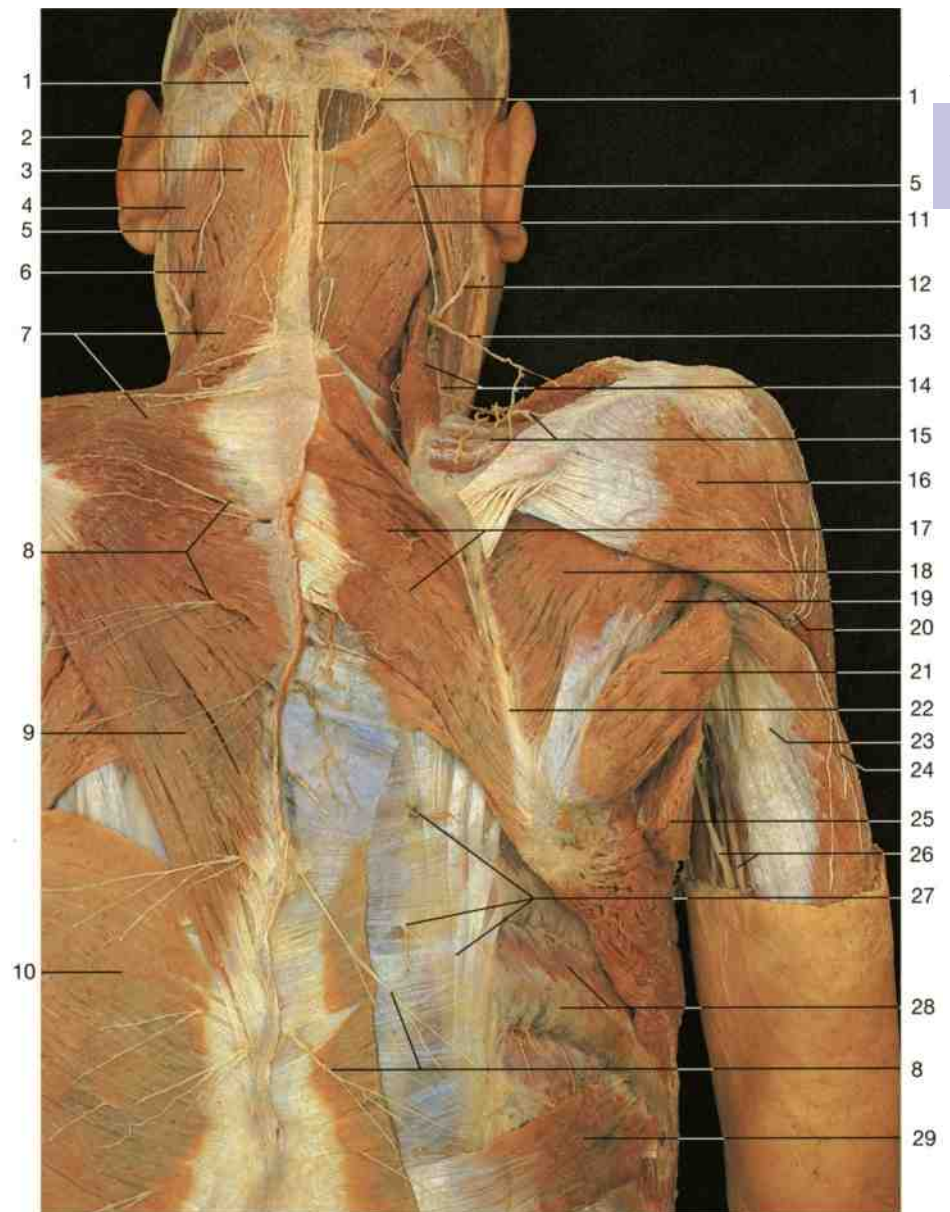Surface anatomy of the right arm and hand (anterior aspect).



Superficial veins of the right arm, injected with blue gelatine (anterior aspect).

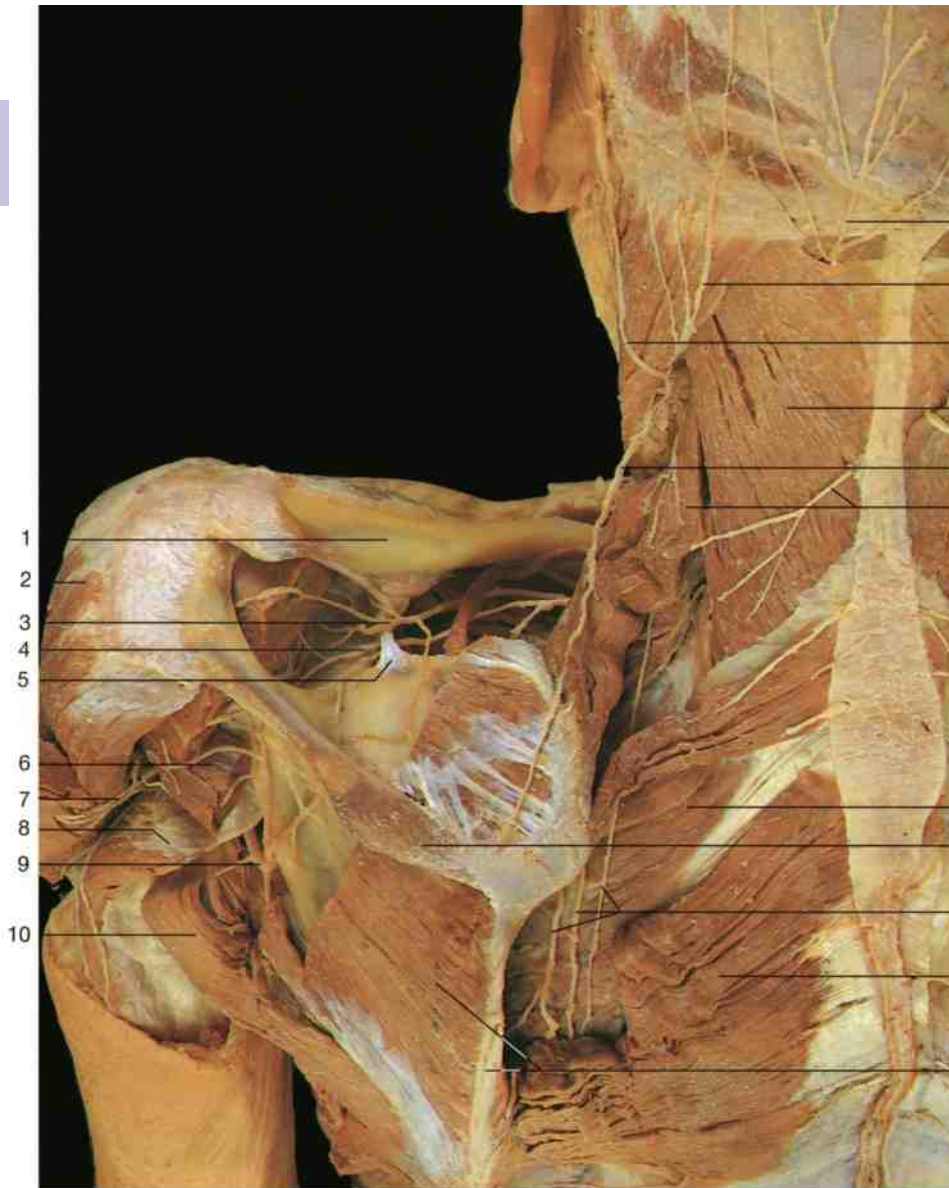
- 1 Trapezius muscle
- 2 Clavicle
- 3 Deltopectoral triangle
- 4 Pectoralis major muscle
- 5 Deltoid muscle
- 6 Brachial vein
- 7 Biceps brachii muscle

- 8 Median cubital vein
- 9 Cephalic vein
- 10 Median vein of forearm
- 11 Tendon of flexor carpi radialis
- 12 Tendon of palmaris longus muscle
- 13 Location of adductor pollicis muscle
- 14 Accessory cephalic vein
- 15 Basilic vein



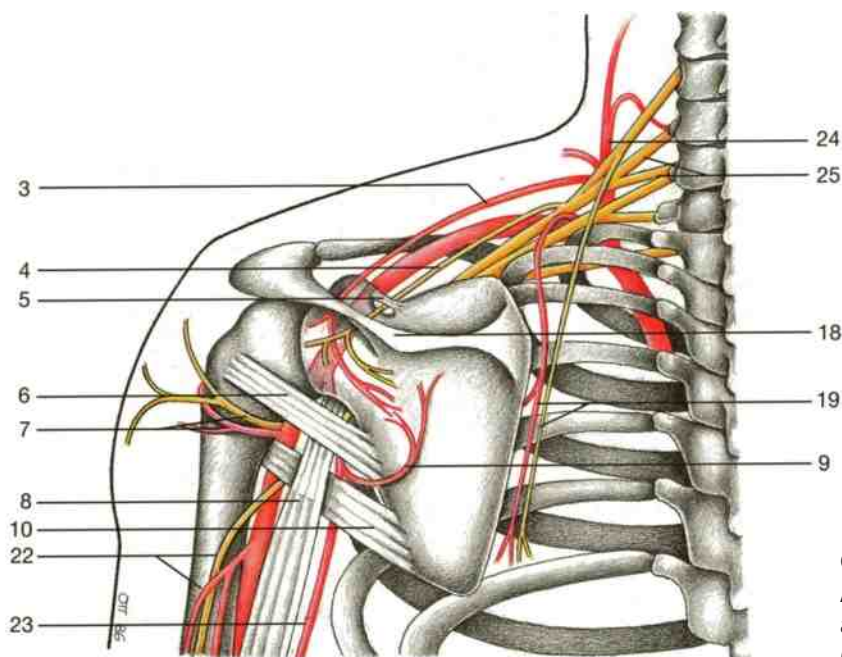
Posterior regions of neck and shoulder (dorsal aspect). Left side: superficial layer. Right side: trapezius and latissimus dorsi muscles have been removed. Dissection of dorsal branches of spinal nerves.

- | | |
|--|--|
| 1 Greater occipital nerve | 16 Deltoid muscle |
| 2 Ligamentum nuchae | 17 Rhomboid major muscle |
| 3 Splenius capitis muscle | 18 Infraspinatus muscle |
| 4 Sternocleidomastoid muscle | 19 Teres minor muscle |
| 5 Lesser occipital nerve | 20 Upper lateral cutaneous nerve of arm (branch of axillary nerve) |
| 6 Splenius cervicis muscle | 21 Teres major muscle |
| 7 Descending and transverse fibers of trapezius muscle | 22 Medial margin of scapula |
| 8 Medial cutaneous branches of dorsal rami of spinal nerves | 23 Long head of triceps muscle |
| 9 Ascending fibers of trapezius muscle | 24 Posterior cutaneous nerve of arm (branch of radial nerve) |
| 10 Latissimus dorsi muscle | 25 Latissimus dorsi muscle (divided) |
| 11 Cutaneous branch of third occipital nerve | 26 Ulnar nerve and brachial artery |
| 12 Great auricular nerve | 27 Lateral cutaneous branches of dorsal rami of spinal nerves and iliocostalis thoracis muscle |
| 13 Accessory nerve (n. XI) | 28 External intercostal muscle and seventh rib |
| 14 Posterior supraclavicular nerve and levator scapulae muscle | 29 Serratus posterior inferior muscle |
| 15 Branches of suprascapular artery | |

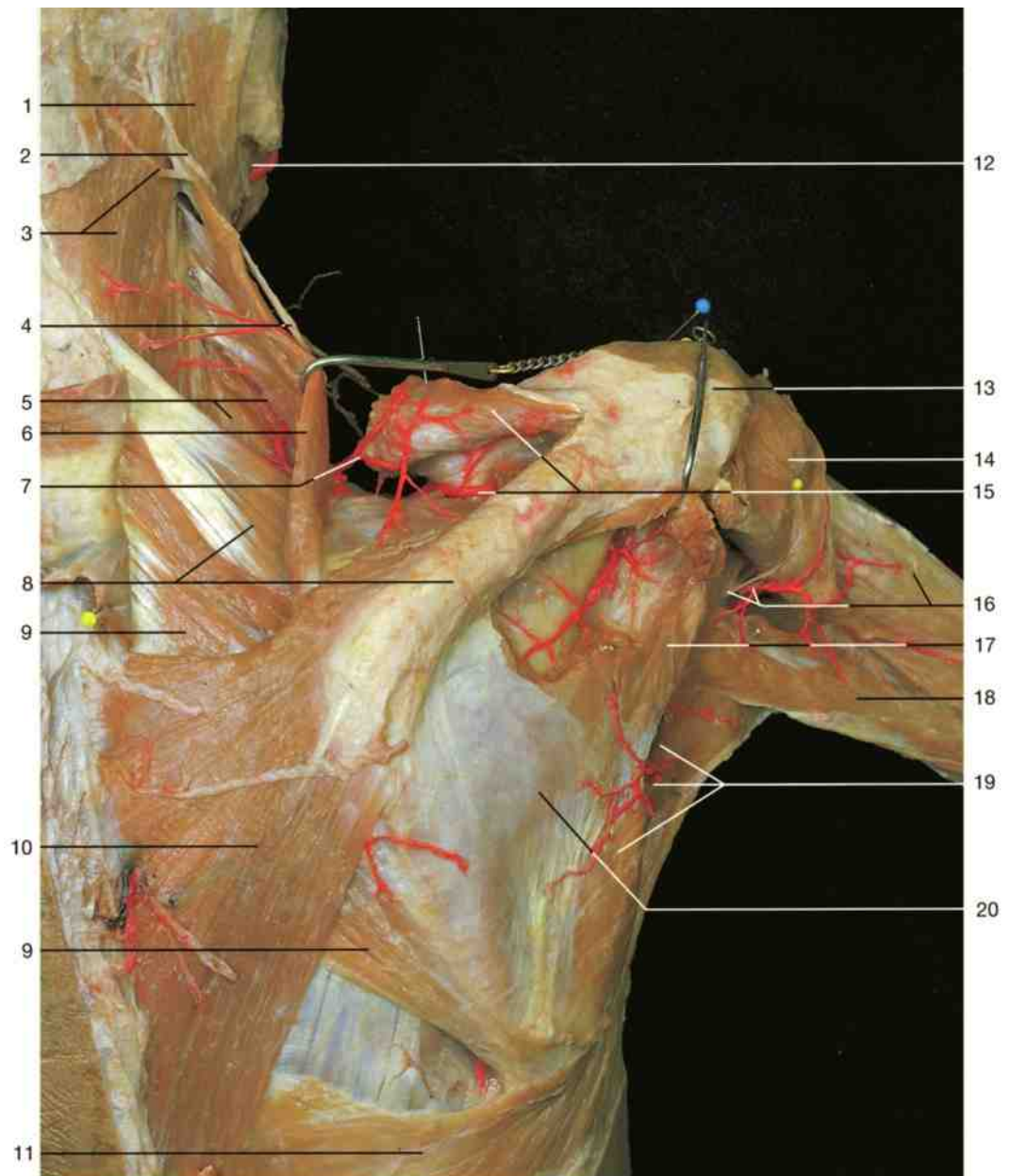


- 1 Clavicle
- 2 Deltoid muscle
- 3 Suprascapular artery
- 4 Suprascapular nerve
- 5 Superior transverse scapular ligament
- 6 Teres minor muscle
- 7 Axillary nerve and posterior circumflex humeral artery
- 8 Long head of triceps muscle
- 9 Circumflex scapular artery
- 10 Teres major muscle
- 11 Greater occipital nerve
- 12 Lesser occipital nerve
- 13 Great auricular nerve
- 14 Splenius capitis muscle
- 15 Accessory nerve (n. XI)
- 16 Third occipital nerve and levator scapulae muscle
- 17 Serratus posterior superior muscle
- 18 Spine of scapula
- 19 Descending scapular artery and dorsal scapular nerve
- 20 Rhomboid major muscle
- 21 Infraspinatus muscle and medial margin of scapula
- 22 Radial nerve and profunda brachii artery
- 23 Thoracodorsal artery
- 24 Thyrocervical trunk
- 25 Roots of brachial plexus

Posterior region of shoulder, deepest layer. Rhomboid and scapular muscles fenestrated; posterior part of deltoid muscle reflected.

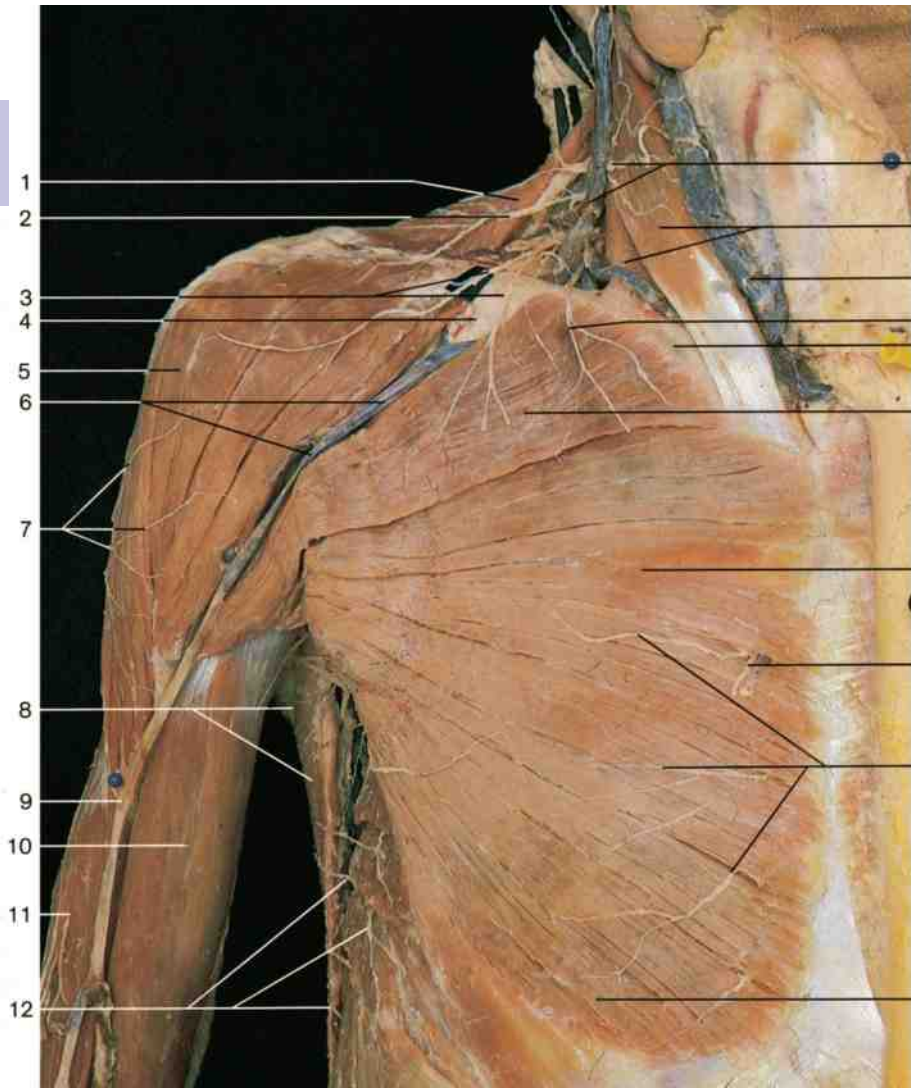


Collateral circulation of shoulder.
Anastomosis of suprascapular and circumflex scapular arteries (schematic drawing).



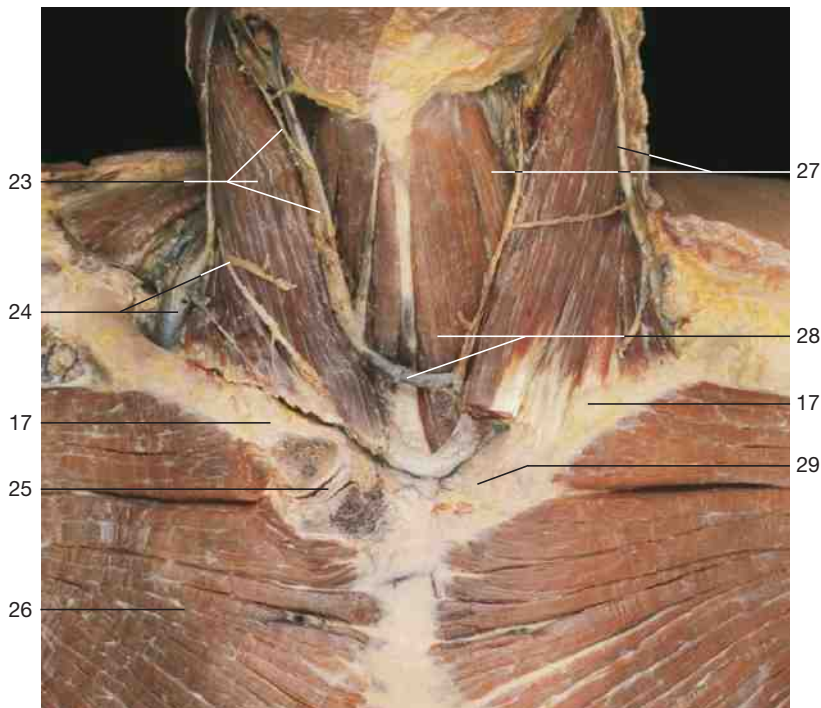
Posterior region of shoulder, deep layer. Arteries of scapular region are injected. Trapezius, deltoid, and infraspinatus muscles are partially removed or reflected.

- | | |
|---|--|
| 1 Sternocleidomastoid muscle | 10 Trapezius muscle |
| 2 Lesser occipital nerve | 11 Latissimus dorsi muscle |
| 3 Splenius capitis muscle and third occipital nerve | 12 Facial artery |
| 4 Accessory nerve (n. XI) | 13 Acromion |
| 5 Splenius cervicis muscle and transverse cervical artery (deep branch) | 14 Deltoid muscle |
| 6 Levator of scapula muscle | 15 Suprascapular artery and supraspinatus muscle (reflected) |
| 7 Transverse cervical artery (superficial branch) | 16 Axillary nerve, posterior circumflex humeral artery, and lateral head of triceps brachii muscle |
| 8 Spine of scapula and serratus posterior superior muscle | 17 Teres minor muscle |
| 9 Rhomboid major muscle | 18 Long head of triceps brachii muscle |
| | 19 Circumflex scapular artery and teres major |
| | 20 Infraspinatus muscle |

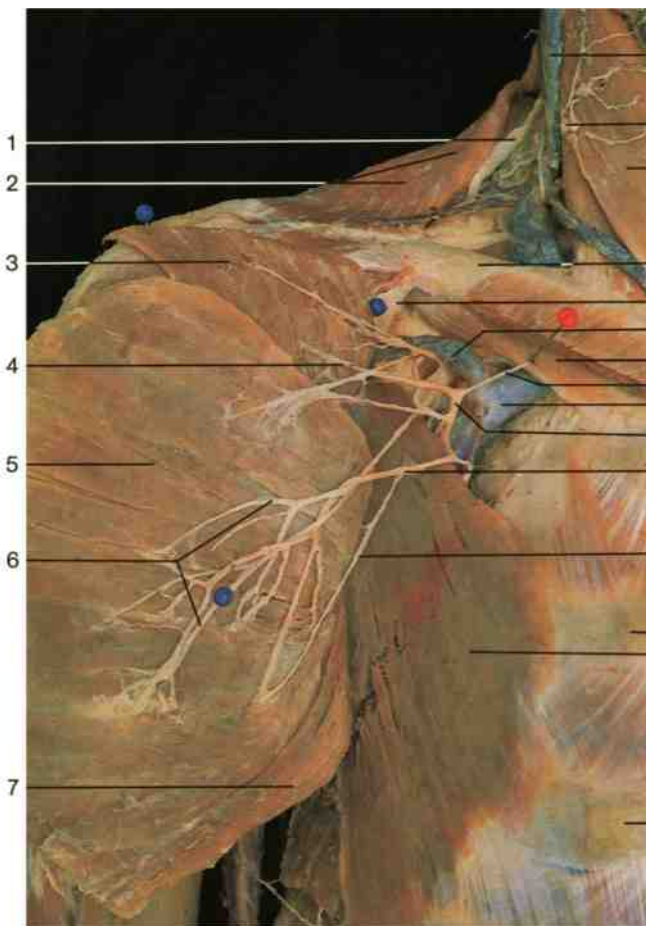


- 1 Trapezius muscle
- 2 Posterior supraclavicular nerve
- 3 Middle supraclavicular nerve
- 4 Deltopectoral triangle
- 5 Deltoid muscle
- 6 Cephalic vein within the deltopectoral groove
- 7 Upper lateral cutaneous nerve of arm (branch of axillary nerve)
- 8 Latissimus dorsi muscle
- 9 Cephalic vein
- 10 Biceps brachii muscle
- 11 Triceps brachii muscle
- 12 Lateral cutaneous branches of intercostal nerves
- 13 Transverse cervical nerve and external jugular vein
- 14 Sternocleidomastoid muscle
- 15 Anterior jugular vein
- 16 Anterior supraclavicular nerve
- 17 Clavicle
- 18 Clavicular part of pectoralis major muscle
- 19 Sternocostal part of pectoralis major muscle
- 20 Perforating branch of internal thoracic artery
- 21 Anterior cutaneous branches of intercostal nerves
- 22 Abdominal part of pectoralis major muscle
- 23 Sternocleidomastoid muscle, cervical branch of facial nerve, and anterior jugular vein
- 24 External jugular vein and transverse cervical nerve (inferior branch)
- 25 Sternoclavicular joint (opened) with articular disc
- 26 Pectoralis major muscle
- 27 Omohyoid muscle and external jugular vein
- 28 Jugular venous arch and sternohyoid muscle
- 29 Sternoclavicular joint (not opened)

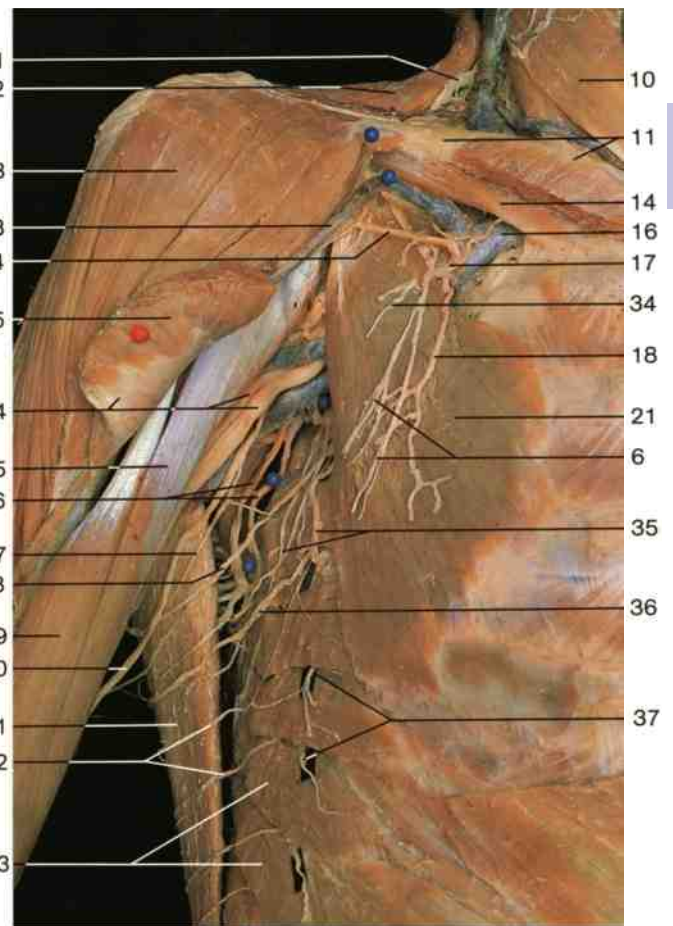
Right shoulder and thoracic wall, superficial layer (anterior aspect). Dissection of the cutaneous nerves and veins.



Thoracic wall with neck region (anterior aspect). The sternoclavicular joint is depicted. On the right side the joint has been opened by a coronal section. Note the articular disc.



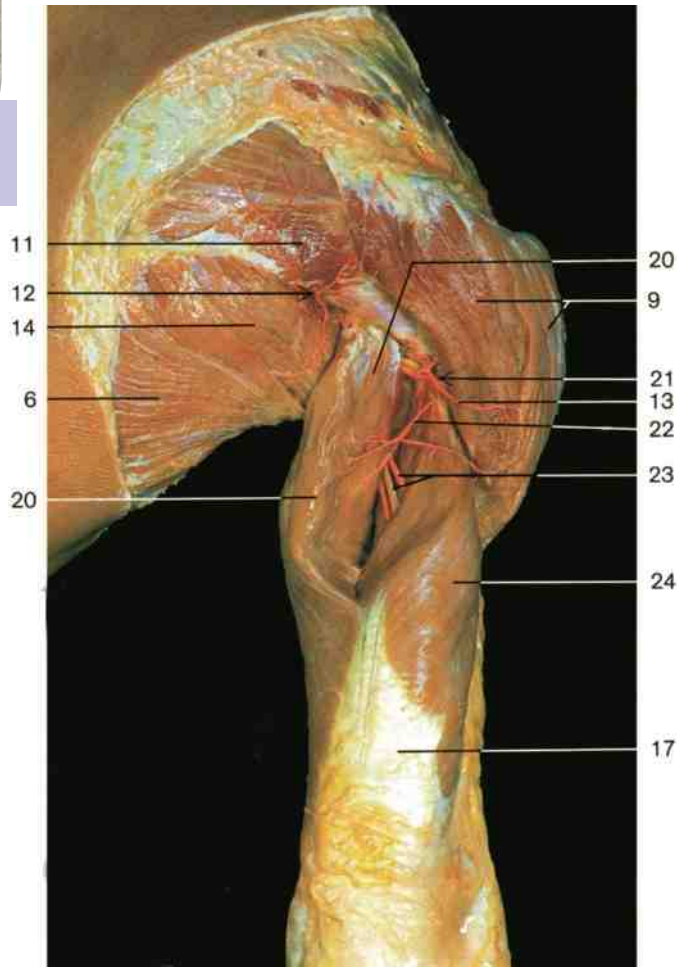
Right deltopectoral triangle, infraclavicular region (anterior aspect). The pectoralis major muscle has been cut and reflected.



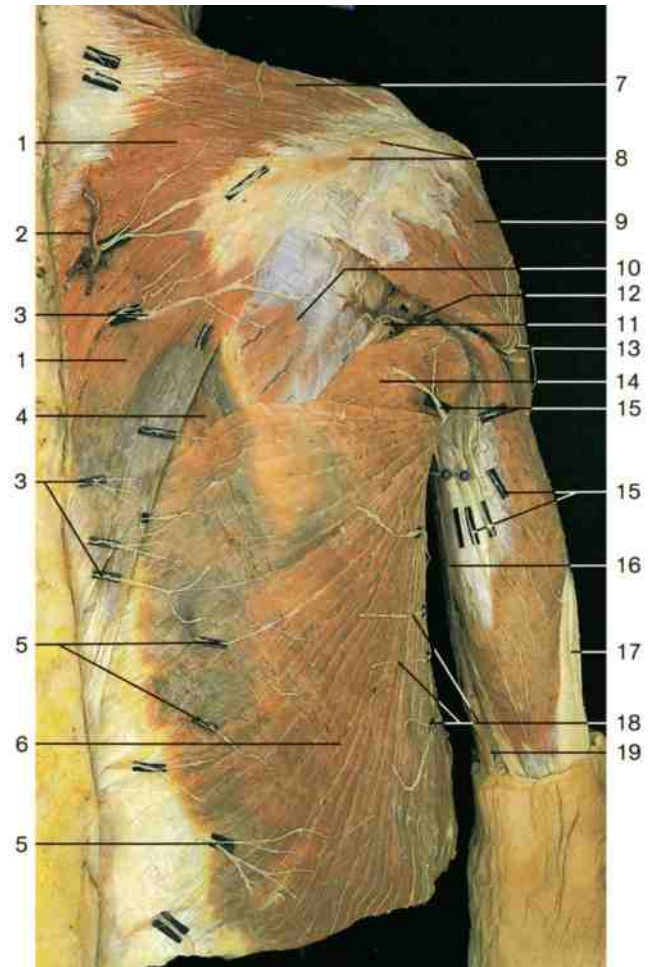
Right shoulder and thoracic wall with axillary region, deep layer (anterior aspect). The pectoralis major muscle has been cut and partly removed.

- 1 Accessory nerve
- 2 Trapezius muscle
- 3 Pectoralis major muscle (clavicular part)
- 4 Acromial branch of thoraco-acromial artery
- 5 Pectoralis major muscle
- 6 Lateral pectoral nerves
- 7 Abdominal part of pectoralis major muscle
- 8 External jugular vein
- 9 Cutaneous branches of cervical plexus
- 10 Sternocleidomastoid muscle
- 11 Clavicle
- 12 Clavipectoral fascia
- 13 Cephalic vein
- 14 Subclavius muscle
- 15 Clavicular branch of thoraco-acromial artery
- 16 Subclavian vein
- 17 Thoraco-acromial artery
- 18 Pectoral branch of thoraco-acromial artery
- 19 Medial pectoral nerve
- 20 Second rib

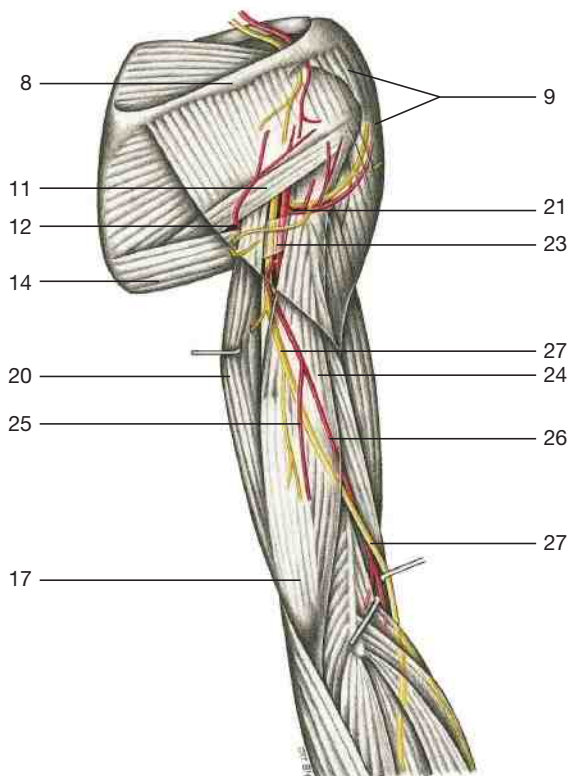
- 21 Pectoralis minor muscle
- 22 Third rib
- 23 Deltoid muscle
- 24 Pectoralis major muscle (reflected), brachial artery, and median nerve
- 25 Short head of biceps brachii muscle
- 26 Thoracodorsal artery and nerve
- 27 Medial cutaneous nerve of arm
- 28 Intercostobrachial nerve (T_2)
- 29 Long head of biceps brachii muscle
- 30 Medial cutaneous nerve of forearm
- 31 Latissimus dorsi muscle
- 32 Lateral cutaneous branches of intercostal nerves (posterior branches)
- 33 Serratus anterior muscle
- 34 Medial pectoral nerve
- 35 Long thoracic nerve and lateral thoracic artery
- 36 Intercostobrachial nerve (T_3)
- 37 Lateral cutaneous branches of intercostal nerves (anterior branches)



Shoulder and arm (dorsal aspect). Dissection of the quadrangular and triangular spaces of the axillary region.

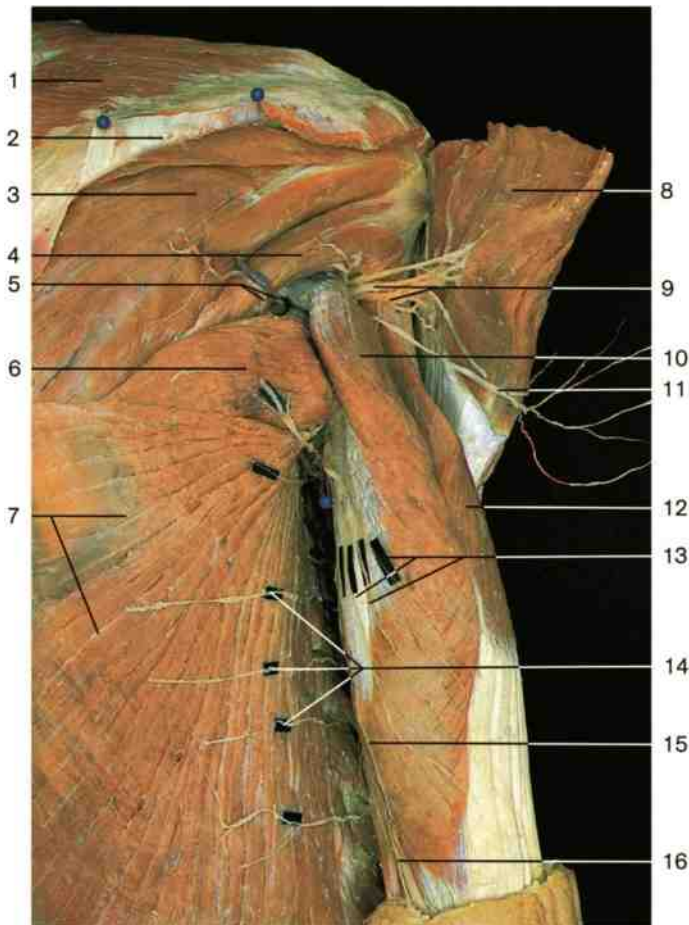


Posterior region of shoulder and arm, superficial layer. Note the segmental arrangement of the cutaneous nerves of the back.

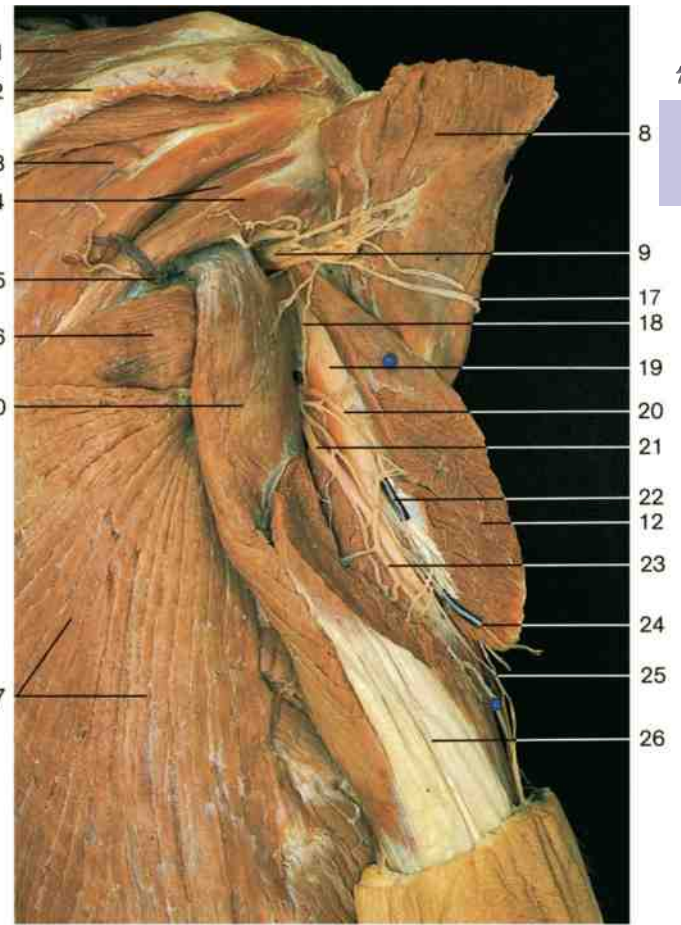


Regional anatomy of the upper limb (dorsal aspect). Localization of vessels and nerves.

- 1 Trapezius muscle
- 2 Dorsal branches of posterior intercostal artery and vein (medial cutaneous branches)
- 3 Medial branches of dorsal rami of spinal nerves
- 4 Rhomboid major muscle
- 5 Lateral branches of dorsal rami of spinal nerves
- 6 Latissimus dorsi muscle
- 7 Posterior supraclavicular nerves
- 8 Spine of scapula
- 9 Deltoid muscle
- 10 Infraspinatus muscle
- 11 Teres minor muscle
- 12 Triangular space with circumflex scapular artery and vein
- 13 Upper lateral cutaneous nerve of arm with artery
- 14 Teres major muscle
- 15 Terminal branches of intercostobrachial nerve
- 16 Medial cutaneous nerve of arm
- 17 Tendon of triceps brachii muscle
- 18 Lateral cutaneous branches of intercostal nerves
- 19 Medial cutaneous nerve of forearm
- 20 Long head of triceps brachii muscle
- 21 Quadrangular space with axillary nerve and posterior humeral circumflex artery
- 22 Anastomosis between profunda brachii artery and posterior humeral circumflex artery
- 23 Course of radial nerve and profunda brachii artery
- 24 Lateral head of triceps brachii muscle
- 25 Medial collateral artery
- 26 Radial collateral artery
- 27 Radial nerve



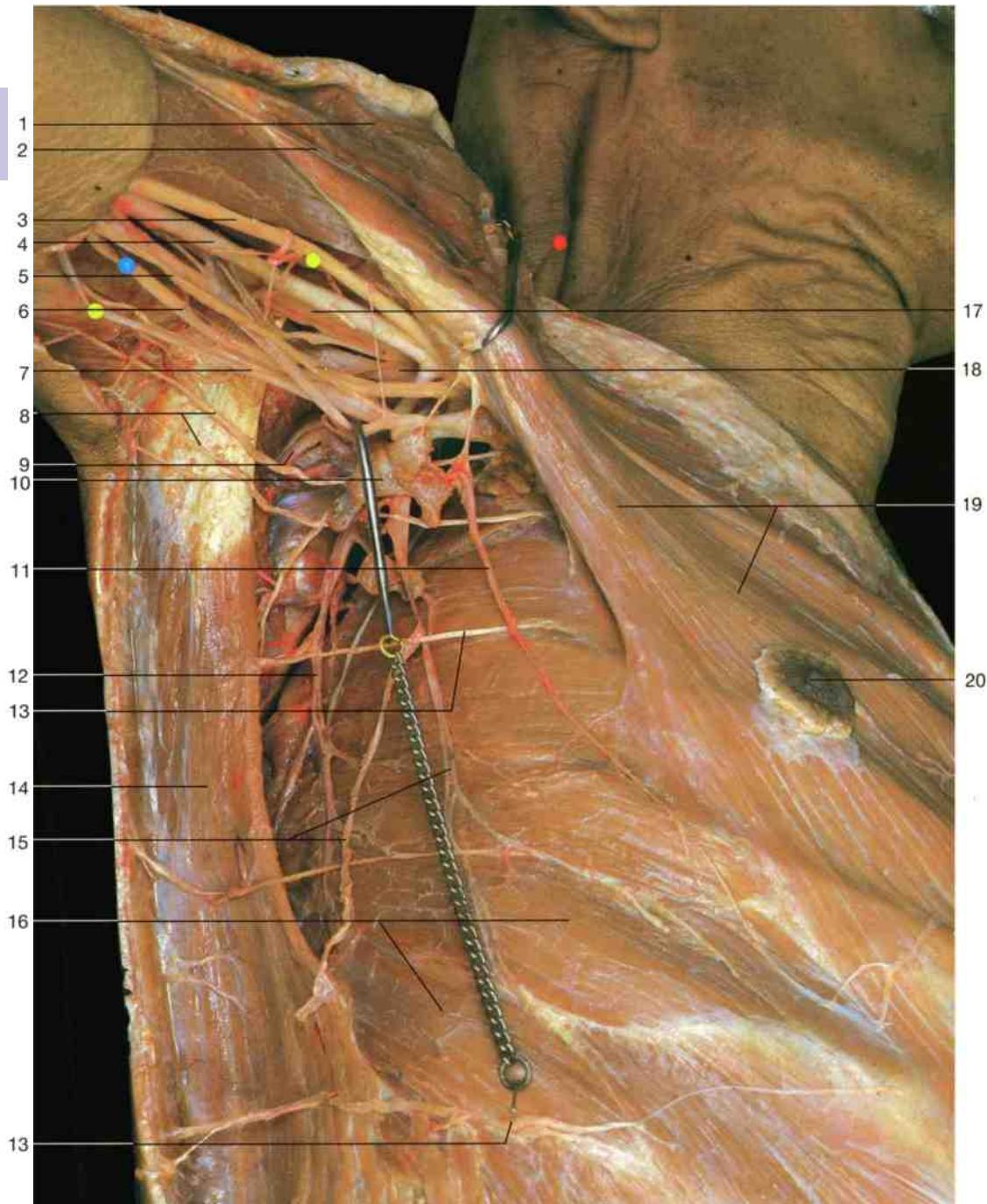
Scapular region, arm and shoulder, deep layer (dorsal aspect).
Part of deltoid muscle has been cut and reflected to display the quadrangular and triangular spaces of the axillary region.



Scapular region, arm and shoulder, deep layer (dorsal aspect).
The lateral head of the triceps brachii muscle has been cut to display the radial nerve and accompanying vessels.

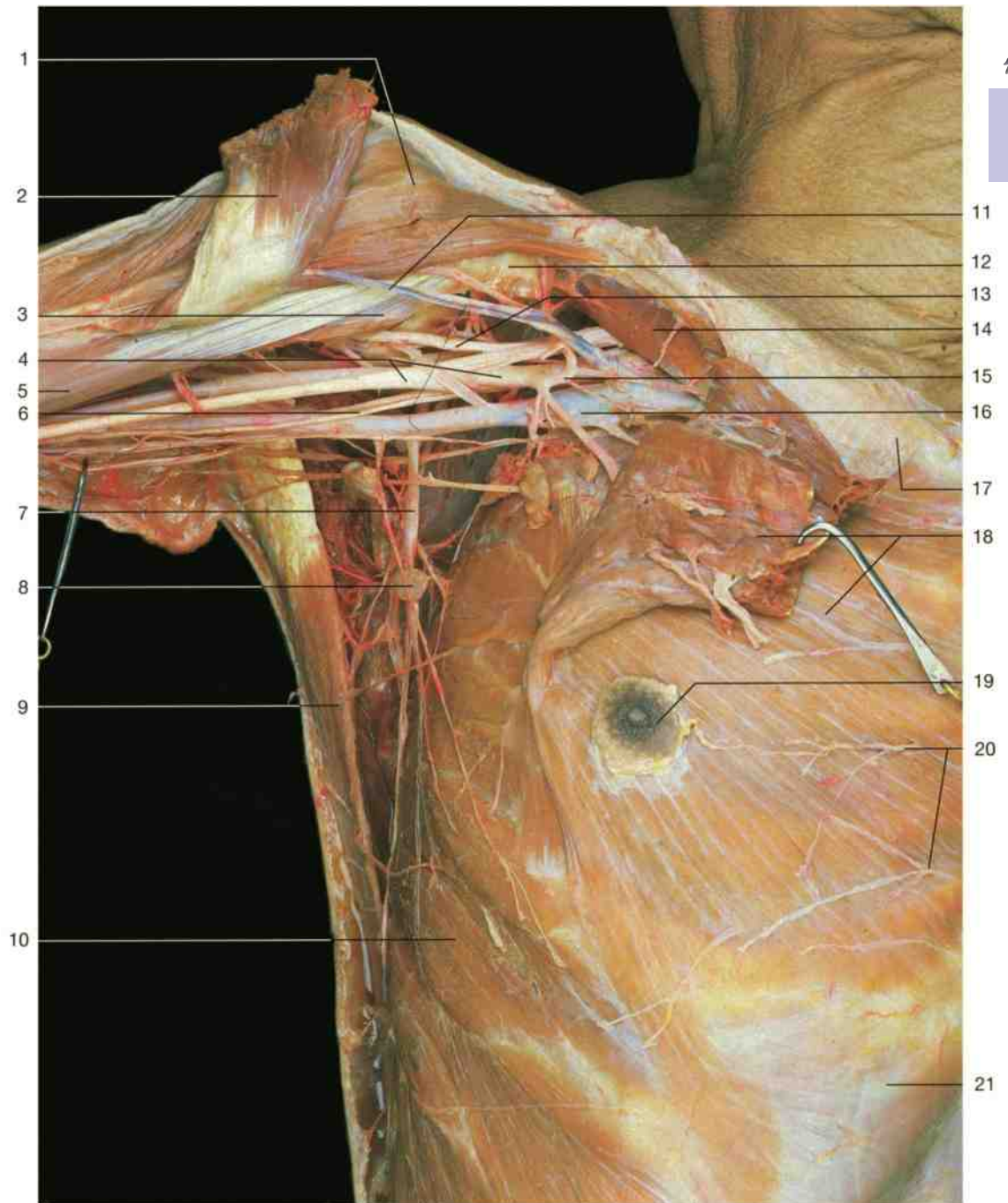
- 1 Trapezius muscle
- 2 Spine of scapula
- 3 Infraspinatus muscle
- 4 Teres minor muscle
- 5 Triangular space containing circumflex scapular artery and vein
- 6 Teres major muscle
- 7 Latissimus dorsi muscle
- 8 Deltoid muscle (cut and reflected)
- 9 Quadrangular space containing axillary nerve and posterior circumflex humeral artery and vein
- 10 Long head of triceps brachii muscle
- 11 Cutaneous branch of axillary nerve
- 12 Lateral head of triceps brachii muscle
- 13 Terminal branches of intercostobrachial nerve

- 14 Lateral cutaneous branches of intercostal nerves
- 15 Medial cutaneous nerve of arm
- 16 Medial cutaneous nerve of forearm
- 17 Upper lateral cutaneous nerve of arm
- 18 Anastomosis between profunda brachii artery and posterior humeral circumflex artery
- 19 Humerus
- 20 Profunda brachii artery
- 21 Radial nerve
- 22 Radial collateral artery
- 23 Middle collateral artery
- 24 Lower lateral cutaneous nerve of arm
- 25 Posterior cutaneous nerve of forearm
- 26 Tendon of triceps brachii muscle



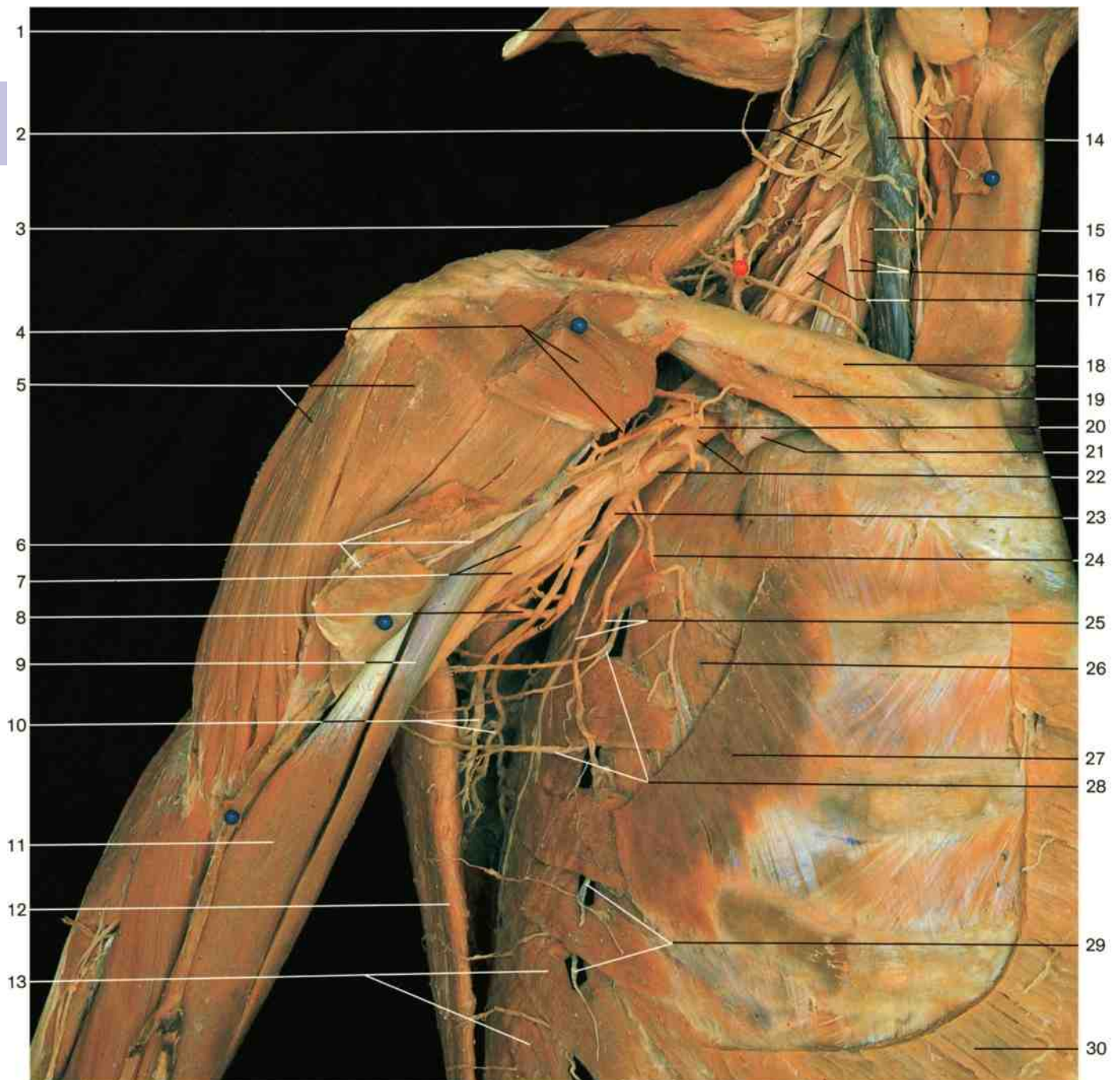
Right axillary region (inferior aspect). Dissection of superficial axillary nodes and lymphatic vessels.
The pectoralis major muscle has been slightly elevated.

- | | |
|--|--|
| 1 Deltoid muscle | 11 Lateral thoracic artery |
| 2 Cephalic vein | 12 Thoracodorsal artery |
| 3 Median nerve | 13 Lateral cutaneous branch of intercostal nerve |
| 4 Brachial artery | 14 Latissimus dorsi muscle |
| 5 Medial cutaneous nerves of arm and forearm | 15 Thoraco-epigastric vein |
| 6 Ulnar nerve | 16 Serratus anterior muscle |
| 7 Basilic vein | 17 Musculocutaneous nerve |
| 8 Intercostobrachial nerves | 18 Radial nerve |
| 9 Circumflex scapular artery | 19 Pectoralis major muscle |
| 10 Superficial axillary nodes | 20 Nipple |



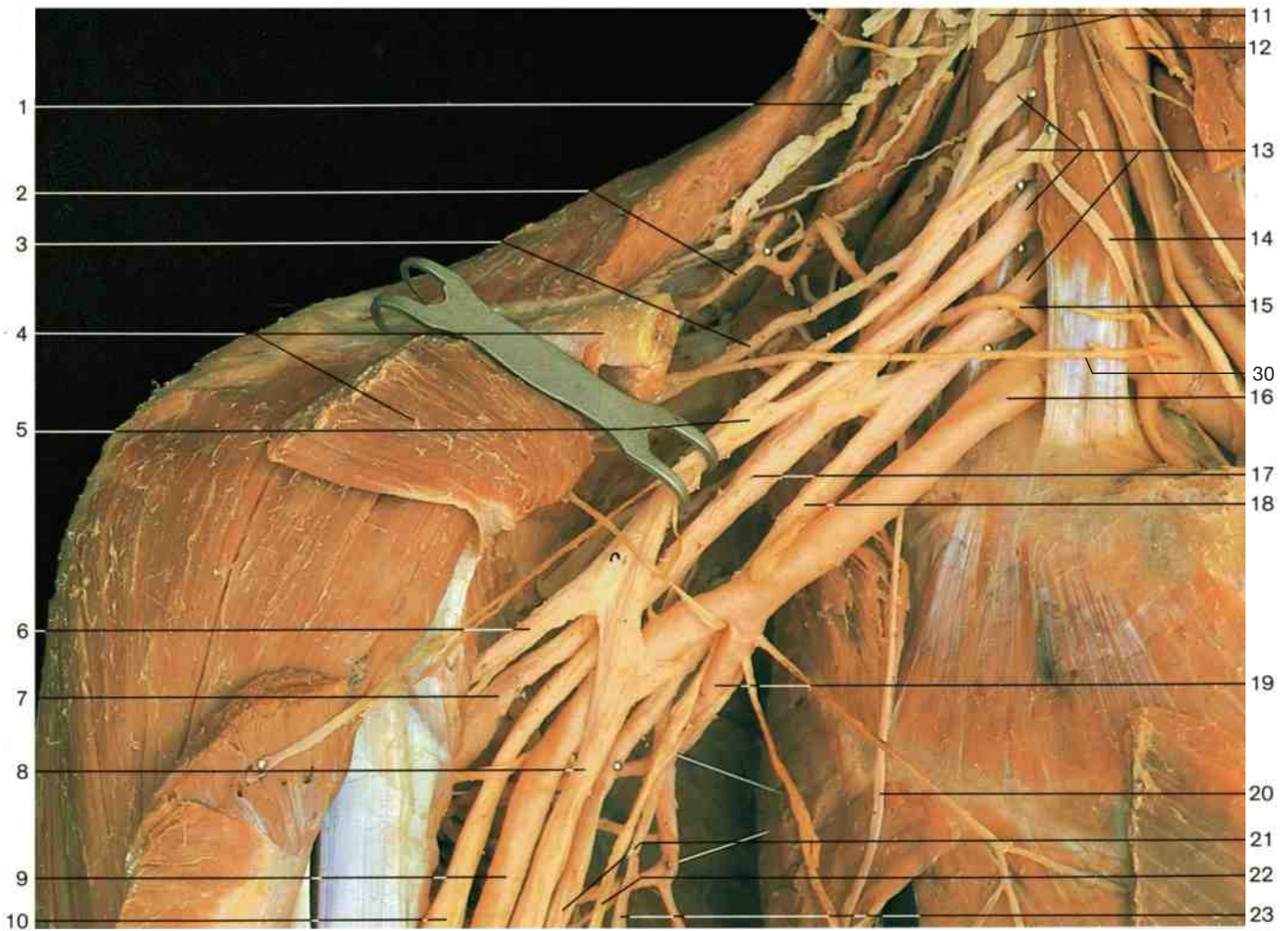
Right axillary region (anterior aspect). Dissection of deep axillary nodes. Pectoralis major and minor muscles divided and reflected. Shoulder girdle and arm elevated and reflected.

- | | | | |
|----|---|----|---|
| 1 | Deltoid muscle | 11 | Cephalic vein |
| 2 | Insertion of pectoralis major muscle | 12 | Insertion of pectoralis minor muscle (coracoid process) |
| 3 | Coracobrachialis muscle | 13 | Musculocutaneous nerve |
| 4 | Roots of median nerve, axillary artery | 14 | Subclavius muscle |
| 5 | Short head of biceps brachii muscle | 15 | Thoraco-acromial artery |
| 6 | Ulnar nerve and medial cutaneous nerve of forearm | 16 | Axillary vein |
| 7 | Thoraco-epigastric vein | 17 | Clavicle |
| 8 | Deep axillary node | 18 | Pectoralis major and minor muscles (reflected) |
| 9 | Latissimus dorsi muscle | 19 | Nipple |
| 10 | Serratus anterior muscle | 20 | Anterior cutaneous branches of intercostal nerves |
| | | 21 | Anterior layer of rectus sheath |

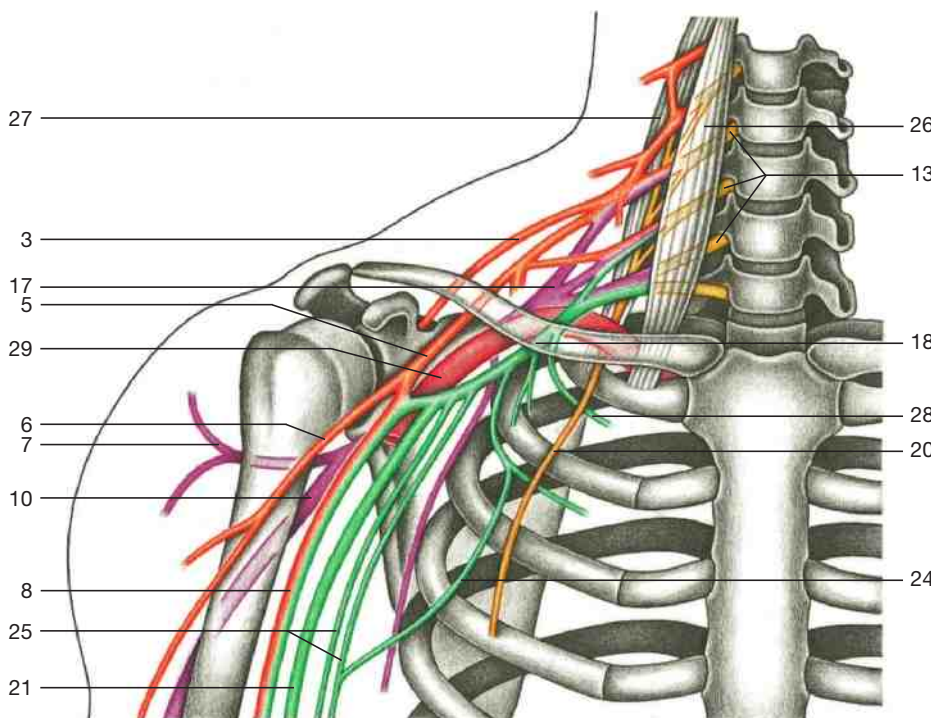


Right axillary region (anterior aspect). The pectoralis major and minor muscles have been cut and reflected to display the vessels and nerves of the axilla.

- | | | | |
|----|--|----|--|
| 1 | Sternocleidomastoid muscle (cut and reflected) | 16 | Phrenic nerve and ascending cervical artery |
| 2 | Cervical plexus | 17 | Brachial plexus (at the levels of the trunks) |
| 3 | Trapezius muscle | 18 | Clavicle |
| 4 | Pectoralis minor muscle and medial pectoral nerve | 19 | Subclavius muscle |
| 5 | Deltoid muscle | 20 | Thoraco-acromial artery |
| 6 | Pectoralis major muscle and lateral pectoral nerve | 21 | Subclavian vein (cut) |
| 7 | Median nerve and brachial artery | 22 | Axillary artery |
| 8 | Circumflex scapular artery | 23 | Subscapular artery |
| 9 | Short head of biceps brachii muscle | 24 | Superior thoracic artery |
| 10 | Thoracodorsal artery and nerve | 25 | Lateral thoracic artery and long thoracic nerve |
| 11 | Long head of biceps brachii muscle | 26 | External intercostal muscle |
| 12 | Latissimus dorsi muscle | 27 | Insertion of pectoralis minor muscle |
| 13 | Serratus anterior muscle | 28 | Intercostobrachial nerves |
| 14 | Internal jugular vein | 29 | Lateral cutaneous branches of intercostal nerves |
| 15 | Scalenus anterior muscle | 30 | Insertion of pectoralis major muscle |

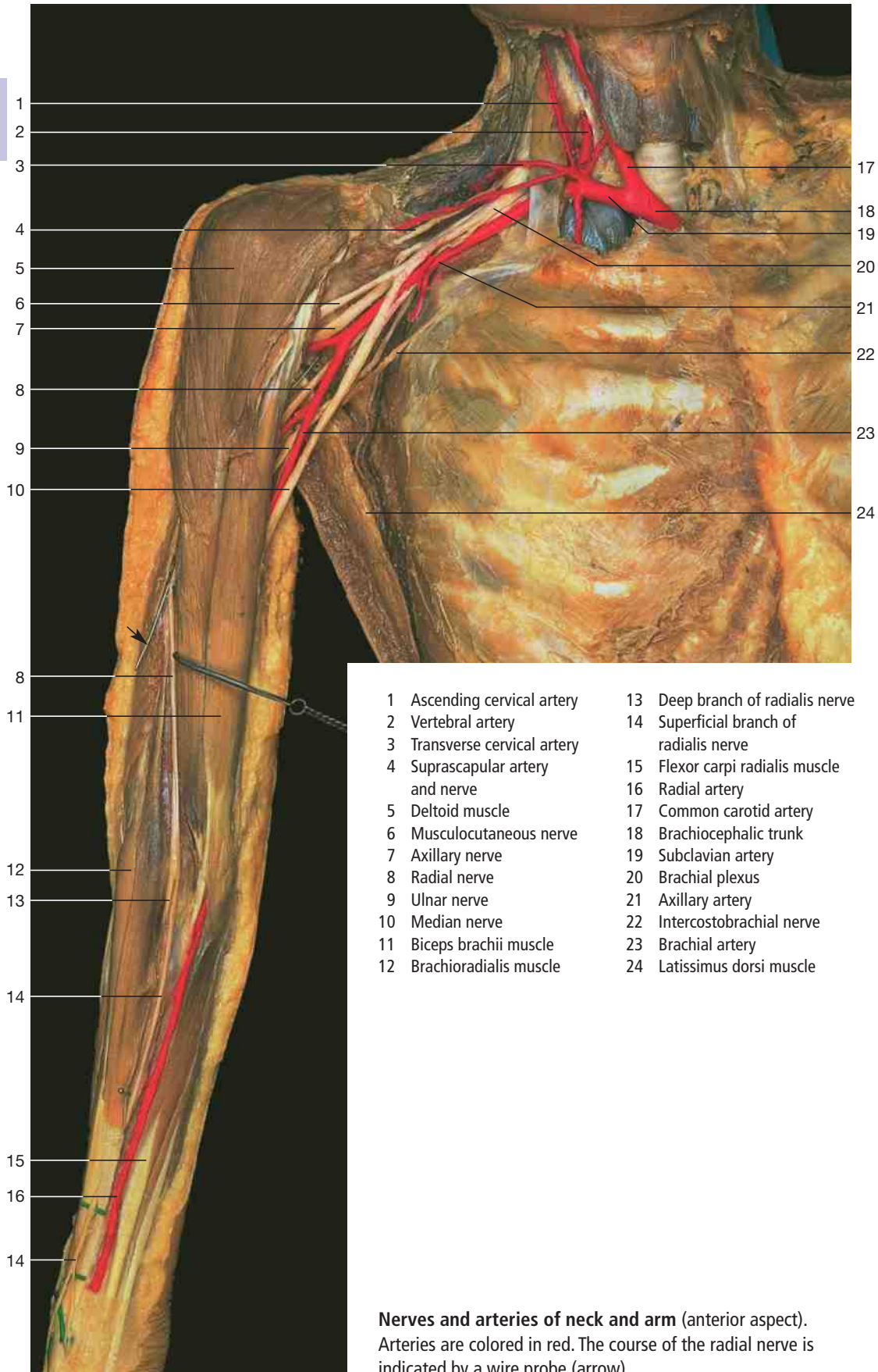


Brachial plexus (anterior aspect). Clavicle and the two pectoralis muscles have been partly removed.



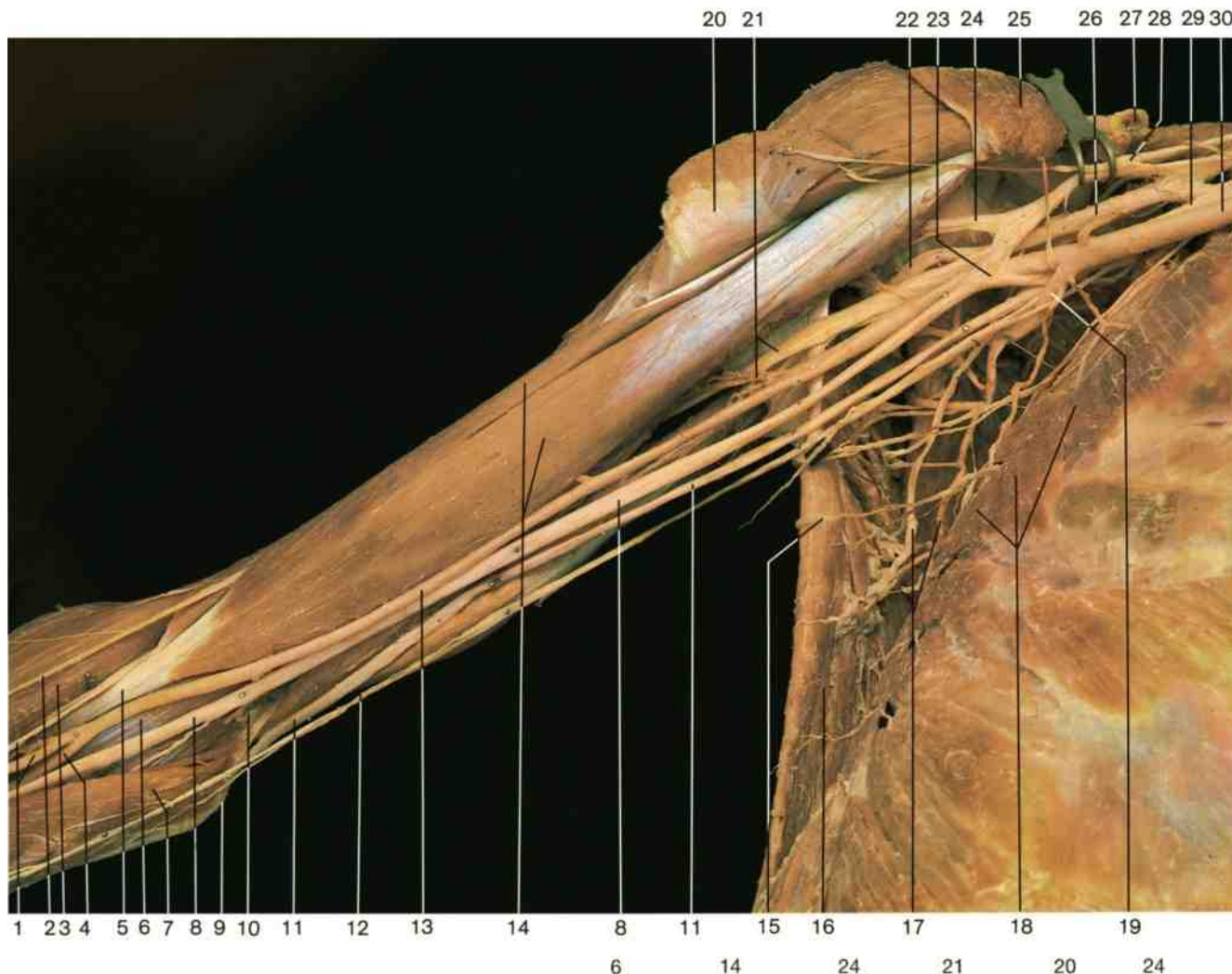
Main branches of brachial plexus. Posterior cord in purple, lateral cord in orange, and medial cord in green (schematic drawing).

- 1 Accessory nerve
- 2 Dorsal scapular artery
- 3 Suprascapular nerve
- 4 Clavicle and pectoralis minor muscle
- 5 Lateral cord of brachial plexus
- 6 Musculocutaneous nerve
- 7 Axillary nerve
- 8 Median nerve
- 9 Brachial artery
- 10 Radial nerve
- 11 Cervical plexus
- 12 Common carotid artery
- 13 Roots of brachial plexus (C₅-T₁)
- 14 Phrenic nerve
- 15 Transverse cervical artery
- 16 Subclavian artery
- 17 Posterior cord of brachial plexus
- 18 Medial cord of brachial plexus
- 19 Subscapular artery
- 20 Long thoracic nerve
- 21 Ulnar nerve
- 22 Medial cutaneous nerve of forearm
- 23 Thoracodorsal nerve
- 24 Intercostobrachial nerve
- 25 Medial cutaneous nerves of arm and forearm
- 26 Scalenus anterior muscle
- 27 Scalenus medius muscle
- 28 Intercostal nerve (T₁)
- 29 Axillary artery
- 30 Suprascapular artery




- | | |
|----------------------------------|---|
| 1 Ascending cervical artery | 13 Deep branch of radialis nerve |
| 2 Vertebral artery | 14 Superficial branch of radialis nerve |
| 3 Transverse cervical artery | 15 Flexor carpi radialis muscle |
| 4 Suprascapular artery and nerve | 16 Radial artery |
| 5 Deltoid muscle | 17 Common carotid artery |
| 6 Musculocutaneous nerve | 18 Brachiocephalic trunk |
| 7 Axillary nerve | 19 Subclavian artery |
| 8 Radial nerve | 20 Brachial plexus |
| 9 Ulnar nerve | 21 Axillary artery |
| 10 Median nerve | 22 Intercostobrachial nerve |
| 11 Biceps brachii muscle | 23 Brachial artery |
| 12 Brachioradialis muscle | 24 Latissimus dorsi muscle |

Nerves and arteries of neck and arm (anterior aspect). Arteries are colored in red. The course of the radial nerve is indicated by a wire probe (arrow).

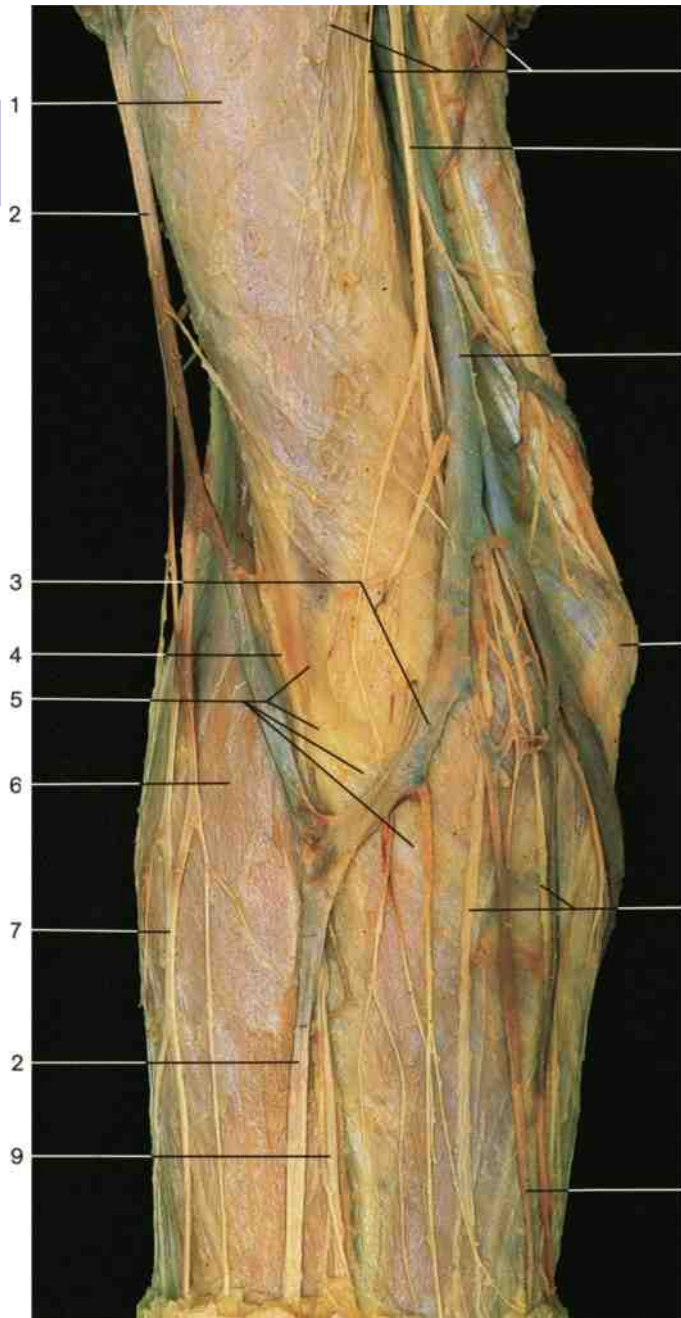


Right arm. Dissection of vessels and nerves (medial aspect).
Shoulder girdle has been reflected slightly.

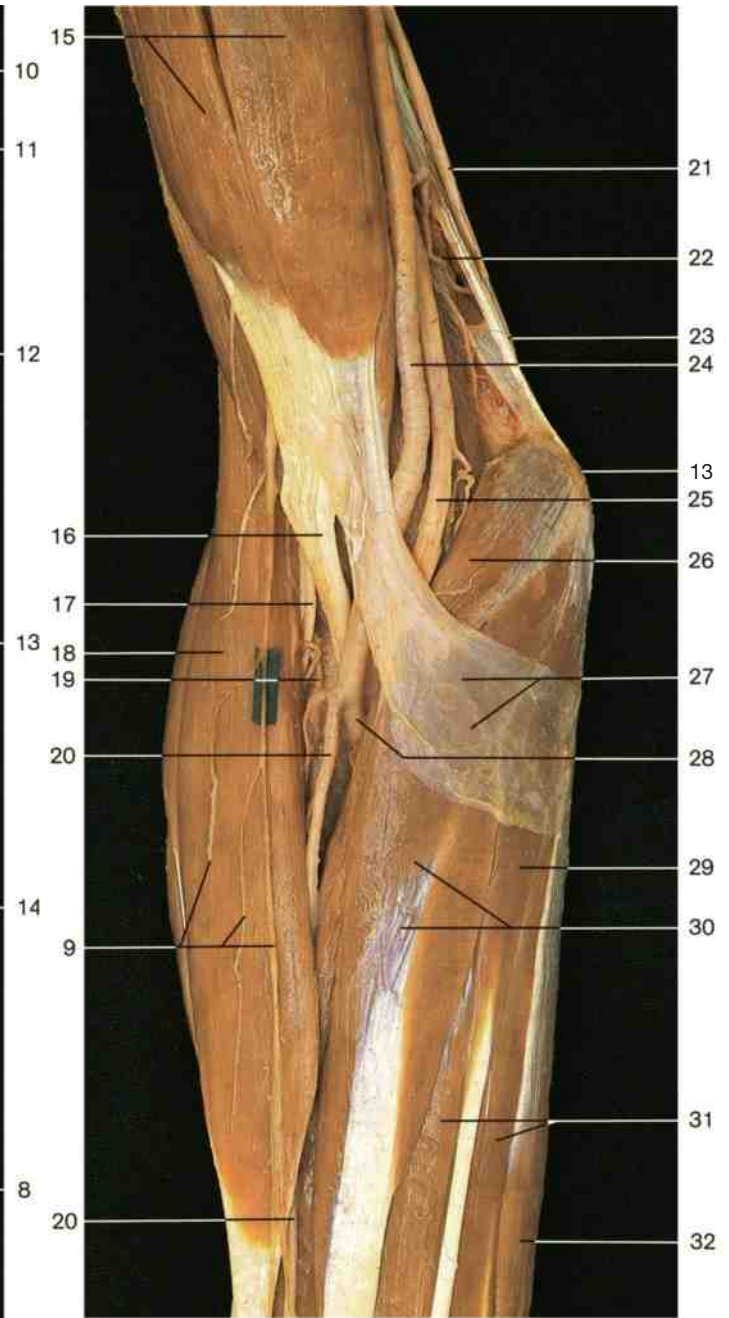


Right arm. Dissection of vessels and nerves, deeper layer.
Biceps muscle has been reflected.

- | | | | |
|--|---|---|--|
| 1 Radial artery and superficial branch of radial nerve | 8 Median nerve | 17 Thoracodorsal nerve and artery | 24 Musculocutaneous nerve |
| 2 Lateral cutaneous nerve of forearm | 9 Medial epicondyle of humerus | 18 Serratus anterior muscle | 25 Pectoralis minor muscle (reflected) and medial pectoral nerve |
| 3 Brachioradialis muscle | 10 Inferior ulnar collateral artery | 19 Subscapular artery | 26 Posterior cord of brachial plexus |
| 4 Ulnar artery | 11 Ulnar nerve | 20 Pectoralis major muscle (reflected) and lateral pectoral nerve | 27 Clavicle (cut) |
| 5 Tendon of biceps brachii muscle | 12 Medial cutaneous nerve of forearm | 21 Radial nerve and profunda brachii artery | 28 Lateral cord of brachial plexus |
| 6 Brachialis muscle | 13 Brachial artery | 22 Axillary nerve | 29 Medial cord of brachial plexus |
| 7 Pronator teres muscle | 14 Biceps brachii muscle | 23 Roots of the median nerve with axillary artery | 30 Subclavian artery |
| | 15 Intercostobrachial nerve (T ₃) | | 31 Brachial vein |
| | 16 Latissimus dorsi muscle | | |



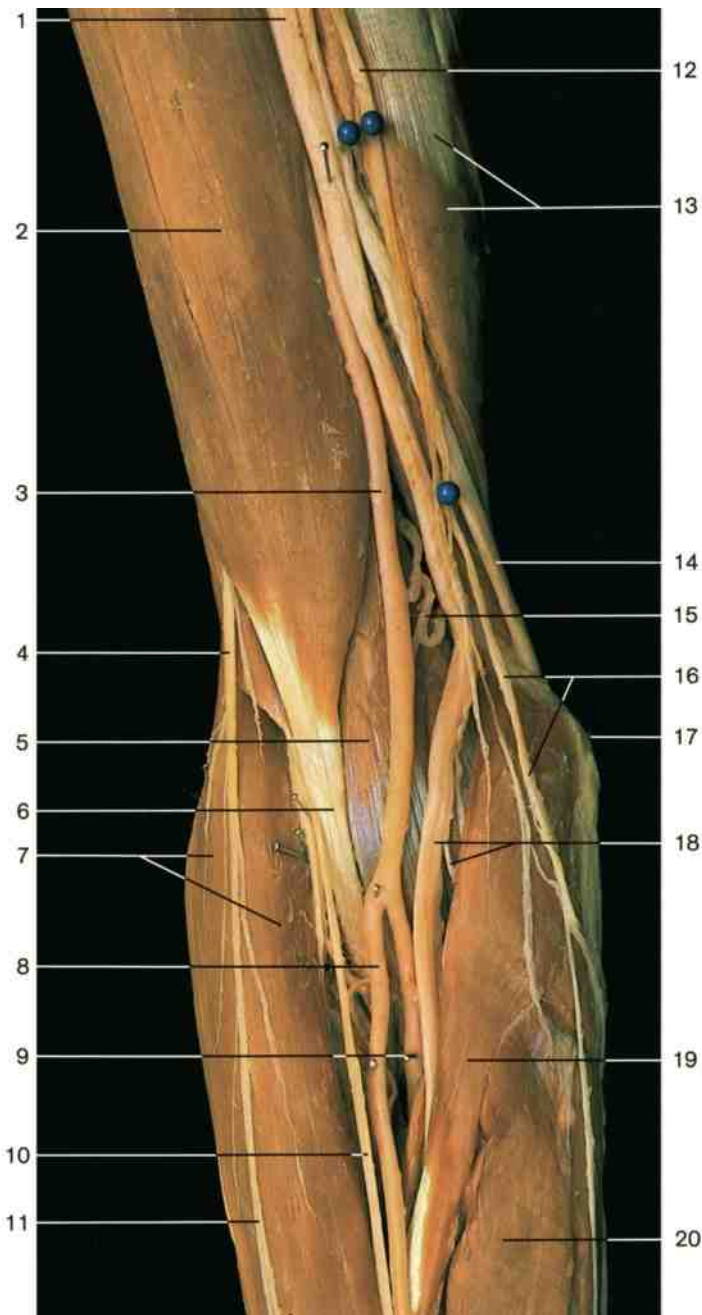
Cubital region (anterior aspect). Dissection of cutaneous nerves and veins.



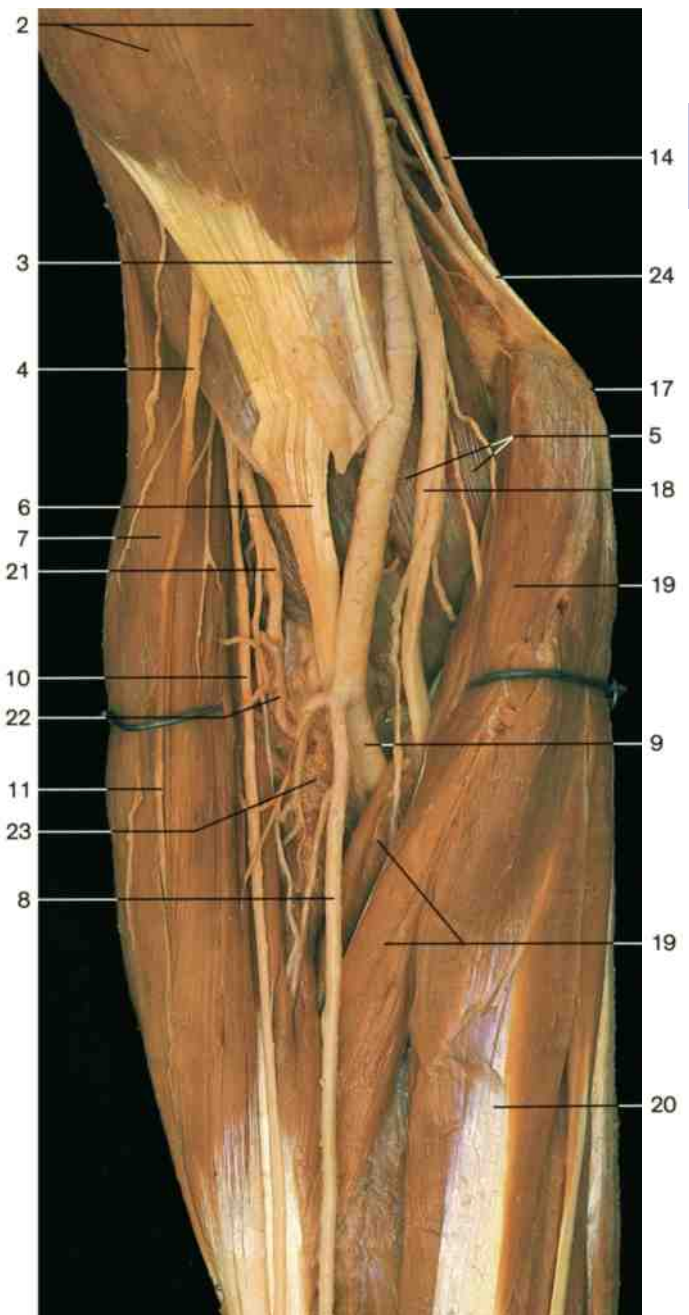
Cubital region, superficial layer (anterior aspect). The fasciae of the muscles have been removed.

- 1 Biceps brachii muscle with fascia
- 2 Cephalic vein
- 3 Median cubital vein
- 4 Lateral cutaneous nerve of forearm
- 5 Tendon and aponeurosis of biceps brachii muscle (covered by the antebrachial fascia)
- 6 Brachioradialis muscle with fascia
- 7 Accessory cephalic vein
- 8 Median vein of forearm
- 9 Branches of lateral cutaneous nerve of forearm
- 10 Terminal branches of medial cutaneous nerve of arm
- 11 Medial cutaneous nerve of forearm
- 12 Basilic vein
- 13 Medial epicondyle of humerus
- 14 Terminal branches of medial cutaneous nerve of forearm
- 15 Biceps brachii muscle

- 16 Tendon of biceps brachii muscle
- 17 Radial nerve
- 18 Brachioradialis muscle
- 19 Radial recurrent artery
- 20 Radial artery
- 21 Ulnar nerve
- 22 Superior ulnar collateral artery
- 23 Medial intermuscular septum
- 24 Brachial artery
- 25 Median nerve
- 26 Pronator teres muscle
- 27 Bicipital aponeurosis
- 28 Ulnar artery
- 29 Palmaris longus muscle
- 30 Flexor carpi radialis muscle
- 31 Flexor digitorum superficialis muscle
- 32 Flexor carpi ulnaris muscle



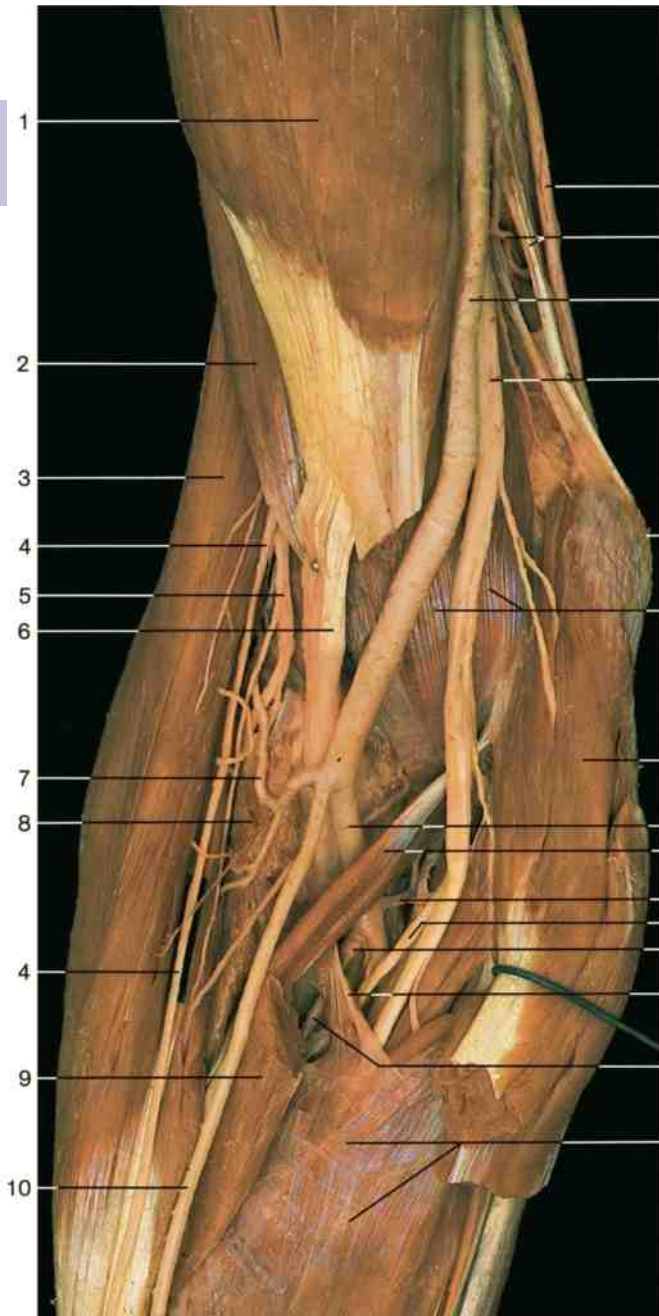
Cubital region, middle layer (anterior aspect). The bicipital aponeurosis has been removed.



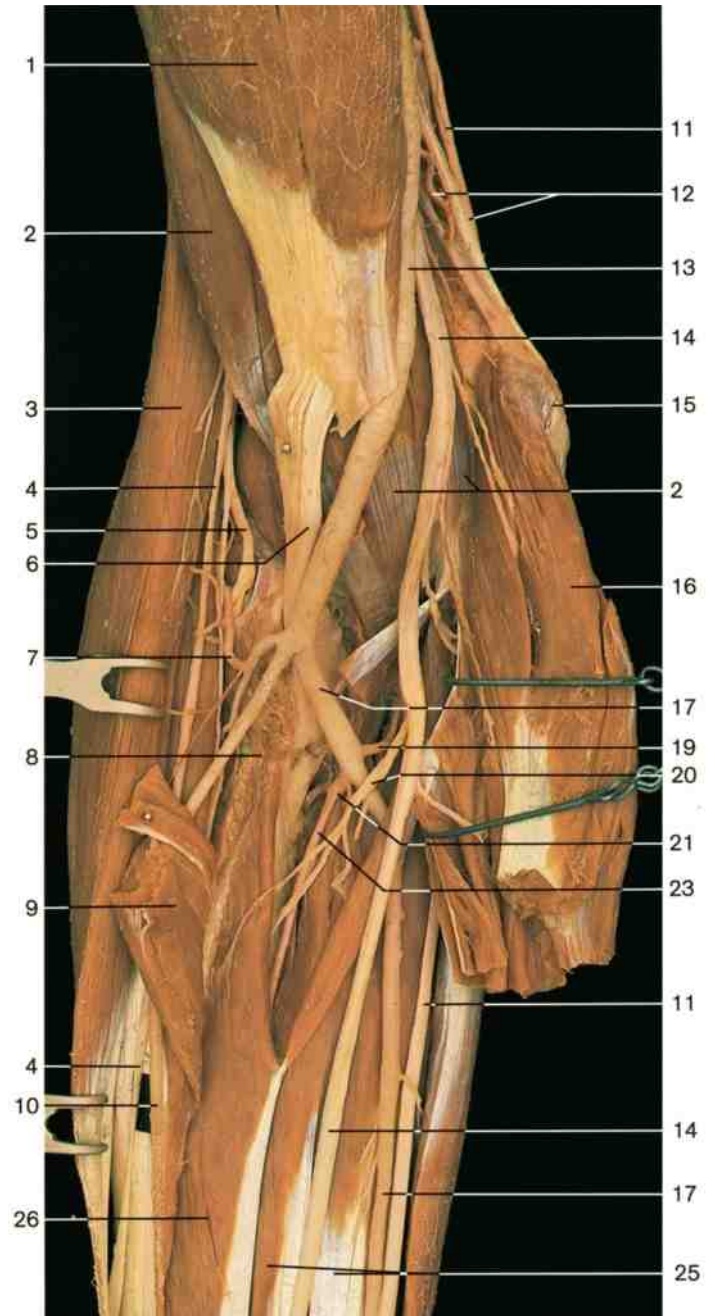
Cubital region, middle layer (anterior aspect). The pronator teres and brachioradialis muscles have been slightly reflected.

- 1 Median nerve
- 2 Biceps brachii muscle
- 3 Brachial artery
- 4 Lateral cutaneous nerve of forearm (terminal branch of musculocutaneous nerve)
- 5 Brachialis muscle
- 6 Tendon of biceps brachii muscle
- 7 Brachioradialis muscle
- 8 Radial artery
- 9 Ulnar artery
- 10 Superficial branch of radial nerve
- 11 Lateral cutaneous nerve of forearm
- 12 Medial cutaneous nerve of forearm

- 13 Triceps brachii muscle
- 14 Ulnar nerve
- 15 Inferior ulnar collateral artery
- 16 Anterior branch of medial cutaneous nerve of forearm
- 17 Medial epicondyle of humerus
- 18 Median nerve with branches to pronator teres muscle
- 19 Pronator teres muscle
- 20 Flexor carpi radialis muscle
- 21 Deep branch of radial nerve
- 22 Radial recurrent artery
- 23 Supinator muscle
- 24 Medial intermuscular septum of arm



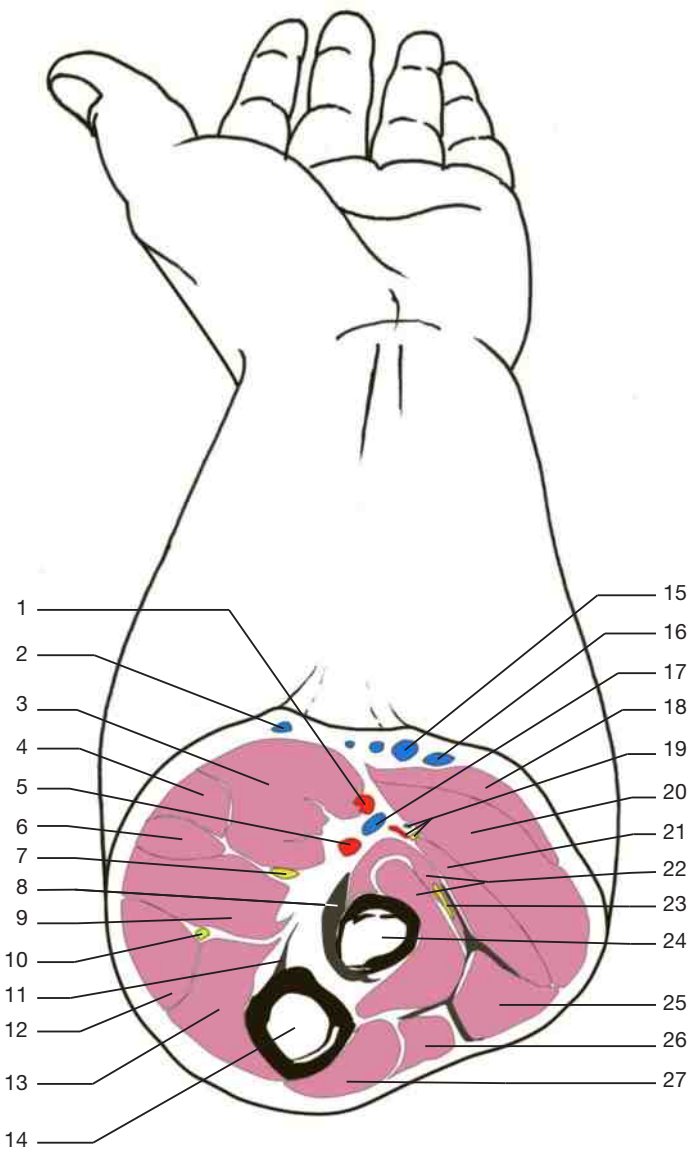
Cubital region, deep layer (anterior aspect). The pronator teres and flexor carpi ulnaris muscles have been cut and reflected.



Cubital region, deepest layer (anterior aspect). The flexor digitorum superficialis muscle and the ulnar head of the pronator teres muscle have been cut and reflected.

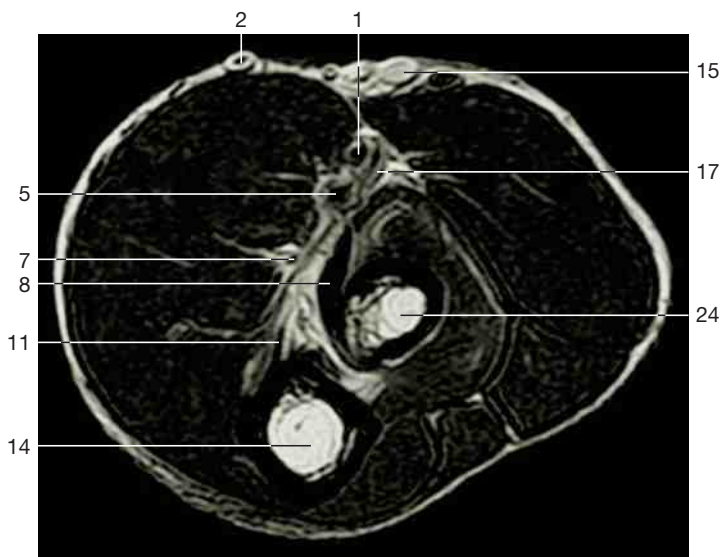
- 1 Biceps brachii muscle
- 2 Brachialis muscle
- 3 Brachioradialis muscle
- 4 Superficial branch of radial nerve
- 5 Deep branch of radial nerve
- 6 Tendon of biceps brachii muscle
- 7 Radial recurrent artery
- 8 Supinator muscle
- 9 Insertion of pronator teres muscle
- 10 Radial artery
- 11 Ulnar nerve
- 12 Medial intermuscular septum of arm and superior ulnar collateral artery
- 13 Brachial artery

- 14 Median nerve
- 15 Medial epicondyle of humerus
- 16 Humeral head of pronator teres muscle
- 17 Ulnar artery
- 18 Ulnar head of pronator teres muscle
- 19 Ulnar recurrent artery
- 20 Anterior interosseous nerve
- 21 Common interosseous artery
- 22 Tendinous arch of flexor digitorum superficialis muscle
- 23 Anterior interosseous artery
- 24 Flexor digitorum superficialis muscle
- 25 Flexor digitorum profundus muscle
- 26 Flexor pollicis longus muscle

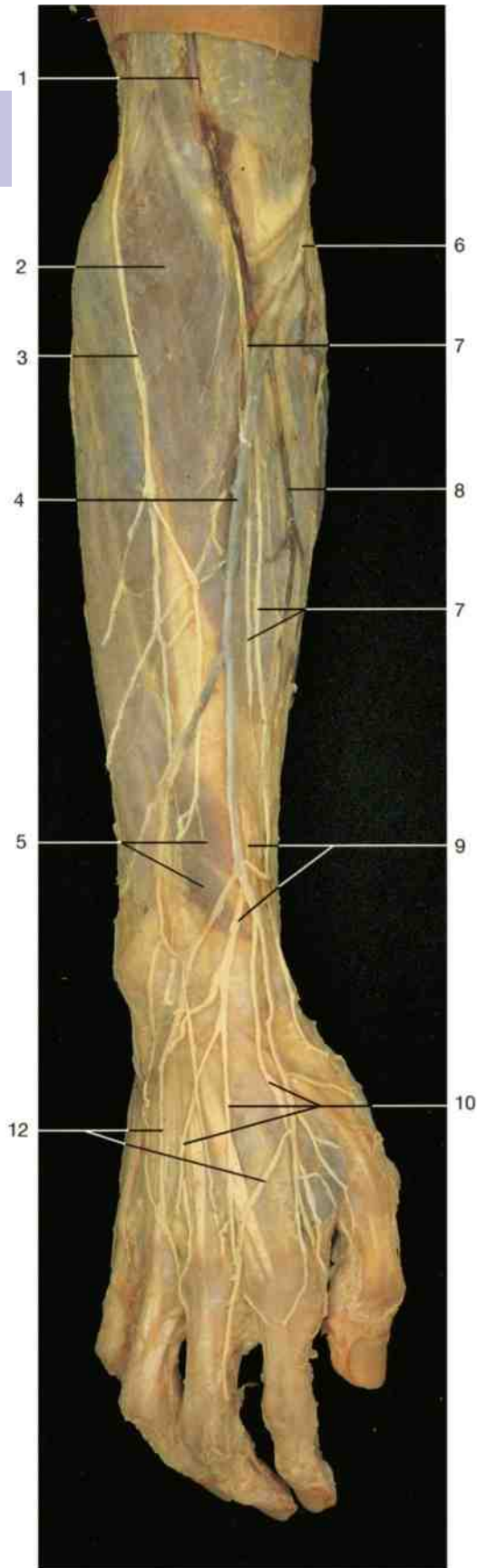


- 1 Radial artery
- 2 Basilic vein
- 3 Pronator teres muscle
- 4 Flexor carpi radialis muscle
- 5 Ulnar artery
- 6 Palmaris longus muscle
- 7 Median nerve
- 8 Tendon of biceps brachii muscle
- 9 Flexor digitorum superficialis muscle
- 10 Ulnar nerve
- 11 Tendon of brachialis muscle
- 12 Flexor carpi ulnaris muscle
- 13 Flexor digitorum profundus muscle
- 14 Ulna
- 15 Median cubital vein
- 16 Cephalic antebrachii vein
- 17 Radial vein
- 18 Brachioradialis muscle
- 19 Superficial branch of radial nerve, radial artery and vein
- 20 Extensor carpi radialis longus muscle
- 21 Extensor carpi radialis brevis muscle
- 22 Supinator muscle
- 23 Deep branch of radial nerve
- 24 Radius
- 25 Extensor digitorum muscle
- 26 Extensor carpi ulnaris muscle
- 27 Anconeus muscle

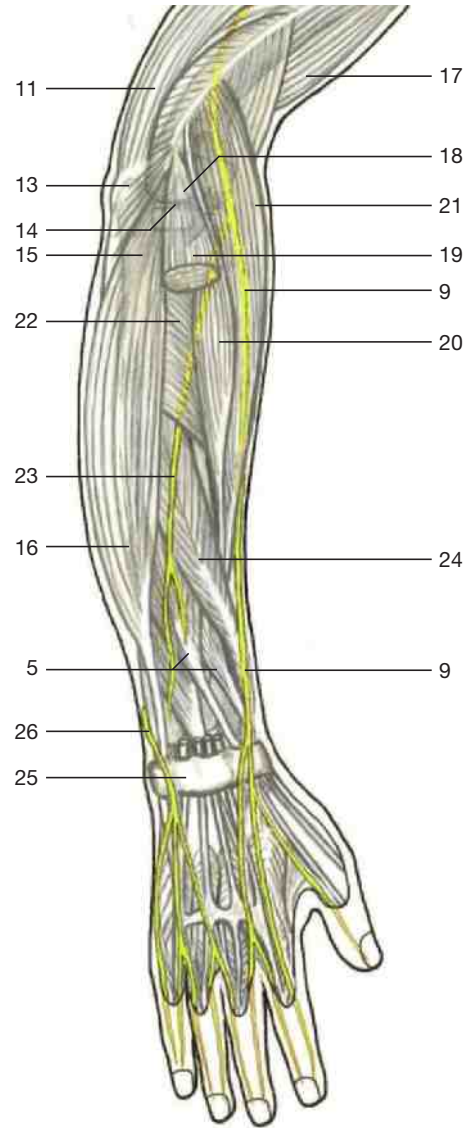
Muscles, nerves, and blood vessels of the forearm (axial section distally of the elbow joint, cf. MRI scan).



Axial section of the forearm (distally of the elbow joint, MRI scan; from Heuck et al., MRT-Atlas, 2009). For details see schematic drawing above.

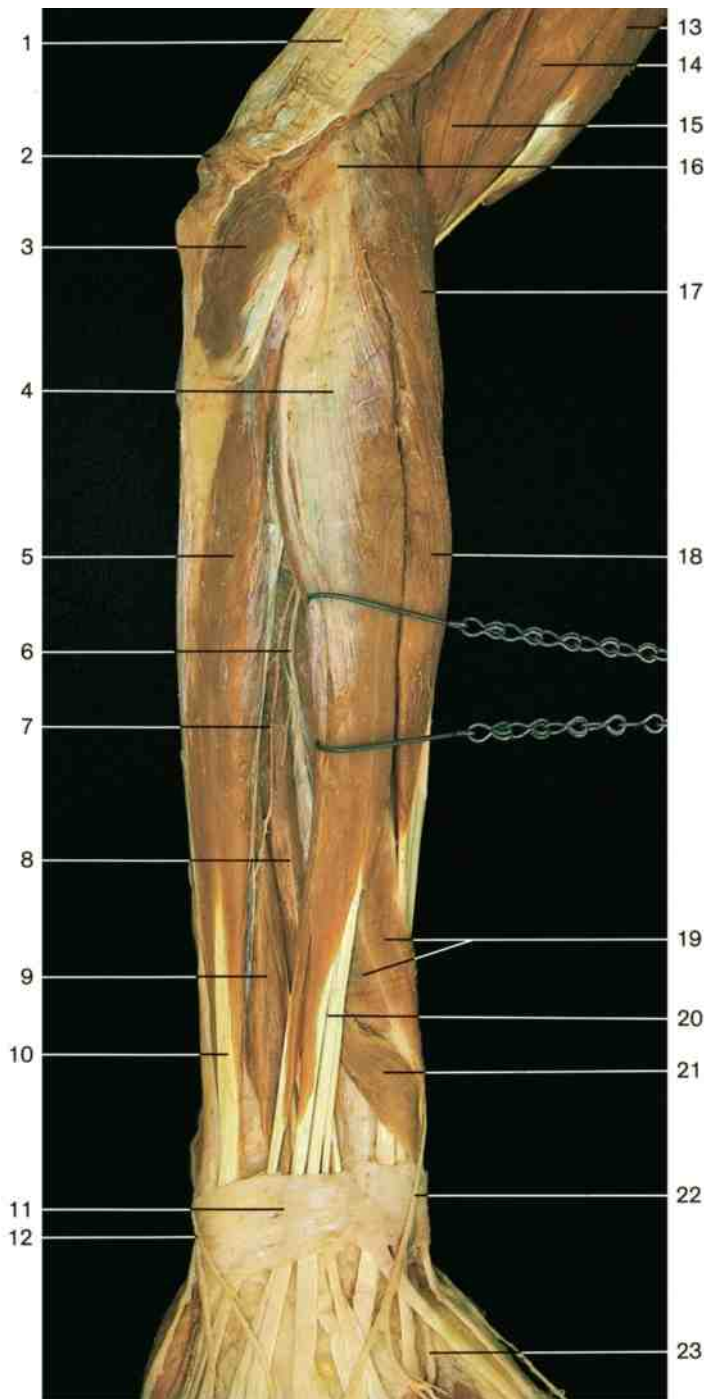


Superficial veins and cutaneous nerves of forearm and hand (posterior aspect).

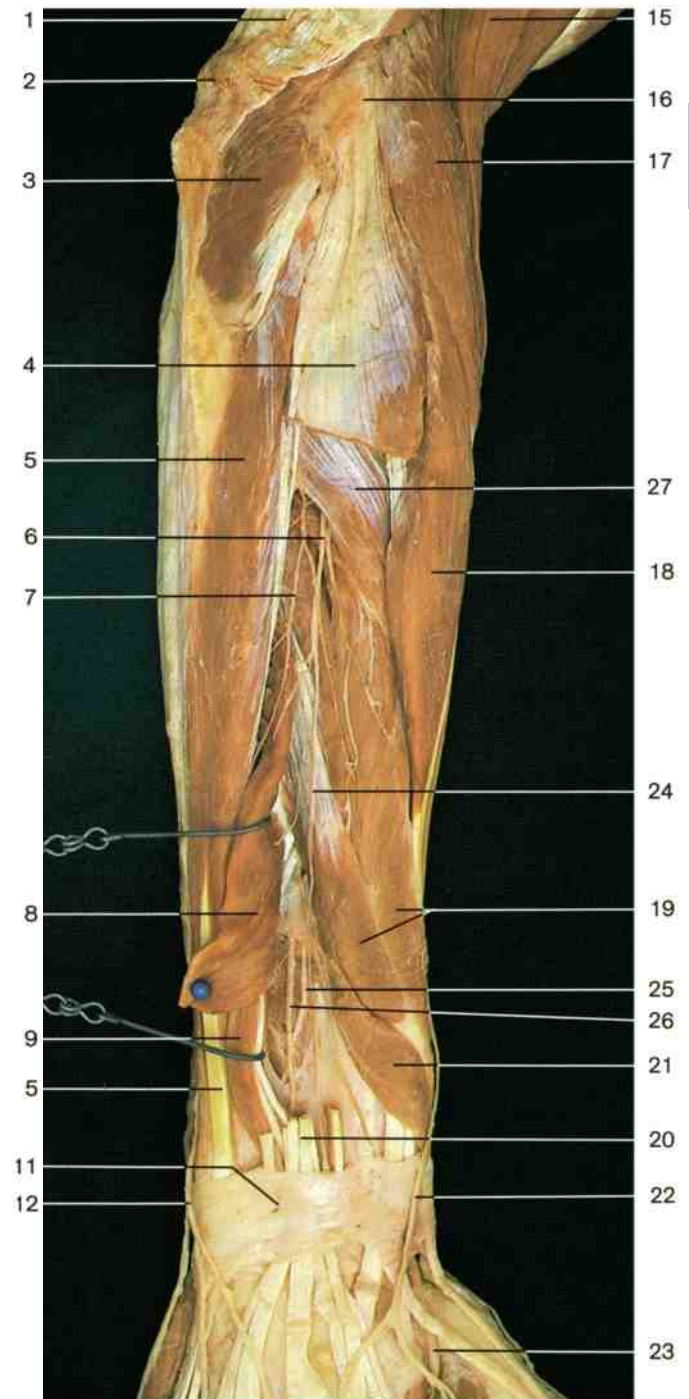


Course of the nerves to forearm and hand (posterior aspect).
Yellow = radial and ulnar nerves.

- | | |
|--|------------------------------------|
| 1 Cephalic vein | 11 Triceps brachii muscle |
| 2 Brachioradialis muscle covered by its fascia | 12 Dorsal venous network of hand |
| 3 Posterior cutaneous nerve of forearm (branch of radial nerve) | 13 Olecranon |
| 4 Cephalic vein of forearm | 14 Humeroradial joint |
| 5 Extensor pollicis longus and brevis muscles covered by their fascia | 15 Ulna |
| 6 Median cubital vein | 16 Extensor carpi ulnaris muscle |
| 7 Lateral cutaneous nerves of forearm (branch of musculocutaneous nerve) | 17 Biceps brachii muscle |
| 8 Intermedian vein of forearm | 18 Trochlea of humerus |
| 9 Superficial branch of radial nerve | 19 Extensor digitorum muscle |
| 10 Dorsal digital branches of radial nerve | 20 Extensor carpi radialis muscle |
| | 21 Brachioradialis muscle |
| | 22 Supinator muscle |
| | 23 Deep branch of radial nerve |
| | 24 Abductor pollicis longus muscle |
| | 25 Extensor retinaculum |
| | 26 Ulnar nerve |



Vessels and nerves of right forearm, superficial layer (posterior aspect).

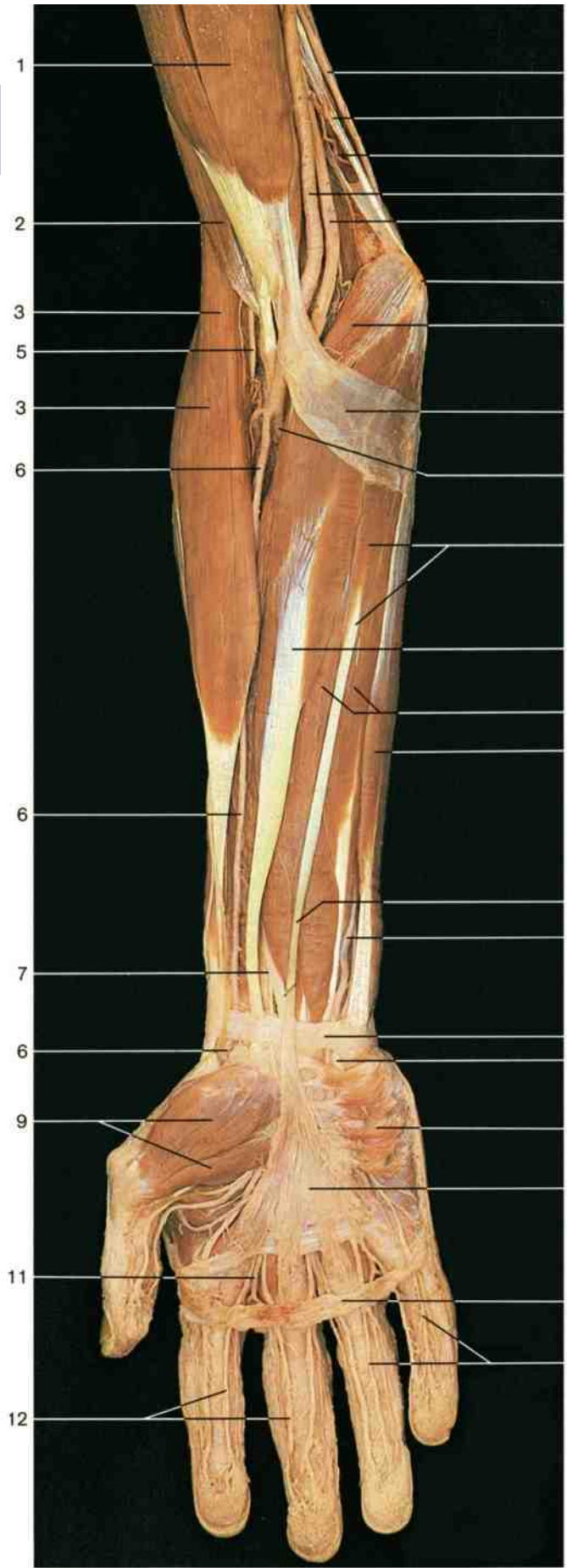


Vessels and nerves of right forearm, deep layer (posterior aspect).

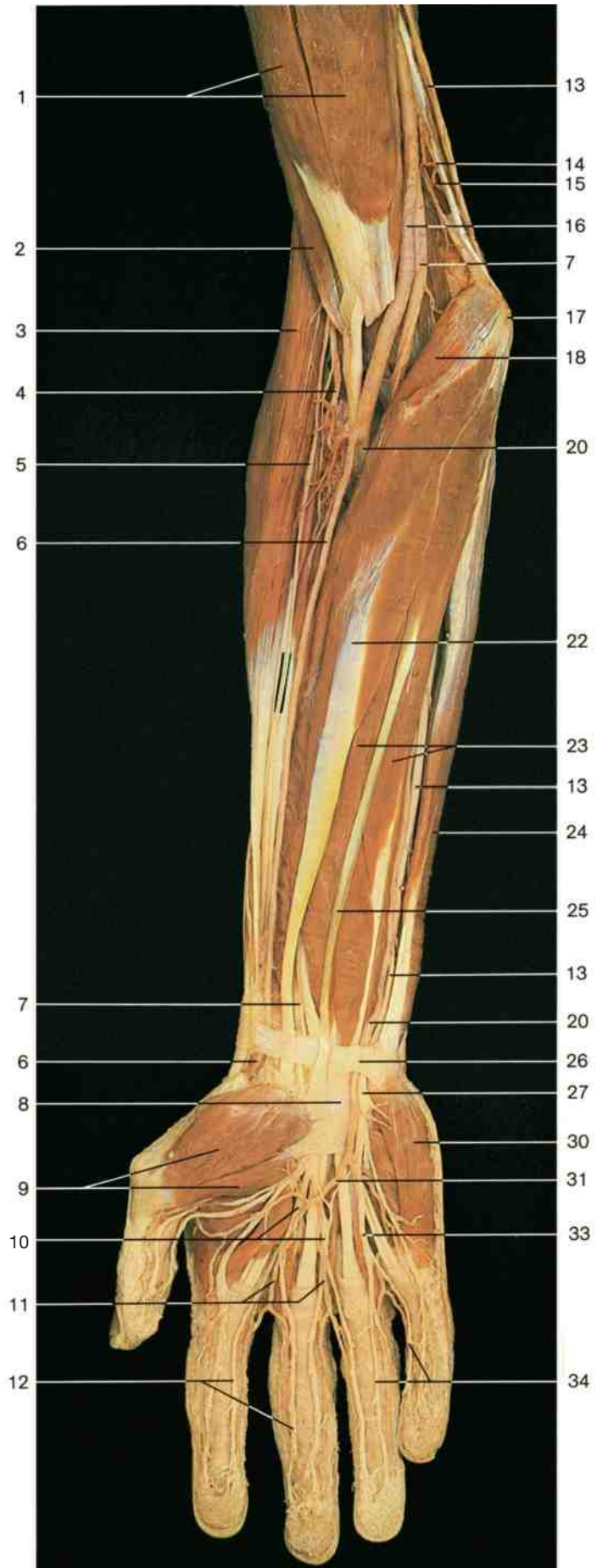
- 1 Tendon of triceps brachii muscle
- 2 Olecranon
- 3 Anconeus muscle
- 4 Extensor digitorum muscle
- 5 Extensor carpi ulnaris muscle
- 6 Deep branch of radial nerve
- 7 Posterior interosseous artery
- 8 Extensor pollicis longus muscle
- 9 Extensor indicis muscle
- 10 Tendon of extensor carpi ulnaris muscle

- 11 Extensor retinaculum
- 12 Dorsal branch of ulnar nerve
- 13 Biceps brachii muscle
- 14 Brachialis muscle
- 15 Brachioradialis muscle
- 16 Lateral epicondyle of humerus
- 17 Extensor carpi radialis longus muscle
- 18 Extensor carpi radialis brevis muscle
- 19 Abductor pollicis longus muscle
- 20 Tendons of extensor digitorum muscle

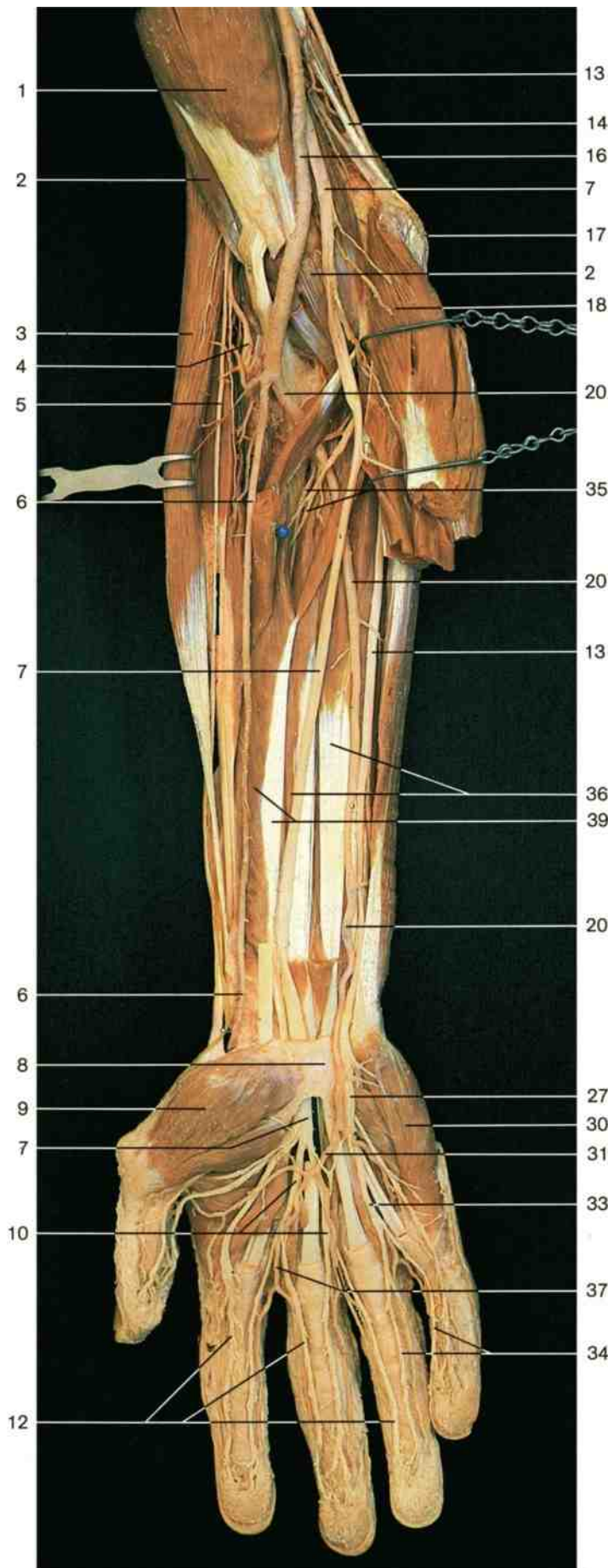
- 21 Extensor pollicis brevis muscle
- 22 Superficial branch of radial nerve
- 23 Radial artery
- 24 Posterior interosseous nerve
- 25 Posterior interosseous branch of radial nerve
- 26 Posterior branch of anterior interosseous artery
- 27 Supinator muscle



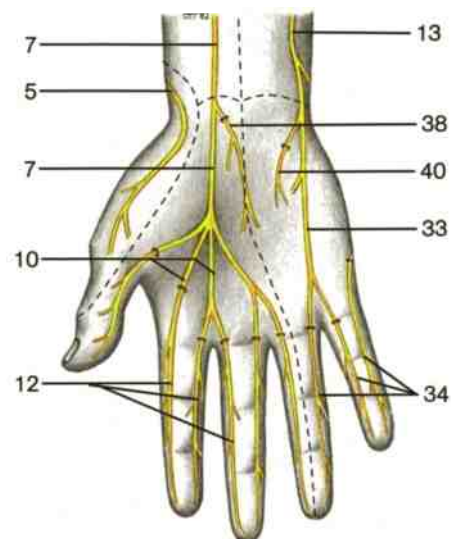
Vessels and nerves of right forearm and hand, superficial layer (palmar aspect).



Vessels and nerves of right forearm and hand, superficial layer (palmar aspect). The palmar aponeurosis of the hand and the bicipital aponeurosis have been removed.

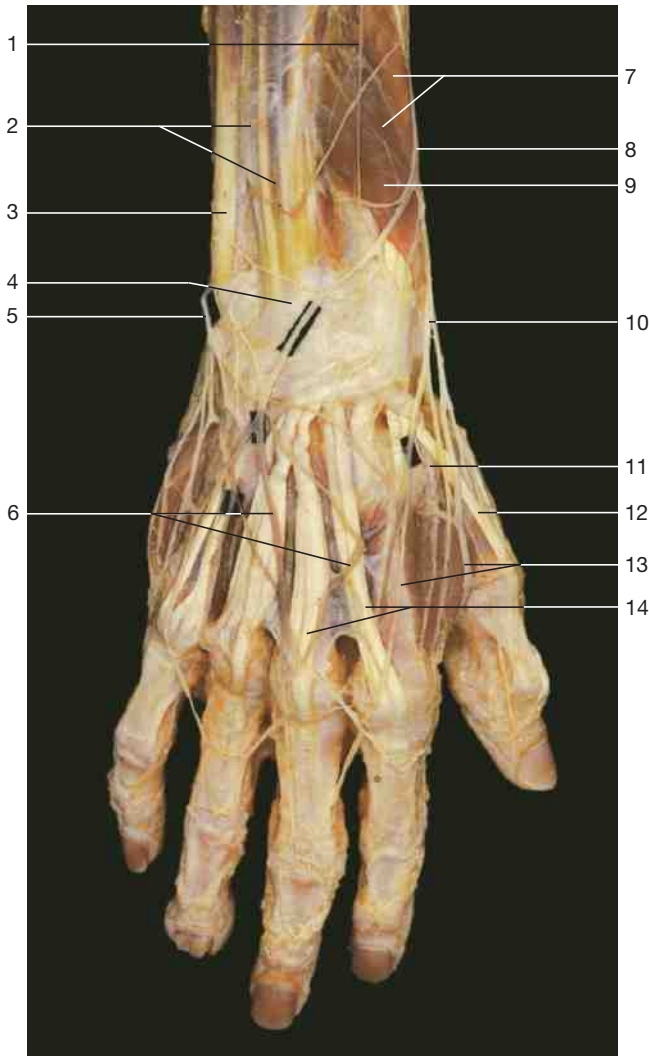


- 1 Biceps brachii muscle
- 2 Brachialis muscle
- 3 Brachioradialis muscle
- 4 Deep branch of radial nerve
- 5 Superficial branch of radial nerve
- 6 Radial artery
- 7 Median nerve
- 8 Flexor retinaculum
- 9 Thenar muscles
- 10 Common palmar digital branches of median nerve
- 11 Common palmar digital arteries
- 12 Proper palmar digital nerves (median nerve)
- 13 Ulnar nerve
- 14 Medial intermuscular septum of arm
- 15 Superior ulnar collateral artery
- 16 Brachial artery
- 17 Medial epicondyle of humerus
- 18 Pronator teres muscle
- 19 Bicipital aponeurosis
- 20 Ulnar artery
- 21 Palmaris longus muscle
- 22 Flexor carpi radialis muscle
- 23 Flexor digitorum superficialis muscle
- 24 Flexor carpi ulnaris muscle
- 25 Tendon of palmaris longus muscle
- 26 Remnant of antebrachial fascia
- 27 Superficial branch of ulnar nerve
- 28 Palmaris brevis muscle
- 29 Palmar aponeurosis
- 30 Hypothenar muscles
- 31 Superficial palmar arch
- 32 Superficial transverse metacarpal ligament
- 33 Common palmar digital branch of ulnar nerve
- 34 Proper palmar digital branches of ulnar nerve
- 35 Anterior interosseous artery and nerve
- 36 Flexor digitorum profundus muscle
- 37 Common palmar digital arteries
- 38 Palmar branch of median nerve
- 39 Flexor pollicis longus muscle
- 40 Palmar branch of ulnar nerve

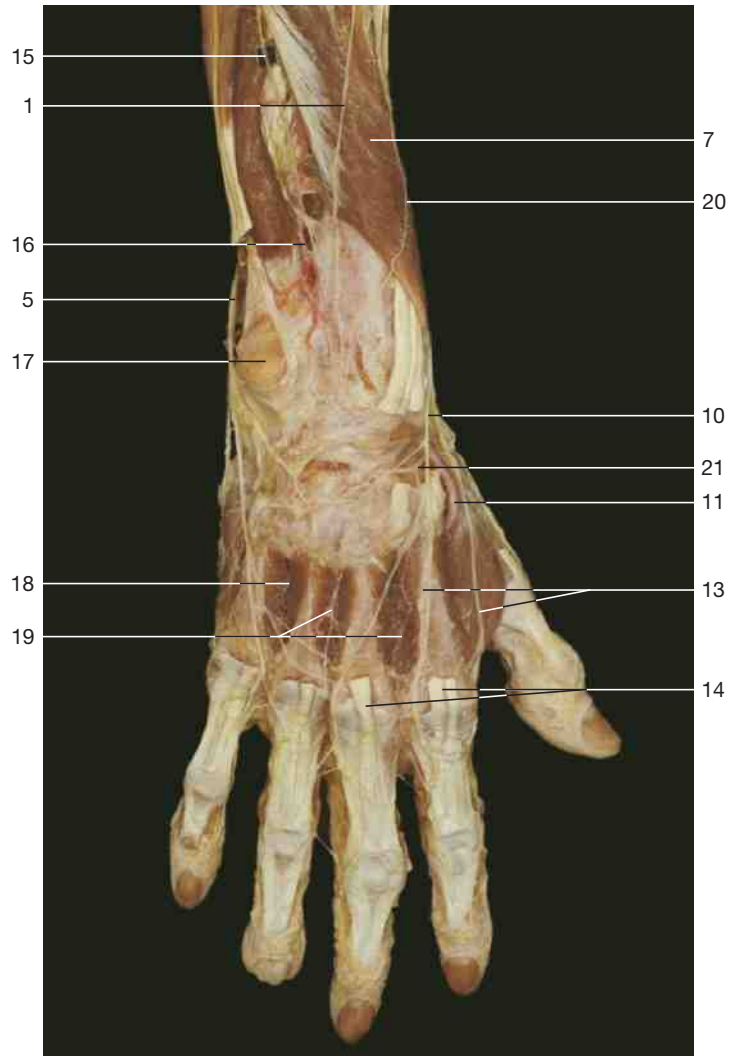


Vessels and nerves of forearm and hand, deep layer (palmar aspect). The superficial layer of the flexor muscles has been removed.

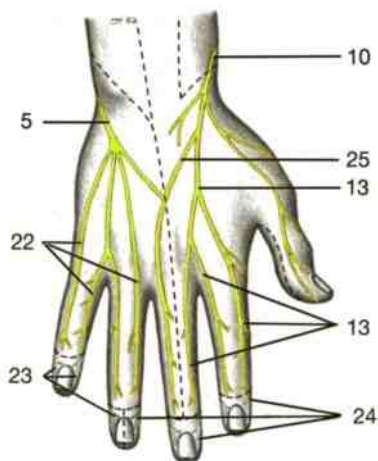
Innervation pattern of palmar surfaces of hand.
3½ digits by median nerve, 1½ digits by ulnar nerve.



Posterior region of hand (superficial layer). Cutaneous nerves and veins are depicted.



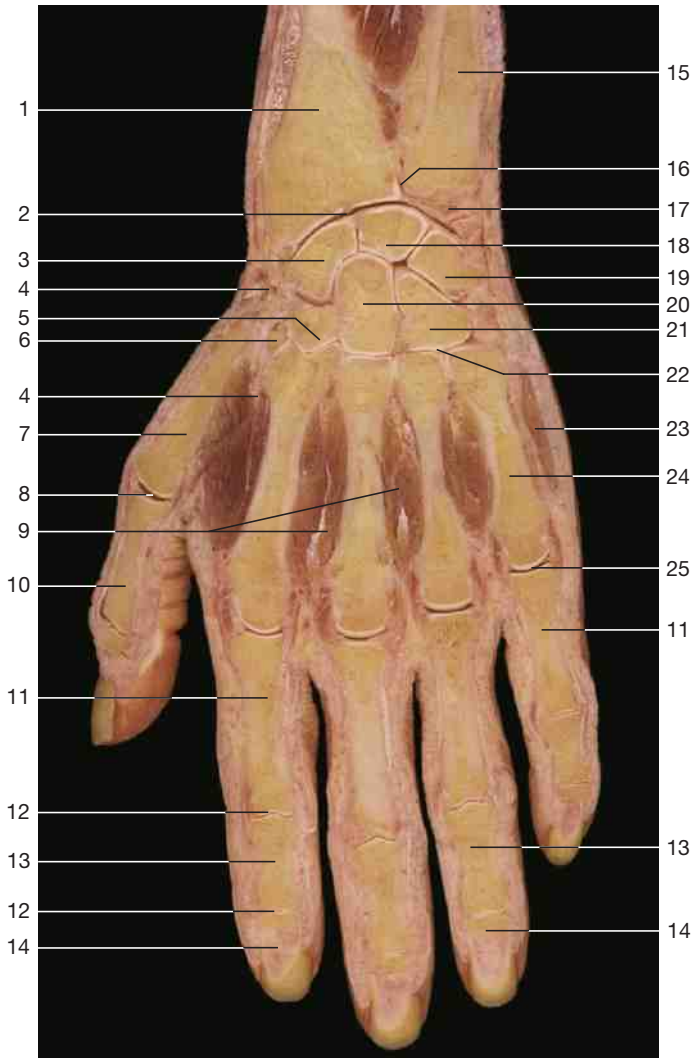
Posterior region of hand (deeper layer). Extensor digitorum muscle has been partly removed.



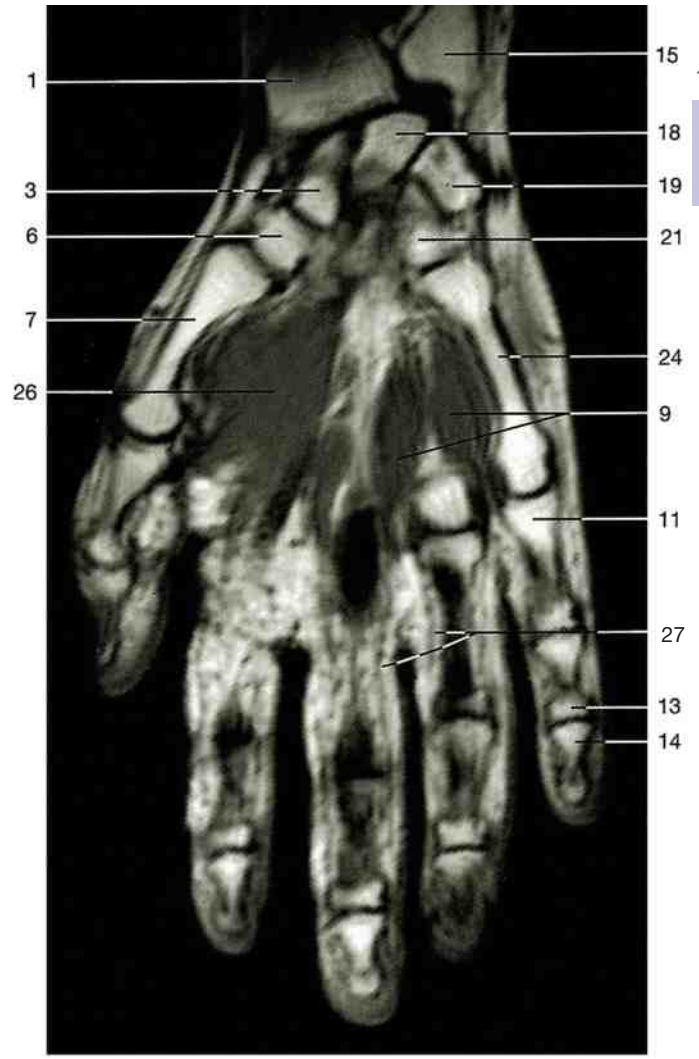
Innervation pattern of posterior surfaces of hand.

2½ digits by radial nerve, 2½ digits by ulnar nerve. Note that the terminal branches to the dorsal surfaces of the distal phalanges are derived from the palmar digital nerves. The cutaneous distribution varies; often 3½ digits are innervated by the radial and 1½ digits by the ulnar nerve.

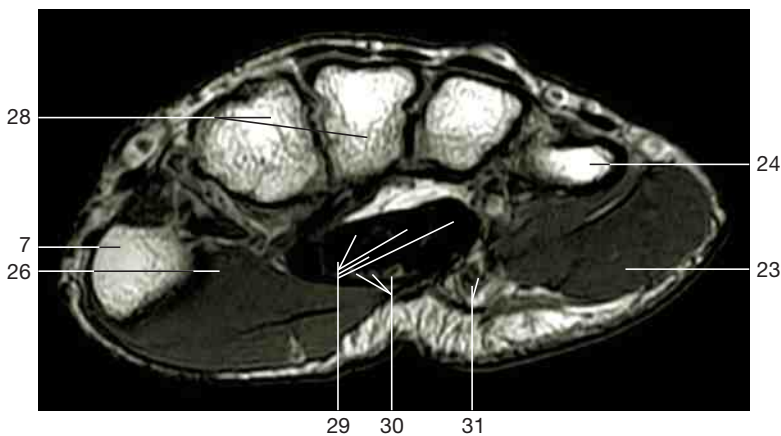
- 1 Posterior cutaneous nerve of forearm (branch of radial nerve)
- 2 Extensor digitorum muscle
- 3 Tendon of extensor carpi ulnaris muscle
- 4 Extensor retinaculum
- 5 Ulnar nerve
- 6 Dorsal venous network of hand
- 7 Abductor pollicis longus muscle
- 8 Cephalic vein
- 9 Extensor pollicis brevis muscle
- 10 Radial nerve, superficial branch
- 11 Radial artery
- 12 Tendon of extensor pollicis longus muscle
- 13 Dorsal digital branches of radial nerve
- 14 Tendons of extensor digitorum muscle with intertendinous connections
- 15 Posterior interosseus nerve (branch of the deep radial nerve)
- 16 Posterior interosseous artery
- 17 Styloid process of ulna
- 18 Dorsal interosseus muscle IV
- 19 Dorsal carpal branch of radial artery
- 20 Lateral cutaneous nerve of forearm (branch of musculocutaneous nerve)
- 21 Dorsal metacarpal artery
- 22 Proper dorsal digital branches of ulnar nerve
- 23 Regions supplied by palmar digital nerves (ulnar nerve)
- 24 Regions supplied by palmar digital nerves (median nerve)
- 25 Communicating branch with ulnar nerve



Coronal section through the left hand (posterior aspect).



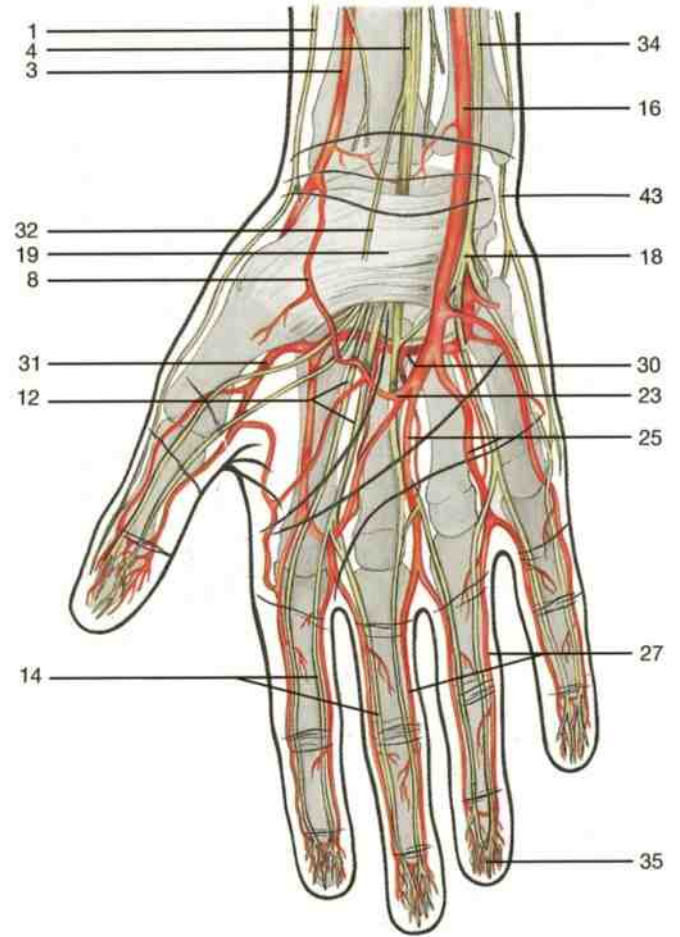
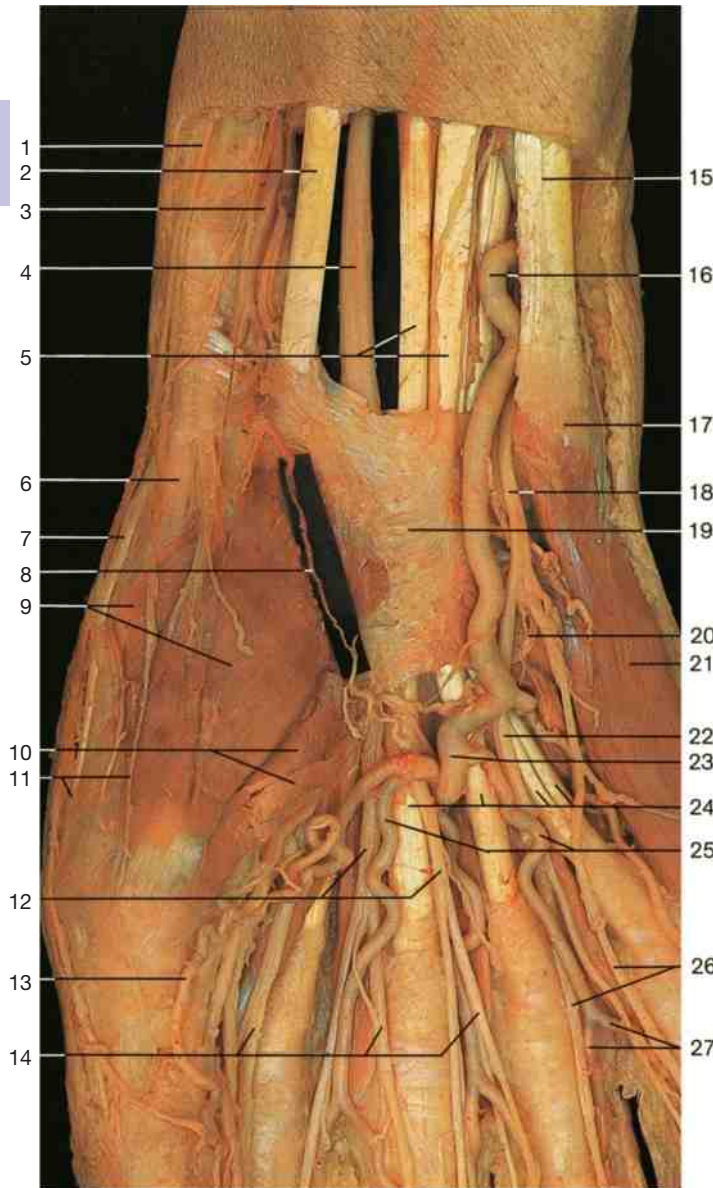
Coronal section through the left hand (posterior aspect) (MRI scan, courtesy of Prof. Heuck, Munich).



Axial section through the left hand (MRI scan; from Heuck et al., MRT-Atlas, 2009).

- | | |
|--------------------------------------|--------------------------------|
| 1 Radius | 10 Proximal phalanx of thumb |
| 2 Wrist joint | 11 Proximal phalanx of fingers |
| 3 Scaphoid (navicular) bone | 12 Interphalangeal joints |
| 4 Radial artery | 13 Middle phalanx |
| 5 Trapezoid bone | 14 Distal phalanx |
| 6 Trapezium bone | 15 Ulna |
| 7 First metacarpal bone | 16 Distal radio-ulnar joint |
| 8 Metacarpophalangeal joint of thumb | 17 Articular disc |
| 9 Interosseous muscles | 18 Lunate bone |

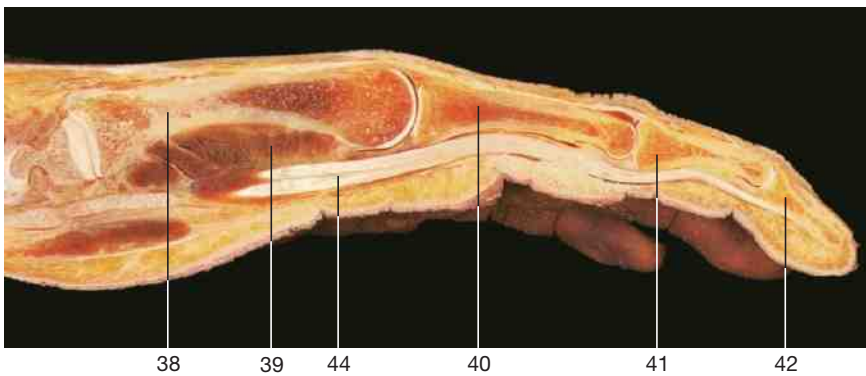
- | |
|--|
| 19 Triquetral bone |
| 20 Capitate bone |
| 21 Hamate bone |
| 22 Carpometacarpal joints |
| 23 Abductor digiti minimi muscle |
| 24 Fifth metacarpal bone |
| 25 Metacarpophalangeal joint |
| 26 Adductor pollicis muscle |
| 27 Proper palmar digital arteries |
| 28 Second and third metacarpal bones |
| 29 Tendons of flexor digitorum superficialis and profundus muscles |
| 30 Median nerve |
| 31 Ulnar artery and vein |



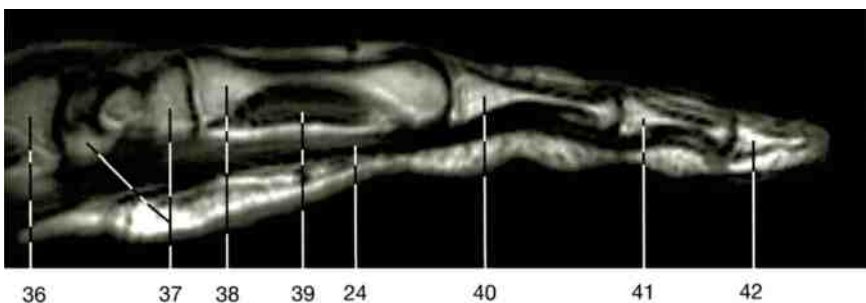
Arteries and nerves of the right hand
(palmar aspect, schematic drawing).



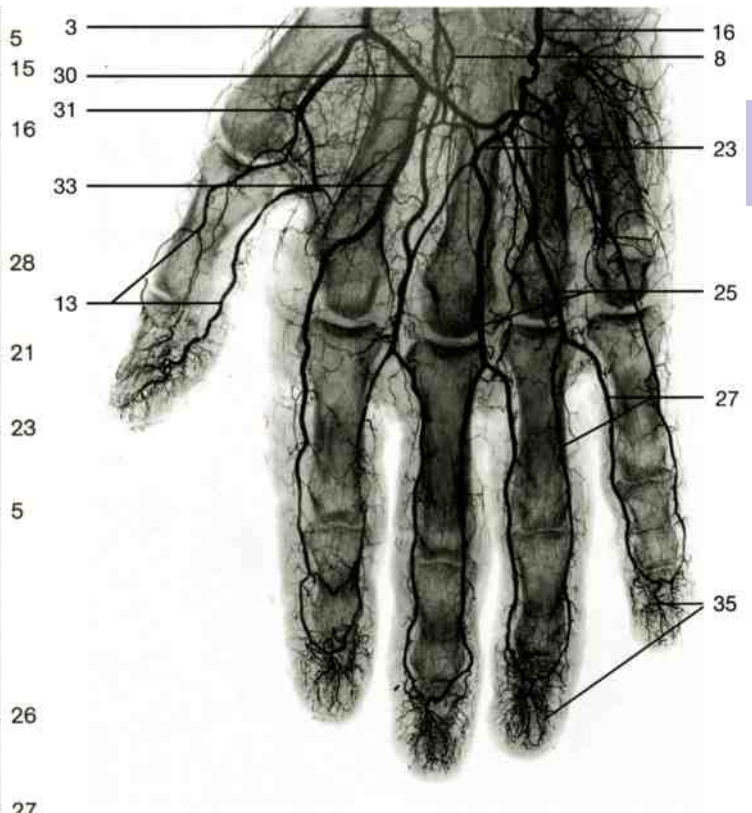
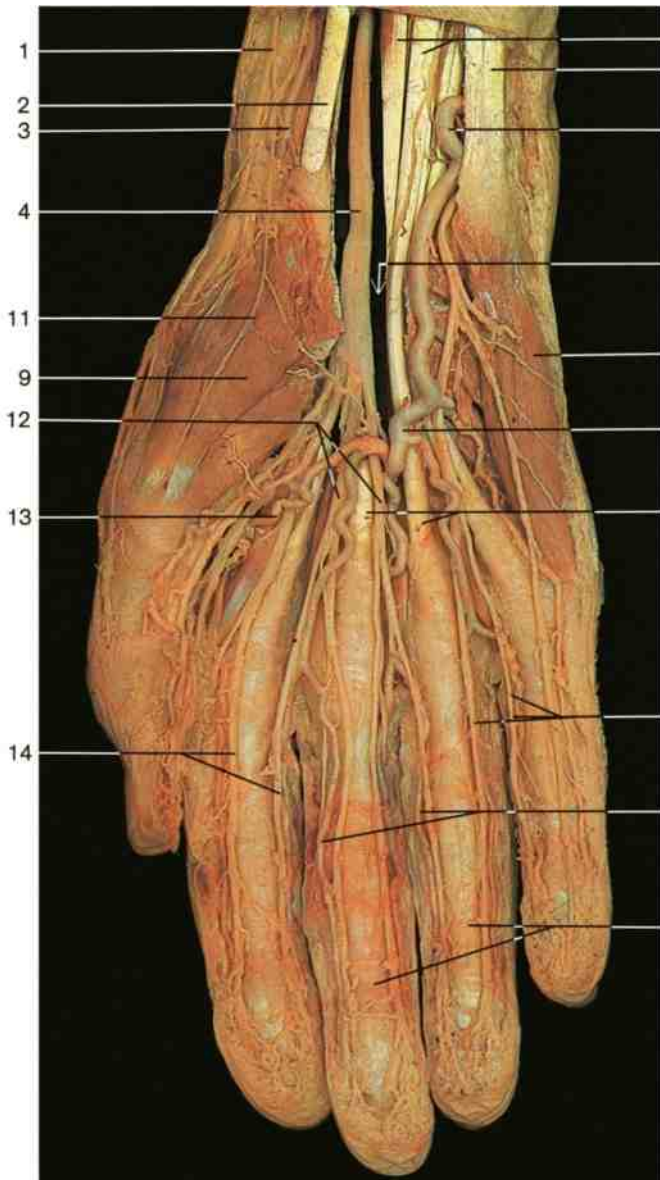
Right hand, superficial layer (palmar aspect).
Dissection of the superficial palmar arch.



Longitudinal section through the hand
at the level of the third finger.



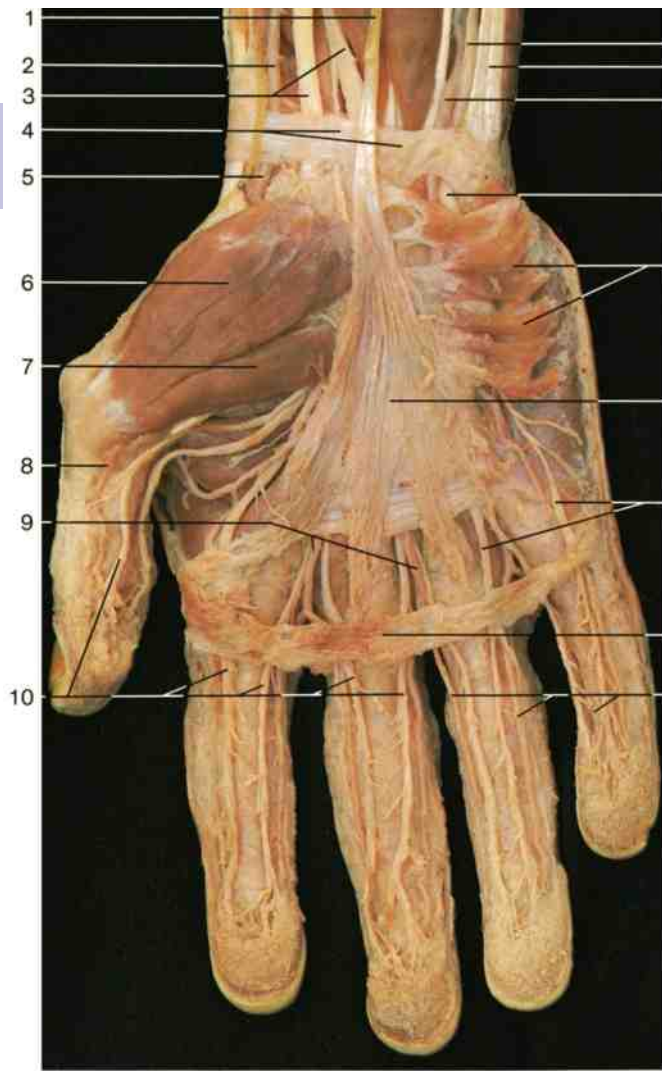
Longitudinal section through the hand
at the level of the third finger (MRI scan,
courtesy of Prof. Heuck, Munich).



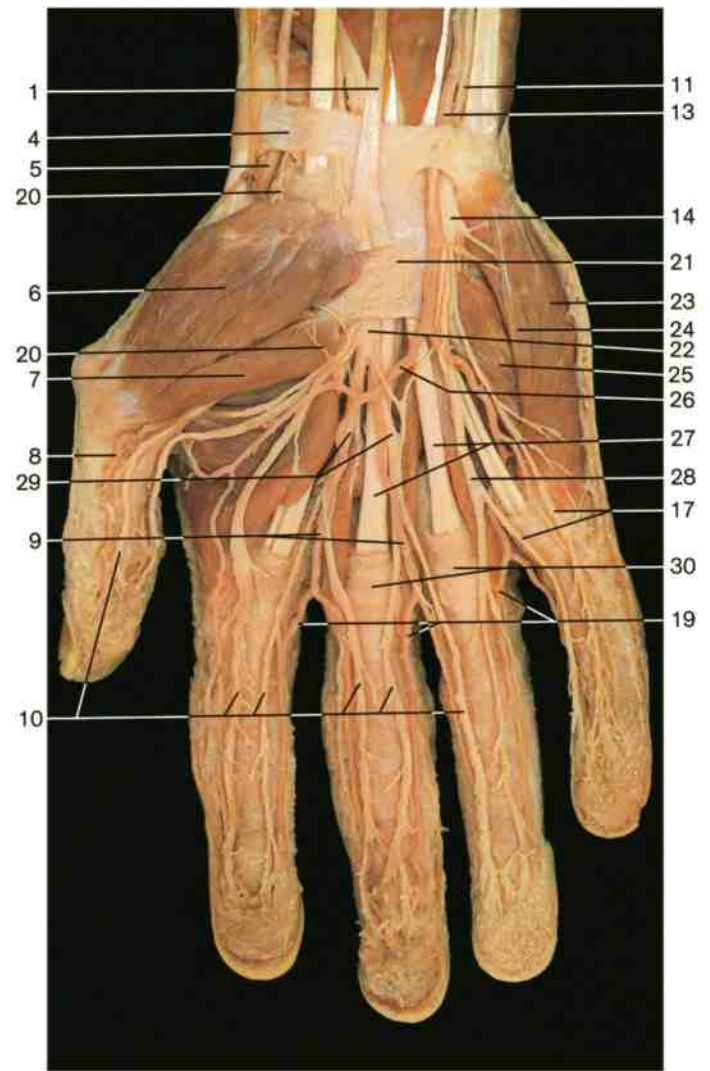
Arteriogram of the right hand (palmar aspect).

Right hand, middle layer (palmar aspect). The flexor retinaculum has been removed.

- | | |
|---|--|
| <ul style="list-style-type: none"> 1 Superficial branch of radial nerve 2 Tendon of flexor carpi radialis muscle 3 Radial artery 4 Median nerve 5 Tendon of flexor digitorum superficialis muscle 6 Tendon of abductor pollicis longus muscle 7 Tendon of extensor pollicis brevis muscle 8 Superficial palmar branch of radial artery 9 Abductor pollicis brevis muscle 10 Superficial head of flexor pollicis brevis muscle 11 Terminal branches of superficial branch of radial nerve 12 Common palmar digital nerves (median nerve) 13 Proper palmar digital arteries of thumb 14 Proper palmar digital nerves (median nerve) 15 Tendon of flexor carpi ulnaris muscle 16 Ulnar artery 17 Position of pisiform bone 18 Superficial branch of ulnar nerve 19 Flexor retinaculum 20 Deep branch of ulnar nerve 21 Abductor digiti minimi muscle 22 Common palmar digital nerves (ulnar nerve) | <ul style="list-style-type: none"> 23 Superficial palmar arch 24 Tendons of flexor digitorum muscles 25 Common palmar digital arteries 26 Palmar digital nerves (ulnar nerve) 27 Proper palmar digital arteries 28 Carpal tunnel 29 Fibrous sheaths for the tendons of flexor digitorum muscles 30 Deep palmar arch 31 Princeps pollicis artery 32 Palmar branch of median nerve 33 Common digital palmar artery 34 Ulnar nerve 35 Capillary network of finger 36 Radius 37 Carpal bones 38 Metacarpal bone 39 Interosseous muscles 40 Proximal phalanx 41 Middle phalanx 42 Distal phalanx 43 Dorsal branch of ulnar nerve 44 Tendons of flexor digitorum profundus (upper) and superficialis (lower) muscles |
|---|--|



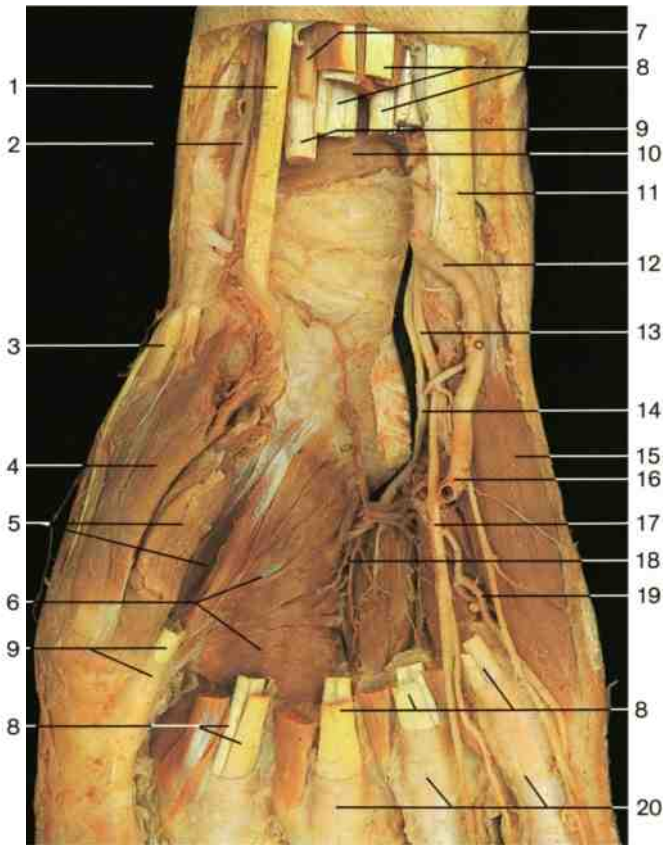
Right hand, superficial layer (palmar aspect). Dissection of vessels and nerves.



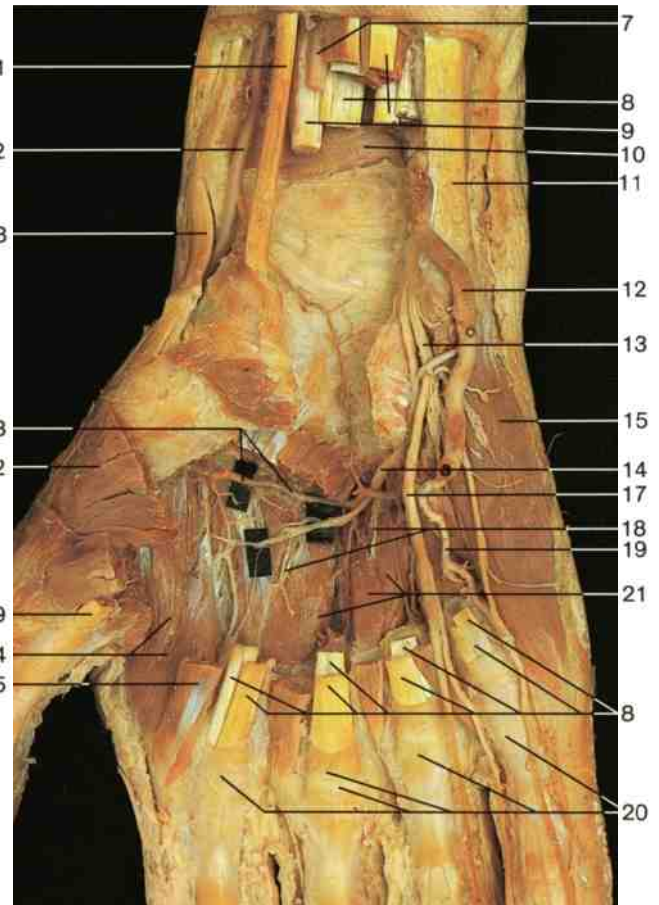
Right hand, superficial layer (palmar aspect). Dissection of vessels and nerves. The palmar aponeurosis has been removed to display the superficial palmar arch.

- 1 Tendon of palmaris longus muscle
- 2 Radial artery
- 3 Tendon of flexor carpi radialis muscle and median nerve
- 4 Distal part of antebrachial fascia
- 5 Radial artery passing into the anatomical snuffbox
- 6 Abductor pollicis brevis muscle
- 7 Superficial head of flexor pollicis brevis muscle
- 8 Palmar digital artery of thumb
- 9 Common palmar digital arteries
- 10 Proper palmar digital nerves (median nerve)
- 11 Ulnar nerve
- 12 Tendon of flexor carpi ulnaris muscle
- 13 Ulnar artery
- 14 Superficial branch of ulnar nerve
- 15 Palmaris brevis muscle
- 16 Palmar aponeurosis

- 17 Palmar digital nerves (ulnar nerve)
- 18 Superficial transverse metacarpal ligament
- 19 Proper palmar digital arteries
- 20 Superficial palmar branch of radial artery (contributing to the superficial palmar arch)
- 21 Flexor retinaculum
- 22 Median nerve
- 23 Abductor digiti minimi muscle
- 24 Flexor digiti minimi brevis muscle
- 25 Opponens digiti minimi muscle
- 26 Superficial palmar arch
- 27 Tendons of flexor digitorum superficialis muscle
- 28 Common palmar digital branch of ulnar nerve
- 29 Common palmar digital branch of median nerve
- 30 Fibrous sheath of flexor tendons



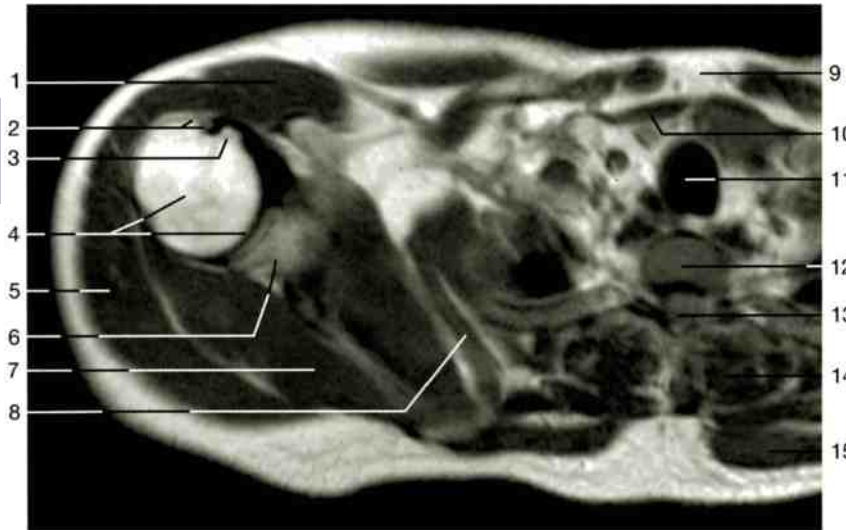
Right hand, deep layer (palmar aspect). The carpal tunnel has been opened, the tendons of the flexor muscles have been removed, and the superficial palmar arch has been cut.



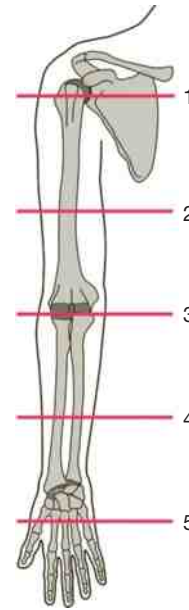
Right hand, deep layer (palmar aspect). Dissection of the deep palmar arch.

- 1 Tendon of flexor carpi radialis muscle
- 2 Radial artery
- 3 Tendon of abductor pollicis longus muscle
- 4 Abductor pollicis brevis muscle
- 5 Superficial and deep heads of flexor pollicis brevis muscle
- 6 Oblique and transverse heads of adductor pollicis muscle
- 7 Median nerve
- 8 Tendons of flexor digitorum superficialis and profundus muscles
- 9 Tendon of flexor pollicis longus muscle
- 10 Pronator quadratus muscle
- 11 Tendon of flexor carpi ulnaris muscle

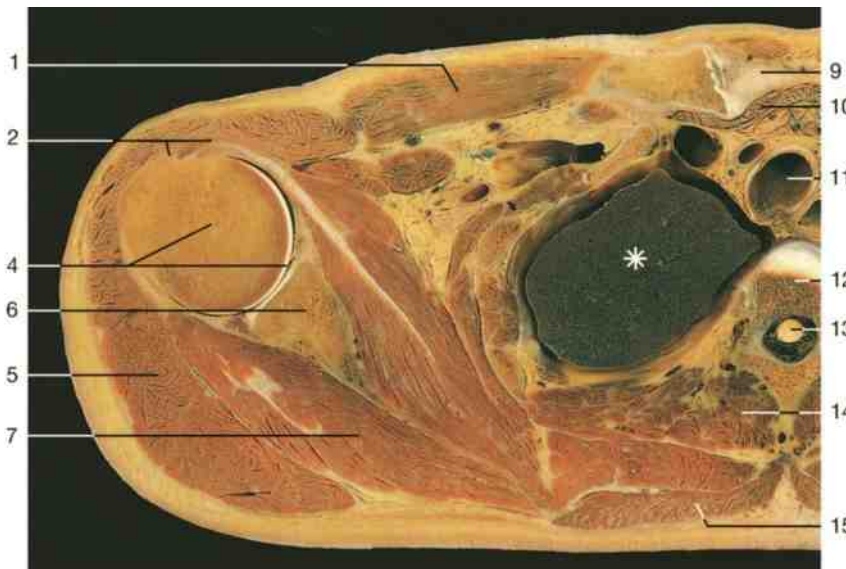
- 12 Ulnar artery
- 13 Superficial branch of ulnar nerve
- 14 Deep branch of ulnar nerve
- 15 Abductor digiti minimi muscle
- 16 Superficial palmar arch (cut end)
- 17 Common palmar digital nerves (ulnar nerve)
- 18 Palmar metacarpal arteries of deep palmar arch
- 19 Palmar digital artery of the fifth finger
- 20 Fibrous sheaths of tendons of flexor muscles
- 21 Palmar interosseous muscles
- 22 Opponens pollicis muscle (cut)
- 23 Deep palmar arch
- 24 First dorsal interosseous muscle
- 25 First lumbrical muscle



Horizontal section through the right shoulder joint (section 1; MRI scan; inferior aspect).

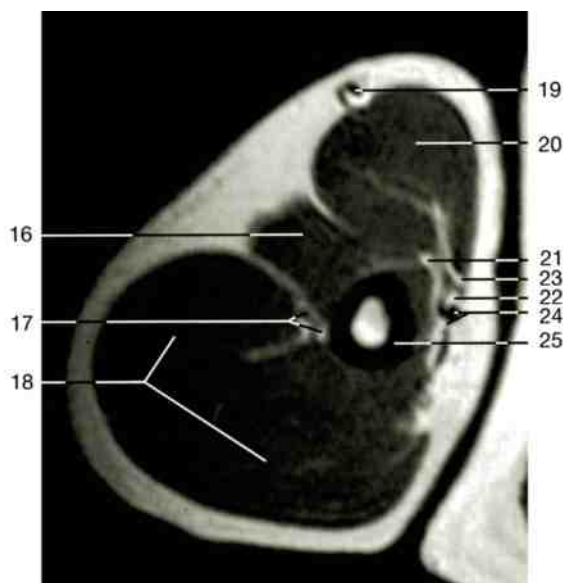


Upper limb, location of sections 1–5
(MRI scans, p. 430: courtesy of Prof. Heuck, Munich, Germany; MRI scans, p. 431: courtesy of Prof. Bautz and R. Janka, M. D., University of Erlangen, Germany).

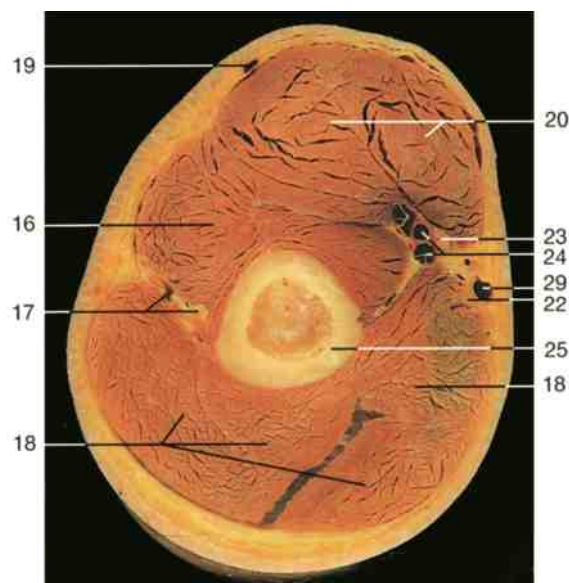


Horizontal section through the right shoulder joint (section 1; inferior aspect).
* = Upper lobe of lung.

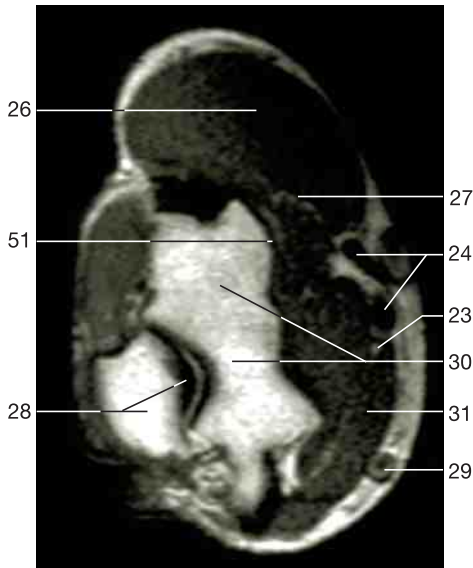
- 1 Pectoralis major muscle
- 2 Greater tubercle and tendon of biceps muscle
- 3 Lesser tubercle
- 4 Head of humerus and articular cavity of shoulder joint
- 5 Deltoid muscle
- 6 Scapula
- 7 Infraspinatus muscle
- 8 Serratus anterior muscle
- 9 Sternum
- 10 Infrahyoid muscles
- 11 Trachea
- 12 Body of thoracic vertebra
- 13 Vertebral canal and spinal cord
- 14 Deep muscles of the back
- 15 Trapezius muscle
- 16 Brachialis muscle
- 17 Radial nerve and profunda brachii vessels



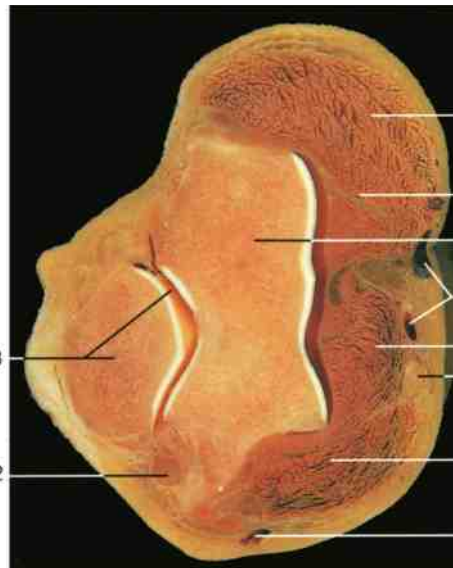
Axial section through the middle of the right arm (section 2; MRI scan; inferior aspect).



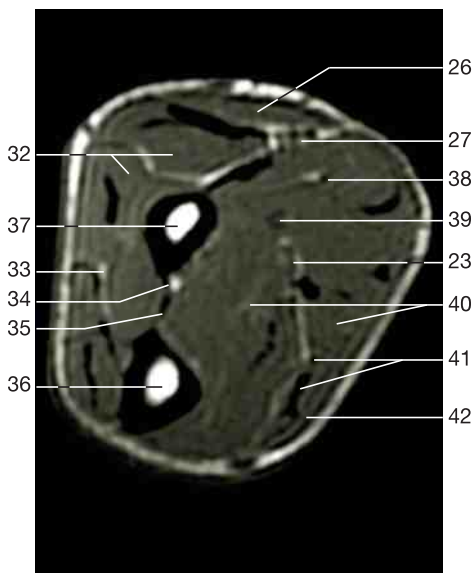
Axial section through the middle of the right arm (section 2; inferior aspect).



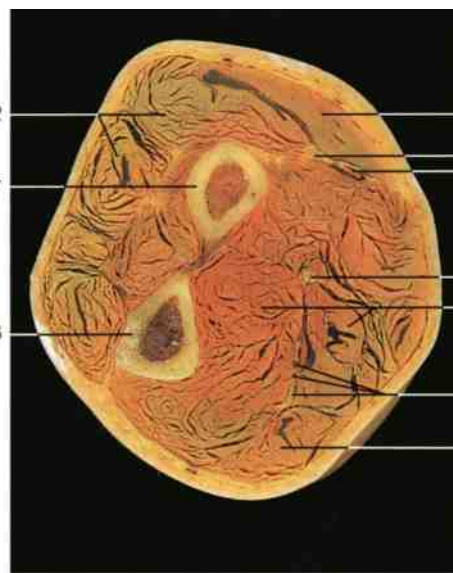
Axial section through the right elbow joint (section 3; MRI scan; inferior aspect).



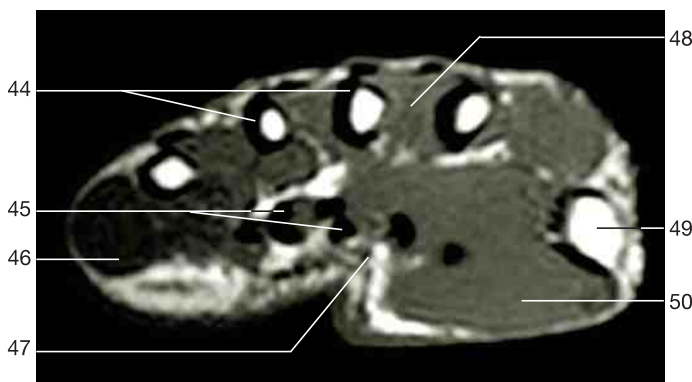
Axial section through the right elbow joint (section 3; inferior aspect).



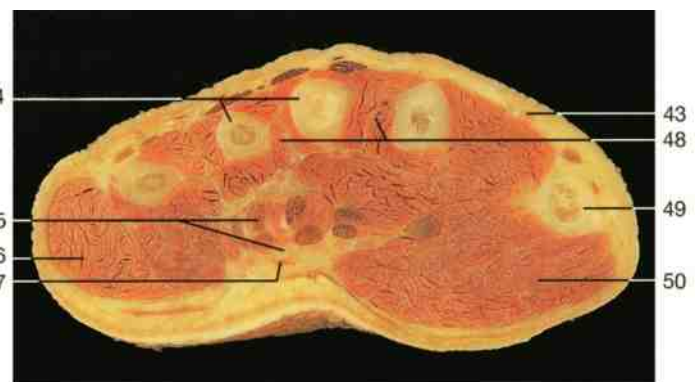
Axial section through the middle of the right forearm (section 4; MRI scan; inferior aspect).



Axial section through the middle of the right forearm (section 4; inferior aspect).



Axial section through the right hand at the level of the metacarpus (section 5; MRI scan; inferior aspect).

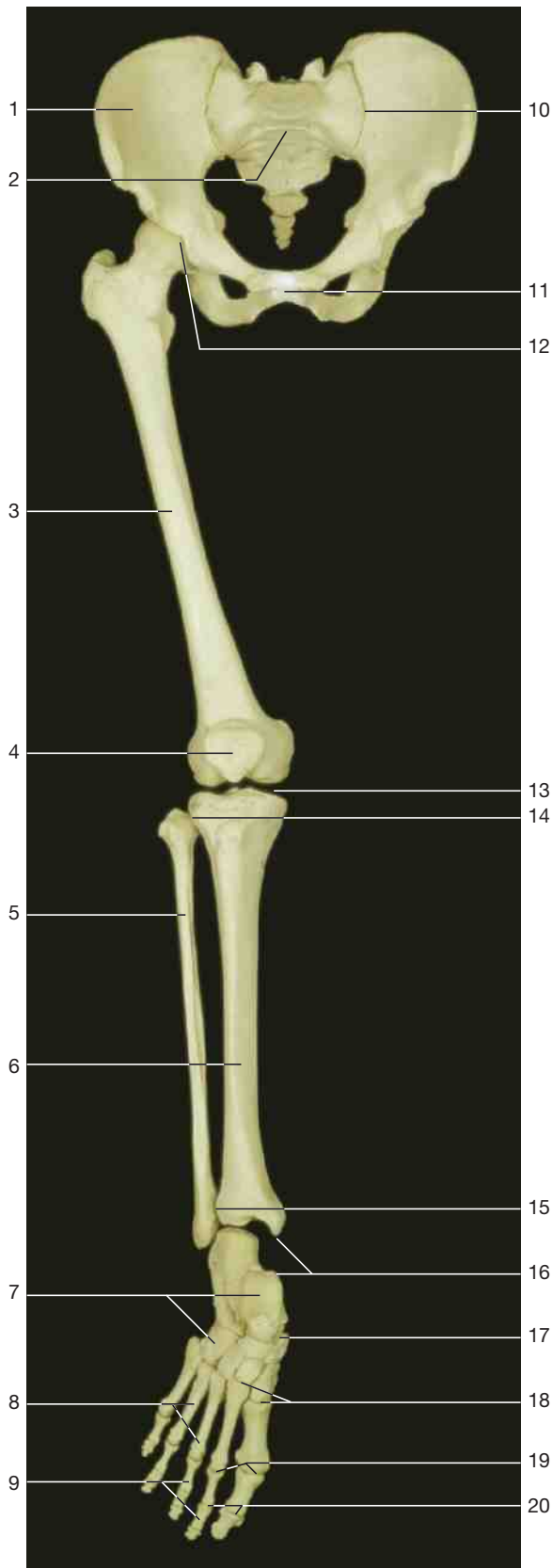


Axial section through the right hand at the level of the metacarpus (section 5; inferior aspect).

- 18 Triceps brachii muscle
- 19 Cephalic vein
- 20 Biceps brachii muscle
- 21 Musculocutaneous nerve
- 22 Ulnar nerve
- 23 Medianus nerve
- 24 Brachial artery and vein
- 25 Shaft of humerus
- 26 Brachioradialis muscle
- 27 Radial nerve
- 28 Olecranon and articular cavity of elbow joint
- 29 Basilic vein
- 30 Humerus
- 31 Pronator teres muscle
- 32 Extensor muscles of forearm
- 33 Ramus profundus of radial nerve
- 34 Anterior interosseus vessels and nerve
- 35 Interosseous membrane
- 36 Ulna
- 37 Radius
- 38 Radial artery and superficial branch of radial nerve
- 39 Flexor pollicis longus muscle
- 40 Flexor digitorum superficialis and profundus muscles
- 41 Ulnar nerve, ulnar artery, and vein
- 42 Flexor carpi ulnaris muscle
- 43 Radial artery
- 44 Metacarpal bones III and IV
- 45 Carpal canal with tendons of flexor digitorum muscles
- 46 Hypothenar muscle
- 47 Median nerve
- 48 Interosseous muscles
- 49 First metacarpal bone
- 50 Thenar muscles
- 51 Articular cavity of humeroradial joint



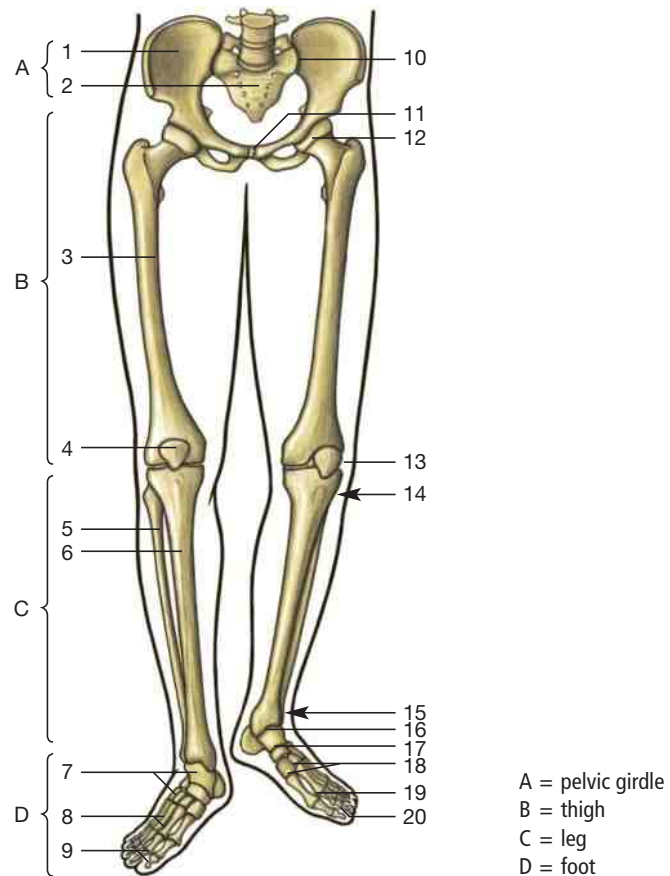
8 Lower Limb



Skeleton of pelvic girdle and lower limb (anterior aspect). The ankle joint has been dislocated.

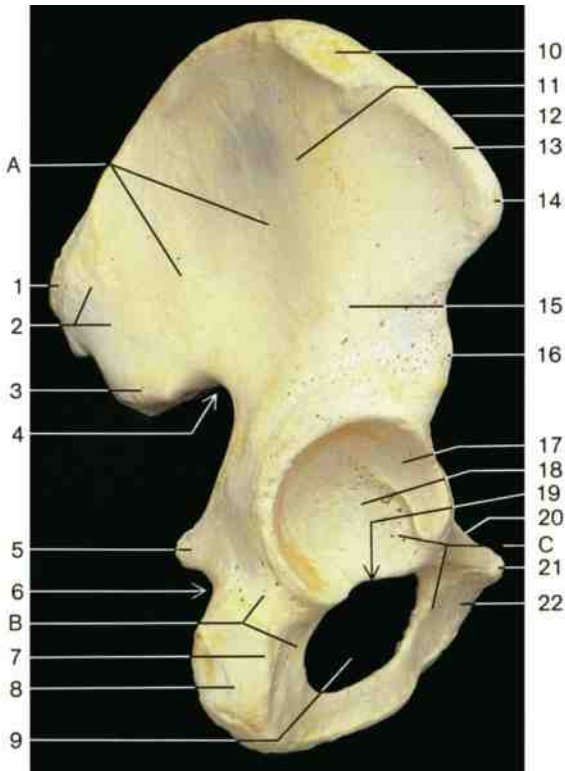
The lower limb (extremity) is specialized for support of the upright posture, locomotion, and maintaining balance. In contrast to the upper limb, the lower limb is more restricted in its movements, and the joints are tighter and fixed by strong ligaments. The hip joint is a ball-and-socket type of synovial joint between the head of the femur and acetabulum. The knee joint is a hinge type of synovial joint that permits only limited rotation. The talocrural joint is a hinge joint between the talus, fibula, and tibia, only allowing movements of flexion and extension.

The long axis of the foot is at a right angle to that of the leg, thus forming an effective arch for the upright stance of the body.

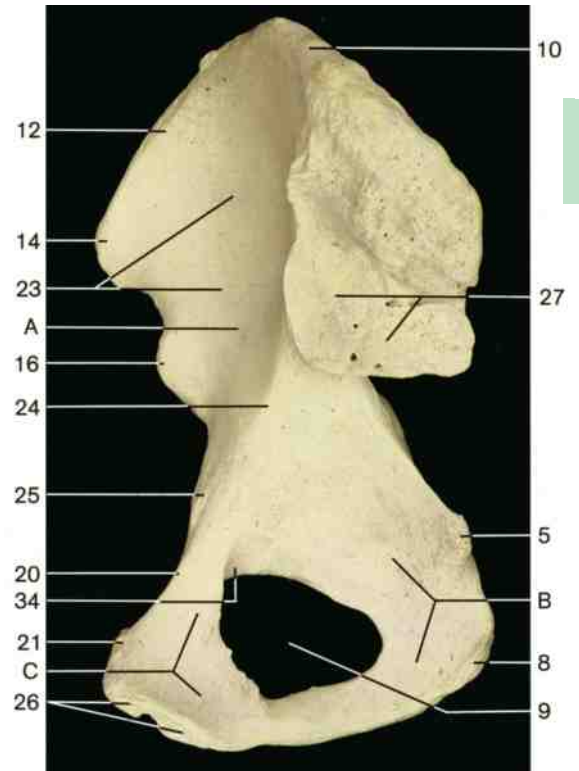


Organization of pelvic girdle and lower limb.

- | | |
|----------------------|--------------------------------|
| 1 Right hip bone | 11 Pubic symphysis |
| 2 Sacrum | 12 Hip joint |
| 3 Femur | 13 Knee joint |
| 4 Patella | 14 Proximal tibiofibular joint |
| 5 Fibula | 15 Distal tibiofibular joint |
| 6 Tibia | 16 Ankle joint |
| 7 Tarsal bones | 17 Talocalcaneonavicular joint |
| 8 Metatarsal bones | 18 Tarsometatarsal joints |
| 9 Phalanges | 19 Metatarsophalangeal joints |
| 10 Sacro-iliac joint | 20 Interphalangeal joints |

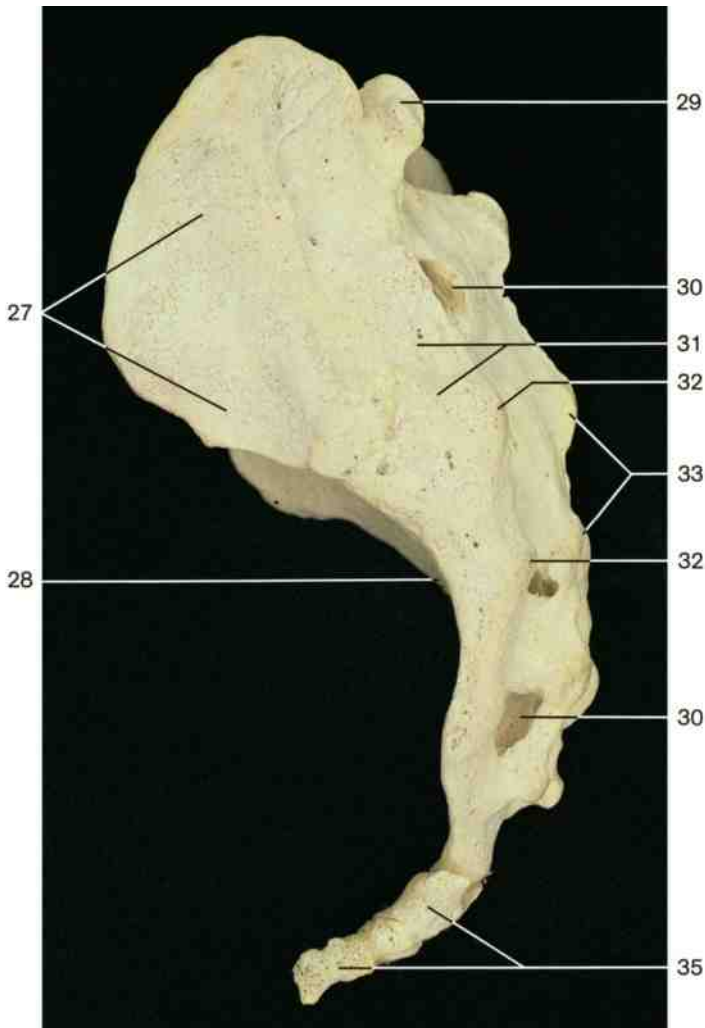


Right hip bone (lateral aspect).



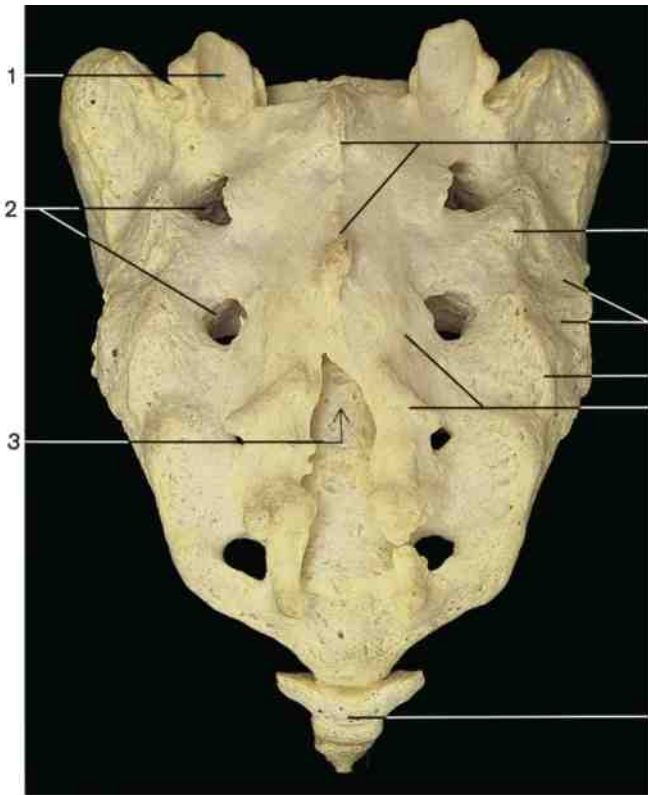
Right hip bone (medial aspect).

A = ilium
 B = ischium
 C = pubis

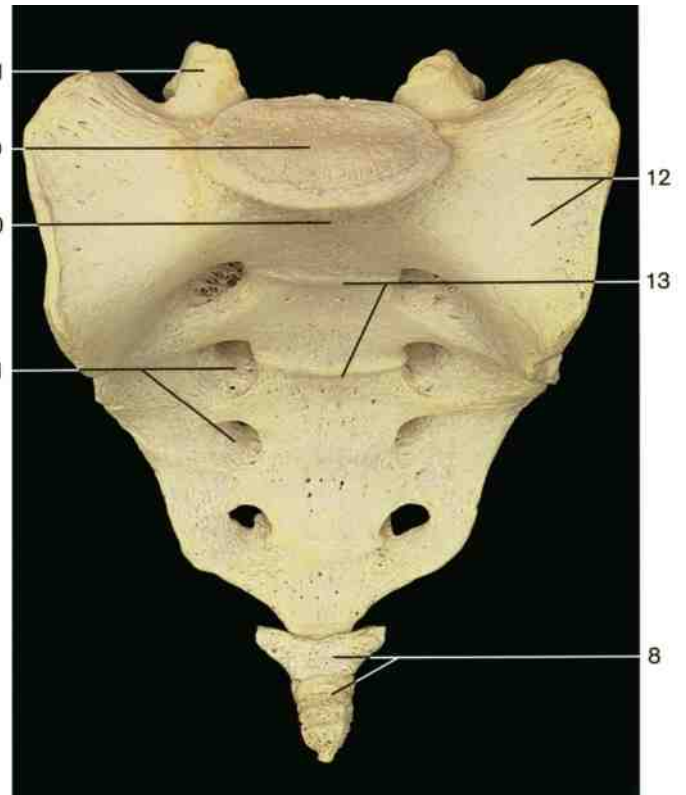


Sacrum and coccyx (lateral aspect).

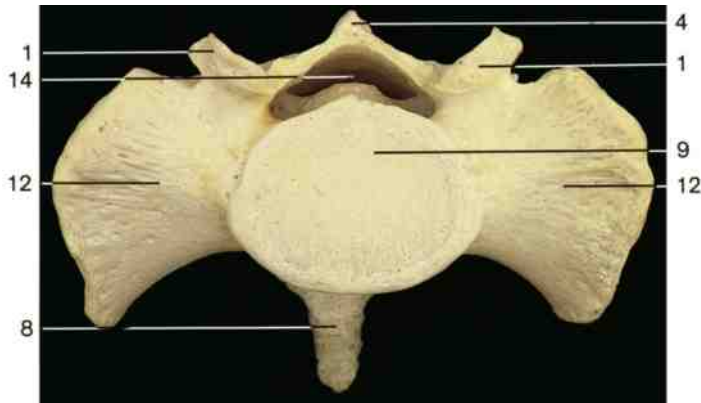
- 1 Posterior superior iliac spine
- 2 Posterior gluteal line
- 3 Posterior inferior iliac spine
- 4 Greater sciatic notch
- 5 Ischial spine
- 6 Lesser sciatic notch
- 7 Body of ischium
- 8 Ischial tuberosity
- 9 Obturator foramen
- 10 Iliac crest
- 11 Anterior gluteal line
- 12 Internal lip of iliac crest
- 13 External lip of iliac crest
- 14 Anterior superior iliac spine
- 15 Inferior gluteal line
- 16 Anterior inferior iliac spine
- 17 Lunate surface of acetabulum
- 18 Acetabular fossa
- 19 Acetabular notch
- 20 Pecten pubis
- 21 Pubic tubercle
- 22 Body of pubis
- 23 Iliac fossa
- 24 Arcuate line
- 25 Iliopubic eminence
- 26 Symphyseal surface of pubis
- 27 Auricular surface
- 28 Pelvic surface of sacrum
- 29 Superior articular process of sacrum
- 30 Dorsal sacral foramina
- 31 Sacral tuberosity
- 32 Lateral sacral crest
- 33 Median sacral crest
- 34 Obturator groove
- 35 Coccyx



Sacrum (posterior aspect).

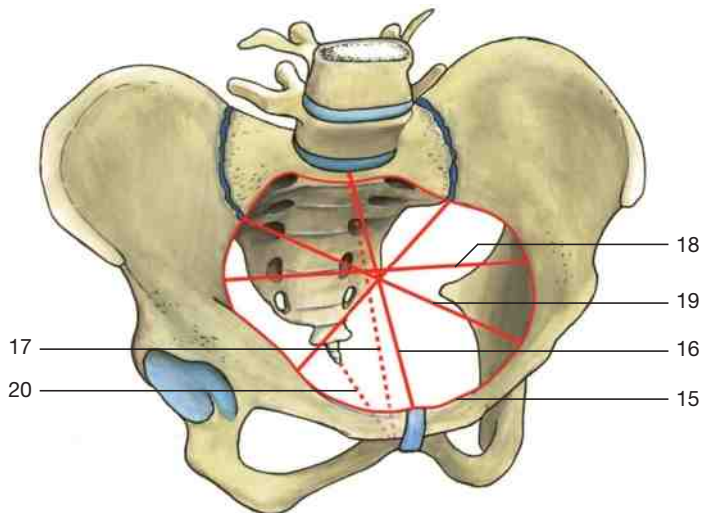


Sacrum (anterior aspect).



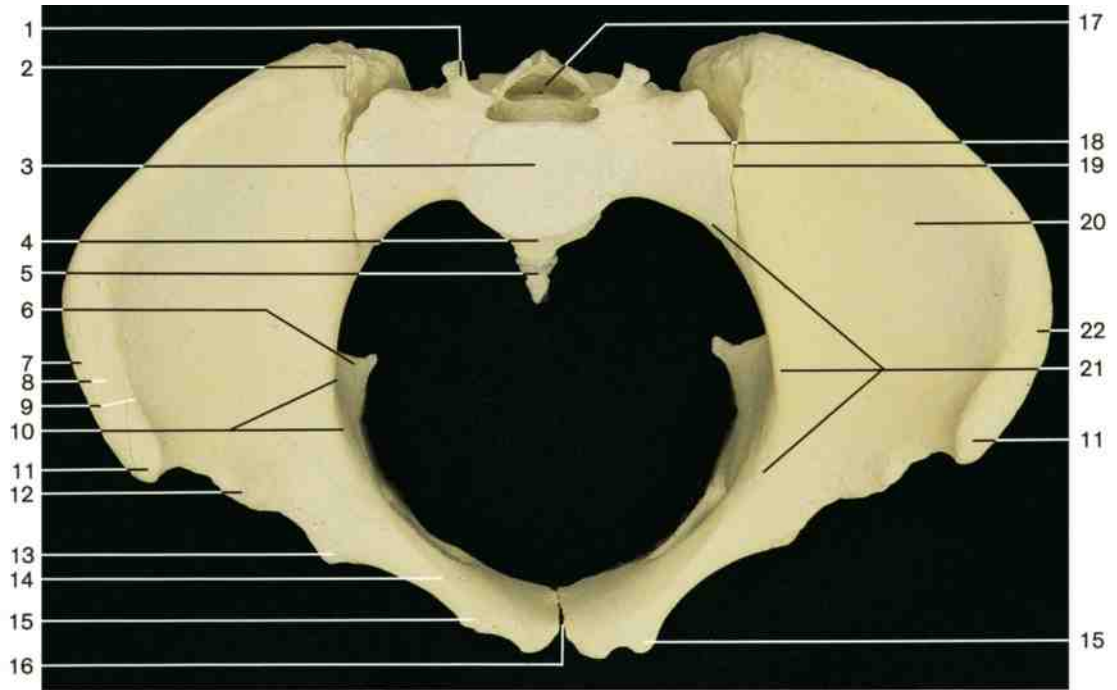
Sacrum (superior aspect).

- 1 Superior articular process of sacrum
- 2 Dorsal sacral foramina
- 3 Sacral hiatus
- 4 Median sacral crest
- 5 Lateral sacral crest
- 6 Sacral tuberosity
- 7 Intermediate sacral crest
- 8 Coccyx
- 9 Base of sacrum
- 10 Sacral promontory
- 11 Anterior sacral foramina
- 12 Lateral part of sacrum (ala)
- 13 Transverse line of sacrum
- 14 Sacral canal
- 15 Linea terminalis
- 16 True conjugate
- 17 Diagonal conjugate
- 18 Transverse diameter
- 19 Oblique diameter
- 20 Inferior pelvic aperture or outlet

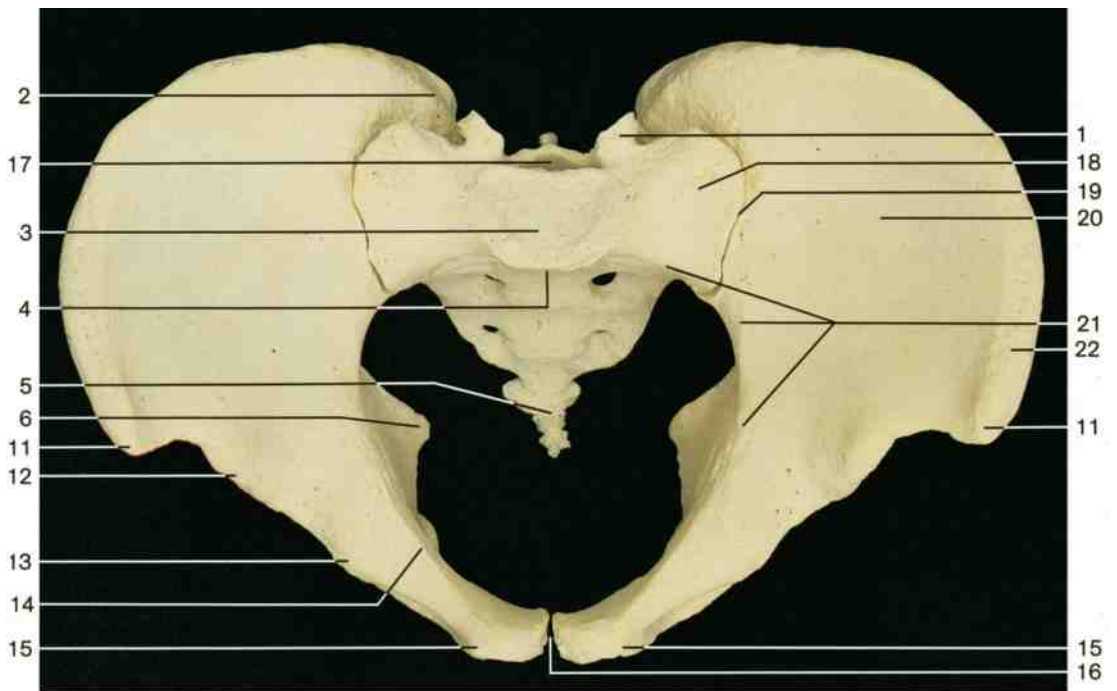


Diameters of pelvis (oblique superior aspect).
(Schematic drawing.)

The pelvic girdle is firmly connected to the vertebral column at the sacro-iliac joint. Therefore, the body can be kept upright more easily even if only one limb is used for support (as in walking). The mobility of the lower limb is more limited than that of the upper limb.

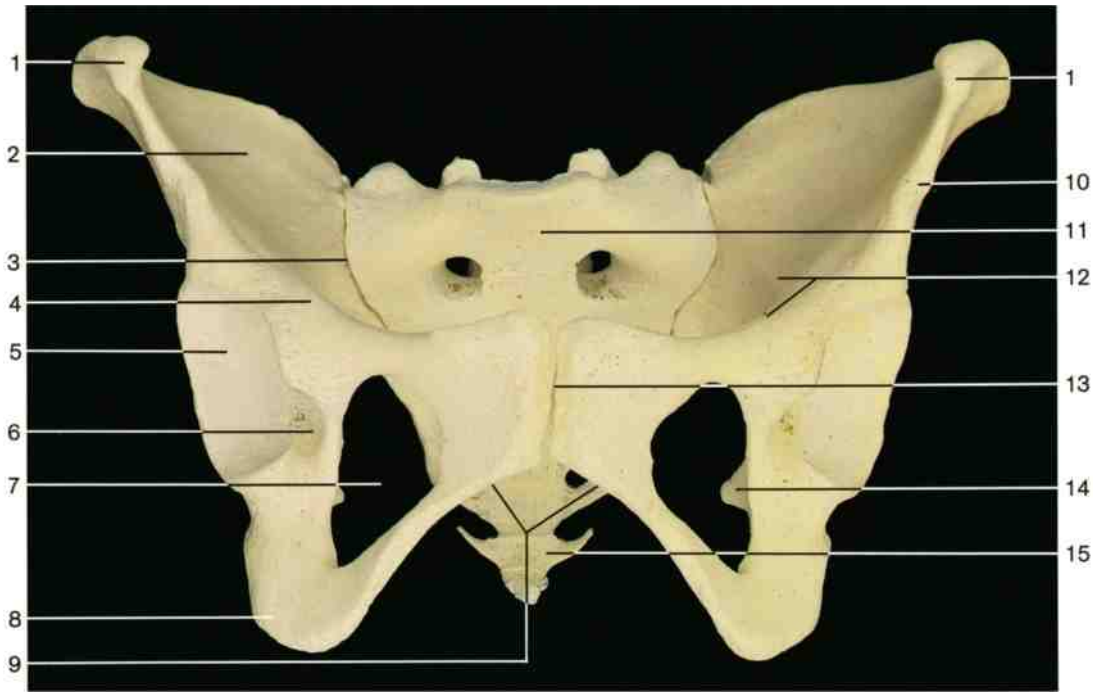


Female pelvis (superior aspect). Note the differences between the male and female pelvis, predominantly in the form and dimensions of the sacrum, the superior and inferior apertures, and the alae of the ilium.

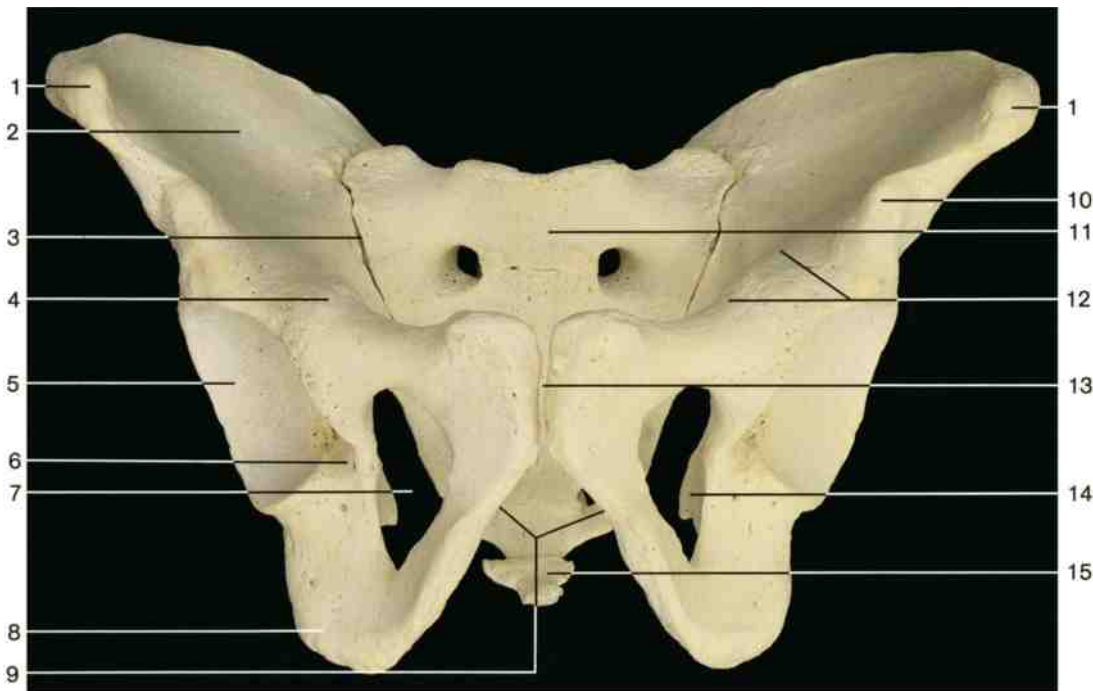


Male pelvis (superior aspect). Compare with the female pelvis (depicted above).

- | | |
|--|----------------------------------|
| 1 Superior articular process of sacrum | 12 Anterior inferior iliac spine |
| 2 Posterior superior iliac spine | 13 Iliopubic eminence |
| 3 Base of sacrum | 14 Pecten pubis |
| 4 Sacral promontory | 15 Pubic tubercle |
| 5 Coccyx | 16 Pubic symphysis |
| 6 Ischial spine | 17 Sacral canal |
| 7 External lip | 18 Ala of sacrum |
| 8 Intermediate line | 19 Position of sacro-iliac joint |
| 9 Internal lip | 20 Iliac fossa |
| 10 Arcuate line | 21 Linea terminalis |
| 11 Anterior superior iliac spine | 22 Iliac crest |

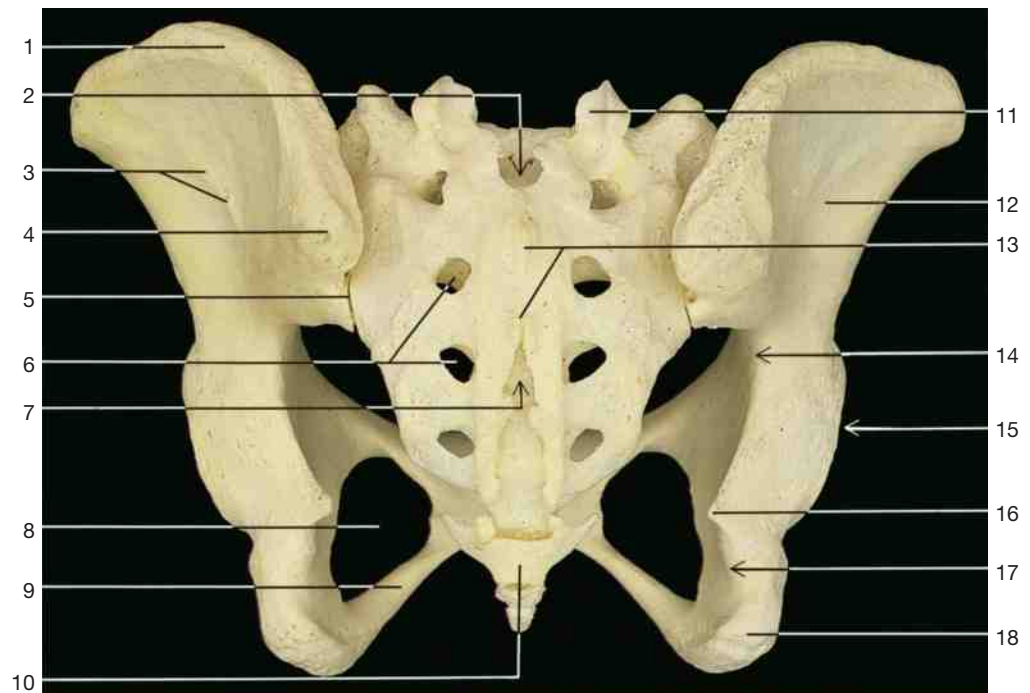


Female pelvis (anterior aspect). Note the differences between the form and dimensions of the male and female pelvis. The female pubic arch is wider than the male. The obturator foramen in the female pelvis is triangular, while that in the male pelvis is ovoid.

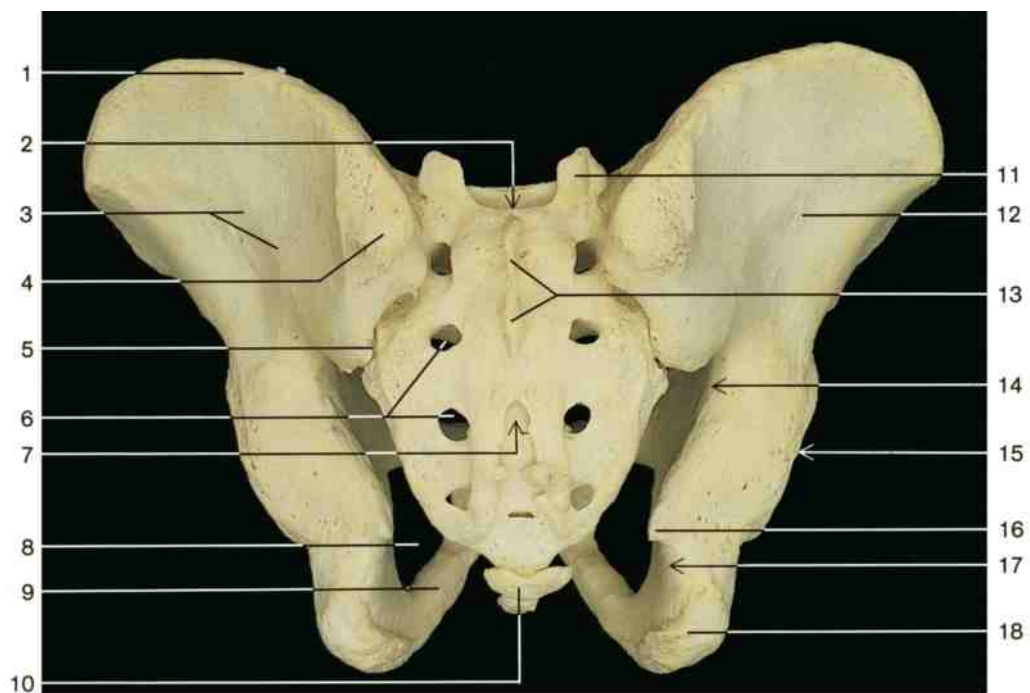


Male pelvis (anterior aspect). Compare with the female pelvis (depicted above).

- | | |
|---------------------------------|--|
| 1 Anterior superior iliac spine | 9 Pubic arch |
| 2 Iliac fossa | 10 Anterior inferior iliac spine |
| 3 Position of sacro-iliac joint | 11 Sacrum |
| 4 Iliopubic eminence | 12 Linea terminalis (at margin of superior aperture) |
| 5 Lunate surface of acetabulum | 13 Pubic symphysis |
| 6 Acetabular notch | 14 Ischial spine |
| 7 Obturator foramen | 15 Coccyx |
| 8 Ischial tuberosity | |

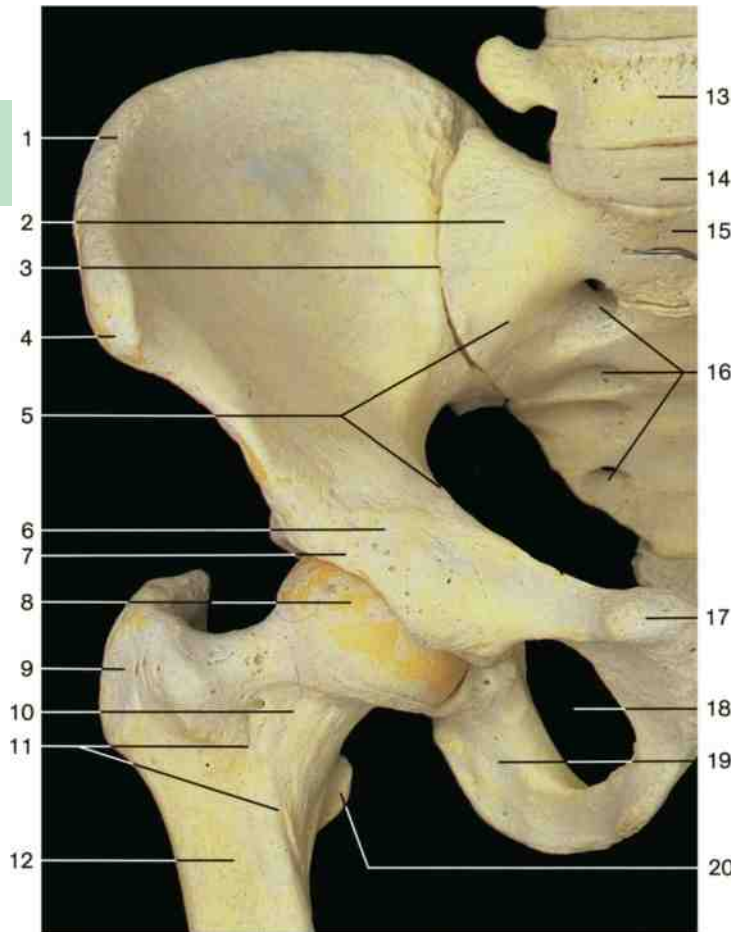


Female pelvis (posterior aspect). Note the differences between the female and male pelvis, especially with respect to the inferior aperture, the shape of the sacrum, the two sciatic notches, and the pubic arch.



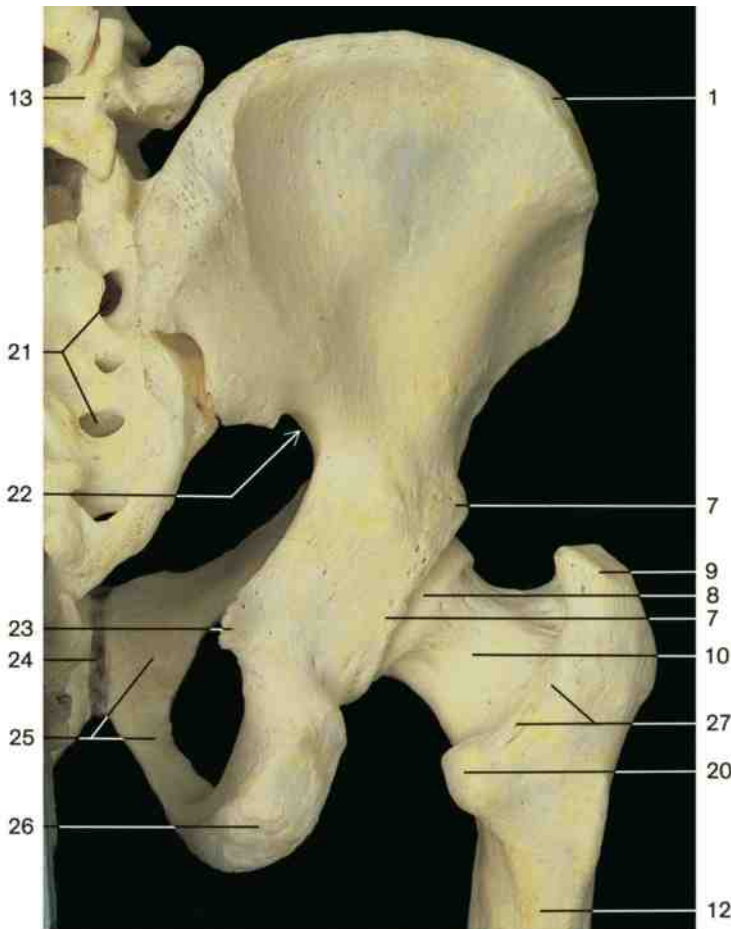
Male pelvis (posterior aspect). Compare with the female pelvis (depicted above).

- | | |
|----------------------------------|---|
| 1 Iliac crest | 10 Coccyx |
| 2 Sacral canal | 11 Superior articular process of sacrum |
| 3 Posterior gluteal line | 12 Gluteal surface of ilium |
| 4 Posterior superior iliac spine | 13 Median sacral crest |
| 5 Position of sacro-iliac joint | 14 Greater sciatic notch |
| 6 Dorsal sacral foramina | 15 Position of acetabulum |
| 7 Sacral hiatus | 16 Ischial spine |
| 8 Obturator foramen | 17 Lesser sciatic notch |
| 9 Ramus of ischium | 18 Ischial tuberosity |



- 1 Iliac crest
- 2 Lateral part of sacrum (ala)
- 3 Position of sacro-iliac joint
- 4 Anterior superior iliac spine
- 5 Linea terminalis
- 6 Iliopubic eminence
- 7 Bony margin of acetabulum
- 8 Head of femur
- 9 Greater trochanter
- 10 Neck of femur
- 11 Intertrochanteric line
- 12 Shaft of femur
- 13 Fifth lumbar vertebra
- 14 Imitation intervertebral disc between fifth lumbar vertebra and sacrum
- 15 Sacral promontory
- 16 Anterior sacral foramina
- 17 Pubic tubercle
- 18 Obturator foramen
- 19 Ramus of ischium
- 20 Lesser trochanter
- 21 Dorsal sacral foramina
- 22 Greater sciatic notch
- 23 Ischial spine
- 24 Pubic symphysis
- 25 Pubis
- 26 Ischial tuberosity
- 27 Intertrochanteric crest
- 28 Symphyseal surface

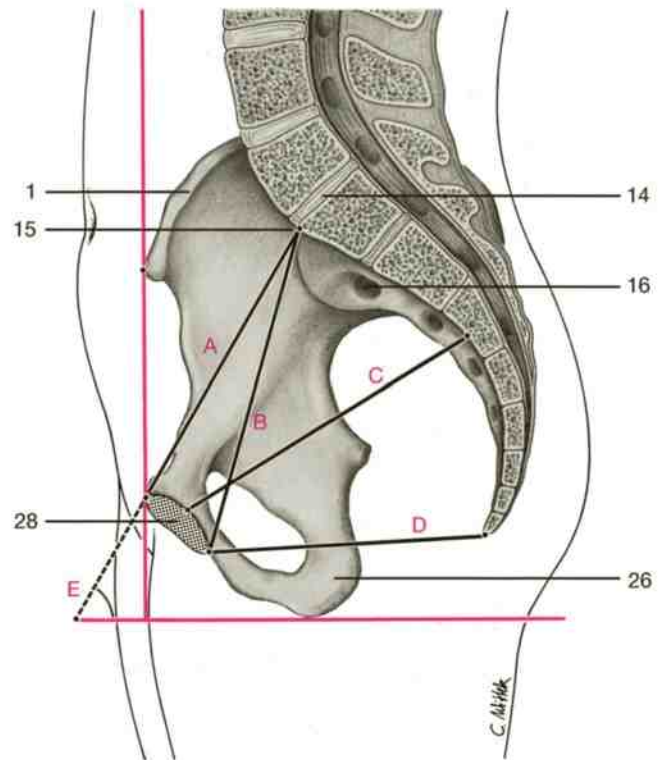
Bones of right hip joint (anterior aspect).



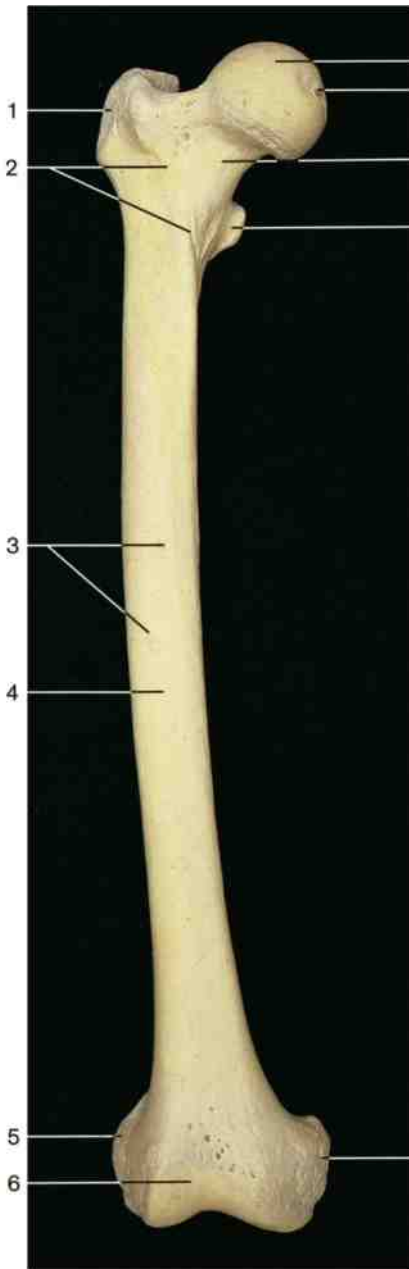
Bones of right hip joint (posterior aspect).

Diameters of the pelvis

- A = true conjugate (11–11.5 cm) (conjugata vera)
- B = diagonal conjugate (12.5–13 cm)
- C = largest diameter of pelvis
- D = inferior pelvic aperture
- E = pelvic inclination (60°)

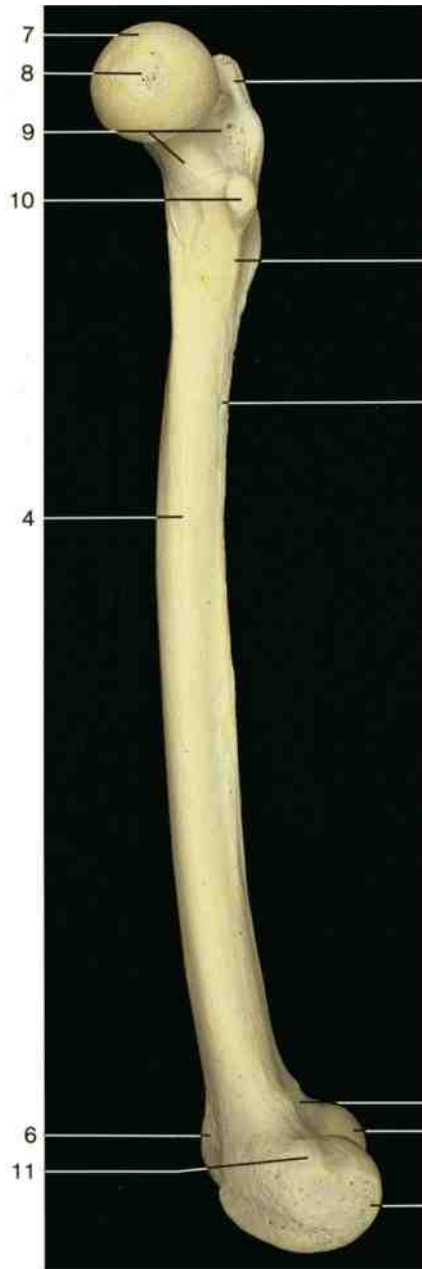


Inclination and diameters of the female pelvis, right half (medial aspect).



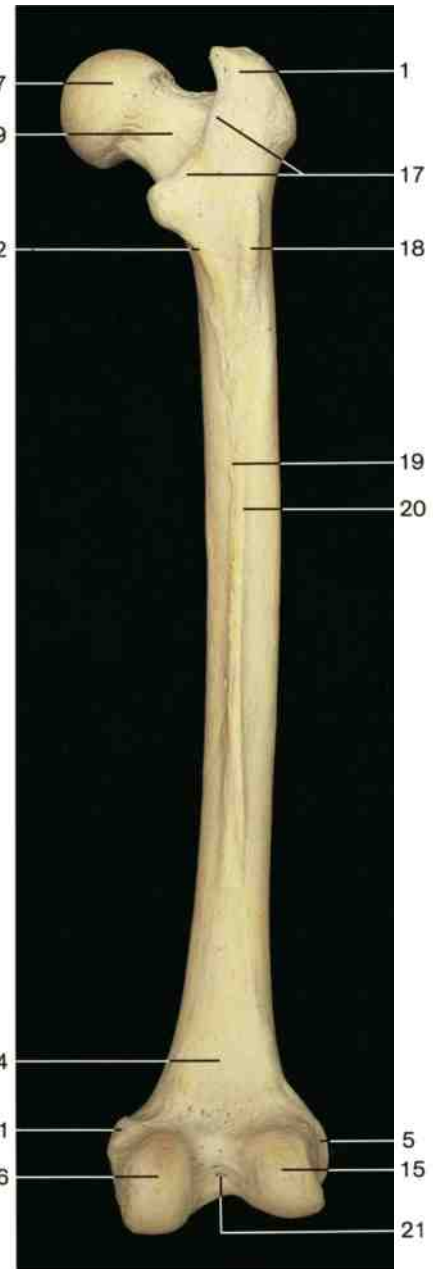
Right femur (anterior aspect).

- 1 Greater trochanter
- 2 Intertrochanteric line
- 3 Nutrient foramina
- 4 Shaft of femur (diaphysis)
- 5 Lateral epicondyle
- 6 Patellar surface



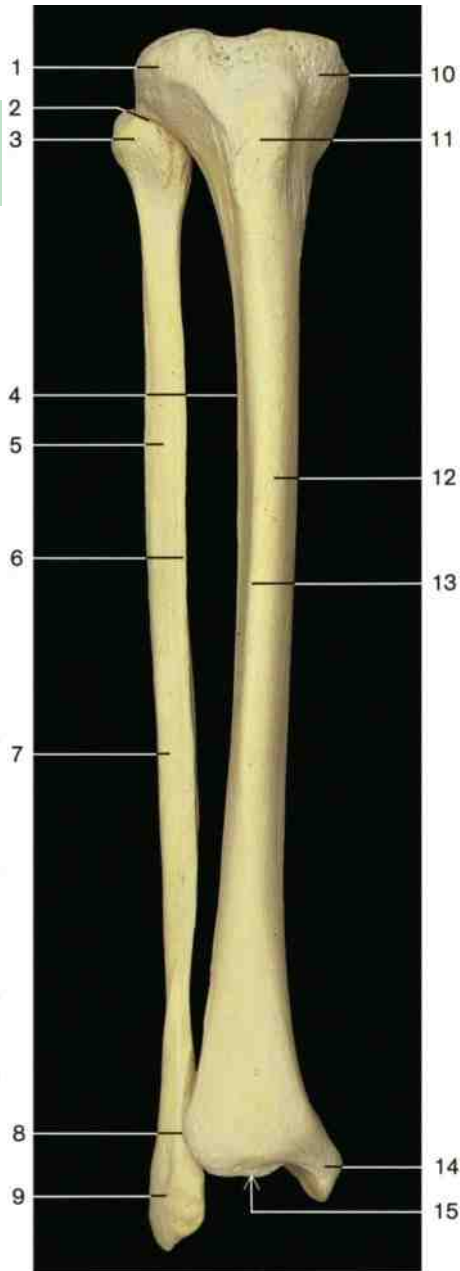
Right femur (medial aspect).

- 7 Fovea of head
- 8 Fovea of head
- 9 Neck
- 10 Lesser trochanter
- 11 Medial epicondyle

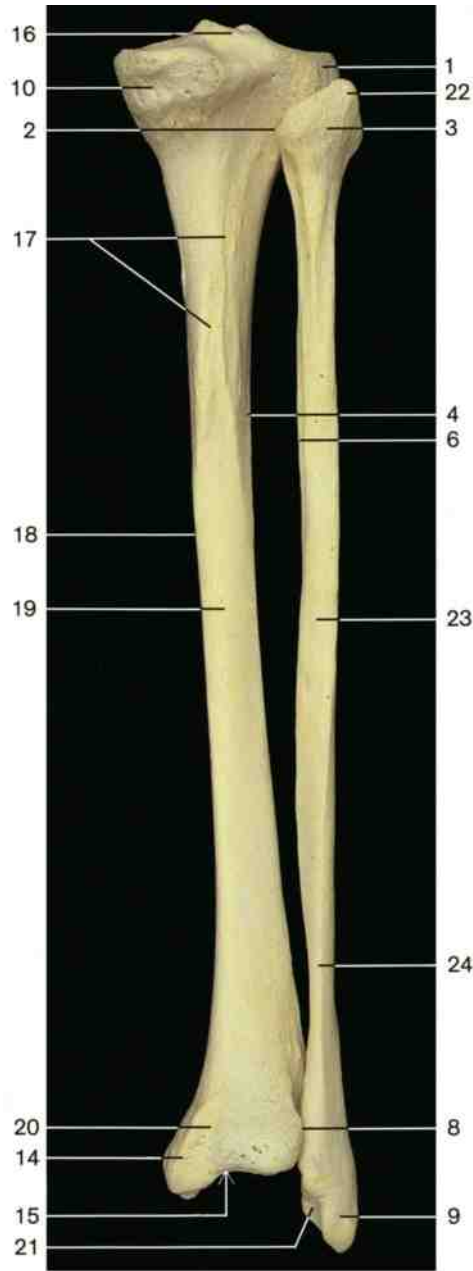


Right femur (posterior aspect).

- 12 Pectineal line
- 13 Linea aspera
- 14 Lateral condyle
- 15 Lateral condyle
- 16 Medial condyle
- 17 Intertrochanteric crest
- 18 Third trochanter
- 19 Medial lip of linea aspera
- 20 Lateral lip of linea aspera
- 21 Intercondylar fossa

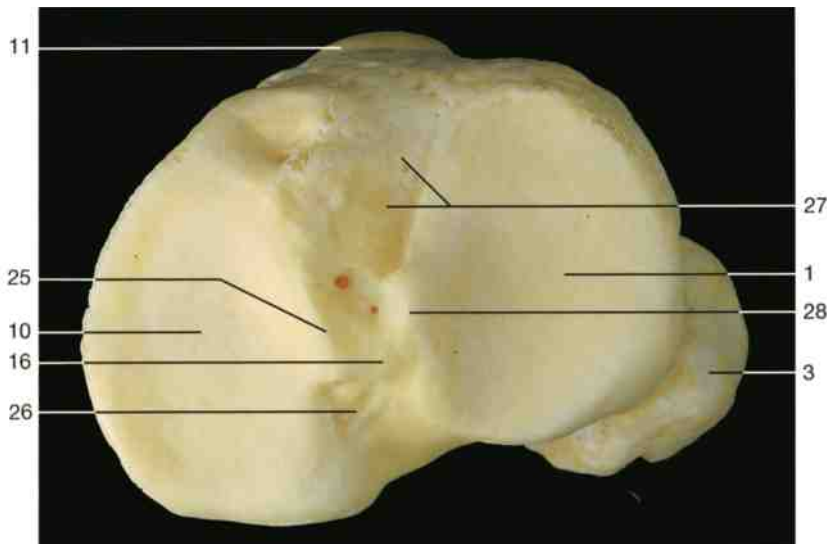


Bones of leg, right tibia, and fibula (anterior aspect).

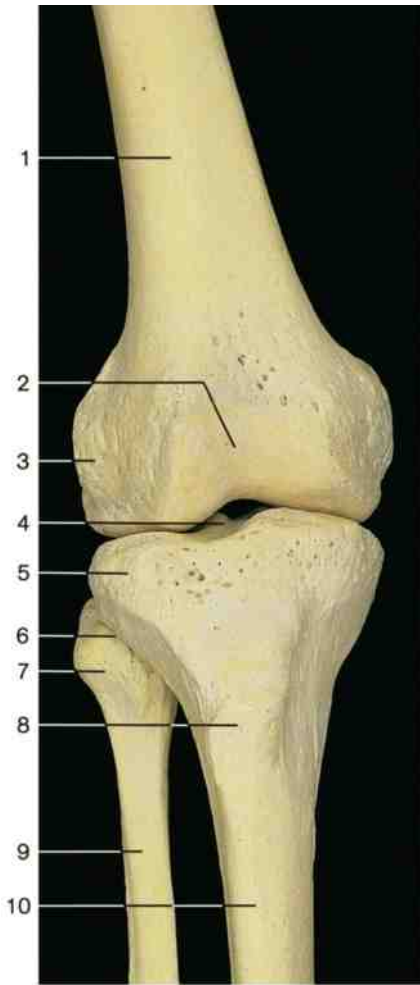


Bones of leg, right tibia, and fibula (posterior aspect).

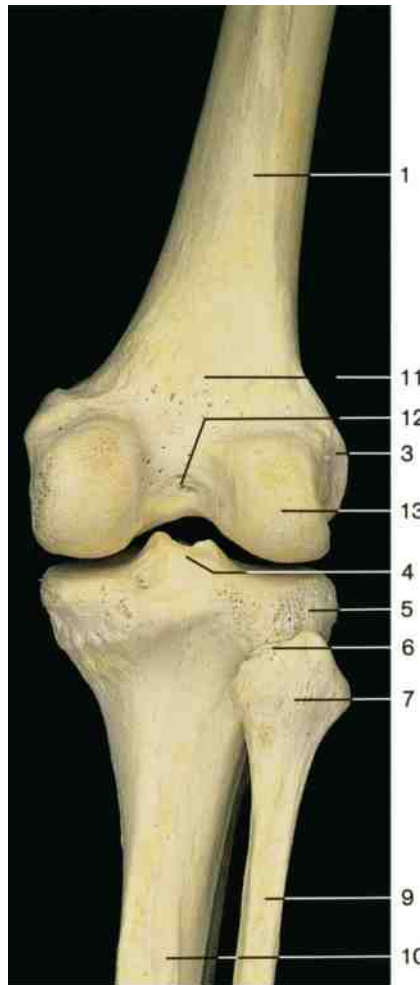
- 1 Lateral condyle of tibia
- 2 Position of tibiofibular joint
- 3 Head of fibula
- 4 Interosseous border of tibia
- 5 Shaft of fibula
- 6 Interosseous border of fibula
- 7 Lateral surface of fibula
- 8 Position of tibiofibular joint
- 9 Lateral malleolus
- 10 Medial condyle of tibia
- 11 Tuberosity of tibia
- 12 Shaft of tibia (diaphysis)
- 13 Anterior margin of tibia
- 14 Medial malleolus
- 15 Inferior articular surface of tibia
- 16 Intercondylar eminence
- 17 Soleal line
- 18 Medial border of tibia
- 19 Posterior surface of tibia
- 20 Malleolar sulcus of tibia
- 21 Malleolar articular surface of fibula
- 22 Apex of head of fibula
- 23 Posterior surface of fibula
- 24 Posterior border of fibula
- 25 Medial intercondylar tubercle
- 26 Posterior intercondylar area
- 27 Anterior intercondylar area
- 28 Lateral intercondylar tubercle



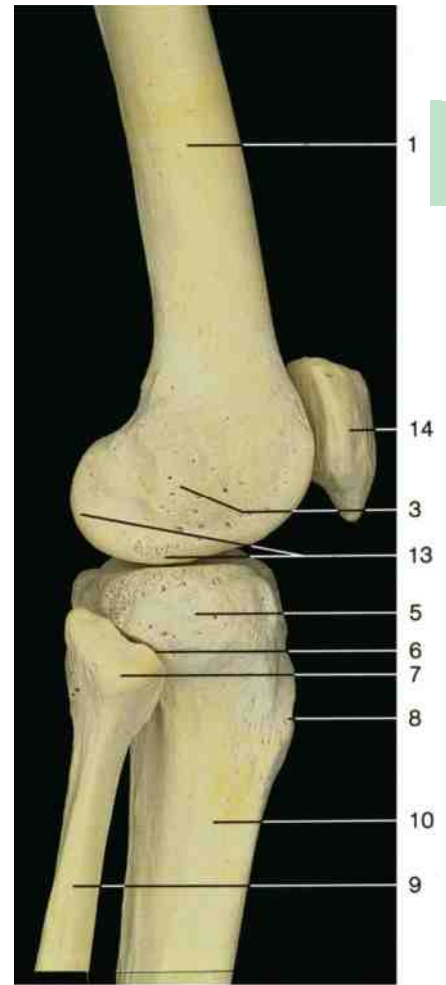
Upper end of right tibia with fibula (from above), anterior margin of tibia above. Superior articular surface of tibia.



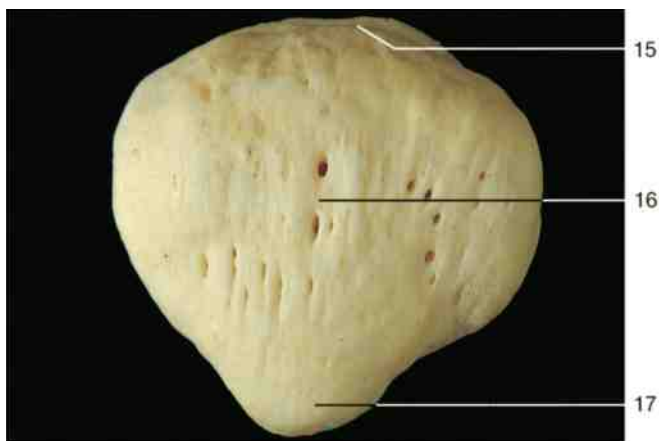
Bones of right knee joint
(anterior aspect).




Bones of right knee joint
(posterior aspect).



Bones of right knee joint
(lateral aspect).



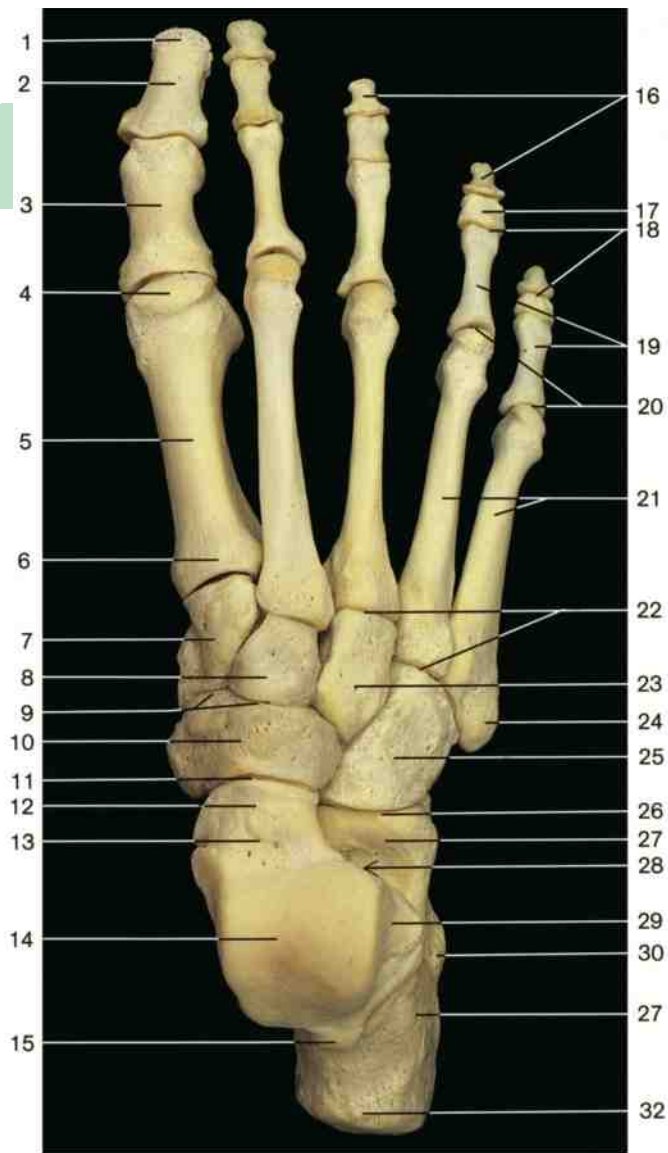
Right patella (anterior aspect).



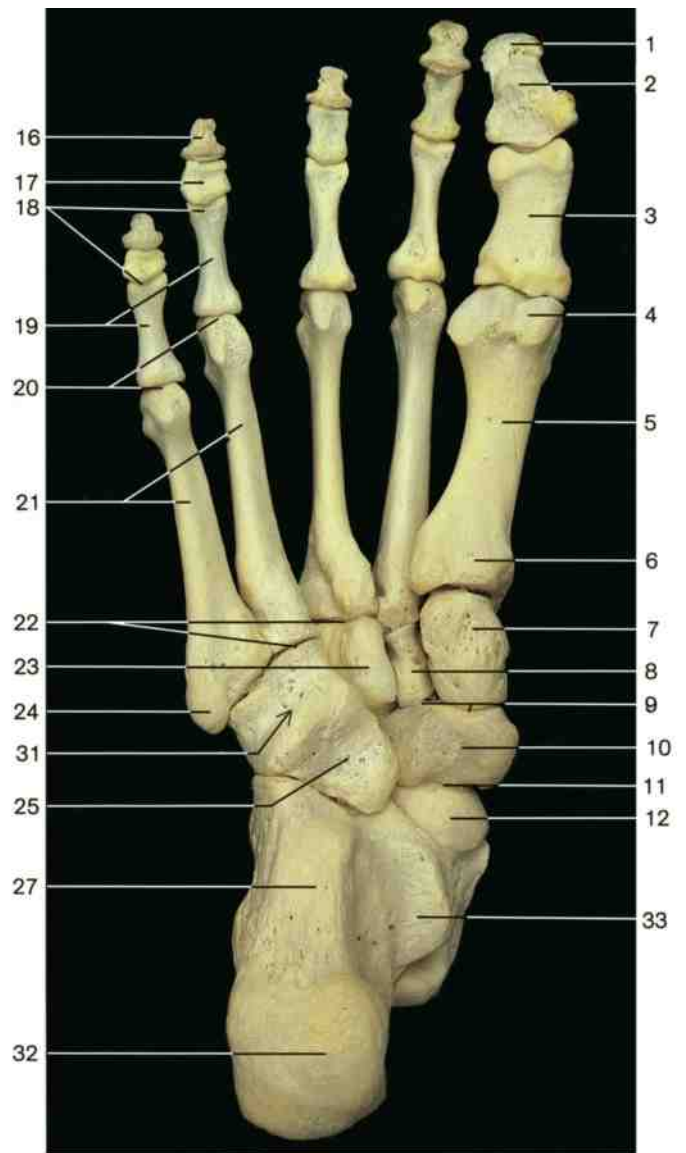
Right patella (posterior aspect).

- 1 Femur
- 2 Patellar surface of femur
- 3 Lateral epicondyle of femur
- 4 Intercondylar eminence of tibia
- 5 Lateral condyle of tibia
- 6 Position of tibiofibular joint
- 7 Head of fibula
- 8 Tuberosity of tibia
- 9 Fibula

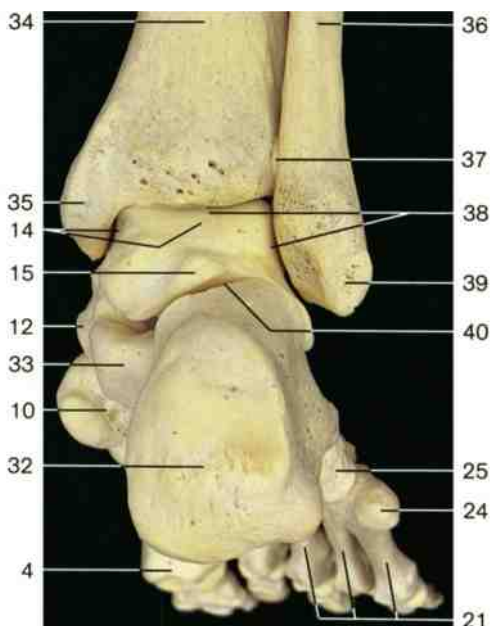
- 10 Shaft of tibia
- 11 Popliteal surface of femur
- 12 Intercondylar fossa of femur
- 13 Lateral condyle of femur
- 14 Patella
- 15 Base of patella
- 16 Anterior surface of patella
- 17 Apex of patella
- 18 Articular surface of patella



Bones of right foot (dorsal aspect).

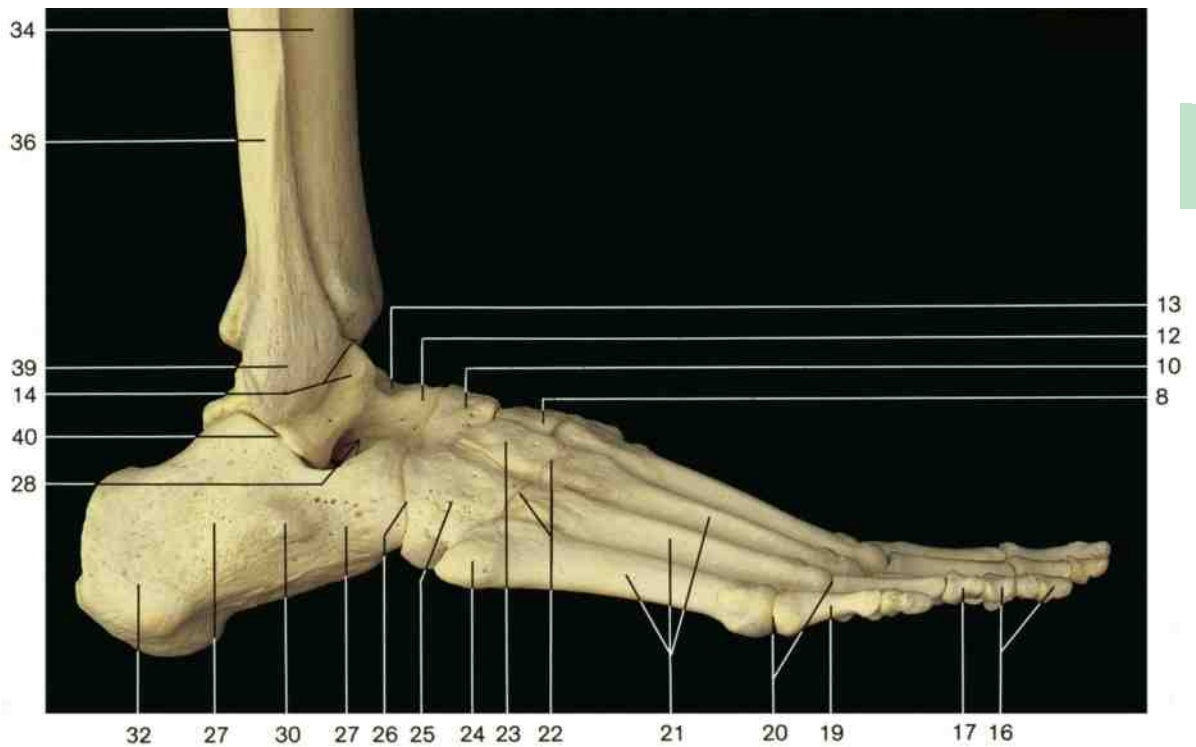


Bones of right foot (plantar aspect).

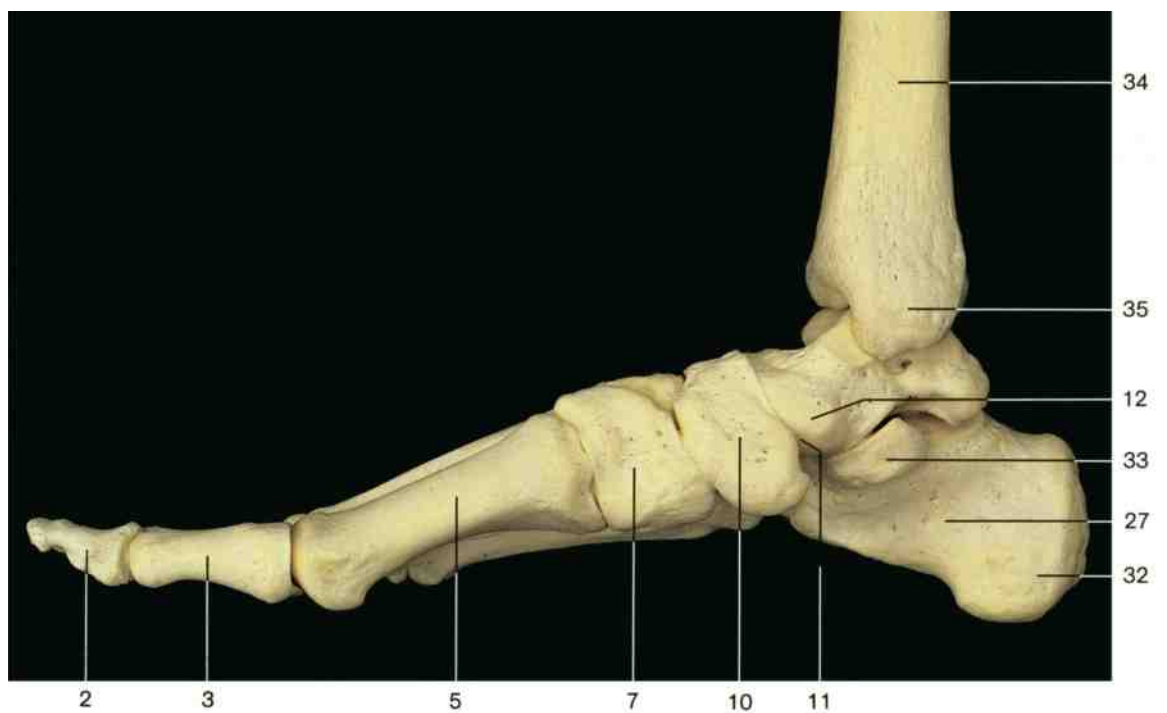


Bones of right foot together with tibia and fibula (posterior aspect).

- 1 Tuberosity of distal phalanx of great toe
- 2 Distal phalanx of great toe
- 3 Proximal phalanx of great toe
- 4 Head of first metatarsal bone
- 5 First metatarsal bone
- 6 Base of first metatarsal bone
- 7 Medial cuneiform bone
- 8 Intermediate cuneiform bone
- 9 Position of cuneonavicular joint
- 10 Navicular bone

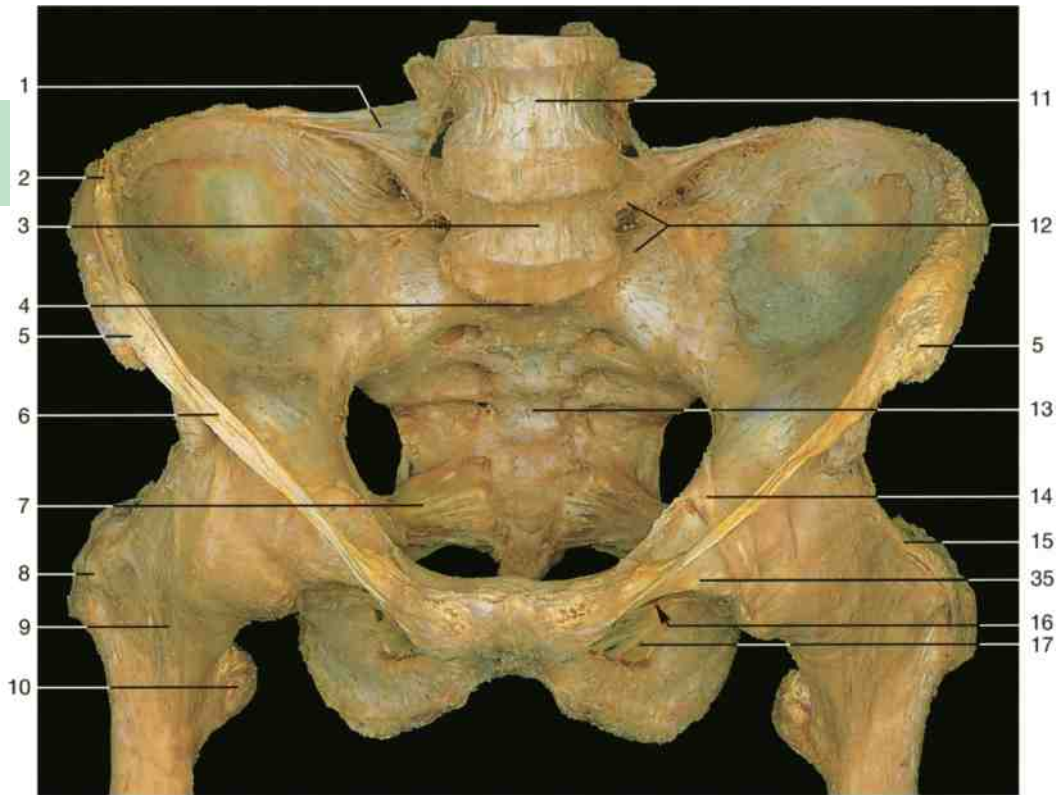


Bones of right foot, tibia, and fibula (lateral aspect).



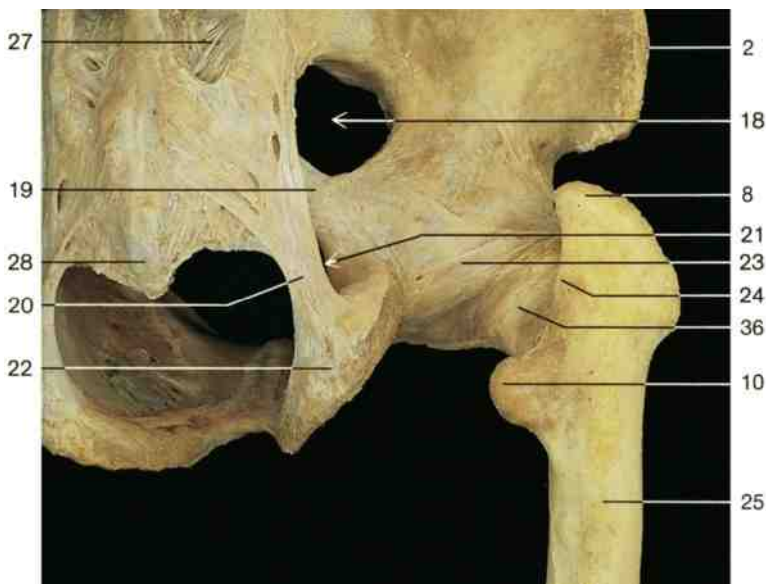
Bones of right foot, tibia, and fibula (medial aspect).

- | | | |
|--|--|---|
| 11 Position of talocalcaneonavicular joint | 21 Metatarsal bones | 31 Groove for tendon of peroneus longus |
| 12 Head of talus | 22 Position of tarsometatarsal joints | 32 Calcaneal tuberosity |
| 13 Neck of talus | 23 Lateral cuneiform bone | 33 Sustentaculum tali |
| 14 Trochlea of talus | 24 Tuberosity of fifth metatarsal bone | 34 Tibia |
| 15 Posterior talar process | 25 Cuboid bone | 35 Medial malleolus |
| 16 Distal phalanges | 26 Position of calcaneocuboid joint | 36 Fibula |
| 17 Middle phalanges | 27 Calcaneus | 37 Position of tibiofibular syndesmosis |
| 18 Position of interphalangeal joints | 28 Tarsal sinus | 38 Position of ankle joint |
| 19 Proximal phalanges | 29 Lateral malleolar surface of talus | 39 Lateral malleolus |
| 20 Position of metatarsophalangeal joints | 30 Peroneal trochlea of calcaneus | 40 Position of subtalar joint |

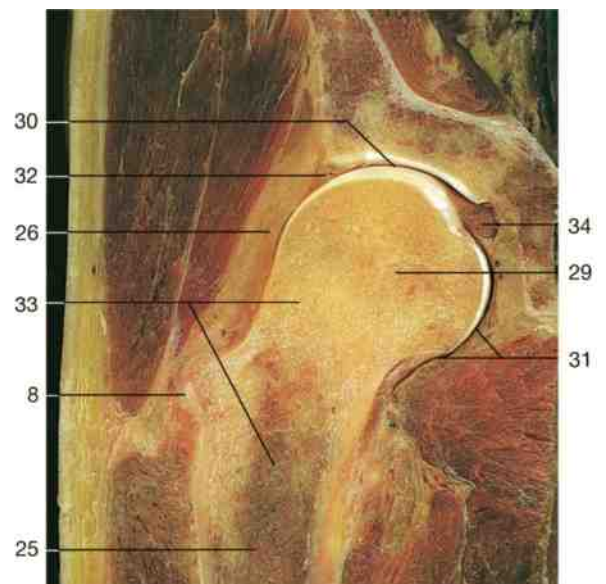


Ligaments of pelvis and hip joint (anterior aspect).

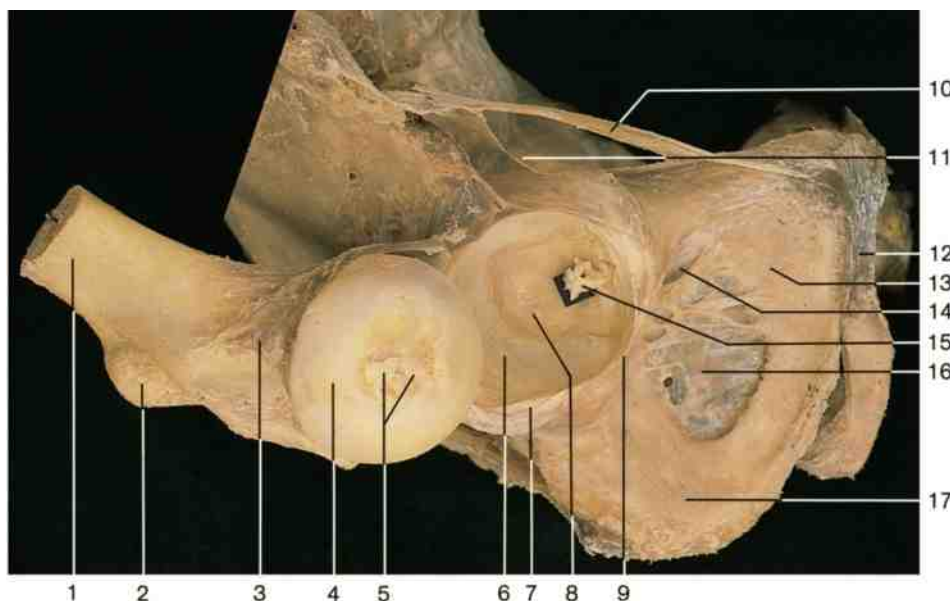
- | | | |
|---|---|---|
| 1 Iliolumbar ligament | 13 Sacrum | 26 Articular capsule of hip joint |
| 2 Iliac crest | 14 Ilipectineal arch | 27 Dorsal sacro-iliac ligaments |
| 3 Fifth lumbar vertebra | 15 Iliofemoral ligament (horizontal band) | 28 Coccyx with superficial dorsal sacrococcygeal ligament |
| 4 Sacral promontory | 16 Obturator canal | 29 Head of femur |
| 5 Anterior superior iliac spine | 17 Obturator membrane | 30 Articular cartilage of head of femur |
| 6 Inguinal ligament | 18 Greater sciatic foramen | 31 Articular cavity of hip joint |
| 7 Sacrospinous ligament | 19 Sacrospinous ligament | 32 Acetabular lip |
| 8 Greater trochanter | 20 Sacrotuberous ligament | 33 Spongy bone |
| 9 Iliofemoral ligament (vertical band) | 21 Lesser sciatic foramen | 34 Ligament of head of femur |
| 10 Lesser trochanter | 22 Ischial tuberosity | 35 Pubofemoral ligament |
| 11 Fourth lumbar vertebra | 23 Ischiofemoral ligament | 36 Zona orbicularis |
| 12 Iliolumbar and ventral sacro-iliac ligaments | 24 Intertrochanteric crest | |
| | 25 Femur | |



Ligaments of pelvis and hip joint (right posterior aspect).

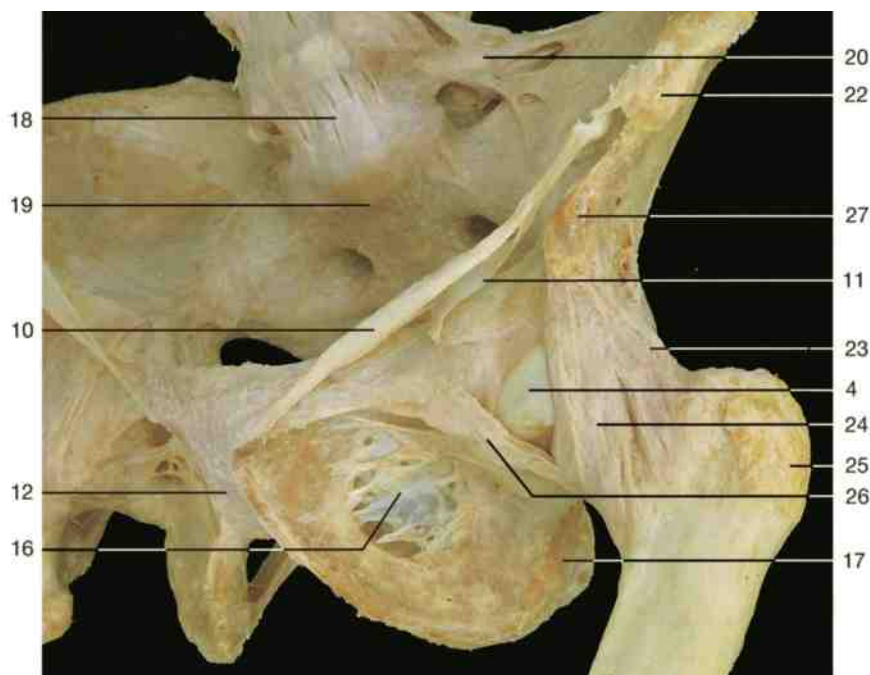


Coronal section of right hip joint (anterior aspect).

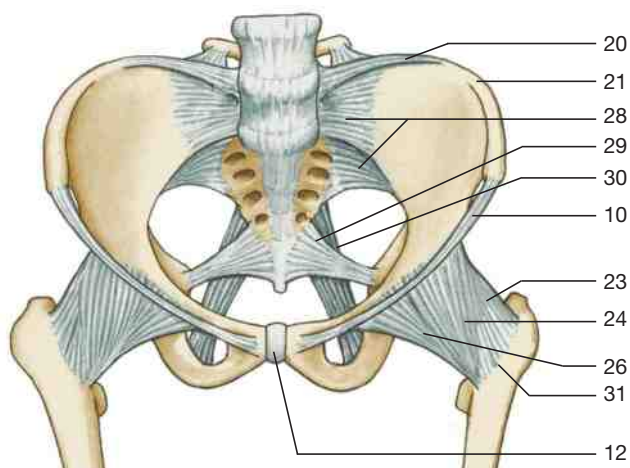


Right hip joint, opened (latero-anterior aspect). The ligament of the head of the femur has been divided, and the femur has been posteriorly reflected.

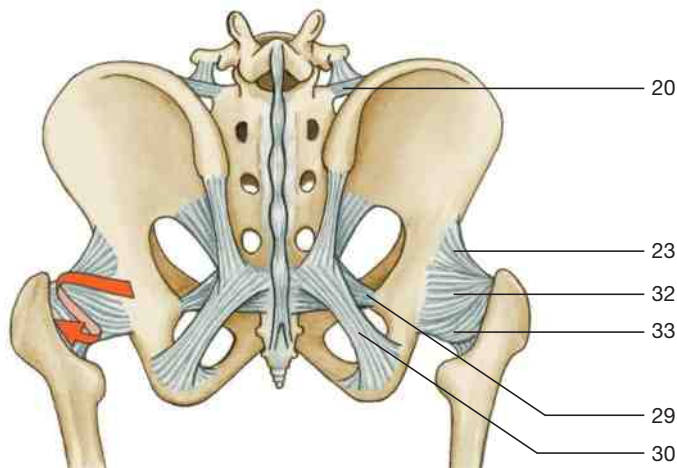
- 1 Femur
- 2 Lesser trochanter
- 3 Neck of femur
- 4 Head of femur
- 5 Fovea of head with cut edge of ligament of head
- 6 Lunate surface of acetabulum
- 7 Acetabular lip
- 8 Acetabular fossa
- 9 Transverse acetabular ligament
- 10 Inguinal ligament
- 11 Iliopectineal arch
- 12 Pubic symphysis
- 13 Pubic bone
- 14 Obturator canal
- 15 Ligament of head of femur
- 16 Obturator membrane
- 17 Ischium
- 18 Anterior longitudinal ligament (level of fifth lumbar vertebra)
- 19 Sacral promontory
- 20 Iliolumbar ligament
- 21 Iliac crest
- 22 Anterior superior iliac spine
- 23 Iliofemoral ligament (horizontal band)
- 24 Iliofemoral ligament (vertical band)
- 25 Greater trochanter
- 26 Pubofemoral ligament
- 27 Anterior inferior iliac spine
- 28 Ventral sacro-iliac ligaments
- 29 Sacrospinous ligament
- 30 Sacrotuberous ligament
- 31 Intertrochanteric line
- 32 Ischiofemoral ligament
- 33 Zona orbicularis



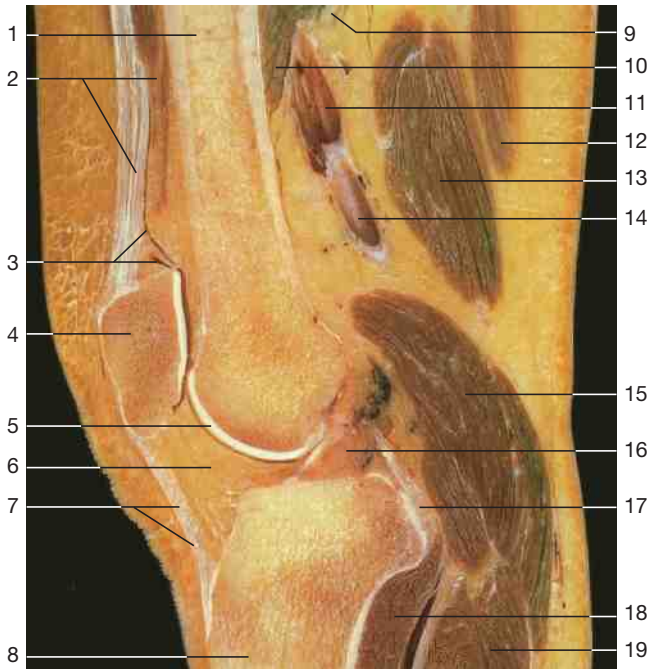
◁ Ligaments of the pelvis and hip joint (antero-lateral aspect).



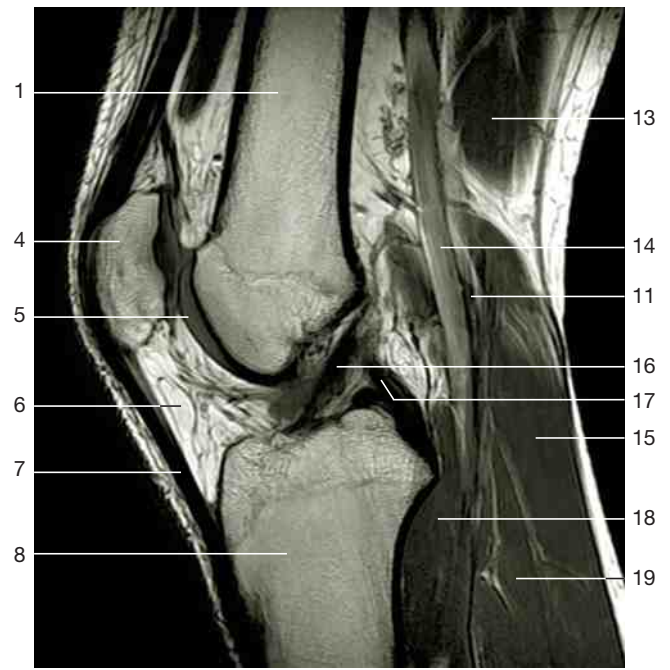
Ligaments of hip joint (anterior aspect, schematic drawing).



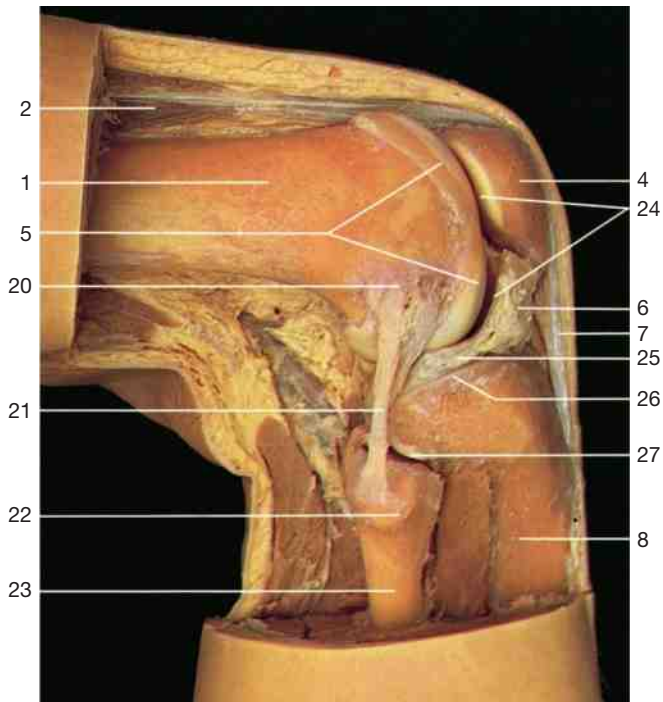
Ligaments of hip joint (posterior aspect, schematic drawing).



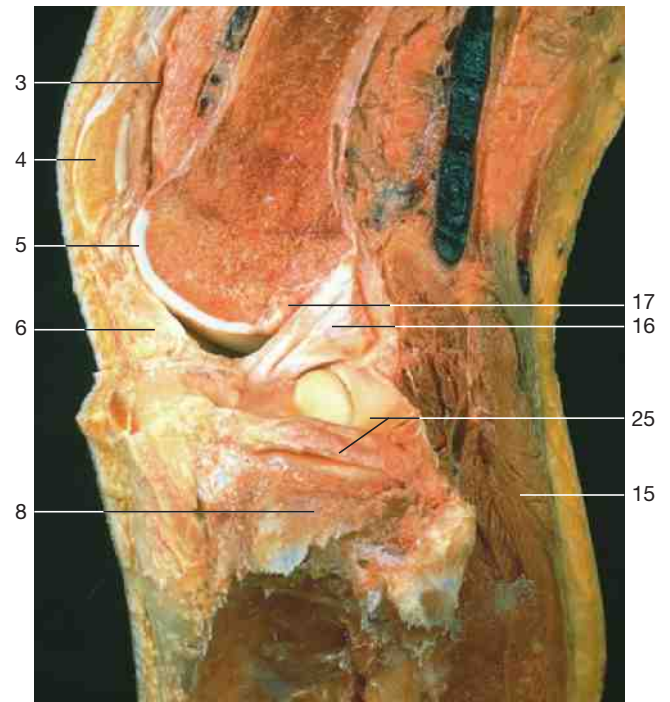
Sagittal section through the knee joint (lateral aspect).
Anterior surface to the left.



Sagittal section through the knee joint (MRI scan;
from Heuck et al., MRT-Atlas, 2009).



Right knee joint and tibiofibular joint with ligaments
(lateral aspect). Note the position of the lateral meniscus.

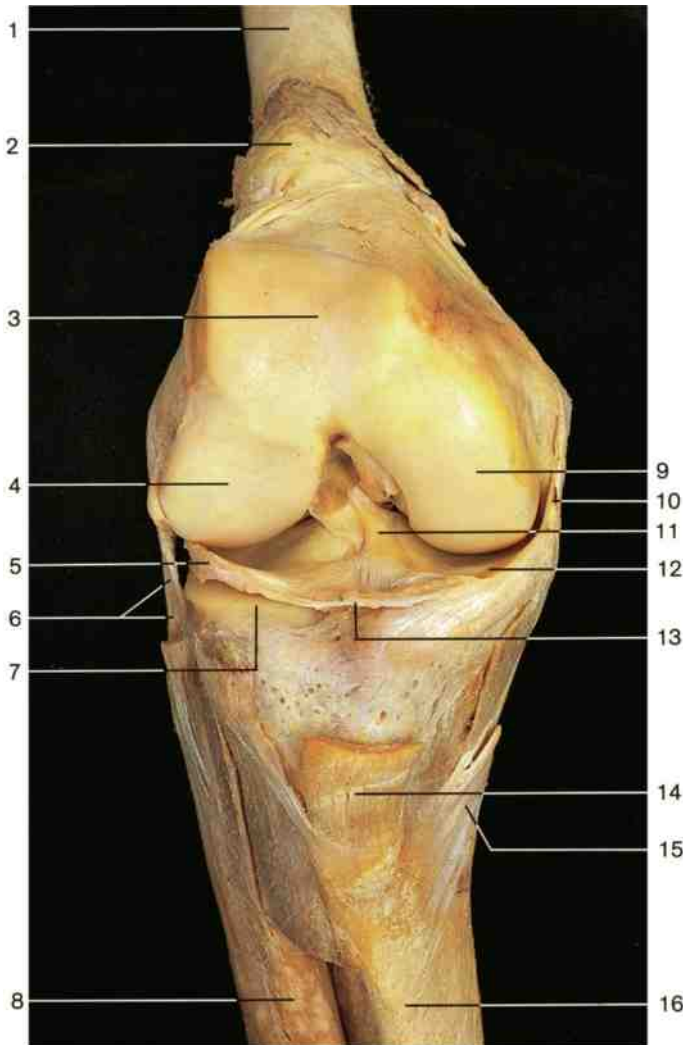


Left knee joint with anterior cruciate ligament (lateral aspect).

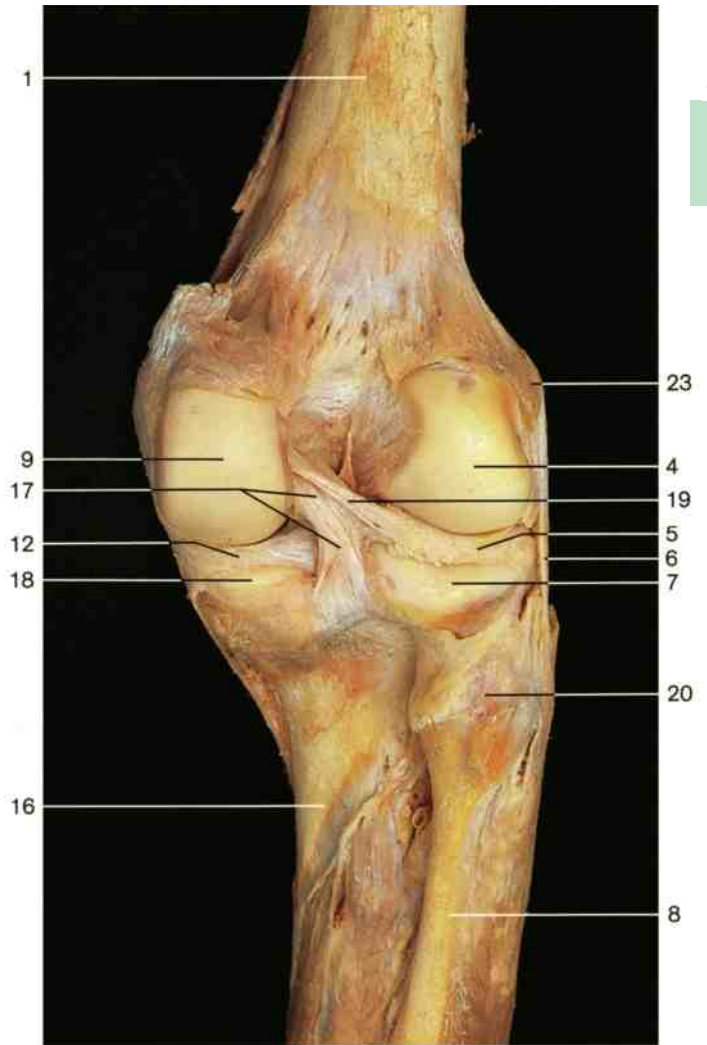
- 1 Femur
- 2 Quadriceps femoris muscle
- 3 Suprapatellar bursa and articular cavity
- 4 Patella
- 5 Articular cartilage of femur
- 6 Infrapatellar fat pad
- 7 Patellar ligament
- 8 Tibia
- 9 Tibial nerve

- 10 Adductor magnus muscle
- 11 Popliteal vein
- 12 Semitendinosus muscle
- 13 Semimembranosus muscle
- 14 Popliteal artery
- 15 Gastrocnemius muscle
- 16 Anterior cruciate ligament
- 17 Posterior cruciate ligament
- 18 Popliteus muscle

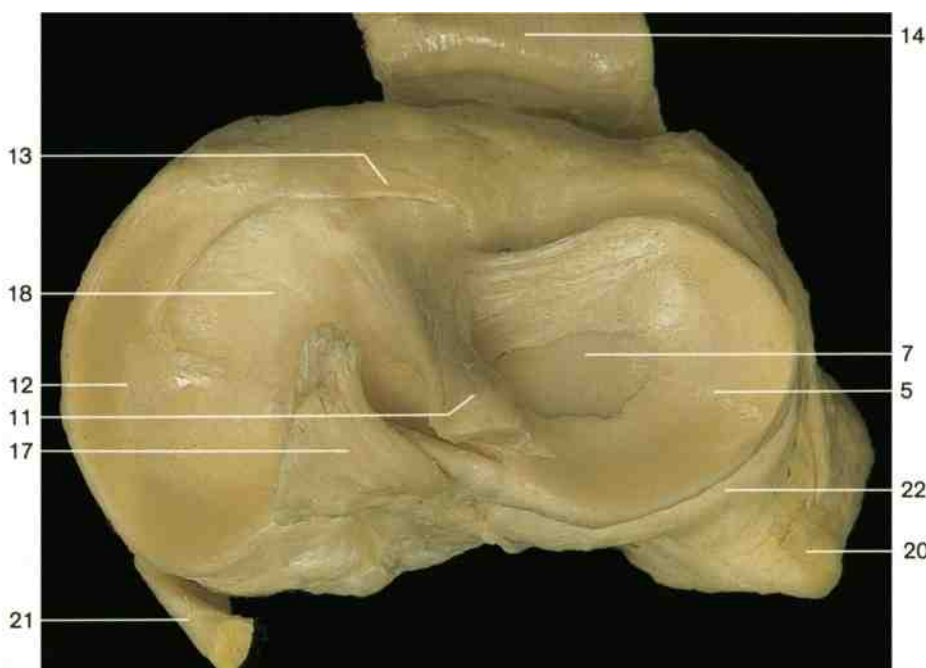
- 19 Soleus muscle
- 20 Lateral epicondyle of femur
- 21 Fibular collateral ligament
- 22 Head of fibula
- 23 Fibula
- 24 Articular cavity of knee joint
- 25 Lateral meniscus of knee joint
- 26 Lateral condyle of tibia
- 27 Tibiofibular joint



Right knee joint (opened) with ligaments (anterior aspect). The patella and articular capsule have been removed and the femur slightly flexed.

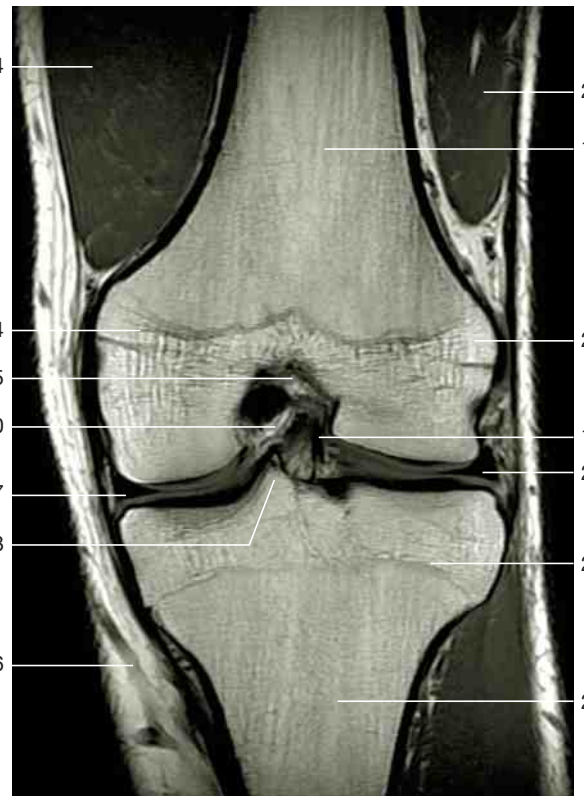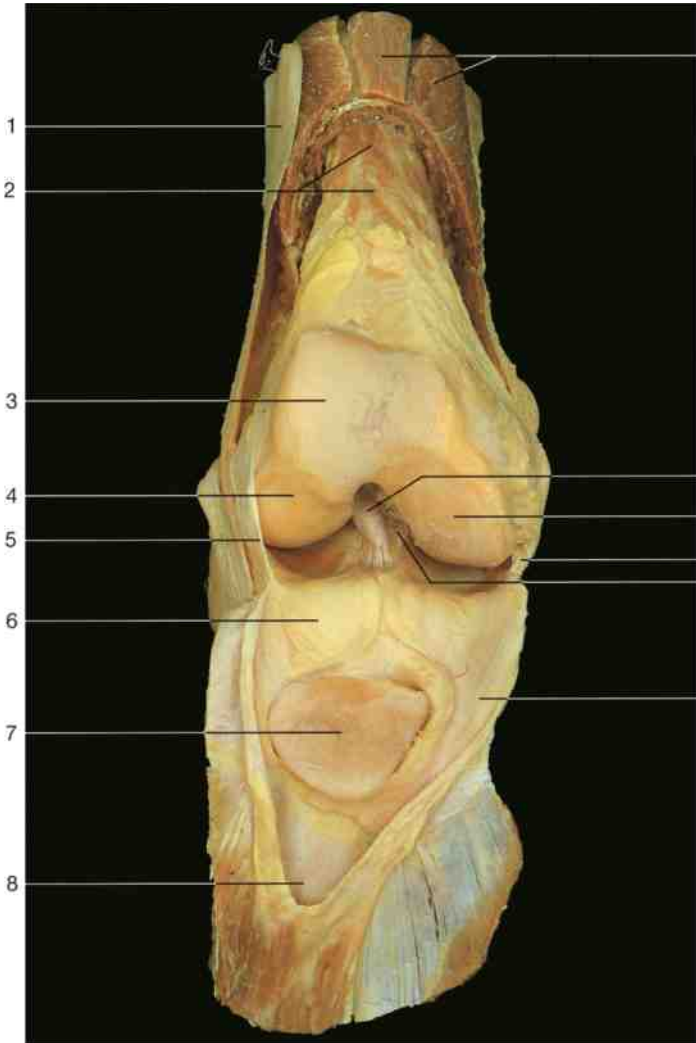


Right knee joint with ligaments (posterior aspect). The joint is extended and the articular capsule has been removed.



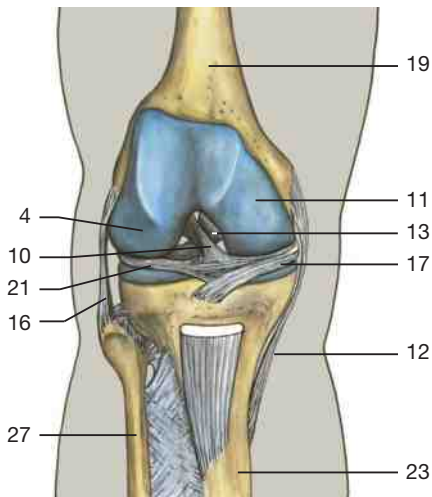
Articular surface of right tibia, menisci, and cruciate ligaments (superior aspect). Anterior margin of tibia above.

- 1 Femur
- 2 Articular capsule with suprapatellar bursa
- 3 Patellar surface
- 4 Lateral condyle of femur
- 5 Lateral meniscus of knee joint
- 6 Fibular collateral ligament
- 7 Lateral condyle of tibia (superior articular surface)
- 8 Fibula
- 9 Medial condyle of femur
- 10 Tibial collateral ligament
- 11 Anterior cruciate ligament
- 12 Medial meniscus of knee joint
- 13 Transverse ligament of knee
- 14 Patellar ligament
- 15 Common tendon of sartorius, semitendinosus, and gracilis muscles
- 16 Tibia
- 17 Posterior cruciate ligament
- 18 Medial condyle of tibia (superior articular surface)
- 19 Posterior meniscofemoral ligament
- 20 Head of fibula
- 21 Tendon of semimembranosus muscle
- 22 Posterior attachment of articular capsule of knee joint
- 23 Lateral epicondyle of femur

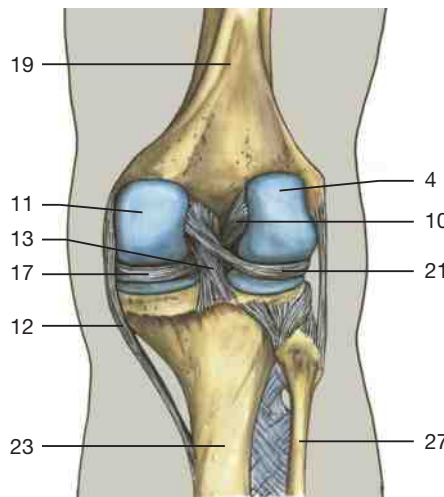


Coronal section through the knee joint (MRI scan; from Heuck et al., MRT-Atlas, 2009).

Right knee joint, opened (anterior aspect). Patellar ligament with patella reflected.

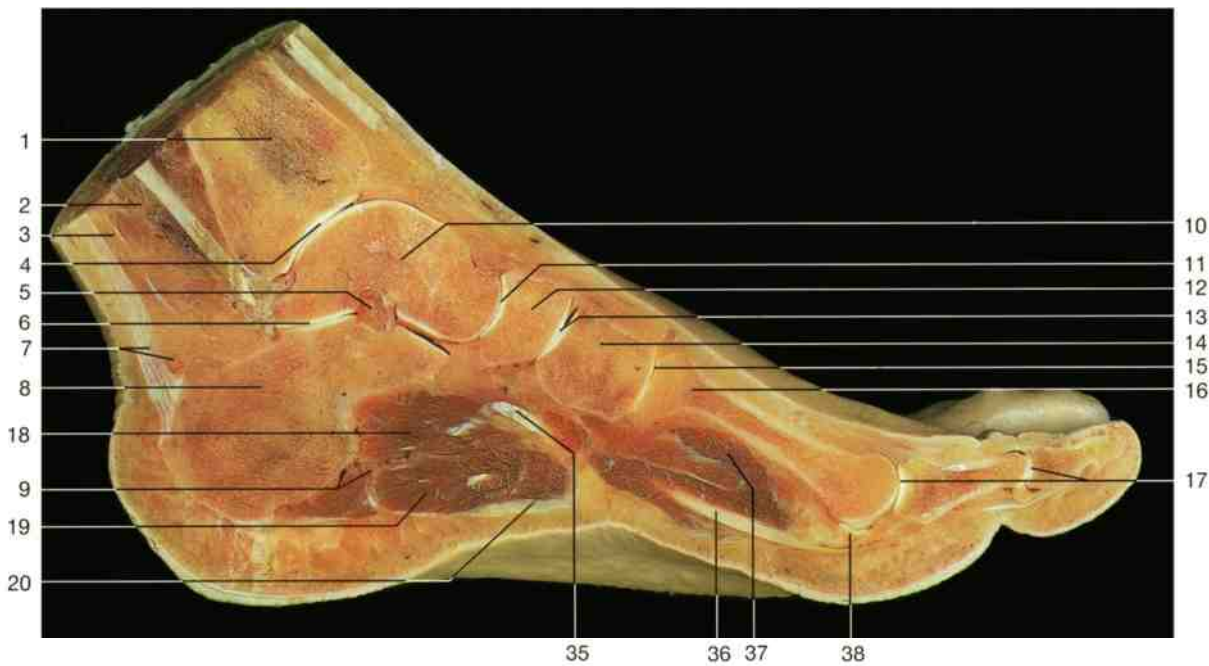


Ligaments of the right knee joint (anterior aspect).

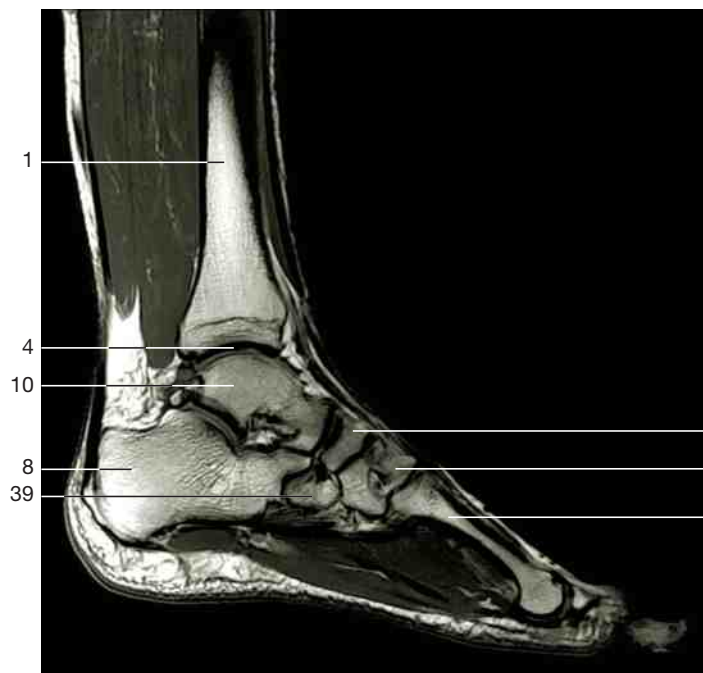


Ligaments of the right knee joint (posterior aspect).

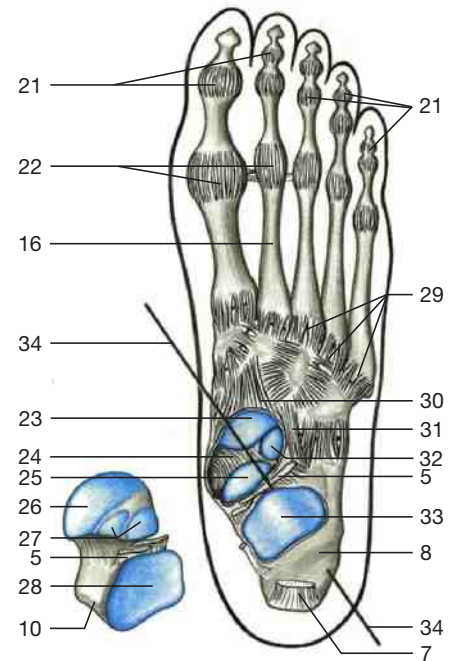
- 1 Iliotibial tract
- 2 Articular muscle of knee
- 3 Patellar surface
- 4 Lateral condyle of femur
- 5 Articular capsule
- 6 Infrapatellar fat pad
- 7 Patella (articular surface)
- 8 Suprapatellar bursa
- 9 Quadriceps femoris muscle
- 10 Anterior cruciate ligament
- 11 Medial condyle of femur
- 12 Tibial collateral ligament
- 13 Posterior cruciate ligament
- 14 Medial epicondyle of femur
- 15 Intercondylar fossa of femur
- 16 Fibular collateral ligament
- 17 Medial meniscus of knee joint
- 18 Medial intercondylar tubercle
- 19 Femur
- 20 Lateral epicondyle of femur
- 21 Lateral meniscus of knee joint
- 22 Epiphysial line of tibia
- 23 Tibia
- 24 Vastus medialis muscle
- 25 Vastus lateralis muscle
- 26 Great saphenous vein
- 27 Fibula



Sagittal section through the foot at the level of first phalanx.

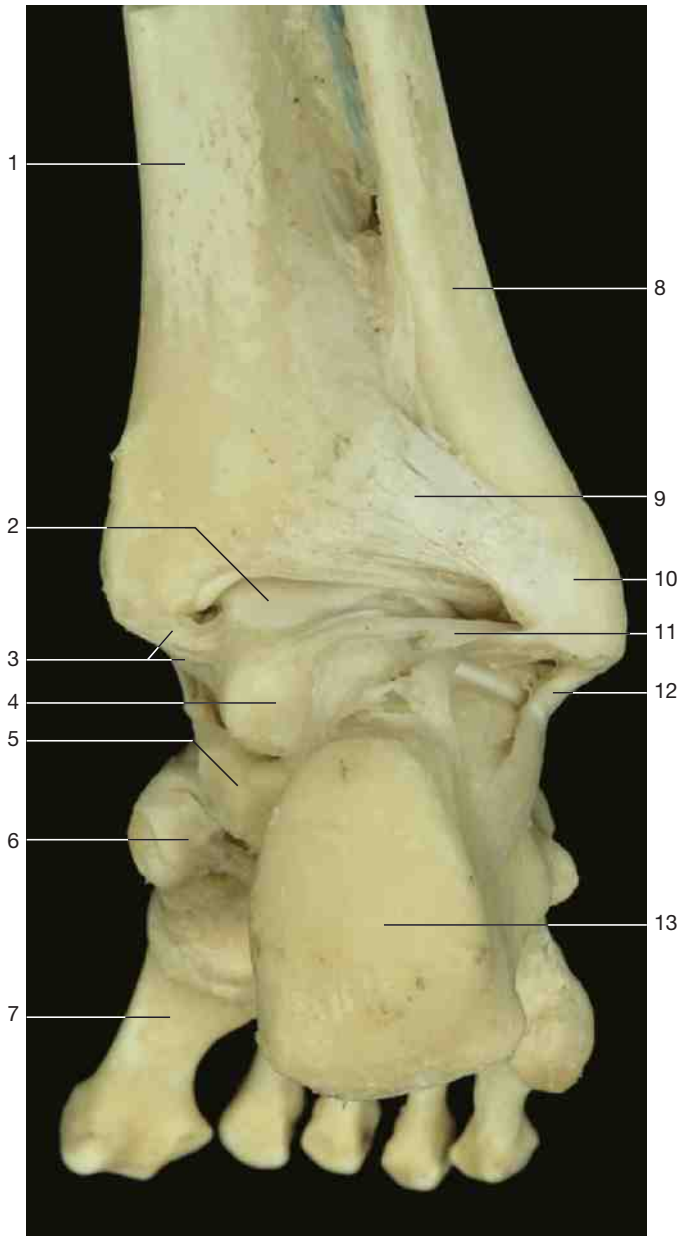


Sagittal section through the foot and leg (MRI scan; from Heuck et al., MRT-Atlas, 2009).

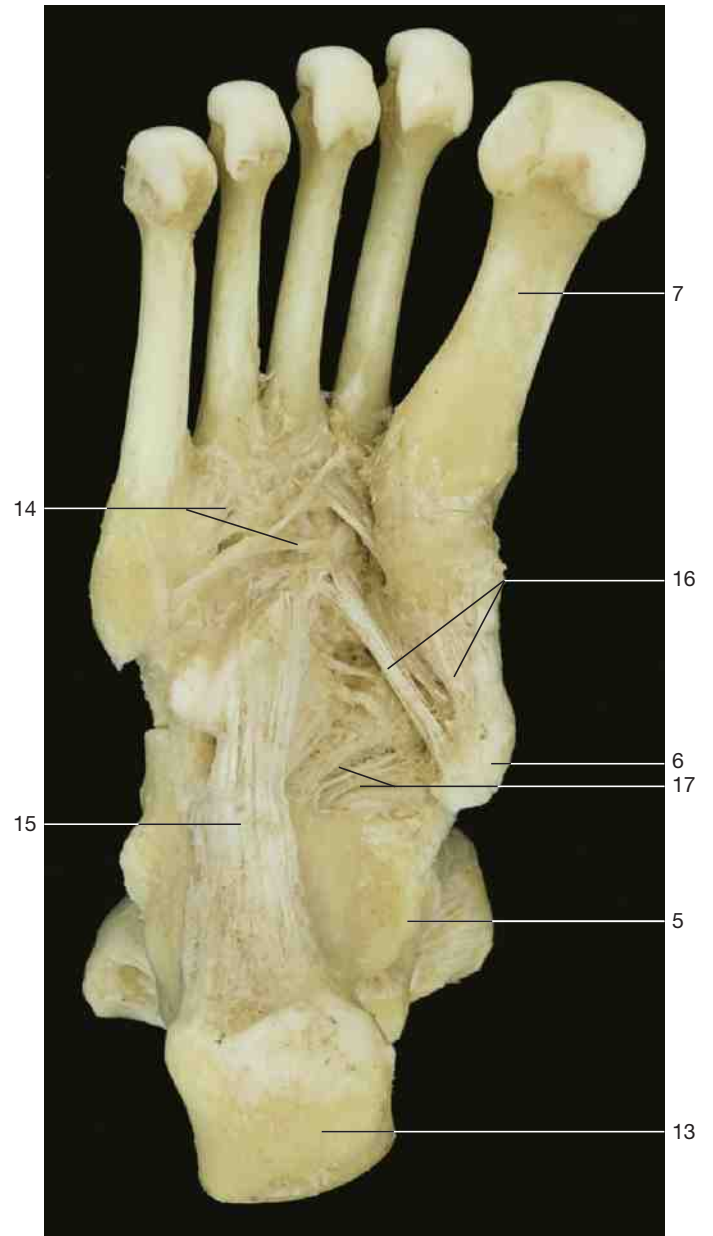


Talocalcaneonavicular joint. The talus has been rotated to show the articular surfaces of the joint.

- | | | |
|--|---|--|
| 1 Tibia | 16 Metatarsal bones | 27 Anterior and middle calcaneal surfaces of talus |
| 2 Deep flexor muscles | 17 Metatarsophalangeal and interphalangeal joints | 28 Posterior calcaneal surface of talus |
| 3 Superficial flexor muscles | 18 Quadratus plantae muscle with flexor tendons | 29 Dorsal tarsometatarsal ligaments |
| 4 Ankle joint | 19 Flexor digitorum brevis muscle | 30 Talonavicular ligament |
| 5 Interosseous talocalcaneal ligament | 20 Plantar aponeurosis | 31 Bifurcate ligament |
| 6 Subtalar joint | 21 Articular capsules of interphalangeal joints | 32 Anterior talar articular surface of calcaneus |
| 7 Calcaneal or Achilles tendon and bursa | 22 Articular capsules of metatarsophalangeal joints | 33 Posterior talar articular surface of calcaneus |
| 8 Calcaneus | 23 Articular surface of navicular bone | 34 Axis for inversion and eversion |
| 9 Vessels and nerves of foot | 24 Plantar calcaneonavicular ligament | 35 Tendon of tibialis posterior muscle |
| 10 Talus | 25 Middle talar articular surface of calcaneus | 36 Tendon of flexor hallucis longus muscle |
| 11 Talocalcaneonavicular joint | 26 Navicular articular surface of talus | 37 Flexor hallucis brevis muscle |
| 12 Navicular bone | | 38 Sesamoid bone |
| 13 Cuneonavicular joint | | 39 Cuboid bone |
| 14 Intermediate cuneiform bone | | |
| 15 Tarsometatarsal joints | | |



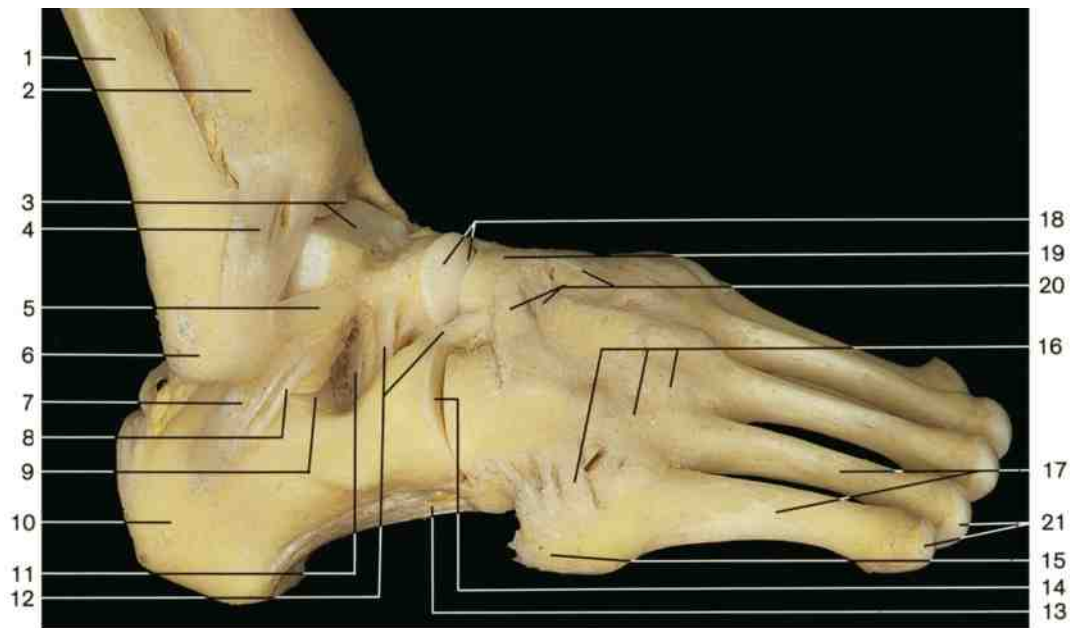
Ligaments of ankle joint, right foot (posterior aspect).



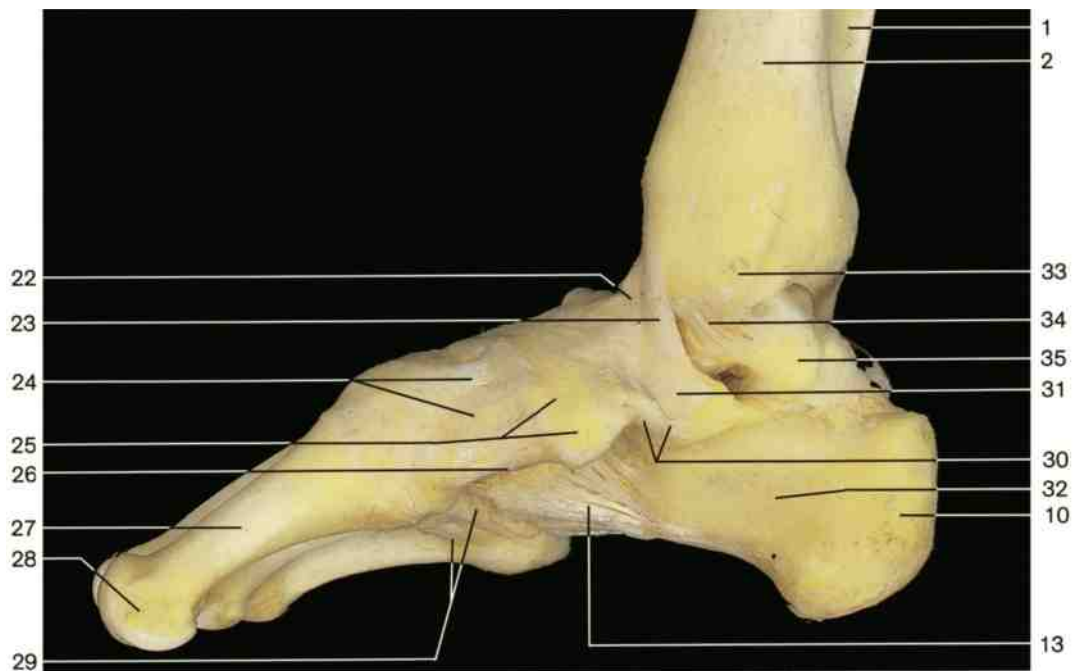
Deep ligaments of the foot, right foot (plantar aspect).
The toes have been removed.

- 1 Tibia
- 2 Trochlea of talus
- 3 Deltoid ligament of ankle (posterior tibiotalar part)
- 4 Talus
- 5 Sustentaculum tali
- 6 Navicular bone
- 7 First metatarsal bone
- 8 Fibula

- 9 Posterior tibiofibular ligament
- 10 Lateral malleolus
- 11 Posterior talofibular ligament
- 12 Calcaneofibular ligament
- 13 Calcaneal tuberosity
- 14 Plantar tarsometatarsal ligaments
- 15 Long plantar ligament
- 16 Plantar cuneonavicular ligaments
- 17 Plantar calcaneonavicular ligament

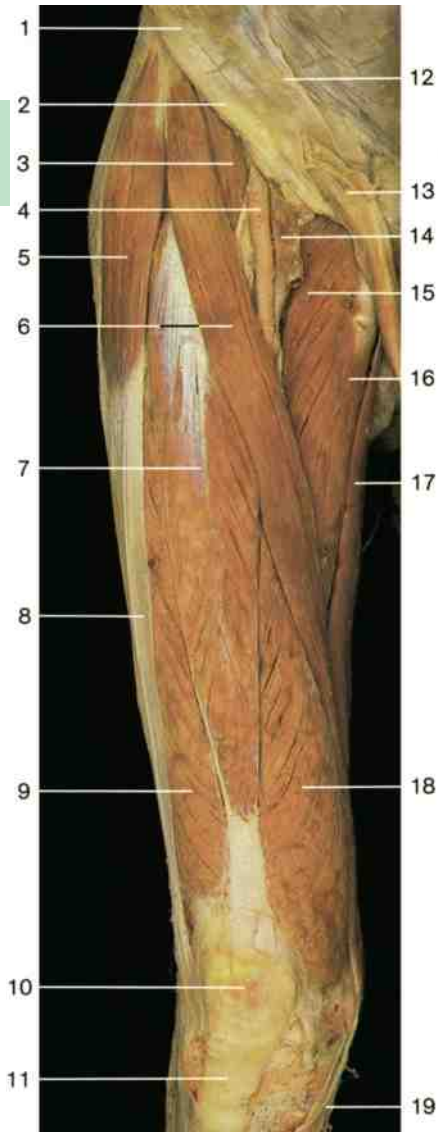


Ligaments of right foot (lateral aspect).

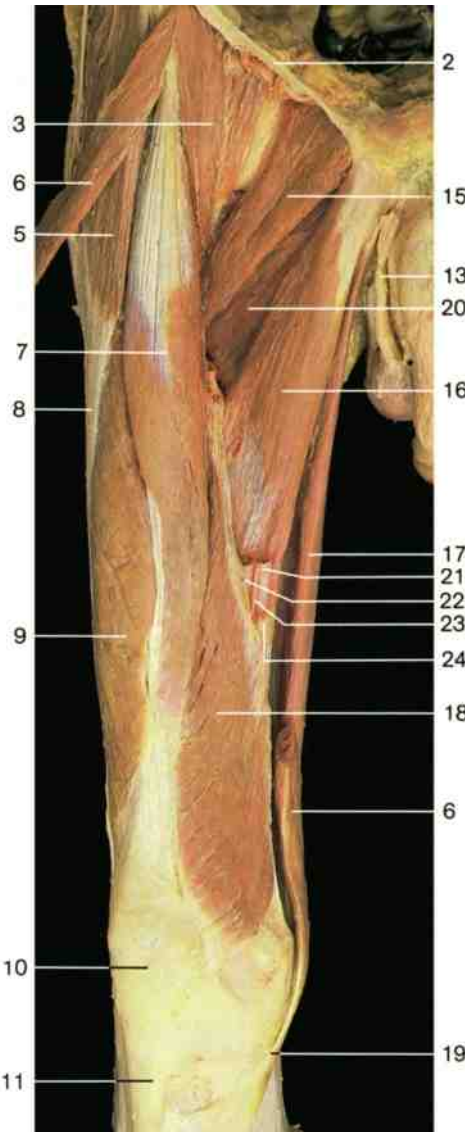


Ligaments of right foot (medial aspect).

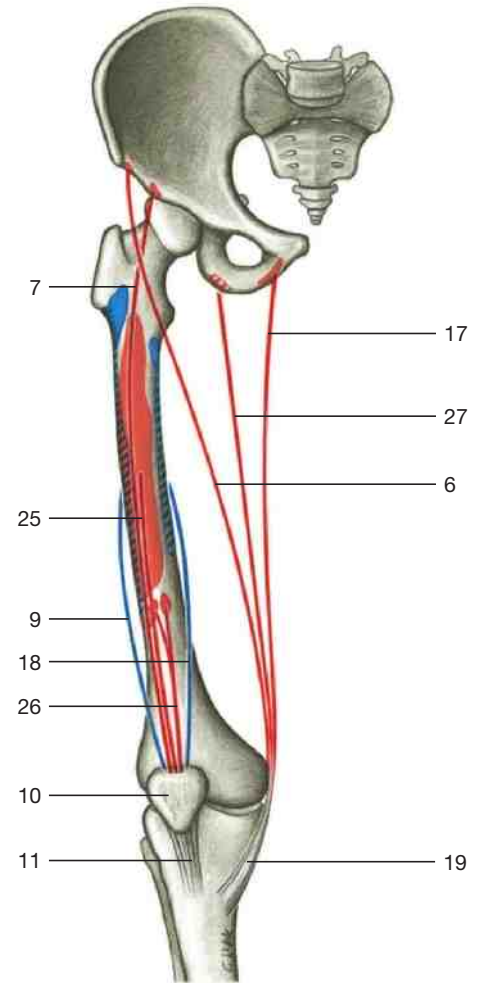
- | | |
|--|--|
| 1 Fibula | 19 Navicular bone |
| 2 Tibia | 20 Dorsal cuneonavicular ligaments |
| 3 Trochlea of talus and ankle joint | 21 Heads of metatarsal bones |
| 4 Anterior tibiofibular ligament | 22 Medial or deltoid ligament of ankle (tibionavicular part) |
| 5 Anterior talofibular ligament | 23 Medial or deltoid ligament of ankle (tibiocalcaneal part) |
| 6 Lateral malleolus | 24 Dorsal cuneonavicular ligaments |
| 7 Calcaneofibular ligament | 25 Navicular bone |
| 8 Lateral talocalcaneal ligament | 26 Plantar cuneonavicular ligament |
| 9 Subtalar joint | 27 First metatarsal bone |
| 10 Tuber calcanei | 28 Head of first metatarsal bone |
| 11 Interosseous talocalcaneal ligament | 29 Plantar tarsometatarsal ligaments |
| 12 Bifurcate ligament | 30 Plantar calcaneonavicular ligament |
| 13 Long plantar ligament | 31 Sustentaculum tali |
| 14 Calcaneocuboid joint | 32 Calcaneus |
| 15 Tuberosity of fifth metatarsal bone | 33 Medial malleolus |
| 16 Dorsal tarsometatarsal ligaments | 34 Medial or deltoid ligament of ankle (posterior part) |
| 17 Metatarsal bones | 35 Talus |
| 18 Head of talus and talocalcaneonavicular joint | |



Extensor and adductor muscles of thigh, right thigh (anterior aspect).



Quadriceps muscle and superficial layer of adductor muscles, right thigh (anterior aspect). The sartorius muscle has been divided.



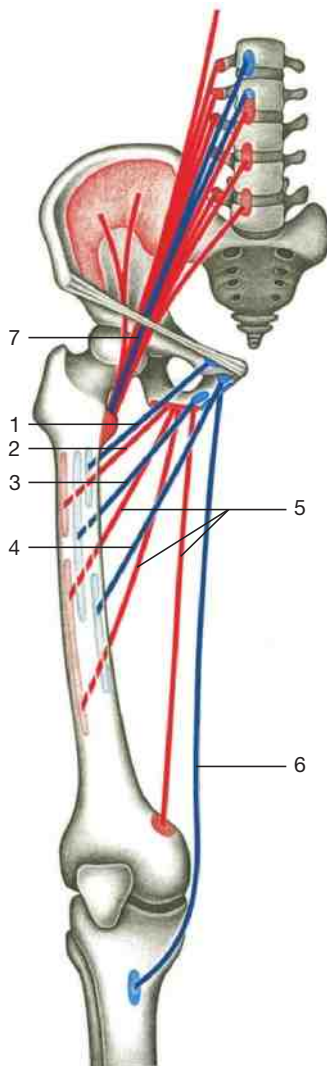
Course of extensor muscles of thigh and muscles inserting with common tendon on tibia (schematic drawing).

- 1 Anterior superior iliac spine
- 2 Inguinal ligament
- 3 Iliopsoas muscle
- 4 Femoral artery
- 5 Tensor fasciae latae muscle
- 6 Sartorius muscle
- 7 Rectus femoris muscle
- 8 Iliotibial tract
- 9 Vastus lateralis muscle
- 10 Patella
- 11 Patellar ligament

- 12 Aponeurosis of external abdominal oblique muscle
- 13 Spermatic cord
- 14 Femoral vein
- 15 Pectineus muscle
- 16 Adductor longus muscle
- 17 Gracilis muscle
- 18 Vastus medialis muscle
- 19 Common tendon of sartorius, gracilis, and semitendinosus muscles (pes anserinus)

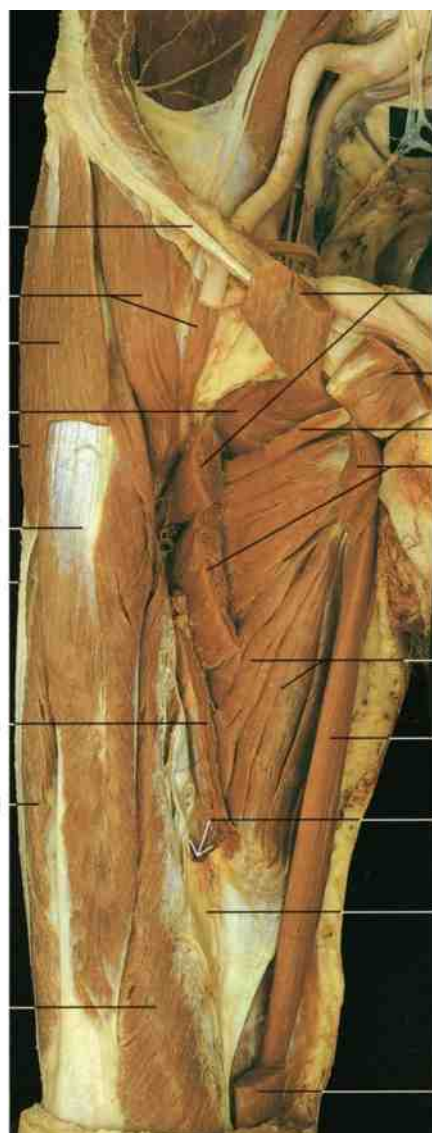
- 20 Adductor brevis muscle
- 21 Femoral artery
- 22 Femoral vein
- 23 Saphenous nerve
- 24 Fascia of adductor canal
- 25 Vastus intermedius muscle
- 26 Articularis genus muscle
- 27 Semitendinosus muscle

} entering the adductor canal



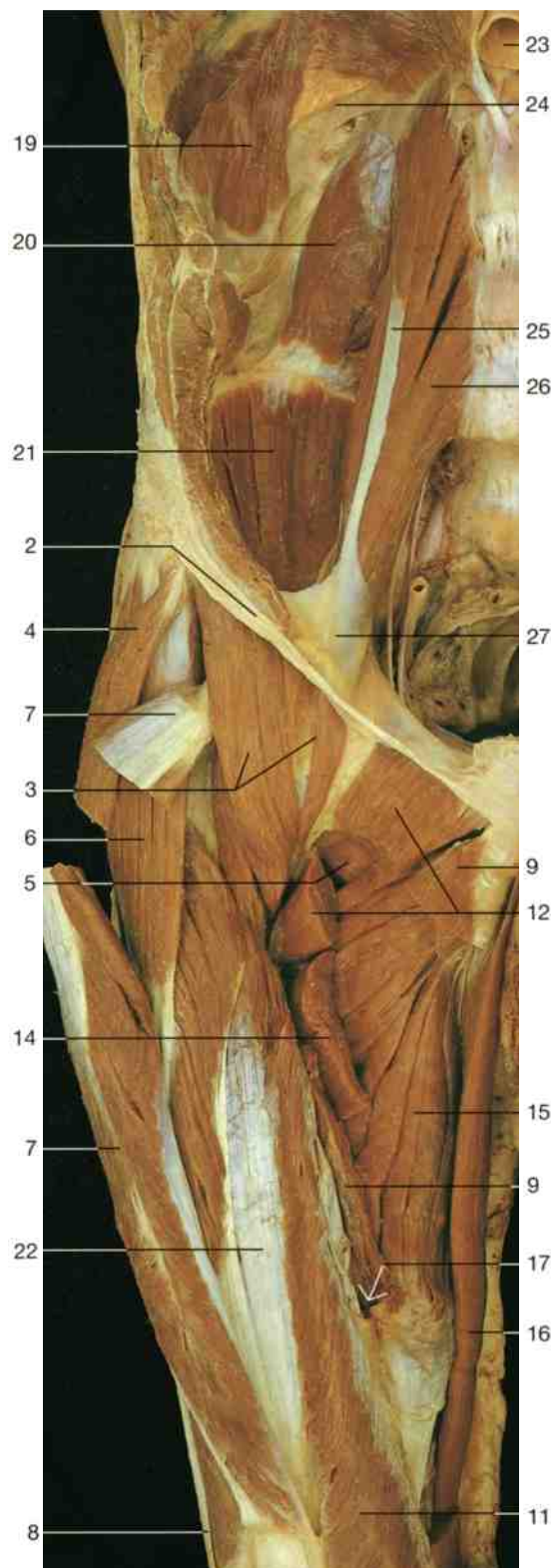
Course of adductor muscles (schematic drawing).

- 1 Pectineus muscle (blue)
- 2 Adductor minimus muscle (red)
- 3 Adductor brevis muscle (blue)
- 4 Adductor longus muscle (blue)
- 5 Adductor magnus muscle (red)
- 6 Gracilis muscle (blue)
- 7 Iliopsoas muscle (red/blue)



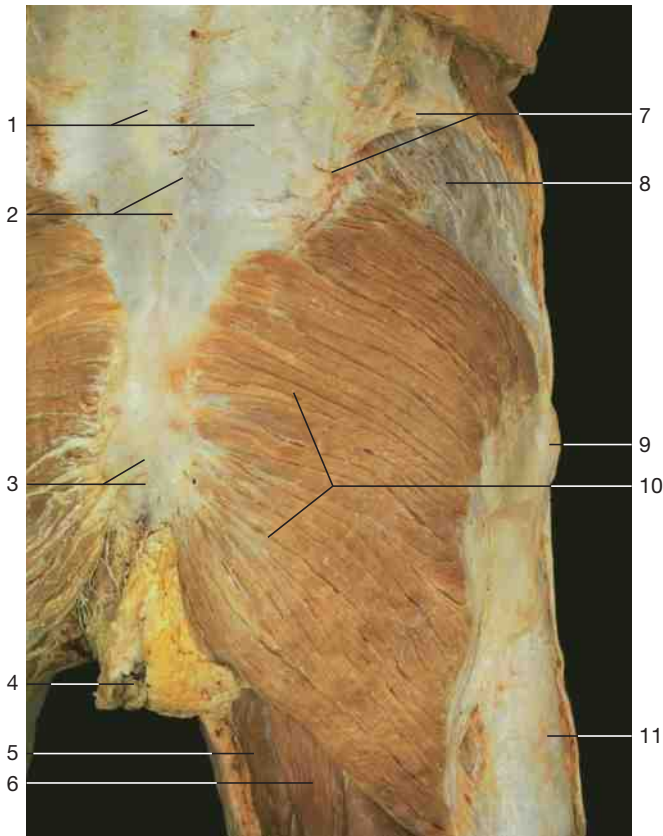
Adductor magnus muscle and deep layer of adductor muscles, right thigh (anterior aspect). Pectineus, adductor longus, and brevis muscles have been divided.

- 1 Anterior superior iliac spine
- 2 Inguinal ligament
- 3 Iliopsoas muscle
- 4 Sartorius muscle
- 5 Obturator externus muscle
- 6 Tensor fasciae latae muscle
- 7 Rectus femoris muscle
- 8 Iliotibial tract
- 9 Adductor longus muscle (divided)
- 10 Vastus lateralis muscle
- 11 Vastus medialis muscle
- 12 Pectineus muscle (divided)
- 13 Adductor minimus muscle
- 14 Adductor brevis muscle (cut)
- 15 Adductor magnus muscle
- 16 Gracilis muscle
- 17 Adductor hiatus
- 18 Vasto-adductor membrane
- 19 Diaphragm
- 20 Quadratus lumborum muscle
- 21 Iliacus muscle
- 22 Vastus intermedius muscle

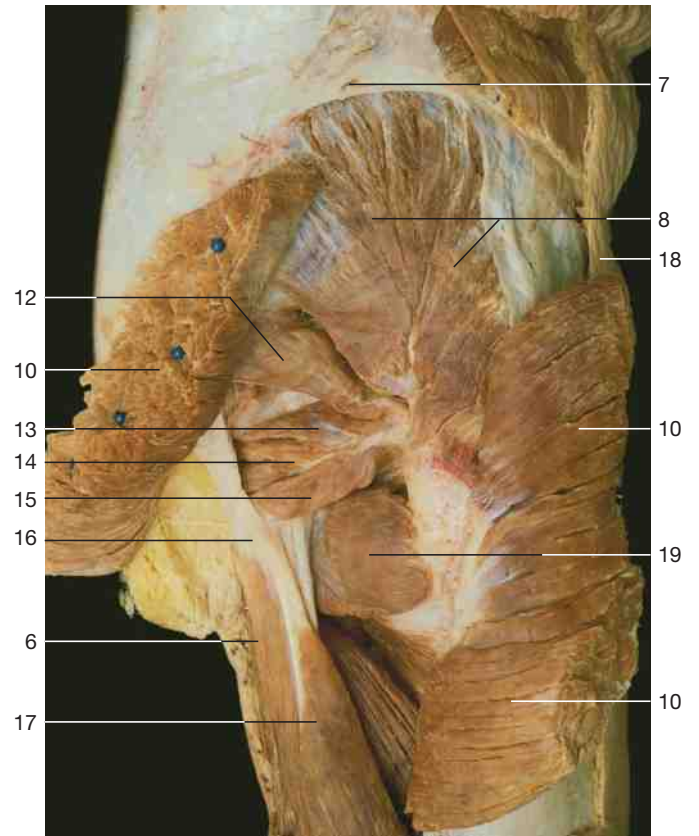

Iliopsoas muscle and deepest layer of adductor muscles, right thigh (anterior aspect). Pectineus, adductor longus and brevis, and rectus femoris muscles have been divided.

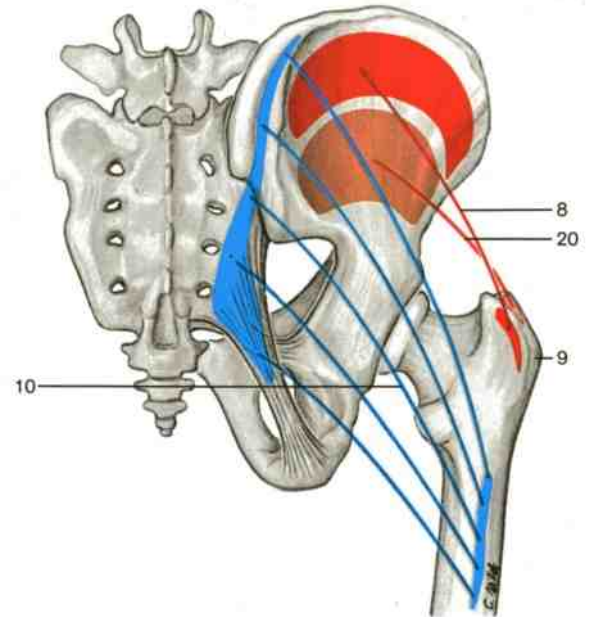
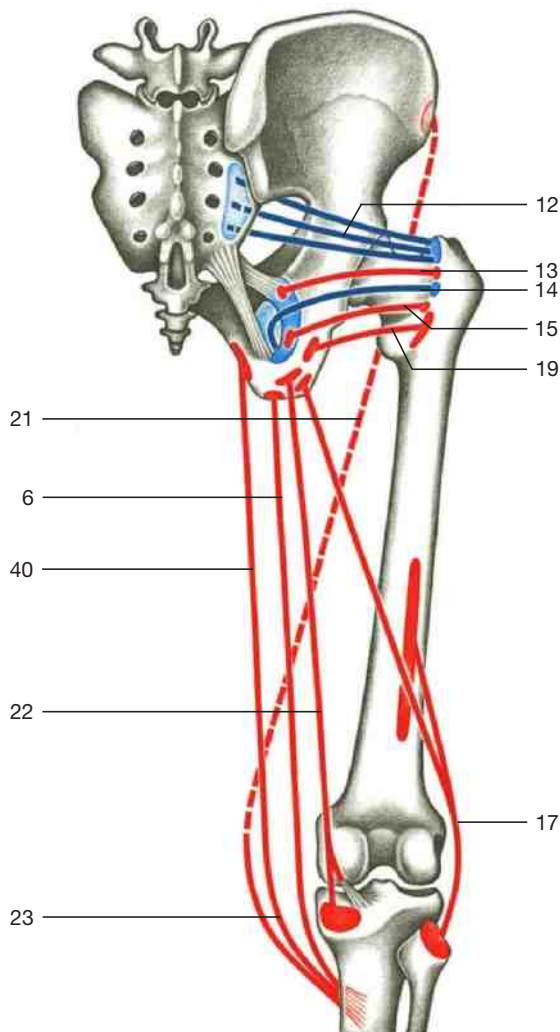
- 23 Aorta in aortic hiatus
- 24 Twelfth rib
- 25 Psoas minor muscle
- 26 Psoas major muscle
- 27 Iliopectineal arch



Gluteal muscles, superficial layer (posterior aspect).

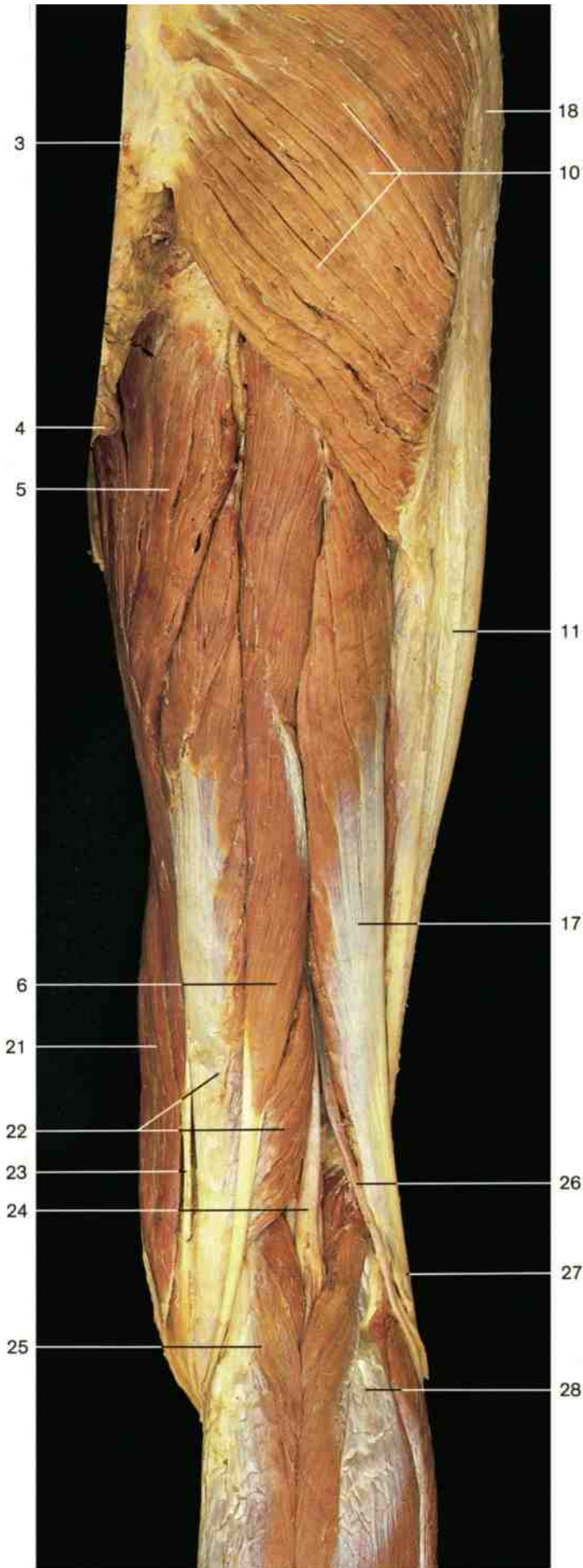


Gluteal muscles, deeper layer (posterior aspect).

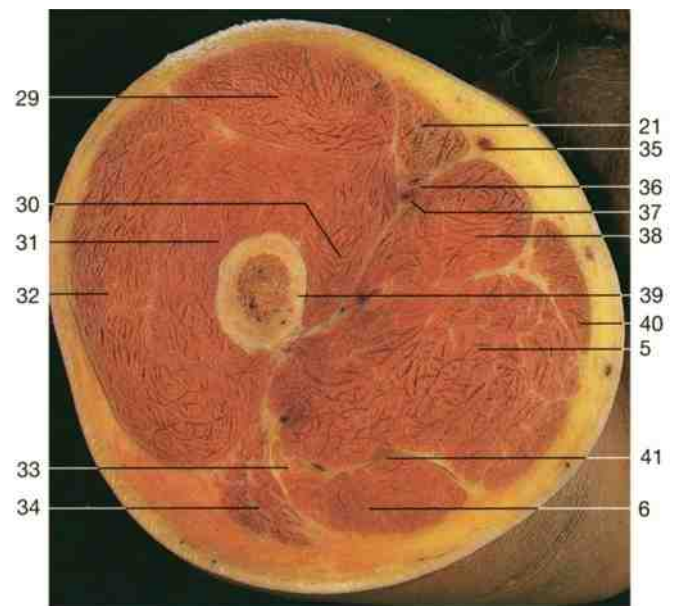

Course of gluteal muscles (posterior aspect; schematic drawing).

◁
 Course of gluteal muscles (deeper layer) and of ischio-crural muscles (posterior aspect). Sartorius muscle is indicated by a dotted line (schematic drawing).

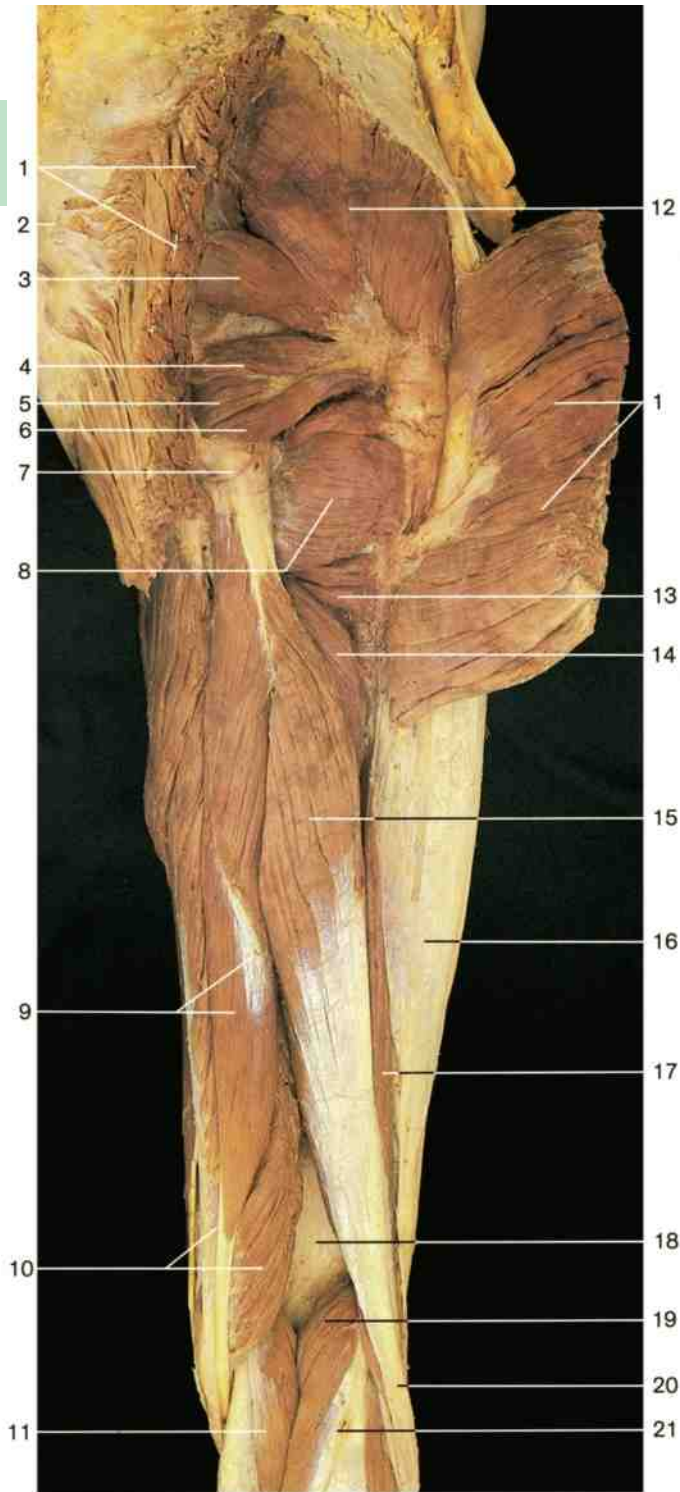


- 1 Thoracolumbar fascia
- 2 Spinous processes of lumbar vertebrae
- 3 Coccyx
- 4 Anus
- 5 Adductor magnus muscle
- 6 Semitendinosus muscle
- 7 Iliac crest
- 8 Gluteus medius muscle
- 9 Greater trochanter
- 10 Gluteus maximus muscle
- 11 Iliotibial tract
- 12 Piriformis muscle
- 13 Superior gemellus muscle
- 14 Obturator internus muscle
- 15 Inferior gemellus muscle
- 16 Ischial tuberosity
- 17 Biceps femoris muscle
- 18 Tensor fasciae latae muscle
- 19 Quadratus femoris muscle
- 20 Gluteus minimus muscle
- 21 Sartorius muscle
- 22 Semimembranosus muscle
- 23 Tendon of gracilis muscle
- 24 Tibial nerve
- 25 Medial head of gastrocnemius muscle
- 26 Common peroneal nerve
- 27 Tendon of biceps femoris muscle
- 28 Lateral head of gastrocnemius muscle
- 29 Rectus femoris muscle
- 30 Vastus medialis muscle
- 31 Vastus intermedius muscle
- 32 Vastus lateralis muscle
- 33 Sciatic nerve
- 34 Gluteus maximus muscle (insertion)
- 35 Great saphenous vein
- 36 Femoral artery
- 37 Femoral vein
- 38 Adductor longus muscle
- 39 Femur
- 40 Gracilis muscle
- 41 Septum between semitendinosus and semimembranosus muscles

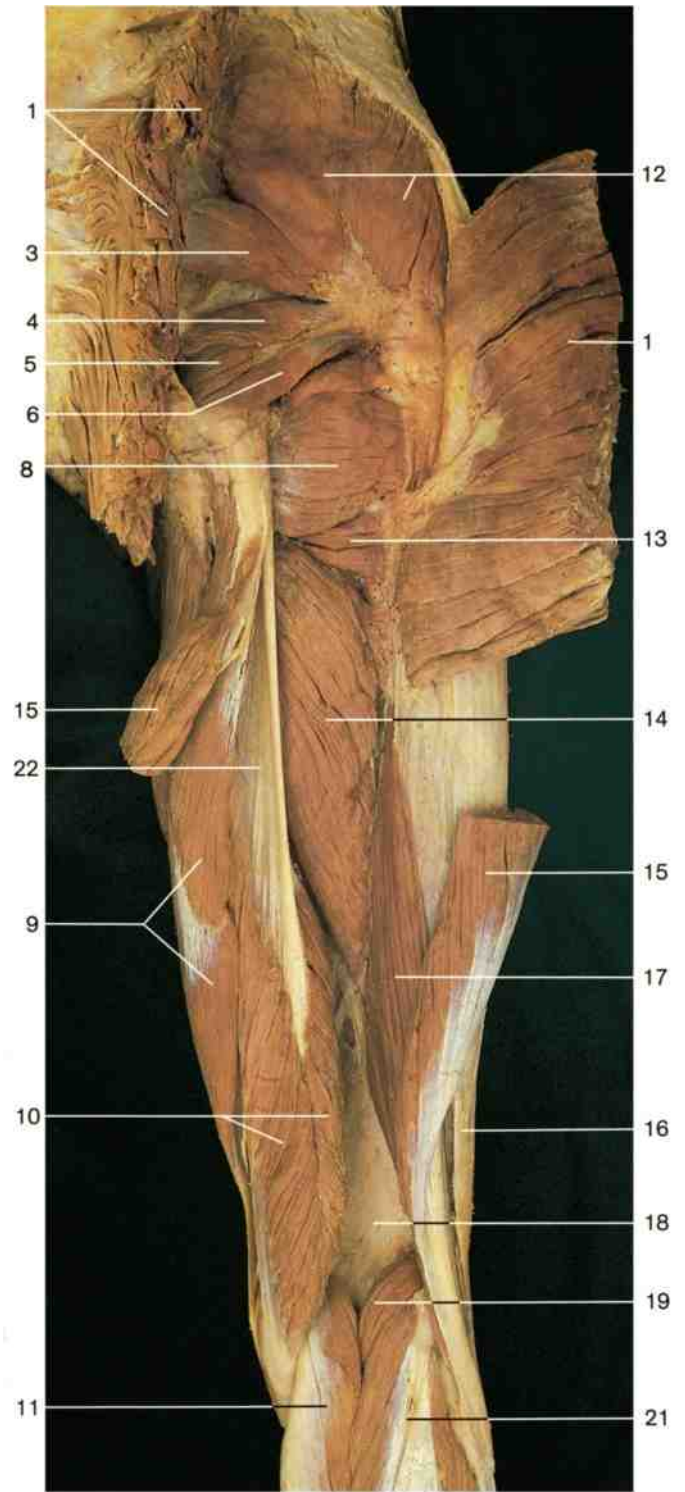


Flexors of the right thigh, superficial layer (posterior aspect).

Cross section of right thigh (inferior aspect). Anterior side on top.

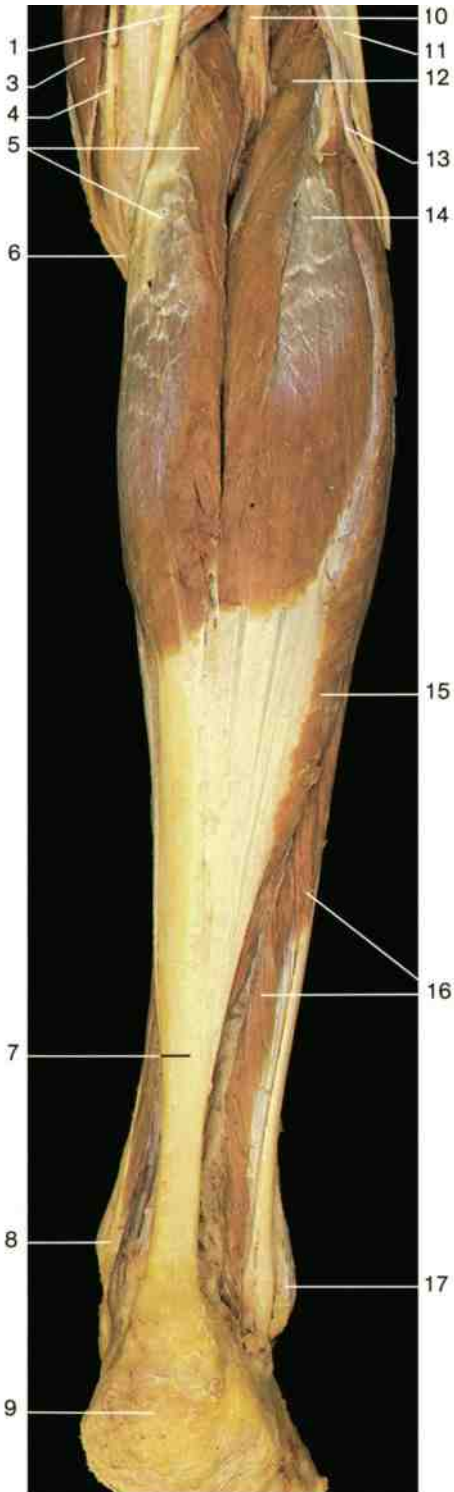


Dorsal muscles of right thigh (posterior aspect).
The gluteus maximus muscle has been cut and reflected.

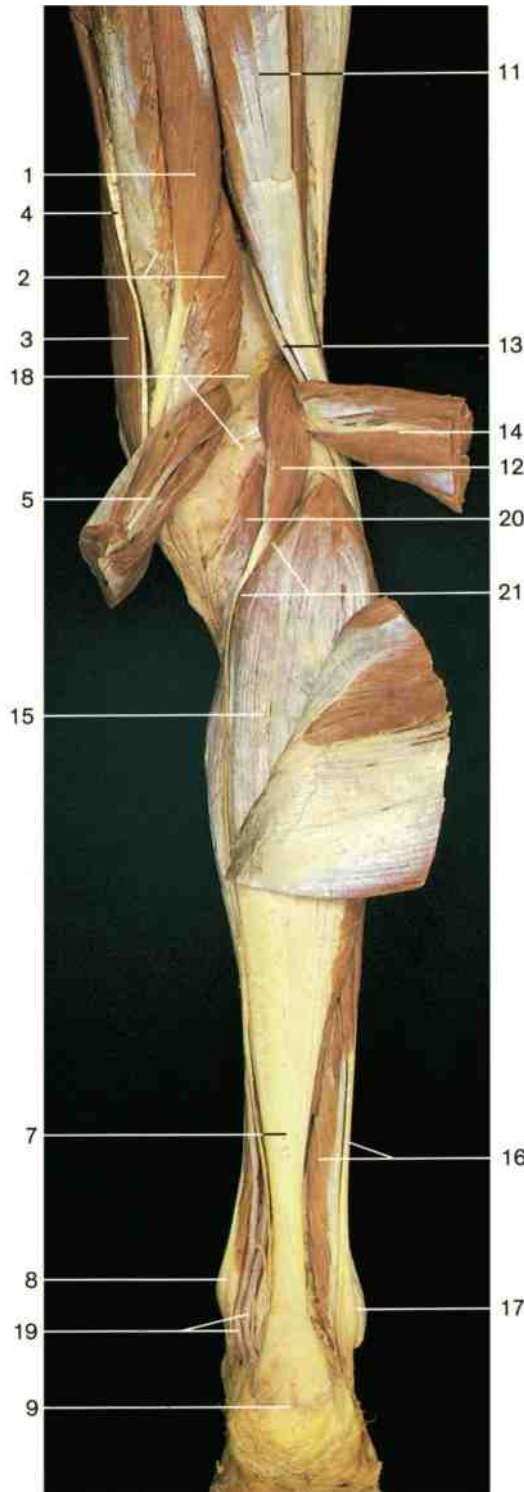


Dorsal muscles of right thigh (posterior aspect).
The gluteus maximus muscle and the long head of biceps femoris muscle have been divided and displaced.

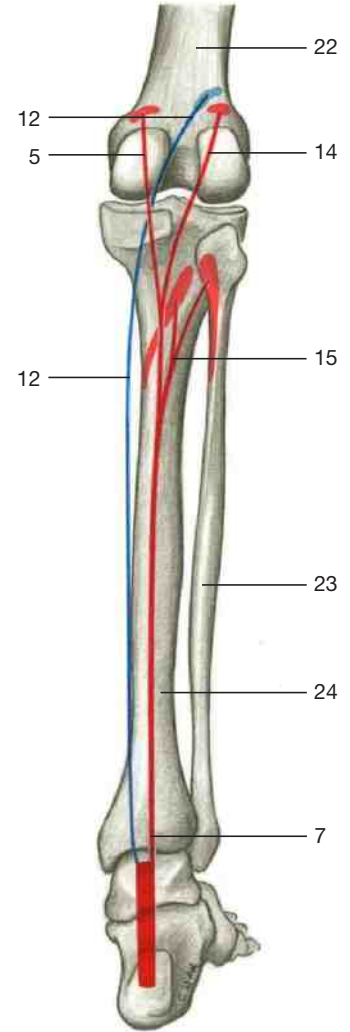
- | | | |
|------------------------------------|--|--|
| 1 Gluteus maximus muscle (divided) | 9 Semitendinosus muscle with intermediate tendon | 17 Short head of biceps femoris muscle |
| 2 Position of coccyx | 10 Semimembranosus muscle | 18 Popliteal surface of femur |
| 3 Piriformis muscle | 11 Medial head of gastrocnemius muscle | 19 Plantaris muscle |
| 4 Superior gemellus muscle | 12 Gluteus medius muscle | 20 Tendon of biceps femoris muscle |
| 5 Obturator internus muscle | 13 Adductor minimus muscle | 21 Lateral head of gastrocnemius muscle |
| 6 Inferior gemellus muscle | 14 Adductor magnus muscle | 22 Membranous part of semimembranosus muscle |
| 7 Ischial tuberosity | 15 Long head of biceps femoris muscle | |
| 8 Quadratus femoris muscle | 16 Iliotibial tract | |



Flexor muscles of right leg (posterior aspect).



Flexor muscles of right leg (posterior aspect). Both heads of the gastrocnemius muscle have been cut and reflected.

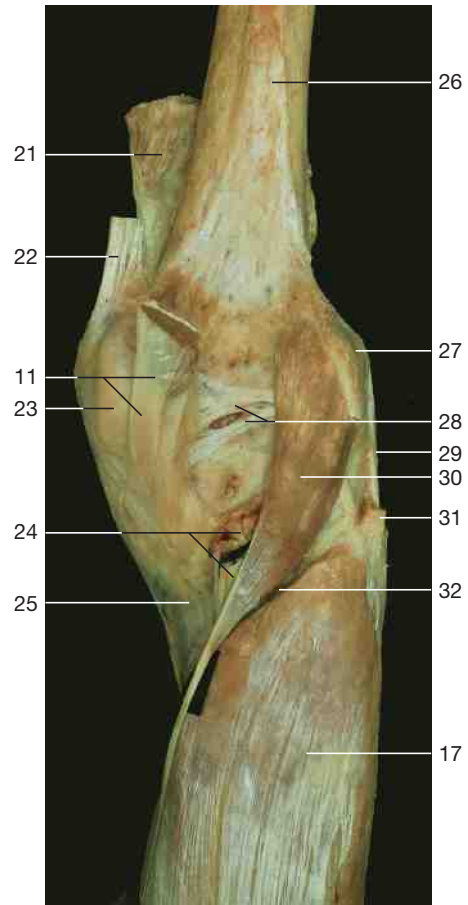
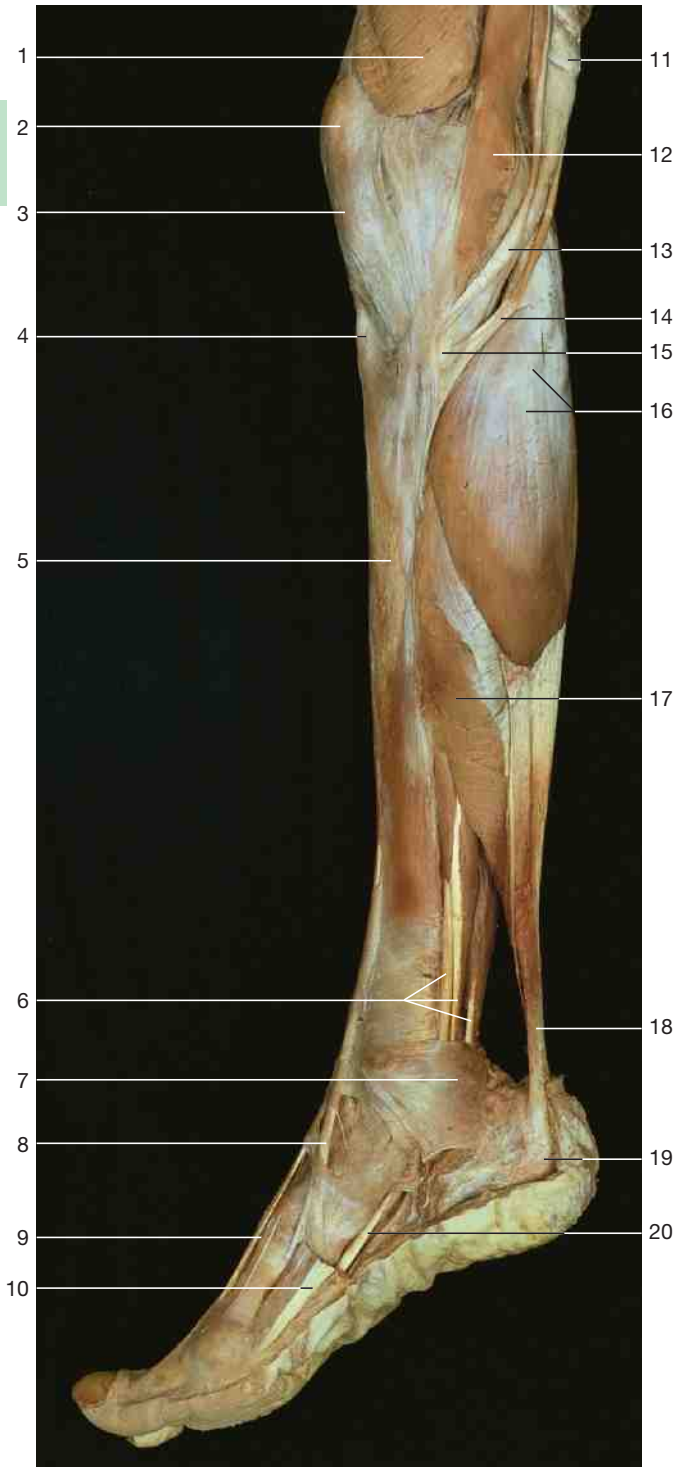


Flexor muscles of the leg (right side).

- 1 Semitendinosus muscle
- 2 Semimembranosus muscle
- 3 Sartorius muscle
- 4 Tendon of gracilis muscle
- 5 Medial head of gastrocnemius muscle
- 6 Common tendon of gracilis, sartorius, and semitendinosus muscles
- 7 Calcaneal or Achilles tendon
- 8 Medial malleolus

- 9 Calcaneal tuberosity
- 10 Tibial nerve
- 11 Biceps femoris muscle
- 12 Plantaris muscle
- 13 Common peroneal nerve
- 14 Lateral head of gastrocnemius muscle
- 15 Soleus muscle
- 16 Peroneus longus and brevis muscles
- 17 Lateral malleolus

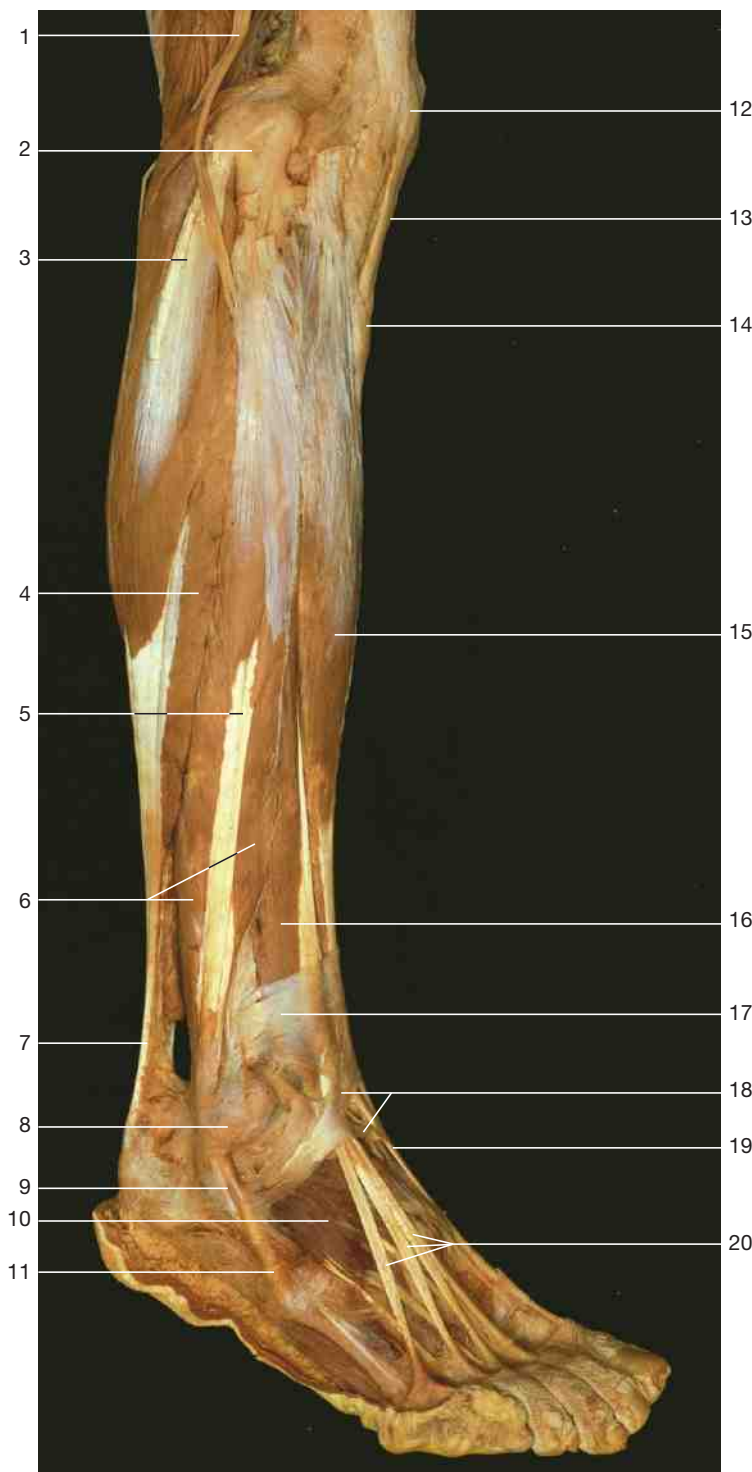
- 18 Popliteal fossa
- 19 Tibial nerve and posterior tibial artery
- 20 Popliteus muscle
- 21 Tendinous arch of soleus muscle
- 22 Femur
- 23 Fibula
- 24 Tibia



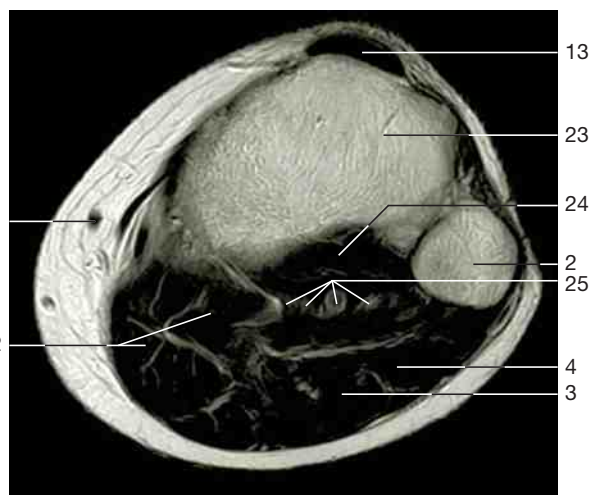
Popliteal region with plantaris and soleus muscles, right side (dorsal aspect). Notice the insertion of the tendon of semimembranosus muscle.

Muscles of right leg and foot (medial aspect).

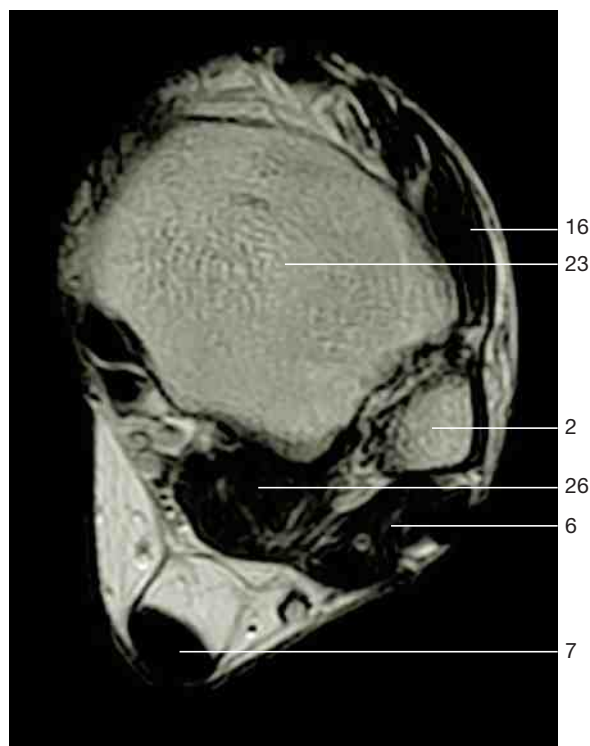- | | | |
|---|---|--|
| 1 Vastus medialis muscle | 11 Semimembranosus muscle | 23 Medial condyle of femur |
| 2 Patella | 12 Sartorius muscle | 24 Popliteal artery and vein, tibial nerve |
| 3 Patellar ligament | 13 Tendon of gracilis muscle | 25 Tibia |
| 4 Tibial tuberosity | 14 Tendon of semitendinosus muscle | 26 Femur |
| 5 Tibia | 15 Common tendon of gracilis, semitendinosus, and sartorius muscles | 27 Lateral epicondyle of femur |
| 6 Tendons of deep flexor muscles (from anterior to posterior: 1. tibialis posterior; 2. flexor digitorum longus; 3. flexor hallucis longus muscles) | 16 Medial head of gastrocnemius muscle | 28 Oblique popliteal ligament |
| 7 Flexor retinaculum | 17 Soleus muscle | 29 Lateral (fibular) collateral ligament |
| 8 Tendon of tibialis anterior muscle | 18 Calcaneal or Achilles tendon | 30 Plantaris muscle |
| 9 Tendon of extensor hallucis longus muscle | 19 Calcaneus muscle | 31 Tendon of biceps femoris muscle (divided) |
| 10 Abductor hallucis muscle | 20 Tendon of flexor hallucis longus muscle | 32 Tendinous arch of soleus muscle |
| | 21 Quadriceps femoris muscle (divided) | |
| | 22 Tendon of adductor magnus muscle (divided) | |



Muscles of right leg and foot (lateral aspect).

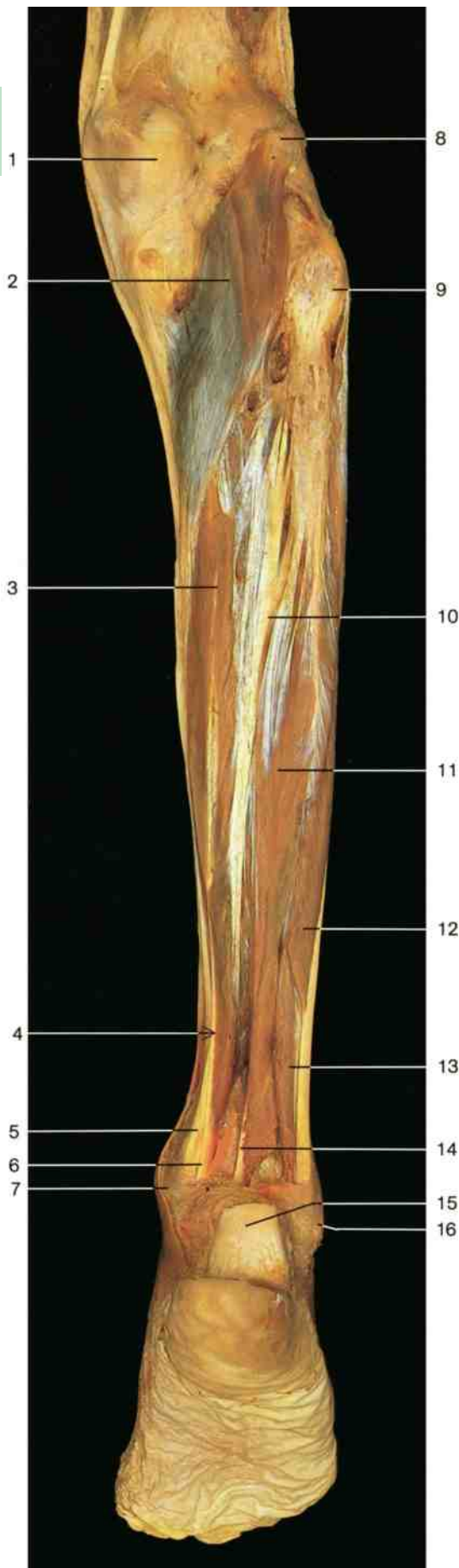


Axial section of the right leg distally of the knee joint (MRI scan; from Heuck et al., MRT-Atlas, 2009).

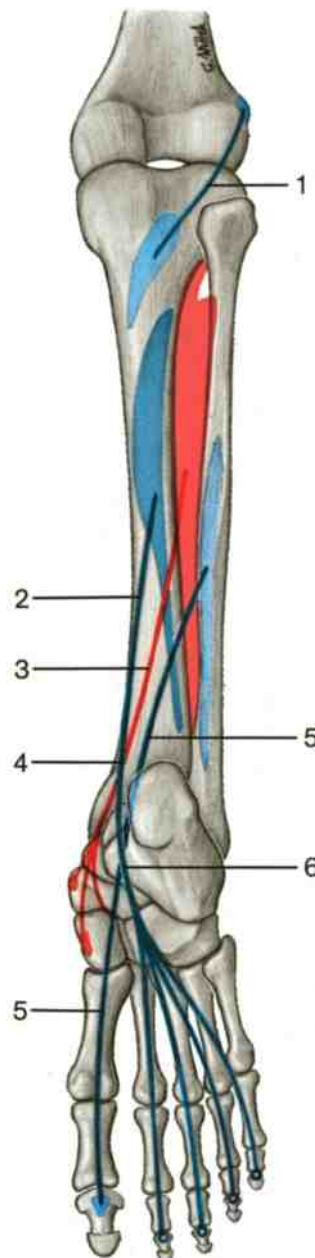


Axial section of the right leg cranially of the ankle joint (MRI scan; from Heuck et al., MRT-Atlas, 2009).

- | | | |
|--|--|--|
| 1 Common peroneal nerve | 11 Tendon of peroneus brevis muscle | 20 Tendons of extensor digitorum longus muscle |
| 2 Head of fibula | 12 Patella | 21 Great saphenous vein |
| 3 Lateral head of gastrocnemius muscle | 13 Patellar ligament | 22 Medial head of gastrocnemius muscle |
| 4 Soleus muscle | 14 Tuberosity of tibia | 23 Tibia |
| 5 Peroneus longus muscle | 15 Tibialis anterior muscle | 24 Popliteus muscle |
| 6 Peroneus brevis muscle | 16 Extensor digitorum longus muscle | 25 Tibial nerve, popliteal artery, and veins |
| 7 Calcaneal or Achilles tendon | 17 Superior extensor retinaculum | 26 Flexor hallucis longus muscle |
| 8 Lateral malleolus muscle | 18 Inferior extensor retinaculum | |
| 9 Tendon of peroneus longus muscle | 19 Tendon of extensor hallucis longus muscle | |
| 10 Extensor digitorum brevis muscle | | |



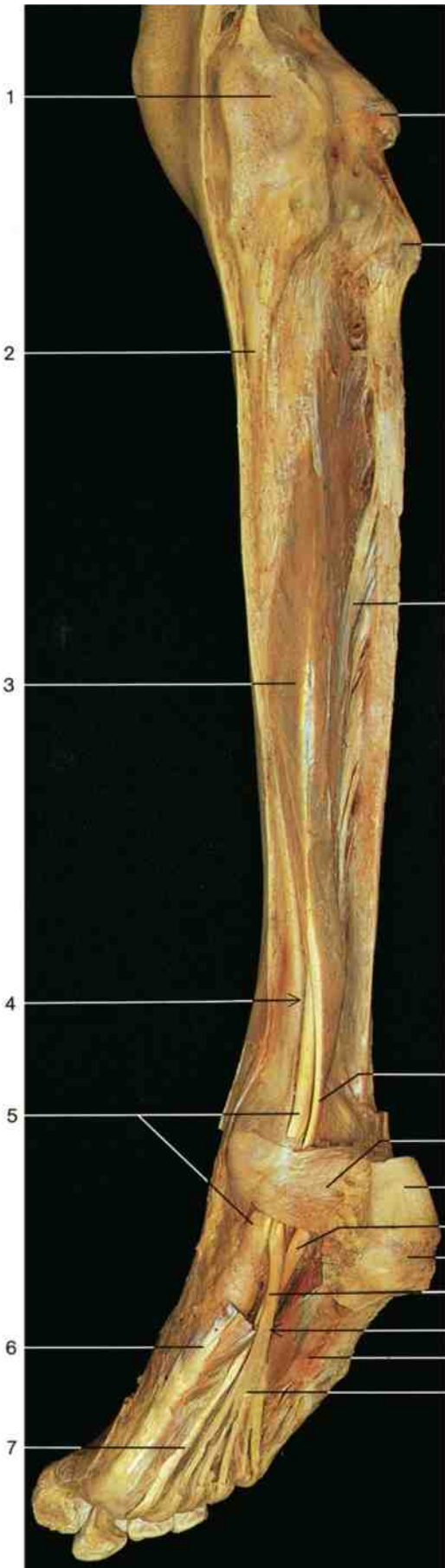
- 1 Medial condyle of femur
- 2 Popliteus muscle
- 3 Flexor digitorum longus muscle
- 4 Crossing of tendons in leg
- 5 Tendon of tibialis posterior muscle
- 6 Tendon of flexor digitorum longus muscle
- 7 Medial malleolus
- 8 Lateral condyle of femur
- 9 Head of fibula
- 10 Tibialis posterior muscle
- 11 Flexor hallucis longus muscle
- 12 Peroneus longus muscle
- 13 Peroneus brevis muscle
- 14 Tendon of flexor hallucis longus muscle
- 15 Calcaneal tendon (divided)
- 16 Lateral malleolus



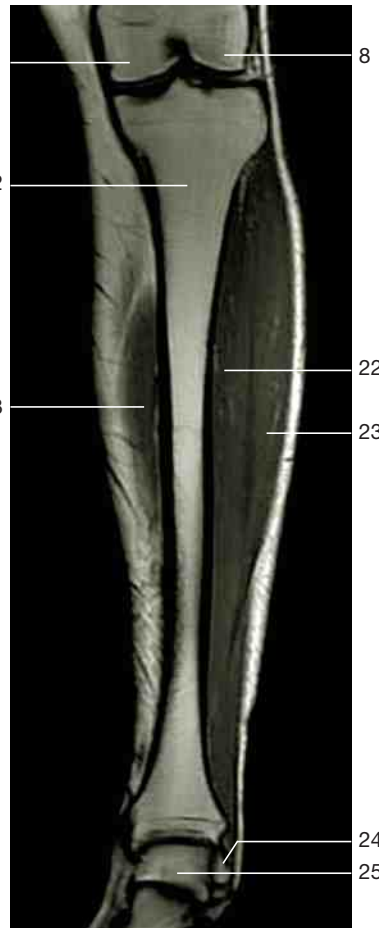- 1 Popliteus muscle (blue)
- 2 Flexor digitorum longus muscle (blue)
- 3 Tibialis posterior muscle (red)
- 4 Crossing of tendons in leg
- 5 Flexor hallucis longus muscle (blue)
- 6 Crossing of tendons in sole

Deep flexor muscles of right leg and foot (posterior aspect).

Course of deep flexor muscles of leg (schematic drawing).

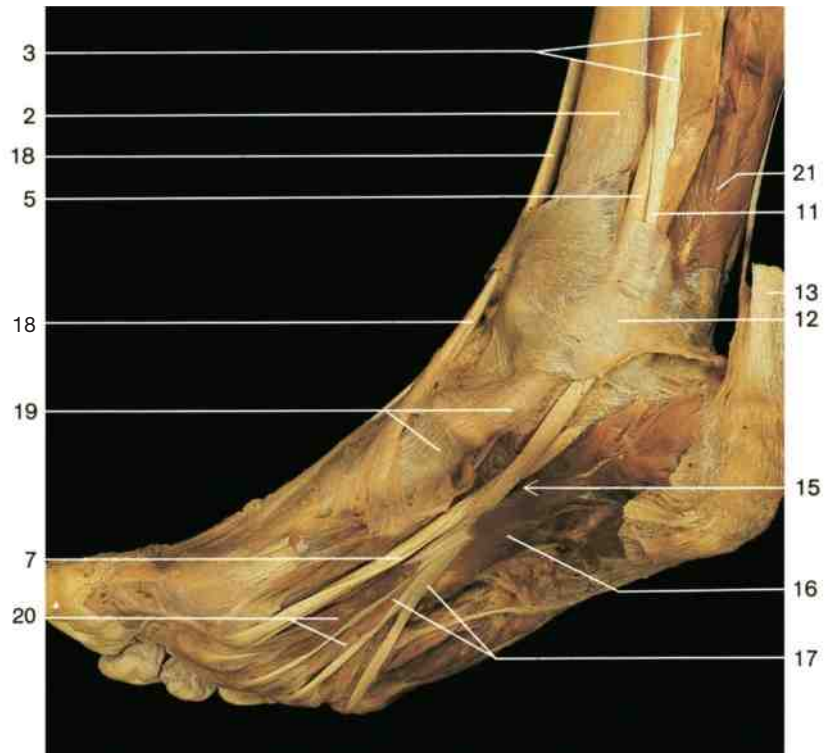

Deep flexor muscles of right leg and foot (posterior oblique medial aspect). Flexor digitorum brevis and flexor hallucis longus muscles have been removed.

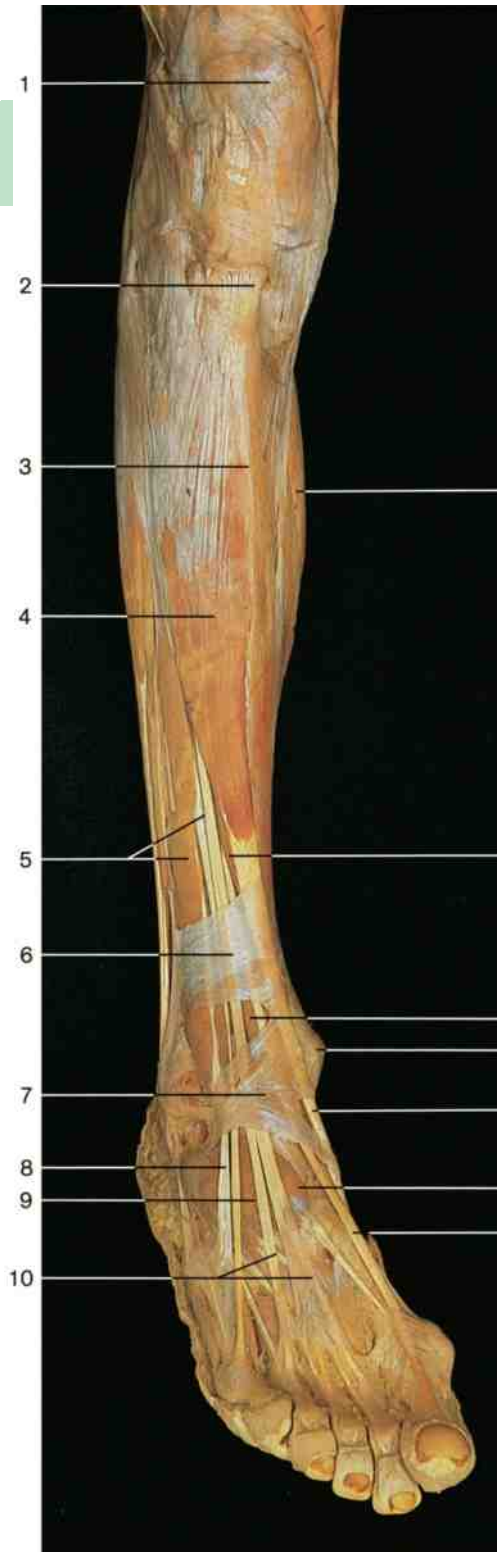


Coronal section of the leg (MRI scan; from Heuck et al., MRT-Atlas, 2009).

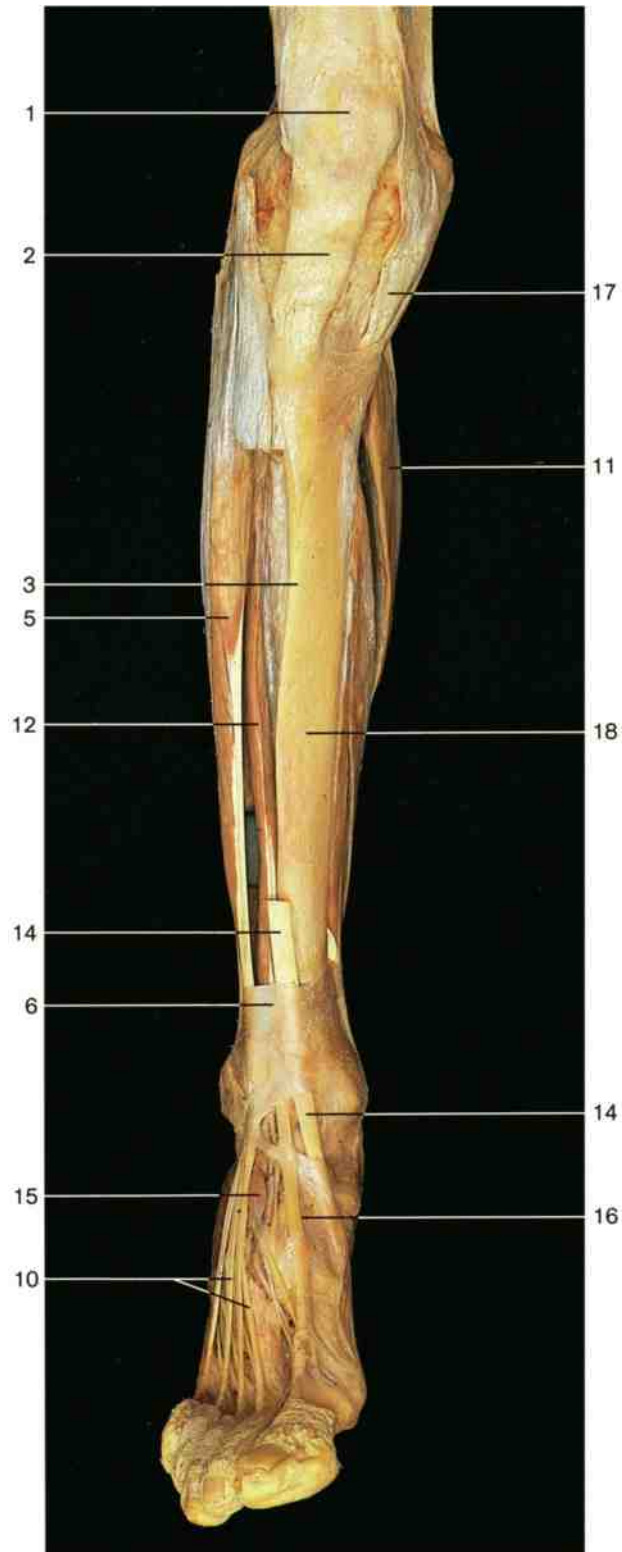
- 1 Medial condyle of femur
- 2 Tibia
- 3 Flexor digitorum longus muscle
- 4 Crossing of tendons in leg
- 5 Tendon of tibialis posterior muscle
- 6 Abductor hallucis muscle
- 7 Tendon of flexor hallucis longus muscle
- 8 Lateral condyle of femur
- 9 Head of fibula
- 10 Tibialis posterior muscle
- 11 Tendon of flexor digitorum longus muscle
- 12 Flexor retinaculum
- 13 Calcaneal tendon
- 14 Calcaneal tuberosity
- 15 Crossing of tendons in sole
- 16 Quadratus plantae muscle
- 17 Tendons of flexor digitorum longus muscle
- 18 Tendon of tibialis anterior muscle
- 19 Area of insertion of tibialis posterior muscle
- 20 Lumbrical muscles
- 21 Flexor hallucis longus muscle
- 22 Tibialis anterior muscle
- 23 Extensor hallucis longus muscle
- 24 Lateral malleolus of fibula
- 25 Trochlea of talus



Sole of foot with tendons of long flexor muscles (oblique medial and inferior aspect).

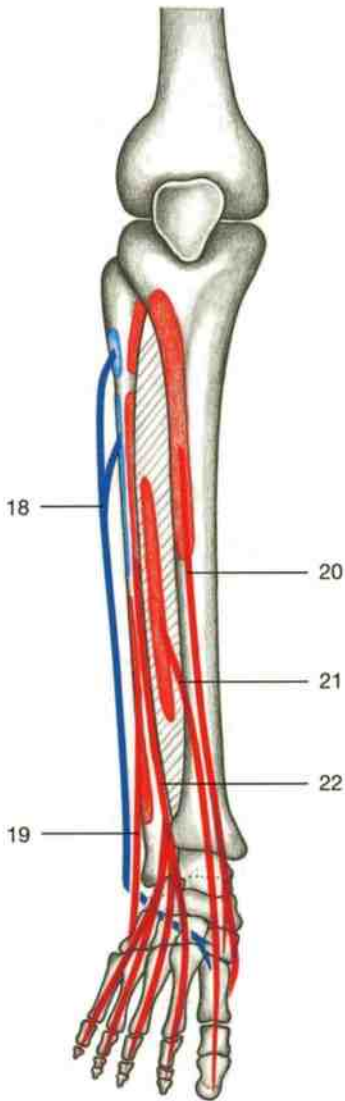


Extensor muscles of right leg and foot (oblique antero-lateral aspect).

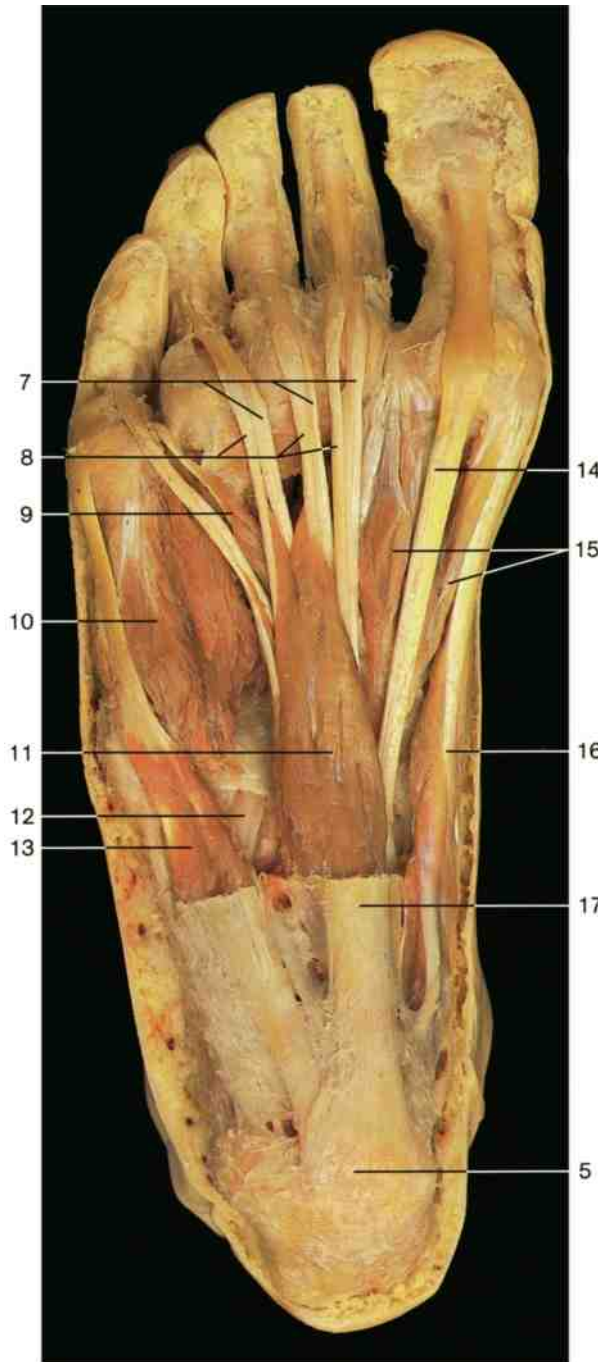


Extensor muscles of right leg and foot (anterior aspect). Part of the tibialis anterior muscle has been removed.

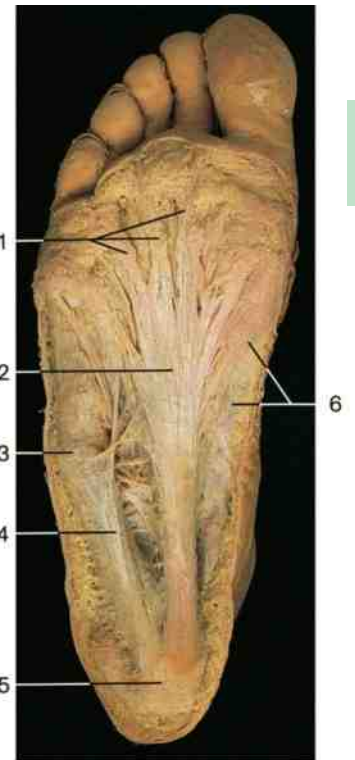
- | | | |
|------------------------------------|--|---|
| 1 Patella | 8 Tendon of peroneus tertius muscle | 14 Tendon of tibialis anterior muscle |
| 2 Patellar ligament | 9 Extensor digitorum brevis muscle | 15 Extensor hallucis brevis muscle |
| 3 Anterior margin of tibia | 10 Tendons of extensor digitorum longus muscle | 16 Tendon of extensor hallucis longus muscle |
| 4 Tibialis anterior muscle | 11 Gastrocnemius muscle | 17 Common tendon of gracilis, semitendinosus, and sartorius muscles |
| 5 Extensor digitorum longus muscle | 12 Extensor hallucis longus muscle | 18 Tibia |
| 6 Superior extensor retinaculum | 13 Medial malleolus | |
| 7 Inferior extensor retinaculum | | |



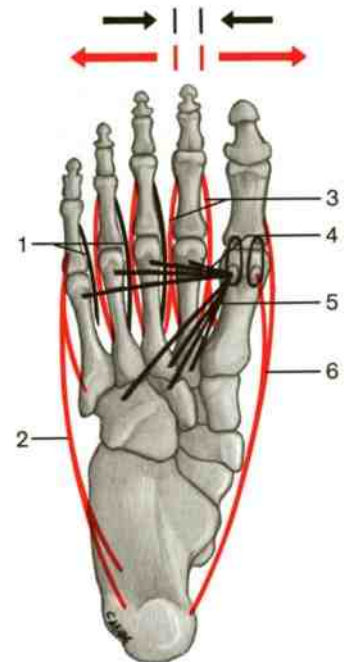
Extensor muscles of the leg (right side).



Muscles of sole of foot, first layer (from below). The plantar aponeurosis and the fasciae of the superficial muscles have been removed.



Sole of foot, plantar aponeurosis (from below).

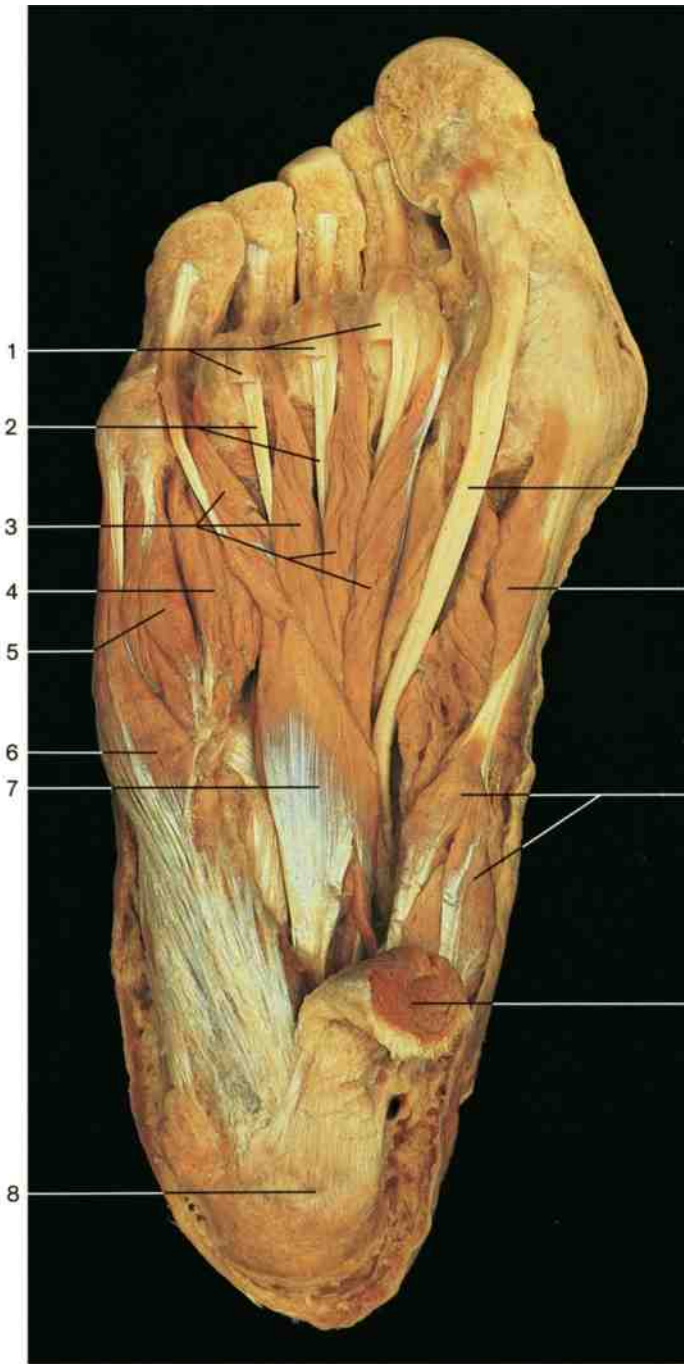


Course of abductor and adductor muscles of foot (schematic drawing).

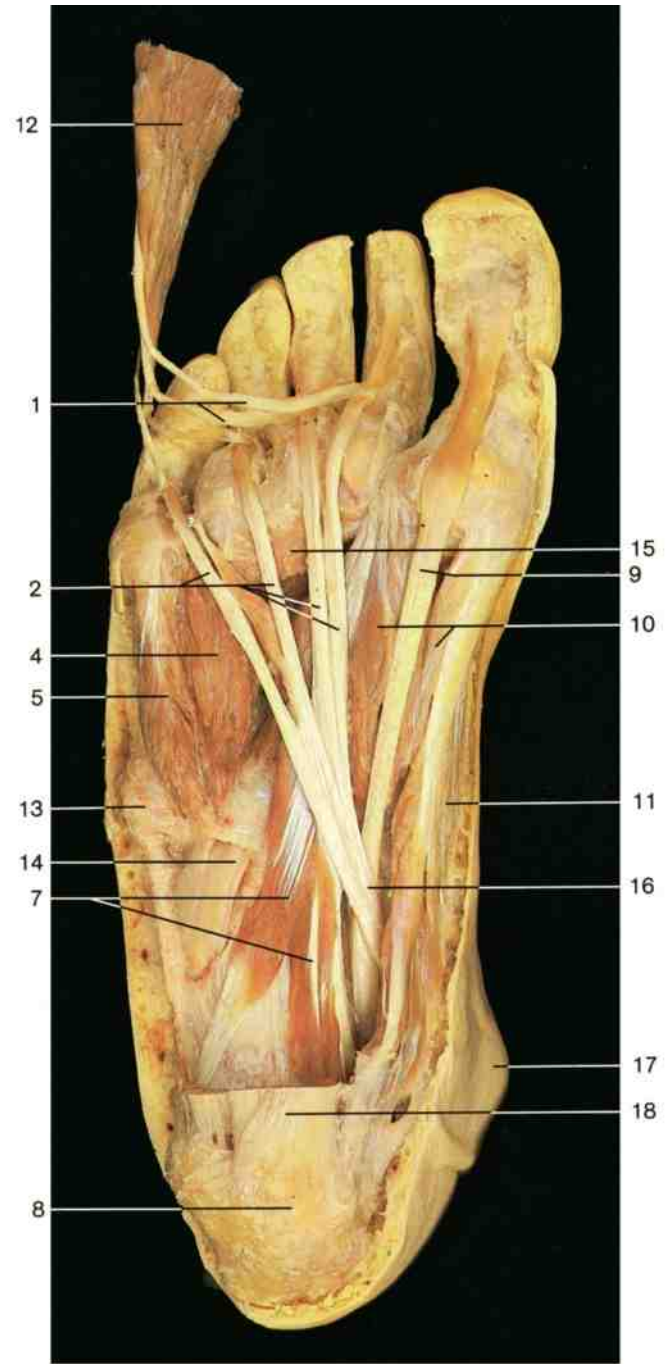
Red arrows = abduction.
Black arrows = adduction.

- 1 Plantar interossei muscles (black)
- 2 Abductor digiti minimi muscle (red)
- 3 Dorsal interossei muscles (red)
- 4 Transverse head of adductor muscle (black)
- 5 Oblique head of adductor muscle (black)
- 6 Abductor hallucis muscle (red)

- 1 Longitudinal bands of plantar aponeurosis
- 2 Plantar aponeurosis
- 3 Position of tuberosity of fifth metatarsal bone
- 4 Muscles of fifth toe with fascia
- 5 Calcaneal tuberosity
- 6 Muscles of great toe with fascia
- 7 Tendons of flexor digitorum longus muscle
- 8 Tendons of flexor digitorum brevis muscle
- 9 Lumbrical muscle
- 10 Flexor digiti minimi brevis muscle
- 11 Flexor digitorum brevis muscle
- 12 Tendon of peroneus longus muscle
- 13 Abductor digiti minimi muscle
- 14 Tendon of flexor hallucis longus muscle
- 15 Flexor hallucis brevis muscle
- 16 Abductor hallucis muscle
- 17 Plantar aponeurosis (cut)
- 18 Peroneus longus muscle
- 19 Peroneus brevis muscle
- 20 Tibialis anterior muscle
- 21 Extensor hallucis longus muscle
- 22 Extensor digitorum longus muscle

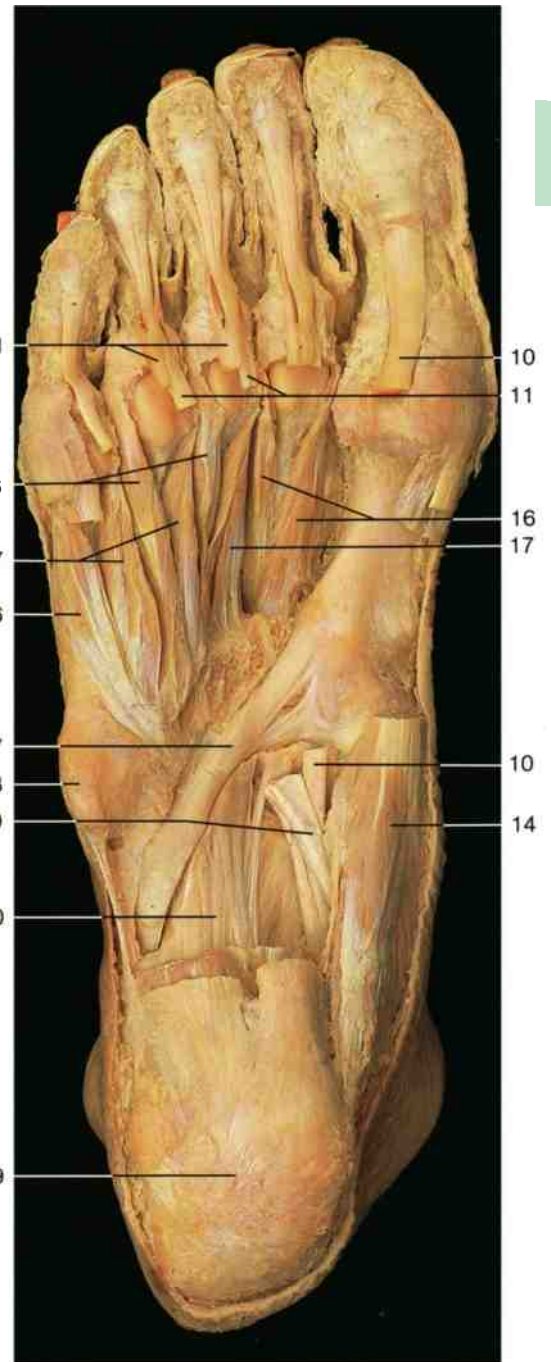
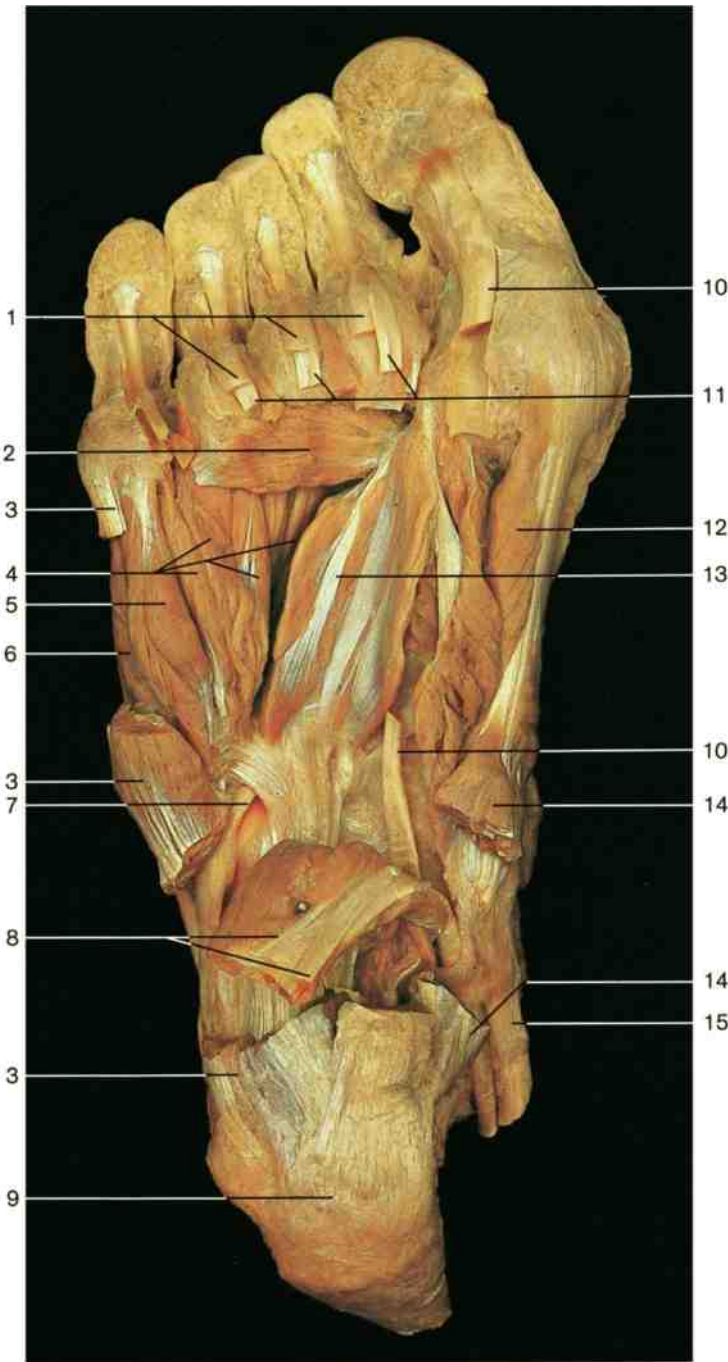


Muscles of sole of foot, second layer (from below). The flexor digitorum brevis muscle has been divided.



Muscles of sole of foot, second layer (from below). The tendons of the flexor muscles and the crossing of tendons are displayed. The flexor digitorum brevis muscle has been divided and reflected.

- | | | |
|---|---|--|
| 1 Tendons of flexor digitorum brevis muscle | 6 Abductor digiti minimi muscle | 13 Tuberosity of fifth metatarsal bone |
| 2 Tendons of flexor digitorum longus muscle | 7 Quadratus plantae muscle | 14 Tendon of peroneus longus muscle |
| 3 Lumbrical muscles | 8 Calcaneal tuberosity | 15 Transverse head of adductor hallucis muscle |
| 4 Interossei muscles | 9 Tendon of flexor hallucis longus muscle | 16 Crossing of tendons in sole of foot |
| 5 Flexor digiti minimi brevis muscle | 10 Flexor hallucis brevis muscle | 17 Medial malleolus |
| | 11 Abductor hallucis muscle | 18 Plantar aponeurosis (divided) |
| | 12 Flexor digitorum brevis muscle (divided) | |



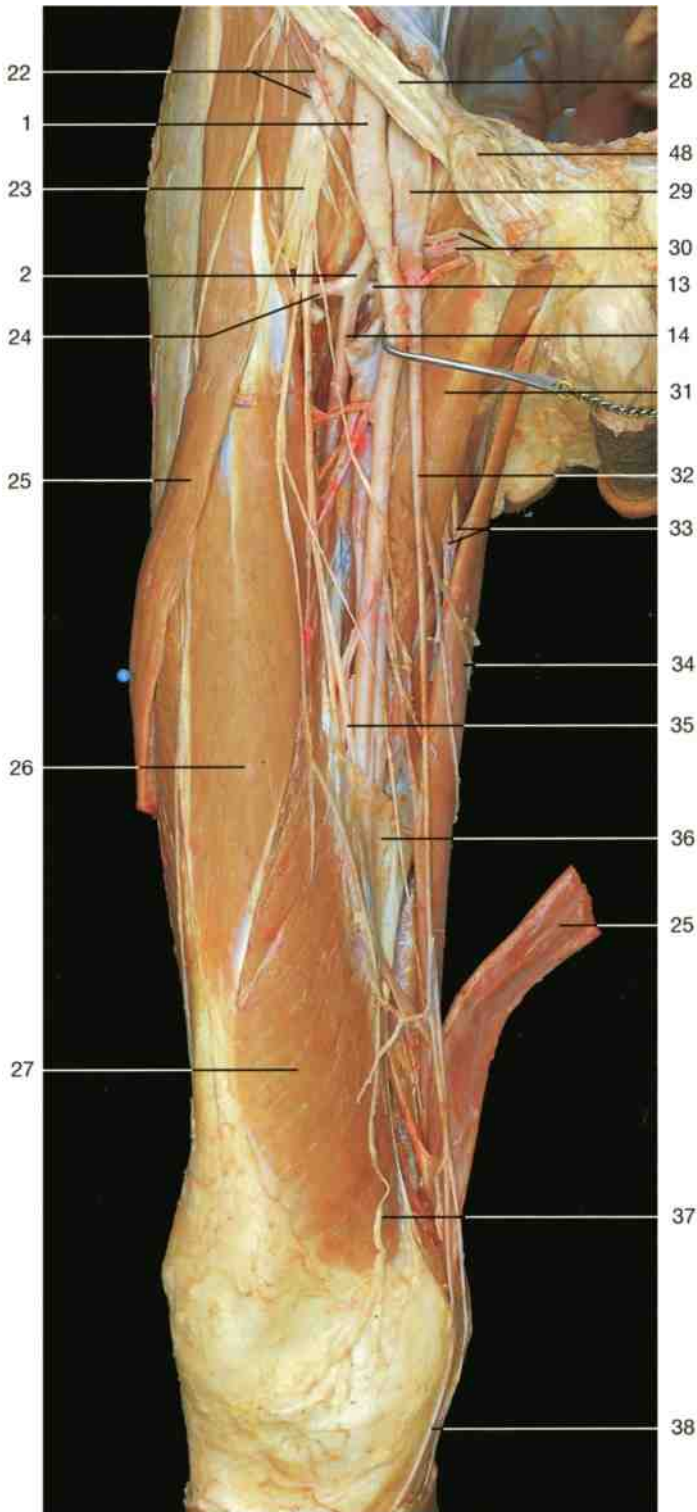
Muscles of sole of foot, third layer (from below). The flexor digitorum brevis muscle has been removed, and the quadratus plantae, abductor hallucis, and digiti minimi muscles have been divided.

Muscles of sole of foot, fourth layer (from below). The interosseous muscles and the canal for the tendon of peroneus longus muscle are shown.

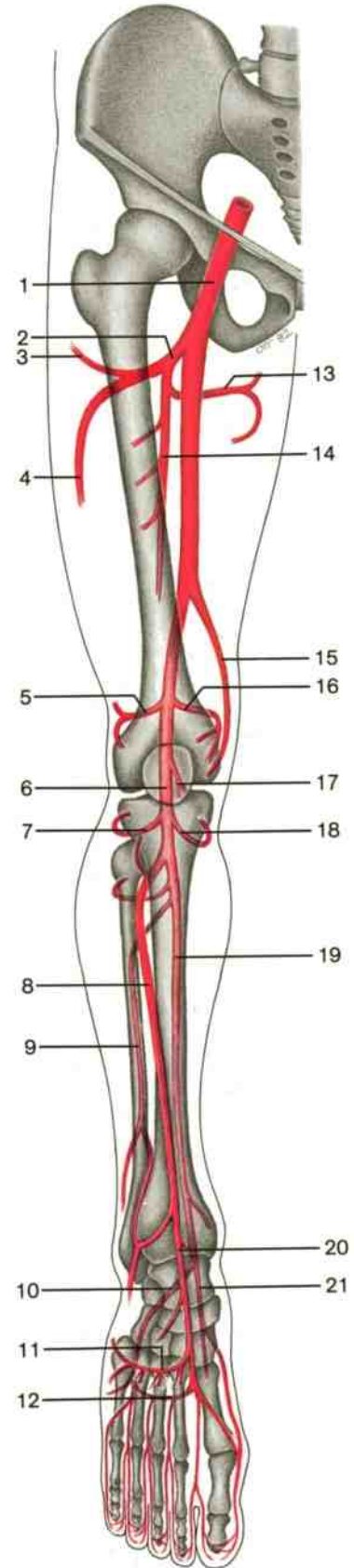
- 1 Tendons of flexor digitorum brevis muscle
- 2 Transverse head of adductor hallucis muscle
- 3 Abductor digiti minimi muscle
- 4 Interossei muscles
- 5 Flexor digiti minimi brevis muscle
- 6 Opponens digiti minimi muscle
- 7 Tendon of peroneus longus muscle

- 8 Quadratus plantae muscle with tendon of flexor digitorum longus muscle
- 9 Calcaneal tuberosity
- 10 Tendons of flexor hallucis longus muscle (divided)
- 11 Tendon of flexor digitorum longus muscle
- 12 Flexor hallucis brevis muscle
- 13 Oblique head of adductor hallucis muscle
- 14 Abductor hallucis muscle (cut)

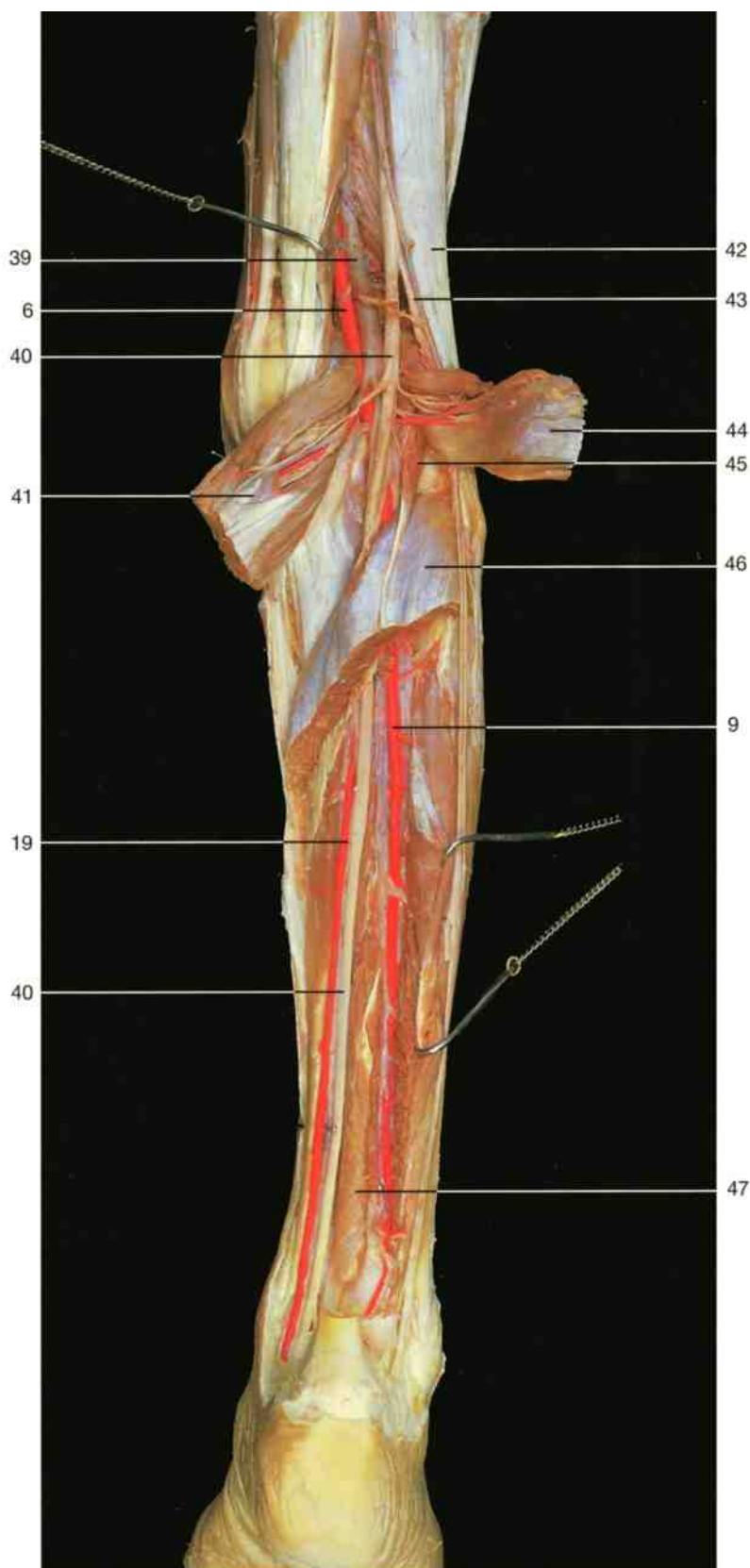
- 15 Tendon of tibialis posterior muscle
- 16 Dorsal interossei muscles
- 17 Plantar interossei muscles
- 18 Tuberosity of fifth metatarsal bone
- 19 Tendon of flexor digitorum longus muscle (crossing of plantar tendons)
- 20 Long plantar ligament



Main arteries and nerves of right thigh (anterior aspect). Sartorius muscle has been divided and reflected. The femoral vein has been partly removed to show the deep femoral artery. Notice: the vessels enter the adductor canal to reach the popliteal fossa.

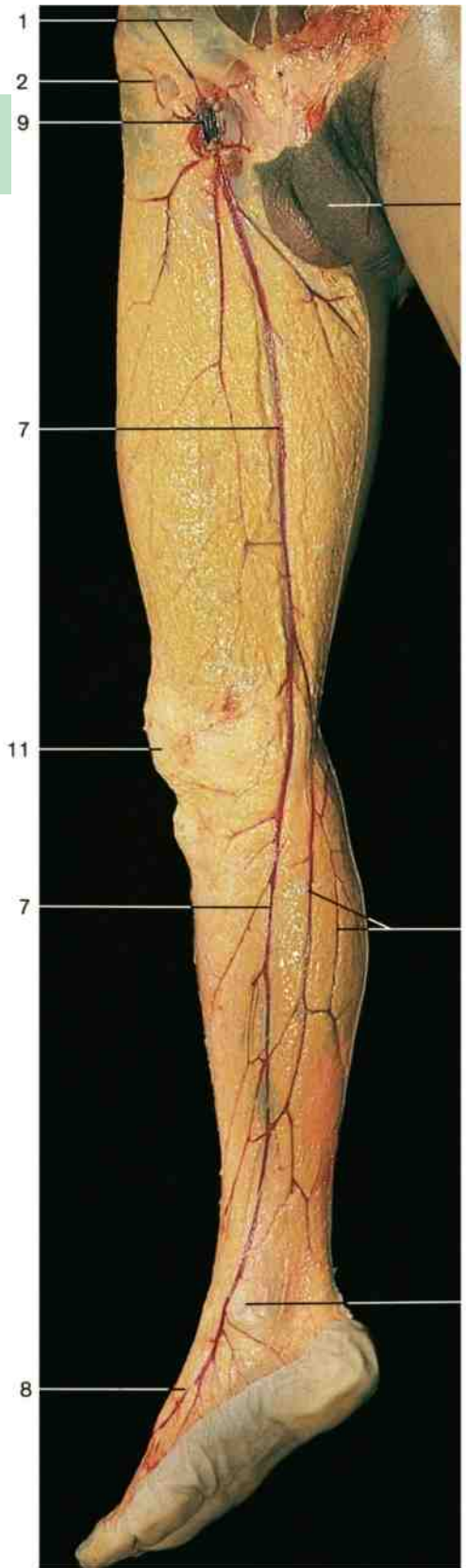


Main arteries of lower limb, right side (anterior aspect, schematic drawing).



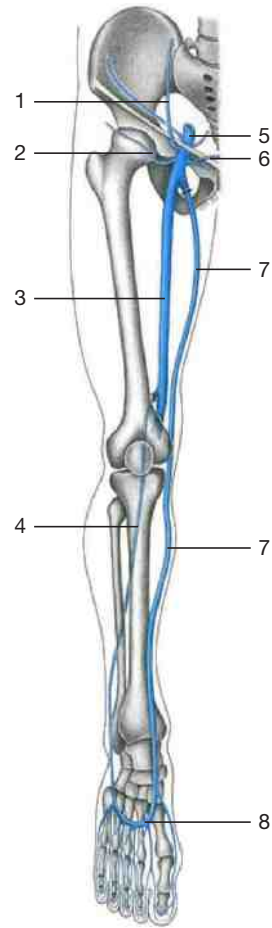
- 1 Femoral artery
- 2 Profunda femoris artery
- 3 Ascending branch of lateral circumflex femoral artery
- 4 Descending branch of lateral circumflex femoral artery
- 5 Lateral superior genicular artery
- 6 Popliteal artery
- 7 Lateral inferior genicular artery
- 8 Anterior tibial artery
- 9 Peroneal artery
- 10 Lateral plantar artery
- 11 Arcuate artery with dorsal metatarsal arteries
- 12 Plantar arch with plantar metatarsal arteries
- 13 Medial circumflex femoral artery
- 14 Profunda femoris artery with perforating arteries
- 15 Descending genicular artery
- 16 Medial superior genicular artery
- 17 Middle genicular artery
- 18 Medial inferior genicular artery
- 19 Posterior tibial artery
- 20 Dorsalis pedis artery
- 21 Medial plantar artery
- 22 Superficial and deep circumflex iliac arteries
- 23 Femoral nerve
- 24 Lateral circumflex femoral artery
- 25 Sartorius muscle (cut and reflected)
- 26 Rectus femoris muscle
- 27 Vastus medialis muscle
- 28 Inguinal ligament
- 29 Femoral vein (cut)
- 30 External pudendal artery and vein
- 31 Adductor longus muscle
- 32 Great saphenous vein
- 33 Obturator artery and nerve
- 34 Gracilis muscle
- 35 Saphenous nerve
- 36 Tendinous wall of adductor canal
- 37 Anterior cutaneous branch of femoral nerve
- 38 Infrapatellar branch of saphenous nerve
- 39 Popliteal vein
- 40 Tibial nerve
- 41 Medial head of gastrocnemius muscle
- 42 Biceps femoris muscle
- 43 Common peroneal nerve
- 44 Lateral head of gastrocnemius muscle
- 45 Plantaris muscle
- 46 Soleus muscle
- 47 Flexor hallucis longus muscle
- 48 Spermatic cord

Arteries of the right leg (posterior aspect).



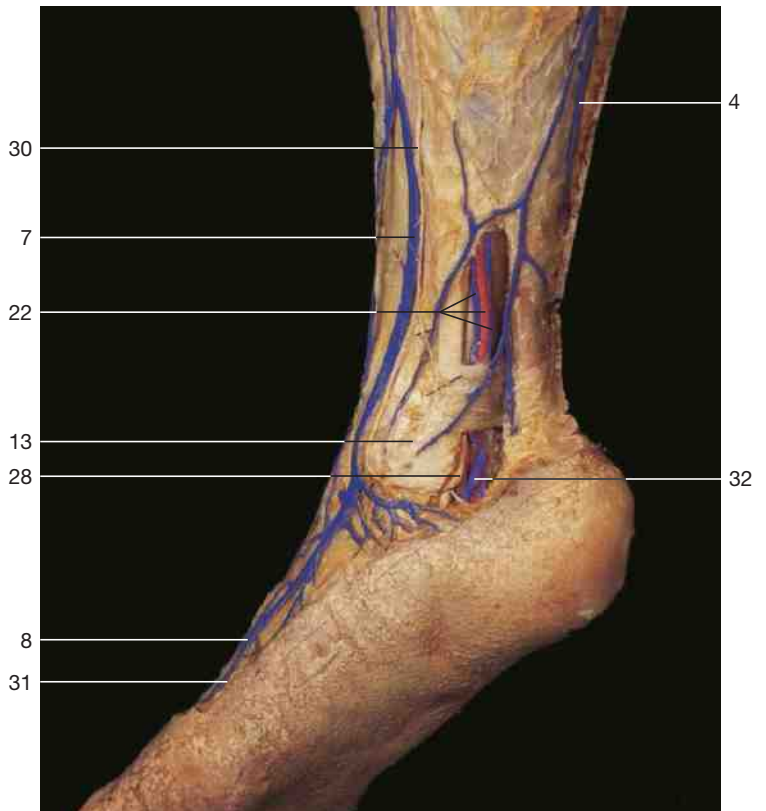
Superficial veins of lower limb, right side (medio-anterior aspect). The veins have been injected with red solution.

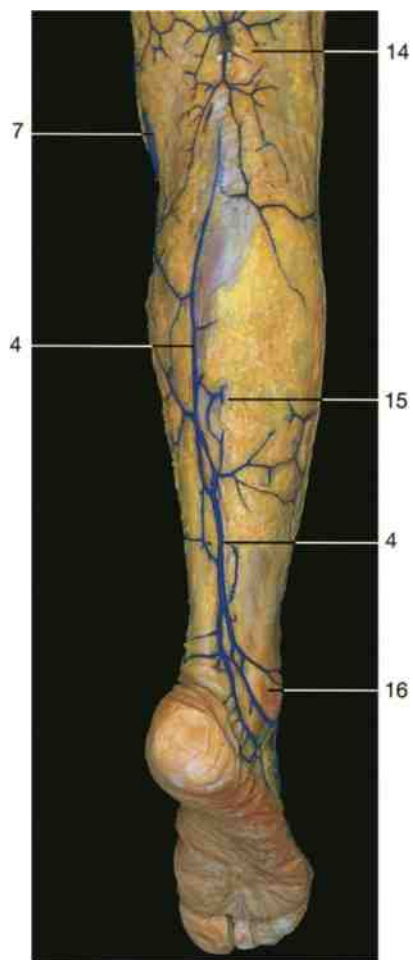
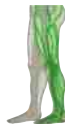Medial malleolar region. Dissection of tibial nerve, posterior tibial vessels, and great saphenous vein (veins injected with blue resin).



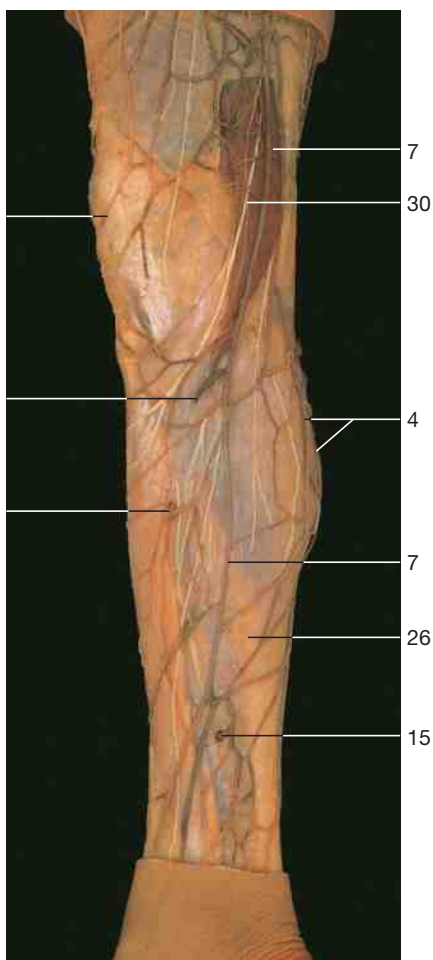
Main veins of lower limb, right side (anterior aspect, schematic drawing).

- 1 Superficial epigastric vein
- 2 Superficial circumflex iliac vein
- 3 Femoral vein
- 4 Small saphenous vein
- 5 External iliac vein
- 6 External pudendal vein
- 7 Great saphenous vein
- 8 Dorsal venous arch
- 9 Saphenous opening with femoral vein
- 10 Venous anastomoses of small saphenous vein with great saphenous vein
- 11 Patella
- 12 Penis
- 13 Medial malleolus
- 14 Popliteal fossa
- 15 Perforating veins
- 16 Lateral malleolus
- 17 Dorsal digital veins of foot
- 18 Dorsal venous arch of foot
- 19 Dorsal metatarsal veins
- 20 Anterior tibial artery and veins
- 21 Tibia
- 22 Posterior tibial artery and veins
- 23 Fibula
- 24 Peroneal artery and vein
- 25 Deep layer of crural fascia
- 26 Superficial layer of crural fascia
- 27 Perforating veins I-III (of Cockett)
- 28 Tibial nerve
- 29 Arcuate vein
- 30 Saphenous nerve
- 31 Medial dorsal cutaneous nerve (branch of superficial peroneal nerve)
- 32 Posterior tibial vein

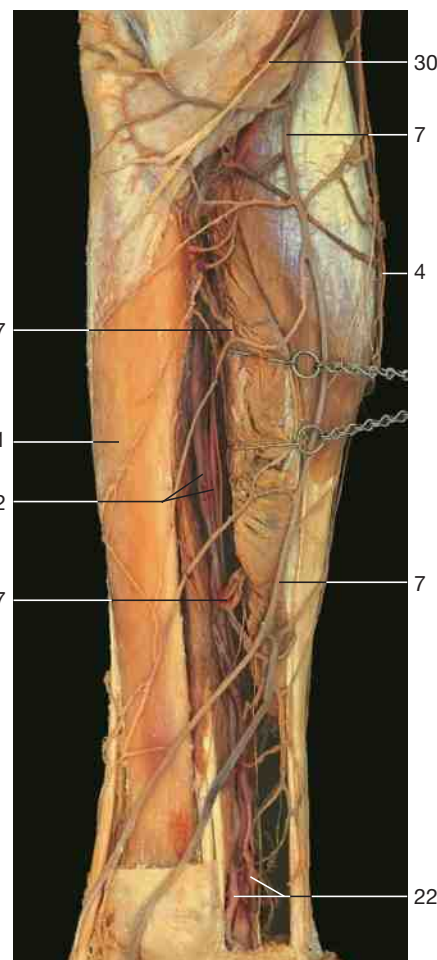




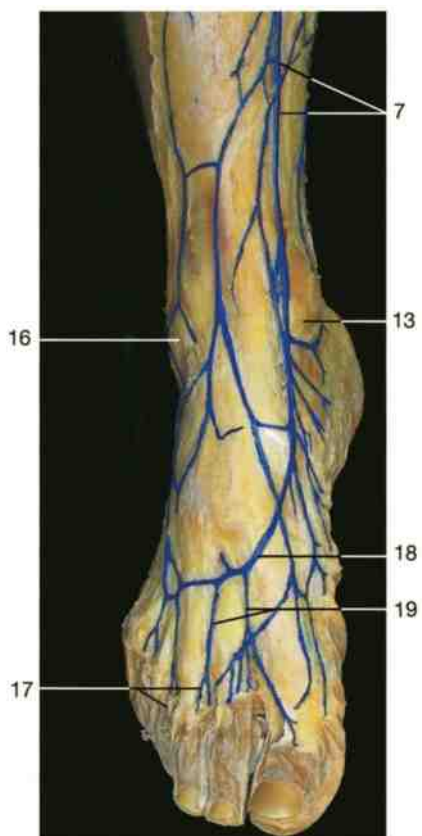
Superficial veins of leg (posterior aspect; veins injected with blue resin).



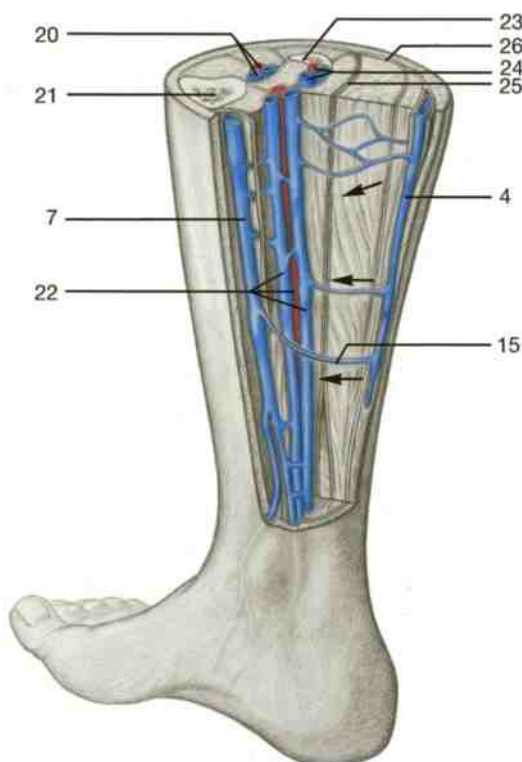Superficial veins of leg. The perforating veins of Cockett have been dissected (left side, medial aspect).



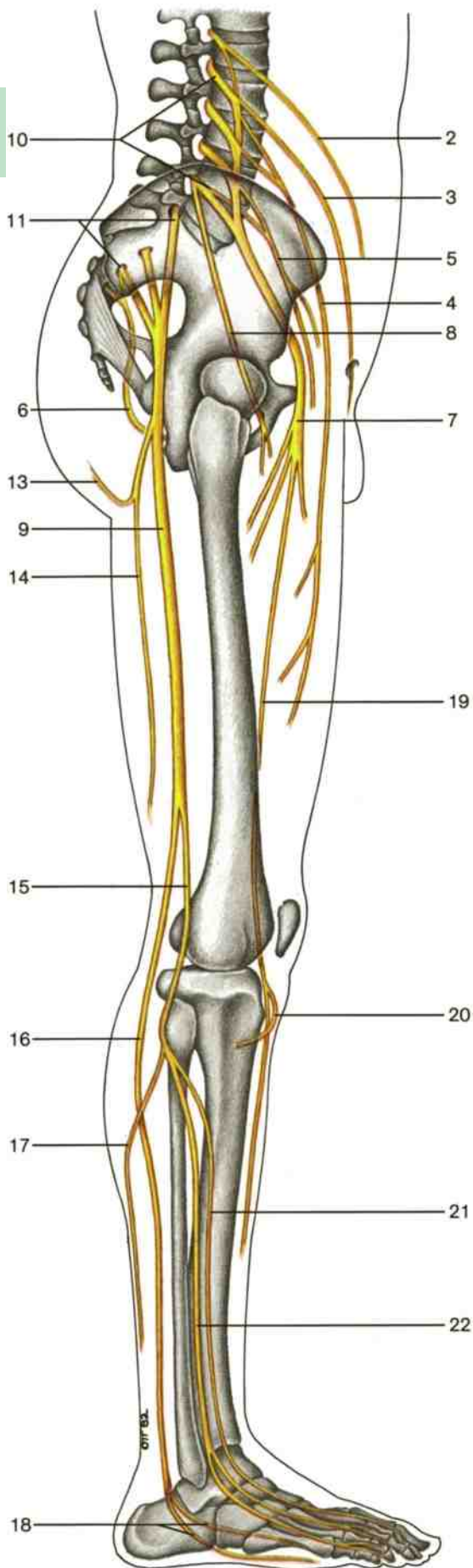
Veins of leg. The anastomoses between superficial and deeper veins are dissected (left side, medial aspect).



Anastomoses between superficial and deep veins of the leg (schematic drawing, after Aigner).
Arrows: directions of blood flow.

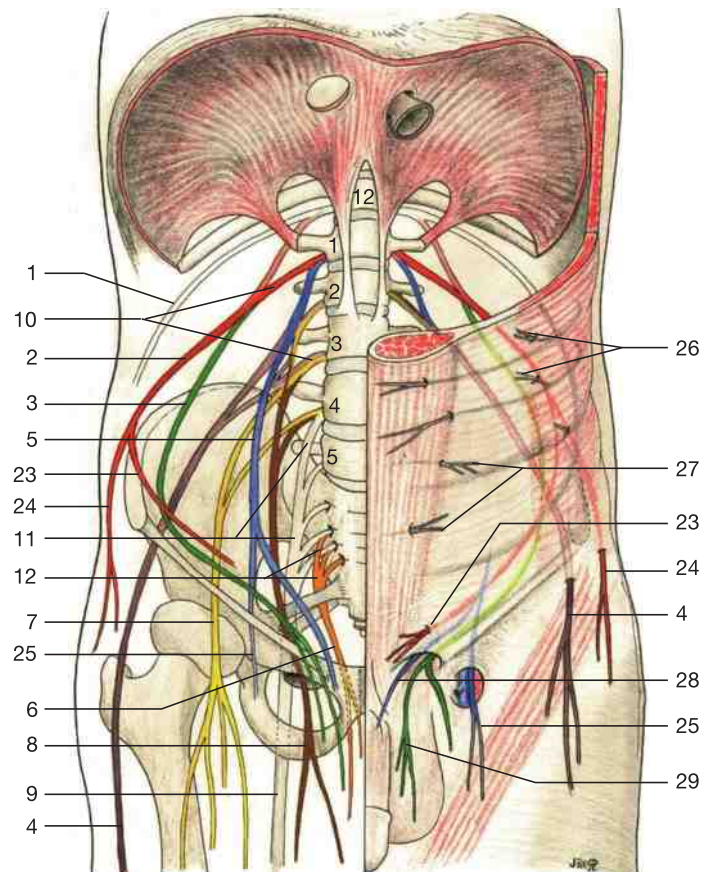


◁ **Superficial veins on dorsum of foot** (veins injected with blue resin).

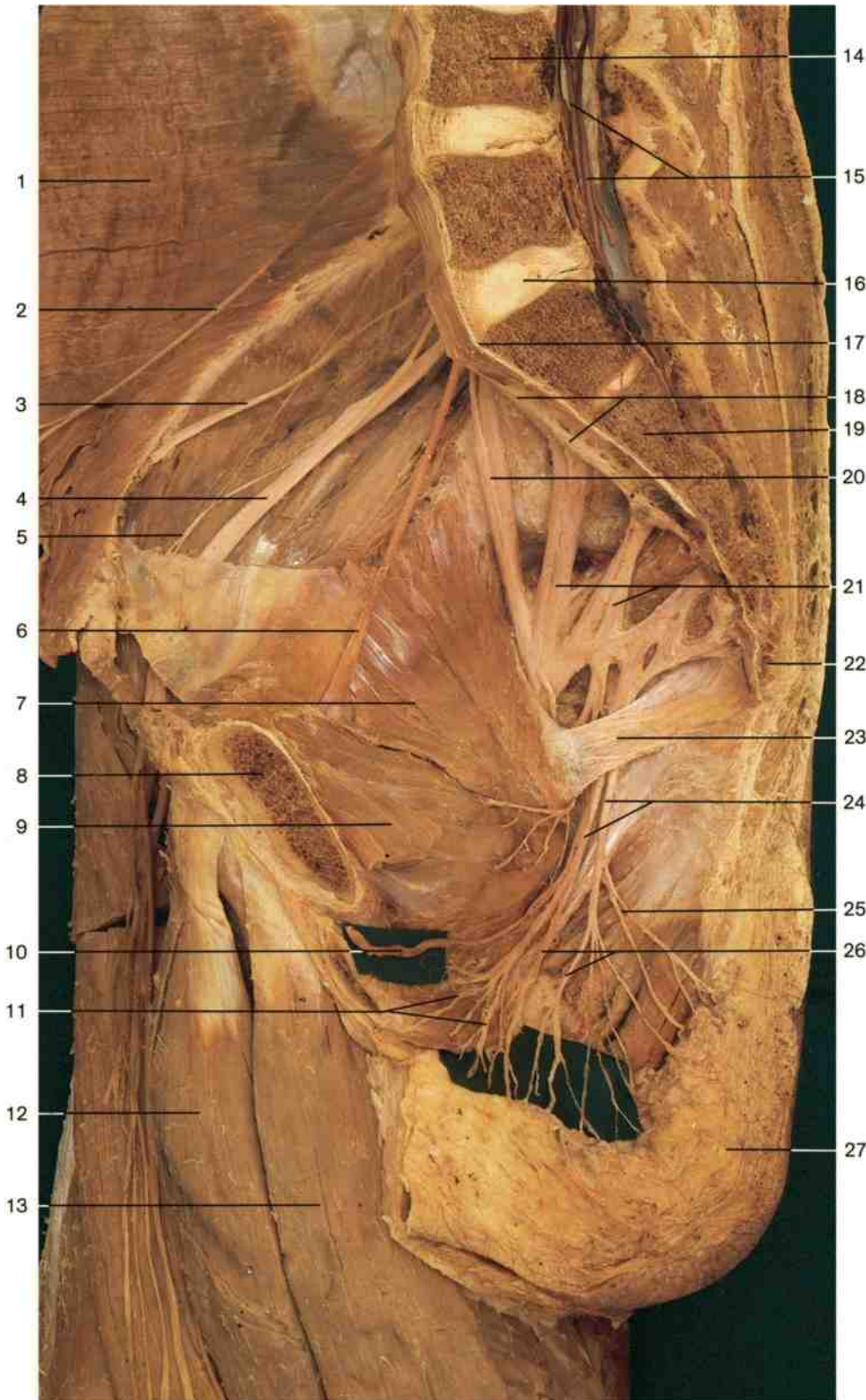

Nerves of lower limb, right side (lateral aspect).
(Schematic drawing.)

- 1 Subcostal nerve
- 2 Iliohypogastric nerve
- 3 Ilio-inguinal nerve
- 4 Lateral femoral cutaneous nerve
- 5 Genitofemoral nerve
- 6 Pudendal nerve
- 7 Femoral nerve
- 8 Obturator nerve
- 9 Sciatic nerve
- 10 Lumbar plexus (L₁-L₄)
- 11 Sacral plexus (L₄-S₄)
- 12 "Pudendal" plexus (S₂-S₄)
- 13 Inferior cluneal nerves
- 14 Posterior femoral cutaneous nerve
- 15 Common peroneal nerve
- 16 Tibial nerve
- 17 Lateral sural cutaneous nerve
- 18 Medial and lateral plantar nerves
- 19 Saphenous nerve
- 20 Infrapatellar branch of saphenous nerve
- 21 Deep peroneal nerve
- 22 Superficial peroneal nerve
- 23 Anterior cutaneous branch of iliohypogastric nerve
- 24 Lateral cutaneous branch of iliohypogastric nerve
- 25 Femoral branch of genitofemoral nerve
- 26 Lateral cutaneous branches of intercostal nerve
- 27 Anterior cutaneous branches of intercostal nerve
- 28 Genital branch of genitofemoral nerve
- 29 Anterior scrotal nerve



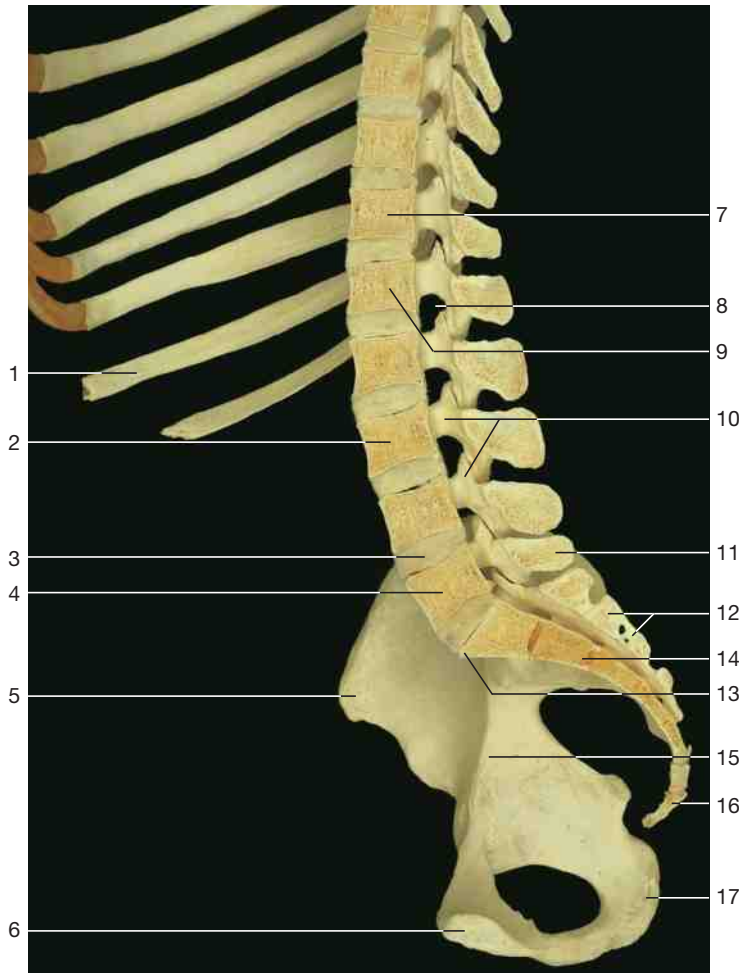
Main branches of lumbosacral plexus (ventral aspect).
(Schematic drawing.)



- 1 Transversus abdominis muscle
- 2 Iliohypogastric nerve
- 3 Ilio-inguinal nerve
- 4 Femoral nerve
- 5 Lateral femoral cutaneous nerve
- 6 Obturator nerve
- 7 Obturator internus muscle
- 8 Pubic bone (cut edge)
- 9 Levator ani muscle (remnant)
- 10 Dorsal nerve of penis
- 11 Posterior scrotal nerves
- 12 Adductor longus muscle
- 13 Gracilis muscle
- 14 Body of fourth lumbar vertebra
- 15 Cauda equina
- 16 Intervertebral disc
- 17 Sacral promontory
- 18 Sympathetic trunk
- 19 Sacrum
- 20 Lumbosacral trunk
- 21 Sacral plexus
- 22 Coccyx
- 23 Sacrospinous ligament
- 24 Pudendal nerve
- 25 Inferior rectal nerves
- 26 Perineal nerves
- 27 Subcutaneous fat tissue of gluteal region

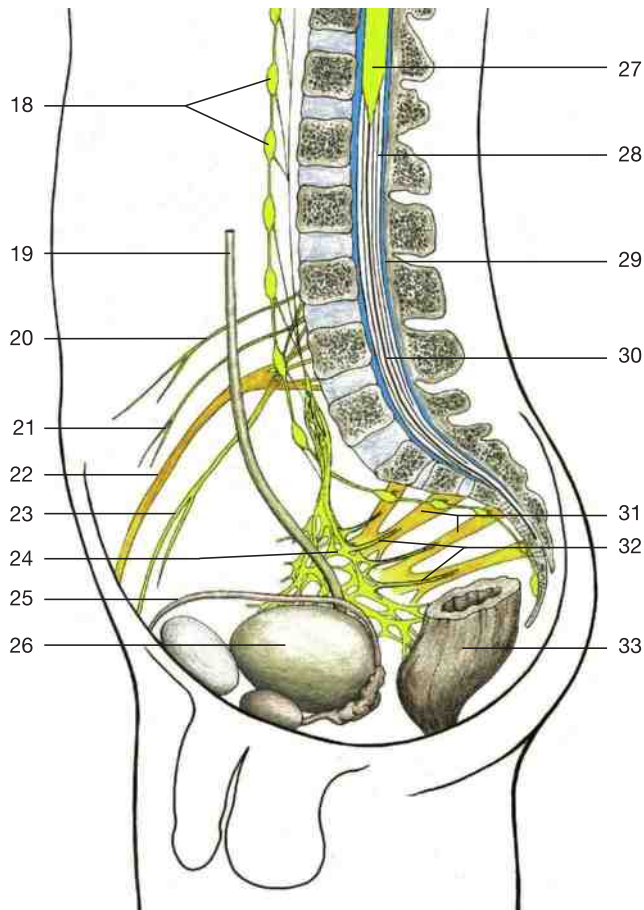
Lumbosacral plexus in situ, right side (medial aspect).

Pelvic organs with peritoneum and part of the levator ani muscle have been removed.

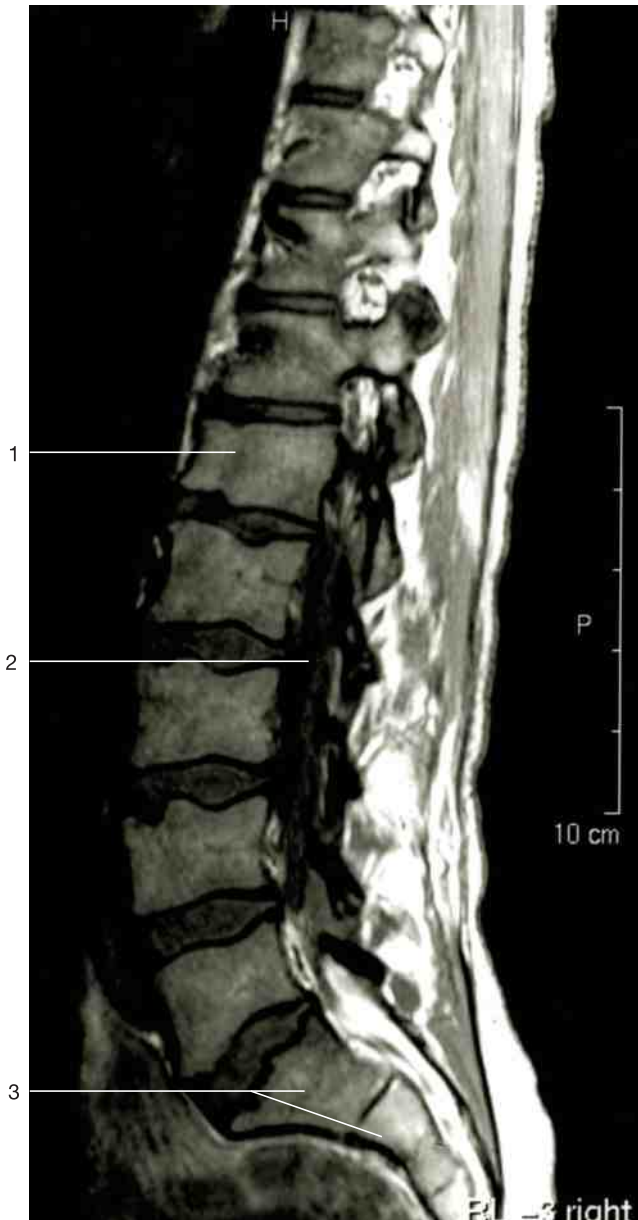

Lumbar part of vertebral column with pelvis
(sagittal section, medial aspect).

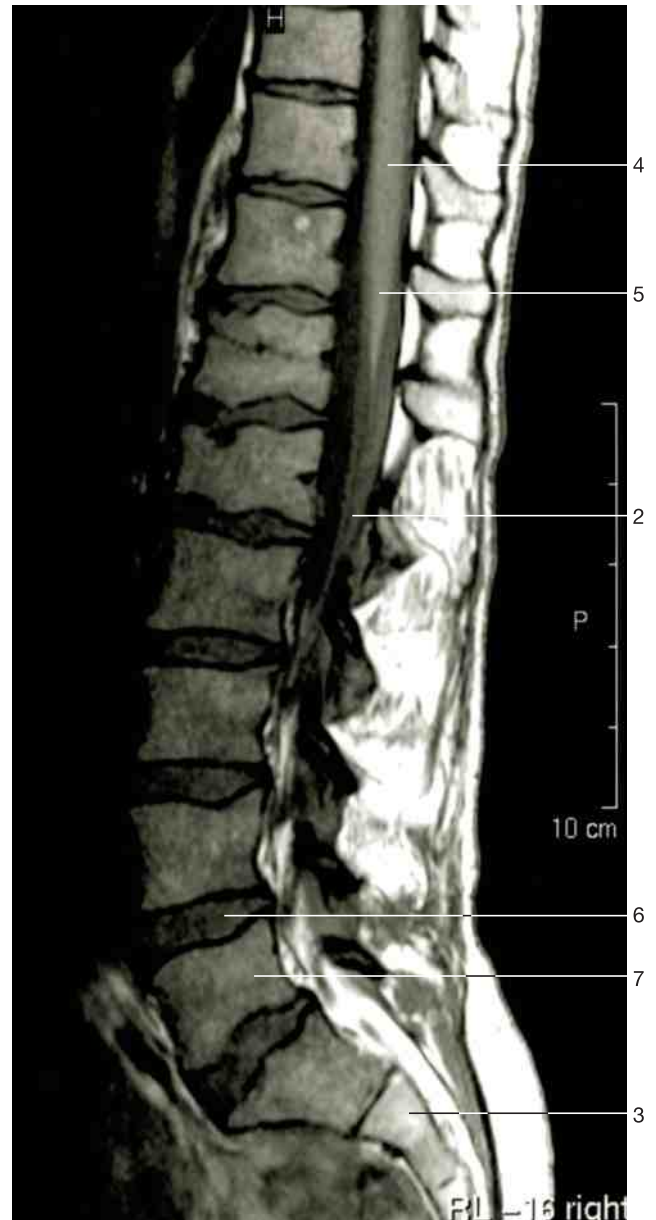
- 1 Eleventh rib
- 2 Body of third lumbar vertebra
- 3 Intervertebral disc
- 4 Body of fifth lumbar vertebra
- 5 Anterior superior iliac spine
- 6 Symphyseal surface
- 7 Body of twelfth thoracic vertebra
- 8 Intervertebral foramen
- 9 Body of first lumbar vertebra
- 10 Vertebral canal
- 11 Spinous process of fifth lumbar vertebra
- 12 Sacrum (median sacral crest)
- 13 Promontory (promontorium)
- 14 Sacrum
- 15 Arcuate line
- 16 Coccyx
- 17 Ischial tuberosity
- 18 Sympathetic trunk with ganglia
- 19 Ureter
- 20 Iliohypogastric nerve (Th₁₂, L₁)
- 21 Ilio-inguinal nerve (L₁)
- 22 Femoral nerve (L₂-L₄)
- 23 Genitofemoral nerve (L₁, L₂)
- 24 Inferior hypogastric plexus
- 25 Ductus deferens
- 26 Urinary bladder
- 27 Medullary cone of spinal cord
- 28 Root filaments of spinal nerves
- 29 Subarachnoid space
(filled with cerebrospinal fluid) (blue)
- 30 Terminal filament of spinal cord
- 31 Sacral plexus
- 32 Pelvic splanchnic nerves (nervi erigentes)
- 33 Rectum



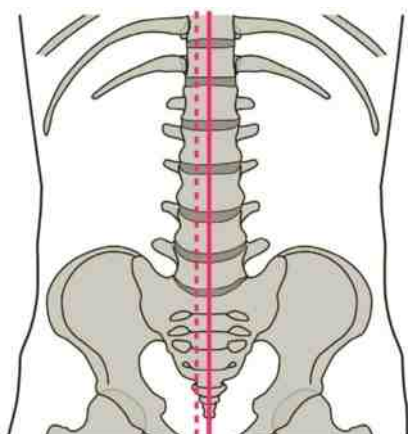
Vertebral canal with spinal cord and root filaments.
Note the high location of the medullary cone. Sacral plexus and inferior hypogastric plexus are schematically shown.



Paramedian section of lumbar part of vertebral canal (MRI scan, dotted line in the schematic drawing below; courtesy of Prof. Bautz, Erlangen, Germany).

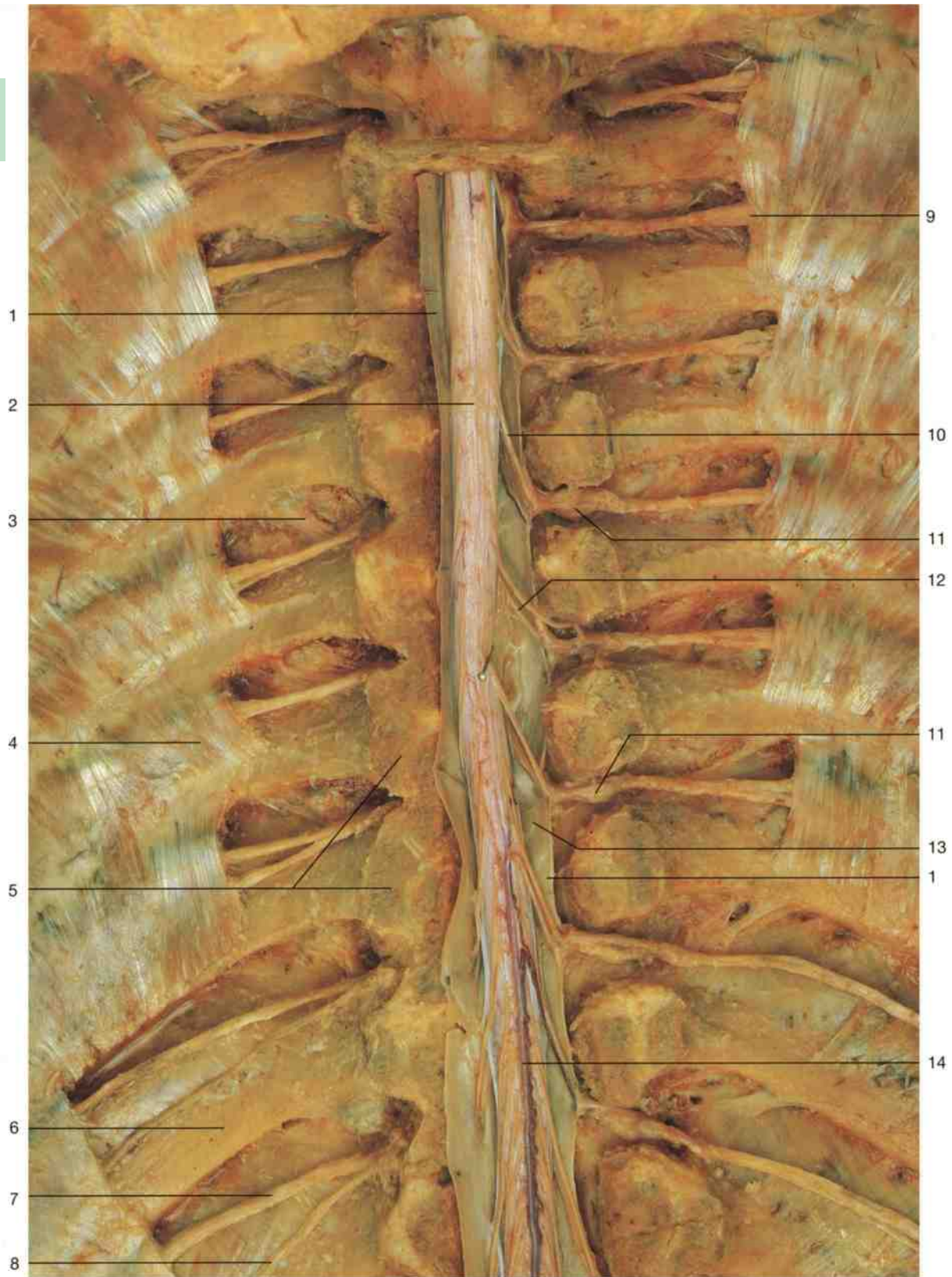


Median section of lumbar part of vertebral canal at the level of the medullary cone (MRI scan, continuous line in the schematic drawing below; courtesy of Prof. Bautz, Erlangen, Germany).



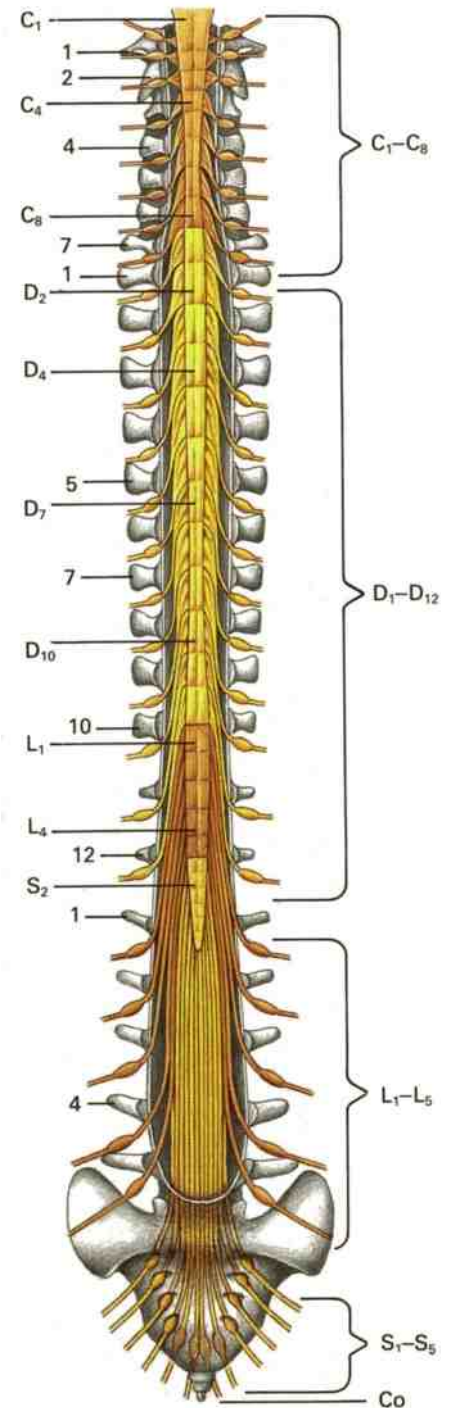
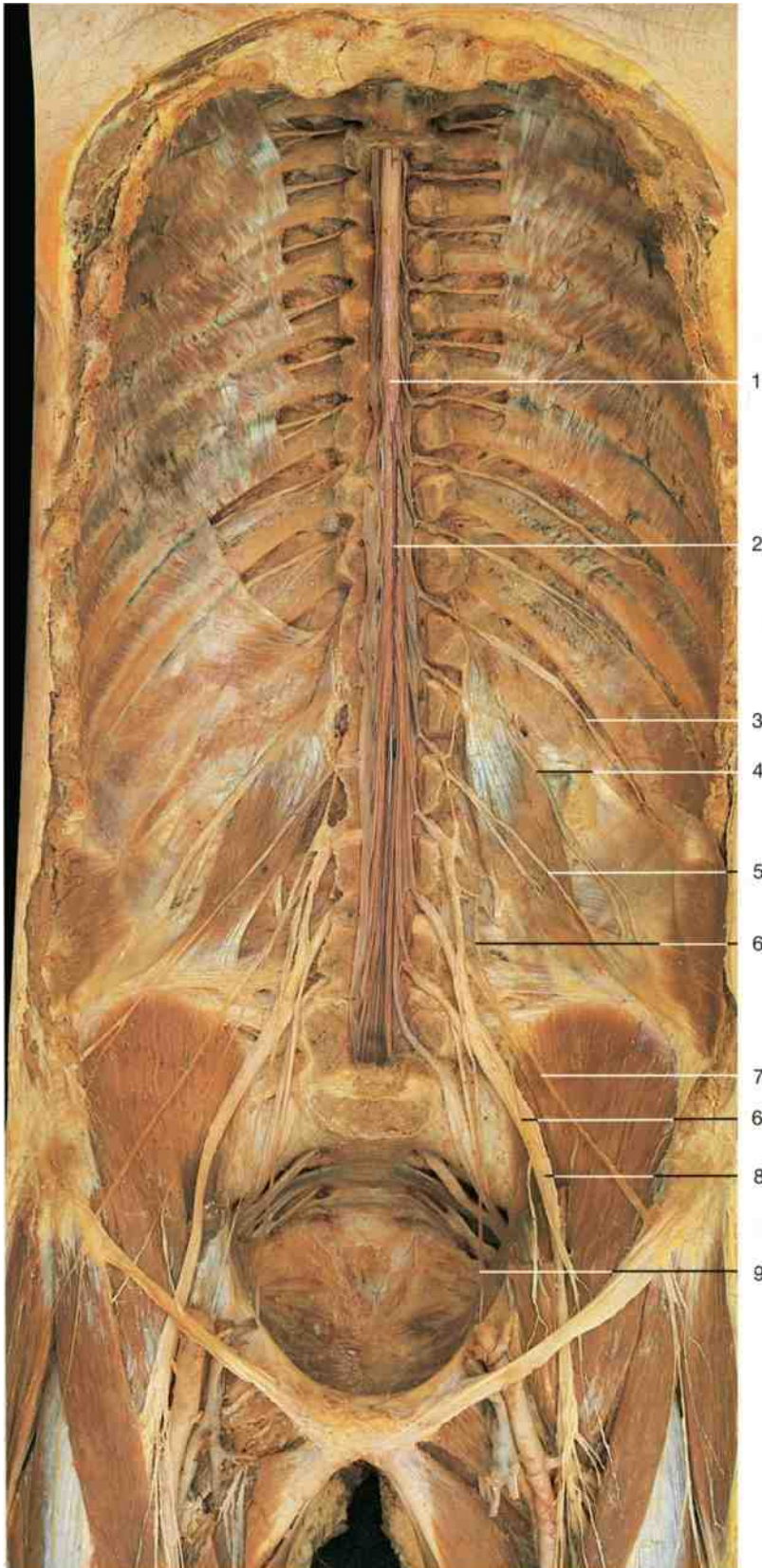
- 1 First lumbar vertebra
- 2 Root filaments of spinal nerves
- 3 Sacrum
- 4 Spinal cord
- 5 Medullary cone of spinal cord
- 6 Intervertebral disc between fourth and fifth lumbar vertebra
- 7 Fifth lumbar vertebra

Location of the sections shown above through the vertebral canal.



Spinal cord with intercostal nerves. Inferior thoracic region (anterior aspect). Anterior portion of thoracic vertebrae removed, dural sheath opened, and spinal cord slightly reflected to the right to display the dorsal and ventral roots.

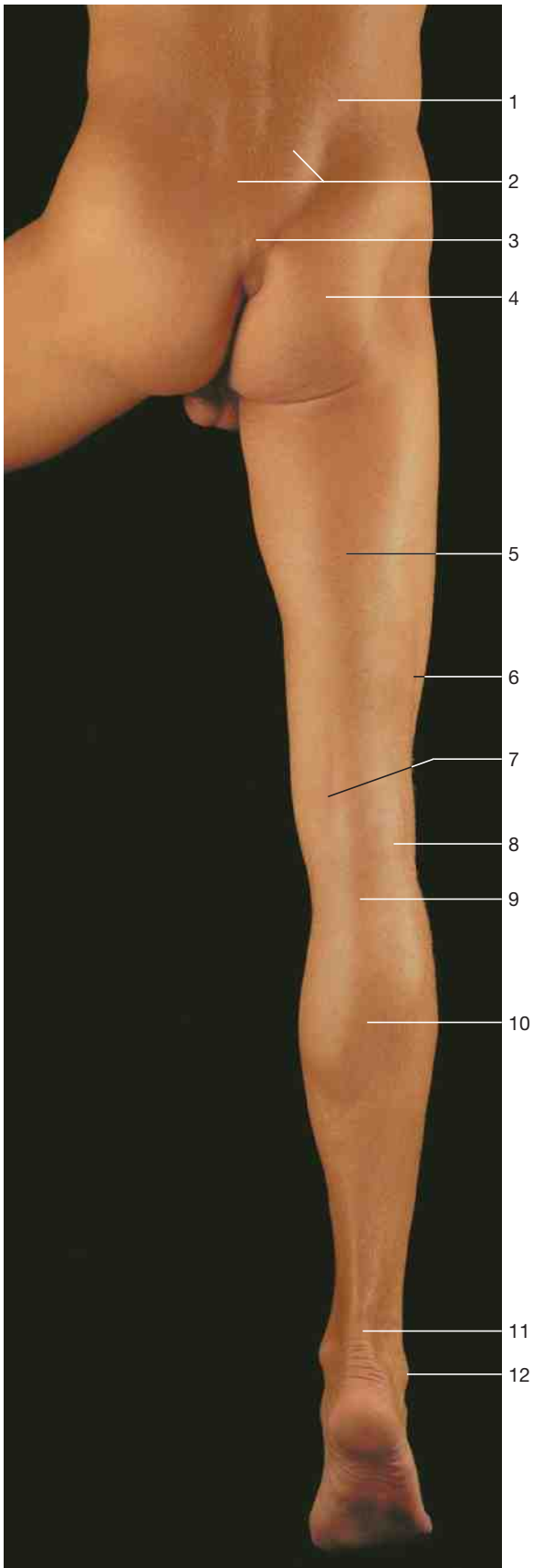
- | | | |
|-----------------------------------|---|---|
| 1 Dura mater | 6 Eleventh rib | 10 Anterior root filaments |
| 2 Spinal cord | 7 Intercostal nerve | 11 Spinal (dorsal root) ganglion |
| 3 Costotransverse ligament | 8 Collateral branch of intercostal nerve | 12 Posterior root filaments |
| 4 Innermost intercostal muscle | 9 Intercostal nerve (entering the intermuscular interval) | 13 Arachnoid mater and denticulate ligament |
| 5 Vertebral arches (cut surfaces) | | 14 Anterior spinal artery |



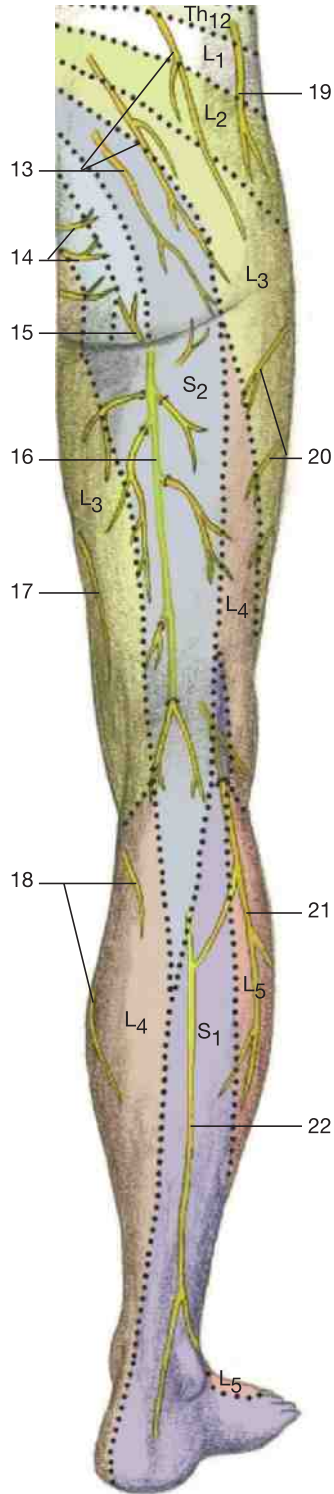
Organization of spinal cord segments in relation to the vertebral column (anterior aspect).
 C = cervical; D = thoracic;
 L = lumbar; S = sacral segments;
 Co = coccygeal bone.
 Numbers indicate the related vertebrae.

Spinal cord and lumbar plexus in situ (anterior aspect).

- | | |
|-------------------------|-----------------------------------|
| 1 Conus medullaris | 6 Genitofemoral nerve |
| 2 Filum terminale | 7 Lateral femoral cutaneous nerve |
| 3 Subcostal nerve | 8 Femoral nerve |
| 4 Iliohypogastric nerve | 9 Obturator nerve |
| 5 Ilio-inguinal nerve | |

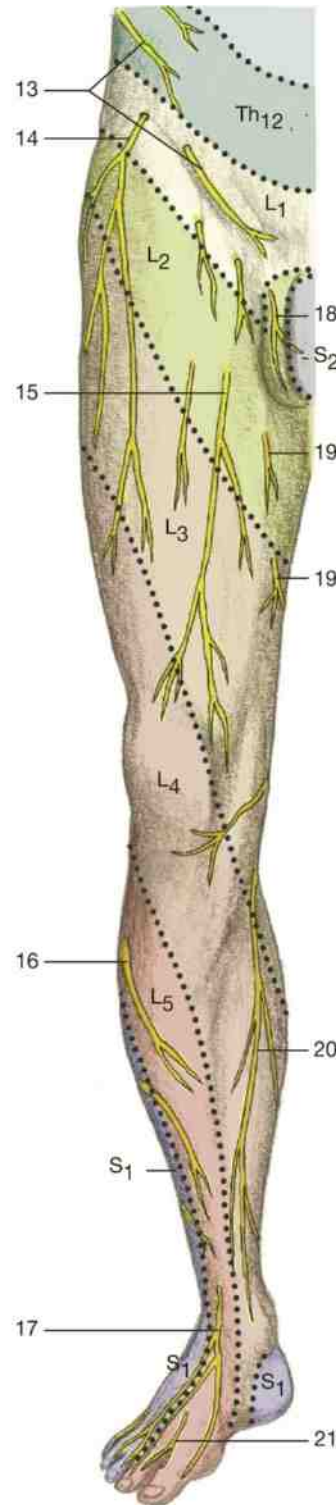
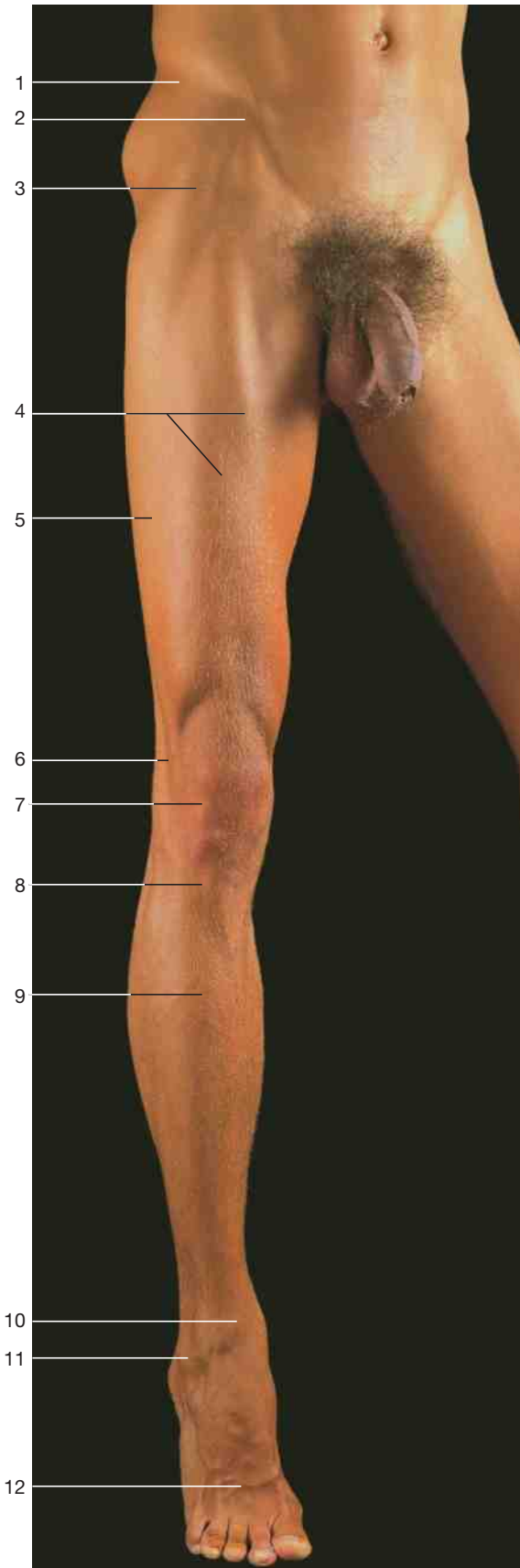
Surface anatomy of the right leg (posterior aspect).
Gluteal muscles contracted.



- 1 Iliac crest
- 2 Sacrum
- 3 Coccyx
- 4 Gluteus maximus muscle
- 5 Dorsal muscles of the leg
- 6 Iliotibial tract
- 7 Tendon of semimembranosus muscle
- 8 Tendon of biceps femoris muscle
- 9 Popliteal fossa
- 10 Triceps surae muscle
- 11 Calcaneal or Achilles tendon
- 12 Lateral malleolus
- 13 Superior cluneal nerves
- 14 Middle cluneal nerves
- 15 Inferior cluneal nerves
- 16 Posterior femoral cutaneous nerve
- 17 Obturator nerve
- 18 Saphenous nerve
- 19 Iliohypogastric nerve
- 20 Branch of lateral femoral cutaneous nerves
- 21 Common peroneal nerve
- 22 Sural nerve

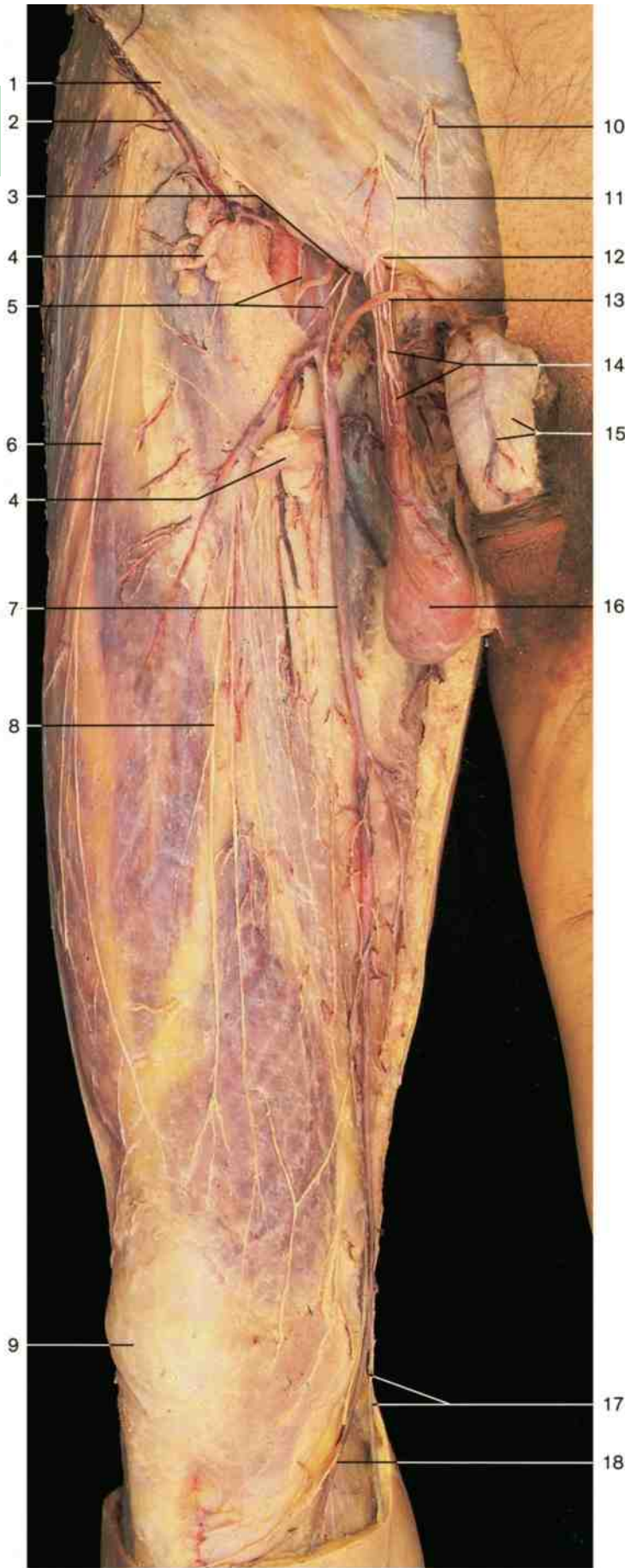
Cutaneous nerves of the lower limb (posterior aspect).
Dotted lines = border of segments.



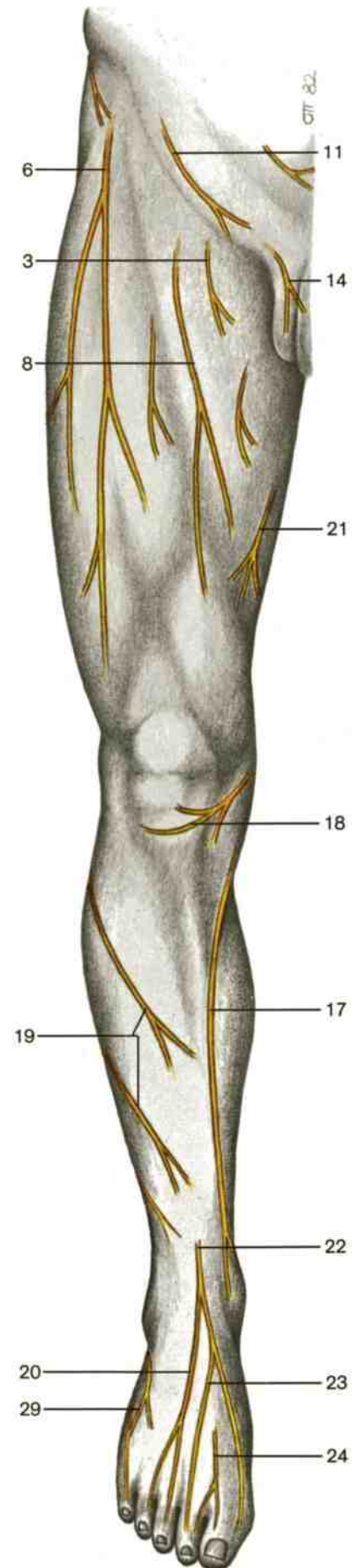
- 1 Iliac crest
- 2 Anterior superior iliac spine
- 3 Tensor fasciae latae muscle
- 4 Quadriceps femoris muscle
- 5 Iliotibial tract
- 6 Tendon of biceps femoris muscle
- 7 Patella
- 8 Patellar ligament
- 9 Tibia
- 10 Tendon of tibialis anterior muscle
- 11 Lateral malleolus
- 12 Venous network of dorsum of foot
- 13 Iliohypogastric nerve
- 14 Lateral femoral cutaneous nerve
- 15 Femoral nerve
- 16 Common peroneal nerve
- 17 Superficial peroneal nerve
- 18 Ilio-inguinal nerve
- 19 Obturator nerve
- 20 Saphenous nerve
- 21 Deep peroneal nerve

Cutaneous nerves of the lower limb (anterior aspect).
Dotted lines = border of segments.

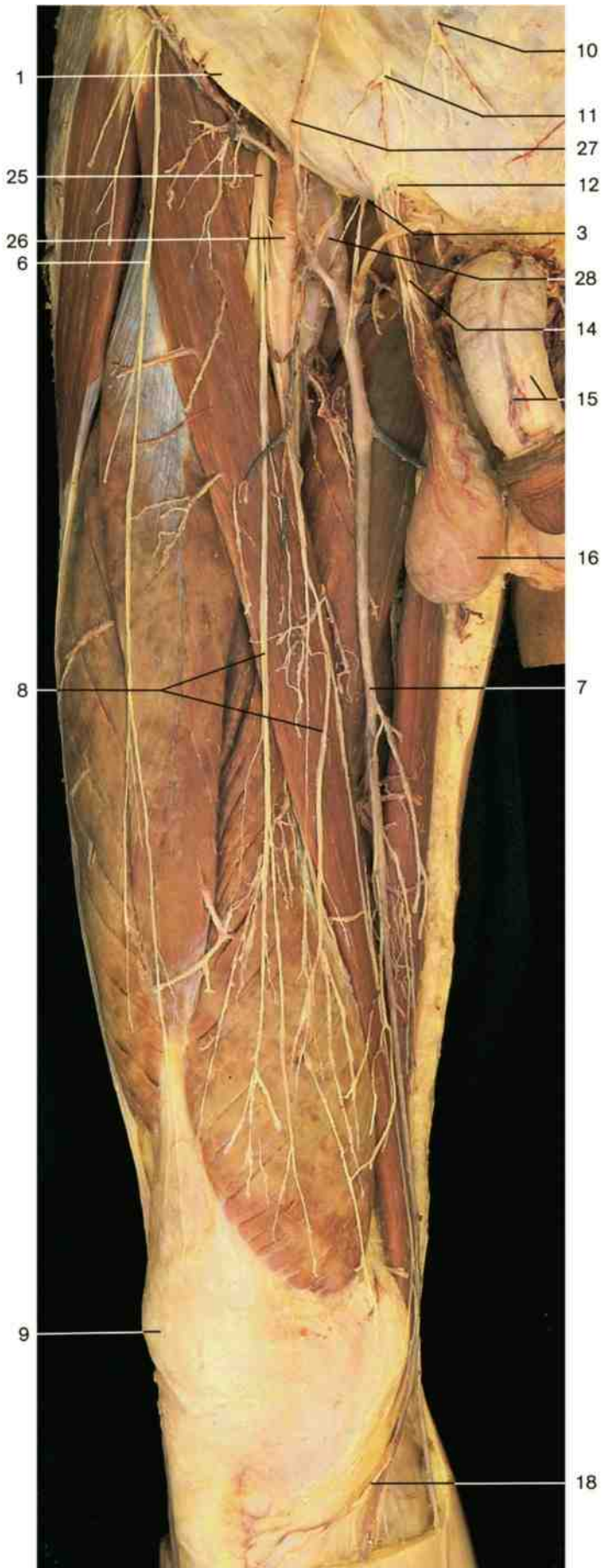
Surface anatomy of the right leg (anterior aspect).



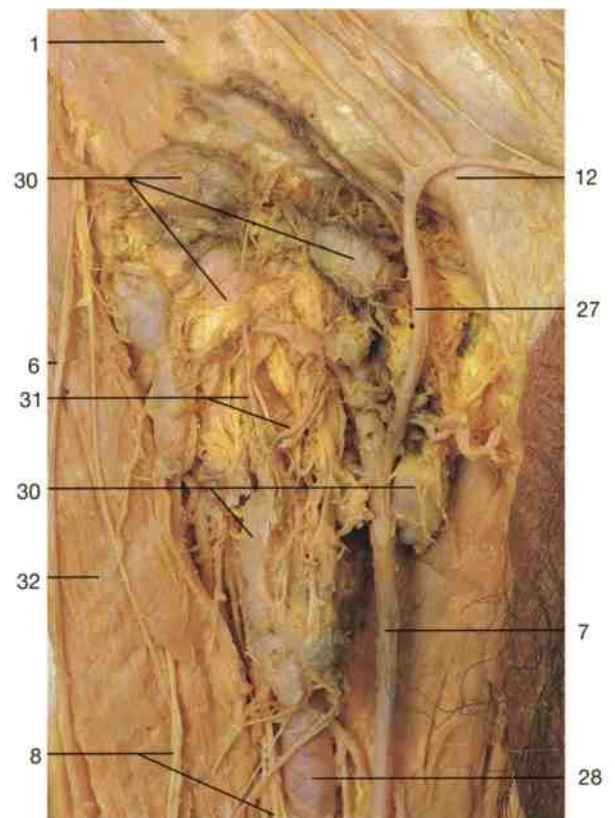
Cutaneous nerves and veins of thigh (anterior aspect).



Cutaneous nerves of lower limb (anterior aspect). (Schematic drawing.)

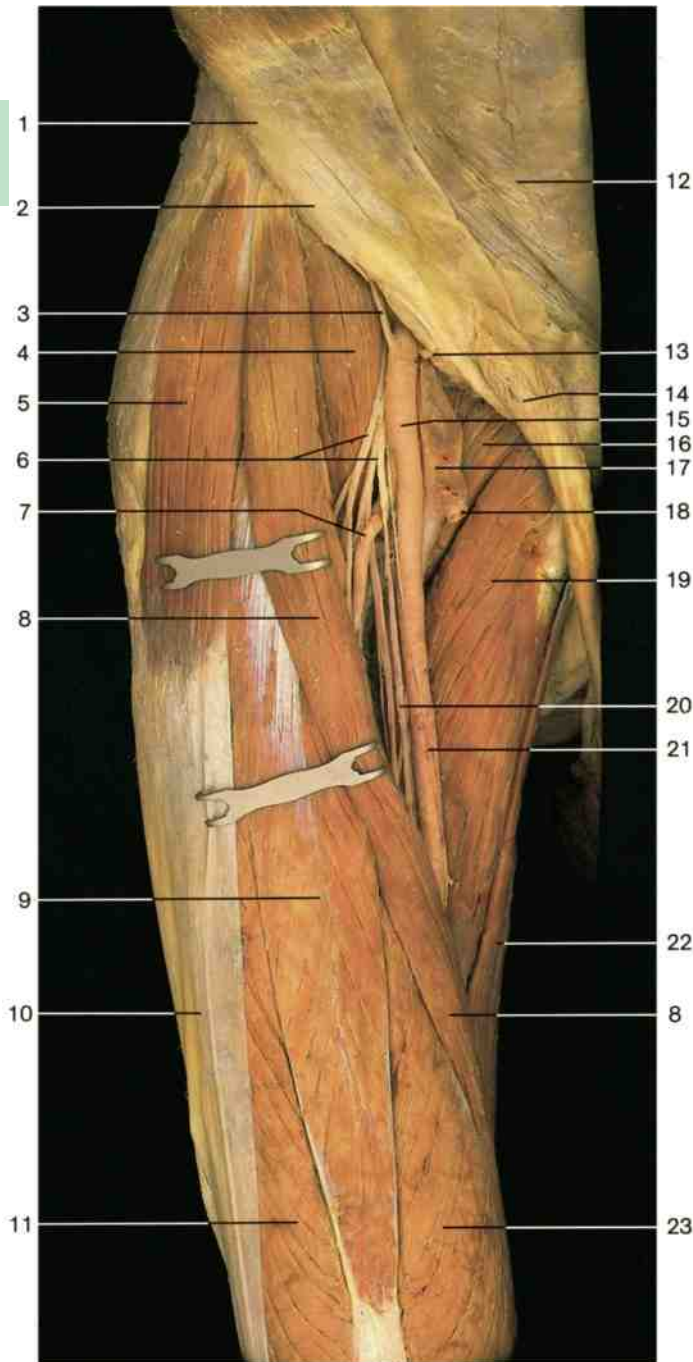


- 1 Inguinal ligament
- 2 Superficial circumflex iliac vein
- 3 Femoral branch of genitofemoral nerve
- 4 Superficial inguinal lymph nodes
- 5 Saphenous opening with femoral artery and vein
- 6 Lateral femoral cutaneous nerve
- 7 Great saphenous vein
- 8 Anterior cutaneous branches of femoral nerve
- 9 Patella
- 10 Terminal branches of subcostal nerve
- 11 Terminal branches of iliohypogastric nerve
- 12 Superficial inguinal ring
- 13 External pudendal vein
- 14 Spermatic cord with genital branch of genitofemoral nerve
- 15 Penis with superficial dorsal vein of penis
- 16 Testis and its coverings
- 17 Saphenous nerve
- 18 Infrapatellar branch of saphenous nerve
- 19 Lateral sural cutaneous nerves
- 20 Intermediate dorsal cutaneous branch of superficial peroneal nerve
- 21 Cutaneous branch of obturator nerve
- 22 Superficial peroneal nerve
- 23 Medial dorsal cutaneous branch of superficial peroneal nerve
- 24 Deep peroneal nerve
- 25 Femoral nerve
- 26 Femoral artery
- 27 Superficial epigastric vein
- 28 Femoral vein
- 29 Lateral dorsal cutaneous branch of sural nerve
- 30 Inguinal nodes (enlarged)
- 31 Lymphatic vessels
- 32 Sartorius muscle



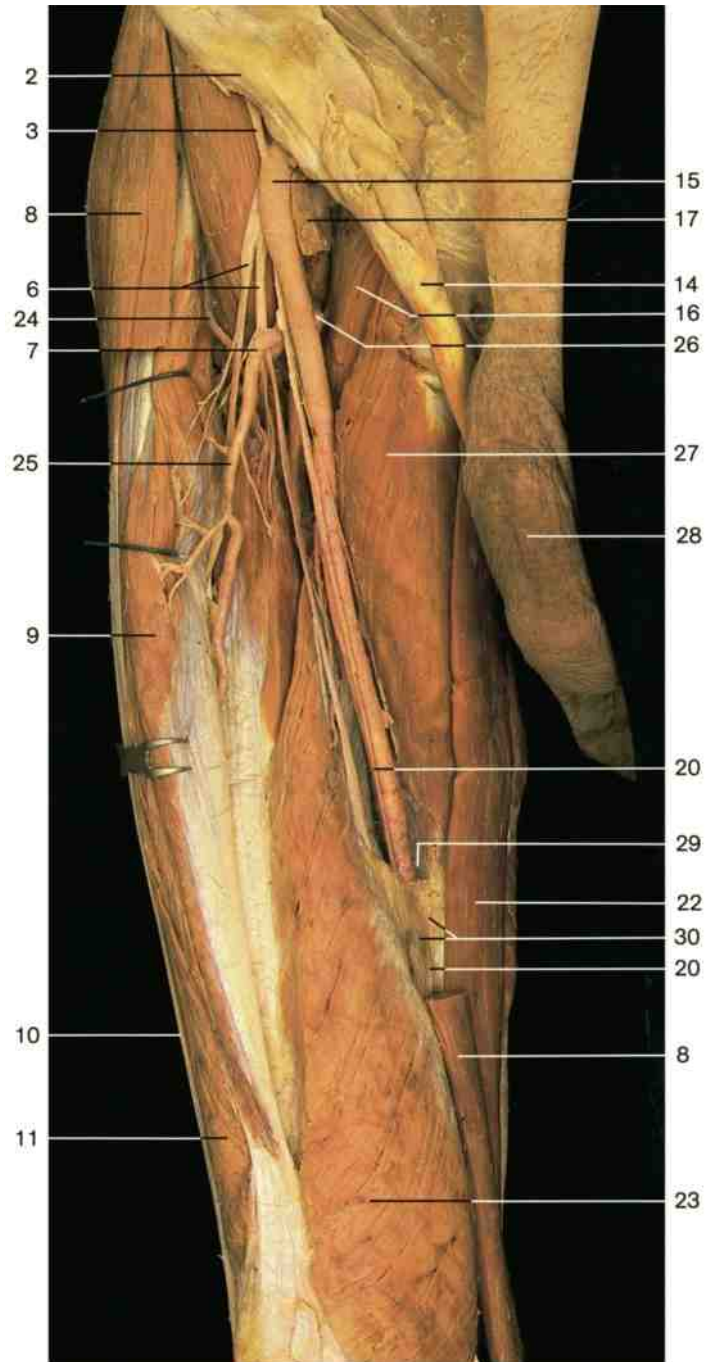
Cutaneous nerves and veins of thigh (anterior aspect). The fascia lata and fasciae of the thigh muscles have been removed.

Inguinal nodes with lymphatic vessels (anterior aspect).



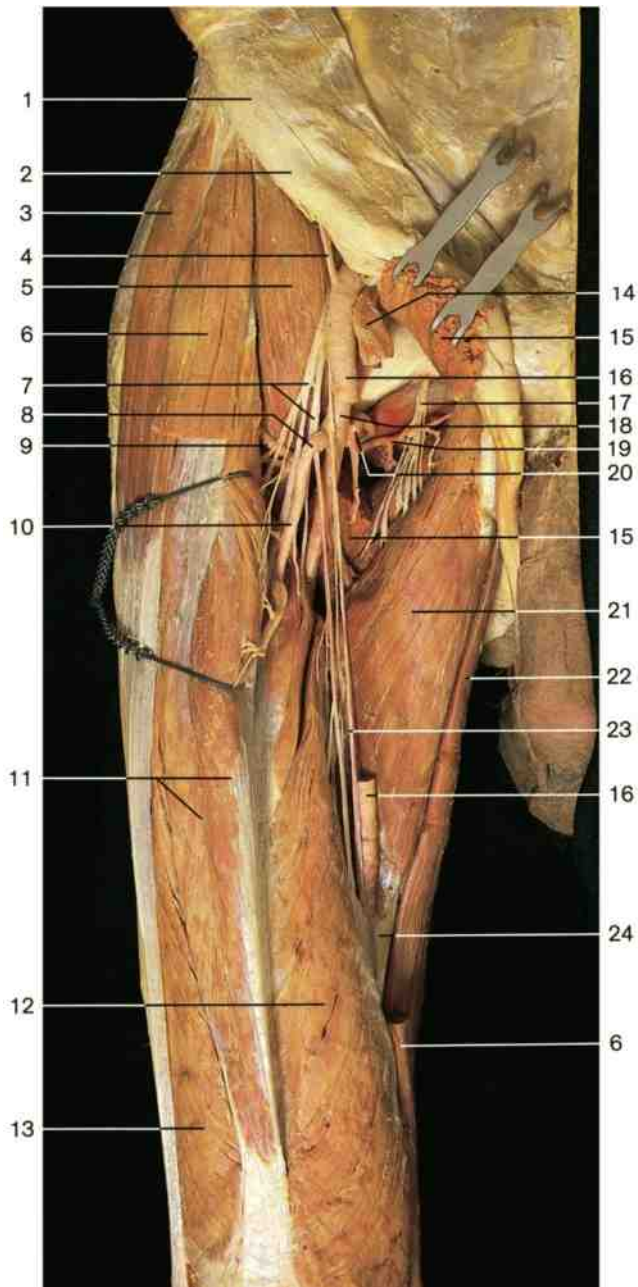
Anterior region of right thigh (anterior aspect). The fascia lata has been removed, and the sartorius muscle has been slightly reflected.

- 1 Anterior superior iliac spine
- 2 Inguinal ligament
- 3 Deep circumflex iliac artery
- 4 Iliopsoas muscle
- 5 Tensor fasciae latae muscle
- 6 Femoral nerve
- 7 Lateral circumflex femoral artery
- 8 Sartorius muscle
- 9 Rectus femoris muscle
- 10 Iliotibial tract
- 11 Vastus lateralis muscle
- 12 Anterior sheath of rectus abdominis muscle
- 13 Inferior epigastric artery
- 14 Spermatic cord
- 15 Femoral artery



Anterior region of right thigh (anterior aspect). The fascia lata has been removed, and the sartorius muscle has been divided.

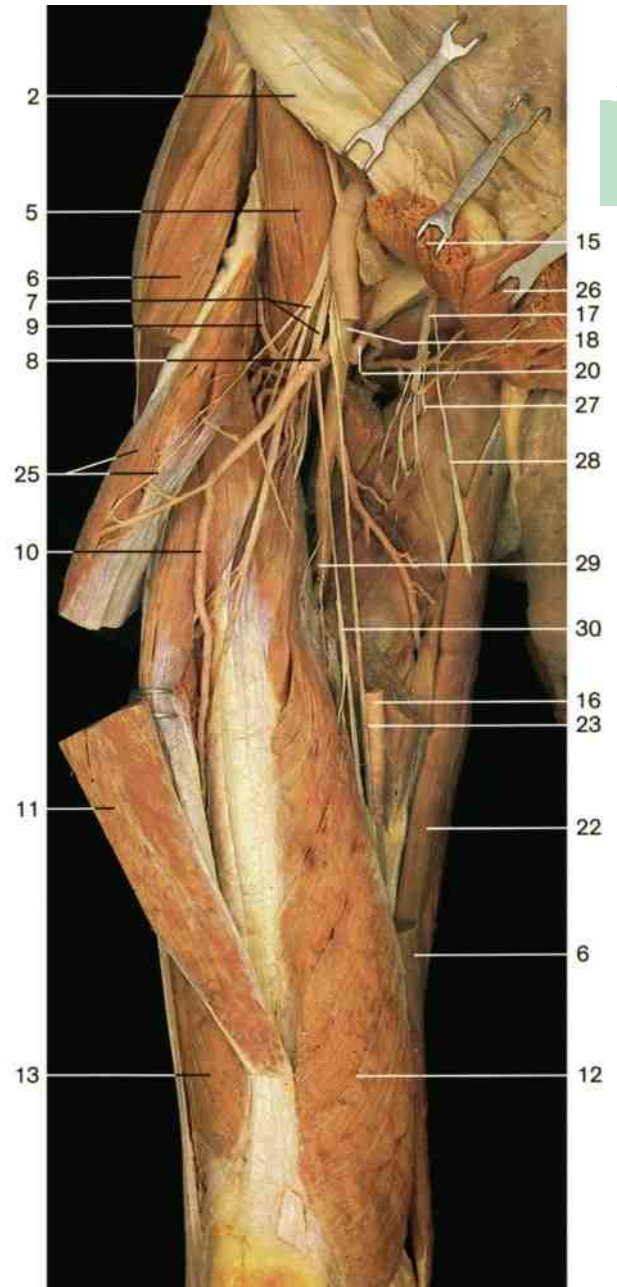
- 16 Pectineus muscle
- 17 Femoral vein
- 18 Great saphenous vein (divided)
- 19 Adductor longus muscle
- 20 Saphenous nerve
- 21 Muscular branch of femoral nerve
- 22 Gracilis muscle
- 23 Vastus medialis muscle
- 24 Ascending branch of lateral circumflex femoral artery
- 25 Descending branch of lateral circumflex femoral artery
- 26 Medial circumflex femoral artery
- 27 Adductor longus muscle
- 28 Penis
- 29 Entrance to adductor canal
- 30 Vasto-adductor membrane of fascia beneath sartorius muscle



Anterior region of right thigh (anterior aspect).

The fascia lata has been removed. Sartorius muscle, pectineus muscle, and femoral artery have been cut to display the deep femoral artery with its branches. The rectus femoris muscle has been slightly reflected.

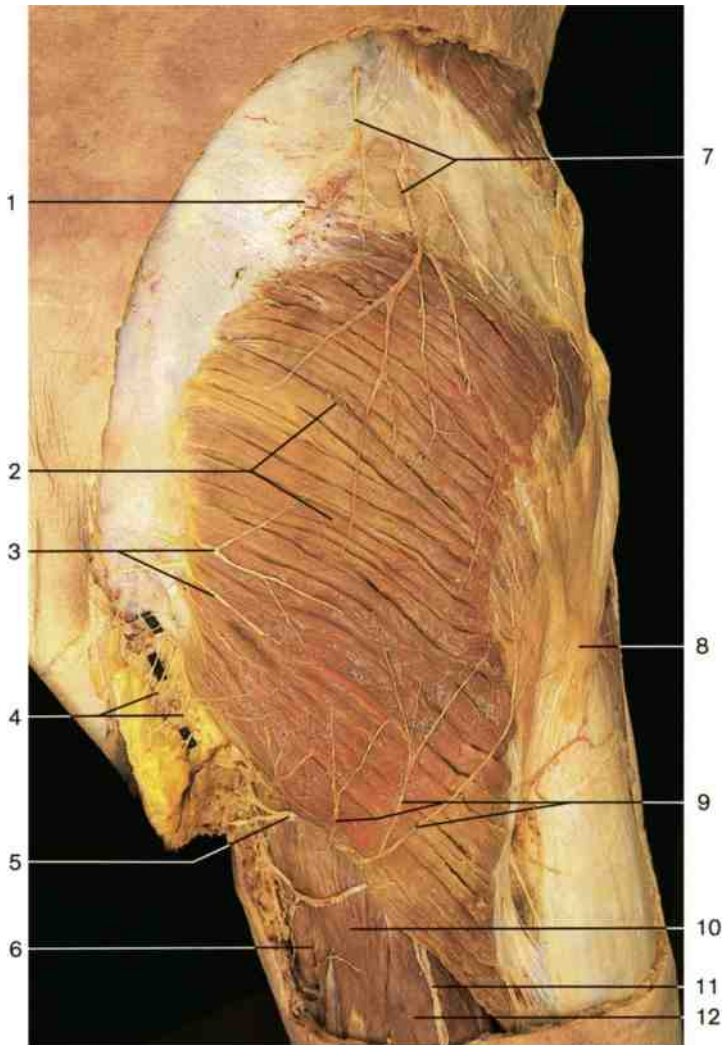
- 1 Anterior superior iliac spine
- 2 Inguinal ligament
- 3 Tensor fasciae latae muscle
- 4 Deep circumflex iliac artery
- 5 Iliopsoas muscle
- 6 Sartorius muscle (cut)
- 7 Femoral nerve
- 8 Lateral circumflex femoral artery
- 9 Ascending branch of lateral circumflex femoral artery
- 10 Descending branch of lateral circumflex femoral artery
- 11 Rectus femoris muscle
- 12 Vastus medialis muscle
- 13 Vastus lateralis muscle
- 14 Femoral vein
- 15 Pectineus muscle (cut)
- 16 Femoral artery (cut)



Anterior region of right thigh (anterior aspect).

The sartorius, pectineus, adductor longus, and rectus femoris muscles have been divided and reflected. The greater part of the femoral artery has been removed.

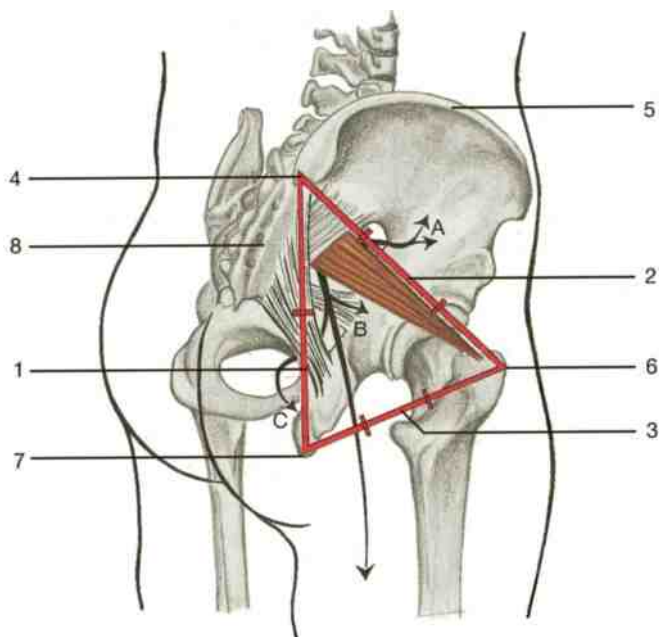
- 17 Obturator nerve
- 18 Profunda femoris artery
- 19 Ascending branch of medial circumflex femoral artery
- 20 Medial circumflex femoral artery
- 21 Adductor longus muscle
- 22 Gracilis muscle
- 23 Saphenous nerve
- 24 Distal part of vasto-adductor membrane
- 25 Rectus femoris muscle with muscular branch of femoral nerve
- 26 Adductor longus muscle (divided)
- 27 Posterior branch of obturator nerve
- 28 Anterior branch of obturator nerve
- 29 Point at which perforating artery branches off from profunda femoris artery
- 30 Muscular branch of femoral nerve to vastus medialis muscle



Gluteal region, right side (posterior aspect).

- 1 Iliac crest
- 2 Gluteus maximus muscle
- 3 Middle cluneal nerves
- 4 Anococcygeal nerves
- 5 Perineal branch of posterior femoral cutaneous nerve
- 6 Adductor magnus muscle
- 7 Superior cluneal nerves
- 8 Position of greater trochanter
- 9 Inferior cluneal nerves
- 10 Semitendinosus muscle
- 11 Posterior femoral cutaneous nerve
- 12 Long head of biceps femoris muscle

A Suprapiriform foramen (of greater sciatic foramen) Superior gluteal artery, vein, and nerve
B Infrapiriform foramen (of greater sciatic foramen) Sciatic nerve Inferior gluteal artery, vein, and nerve Posterior femoral cutaneous nerve Internal pudendal artery and vein Pudendal nerve
C Lesser sciatic foramen Pudendal nerve Internal pudendal artery and vein



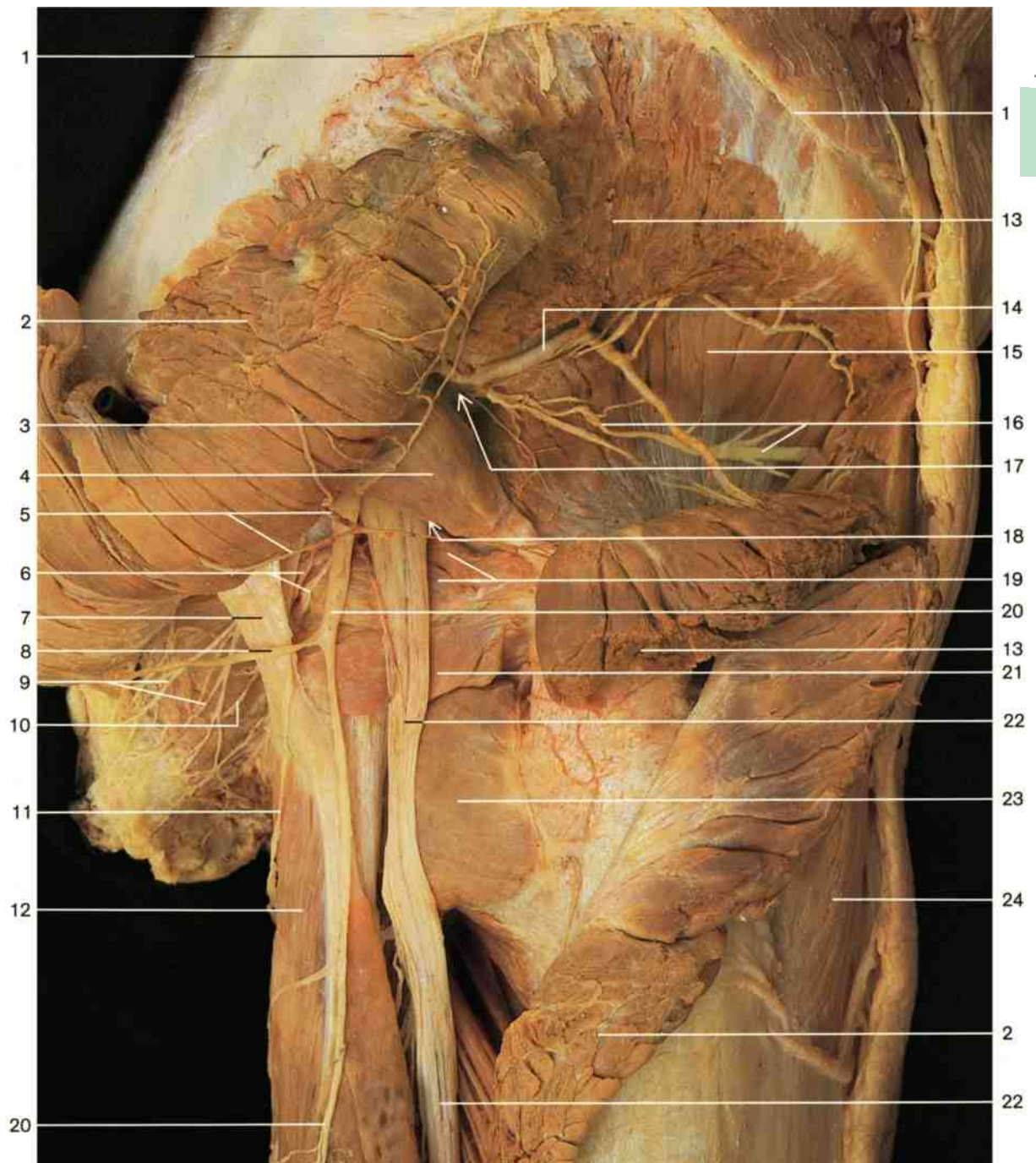
Gluteal region, right side (postero-lateral aspect). Location of sciatic foramina in relation to the bones (schematic drawing).

Red lines

- 1 Spine-tuber line:
the infrapiriform foramen is situated in the middle of this line
- 2 Spine-trochanter line:
the suprapiriform foramen is located in the upper third
- 3 Tuber-trochanter line:
the ischiadic nerve can be found between the middle and posterior third

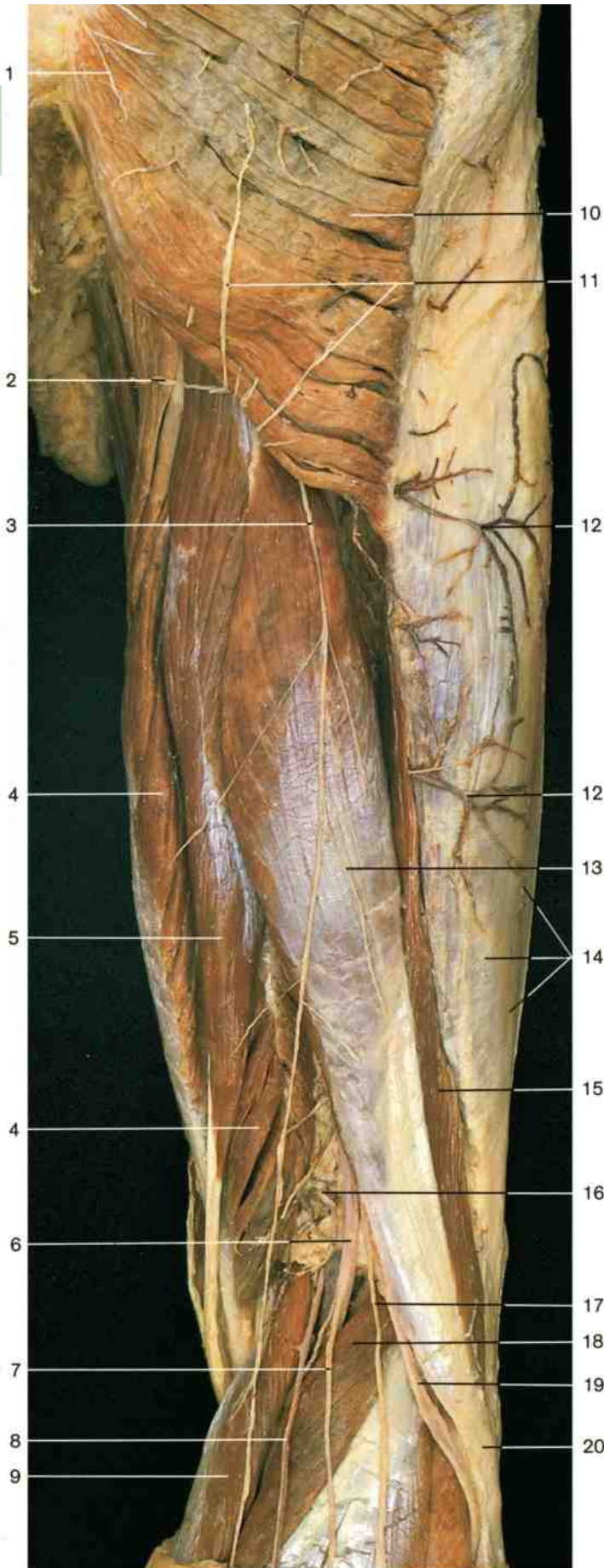
Other structures

- 4 Posterior superior iliac spine
- 5 Iliac crest
- 6 Greater trochanter
- 7 Ischial tuberosity
- 8 Sacrum



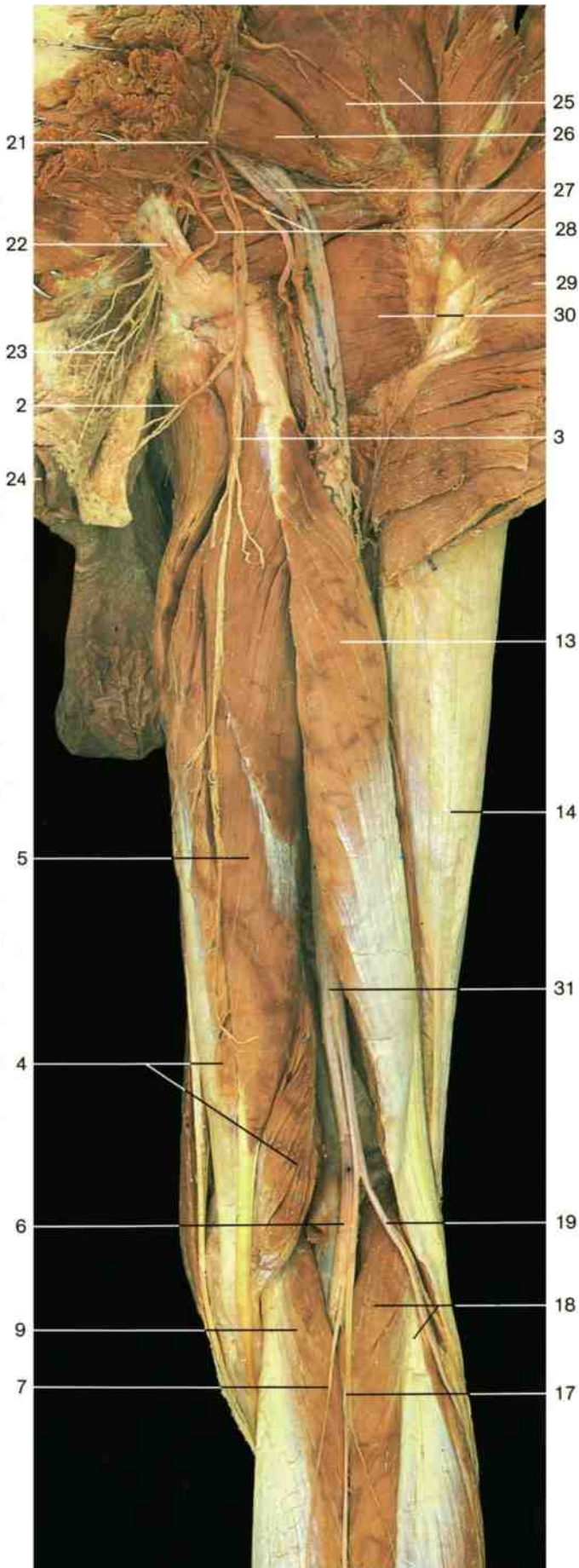
Gluteal region, right side (posterior aspect). The gluteus maximus and gluteus medius muscles have been divided and reflected. Notice the position of the foramina above and below the piriformis muscle and the lesser sciatic foramen.

- | | |
|--|---|
| 1 Iliac crest | 13 Gluteus medius muscle (cut) |
| 2 Gluteus maximus muscle (cut) | 14 Deep branch of superior gluteal artery |
| 3 Inferior gluteal nerve | 15 Gluteus minimus muscle |
| 4 Piriformis muscle | 16 Superior gluteal nerve |
| 5 Muscular branches of inferior gluteal artery | 17 Suprapiriform foramen } greater sciatic foramen |
| 6 Pudendal nerve and internal pudendal artery within the lesser sciatic foramen (entrance to the pudendal canal) | 18 Infrapiriform foramen } |
| 7 Sacrotuberous ligament | 19 Tendon of obturator internus and superior gemellus muscles |
| 8 Inferior cluneal nerve | 20 Posterior femoral cutaneous nerve |
| 9 Inferior rectal nerves | 21 Inferior gemellus muscle |
| 10 Inferior rectal arteries | 22 Sciatic nerve |
| 11 Perforating cutaneous nerve | 23 Quadratus femoris muscle |
| 12 Long head of biceps femoris muscle | 24 Tensor fasciae latae muscle |

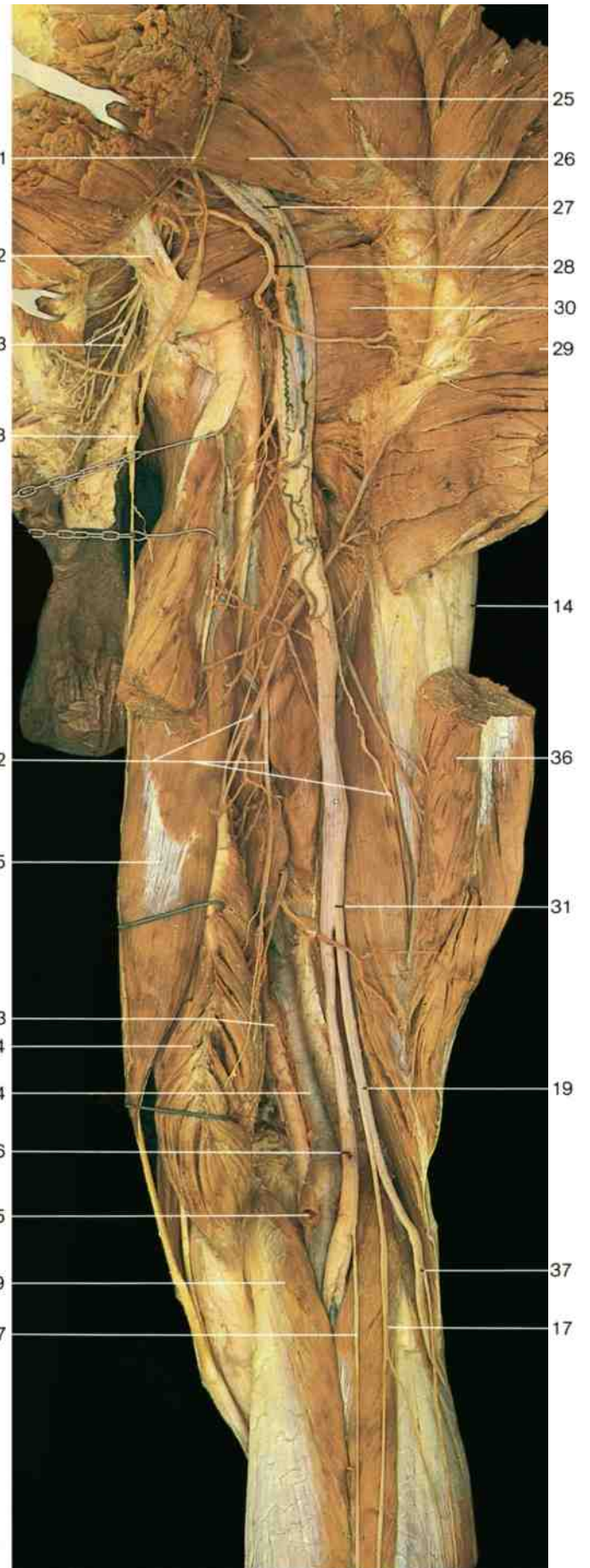


- 1 Middle cluneal nerves
- 2 Perineal branch of posterior femoral cutaneous nerve
- 3 Posterior femoral cutaneous nerve
- 4 Semimembranosus muscle
- 5 Semitendinosus muscle
- 6 Tibial nerve
- 7 Medial sural cutaneous nerve
- 8 Small saphenous vein
- 9 Medial head of gastrocnemius muscle
- 10 Gluteus maximus muscle
- 11 Inferior cluneal nerves
- 12 Cutaneous veins
- 13 Long head of biceps femoris muscle
- 14 Iliotibial tract
- 15 Short head of biceps femoris muscle
- 16 Popliteal fossa
- 17 Lateral sural cutaneous nerve
- 18 Lateral head of gastrocnemius muscle
- 19 Common peroneal nerve
- 20 Tendon of biceps femoris muscle
- 21 Inferior gluteal nerve
- 22 Sacrotuberous ligament
- 23 Inferior rectal branches of pudendal
- 24 Anus
- 25 Gluteus medius muscle
- 26 Piriformis muscle
- 27 Sciatic nerve
- 28 Inferior gluteal artery
- 29 Gluteus maximus muscle (cut)
- 30 Quadratus femoris muscle
- 31 Sciatic nerve dividing into its two branches: the common peroneal nerve and the tibial nerve
- 32 Muscular branches of sciatic nerve to hamstring muscles
- 33 Popliteal artery
- 34 Popliteal vein
- 35 Small saphenous vein (cut)
- 36 Long head of biceps femoris muscle (cut)
- 37 Superficial peroneal nerve

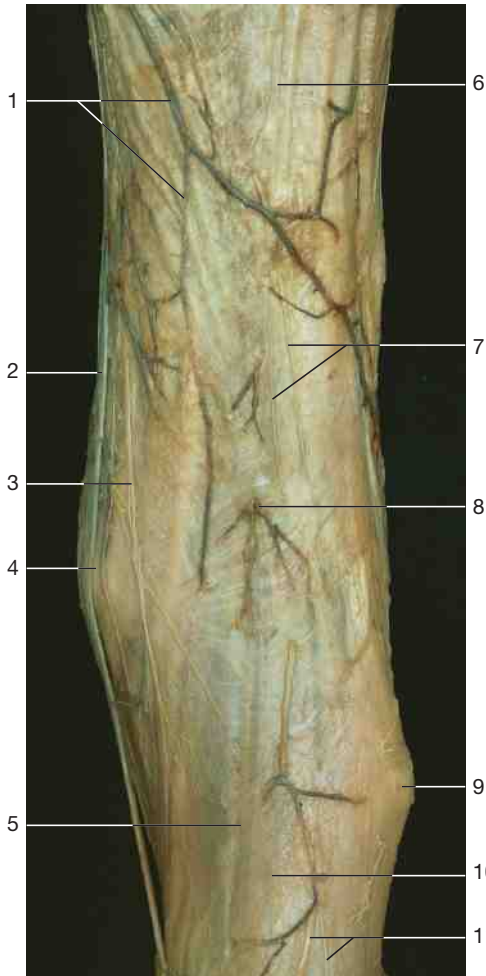
Cutaneous nerves of thigh (posterior aspect).
The fascia lata and the fasciae of muscles have been removed.



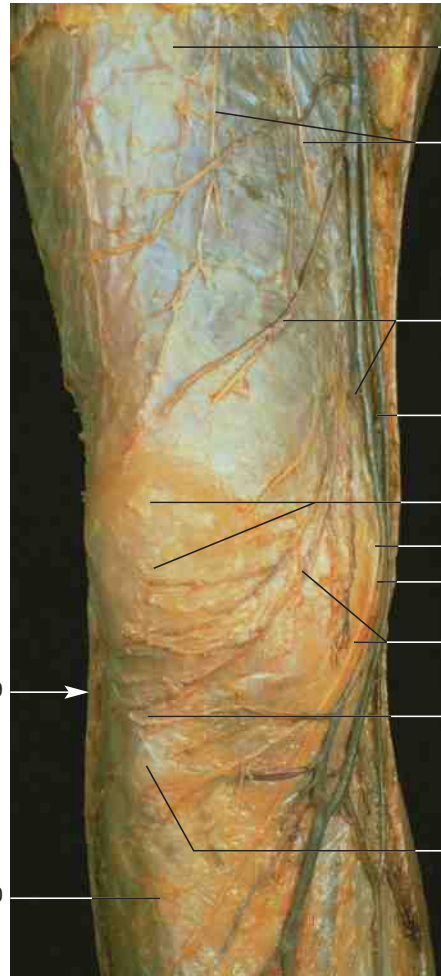
Gluteal region and posterior region of right thigh (posterior aspect). The gluteus maximus muscle has been divided and reflected.



Gluteal region and posterior region of right thigh (posterior aspect). The gluteus maximus muscle and the long head of the biceps femoris muscle have been divided and reflected.

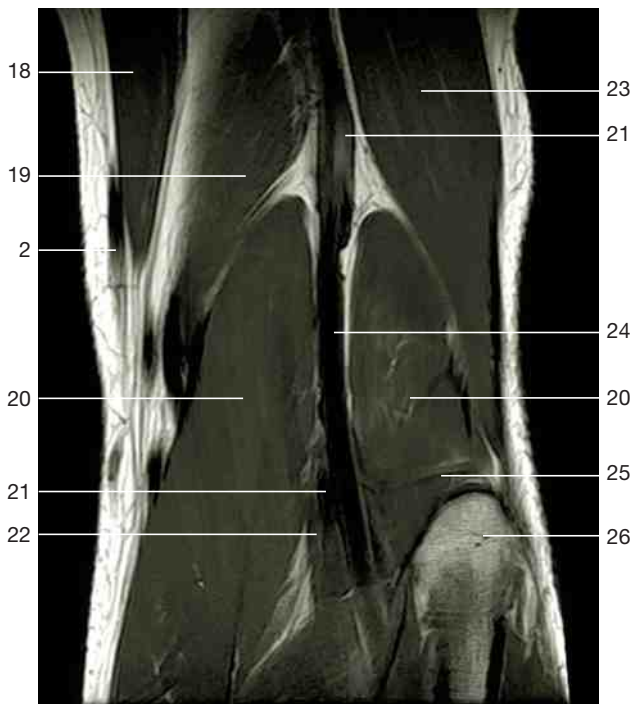


Posterior region of right knee, cutaneous nerves and veins (posterior aspect).

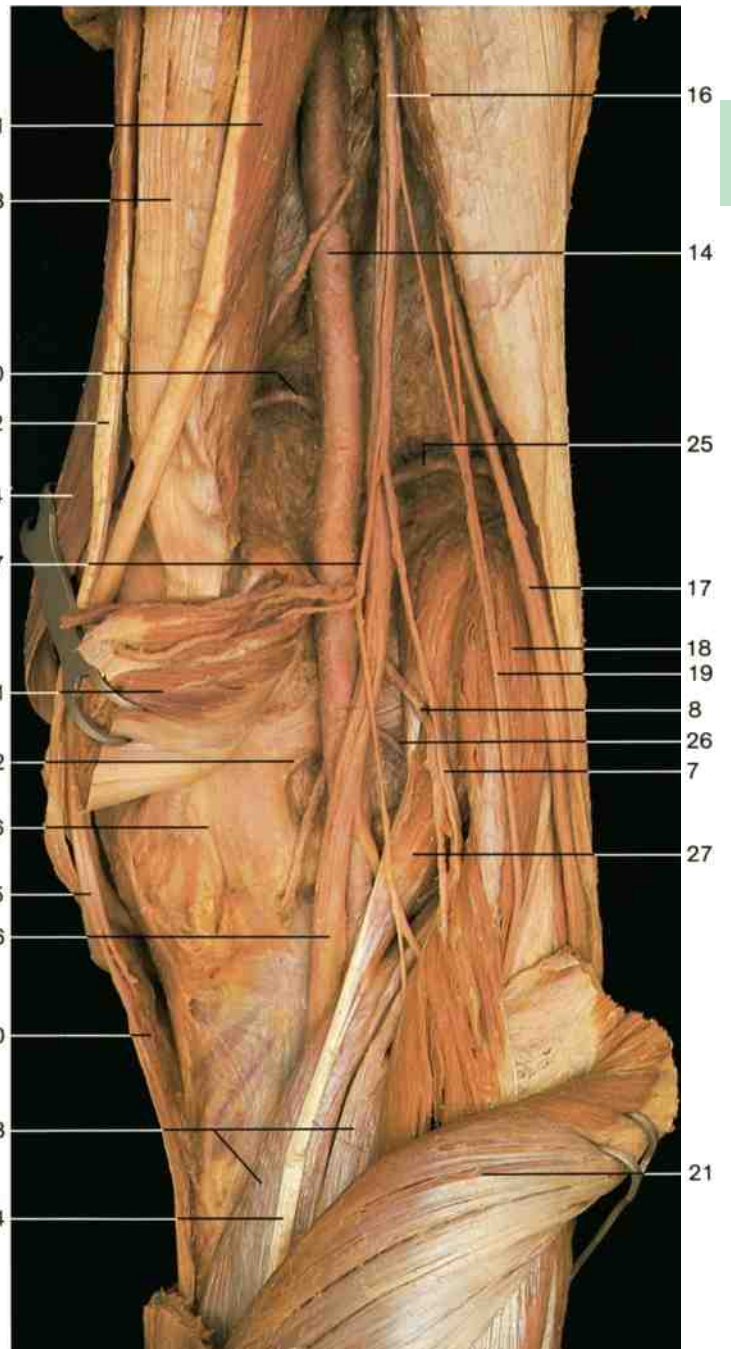
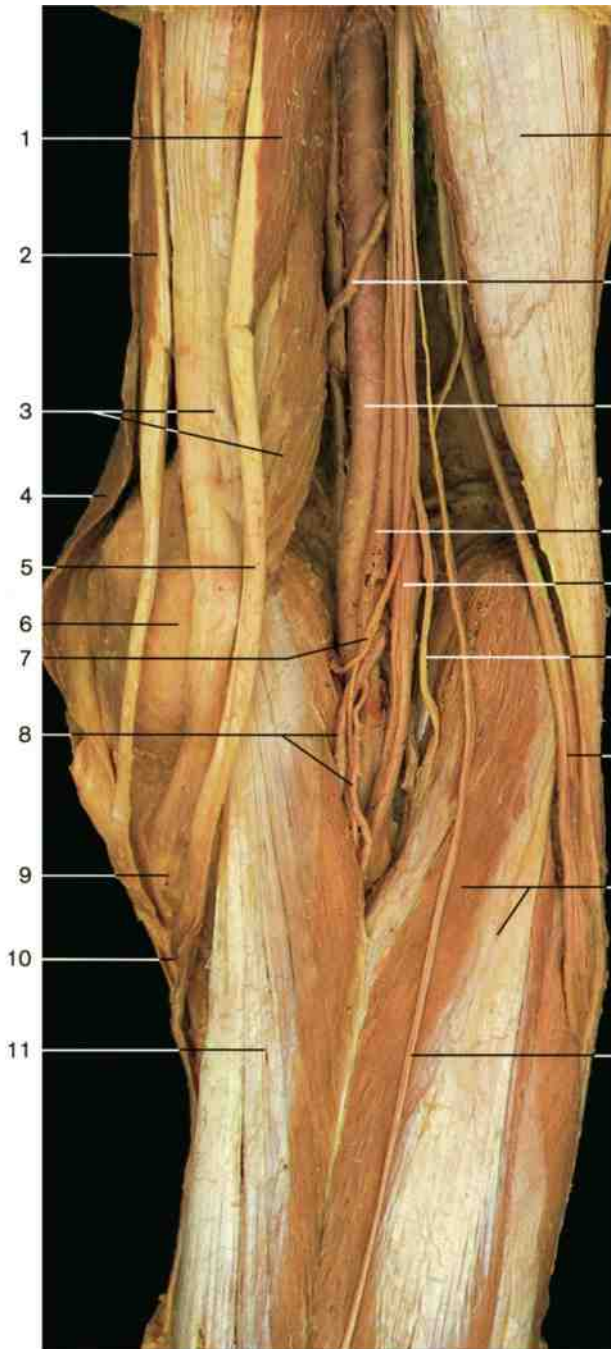


Anterior region of right knee, cutaneous nerves and veins (anterior aspect).

- 1 Cutaneous veins (tributaries of great saphenous vein)
- 2 Great saphenous vein
- 3 Cutaneous branch of femoral nerve
- 4 Position of medial condyle of femur
- 5 Position of small saphenous vein
- 6 Fascia lata
- 7 Terminal branches of posterior femoral cutaneous nerve
- 8 Cutaneous veins of popliteal fossa
- 9 Position of head of fibula
- 10 Superficial layer of fascia cruris
- 11 Lateral sural cutaneous nerve
- 12 Venous network around knee
- 13 Patella
- 14 Saphenous nerve
- 15 Infrapatellar branch of saphenous nerve
- 16 Patellar ligament
- 17 Position of tuberosity of tibia
- 18 Sartorius muscle
- 19 Semimembranosus muscle
- 20 Gastrocnemius muscle
- 21 Popliteal vein
- 22 Tibial nerve
- 23 Biceps femoris muscle
- 24 Popliteal artery
- 25 Lateral inferior genicular artery
- 26 Fibula



Coronal section of popliteal fossa (MRI scan; from Heuck et al., MRT-Atlas, 2009).

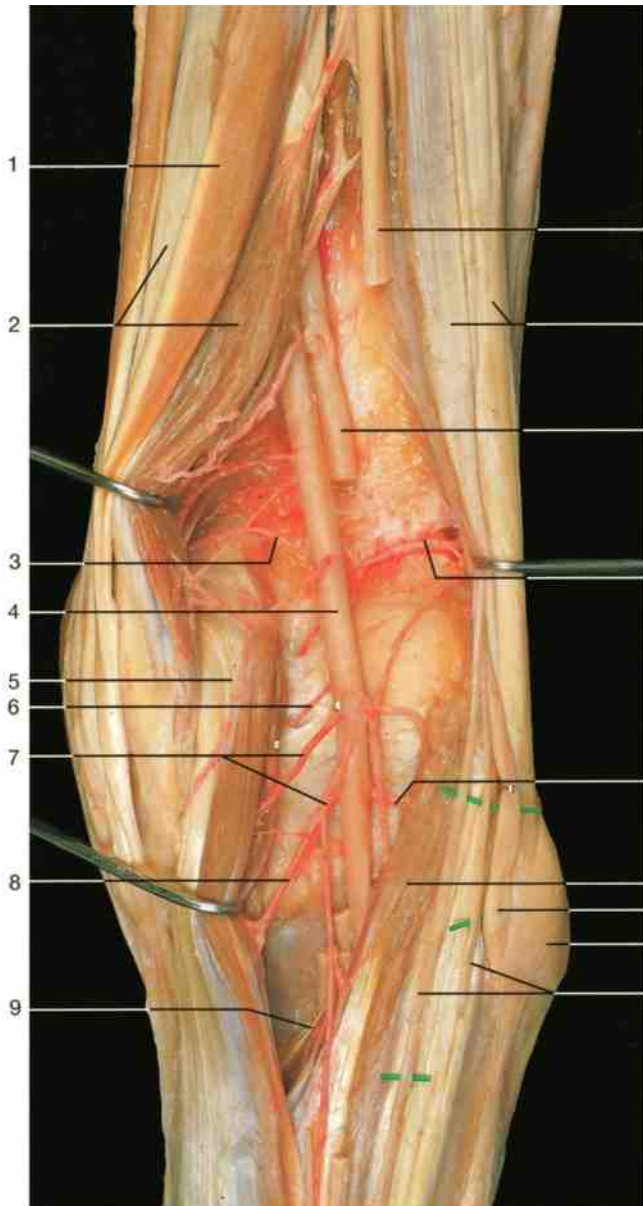


Right leg, popliteal fossa, middle layer (posterior aspect). The gastrocnemius muscle has been divided and reflected.

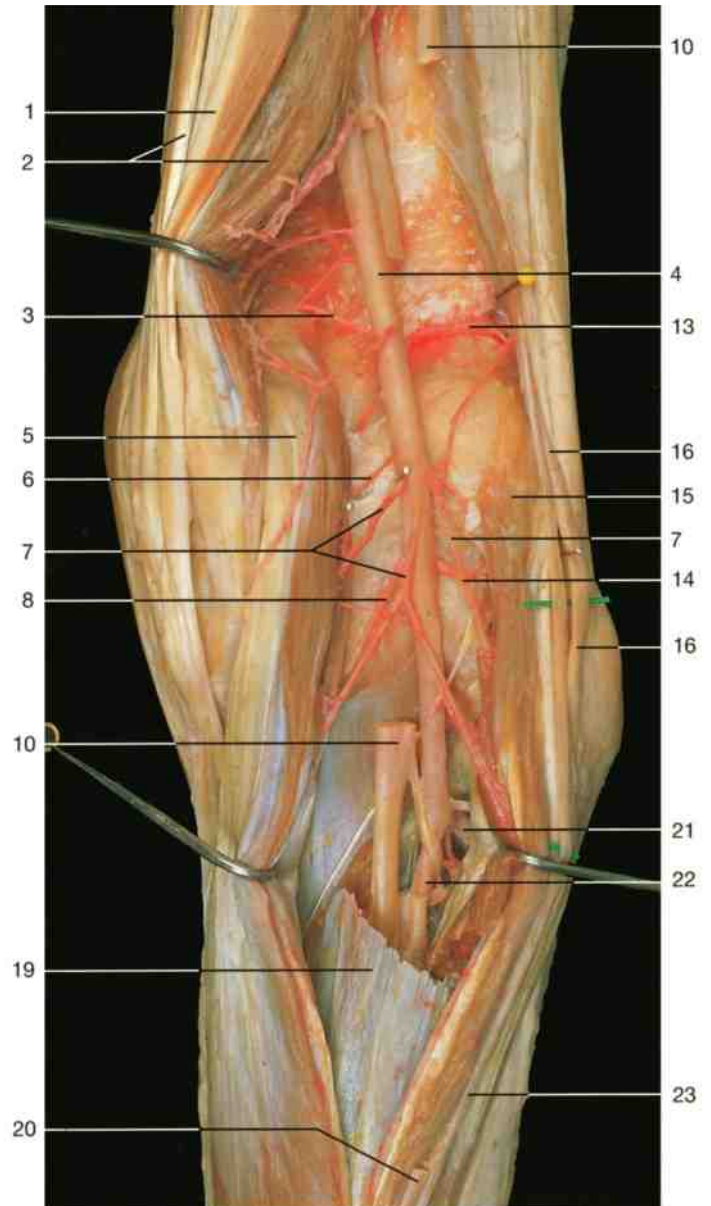
Right leg, popliteal fossa, deep layer (posterior aspect). The gastrocnemius and the soleus muscles have been divided and reflected.

- 1 Semitendinosus muscle
- 2 Gracilis muscle
- 3 Semimembranosus muscle
- 4 Sartorius muscle
- 5 Tendon of semitendinosus muscle
- 6 Position of medial condyle of femur
- 7 Muscular branches of tibial nerve
- 8 Sural arteries and veins
- 9 Tendon of semimembranosus muscle
- 10 Common tendon of gracilis, semitendinosus, and sartorius muscles
- 11 Medial head of gastrocnemius muscle
- 12 Biceps femoris muscle
- 13 Muscular branch of popliteal artery

- 14 Popliteal artery
- 15 Popliteal vein
- 16 Tibial nerve
- 17 Common peroneal nerve
- 18 Lateral head of gastrocnemius muscle
- 19 Medial sural cutaneous nerve
- 20 Medial superior genicular artery
- 21 Medial head of gastrocnemius muscle (cut and reflected)
- 22 Medial inferior genicular artery
- 23 Soleus muscle
- 24 Tendon of plantaris muscle
- 25 Lateral superior genicular artery
- 26 Lateral inferior genicular artery
- 27 Plantaris muscle



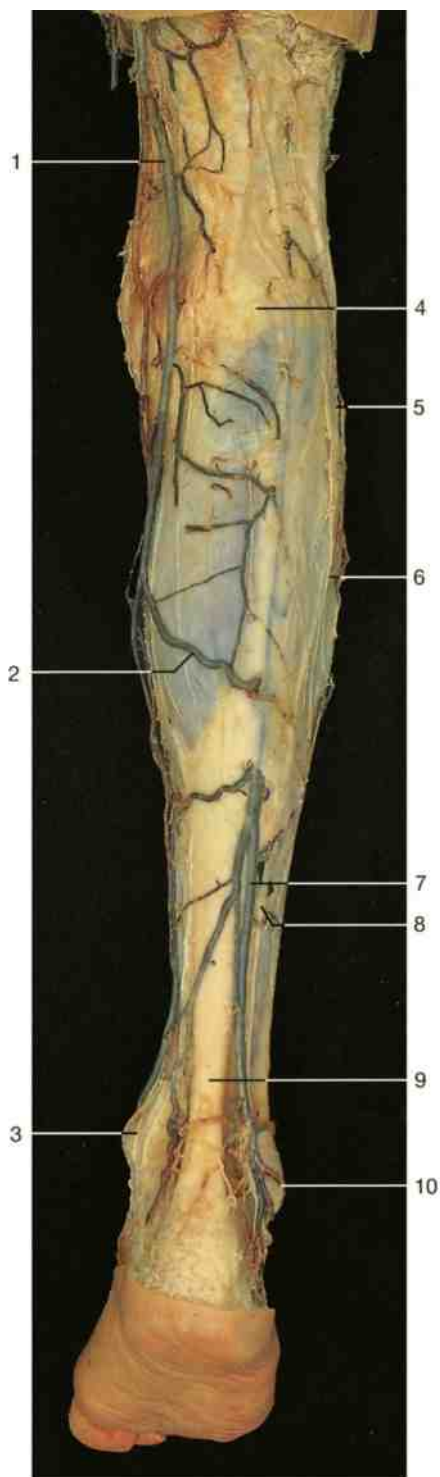
Right leg, popliteal fossa, deep layer (posterior aspect).
The muscles have been reflected to display the genicular arteries.



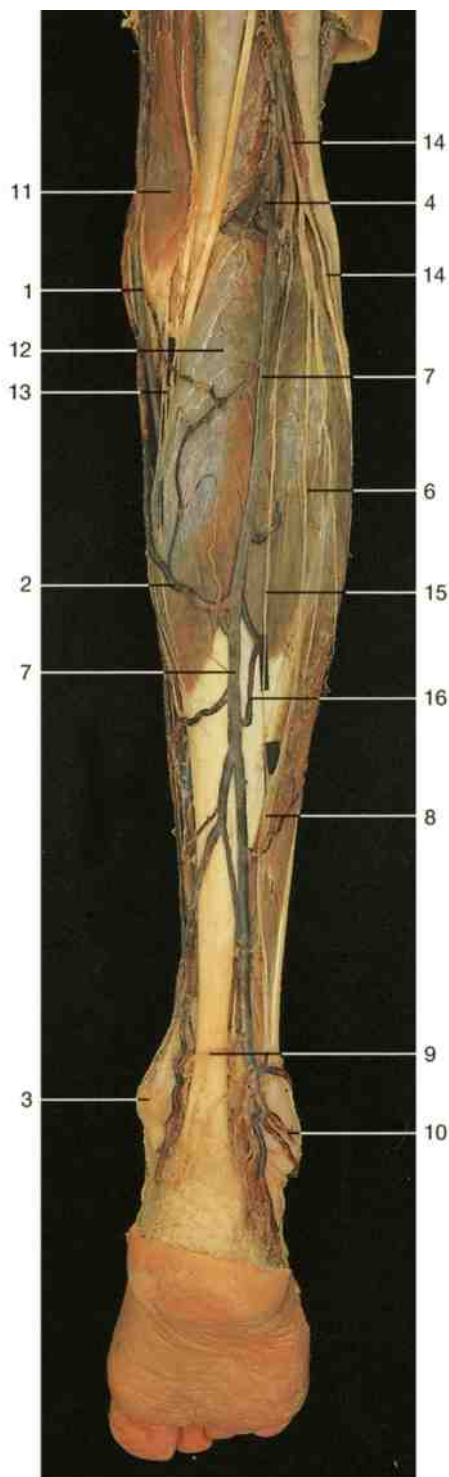
Right leg, popliteal fossa, deepest layer (posterior aspect).
Tibial nerve and popliteal vein have been partly removed and a portion of the soleus muscle was cut away to display the anterior tibial artery.

- 1 Semitendinosus muscle
- 2 Semimembranosus muscle
- 3 Medial superior genicular artery
- 4 Popliteal artery
- 5 Medial head of gastrocnemius muscle
- 6 Middle genicular artery
- 7 Muscular branches
- 8 Medial inferior genicular artery
- 9 Tendon of plantaris muscle
- 10 Tibial nerve (cut)
- 11 Biceps femoris muscle

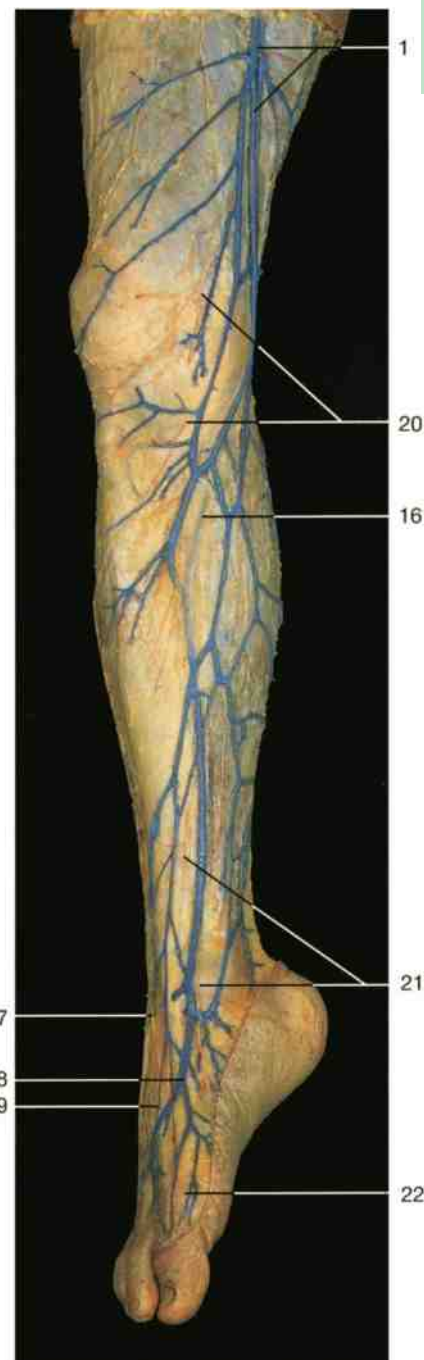
- 12 Popliteal vein (cut)
- 13 Lateral superior genicular artery
- 14 Lateral inferior genicular artery
- 15 Lateral head of gastrocnemius muscle
- 16 Common peroneal nerve
- 17 Head of fibula
- 18 Lateral sural cutaneous nerves
- 19 Soleus muscle
- 20 Medial sural cutaneous nerve
- 21 Anterior tibial artery
- 22 Posterior tibial artery
- 23 Lateral sural cutaneous nerve



Right leg, cutaneous veins and nerves (posterior aspect).



Right leg, cutaneous veins and nerves (posterior aspect).
The superficial layer of the crural fascia has been removed.

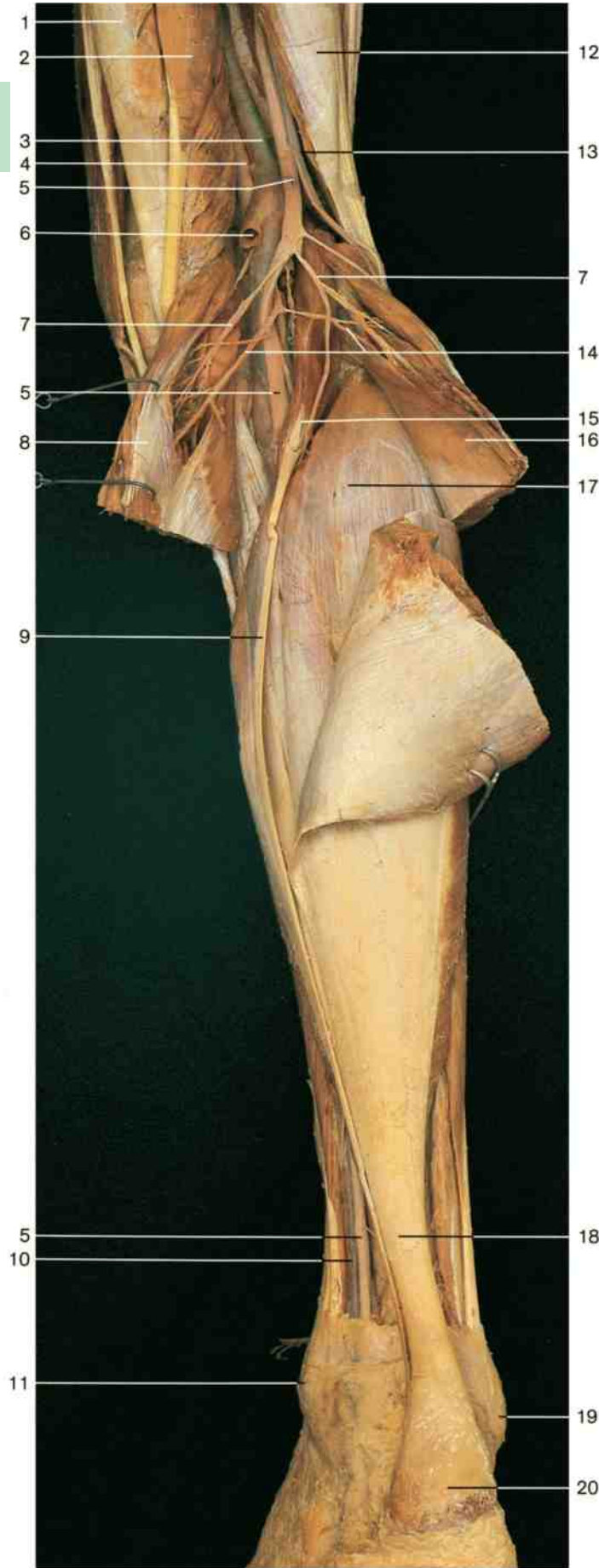


Right leg, cutaneous veins and nerves (antero-medial aspect).

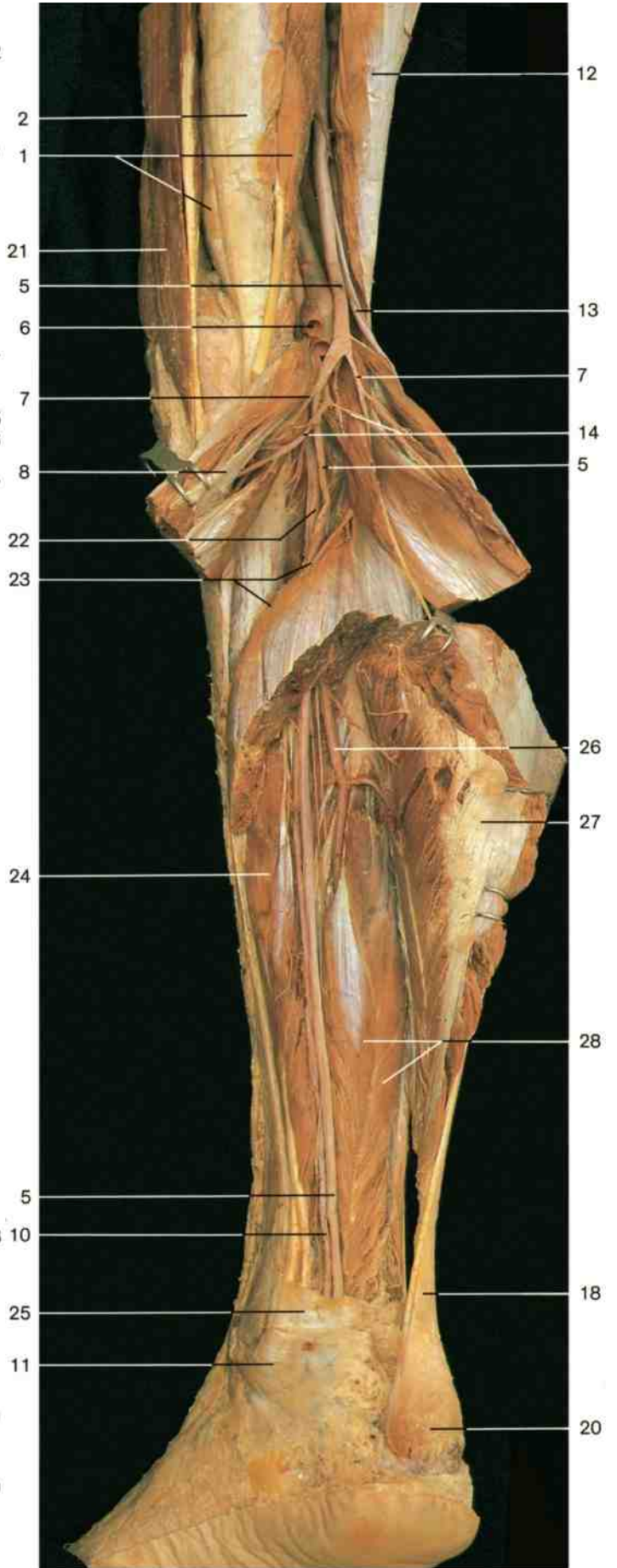
- 1 Great saphenous vein
- 2 Venous anastomosis between small and great saphenous veins
- 3 Medial malleolus
- 4 Popliteal fossa
- 5 Position of head of fibula
- 6 Lateral sural cutaneous nerve
- 7 Small saphenous vein

- 8 Sural nerve
- 9 Calcaneal tendon
- 10 Lateral malleolus
- 11 Semitendinosus muscle
- 12 Medial head of gastrocnemius muscle
- 13 Saphenous nerve
- 14 Common peroneal nerve
- 15 Medial sural cutaneous nerve

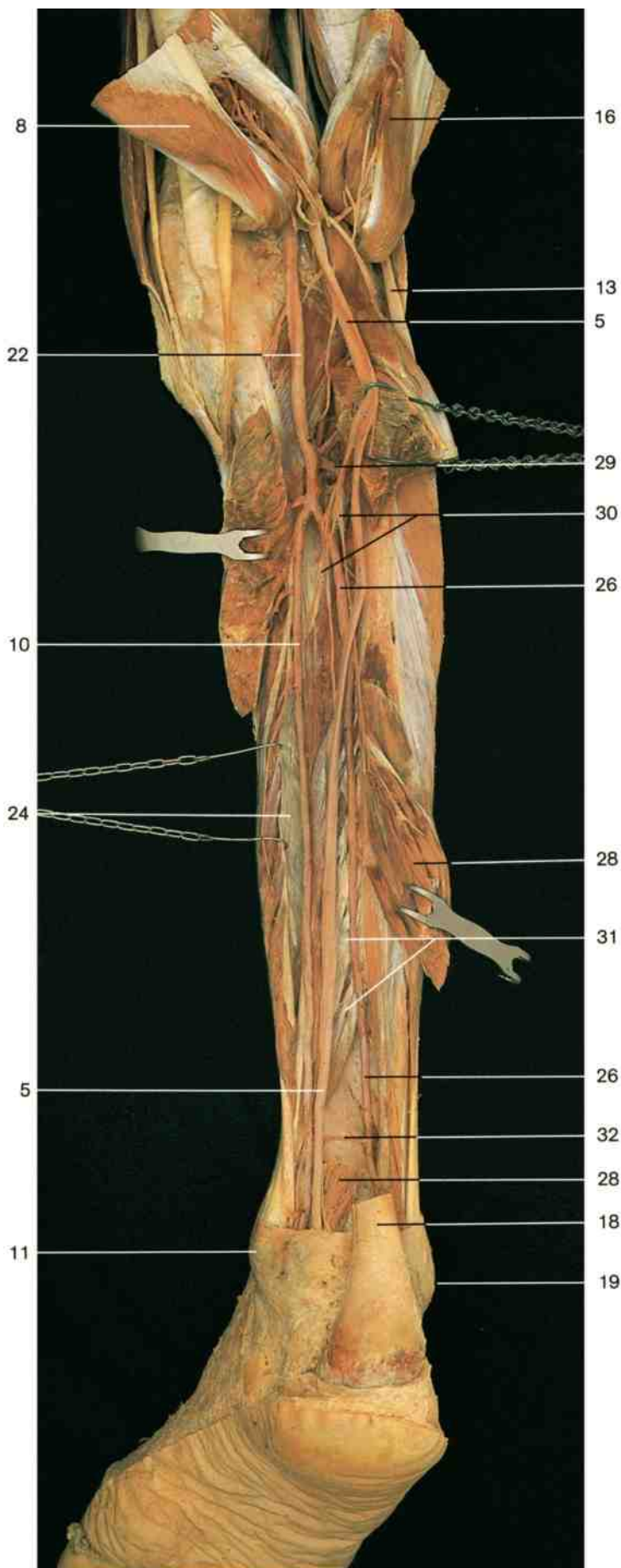
- 16 Perforating veins
- 17 Superficial peroneal nerve
- 18 Dorsal venous arch
- 19 Intermediate dorsal cutaneous nerve
- 20 Infrapatellar branches of saphenous nerve
- 21 Terminal branches of saphenous nerve
- 22 Medial dorsal cutaneous nerve



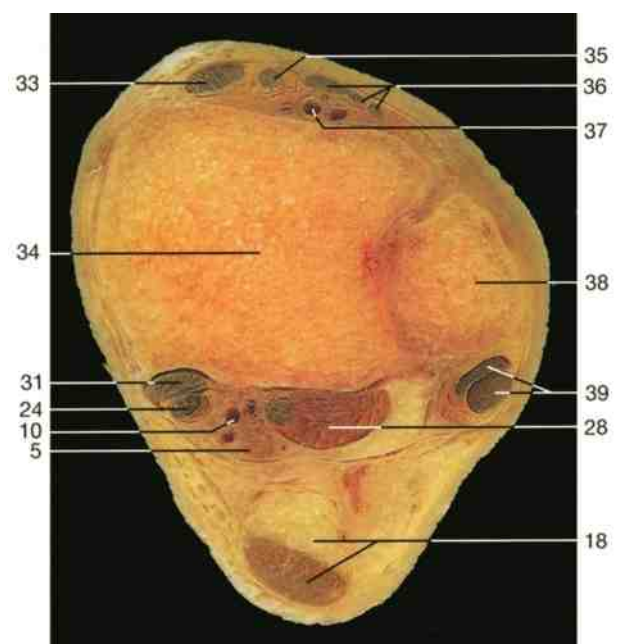
Right leg, posterior crural region, and popliteal fossa, middle layer (posterior aspect). The cutaneous veins and nerves have been removed.



Right leg, posterior crural region, and popliteal fossa, deep layer (posterior aspect). The medial head of gastrocnemius muscle has been divided and reflected.

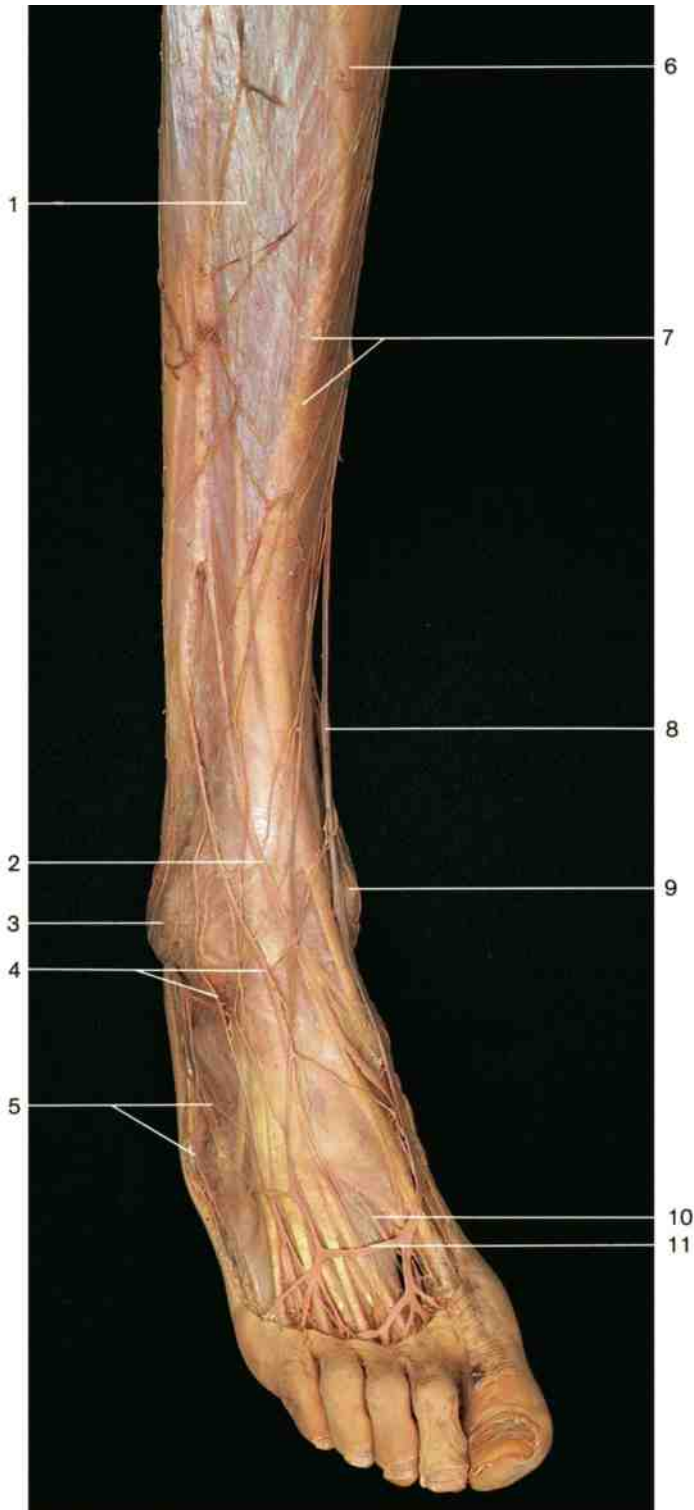


- 1 Semimembranosus muscle
- 2 Semitendinosus muscle
- 3 Popliteal vein
- 4 Popliteal artery
- 5 Tibial nerve
- 6 Small saphenous vein (cut)
- 7 Muscular branch of tibial nerve
- 8 Medial head of gastrocnemius muscle
- 9 Tendon of plantaris muscle
- 10 Posterior tibial artery
- 11 Medial malleolus
- 12 Biceps femoris muscle
- 13 Common peroneal nerve
- 14 Sural arteries
- 15 Plantaris muscle
- 16 Lateral head of gastrocnemius muscle
- 17 Soleus muscle
- 18 Calcaneal tendon
- 19 Lateral malleolus
- 20 Calcaneal tuberosity
- 21 Sartorius muscle
- 22 Popliteal artery
- 23 Tendinous arch of soleus muscle
- 24 Flexor digitorum longus muscle
- 25 Flexor retinaculum
- 26 Peroneal artery
- 27 Soleus muscle
- 28 Flexor hallucis longus muscle
- 29 Anterior tibial artery
- 30 Muscular branches of tibial nerve
- 31 Tibialis posterior muscle
- 32 Communicating branch of peroneal artery
- 33 Tendon of tibialis anterior muscle
- 34 Tibia
- 35 Tendon of extensor hallucis longus muscle
- 36 Tendons of extensor digitorum longus muscle
- 37 Anterior tibialis artery
- 38 Fibula
- 39 Tendons of peroneus longus and brevis muscles

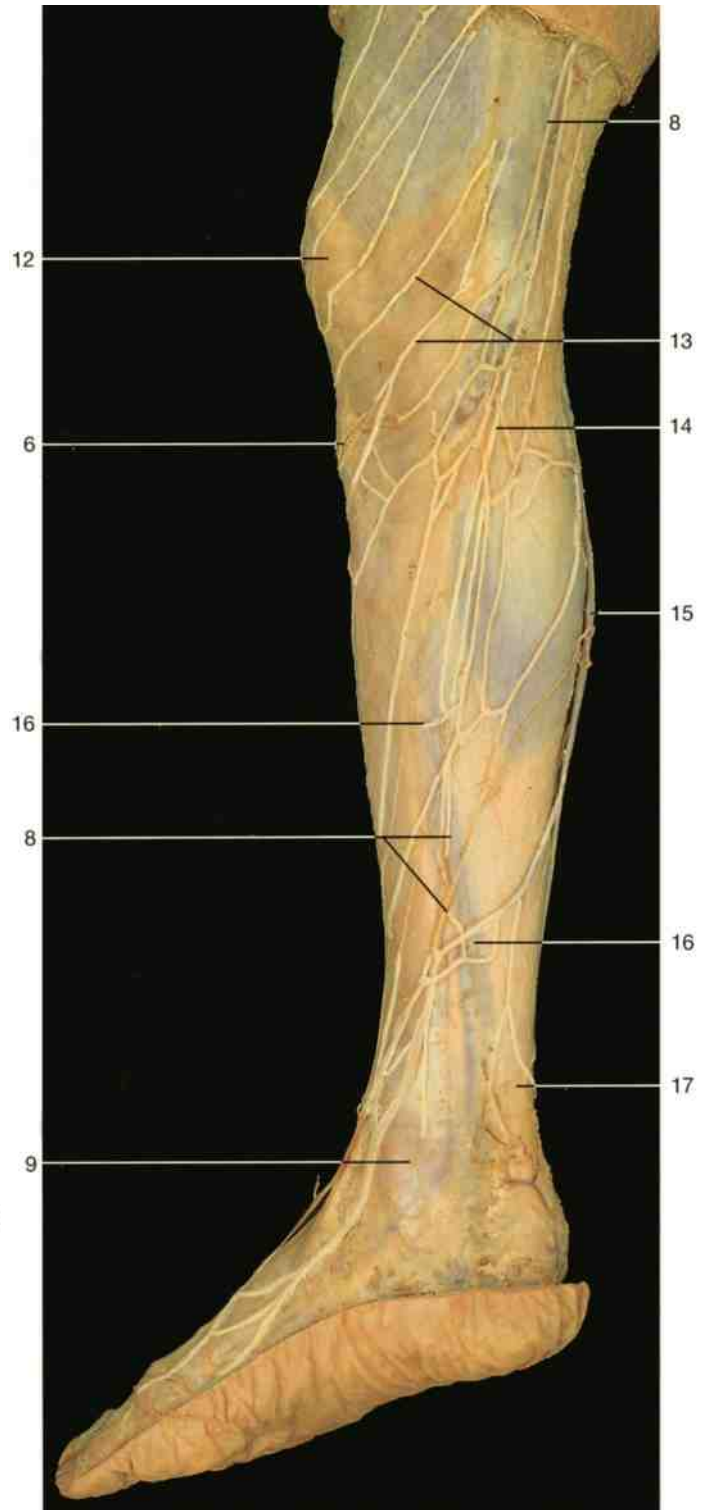


Right leg, posterior crural region, deepest layer (posterior aspect). Triceps surae (gastrocnemius and soleus) and flexor hallucis longus muscles have been cut and reflected.

Cross section of the leg, superior to the malleoli (from below).



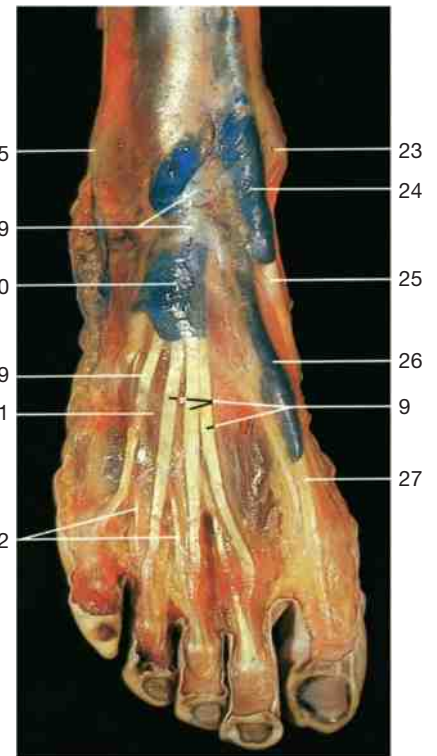
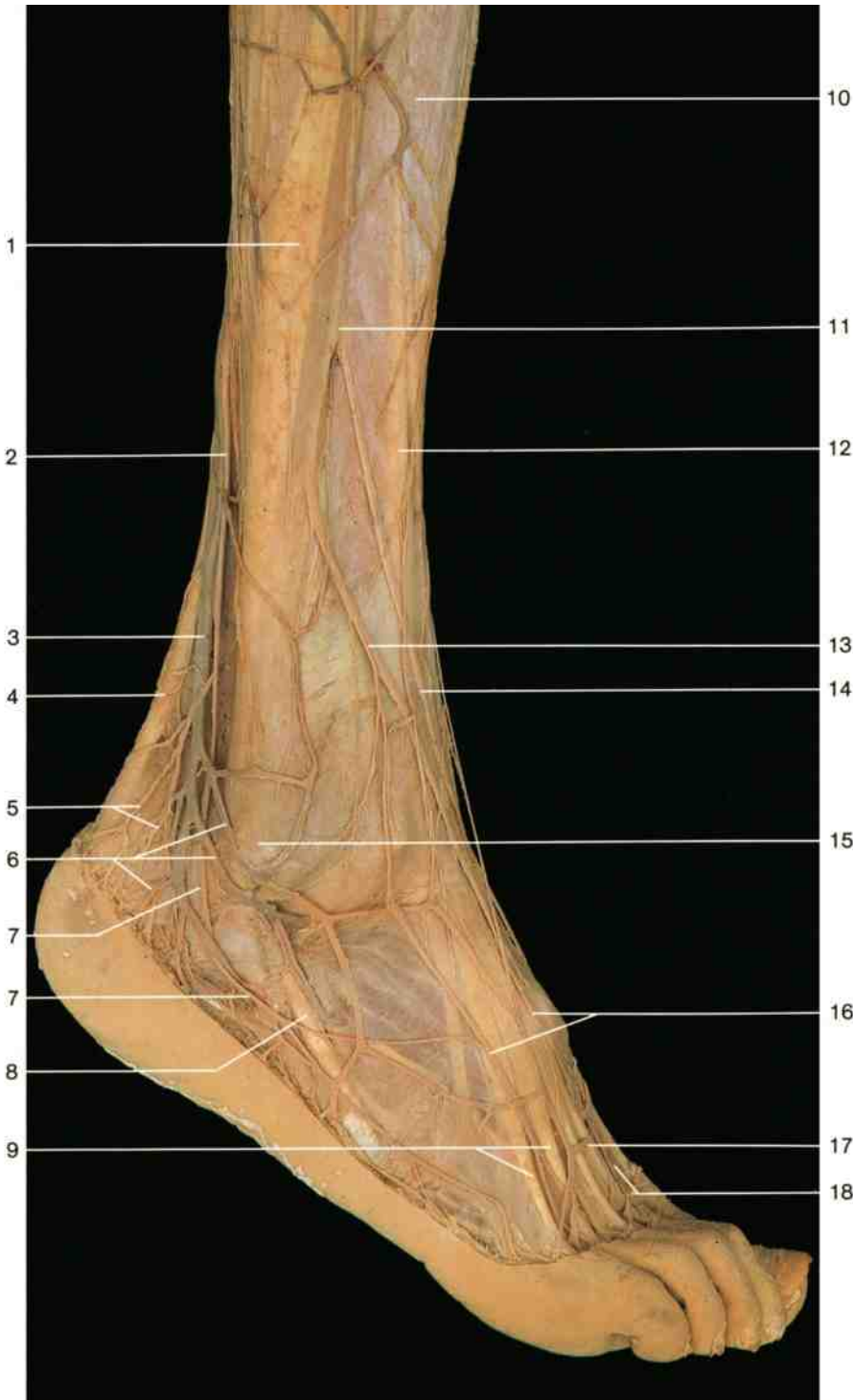
Right leg and foot, anterior crural region and dorsum of foot (anterior aspect). Cutaneous nerves and veins.



Right leg and foot (medial aspect). Cutaneous nerves and veins.

- 1 Superficial crural fascia
- 2 Medial cutaneous branch of superficial peroneal nerve
- 3 Lateral malleolus
- 4 Lateral cutaneous branch of superficial peroneal nerve
- 5 Cutaneous branch of sural nerve
- 6 Position of tuberosity of tibia
- 7 Anterior margin of tibia
- 8 Great saphenous vein
- 9 Medial malleolus

- 10 Deep peroneal nerve
- 11 Venous arch of dorsum of foot
- 12 Position of patella
- 13 Infrapatellar branches of saphenous nerve
- 14 Saphenous nerve
- 15 Small saphenous vein
- 16 Perforating vein
- 17 Calcaneal tendon

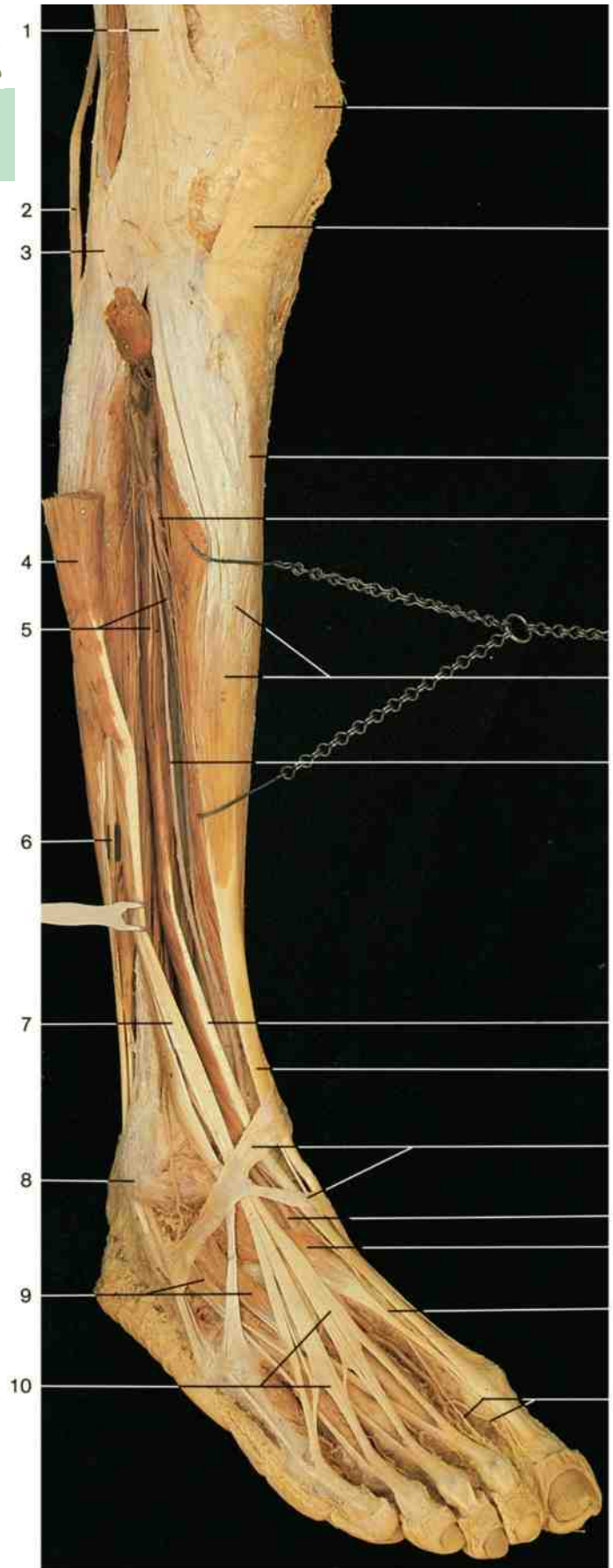


Right leg and foot (lateral aspect). Cutaneous nerves and veins.

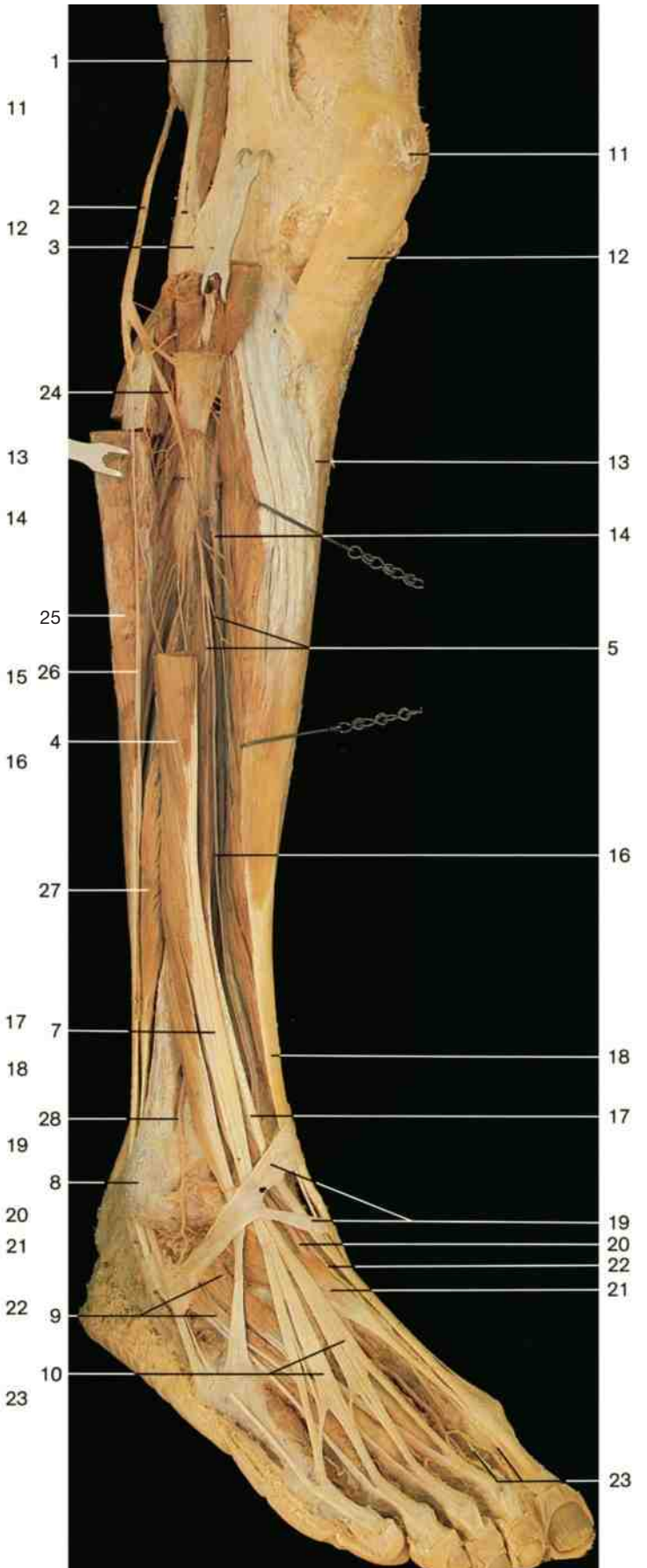
Right foot with synovial sheaths of extensor muscles (dorsal aspect). The synovial sheaths have been injected with blue solution.

- | | |
|---|---|
| 1 Position of fibula | 11 Superficial peroneal nerve |
| 2 Sural nerve | 12 Position of tibia |
| 3 Small saphenous vein | 13 Lateral cutaneous branch } of superficial |
| 4 Calcaneal tendon | 14 Medial cutaneous branch } peroneal nerve |
| 5 Lateral calcaneal branches of sural nerve | 15 Lateral malleolus |
| 6 Venous network at lateral malleolus | 16 Dorsal digital nerves |
| 7 Cutaneous branch of sural nerve | 17 Dorsal venous arch |
| 8 Tendon of peroneus brevis muscle | 18 Deep peroneal nerve |
| 9 Tendons of extensor digitorum longus muscle | 19 Inferior extensor retinaculum |
| 10 Fascia cruris | 20 Common synovial sheath of extensor digitorum longus muscle |
| | 21 Extensor digitorum brevis muscle |

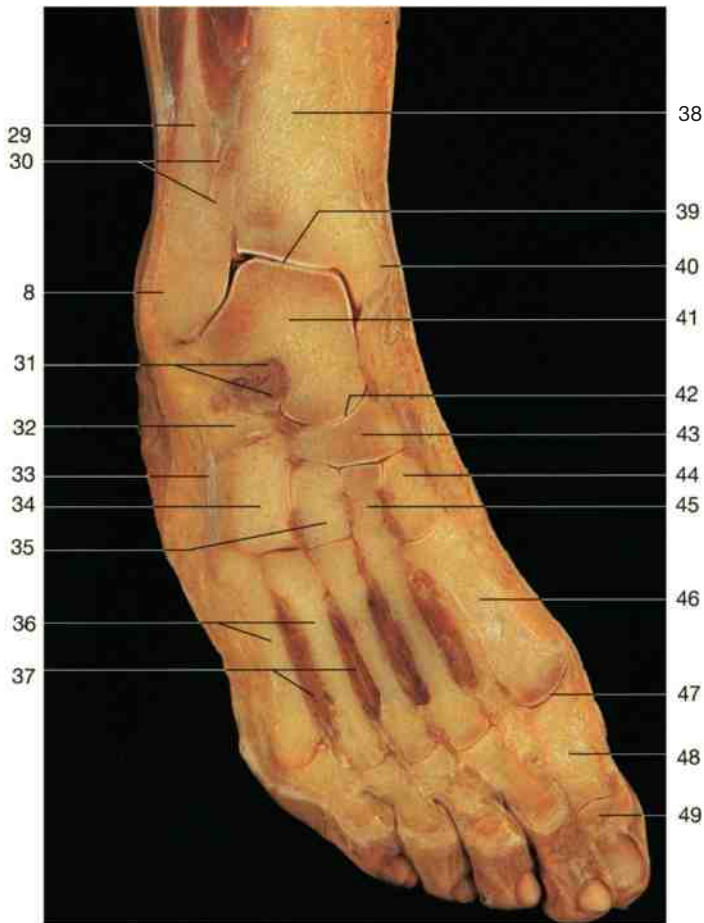
- | |
|---|
| 22 Tendons of extensor digitorum brevis muscle |
| 23 Medial malleolus |
| 24 Synovial sheath of tendon of tibialis anterior muscle |
| 25 Tendon of tibialis anterior muscle |
| 26 Synovial sheath of tendon of extensor hallucis longus muscle |
| 27 Tendon of extensor hallucis longus muscle |



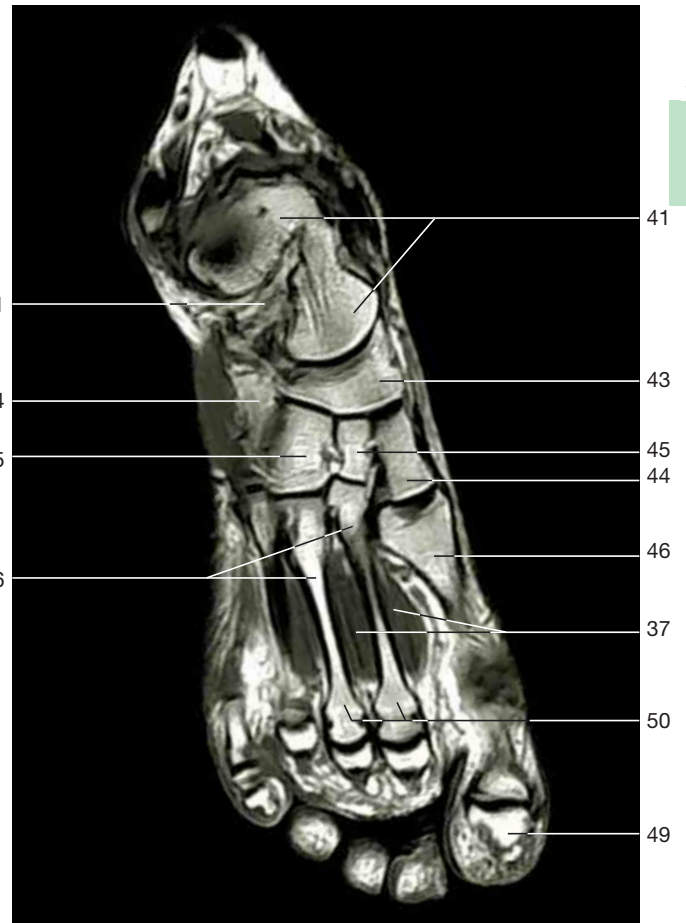
Right leg and foot, anterior crural region and dorsum of foot, middle layer (antero-lateral aspect). The extensor digitorum longus muscle has been divided and reflected laterally.



Right leg and foot, anterior crural region and dorsum of foot, deep layer (antero-lateral aspect). The extensor digitorum longus and peroneus longus muscles have been divided or removed. The common peroneal nerve has been elevated to show its course around the head of fibula.

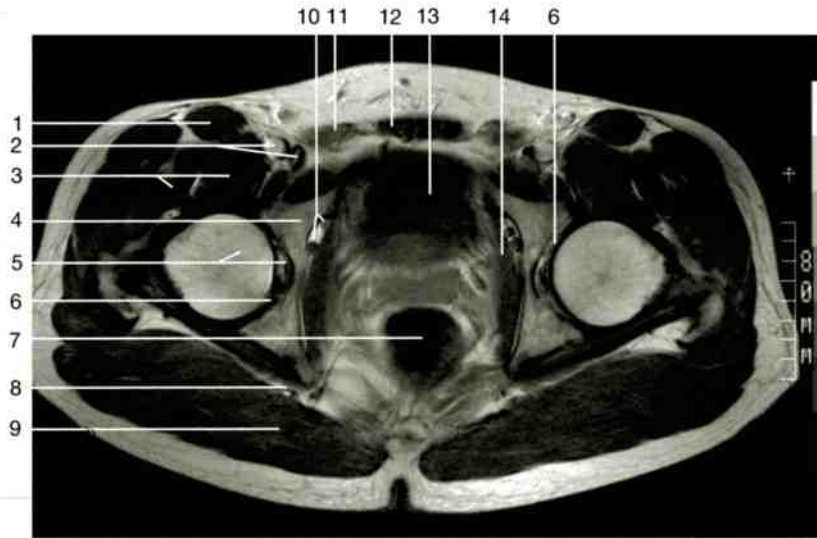


Coronal section through the foot and ankle joint (anterior aspect).

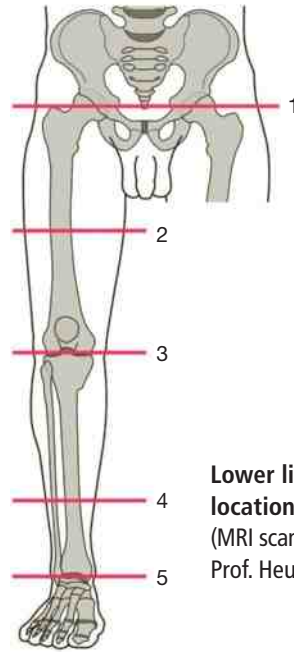


Coronal section through the foot and ankle joint (MRI scan; from Heuck et al., MRT-Atlas, 2009).

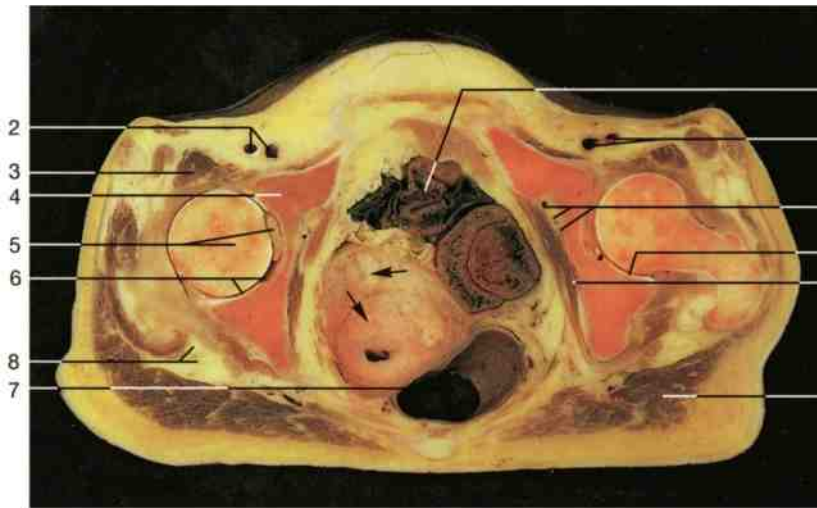
- | | |
|---|---|
| 1 Iliotibial tract | 26 Superficial peroneal nerve (with peroneal muscles laterally reflected) |
| 2 Common peroneal nerve | 27 Peroneus brevis muscle |
| 3 Position of head of fibula | 28 Lateral anterior malleolar artery |
| 4 Extensor digitorum longus muscle | 29 Fibula |
| 5 Muscular branches of deep peroneal nerve | 30 Distal tibiofibular joint (syndesmosis) |
| 6 Superficial peroneal nerve | 31 Talocalcaneal interosseous ligament |
| 7 Tendon of extensor digitorum longus muscle | 32 Calcaneus |
| 8 Lateral malleolus | 33 Tendon of peroneus brevis muscle |
| 9 Extensor digitorum brevis muscle | 34 Cuboid bone |
| 10 Tendons of extensor digitorum longus muscle | 35 Lateral cuneiform bone |
| 11 Patella | 36 Metatarsal bones |
| 12 Patellar ligament | 37 Dorsal interosseous muscles |
| 13 Anterior margin of tibia | 38 Tibia |
| 14 Anterior tibial artery | 39 Ankle joint |
| 15 Tibialis anterior muscle | 40 Medial malleolus |
| 16 Deep peroneal nerve | 41 Talus |
| 17 Extensor hallucis longus muscle | 42 Talocalcaneonavicular joint |
| 18 Tendon of tibialis anterior muscle | 43 Navicular bone |
| 19 Extensor retinaculum | 44 Medial cuneiform bone |
| 20 Dorsalis pedis artery | 45 Intermediate cuneiform bone |
| 21 Extensor hallucis brevis muscle | 46 First metatarsal bone |
| 22 Deep peroneal nerve (on dorsum of foot) | 47 Metatarsophalangeal joint of great toe |
| 23 Dorsal digital nerves (terminal branches of deep peroneal nerve) | 48 Proximal phalanx of great toe |
| 24 Deep peroneal nerve | 49 Distal phalanx of great toe |
| 25 Peroneus longus muscle (cut) | 50 Heads of metatarsal bones II–III |



Axial section through the pelvis and the hip joints (section 1; MRI scan; inferior aspect).

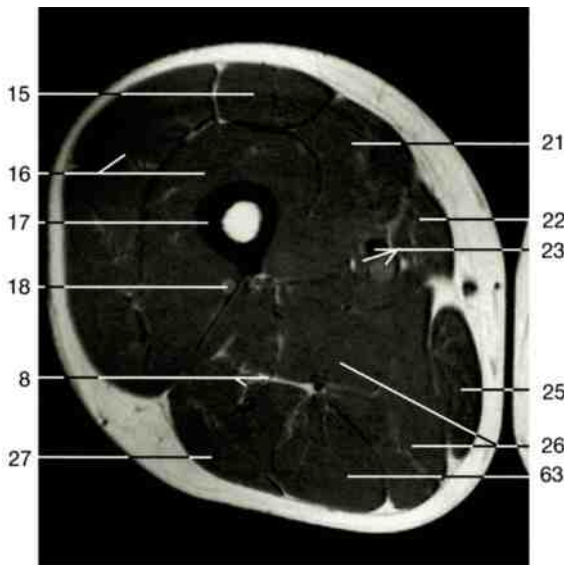


Lower limb, location of sections 1–5 (MRI scans, courtesy of Prof. Heuck, Munich, Germany).

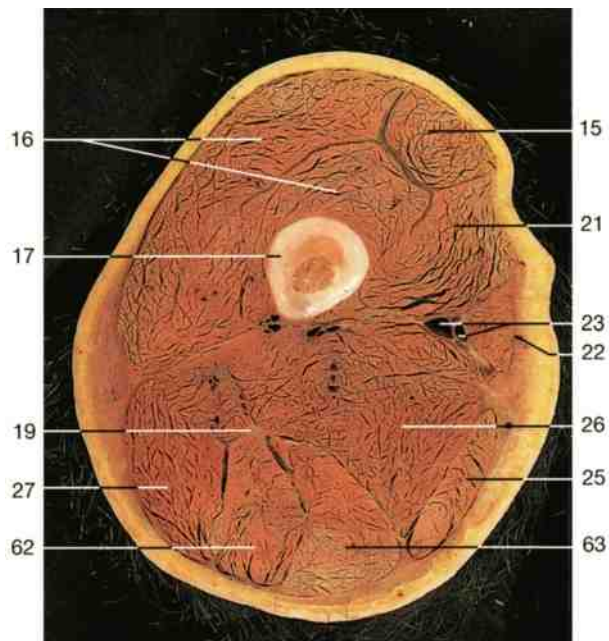


Axial section through the pelvis and the hip joints in the female (section 1; inferior aspect). Arrows: uterus, myometrium with myoma.

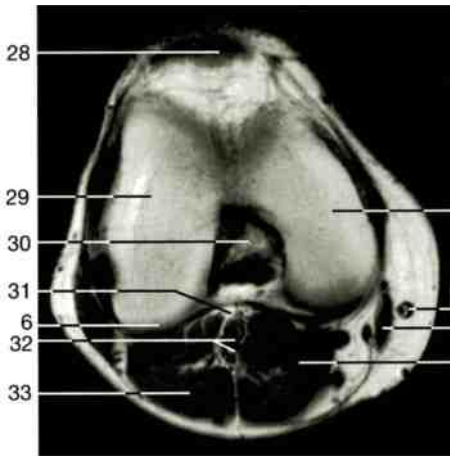
- 1 Sartorius muscle
- 2 Femoral artery and vein
- 3 Iliopsoas muscle
- 4 Pubis (os pubis)
- 5 Femoral head with ligament of femoral head
- 6 Articular cavity
- 7 Rectum
- 8 Sciatic nerve and accompanying artery
- 9 Gluteus maximus muscle
- 10 Obturator vessels and obturator nerve
- 11 Rectus abdominis muscle
- 12 Pyramidalis muscle
- 13 Urinary bladder
- 14 Obturator internus muscle
- 15 Rectus femoris muscle
- 16 Vastus intermedius and vastus lateralis of quadriceps femoris muscle



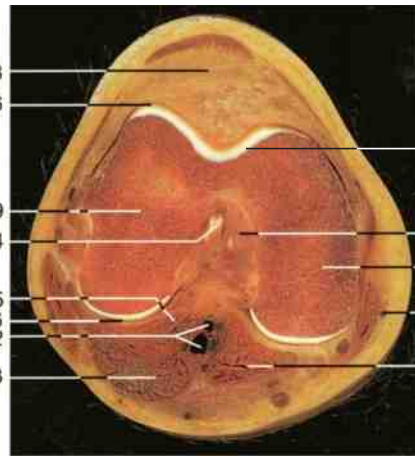
Axial section through the middle of the right thigh (section 2; MRI scan; inferior aspect).



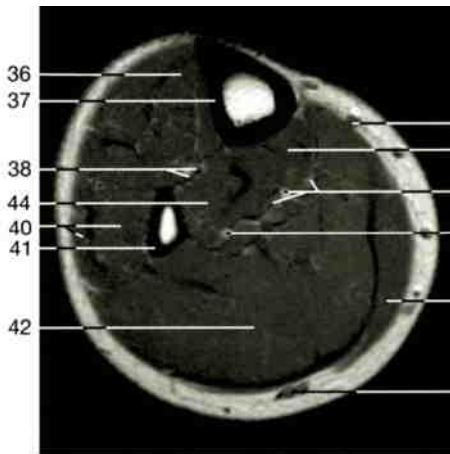
Axial section through the middle of the right thigh (section 2; inferior aspect).



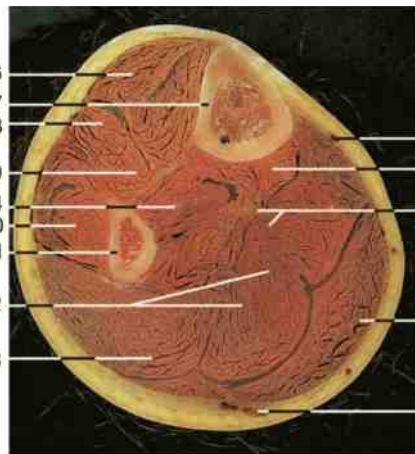
Axial section through the right knee joint (section 3; MRI scan; inferior aspect).



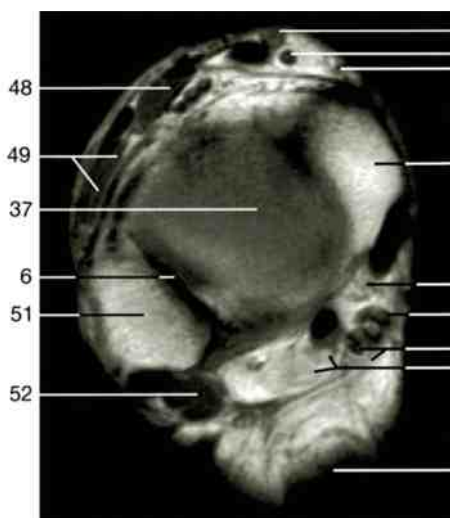
Axial section through the right knee joint (section 3; inferior aspect).



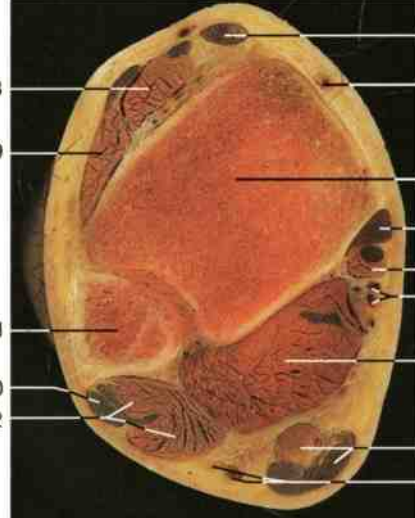
Axial section through the middle of the right leg (section 4; MRI scan; inferior aspect).



Axial section through the middle of the right leg (section 4; inferior aspect).

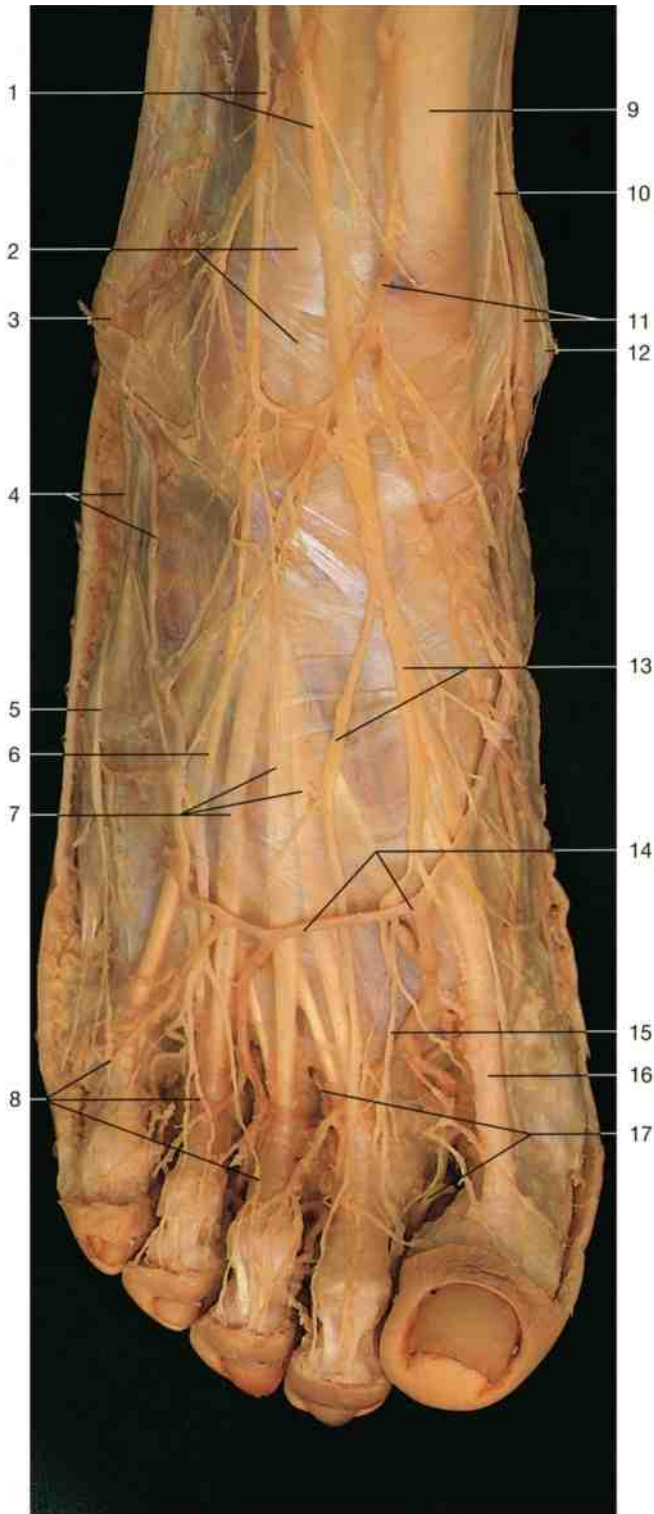


Axial section through the end of the right leg (section 5; MRI scan; inferior aspect).

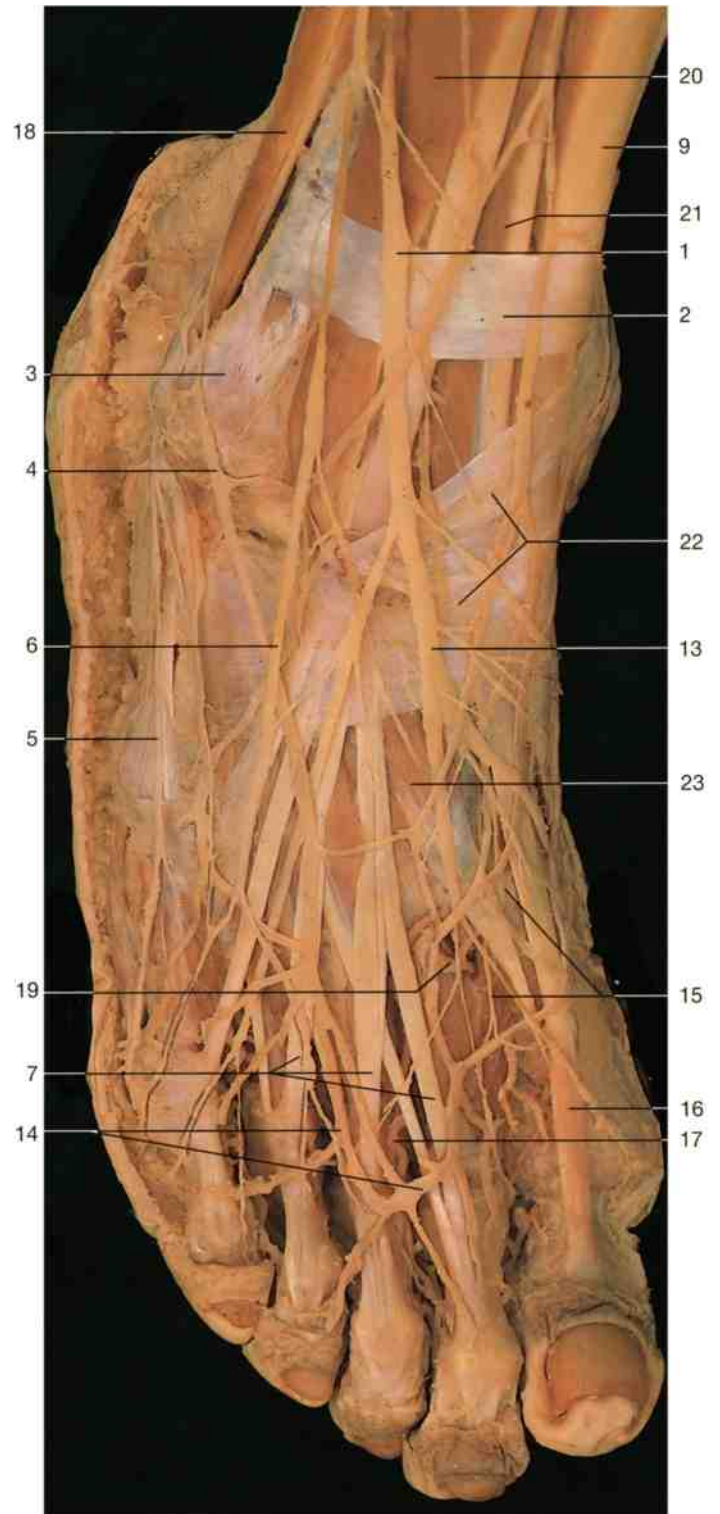


Axial section through the end of the right leg (section 5; inferior aspect).

- 17 Femur
- 18 Perforating artery
- 19 Sciatic nerve
- 20 Gluteus maximus muscle (insertion)
- 21 Vastus medialis muscle
- 22 Sartorius muscle
- 23 Femoral artery and vein
- 24 Great saphenous vein
- 25 Gracilis muscle
- 26 Adductor muscles
- 27 Biceps femoris muscle
- 28 Patellar ligament
- 29 Lateral condyle of femur
- 30 Posterior cruciate ligament
- 31 Tibial nerve
- 32 Popliteal artery and vein
- 33 Lateral head of gastrocnemius muscle
- 34 Medial condyle of femur
- 35 Medial head of gastrocnemius muscle
- 36 Tibialis anterior muscle
- 37 Tibia
- 38 Deep peroneal nerve, anterior tibial artery, and vein
- 39 Patellar surface
- 40 Peroneus longus and brevis muscles
- 41 Fibula
- 42 Soleus muscle
- 43 Flexor digitorum longus muscle
- 44 Tibialis posterior muscle
- 45 Posterior tibial artery and vein and tibial nerve
- 46 Peroneal artery
- 47 Small saphenous vein and sural nerve
- 48 Extensor hallucis longus muscle
- 49 Extensor digitorum longus muscle
- 50 Tendon of peroneus longus muscle
- 51 Lateral malleolus (fibula)
- 52 Peroneus brevis muscle
- 53 Tibialis anterior muscle (tendon)
- 54 Dorsalis pedis artery
- 55 Medial malleolus (tibia)
- 56 Tibialis posterior muscle (tendon)
- 57 Flexor digitorum longus muscle (tendon with synovial sheath)
- 58 Flexor hallucis longus muscle
- 59 Posterior tibial artery and vein
- 60 Lateral and medial plantar nerves
- 61 Calcaneal tendon
- 62 Semitendinosus muscle
- 63 Semimembranosus muscle
- 64 Anterior cruciate ligament
- 65 Plantaris muscle
- 66 Small intestine



Dorsum of the right foot, superficial layer (anterior aspect).

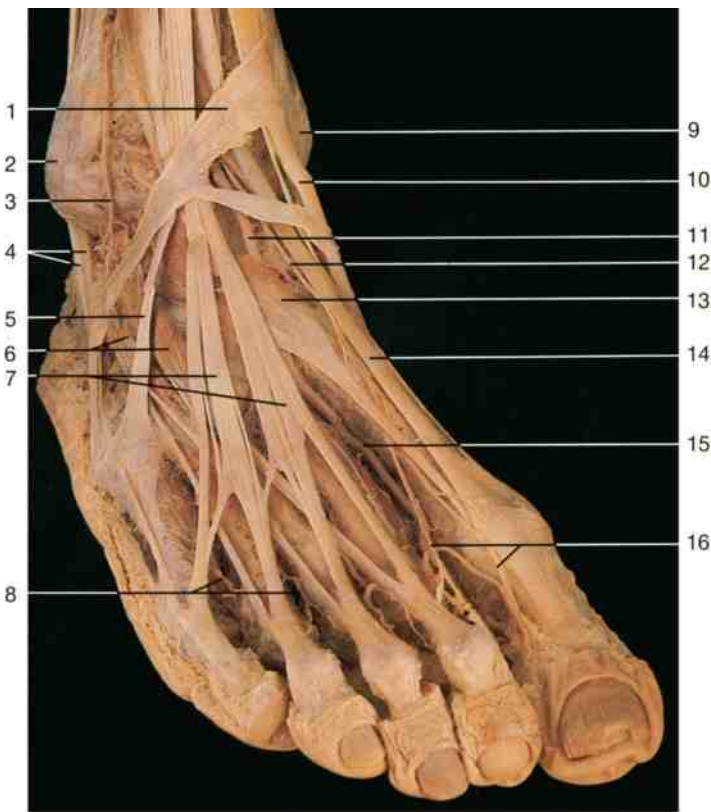


Dorsum of the right foot, superficial layer (anterior aspect). The fascia of the dorsum has been removed.

- 1 Superficial peroneal nerve
- 2 Superior extensor retinaculum
- 3 Lateral malleolus
- 4 Venous network of lateral malleolus and tributaries of small saphenous vein
- 5 Lateral dorsal cutaneous nerve (branch of sural nerve)
- 6 Intermediate dorsal cutaneous nerve
- 7 Tendons of extensor digitorum longus muscle
- 8 Dorsal digital nerves

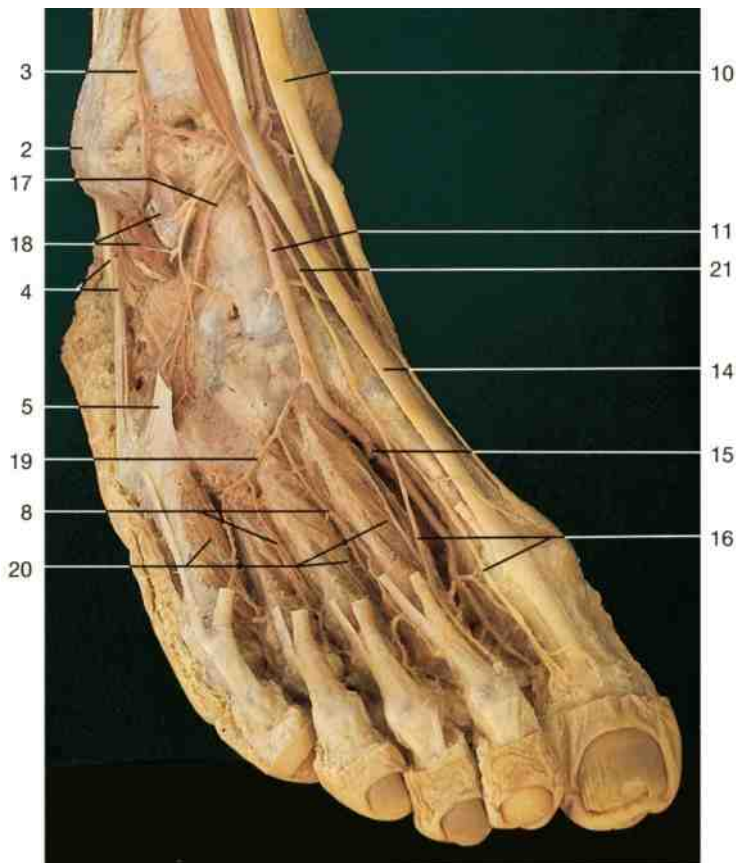
- 9 Tendon of tibialis anterior muscle
- 10 Saphenous nerve
- 11 Venous network of medial malleolus and tributaries of great saphenous vein
- 12 Medial malleolus
- 13 Medial dorsal cutaneous nerves
- 14 Dorsal venous arch
- 15 Dorsal digital nerve (of deep peroneal nerve)
- 16 Tendon of extensor hallucis longus muscle

- 17 Dorsal digital arteries
- 18 Peroneal muscles
- 19 Deep plantar branch of dorsalis pedis artery anastomosing with plantar arch
- 20 Extensor digitorum longus muscle
- 21 Extensor hallucis longus muscle
- 22 Inferior extensor retinaculum
- 23 Extensor hallucis brevis muscle

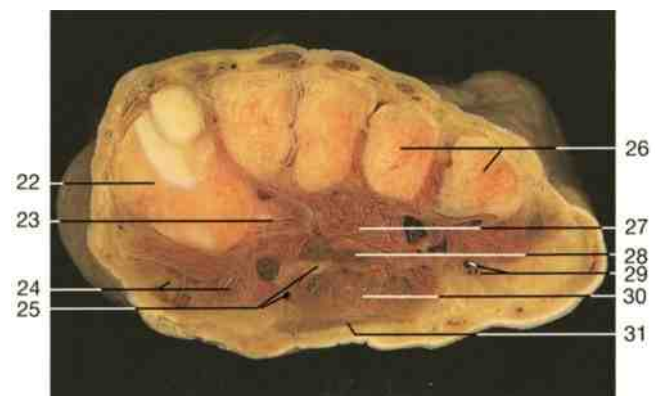


Dorsum of the right foot, middle layer (antero-lateral aspect).
The cutaneous nerves have been removed.

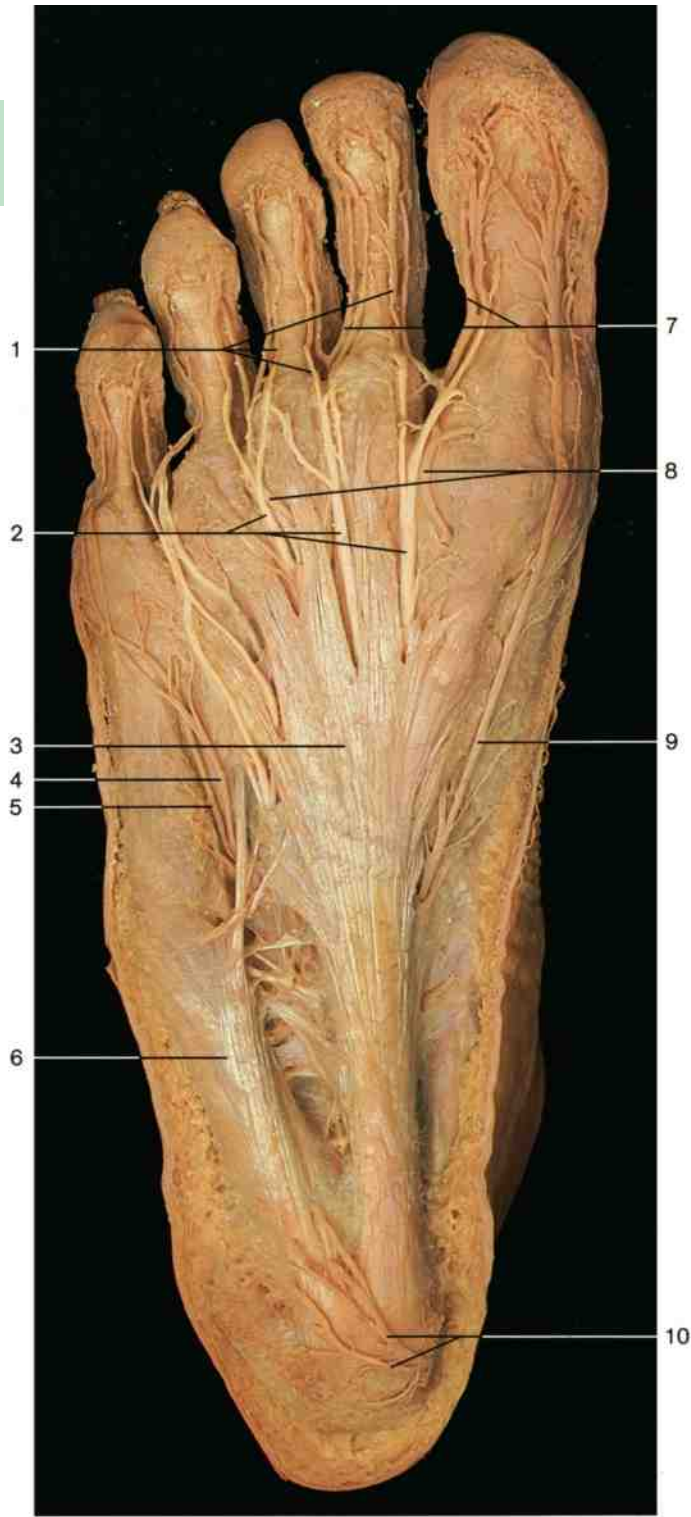
- 1 Extensor retinaculum
- 2 Lateral malleolus
- 3 Lateral anterior malleolar artery
- 4 Tendons of peroneal muscles
- 5 Tendon of peroneus tertius muscle
- 6 Extensor digitorum brevis muscle
- 7 Tendons of extensor digitorum longus muscle
- 8 Dorsal metatarsal arteries
- 9 Medial malleolus
- 10 Tendon of tibialis anterior muscle
- 11 Dorsalis pedis artery
- 12 Deep peroneal nerve (on dorsum of foot)
- 13 Extensor hallucis brevis muscle
- 14 Tendon of extensor hallucis longus muscle
- 15 Dorsalis pedis artery with deep plantar branch to the plantar arch
- 16 Dorsal digital nerves (terminal branches of deep peroneal nerve)
- 17 Lateral tarsal artery
- 18 Extensor digitorum brevis muscle (divided)
- 19 Arcuate artery
- 20 Dorsal interosseous muscles
- 21 Deep peroneal nerve
- 22 Medial cuneiform and first metatarsal bone
- 23 Tendon of peroneus longus muscle
- 24 Abductor hallucis and flexor hallucis brevis muscles
- 25 Medial plantar artery, vein, and nerve
- 26 Fourth and fifth metatarsal bone
- 27 Adductor hallucis muscle (oblique head)
- 28 Tendons of flexor digitorum longus muscle
- 29 Lateral plantar artery, vein, and nerve
- 30 Flexor digitorum brevis muscle
- 31 Plantar aponeurosis



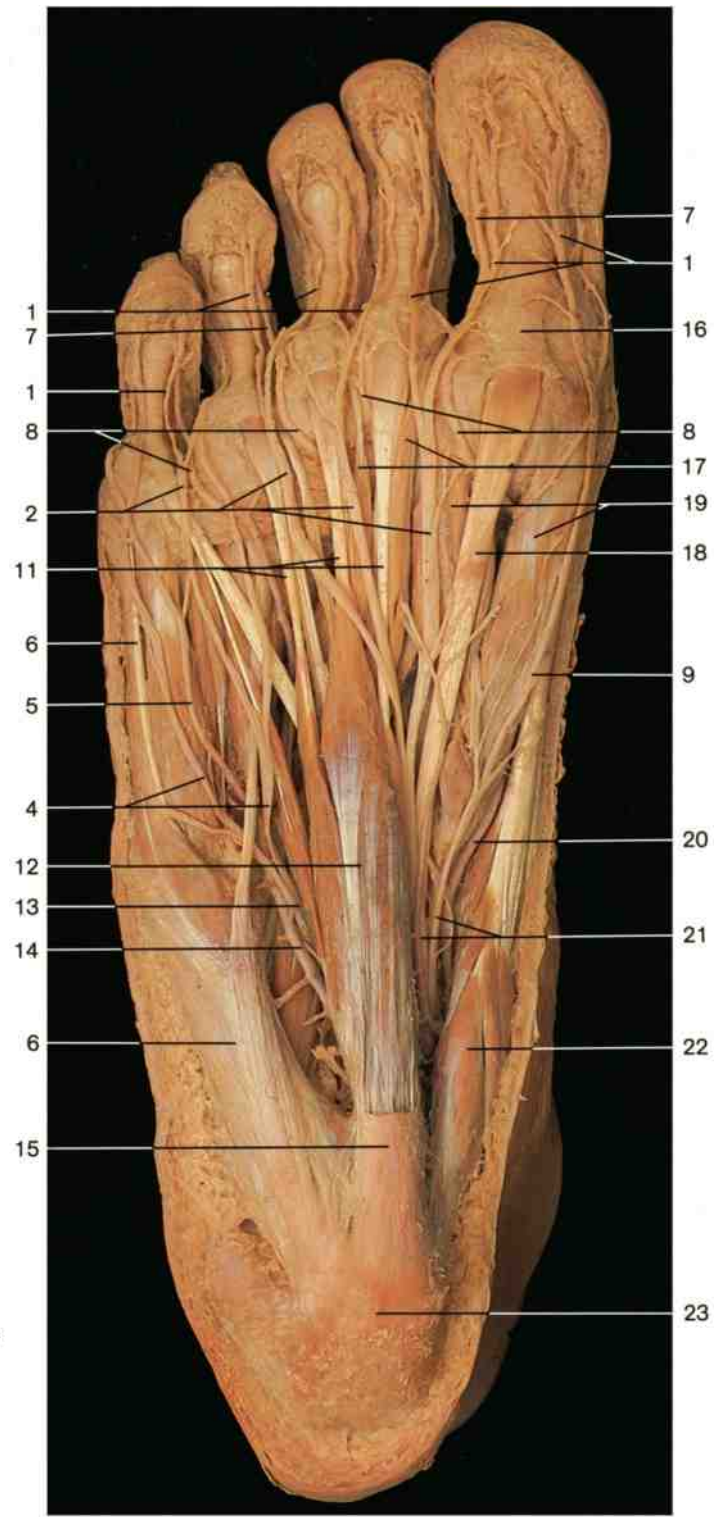
Dorsum of the right foot, deep layer (antero-lateral aspect).
The extensor digitorum and hallucis brevis muscles have been removed.



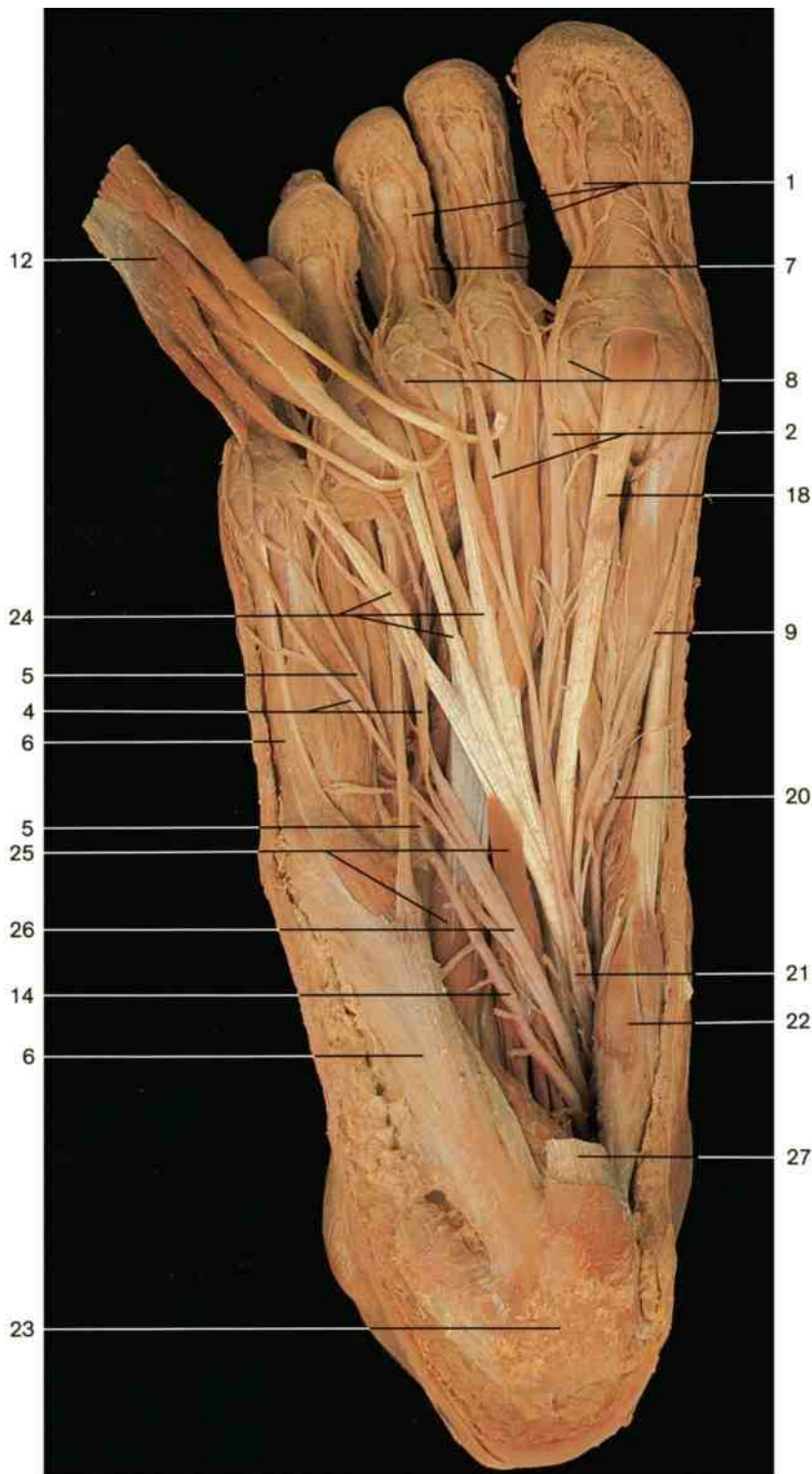
Cross section of the right foot at the level of the metatarsal bones (posterior aspect).



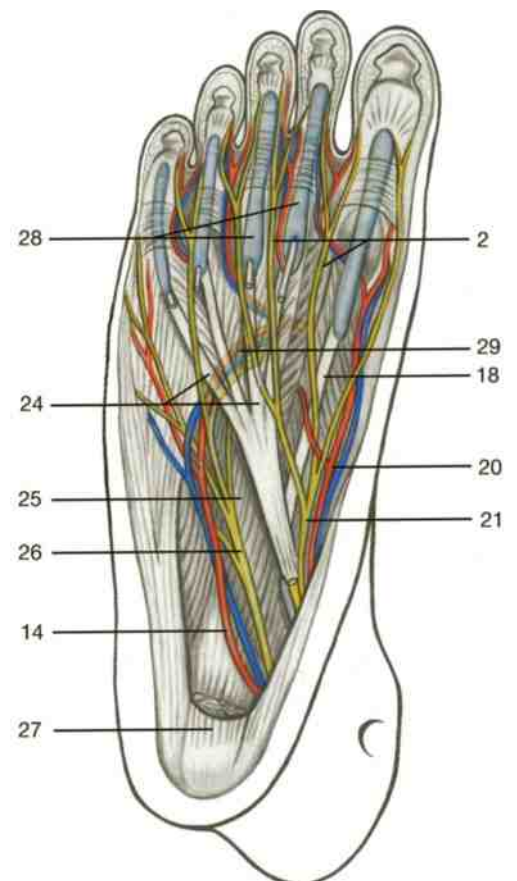
Sole of the right foot, superficial layer (from below).
Dissection of cutaneous nerves and vessels.



Sole of the right foot, middle layer (from below).
The plantar aponeurosis has been removed.

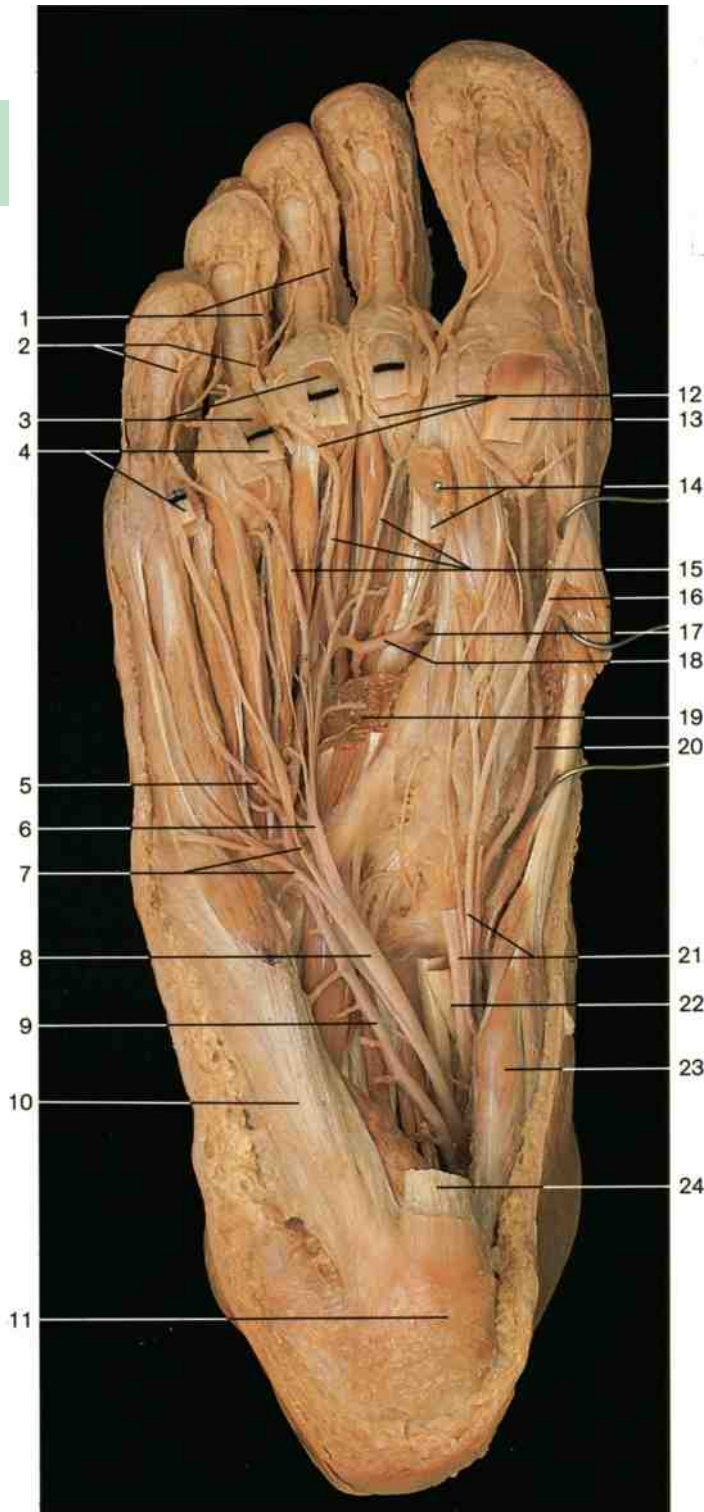


- 1 Proper plantar digital nerves
- 2 Common plantar digital nerves
- 3 Plantar aponeurosis
- 4 Superficial branch of lateral plantar nerve
- 5 Superficial branch of lateral plantar artery
- 6 Abductor digiti minimi
- 7 Proper plantar digital arteries
- 8 Common plantar digital arteries
- 9 Digital branch of medial plantar nerve to great toe
- 10 Medial calcaneal branches
- 11 Tendons of flexor digitorum brevis muscle
- 12 Flexor digitorum brevis muscle
- 13 Superficial branch of lateral plantar nerve
- 14 Lateral plantar artery
- 15 Plantar aponeurosis (remnant)
- 16 Digital synovial sheath
- 17 Lumbrical muscles
- 18 Tendon of flexor hallucis longus muscle
- 19 Flexor hallucis brevis muscle
- 20 Medial plantar artery
- 21 Medial plantar nerve
- 22 Abductor hallucis muscle
- 23 Calcaneal tuberosity
- 24 Tendons of flexor digitorum longus muscle
- 25 Quadratus plantae muscle
- 26 Lateral plantar nerve
- 27 Flexor digitorum brevis muscle (cut)
- 28 Synovial sheaths
- 29 Plantar arch



Sole of the right foot, middle layer (from below). Dissection of vessels and nerves. The flexor digitorum brevis muscle has been divided and anteriorly reflected.

Sole of the right foot. Synovial sheaths of flexor tendons indicated in light blue (schematic drawing).



- 1 Proper plantar digital arteries
- 2 Proper plantar digital nerves
- 3 Tendons of flexor digitorum brevis muscle
- 4 Tendons of flexor digitorum longus muscle
- 5 Superficial branch of lateral plantar artery
- 6 Deep branch of lateral plantar nerve
- 7 Superficial branch of lateral plantar nerve
- 8 Lateral plantar nerve
- 9 Lateral plantar artery
- 10 Abductor digiti minimi muscle
- 11 Calcaneal tuberosity
- 12 Common plantar digital arteries
- 13 Tendon of flexor hallucis longus muscle
- 14 Insertion of both heads of adductor hallucis muscle
- 15 Plantar metatarsal arteries
- 16 Medial plantar nerve of great toe
- 17 Deep plantar branch of dorsalis pedis artery (perforating branch)
- 18 Plantar arch
- 19 Oblique head of adductor hallucis muscle (cut)
- 20 Medial plantar artery
- 21 Medial plantar nerve
- 22 Crossing of tendons in sole of foot (flexor hallucis longus and flexor digitorum longus muscles)
- 23 Abductor hallucis muscle
- 24 Origin of flexor digitorum brevis muscle

Sole of the right foot, deep layer (from below). Dissection of vessels and nerves. The flexor digitorum brevis muscle, the quadratus plantae muscle with the tendons of the flexor digitorum longus muscle, and some branches of the medial plantar nerve have been removed. The flexor hallucis brevis and adductor hallucis muscles have been cut and portions removed to show the somewhat atypical course of the medial plantar artery and deep muscles of the foot.

Index

Page numbers in **bold** indicate main discussions.

A

- Abdomen, parasagittal section 298
- Abdominal organs 291 ff
 - position 292, 306
 - upper 301, 312 ff
 - – arteries 314 f
 - – blood supply 316
 - vessels 302 ff
- Abduction of fingers 395
- Acetabulum 188, 345, 432
 - bony margin 438
 - lunate surface 433, **436**, 445
- Achilles tendon 449, **457 ff**, 489, 491 ff
 - surface anatomy 476
- Acromion 15, 188 f, **369 ff**, 378, 382, 384 f
- Adduction of fingers 395
- Adductor hiatus 453
- Adhesion, interthalamic 86, **107**
- Adnexa of uterus 359 ff
- Air cells
 - ethmoidal 28, 36, **38**, 41 f, 44 f, **48**, 53, 135
 - – openings 144
 - mastoid 70, 125 ff
- Ala s. also Wing
 - of central lobule of vermis 102
 - of ilium 435
 - of sacrum **434 f**, 438
 - of vomer 37, 45, **48 f**
- Amnion 359
- Ampulla 128 f
 - bony 129
 - of ductus deferens **336 ff**, 342, 344
 - of rectum 342, 354
 - of uterine tube 358, 361, 366
- Amygdala (amygdaloid body) **107**, 110 f, **114 f**, 116
- Anastomoses, portocaval 303
- Aneurysm, infrarenal, of aorta 348
- Angiogram(-graphy)
 - fluorescent, of eye 134
 - internal carotid artery 95 f
- Angle
 - costal 192
 - inferior, of scapula **370 f**, 382 f
 - infrasternal 7, 192, 248
 - – surface anatomy 204
 - lateral, of scapula 188, **370 f**
 - of mandible 21, **52**
 - of ribs 370
 - sphenoidal, of parietal bone 29
 - sternal 192 f
 - superior, of scapula 371
 - venous
- – left 17
- – right 17, 398
- Ankle joint 432, **443**, **449 ff**, 495
- Ansa
 - cervicalis 71, **163**, 177, **181 f**, 266
 - – muscular branches 181, 265
 - – root
 - – – inferior 184
 - – – superior 69, 71, **82 f**, 152, 179
 - lenticular 116
 - subclavia of sympathetic trunk 169
 - thyroid, of sympathetic trunk 169
- Antihelix 124
- Antitragae 124
- Antrum
 - mastoid 127
 - pyloric 294, 324
 - tympanic 126
- Anulus
 - fibrosus 198
 - inguinalis s. Ring, inguinal
 - tympanic, of newborn 33
- Anus 350 ff, 354, 361 ff, 366
- Aorta 16 f
 - abdominal 16, 210, **245**, 256, 278, 292, 296, 300, 302, 329 ff, **348**, 359 f
 - – subtraktion angiography 328
 - ascending 243, 245, **252 ff**, 260, 266, 272, 284, 396
 - – bypass vessel 263
 - – of fetus 288
 - – horizontal section 286
 - descending 244, 252 f, 276
 - – of fetus 288 f
 - – horizontal section 286
 - – main branches 281
 - relation to bronchial tree 275
 - thoracic 253, 274, **281**
- Aperture
 - lateral, of fourth ventricle 112
 - of Luschka 112
 - of Magendie 94, **112**
 - median, of fourth ventricle 94, **112**
 - nasal, anterior 22 f, 45
 - pelvic, inferior 434, **438**
- Apex
 - of cochlea 125
 - of head of fibula 440
 - of heart **252**, 257 f, 262 f
 - of lung 248 f, 271
 - of patella 441
 - of petrous part of temporal bone 27, 127
 - of sacrum 191
 - of urinary bladder 337, 339, 357
- Aponeurosis 388 ff
 - of abdominal wall 187
 - bicipital **387 f**, 416, 423
 - of external abdominal oblique muscle 217, 362
- of levator palpebrae superioris muscle 142
- palmar 388, 423
- – transverse fasciculi 388
- plantar 449, **463**, 499, 501
- – longitudinal bands 463
- Apparatus
 - auditory 22, **122 ff**, 129
 - lacrimal 142
 - masticatory 22
 - vestibular **122 ff**, 129
 - visual 132 ff
- Appendix(-ces) 304
 - of epididymis 343
 - epiploicae 306
 - fibrosa 299
 - of testis 343
 - vermiform 291, 304, **306 f**, 310, 318, 324
 - – Head's area 205
 - – orifice 310
 - – variations in the position 307
- Aqueduct
 - cerebral 65, 73 ff, **86**, 90, 94, 99, **112**, 116, 121
 - of cochlea 129
 - of vestibule 27, **129**
- Arachnoid mater 84 f, **89**, **92**, 100, 118
 - spinal 230, **232**, 474
- Arbor vitae of cerebellum 94, 116
- Arch
 - anterior, of atlas 165, 200, 203
 - aortic 95, 154, 169, 177, **245**, 253, 256 f, 273 f, 279, **284**
 - – of fetus 288 f
 - azygos 273 f, 276, 283
 - of cervical vertebra 239 f
 - costal 3 f, 188, **192 ff**, 196, 212 f, 243 f, 264 f, **370**
 - – surface anatomy 204
 - of cricoid cartilage 158
 - dental 52
 - iliopectineal 444 f, **453**
 - palatoglossal 147
 - palatopharyngeal 147
 - palmar
 - – deep 427, **429**
 - – superficial 396, 423, **426 ff**
 - plantar 467, 501 f
 - posterior
 - – of atlas **200**, 239
 - – of axis 239
 - pubic 436 f
 - tendinous
 - – of flexor digitorum superficialis muscle 418
 - – of soleus muscle 457, 491
 - venous
 - – dorsal, of foot **468**, 489, 492 f, 498
 - – jugular 170, **172**, 398, 406
 - of vertebra 191, 231, 474

Page numbers in **bold** indicate main discussions.

- Arch
 - zygomatic 20, **33**, 52, **54**, 60 f, 79
 - – coronal section 62
 - – of newborn 33
- Arcus costalis (s. also Arch, costal) 194
- Area
 - of acoustic centers 131
 - bare, of liver 299, 318
 - calcarina 138
 - cortical
 - – acoustic 101
 - – premotor 101
 - – reading comprehension 101
 - – sensory speech 101
 - – somatomotor 101
 - – somatosensory 101
 - – visuosensory 101
 - – of Wernicke 101
 - cribriform, of renal papilla 326
 - intercondylar, anterior, of tibia 440
 - muscle-free, of pharynx 167
 - of primary acoustic centers 131
 - vestibular, superior 123, 130
- Areola **204**, 290
- Arm (s. also Limb, upper) 368
 - arteries 396 f
 - axial section 430
 - MRI scan 386
 - muscles 382 ff, **386 f**
 - nerves 399 f, **414 ff**
 - – cutaneous 400
 - sagittal section 386
 - surface anatomy 401 f
 - veins 398
- Arteriole
 - afferent, of glomerulus 329
 - efferent, of glomerulus 329
- Artery(-ies) **16**, 98, 241, 399 ff
 - alveolar
 - – inferior 63, 80, **81 ff**
 - – superior posterior 63, 82
 - angular 77, 79, 82, **168**
 - appendicular 302, 304, 310
 - arcuate
 - – of foot 467, 499
 - – of kidney 329
 - auricular
 - – deep 63
 - – posterior 80
 - axillary **168**, 170, **186**, 207, 252, 387, **396**, 411 f, 414 f
 - basilar 31, 74, 86, 89, **93 ff**, **98**, 116, 121
 - brachial 387, **396**, 403, 410, 412, 414 ff, 418, 423
 - – profunda 396, 404
 - buccal 63, **80**
 - – of bulb of penis 341, 351
 - capsular, lower, of kidney 328
 - carotid 154
 - – common 83, 95, 97, 152, **157**, **163**, 165, **168 ff**, 252 f, 255, 266, **281**, 396, 414
 - – – of fetus 288
 - – external 63, 67, 69, 79, **97**, **152**, 163, **164**, **168 ff**, **396**
 - – internal 31, 62, 67, 69, **73 f**, 87, 92 ff, 97 f, 122, 124, **168 ff**, **396**
 - – – Angiogram 95 f
 - – – loop 96
 - cerebellar
 - – inferior
 - – – anterior **93 f**, 96, 98
 - – – posterior **93 f**, 96, 98, 116
 - – – superior **93 f**, 96
 - cerebral 92 ff
 - – anterior 86, **92 ff**, 97 f, 111
 - – – area of blood supply 96
 - – – circle of Willis 93, 98
 - – – middle 92 ff, 98
 - – – area of blood supply 96
 - – – parietal branch 94
 - – – temporal branch 94
 - – MRI angiograph 95
 - – posterior **92 ff**, 97 f
 - – – area of blood supply 96
 - cervical
 - – ascending **168**, 170, 185, 396, 414
 - – deep **168**, 237
 - – superficial **168**, 170, 236
 - – transverse **168**, 170, 264, 396, 414
 - – – deep branch 235
 - – – superficial branch 235
 - ciliary
 - – anterior **93**, 133 f
 - – posterior 93
 - – – long 133 f
 - – – short 133 f
 - colic
 - – left 304, 308
 - – – anastomosis with middle colic artery 308
 - – middle **302 ff**, 308 f, 316 f, 328
 - – right 302 ff, 309
 - collateral
 - – medial 408
 - – middle 396, 409
 - – radial 396, 408 f
 - – ulnar
 - – – inferior 396, 415
 - – – superior 396, 416, 423
 - communicating
 - – anterior 93, 98
 - – posterior 92 ff, 98
 - coraco-acromial 411
 - coronary 262 f
 - – left 253, 258, **261 f**, 284, 286 f
 - – – circumflex branch 254, **262 f**
 - – – diagonal branch 262
 - – – interventricular branch 253
 - – – anterior 254 f, 263
 - – – septal branch 254
 - – right 243, **253 ff**, 257 f, 263, 270, 287
 - – – posterior interventricular branch 262
 - cortical, radiating 329
 - cystic 299, 316, 317
 - – deep
 - – – of clitoris 362, 365
 - – – of penis 339, 341, **346**, 347
 - digital
 - – dorsal, of foot 498
 - – palmar 396, **428**
 - – – common 396, 423, **427 f**
 - – – proper 425, **427 f**
 - – – of thumb 427
 - – – of thumb 428
 - – plantar
 - – – common 501 f
 - – – proper 501 f
 - dorsal
 - – of clitoris 365
 - – of penis 341 f, 346 f, 352
 - dorsalis pedis 467, 499
 - – deep plantar branch 498 f, 502
 - of ductus deferens 343
 - epigastric 265
 - – inferior 208, 212, 214, 216, 219, 293, 480
 - – – pubic branch **218**, 220
 - – superficial 208, 216
 - – superior 206, 208, **214**, 216, 264 ff
 - ethmoidal 94
 - – anterior 31, 134, 141, **146**
 - – – nasal branch 146
 - – posterior 134
 - facial 63, 77, **79**, 81, 97, 152, **168**, 170, 398
 - – transverse 63, **77**, 80, **168**, 170
 - femoral 214, 216 f, 293, 340, 360, 367, 452, **466 f**, 480, 496
 - – circumflex
 - – – lateral 467, **480 f**
 - – – – ascending branch 480 f
 - – – – descending branch 467, 480 f
 - – – medial 467, **480 f**
 - – – – ascending branch 481
 - – entering the adductor canal 452
 - gastric
 - – left 315 ff
 - – – esophageal branches 315
 - – – right 304, **315 ff**
 - – short 315 f
 - gastroduodenal 296, **315 ff**
 - gastro-epiploic 315 f
 - gastro-omental 315 f
 - genicular
 - – descending 467
 - – inferior
 - – – lateral 467, 487 f
 - – – medial 467, 487
 - – middle 467

Page numbers in **bold** indicate main discussions.

- - superior
 - - - lateral 467, 487 f
 - - - medial 467, 487
- gluteal
 - - inferior 346 f, **360**, 484
 - - superior 347, **360**
 - - - deep branch 483
- helicine 341
- hepatic
 - - common 296, 315 f
 - - of fetus 289
 - - proper 279, 296, 299 f, **304**, 316 f
 - - - left branch 315
 - - - right branch 315
- humeral, circumflex
 - - anterior 170, 396
 - - posterior 383, 396, 404 f, **408 f**
- ileal 303 ff, **309**
- ileocolic 302 ff, **309 f**
- iliac
 - - circumflex
 - - - deep 208, 216, 338, **467**, 480
 - - - superficial 208, 216, **467**
 - - common **281**, 308, 330 f, 346 f, 358 f
 - - external 293, 330, 332, 338, **346 f**
 - - internal 332, **346 f**, 360, 366
 - - - main branches 347
- iliolumbar 347
- infra-orbital 63, 142
- intercostal 206, **210 f**
 - - anterior 207
 - - highest 208, **281**
 - - medial branches 290
 - - posterior 214, 276, **279 ff**
 - - - dorsal branches 408
 - - superior 168
- interlobar, of kidney 329
- interlobular, of kidney 328 f
- interosseous
 - - anterior 396, 418, 423
 - - - posterior branch 421
 - - posterior 396, 421, **424**
- interventricular, anterior 257, 262, 270
 - - bypass vessel 263
- iridial 134
- jejunal 302 ff, **308 f**
- labial
 - - inferior 168
 - - superior 168
- of labyrinth 31, **93**, 98
- lacrimal **93**, 141
- laryngeal, superior 152, 166, 169
- lingual 146, **152**, **168**
 - - deep 153
- lumbar 335
- macular, superior 134
- malleolar, anterior, lateral 495, 499
- mandibular, inferior 63
- masseteric 63, **79**
 - - maxillary **62 f**, 79 f, **81 ff**, 97, **168**
 - - branches 63
 - - - deep temporal 63
 - - - pterygoid 63
- meningeal
 - - anterior 31
 - - base of skull 31
 - - middle 31, 63, 82 f, 85, 87 f, 126, 141
 - - - parietal branch 88
 - - posterior 31
- meningolacrimal 141
- mesenteric 308 f
 - - inferior **281**, 304 f, **308**, 329
 - - superior **281**, 283, 292, 296, 300, **302 ff**, **309**, 316 f, 328 f
- metacarpal, dorsal 424
- metatarsal
 - - dorsal 467, 499
 - - plantar 467, 502
- musculophrenic 206, 208, 216
- nasal
 - - dorsal 168
 - - inferior, of retina 134
 - - superior, of retina 134
- obturator **346 f**, 360, 366, 467
- occipital 63, **81 f**, **85**, **168**, 223, 235, 237 f, **240 ff**
 - - occipital branch 170
- ophthalmic **73**, **93 f**, 98, 132, **134**, 141, 146
- ovarian 328, 360
 - - ovarian branch 360
 - - tubal branch 360
- palatine
 - - descending 63, **146**
 - - greater 146
 - - lesser 146
- pallidostriate 92
- pancreaticoduodenal
 - - inferior 316 f
 - - superior 315
- - - anterior 316
- - - posterior 316
- perforating 467
- pericardiophrenic 272, 281
- perineal 346, 352
- - superficial 351
- peroneal 467 f, 491
- pharyngeal, ascending 146, 165
- phrenic, inferior 315, 328
- plantar 499
 - - lateral **467**, 499, 501 f
 - - - superficial branch 501
 - - medial **467**, 499, 501 f
- popliteal 446, **467**, 484, **486 ff**, 491
- princeps pollicis 396, **427**
- profunda
 - - brachii 409, 415
 - - - anastomosis with posterior humeral circumflex artery 408 f
- - femoris 467, 481
- of pterygoid canal 63
- pudendal
 - - external **220**, 467
 - - internal 341, **346 f**, 351 f, 360, 362, 364, 483
- pulmonary 16, 252 f, 260, 273, **274 ff**, 281
 - - branches 246
 - - of fetus 288 f
- radial 388, **396**, **414 ff**, 419, 421, 423 f, 428
 - - dorsal carpal branch 424
 - - superficial palmar branch 396
- rectal
 - - inferior 346 f, **351 f**, 483
 - - middle 347
 - - superior 304, 308
- recurrent
 - - radial 396, **416 ff**
 - - ulnar 418
- renal **281**, **326 f**, 331, 335
 - - anterior branch 328
 - - left 292
 - - posterior branch 328
 - - superior 329
- retinal 134
 - - central **93**, 133 f
 - - of round ligament 360
- sacral
 - - lateral 347
 - - median 333
 - - middle 360
- scapular
 - - circumflex 378, 404 f, **408 ff**, 412
 - - descending **168**, 396, 404
 - - dorsal 168
- scrotal, posterior 351
- segmental, inferior, anterior, of kidney 328
- septal 146
- sphenopalatine 63
- sigmoid 304, 308, 346
- spinal
 - - anterior 31, 93, 98, 232, 474
 - - posterior 31, 93, 98, 232
- spiral, of renal pelvis 329
- splenic 279, 296, 300, **309**, 315 f, 328 f
 - - posterior pancreatic branch 316
- subclavian 95, 97, 170, **177**, 184, 206, 208, 252, 271, 273 ff, **281**, 396, 414
 - - of fetus 288
- subcortical, of kidney 329
- submental 152, **168**
- subscapular 396, 412, 415
- supra-orbital 134, **168**
 - - medial branch 82
- suprarenal
 - - inferior 328 f
 - - middle 328
 - - superior 328
- suprascapular 168, 170, 378, **396**, 404 f, 414

Page numbers in **bold** indicate main discussions.

- Artery(-ies)
 - suprascapular
 - – anastomosis with circumflex scapular artery 404
 - supratrochlear **93**, 134, **168**
 - sural 487, 491
 - tarsal, lateral 499
 - temporal
 - – deep 80, **82**
 - – – anterior 81
 - – inferior, of retina 134
 - – middle 168
 - – superficial 63, **77**, **81 ff**, 85, **168**, 170, 183
 - – – anterior articular branch 80
 - – – frontal branch 79 f, **168**
 - – – parietal branch 79 f, **168**
 - – superior, of retina 134
 - testicular 218, 328, 341, **343**, 346
 - thalamic 92
 - thoracic
 - – internal **168**, 177, 206, **208**, **214**, 216, **264 ff**, 272, 396, 398
 - – lateral 168, 170, 196, **207 f**, **214**, 396, 410, 412
 - – superior 396, 412
 - thoraco-acromial 168, 170, **184 f**, 207, 264, 396, 407
 - – acromial branch 407
 - – pectoral branch 407
 - thoracodorsal 396, 404, **407**, 410, 412, 415
 - thyroid
 - – inferior **168 f**, 177, 185, 396
 - – superior 152, **168 ff**, 177, 185, 396
 - tibial 468
 - – anterior 467 f, 491, 495
 - – posterior 457, **467 f**, 488, 491
 - tympanic
 - – anterior 126
 - ulnar 388, **396**, 415 ff, 419, 423, 425, 428
 - umbilical 289, **346 f**
 - – obliterated 293
 - – remnant 219
 - uterine 360, 366
 - – ovarian branch 360
 - vaginal 360
 - vertebral 31, 62, 69, 71, 89, **93 ff**, 96 ff, 165, **168 f**, 174, 177, 200, **237**, 240, 414
 - – muscular branch 237
 - vesical
 - – inferior 347
 - – superior 346 f
 - zygomatico-orbital 85
 - Articulation s. Joint
 - Atlas 53, 159, 165, **188 ff**, **192 ff**, **200 ff**, 240, 369 f
 - articulation with dens of axis 200
 - Atrium
 - left, of heart **245**, **252 ff**, 256 ff, 273, 281, 285
 - – midsagittal section 322
 - – orifices of pulmonary veins 285
 - nasal 144
 - right, of heart 244 f, **252 f**, 255 ff, 259, 261 ff, 270 f, 273, 283 f
 - – of fetus 288
 - Auditory apparatus **122 ff**, 129
 - Auditory pathway 131
 - Auricle 122 ff
 - of left atrium **252**, 258, 260 ff
 - – of fetus 288
 - of right atrium **244**, **252**, 255 f, 258, **260 ff**, 269, 271, 283
 - – of fetus 288
 - Axilla, lymphatics 290
 - Axis 159, **188 ff**, 192 ff, **200 ff**, 369 f
- ## B
- Back
 - innervation 229
 - muscles 221 ff
 - – deep 292
 - – deepest layer 224
 - nerves **226 ff**, 229
 - Ball-and-socket joint 10, 432
 - Band, longitudinal
 - inferior, of cruciform ligament 200 f
 - superior, of cruciform ligament 200 f
 - Base
 - of cochlea 123, 125, **129**
 - of coracoid process 371
 - of mandible 22 f
 - of metacarpal bone 376 f
 - of metatarsal bone 442
 - of patella 441
 - of proximal phalanx 376 f
 - of sacrum **191**, 434 f
 - of skull 20, **30 ff**, 84, 97, 203
 - – angulation 19, 37, 143
 - – bones 23
 - – canals 34
 - – cranial nerves **31**, **75**, 98
 - – fissures 34
 - – foramina 34
 - – inferior aspect 32 f
 - – internal aspect **30 f**, 34
 - – of newborn **33**, 35
 - of stapes 128
 - of urinary bladder 367
 - Bicuspid
 - first 50
 - second 50
 - Bifurcation
 - of atrioventricular bundle 261
 - of trachea 18, **246**, **274 ff**, 281
 - Bile duct(s) 296 f
 - common 292, **296 f**, 299 f, 317
 - extrahepatic 296 f, **301**, **316**
 - Bladder, urinary s. Urinary bladder
 - Blindness 139
 - Body
 - amygdaloid **107**, 110 f, **114 ff**
 - of axis 200
 - carotid 164 f
 - cavernous s. Corpus cavernosum
 - of cervical vertebra 53, 177, **194 f**
 - – MRI scan 201, 203
 - ciliary 133
 - of clitoris 361 f, 365
 - of corpus callosum 99, **107**
 - of epididymis 343
 - of fifth lumbar vertebra 189
 - of first lumbar vertebra 189, 211
 - of fornix 106 f, 113
 - of gallbladder 297
 - geniculate 107
 - – lateral 131, 137
 - – medial 115, 131, 137
 - of hyoid bone **150**, 158
 - of incus 128
 - of ischium 433
 - of lumbar vertebra **190 f**, 194, **198 f**
 - mamillary 65 f, 86, 94, 99, 103, **107**, 137
 - of mandible 22 f, **52**
 - of maxilla 21 f
 - – nasal surface 42
 - of metacarpal bone 376
 - of pancreas 296 f, 316
 - perineal 350 f, 362
 - pineal 86, 99, 107, 115, 120
 - of pubis 433
 - restiform 116
 - retrosternal 398
 - of rib 192, **197**
 - of sphenoidal bone 26
 - of sternum 188 f, 192 f, **264**, **369 f**
 - of stomach 294, 316
 - of thoracic vertebra 192
 - trapezoid 131
 - of twelfth thoracic vertebra 189
 - of uterus 357
 - of vertebra 53, 177, **191 f**, **194 f**, 199
 - vitreous 133, **148**
 - Bone(s) 42, 155
 - capitate **376 f**, 380
 - – coronal section 425
 - carpal 7, **368**, **375 ff**, 427
 - cranial 20 ff
 - – of newborn 35
 - cuboid 443, 449, 495
 - cuneiform
 - – intermediate **442**, 449, 495
 - – lateral 443
 - – medial 495
 - ethmoidal 20 ff, 23, 34, **37 f**, **40 ff**, 44 f, 47
 - – of newborn 35

Page numbers in **bold** indicate main discussions.

- - orbital part 21
 - facial 20, **28**
 - - lateral aspect 52
 - frontal 7, 19 ff, 23, **28 f**, 34, 36 f, 42, **44 f**, 47, 52
 - - of newborn 35
 - - squamous part 28, **44 f**
 - - temporal surface 44
 - hamate **376 f**, 380
 - - coronal section 425
 - hyoid 20, 22, 55, **60 f**, 67, 69, 86, **150 f**, 154 f, **158 ff**, 161, **166**, 169, 175
 - incisive **33**, 45
 - lacrimal 20 ff, 23, 28, 37, 47, 52, 132
 - lunate **376 f**, 380
 - - coronal section 425
 - metacarpal 7, **368**, 375 ff, 427
 - - axial section 431
 - - coronal section 425
 - - first **375 ff**, 380, 425
 - - of newborn 9
 - - of thumb 375 f
 - metatarsal 7, 432, **442 f**, 449 ff, 495
 - - first 450
 - - of newborn 9
 - nasal 20 ff, 23, 37, **47 f**, 52, **144**
 - of nasal cavity 48
 - navicular **442**, 449 ff, 495
 - - articular surface 449
 - occipital 7, 20 f, **24 ff**, **27 ff**, 33 f, 37, **38 ff**, 42, 46 f, 194
 - - basilar part 25, 33
 - - lateral part 33, 39
 - - of newborn 33, **35**
 - - squamous part 20 f, 25, 28, 33, 39 ff, 44
 - - - lower part 27
 - - - upper part 27
 - palatine 20, **33**, 37, **39 ff**, 42, **44 f**, 48, 49
 - parietal 7, 20 ff, 23, **29**, 34, 37
 - - of newborn 33
 - pisiforme **377**, 381, 389 f, 394
 - pubic 346, 355
 - scaphoid **376 f**, 380
 - - coronal section 425
 - sesamoid 449
 - of skull 20 ff
 - sphenoidal 20 ff, 23, **24 ff**, 28, 33 f, 37, **38 ff**, **41 f**, 44 f
 - - of newborn 35
 - tarsal 7, 432
 - temporal 20 ff, 23, **27 ff**, 33 f, 37, 46 f, 52, **125**
 - - of newborn 35, 125
 - - petromastoid part 125
 - - petrous part 20, 33 f, 37, 122, 127, 130
 - - squamous part 20 f, **27 f**, 125
 - - - of newborn 35
 - - tympanic part 20 f, 27
 - trapezium 376 f
 - - coronal section 425
 - trapezoid **376 f**, 380
 - - coronal section 425
 - triquetral **376 f**, 380
 - - coronal section 425
 - zygomatic 7, 19 ff, 23, 28, 33, 37, 45, 47, 52, 54
 - - orbital surface 45
 - Border
 - anterior, of spleen 300
 - inferior, of lung 249
 - interosseous
 - - of fibula 440
 - - of tibia 440
 - lateral, of scapula 370 f
 - medial
 - - of scapula 371, 382
 - - of tibia 440
 - posterior, of fibula 440
 - superior, of scapula 371
 - Brachium of inferior colliculus 115, 131
 - Brain 3, **99 ff**
 - areas of blood supply 96
 - arterial blood supply 92
 - coronal section 92, **116 f**
 - cross section 116 f
 - dissections 104 ff
 - divisions 91
 - horizontal section 118 ff
 - inferior aspect 65, **99**
 - median section 90 f
 - ventricular cavities 112
 - Brain stem **67**, **69 ff**, 84, **91**, **114 f**, 139
 - auditory pathway 131
 - median section 90 f
 - Breast, lymphatics 290
 - Breast tissue 290
 - Bronchial tree 246 f, 275
 - mediastinal dissection 247
 - Bronchus(-i) **246**, 249
 - primary
 - - left 276, 278 f, 281
 - - - of fetus 288
 - - right 280
 - secondary 278
 - segmental 246
 - Bulb 147
 - of aorta 244, 252, 259, 261
 - olfactory 31, **65 f**, **75**, 89, 99, 103, **107**, **146 f**
 - of penis **336 f**, 339, **342**, 345
 - of vestibule 355, **360 ff**, 364
 - Bulla, ethmoidal 37, 53, 145
 - Bundle
 - atrioventricular 261
 - of His 261
 - Bursa
 - of Achill tendon 449
 - omental 292, **311 ff**
 - - horizontal section 324
 - - isthmus 318
 - - midsagittal section 322
 - - splenic recess 318
 - - superior recess 318
 - suprapatellar 446 ff
 - Bypass vessel 263
- ## C
- Calcaneus 7, **443**, 449, 451, 495
 - articular surface
 - - talar
 - - - anterior 449
 - - - middle 449
 - - - posterior 449
 - of newborn 9
 - Calcar avis 104, 106, **110**
 - Calvaria **29**, 53, 87 ff, 97, 149
 - Calyx, renal 326 f
 - major 326
 - minor 326 f
 - Canal
 - adductor 452
 - - entrance 480
 - - tendinous wall 467
 - anal 3, **336 f**
 - - coronal section 345
 - - midsagittal section 322
 - carotid 27, 31, **33**, 46, 98, 125, 127, **164**
 - central 86, 91, 116
 - cervical 357
 - condylar 25, 27, **33**, 39
 - facial 31, 125 f, 129 f
 - gastric 294
 - for greater petrosal nerve, hiatus 27
 - hypoglossal 25, **30 f**, **33**, 36, 39, 46, 201
 - incisive **33**, 42, 145, 147
 - infra-orbital 46
 - inguinal 217 f
 - - in the female **220**, 323
 - - in the male 217 ff
 - mandibular 165
 - - entrance **52**, 83
 - musculotubal 129
 - nasolacrimal **46 f**, 132
 - obturator 444 f
 - optic 23, 25 f, **30 f**, 34, 38, 44, 46 f, 132, **138**
 - osseus semicircular
 - - anterior **123 ff**, **129 f**
 - - lateral **123 ff**, 127, **129 f**
 - - posterior 124 f, **129 f**
 - palatine
 - - greater 40, 46
 - - lesser 46
 - pterygoid 25, **33**, 45 f, 146, 164
 - pudendal, entrance 483
 - pyloric 294
 - sacral 434 f, **437**

Page numbers in **bold** indicate main discussions.

- Canal
 - of Schlemm 133
 - spiral, of cochlea 125
 - vertebral 88, 188, **230 ff**, 472
 - – sagittal section 232
- Canaliculus
 - chordae tympani 125
 - cochlear 27
 - lacrimal, inferior 142
 - mastoid 27, 125
- Canalis
 - carpi 14, **389**, 394 f, 427, 429
 - musculetubarius 27
- Canine 50 f
 - permanent 51
- Capitulum of humerus 373, 375, 379, 391
- Capsula adiposa perirenalis 296, 300, 324
- Capsule
 - articular 12
 - – of atlanto-occipital joint 200
 - – of elbow joint 379, **391**
 - – of hip joint 444
 - – of interphalangeal joint
 - – – of fingers 381
 - – – of toes 449
 - – of knee joint 12, 447 f
 - – of metacarpophalangeal joint 381
 - – – of thumb 381
 - – of metatarsophalangeal joint 449
 - – – of shoulder joint 378
 - – of temporomandibular joint 53 f
 - – – of wrist joint 380
 - external **116**, 120
 - fibrous, of kidney 326
 - – vessels 329
 - internal 92, **105**, 109 f, **111**, 113, 115 f
 - – anterior limb 120
 - – posterior limb 120
- Cardia 296, 300
- Carotid sheath 174
- Carotid sinus nerve 164 f
- Carpal tunnel 14, **389**, 394 f, 427, 429
- Cartilage(s)
 - alar
 - – greater 49
 - – lesser 49
 - articular
 - – of condylar process of mandible 54
 - – of knee joint 12
 - – of shoulder joint 15
 - arytenoid 158 f
 - corniculate 158
 - costal 7, 189, 192
 - cricoid 155, 157, **158 f**
 - of larynx 158
 - – nasal 49
 - – lateral 49
 - – septal 49
 - thyroid 151, 154 f, **158 f**, 255
 - – tracheal 158 f
- Cauda equina **230**, 232, 471
 - horizontal section 320, 324
- Cavity(-ies) 345
 - abdominal 1, **291 ff**
 - – coronal section 1
 - – CT scan 321
 - – frontal section 309
 - – horizontal section 320 f, 324
 - – midsagittal section 313
 - – MRI scan 309, 320
 - – parasagittal section 325
 - – posterior 332 f
 - – veins of posterior wall 279
 - articular 12
 - – elbow joint 431
 - – hip joint 496
 - – humeroradial joint 431
 - – knee joint 446
 - – shoulder joint 10, **15**, 378
 - cranial 84 ff
 - – coronal section 62
 - – glenoid 188 f, **369 ff**, 378
 - – nasal 7, 22, 31, 84, **88**, 90, **143 ff**
 - – arteries 146 f
 - – bones 48
 - – coronal section 62
 - – horizontal section 148
 - – lateral wall 145 ff
 - – – nerves 147
 - – median section 145
 - – nerves 146 f
 - – oral **50**, 84, 143, **150 ff**, 163
 - – coronal section 50, 62
 - – floor 150 f
 - – median section **88**, 145
 - – transverse section 82
 - pelvic
 - – in the female 366 f
 - – horizontal section 4
 - – in the male
 - – – coronal section 345
 - – – MRI scan 342, 345
 - – – nerves 349
 - – – parasagittal section 346
 - – – sagittal section 342
 - – – vessels 346 f
 - – MRI scan 4 f
 - of septum pellucidum 104, 120
 - thoracic
 - – coronal section 1
 - – parasagittal section 325
 - – posterior 332 f
 - – veins of posterior wall 279
 - – tympanic 69, 120, **122 ff**, **128 ff**
 - – medial wall 126 f
 - – roof 123
 - – uterine 367
 - ventricular, of brain 112
 - Cecum 291 f, 304, 307, 318
 - horizontal section 320
 - Center, acoustic 131
 - Cerebellum 66, 74 f, 84, 86, 90, 94, **102 f**
 - median section 90 f
 - Cerebrum 18, **99 ff**, 233
 - in neonate 233
 - Cervix of uterus 354, **356 f**, 359
 - vaginal portion 322, 356 f, 360
 - Chamber, anterior, of eyeball 134
 - Chiasma, optic 65 f, **73 f**, 86, 90 f, 99, 103, **138 f**
 - lesion 139
 - Choana 45, 146, 163, **164**
 - of newborn 33
 - Chondrocranium 22
 - Chord, oblique 379
 - Chorda(-ae)
 - tendineae 253, 256, 258
 - tympani 62, 68 ff, 77, **124 ff**, 128, 146
 - – extracranial part 126
 - – intracranial part 126
 - Chorion 359
 - Circle
 - arterial, of Willis 93, 98
 - greater, of iris 134
 - lesser, of iris 134
 - Circulation
 - collateral, of shoulder 404
 - lymphatic 16
 - portal 16
 - pulmonary 16
 - systemic 16
 - Circulatory system 16
 - fetal 288 f
 - shunts 288
 - Circumference, articular
 - of radius 374 f
 - of ulna 374 f
 - Cistern
 - cerebellomedullar 85 f, 89, **112**, **145**, 230, 240 f
 - chiasmatic 85
 - interpeduncular 85
 - of lateral cerebral fossa 89
 - of pons 201
 - Cisterna chyli 17, 332
 - Clastrum 92, 116, 120
 - Clava 115
 - Clavicle 3, 7, 168, 174, 177, 187 ff, **206 ff**, **264**, 284, **368 ff**
 - articular facet
 - – for acromion 369
 - – for sternum 369
 - end
 - – acromial **369 f**, 378
 - – sternal 369 f
 - surface anatomy **204**, 401 f
 - Clitoris 354, **360 ff**
 - Clivus 25, 27, **30**, 38

Page numbers in **bold** indicate main discussions.

- Dura mater 89
- Coccyx 3, 7, 189, **191, 193**, 195, 350, **433 ff**, 437, 472
 - surface anatomy 476
- Cochlea **122 ff**, 127, 129
- Cockett veins 468 f
- Colliculus(-i)
 - facial 115
 - inferior of midbrain 67, 103, 111, **114 ff**, 131
 - of midbrain 67, 86, 90 f, 99, 107
 - seminal **338 f**, 344 f
 - superior of midbrain 114 ff
- Colon 3
 - ascending 302, 304, 307
 - descending 210, 304, 310
 - Head's area 205
 - sigmoid 292, 304, 306 f, 310, 322
 - transverse 244, 291 f, 302, 306 ff
 - – midsagittal section 322
- Column
 - of fornix 103, 105, 107, **114 ff**, 119 f
 - lateral, of erector spinae muscle 212
 - medial, of intrinsic muscles of back 212, **225**
 - renal 326
 - vertebral s. Vertebral column
- Commissure
 - anterior 86, 90 f, 94, **99, 107**, 110, 116, 137
 - of fornix 104
 - habenular 107
 - labial, posterior 361
- Concha
 - of auricle 122, **124**
 - nasal
 - – inferior 20, 22 f, 36 f, 42, 44, 46, **48, 53, 86**, 90, 142, **143 ff**, 147 f
 - – – inferior border 48
 - – middle 22 f, 33, 36 f, **38, 40, 44 f, 48, 86**, **143 ff**
 - – superior 36 f, **48, 86**, 145
- Condyle
 - lateral
 - – of femur 9, 439, **441, 447**
 - – of tibia **440**, 446 f
 - medial
 - – of femur 9, **439**, 447
 - – of tibia 440
 - occipital 21, 25, 27, **33**, 36, 46, 62, 202
- Cone, medullary, of spinal cord 472 f
- Confluence of sinuses 75, **85, 87 f**, 241
- Conjugate
 - diagonal 434, **438**
 - true 434, **438**
- Conjunctiva
 - of eyeball 133
 - palpebral, of lower lid 142
- Connection, intertendinous 392
- Conus
 - arteriosus 256, 258
 - – horizontal section 286
 - elasticus 158
 - medullaris 230, 232 f, **475**
 - – midsagittal section 322
 - – in neonate 233
- Cord
 - spermatic 204, 211 ff, 217, **219, 337, 340**, **343, 346**, 479 f
 - spinal s. Spinal cord
 - umbilical 233, 359
 - urachus 219
- Cornea **132 f**, 135 f
- Cornu s. also Horn
 - greater, of hyoid bone 61, 67, 149, **150, 158**, 167
 - inferior, of thyroid cartilage 159
 - lesser, of hyoid bone **150, 158**
 - sacral 191
 - superior, of thyroid cartilage 158 f
- Corona
 - of glans penis 342
 - radiata 109 f
- Corpus
 - callosum 62, 85 f, 233
 - – coronal section 116
 - – fiber system 104
 - – median section 90 f, 233
 - – in neonate 233
 - cavernosum
 - – of clitoris 356, 360
 - – of penis **336 ff**, 339 f, **341 f**, 347
 - spongiosum of penis 336 f, **339 ff**
 - sterni 194
- Cortex
 - cerebral 85, 92, **118 ff**
 - insular 113
 - of kidney 326
 - limbic 99
 - striate 121
 - of suprarenal gland 326
 - of temporal lobe 116
 - visual 121, **138**
- Costae fluctuantes 194
- Cowper's gland 336 f, 339, 342, **344**
- Crest
 - conchal 40, 42, 44
 - frontal 28, **30**
 - of greater tubercle of humerus 373
 - iliac 3, 189, 330, **433, 435**, 482 f
 - – surface anatomy 476 f
 - infratemporal 52
 - – of sphenoid 21, 25 f, 38
 - intertrochanteric 438 f
 - lacrimal
 - – anterior 41
 - – posterior 22
 - of lesser tubercle of humerus 373
 - nasal 40, 42, 44 f
 - of nasal septum 146
 - occipital
 - – external 25
 - – internal 27, **30**, 39, 42
 - sacral
 - – intermediate 191, 434
 - – lateral 191, 433 f
 - – median **191**, 195, 433 f, **437, 472**
 - sphenoidal 25
 - supraventricular 271
 - transverse 123
 - urethral 338
- Crista
 - galli **30, 34, 37, 38**, 40 f, 49, 53, 86
 - spiralis ossea 127
 - terminalis of right atrium 258, 283
- Crossing of tendons
 - in leg 460 f
 - in sole of foot 460 f, **464 f**, 502
- Crus
 - anterior, of stapes 128
 - cerebri 73
 - of clitoris 356, **361 f**, 364
 - commune 129
 - of fornix **105, 106**
 - lateral, of superficial inguinal ring 217, 362
 - long, of incus 126, 128
 - medial, of superficial inguinal ring 362
 - penis 337, 339, **342, 345, 352**
 - posterior, of stapes 128
 - right of lumbar part of diaphragm 282 f, 335
 - short, of incus 126, 128
- Culmen of vermis 102
- Cuneus 137
- Cupula 125, **129**
- Curvature
 - cervical 193
 - greater, of stomach 294 f, **311 f**, 316
 - lesser, of stomach 294 f, **311 f**
 - – longitudinal muscle layer 295
 - lumbar 193
 - thoracic 193
- Cusp 261
 - anterior, of tricuspid valve 258
 - semilunar
 - – anterior, of pulmonary valve 259
 - – left
 - – – of aortic valve 259
 - – – of pulmonary valve 259
 - – posterior, of aortic valve 259
 - – right
 - – – of aortic valve 259
 - – – of pulmonary valve 259
 - septal, of tricuspid valve 259, 261
- Cuspid (canine) 50 f
- permanent 51

Page numbers in **bold** indicate main discussions.

D

- Declive of vermis 102
- Decussation
 - of pyramidal tracts 109, **114**
 - of superior cerebellar peduncle 103
- Demifacet
 - inferior, for head of rib 191, **197**
 - superior, for head of rib 191, **197**
- Dens of axis 53, 86, 89 f, 165, **191**, 195, **200 f**, 203
 - articulation with atlas 200
- Dentition 50
- Desmocranium 22
- Diameter
 - largest, of pelvis 438
 - oblique 434
 - transverse 434
- Diaphragm 3, 16, 206, 244, 255, **264 ff**, 269 ff, 273, 276, 279 f, **281 ff**, 284 f, **292 f**, 307, 320
 - central tendon **278**, 283, 298, 329
 - changes of position during respiration 282
 - costal part 278, 282 f
 - lumbar part **282**, 315, 327
 - – right crus 282 f
 - midsagittal section 322
 - oral 150
 - pelvic
 - – in the female 362 f
 - – in the male 350 ff
 - sternal part 278, 283
 - superior aspect 283
 - urogenital
 - – fascia inferior 350
 - – in the female 362 ff
 - – in the male 337, 347, 350 ff, **353**
- Diaphragma sellae 75
- Diaphysis s. Shaft
- Diastole 260
- Diencephalon 91
- Digestive system, organization 291
- Digitations, hippocampal 107, **110**
- Diploe **30**, 53, 85, 87
- Direction of the body 4 f
- Disc
 - articular
 - – fibrocartilagenous 12
 - – of sternoclavicular joint 177
 - – of temporomandibular joint 54, 56 f, 79
 - – of wrist joint 380, **425**
 - intervertebral 7, 89, 193, **197 ff**, 472 f
 - – inner core 198 f
 - – midsagittal section 322
 - – MRI scan 195, 201, 203, 232
 - – outer portion 198
 - optic 133 f
- Dorsum
 - of foot 492 ff, **498 f**
 - sellae 25 f, **30**, 34, **36**, 38, 41, 46, 75
 - – of newborn 35
- Douglas'pouch **354**, 357 ff, 366 f
- Duct **128 ff**, **219**
 - cystic **296 f**, 299 f, 317
 - ejaculatory 336 ff, **344**
 - endolymphatic 128 f
 - epididymal 343
 - hepatic 296 f
 - – common 297, 299, 317
 - lymphatic, right 332
 - nasofrontal 145
 - nasolacrimal 135, **142**, 145
 - – opening 145
 - pancreatic **296 f**, **300 f**, 317
 - – accessory 297, **301**, 317
 - parotid 54, 58, 61, **77**, 82, 151, **153**, 168
 - perilymphatic 129
 - semicircular
 - – anterior **122**, 127 f
 - – lateral **122**, 127 f
 - – posterior **122**, 127 f
 - submandibular 152 f
 - thoracic 17, 170, **172 f**, 184 f, 276, 279, **332**
- Ductus 338
 - arteriosus Botalli 263, **288 f**
 - – remnant 253, 256
 - deferens 218 f, 330, **336 ff**, **341 ff**, 344
 - venosus 288 f
- Duodenum 291 f, 296, 300, 302, 316
 - descending part 297, **311 f**
 - Head's area 205
 - horizontal part 309, 317
 - superior part 312
- Dura mater **84 ff**, 87, **88 f**, 97, 118, 133, 200
 - spinal 69, 71, **198**, 230 f, **232**, 474

E

- Ear
 - inner 31, 122 ff, 128 ff
 - middle **122 ff**, 128
 - outer 122 ff
- Elbow joint 10, **368**, **374 f**, **379**
 - axial section 431
 - axis
 - – of extension 391
 - – of flexion 391
 - – of rotation 391
 - bones 374 f
 - coronal section 10, 379
 - ligaments 10, **379**
 - MRI scan 10, 379
 - of newborn 9
- Eminence
 - arcuate 27, **122**
 - carpal
 - – radial 394

- collateral 107
- frontal 35
- iliopubic 433, **435**, 438
- intercondylar 440 f
- parietal 29, **35**
- Epicardium 273
- Epicondyle
 - lateral
 - – of femur 439, **441**, 446
 - – of humerus **373**, 379, 391 f
 - medial
 - – of femur 439
 - – of humerus **373**, 379, 387 f, 415
- Epididymis 218, 330, **336 f**, 339, 341, **343**
 - longitudinal section 343
- Epiglottis 86, 89 f, 146, 155, **158**, 161, 163
- Epiphysis 114
- Epithelium
 - conjunctival 133
 - corneal 133
 - pigmented, retinal 133
- Equator of lens 133
- Esophagus 86, 154 f, 157, 244 f, **273 ff**, 279, 291
 - abdominal part 278, **282**
 - Head's area 205
 - horizontal section 286
 - relation to bronchial tree **275**
 - thoracic part 278, 281
- Eustachian valve (Valve of inferior vena cava) 288
- Exostosis 380
- Extremity s. also Limb
 - caudal, of caudate nucleus 110 f, 114
- Eye 84, **133 ff**
- Eyeball 68 f, **72 ff**, **133**, 142
 - anterior segment 133 f
- Eyelid 142
 - upper 142

F

- Facet, articular
 - for acromion 369, 371
 - inferior, of vertebra 191
 - for sternum 369
 - superior
 - – of atlas 191, 200
 - – of vertebra **191**, 197
- Falx
 - cerebelli 86
 - cerebri 67, **74 f**, **86 f**, 97, 120, 241
 - inguinalis 218
- Fascia
 - of adductor canal 452
 - antebrachial 388, 423
 - – distal part 428
 - cervical 178 ff

Page numbers in **bold** indicate main discussions.

- – lamina
- – pretracheal 174, 179 f
- – prevertebral 174
- – – superficial 174, 178
- cremasteric 341
- crural 493
- superficial 468, 486, **492**
- deep, of penis 339
- of external abdominal oblique muscle 213
- of Gerota 324 f
- inferior, of urogenital diaphragm 350
- lata **218**, 486
- pectoral 290
- pharyngobasilar 164, 167
- renal
 - – anterior layer 324 f
 - – posterior layer 324 f
- spermatic
 - – external 218, 340
 - – internal 218, 340, **343**
 - temporal **58 ff**, 79
- thoracolumbar 212, 214, 223, **455**
- transversalis 210, 212 f
- Fasciculus(-i)
 - longitudinal
 - – dorsal 107
 - – medial 116
 - mamillotegmental 107
 - mamillothalamic 107 f
 - of Schütz 107
 - transverse, of palmar aponeurosis 389
 - of Vicq d'Azyr 107 f
- Fastigium 102
- Fat
 - capsular, perirenal 300
 - epicardial 252
- Fat pad
 - buccal 168
 - infrapatellar 446, 448
- Fatty tissue
 - orbital 132
 - subcutaneous 210
- Femur 7, 12, 432, **438 f**, 441, 446 ff
 - coronal section 8 f
 - MRI scan 8
 - of newborn 9
 - ossification 9
 - proximal end 8
 - X-ray 8
- Fenestra 126
 - cochleae **125 f**, 128
 - vestibuli **125**, 129
- Fiber(s)
 - arcuate, cerebral 109, 116
 - corticospinal 116
 - intercrural 217 f, **220**, 362
 - pontine, transverse 109, 116
 - radiating, of corpus callosum 104
 - zonular 133
- Fibula 7, 12, 432, **440 ff**, 446 f, 493
 - of newborn 9
 - upper end 440
- Filum(-a)
 - radicularia posteriora 98, 239, **241**
 - terminale 230 ff, **475**
- Fimbria(-ae)
 - hippocampal 106 f
 - of uterine tube 354, **356 ff**
- Finger 368
 - joints 381
 - ligaments 381
- Fissure 23
 - cerebral, longitudinal 66, **99 f**, **104**
 - horizontal
 - – of cerebellum 101
 - – of right lung **244**, **246**, 248 f, 267 f
 - oblique
 - – of left lung **246**, 248 f
 - – of right lung **244**, **246**, 248 f, 267
 - orbital
 - – inferior 22 f, 33, 41, **47**, 132
 - – superior 22 f, 25, **30 f**, 34, 38, 40 f, **47**
 - petrotympanic 27, 125
- Flexure
 - colic
 - – left 284 f, **302**, **304**, 312, 316
 - – right 311 f
 - duodenojejunal 296, 302 ff, 306, **309 f**, 317 f
- Flocculus of cerebellum 66, **102**, 114
- Floor of the oral cavity 150 f
- Fluid, cerebrospinal 84 f
 - flow 85, **112**
- Fluorescent angiography of eye 134
- Fold(s)
 - ary-epiglottic 150, 160 f, 163
 - axillary
 - – anterior 385
 - – posterior 385
 - duodenal
 - – inferior 310
 - – superior 310
 - gastropancreatic 312
 - ileocecal 310
 - interureteric 338, **355**
 - iridial 134
 - of mucous membrane
 - – of gallbladder 297
 - – of stomach 294
 - – of urinary bladder 355
 - recto-uterine 366 f
 - salpingopalatine 145
 - salpingopharyngeal 144 f
 - umbilical
 - – content 293
 - – lateral **219**, 337
 - – medial **219**, 337 f
 - – median **219**, 293, 338, 354
- vestibular 161
- vocal 86, 89, **155**, **161**
- Fontanelle
 - anterior 35
 - antero-lateral 33, **35**
 - mastoid 33, **35**
 - posterior 35
 - postero-lateral 33, **35**
 - sphenoidal 33, **35**
- Foot 442 f
 - axis
 - – for eversion 449
 - – for inversion 449
 - – long 432
 - coronal section 495
 - cross section 499
 - ligaments 450 f
 - MRI scan 449, 495
 - of newborn, X-ray 9
 - sagittal section 449
 - skeleton 442 f
- Foramen(-ina)
 - alveolaria 41, 46
 - cecum 28, **30**, 149
 - epiploic **311 ff**, 315, 317 f
 - – midsagittal section 322
 - ethmoidal 132
 - – anterior 28, 46 f
 - – posterior 46 f
 - infra-orbital 22 f, 41 f, 44 f, **47**, 68, **142**
 - infrapiriform 482 f
 - interventricular, of Monroe 86, **94**, 99, **105**, **112 f**
 - intervertebral 193, **197 ff**, **472**
 - jugular **30 f**, **33 f**, 201
 - lacerum 26, **30**, 127, 164
 - magnum 25, **27**, **30 f**, **33 f**, 39, 62, 89, 201 f
 - mandibular 36, **52 f**
 - mastoid 27
 - mental 20 ff, 23, 51, **52**, 68 f
 - nasal, of nasal bone 47
 - nutrient 439
 - obturator 188 f, **433**, **436**
 - ovale 25 f, **30 f**, **33 f**, 38, 125, 164, 288 f
 - palatine
 - – greater 33, 37, 45, 164
 - – lesser 33, 45, 164
 - parietal 29
 - rotundum 25 f, **30 f**, 34, 38, 45, 46, 72
 - sacral
 - – anterior **434**, 438
 - – dorsal **191**, 195, **433 f**, 437
 - sciatic
 - – greater 444, **482 f**
 - – lesser 444, **482 f**
 - singulare 123
 - sphenopalatine 46
 - spinosum 25 f, **30 f**, 34, 38
 - stylo mastoid 27, 31, **33**, 70, 77, 127, 164

Page numbers in **bold** indicate main discussions.

- Foramen(-ina)
- supra-orbital 42, **44 f**
 - suprapiriform 482 f
 - transversarium 157, **191**
 - – of atlas 200
 - – of axis 200
 - vertebral 191
 - zygomaticofacial 28
- Forceps
- major of corpus callosum 104
 - minor of corpus callosum 104
- Forearm 368
- anterior region 423
 - arteries 397, 421
 - axial section 419, 431
 - blood vessels 419, 421
 - bones 374 f
 - muscles 388 ff, 419
 - – extensor 392 f
 - – flexor 389 ff
 - nerves 419 ff
 - – cutaneous 420
 - position to manual skills 368
 - posterior region 420 f
- Forebrain 91
- Foreskin 336
- Formation, reticular 116
- Fornix 90, **99, 114**
- anterior, of vagina 354, **357**
 - conjunctival 148
 - – inferior 132
 - – superior 132
 - posterior, of vagina 354
- Fossa
- acetabular 433, 445
 - axillary 385
 - canine 41, 45, 52
 - cerebellar 25, 27
 - cerebral 25, 27
 - condylar 25
 - coronoid **373, 379**
 - cranial
 - – anterior 30 f
 - – middle 30 f
 - – posterior **30 f, 39**
 - hypophysial 25 f, **30, 34, 36 ff, 49, 75, 88**
 - – of newborn 35
 - iliac 433, **435**
 - incisive 45
 - infraspinous 371
 - infratemporal 31, 52
 - inguinal, lateral 293
 - intercondylar 439, **441, 448**
 - interpeduncular 66, 99, **103**
 - ischiorectal 345
 - jugular 27, 127, 155
 - for lacrimal gland 28
 - mandibular 27, 28, **33, 50, 54, 126, 164**
 - navicular, of urethra 336
 - ovalis 258, 283
 - popliteal **457, 468, 484, 487, 489**
 - – coronal section 486
 - – surface anatomy 476
 - pterygopalatine 31, 37, **46, 72 f**
 - radial, of humerus **373, 379**
 - retromandibular 168
 - rhomboid 67, 69, 71, 115 f, 163
 - scaphoid 124
 - sublingual 52
 - submandibular 52
 - supraspinous 371
 - supravesical 293
 - temporal 20, 52
 - triangular 124
 - trochlear 28
- Fovea
- centralis 134
 - of head of femur 439, **445**
 - submandibular 36
- Frenulum
- of clitoris 362
 - of ileocecal valve 310
 - veli 115
- Fundus
- of bladder 339
 - of eye 134
 - of gallbladder 297 ff, 311, 316
 - of stomach **294 f, 312**
 - of uterus 356 ff
- ## G
- Galea aponeurotica **55 ff, 60, 63, 79, 85, 234 ff**
- Galen's vein 145
- Gallbladder **296 f, 299 f, 302, 311 f, 317 f**
- Head's area 205
- Ganglion(-ia) 164
- autonomic 334
 - celiac 302, 323, **327, 331, 335**
 - cervical
 - – middle **162, 185**
 - – superior, of sympathetic trunk 71, 146, 162 ff, 165, 168, 183 f
 - ciliary 68 f, 72 f, 136, 141
 - geniculate **70, 77, 123 f, 127, 146**
 - impar 335
 - intramural 18
 - otic 69
 - prevertebral 18
 - pterygopalatine 68 f, **146**
 - spinal 69, **98, 229 f, 240**
 - – dorsal root 474
 - – dural sheath 71
 - – meningeal covering 231
 - spirale 131
 - stellate 185
 - submandibular 81, 151
 - sympathetic 279 f, 327, 335
 - trigeminal 31, **68 f, 72 ff, 140, 146**
- Genital organs
- female 354 ff
 - – external 361 ff
 - – – cavernous tissue 362
 - – internal **358 ff, 366 f**
 - – arteries 360
 - – lymph vessels 360
 - – position 354
 - male 336 ff
 - – arteriography 341
 - – external 340 ff
 - – internal 343 f
 - – nerves 349
 - – vessels 340, **346 f, 351**
 - position 323
- Genu s. also Knee
- of corpus callosum **99, 104 f, 107, 118, 120**
 - of facial nerve 70
 - of internal capsule 120
 - of optic radiation 137
- Gerota's fascia 324 f
- Gingiva of upper jaw 61
- Glabella 21 f
- Gland(s)
- accessory, of male genital organs 344
 - bulbo-urethral 336 f, 339, 342, **344**
 - of Cowper 336 f, 339, 342, **344**
 - lacrimal 69, 72, 140, 142
 - mammary 208, **290**
 - palatine 50, 165
 - parathyroid 167
 - parotid 58, **77 f, 152 f, 178**
 - pituitary (Hypophysis) 86 ff, 121, **148**
 - salivary 153
 - sublingual 50, 149, **152 f**
 - submandibular 62, 69, **77, 152 ff, 177**
 - suprarenal 300, 311, 324, **326 f, 331**
 - – arteries 328
 - thyroid 154, 161 f, 167, 169, 176, **266 ff, 275 ff**
 - – pyramidal lobe 184
 - vestibular, greater 360, **361 f, 366**
- Glans
- of clitoris 356, **361 f**
 - penis 336, **339, 341**
- Globus pallidus 116, 120
- Glomerulus 329
- Glottis 161
- Granulations, arachnoid, of Pacchioni **85, 100, 112**
- Gray matter 116, **118 f**
- Groove
- of aortic arch 249
 - for auditory tube 33
 - of azygos arch 249
 - chiasmatic 25
 - deltopectoral 170, **290, 387, 398, 406**

Page numbers in **bold** indicate main discussions.

- of esophagus 249
 - for greater petrosal nerve 30
 - infra-orbital 39 ff, 42, 44 f, 47
 - lacrimal 41 f, 52
 - for middle meningeal artery 27, 29, 34, **36**, 49
 - mylohyoid 36, 53
 - nasolacrimal 39
 - obturator 433
 - for occipital artery 33
 - for radial nerve 373
 - for sigmoid sinus 27, **30**, 34, 36, 53
 - of subclavian artery 249
 - for superior petrosal sinus 27, **30**
 - for superior sagittal sinus 25, 27 f, 42
 - for tendon of peroneus longus muscle 443
 - of thoracic aorta 249
 - for transverse sinus 25, 27, **30**, 42
 - for ulnar nerve 373
 - Gubernaculum testis 343
 - Gyrus(-i)
 - angular 101
 - cingulate **99**, 103
 - dentate 106
 - frontal
 - – inferior 101
 - – middle 100 f
 - – superior 101
 - of Heschl 131
 - long, of insula 109
 - occipitotemporal
 - – lateral 99
 - – medial 66, 99
 - orbital 66, 99
 - parahippocampal 66, **99**, 106
 - postcentral 99 f
 - precentral 99 ff
 - rectus 99
 - short, of insula 109
 - straight 66
 - of striate cortex 137
 - supracallosal 107
 - supramarginal 101
 - temporal
 - – inferior 101
 - – middle 101, 131
 - – superior 101, 131
 - – transverse 131
- ## H
- Hamulus
 - of hamate bone 377, 394
 - pterygoid **25 f**, 37, 144, 164
 - Hand
 - anterior region 423, 426
 - arteries 396 f, **426 ff**
 - arteriogram 427
 - axial section 425, 431
 - coronal section 380, 425
 - innervation 423 f
 - ligaments 380 f
 - longitudinal section 426
 - MRI scan 380, 425 f
 - muscles 388 ff
 - – extensor 392 f
 - – flexor 389 ff
 - nerves 399 f, 423 f, **426 ff**
 - – cutaneous 400
 - of newborn, X-ray 9
 - posterior region 420 f, 424 f
 - surface anatomy 401 f
 - synovial sheaths of flexor tendons 14
 - transverse section 395
 - veins 398
 - Handle of malleus 126, 128
 - Haustra 307
 - Head 7, **145 ff**, 458
 - arteries 168 ff
 - of caudate nucleus **104 ff**, 110, 113, 115 f, 120
 - coronal section 149
 - CT scan 121
 - deep, of flexor pollicis brevis muscle 394
 - of epididymis 339, **343**
 - of femur 367, 432, **438 f**, 445, 496
 - – coronal section 345, 355, 367
 - – frontal section 293
 - – horizontal section 367
 - – ossification center 9
 - – trajectorial lines 8
 - of fibula 440, 446
 - horizontal section 1, **118 ff**, 138, 148
 - humeral, of pronator teres muscle 418
 - of humerus 15, **372 f**, 378, 430
 - lateral
 - – of gastrocnemius muscle 455 ff, 484, **487 f**, 491
 - – of triceps brachii muscle 382, 401, 408 f
 - long
 - – of biceps brachii muscle 207, **384 f**, 407, 412
 - – of biceps femoris muscle 456, 482 ff
 - – of triceps brachii muscle **382 f**, 387, 403 ff, 408 f
 - lymph vessels 172 f
 - of malleus 126, **128**
 - of mandible 50, **52**, 62, 79
 - medial
 - – of gastrocnemius muscle 455 ff, 458, **487 f**, 491
 - – of triceps brachii muscle 382, 387, 401
 - median sagittal section 143
 - median section 90 f, 145, 233
 - – in neonate 233
 - of metacarpal bone 376 f
 - of metatarsal bone 442, 451, 495
 - midsagittal section 85
 - MRI scan 90, **118 f**, 149
 - muscles 19
 - oblique
 - – of adductor hallucis muscle 463, 499, 502
 - – of adductor pollicis longus muscle 394, 429
 - of optic nerve 138, **148**
 - of pancreas 297, 312, **316 f**, 320
 - of proximal phalanx 376 f
 - of radius **374**, 379
 - of rib 191, **197**
 - sagittal section 84
 - short
 - – of biceps brachii muscle 384 f, **407**, 411 f
 - – of biceps femoris muscle 456, 484
 - of stapes 128
 - superficial, of flexor pollicis brevis muscle 388, 394
 - of talus 443, 451
 - transverse
 - – of adductor hallucis muscle 463 f
 - – of adductor pollicis longus muscle 394, 429
 - of ulna **374**, 380
 - ulnar, of pronator teres muscle 418
 - veins **170 f**, 398
 - vessels 262 f
 - Head's areas 205
 - Heart **16**, **252 ff**, **268 ff**, 306
 - blood flow 256
 - – fetal circulatory system 288
 - conducting system 261
 - electron beam tomographic image 254
 - of fetus 288
 - function 260
 - Head's area 205
 - left 16
 - left lateral aspect 281
 - movements 260
 - MRI scan 256
 - position 3, 243, **252**
 - right 16
 - right lateral aspect 280
 - valves 255 ff
 - Helix **122**, 124
 - Hemianopsia
 - binasal 139
 - bitemporal 139
 - homonymous 139
 - Hemisphere
 - cerebellar 89, **102 f**, 116
 - cerebral
 - – auditory areas 130
 - – frontal pole 89
 - – lateral aspect 100
 - – median aspect 99
 - – occipital pole 88 f
 - – temporal pole 89
 - Hernia
 - femoral 218

Page numbers in **bold** indicate main discussions.

- Hernia
– inguinal 217 ff
- Hiatus
– adductor 453
– aortic **282**, 453
– esophageal **282**, 298
– maxillary 36 f, 42, 46, **48**, **144**
– sacral 434, **437**
– semilunar 53, 145
- Hilum of spleen 300
- Hindbrain 91
- Hindgut 291
- Hinge joint 10, **11**, 432
- Hip bone 188 f, 432
- Hip joint 432
– axial section 496
– bones 438
– coronal section 444
– ligaments 444
– MRI scan 5, 8
– X-ray 8
- Hippocampus 138
- Hook of hamate bone 377, 394
- Horn s. also Cornu
– anterior, of lateral ventricle **104 f**, **110**, **112**, 118 ff
– inferior, of lateral ventricle **105 f**, **112**, 116
– – entrance 119
– posterior, of lateral ventricle **104 ff**, **110**, **112 f**, 120
- Humerus 7, 10, 15, **368**, **372 ff**, 378, 430
– antero-lateral surface 373
– antero-medial surface 373
– of newborn 9
– posterior surface 373
- Hymen 354, 356, **361**
- Hyoid s. Bone, hyoid
- Hypophysis 86 ff, 121, **148**
- Hypothalamus 90 f, **108**, 116
- Hypothenar muscles **390 f**, 395, **423**
– axial section 431
- Hypotympanon 127
- I**
- Ileum 302, 304, 306
– terminal 307
- Ilium 7, **433**
– gluteal surface 437
– horizontal section 320
- Impression(s)
– cardiac, of lung 249
– for costoclavicular ligament 369
– digitate **30**, 34
– trigeminal 27, 34
- Incisor
– central 37, 45, **50**
– lateral 50
– permanent 51
- Incisura
– angularis 294 f
– tentorii 75
- Incisure
– of pancreas 297
– of tympanic ring 125
- Inclination, pelvic 438
- Incus 20, **122 f**, 126, **128 f**
- Indusium griseum 104
- Infundibulum
– of hypophysis 65, 74 f, 93 f, 99, **114**, 116, 148
– of right ventricle 256
– of uterine tube 354, **356 f**, 361, 366
- Insula **94**, 116, 119 f
- Intersections, tendinous, of rectus abdominis muscle **211**, 213, 293
- Intestine, small s. Small intestine
- Iris 133 f
– pupillary margin 134
- Ischium 7, **433**
- Isthmus
– of lesser sac 318
– oropharyngeal 246
– of uterine tube 354
- J**
- Jejunum 292, 302 ff, 306
- Joint
– acromioclavicular **368 ff**, 372, 378
– of ankle 432, **443**, **449 ff**, 495
– atlanto-axial 200 f
– – lateral 200 ff
– – median 53, 145, 165, **200**, 202
– atlanto-occipital 53, 194, **200 ff**
– biaxial 11
– calcaneocuboid 443, 451
– carpometacarpal **368**, 375
– – coronal section 425
– – of thumb 11, **368**, 375, 377
– costotransverse 191 f, **197**, **199**, 372
– – effect of intercostal muscles 196
– – of first rib 194
– costovertebral 191, 195, **197**, **199**
– – effect of intercostal muscles 196
– crico-arytenoid 158
– cricothyroid 158
– cuneonavicular 442, 449
– of fingers 10
– hip (s. Hip joint) 5
– humeroradial **374 f**, 420, 431
– humero-ulnar 10, **374 f**
– interphalangeal
– – of fingers **368**, 375, 381, **425**
– – of toes 432, **443**, **449**
– knee s. Knee joint
– metacarpophalangeal 10 f, **368**, 375, 381, 394, **425**
– – of thumb 425
– metatarsophalangeal 432, **443**, **449**
– – of great toe 495
– midcarpal **368**, 375
– monaxial 11
– multiaxial 11
– radio-ulnar 10
– – distal 375, 381, **425**
– – proximal **374 f**, 379
– sacro-iliac 432, **434 f**, **437**
– of shoulder 378
– sternoclavicular 177, **368 f**, 406
– subtalar 443, **449**, 451
– synovial 12
– talocalcaneonavicular 432, 443, **449**, 451, 495
– talocrural 432
– tarsometatarsal 443, **449**
– temporomandibular 19, **53 ff**, 63, 120
– – effect of masticatory muscles 55
– – ligaments 52 f
– tibiofibular
– – distal **432**, 440, 495
– – proximal 432, **440 f**, 446
– zygapophysial 195
- Joint capsule s. Capsule, articular
- Joint cavity s. Cavity, articular
- Juga
– alveolaria 41, 45
– cerebralia 28
- Junction
– costochondral 196
– ileocecal 310
- K**
- Kerckring's fold 297
- Kidney 296, 300, **326 ff**
– arteries 328 f
– arteriography 328
– coronal section 326
– Head's area 205
– horizontal section 320, 324
– left 17, 292, **330 ff**
– position 3, 323 ff
– right 292, 311, **330 ff**
– segments 326
– ultrasound image 327
– upper pole 328
– vascular system 329
– veins 329
- Killian's triangle 167
- Knee (s. also Genu) 486 f
Knee joint 432, 446 ff
– articular capsule 12

Page numbers in **bold** indicate main discussions.

- axial section 497
- bones 441
- coronal section 12
- ligaments 447 f
- MRI scan 4, 446
- of newborn 9
- sagittal section 4, 446

L

- Labium 355
- majus 354, **361**
 - minus 354 ff, **361 ff**, 364
- Labrum, glenoid 378
- Labyrinth 128 ff
- bony 130
 - membranous 130
- Lacrimal apparatus 142
- Laimer's triangle (area prone to developing diverticula) 167
- Lamina
- affixa 104 f, 115
 - of axis 200
 - cribrosa **30 f**, 34, **38**, 49
 - of cricoid cartilage 158
 - pretracheal, of cervical fascia 174, 179 f
 - prevertebral, of cervical fascia 174
 - superficial, of cervical fascia 174, 178
 - terminalis 91, **108**
 - of thyroid cartilage 159
 - of vertebra 191
- Laryngopharynx **150**, 155
- Larynx 143, 154, **158 ff**, 165, 233, 255
- cartilages 158 f
 - coronal section 161
 - entrance 246
 - horizontal section 161
 - MRI scan 203
 - muscles 160
 - – internal, action 160
 - nerves 162
 - position 159
 - sagittal section 161
- Layer, subcutaneous 204
- Leg s. also Limb, lower
- axial section 459, **497**
 - bones 440 f
 - coronal section 461
 - cross section 491
 - long axis 432
 - surface anatomy
 - – anterior aspect 477
 - – posterior aspect 476
- Lemniscus
- lateral 131
 - medial 103, 116
- Lens 121, **132 f**
- anterior pole 133 f
 - posterior pole 133
- Ligament(s) 484
- acetabular, transverse 445
 - alar 200 f
 - annular, of proximal radio-ulnar joint 379
 - anococcygeal 350, 353, 364 f
 - anterior, of malleus 126
 - arcuate, medial 282 f
 - bifurcate 449 f
 - broad, of uterus 356, 367
 - calcaneofibular 450 f
 - calcaneonavicular, plantar 449 ff
 - carpal, radiating 380 f
 - carpometacarpal
 - – dorsal 380
 - – palmar 380
 - collateral
 - – carpal, ulnar 380
 - – of elbow joint 379
 - – fibular 446 ff
 - – of interphalangeal joint 381
 - – of knee joint 12, 446 ff
 - – radial 379 f
 - – tibial 447 f
 - – ulnar 379
 - coraco-acromial 378
 - coronary, of liver 299
 - costoclavicular, impression of clavicle 369
 - costotransverse 474
 - – lateral 199
 - – superior 197 ff
 - crico-arytenoid, posterior 158
 - cricothyroid 158
 - cruciate 12
 - – anterior 446 ff, 497
 - – posterior 446 ff
 - cruciform 200
 - cuneonavicular
 - – dorsal 451
 - – plantar 450 f
 - deltoid 450 f
 - – posterior part 450 f
 - – tibioacneal part 451
 - – tibionavicular part 451
 - denticulate 231, 240
 - of elbow joint 10, **379**
 - falciform, of liver 244, 268, 278, 293, **298 f**, 306 f, 311 f, 318, 320
 - – free margin 293
 - of foot 450 f
 - fundiform, of penis 212
 - gastrocolic 298, 306 f, **311 f**, 315
 - gastrosplenic 300, 311
 - of hand 380 f
 - of the head of femur 345, 351, 367, **444**, 496
 - hepatoduodenal **311 f**, 318
 - – content 291
 - of hip joint 444
 - iliofemoral 444 f
 - iliolumbar 444 f
 - of inferior vena cava 299
 - inguinal 3, 187, 209, 211, 213 f, **216 ff**, **220**, **444 f**, 452 f, 479 f
 - – surface anatomy 204
 - intercarpal
 - – deep 380
 - – dorsal 380
 - interfoveolar 218, 293
 - interspinous 198 f
 - intertransverse **197 ff**, 225, 240
 - intra-articular 197, 199
 - ischiofemoral 444 f
 - of knee joint 446 ff
 - of larynx 158
 - lateral, of temporomandibular joint 53 f
 - lienorenal 311
 - longitudinal
 - – anterior 197 ff
 - – posterior **198 f**, 201
 - medial, of ankle s. Ligament, deltoid
 - meniscofemoral, posterior 447
 - metacarpal
 - – dorsal 380
 - – palmar 380
 - – transverse
 - – – deep 381
 - – – superficial 423
 - of ovary 356 ff
 - palmar
 - – of interphalangeal joint 381
 - – of metacarpophalangeal joint 381
 - palpebral
 - – lateral 142
 - – medial 142
 - patellar **446 f**, 452, 458 f, 462, 486, 495
 - – surface anatomy 477
 - of pelvis 444
 - pisohamate 380 f
 - pisometacarpal 380 f
 - plantar, long 450 f, **465**
 - pubofemoral 444 f
 - puboprostatic 344
 - pulmonary 249
 - radiate 197, 199
 - radiocarpal
 - – dorsal 380
 - – palmar 380 f
 - – round 220
 - – – fatty tissue 363
 - – – of liver **292 f**, 298, 303 f, 306, 317
 - – – of uterus 220, 354, **356 ff**, 359 f, **362**, 366
 - sacro-iliac
 - – dorsal 444
 - – ventral 445
 - sacrospinous 346, 444 f, 471
 - sacrotuberous 346, 353, 444 f, **483 f**

Page numbers in **bold** indicate main discussions.

Ligament(s)

- scapular, transverse, superior 404
 - of shoulder 378
 - sphenomandibular **53**, 153
 - stylomandibular 53 f
 - superior, of malleus 122
 - supraspinous **198 f**, 224
 - suspensory
 - of clitoris 362
 - of ovary 356 ff, 360 f, 366
 - of penis 211, 218, **342**
 - talocalcaneal
 - interosseous 449, 451, 495
 - lateral 451
 - talofibular
 - anterior 451
 - posterior 450
 - talonavicular 449
 - tarsometatarsal
 - dorsal 449, 451
 - plantar 450 f
 - thyro-epiglottic 158
 - thyrohyoid 161
 - lateral 158
 - tibiofibular
 - anterior 451
 - posterior 450
 - transverse
 - of atlas 200 f
 - of knee 447
 - trapezoid 378
 - triangular 299
 - ulnocarpal, palmar 380 f
 - umbilical 330
 - lateral 366
 - medial 330, 347, 366
 - median 336, 357, **361**
 - vocal **158**, **161**
 - of wrist of hand 380 f
- Ligamentum
- arteriosum 162, **252 f**, 256
 - flavum 198
 - nuchae **235**, 403
 - teres
 - hepatis **292 f**, 298, 303 f, 306, 317
 - uteri 220, **356 ff**, 359 f, **362**, 366
 - fatty tissue 363
- Limb(s) 477
- anterior, of internal capsule 120
 - lower (s. also Leg; s. also Thigh) 7, 432 ff
 - arteries 466 f
 - nerves 466 f
 - cutaneous 476 ff
 - of newborn, X-ray 9
 - organization 432
 - skeleton 432
 - surface anatomy 476 f
 - anterior aspect 477
 - posterior aspect 476
 - veins 468 f, 478 f
 - superficial 468 f
 - anastomoses with deep veins 469
 - ossification 9
 - posterior, of internal capsule 120
 - upper (s. also Arm; s. also Forearm) 7, 368 ff
 - arteries 396 f
 - bones 368
 - joints 368
 - muscle(s) 14
 - extensor 14
 - flexor 14
 - nerves 399 ff
 - cutaneous 400
 - of newborn, X-ray 9
 - organization 368
 - regional anatomy 408
 - skeleton 10, 368
 - surface anatomy 401 f
 - veins 398
 - superficial 398
- Limbic system 107
- Limen
- insulae 109
 - nasi 53
- Line(s)
- arcuate 212, **216**, 293
 - of ilium **433**, 435, 472
 - axillary 217
 - anterior 2
 - posterior 3
 - epiphysial
 - of humerus 378
 - of tibia 448
 - of Gennari 137
 - gluteal
 - anterior 433
 - inferior 433
 - posterior 437
 - intertrochanteric **438 f**, 445
 - median 217
 - midclavicular 2, 217
 - mylohyoid 36, **52**, 53
 - nuchal
 - inferior 25, **27**, 29, **33**
 - superior 25, **27**, **33**
 - oblique, of mandible 52
 - of orientation
 - dorsal 3
 - ventral 2
 - parasternal 2, 217
 - paravertebral 3
 - pectinal 439
 - regional, ventral 2
 - scapular 3
 - semilunar 216
 - soleal 440
 - sternal, lateral 217
 - temporal
 - inferior 20, 44
 - superior 20, 29
 - trajectorial, of femoral head 8
 - transverse, of sacrum 434
 - trapezoid 369
 - umbilical-pelvic 2
- Linea
- alba 187, 204, 209, 211, **212 f**, 265
 - aspera 439
 - terminalis, of pelvis 356, **434 ff**, 438
- Lingula
- cerebellar 102
 - of lung 249, 268, 270
 - of mandible 36, **52**
 - sphenoidal 25 f, 38
- Lip
- external, of iliac crest 433, 435
 - intermediate, of iliac crest 435
 - internal, of iliac crest 433, 435
 - lateral, of linea aspera 439
 - lower 53
 - medial, of linea aspera 439
- Liver 243 f, 278 f, 291 f, 296, **298 ff**
- bare area 299, 318
 - coronal section 284
 - of fetus 289
 - Head's area 205
 - midsagittal section 322
 - position 3
 - sagittal section 245
 - segmentation 299
- Lobe 149
- caudate, of liver 299, 304, **311 f**, 317
 - midsagittal section 322
 - frontal 65, 68, 72, 84 f, 89, 97, **99 f**
 - coronal section 149
 - horizontal section 148
 - median section 90 f
 - insular 92
 - left, of liver 278, 292, **298 f**, 304, 306, 317
 - lower
 - of left lung **244**, **246**, 248 f, **267 ff**, 284
 - of right lung **244**, **246**, 248 f, **267 ff**
 - of fetus 288
 - middle, of right lung **244**, **246**, 248, **249 ff**, **267 ff**, 273, 306
 - occipital 65 ff, 74, 84, **99 f**, 101, 113
 - median section 90 f
 - parietal 90, **99 f**, 101
 - postcentral 99 f
 - precentral 99 f
 - pyramidal, of thyroid gland 184
 - quadrate, of liver 299, 306
 - right, of liver **298 f**, 315
 - temporal 65 f, **99 f**, 107, 148
 - area of acoustic centers 131
 - upper
 - of left lung **244**, **246**, 248, **249 ff**, **267 ff**, 273, 284 f, 306

Page numbers in **bold** indicate main discussions.

- – of right lung 244, 246, 248, 249 ff, 267 ff, 272, 284 f
 - – – of fetus 288
 - Lobe bronchus
 - inferior
 - – left 246
 - – right 246
 - lower
 - – of left lung 251
 - – of right lung 251
 - middle, of right lung 246, 251
 - upper
 - – of left lung 246, 251
 - – of right lung 246, 251
 - Lobule
 - of auricle 122, 124
 - biventral, of cerebellum 102
 - central, of vermis 102
 - semilunar, inferior, of cerebellum 102
 - Lobus insularis 94, 116, 119 f
 - Lung 3, 177
 - cardiac impression 249
 - groove
 - – of aortic arch 249
 - – of azygos arch 249
 - – of esophagus 249
 - – of subclavian artery 249
 - – of thoracic aorta 249
 - horizontal section 286 f
 - impressions of rib 249
 - left 243, 249 ff, 267 ff, 274
 - – bronchopulmonary segments 251
 - position 243
 - right 249 ff, 267 ff, 274
 - – bronchopulmonary segments 251
 - surface projection of the thorax wall 248
 - Lymph node(s) 17
 - axillary 17, 290
 - – deep 411
 - – superficial 410
 - bronchopulmonary 275
 - cervical 172 f
 - – deep 173, 180
 - – superficial 172, 175, 182
 - – superior 173
 - iliac
 - – common 332 f
 - – external 332 f, 360
 - – internal 360
 - infraclavicular 172 f
 - inguinal 17, 360
 - – superficial 210, 212, 218, 220, 479
 - jugulodigastric 172 f
 - jugulo-omohyoid 172 f, 332
 - lumbar 332, 360
 - mediastinal 332
 - – superior 172
 - mesenteric 309
 - occipital 173
 - parasternal 265
 - parotid 173
 - – superficial 172
 - retro-auricular 172 f
 - sacral 332, 360
 - submandibular 172 f, 179
 - submental 172 f
 - supraclavicular 172
 - tracheal 275
 - tracheobronchial, superior 275
 - Lymph trunk, lumbar 335
 - Lymph vessels 290
 - iliac 335
 - inguinal 218, 479
 - of internal female genital organs 360
 - of neck 172
 - of trunk 17
 - Lymphatic system 17
- ## M
- Macula
 - lutea 134
 - of sacculle 129
 - of utricle 129
 - Main bronchus
 - left 244, 246
 - right 244, 246
 - Malleolus
 - lateral 440, 443, 451, 457
 - – surface anatomy 476 f
 - medial 440, 443, 451, 457
 - Malleus 20, 71, 122 f, 128 f
 - Mandible 7, 19 ff, 22, 33, 37, 49, 50 ff, 53 ff, 63, 159, 194
 - coronal section 62
 - Manubrium of sternum 3, 159, 177, 188 f, 192 ff, 369
 - Margin 39, 265 f
 - anterior, of tibia 440, 462, 492, 495
 - bony, of acetabulum 438
 - costal s. Arch, costal
 - frontal, of parietal bone 29
 - infra-orbital, of maxilla 39 f
 - lambdoid, of occipital bone 39
 - lateral, of scapula 370 f
 - mastoid, of occipital bone 39
 - medial, of scapula 234 ff, 382, 403
 - nasal, of frontal bone 28
 - occipital
 - – of parietal bone 29
 - – of temporal bone 27
 - parietal
 - – of frontal bone 28
 - – of temporal bone 27
 - pupillary, of iris 134
 - sagittal, of parietal bone 29
 - sphenoidal, of temporal bone 27
 - squamous, of parietal bone 29
 - superior, of spleen 300
 - supra-orbital 21 ff, 28, 45
 - Marshall's vein 262
 - Mass, intermediate 90, 99
 - Masticatory apparatus 22
 - Maxilla 7, 19 ff, 22 f, 28, 33, 36 f, 39 ff, 42 ff, 45, 47, 52, 54, 132
 - orbital surface 39 ff
 - Meatus
 - acoustic
 - – external 19 ff, 27 f, 54, 55 f, 68 f, 72, 120, 122, 126
 - – – of newborn 33
 - – internal 27, 30 f, 34, 36, 46, 53, 164, 201
 - – – bony base 124
 - nasal
 - – inferior 36, 42, 48, 53, 144
 - – middle 42, 53, 144
 - – superior 144
 - Mediastinum 274 ff
 - anterior portion 245, 266
 - content 245
 - middle portion 245, 266
 - posterior 245, 278 f, 281
 - – inferior segment 279
 - superior 245, 281
 - testis 343
 - Medulla
 - of kidney 326
 - oblongata 31, 67, 86, 101, 114 f, 240 f
 - – median section 90 f
 - – MRI scan 203
 - of suprarenal gland 326
 - Membrana tectoria 201
 - Membrane
 - intercostal, external 196, 207
 - interosseous, of forearm 379 ff, 390 f
 - mucous, of uterus 357
 - mucous, of urinary bladder 338 f, 355
 - obturator 444 f
 - thyrohyoid 158, 160
 - tympanic 69, 120, 122 f, 126 ff
 - vasto-adductor 453, 480
 - Meniscus 12
 - lateral, of knee joint 446 ff
 - medial, of knee joint 447 f
 - Mesencephalon s. Midbrain
 - Mesentery 306 f, 310
 - midsagittal section 322
 - root 306
 - Meso-appendix 307, 310, 318
 - root 318
 - Mesocolon, transverse 304, 306, 309 f
 - midsagittal section 322
 - root 312, 318
 - Mesosalphinx 356 ff
 - Mesosigmoid 310

Page numbers in **bold** indicate main discussions.

- Mesosigmoid
 - root 318
- Mesovarium 356 f
- Metacarpals s. Bones, metacarpal
- Metacarpus, axial section 431
- Metatarsals s. Bones, metatarsal
- Metencephalon 91
- Midbrain 65, 73 f, **91**
 - cross section 117
 - inferior portion 91
 - median section 90 f
- Moderator band 258
- Modiolus 127
- Molar 50 f
 - permanent 51
- Monro foramen 86, **94**, 99, **105**, **112 f**
- Mons pubis 204, **364**, 367
- MRI angiograph, cerebral arteries 95
- Mucosa of wall of stomach 294
- Muscle(s) **13 f**, 62, 161, **196**, 225, 395, 463, 498
 - abductor 375
 - – digiti minimi
 - – of foot 463 f, 501 f
 - – of hand 388, 390, **394 f**, 425, **427 f**
 - – of foot 463 ff
 - – hallucis 463 f, 499, 501 f
 - – pollicis
 - – – brevis 388, 394 f, **427 ff**
 - – – longus 392 f, **424**
 - – – – tendon 427
 - – adductor 344, 350
 - – brevis 365, **453**
 - – – of thigh 452 f
 - – of foot 463
 - – great 364
 - – hallucis
 - – – oblique head 463, 499, 502
 - – – transverse head 463 f
 - – longus, of thigh 365, **452 f**, 455, 480
 - – magnus 351, 446, **453**, 455 f, 482
 - – minimus **453**, 456
 - – pollicis 390, 395, 402, **425**
 - – – longus 394
 - – – oblique head 429
 - – – transverse head 429
 - – of thigh 452 f
 - anal sphincter
 - – external 336 f, 345
 - – internal 336, 345
 - anconeus 392, 392 f, 419
 - of arm 382 ff, **386 f**
 - articular, of knee 448, 452
 - ary-epiglottic 160
 - arytenoid 155
 - – transverse 160 f
 - auricular, superior 85, 168
 - of back 204, **221 ff**
 - – deepest layer 224
 - biceps 416
 - – brachii 14, **384 ff**, 387, 393, **416 ff**, 431
 - – – fascia 416
 - – – long head 207, 384 f, 407, 412
 - – – – tendon 378, **387**, 415 f, 419
 - – – short head 384 f, **407**, 411 f
 - – – – tendon 387
 - – femoris **455 ff**, 491
 - – – long head **456**, 482 ff
 - – – short head 456, 484
 - – – – tendon 455 f, 484
 - – bicipital 13
 - – bipennate 13
 - – brachialis 14, **384 ff**, 387, 389, 393, 415
 - – brachioradialis 14, **387**, 390, 392 f, 416
 - – broad 13
 - – buccinator 50, 54, **55 ff**, 58, 60 f, 63, 68, 82 f, **151**, 167
 - – bulbospongiosus 350 ff, 361
 - – calcaneal 458
 - – ciliary 133
 - – coccygeus 351
 - – constrictor
 - – – inferior, of pharynx 60 f, 161, **164 f**, **167**, 182
 - – – – cricopharyngeal part 166
 - – – – thyropharyngeal part 166
 - – – middle, of pharynx 61, 67, **151**, **164 f**, **167**
 - – – superior, of pharynx 60 f, **151**, 164, 166, **167**
 - – coracobrachialis **384 ff**, 387, 411
 - – corrugator supercilii 58
 - – cremaster 218, 340, 341, **343**
 - – crico-arytenoid
 - – – lateral 160 f
 - – – posterior 160
 - – cricothyroideus 160, **166 f**, 266
 - – dartos 218, **343**
 - – deep, of back 214
 - – deltoid 14 f, 204, **209 ff**, 290, 378, **385**, **403 ff**, 408 f, 430
 - – – acromial part 384, 387
 - – – clavicular part 384 f, 387
 - – – posterior fibers 382
 - – – scapular part 387
 - – depressor
 - – – anguli oris 58, 60, **77 f**, 167
 - – – labii inferioris 58, 167
 - – – supercilii 58
 - – digastric **13**, 63
 - – – anterior belly **55**, 60 ff, 68, **77 f**, 150, 152, **156**, **166**, 168, 175, 181
 - – – posterior belly 54, **55**, 60, 67 f, 80, **81 f**, 151, **156**, 163, 165, **166 f**, 168, 175, 181
 - – dorsal
 - – – of leg, surface anatomy 476
 - – – of shoulder 382 f
 - – erector spinae
 - – – lateral tract 210
 - – – medial tract 210
 - – extensor 14
 - – – carpi
 - – – – radialis
 - – – – – brevis 389, **392 f**, 419
 - – – – – longus 387, **392 f**, 419
 - – – – ulnaris 392 f, 419
 - – – – – tendon 424
 - – – digiti minimi of hand 392 ff
 - – – digitorum
 - – – – brevis of leg 459, 462, 493, 499
 - – – – of hand 392 ff, 419, **424**
 - – – – longus of leg 459, **462 f**, 498
 - – – – – tendon 498
 - – – of foot 462
 - – – – of forearm 392 f
 - – – – – surface anatomy 401
 - – – hallucis
 - – – – brevis 462, 498 f
 - – – – longus **462 f**, 495, 498
 - – – – – tendon 458 f, **498**
 - – – of hand 392 f
 - – – indicis 393
 - – – – tendon 392
 - – – of leg 462 f
 - – – pollicis
 - – – – brevis 392 f, **424**
 - – – – tendon 388
 - – – longus 393
 - – – – tendon 424
 - – – of thigh 452
 - – – of thumb 393 f
 - extra-ocular 135 f
 - – action 135
 - – innervation 72
 - facial 19, **58 f**
 - – of fifth toe 463
 - flexor(s) 14
 - – of arm 385
 - – – carpi
 - – – – radialis **388 f**, 416 f, 419, **423**
 - – – – – tendon 380, **427 f**
 - – – – ulnaris **388 f**, 416, 419, **423**
 - – – – – tendon 380, **427 f**
 - – – deep, of leg 460 ff
 - – – digiti minimi brevis
 - – – – of foot 463 f
 - – – – of hand 389 f, 394, **428**
 - – – digitorum
 - – – – brevis of foot 449, **463 f**, 501
 - – – – – origin 502
 - – – – of hand 389, 427
 - – – – longus of foot 460 f, 464, 491, 499
 - – – profundus of hand 389, 418 f, 423, 425, 427
 - – – – superficialis of hand **388 f**, 391, 416, 418 f, **423**, 425, **427 f**
 - – – tendon 389
 - – – of forearm 389 ff

Page numbers in **bold** indicate main discussions.

- - hallucis
 - - - brevis 449, **464**, 499, 501
 - - - longus 459 ff, 491
 - - - - tendon 449, **460 f**, 463, 501 f
 - - of hand 389 ff
 - - of leg 457
 - - pollicis
 - - - brevis 427
 - - - - deep head 429
 - - - - superficial head 388, **427 ff**
 - - - longus **388 f**, 418, 423
 - - of thigh 455 f
 - - of foot 457 ff, **463 ff**
 - - of forearm 388 ff, 419
 - fusiform 13
 - gastrocnemius 446, **455 f**, 462
 - - lateral head 455 ff, 484, **487 f**, 491
 - - medial head 455 ff, 458, **487 f**, 491
 - gemellus
 - - inferior 455 f, 483
 - - superior 455 f
 - genioglossus 50, 86, **149 ff**, 155, 166
 - geniohyoid 62, 86, **150 ff**, 155
 - gluteus 454 f
 - - maximus 225, 350 ff, 362, **455 f**, **482 ff**
 - - - surface anatomy 476
 - - medius 320, **455 f**, 483 f
 - - minimus **455**, 483
 - gracilis 350, 365, **452 f**, 455, 480, 487
 - - tendon 447, 452, **455**, 457
 - of great toe 463
 - hamstring 484
 - of hand 388 ff
 - - deep layer 395
 - of head 19
 - hyoglossus 61 f, **150 ff**, 160, 166 f
 - iliacus 330, 453
 - - horizontal section 320
 - iliococcygeus 351
 - iliocostalis 210 f, **221 ff**, 320, 324
 - - cervicis 222
 - - insertion 222
 - - lumborum 222
 - - origin 222
 - - tendons 225
 - - thoracis 222, 236
 - iliopsoas 293, 338, 367, **452 f**, 480, 496
 - of index finger 394
 - infrahyoid 60 f, **151**, 174, **175**, 182
 - infraspinalis 223, 240, **242**, **382 f**, 403 f, 408 f, 430
 - intercostal
 - - effect
 - - - on costotransverse joint 196
 - - - on costovertebral joint 196
 - - external **196**, 207, 222, 403, 412
 - - innermost **206**, 474
 - - internal **196**, **206 f**, 210 f, 264
 - - of larynx, action 160
 - interosseus(-i)
 - - dorsal
 - - - of foot 463, 495, 499
 - - - of hand 380, 393 ff, **424**
 - - of foot 464
 - - of hand 425, 427
 - - - actions 394 f
 - - palmar 394 f, **429**
 - - plantar 463
 - interspinal, lumbar 224
 - intertransversarius(-i) 221, **225**
 - - cervical, posterior 225
 - - lumborum 224 f
 - intrinsic, of back, medial column 212, **225**
 - ischiocavernosus 345, 349, **350 ff**, 364
 - ischiocrural 454
 - latissimus dorsi 196, 207, 211, 223, 228, 234, 324, **382 f**, 385, **403**, 408 f
 - - of leg 457 ff
 - levator(es) 351
 - - anguli oris 58, 167
 - - ani 337, 344 f, **350 f**, 355, 362, 364
 - - costarum **223 f**, 225, 241
 - - labii superioris 58, 167
 - - - alaeque nasi 58, 167
 - - palpebrae superioris **73**, 132, 135 f, 140
 - - scapulae 181, 184, 222 ff, **235 ff**, 240, **382 f**, 403 ff
 - - veli palatini 62, **122 f**, 147, 167
 - long, of back 221 f
 - longissimus 210 f, **221 ff**, 320
 - - capitis **222**, 225
 - - cervicis 222, 236
 - - insertion 222
 - - origin 222
 - - thoracis 222, 236
 - longitudinal
 - - inferior, of tongue 50, **149** 166
 - - superior, of tongue 50, 62, **86**, **149**
 - longus
 - - capitis 60 f, 157, 165
 - - colli 157, 174, **185**
 - lumbrical
 - - of foot 461, **463 f**, 501
 - - of hand 389, 394 f, **429**
 - masseter 19, 54, **55 ff**, 58, 62, **77 ff**, 168
 - masticatory 19, **55 ff**
 - - effect on the temporomandibular joint 55
 - mentalis 58, 167
 - multicaudal 13
 - multifidus 211, 223 ff, 324
 - multiventral 13
 - mylohyoid 55, 60 ff, **77 f**, 86, **150 ff**, 152, 155, **156**, **166**, 175
 - nasalis 77, 167
 - - alar part 58
 - - transverse part 58
 - of neck 203
 - oblique
 - - abdominal
 - - - external 187, 196, 204, **208 ff**, 212 f, 264, 300
 - - - internal 187, 204, 210 ff
 - - inferior **72**, 132, **135 f**
 - - superior **72 f**, 132, **135 f**, 140
 - obliquus capitis
 - - inferior 222 f, 225, **237 f**
 - - superior 223, **237**
 - obturator
 - - externus 344 f, 453
 - - internus 344 f, **350**, 351, 353, 355, 367, 455 f
 - occipitofrontalis
 - - frontal belly **56 ff**, 60, 79, 85, 168
 - - occipital belly 58, 70, **77**, 85, 234 ff, **237 ff**
 - ocular, external 133
 - omohyoid 60 f, **77 f**, 81, 151, **156 f**, 174 f, 264, 266
 - - intermediate tendon 179
 - opponens
 - - digiti minimi 394, **428**
 - - of foot 465
 - - of hand 389
 - pollicis 390, 394
 - orbicularis
 - - oculi **58 ff**, 61, 70, 77, 79, 85, **142**, 167
 - - - orbital part 58, 60, 168
 - - - palpebral part 58, **142**
 - - oris 58, 77, 167
 - palatopharyngeus 163
 - palmaris
 - - brevis 388, **423**
 - - longus 388, 416, 419, 423
 - - - tendon 388, 423, **428**
 - papillary 253, 261
 - - anterior 256, 258 f, 271
 - - - of right ventricle of fetus 288
 - - posterior 258, 271
 - - septal 258
 - pectineus 344, 367, **452 f**, 480
 - pectoral 384 f
 - pectoralis
 - - major 14, 187, 207 f, **209 ff**, 264 f, 290, **384 f**, 387, 410, 412
 - - - abdominal part 384
 - - - clavicular head 185, 384
 - - - insertion 411
 - - - sternocostal part 384
 - - - surface anatomy **204**, 402
 - - minor 168, 204, 207, **264 ff**, **384 f**
 - - - insertion 411
 - perineus transverse
 - - deep 345, 350, **351 ff**, 362, 364
 - - superficial 350, 364
 - peroneal 498

Page numbers in **bold** indicate main discussions.

Muscle(s)

- peroneus
 - – brevis **457**, 460, 495
 - – longus **457**, 460, 495
 - – – tendon 462
 - piriform 455 f, **483**
 - plantaris 456 ff, **487**, 491
 - popliteus 446, 457, **460**
 - procerus 58
 - pronator
 - – quadratus **390 f**, 395
 - – teres 387, **389**, **391**, 416, 419
 - – – humeral head 418
 - – – ulnar head 418
 - psoas
 - – major 210 f, 282 f, 292, 325, **330 f**, 333, 335, 355, **359**, **453**
 - – minor 453
 - pterygoid
 - – lateral 53 f, **55**, **57**, 62, 80
 - – – connection with articular disc of temporomandibular joint 57
 - – medial 54, **55**, 57, 62, 68, 80, 83, **146**, 165 ff
 - – – connection with articular disc of temporomandibular joint 57
 - pubococcygeus 351
 - puborectalis 351
 - pyloric sphincter 295
 - pyramidalis 211 f, 367
 - quadratus
 - – femoris **455 f**, 483 f
 - – lumborum 210 f, 282, 330, 453
 - – – horizontal section 320
 - – plantae 449, **464**, 501
 - – quadriceps femoris **446**, **448**, 452, 458
 - – surface anatomy 477
 - quadricipital 13
 - rectus
 - – abdominis **206**, 208, 210, 212 f, **216**, **264 ff**, 292 f, 320, 324, 385
 - – – surface anatomy **204**
 - – capitis posterior
 - – – major 222 f, 225, **237**
 - – – minor 222 f, 225, **237 f**
 - – femoris **452 f**, 455, **480 f**
 - – inferior **72**, 132, **135 f**
 - – lateral 69, **71 ff**, 74, 121, 132, **135 f**, 138, 148
 - – medial 74, 132, **135 f**, 148
 - – superior **72 f**, 132, **135 f**, 140
 - rhomboid
 - – major **222 f**, 225, 234 f, 238, **382 f**, 387, 403 ff, 408
 - – minor **235**, 238, **382 f**
 - ring-like 13
 - risorius 58
 - rotator 225
 - – lumbar 224
 - – sartorius 218, 344, 367, **452 ff**, 455, 457, 479 f, 487, 496
 - – – tendon 447, 452
 - – scalenus 60
 - – – anterior 162, 168, 170, **181**, **184 f**, 269, 271
 - – – – medius 162, 180, **184 f**
 - – – – posterior 162, **181**, **184 f**
 - – semimembranosus 446, **455 ff**, 484, 487
 - – – membranous part 456
 - – – tendon 447
 - – semispinalis
 - – – capitis 165, **222**, 225, **228**, 235, 238
 - – – cervicis **222 ff**, 225, 238
 - – – thoracis 225, 228
 - – semitendinosus **13**, 446, 452, **455 ff**, 482, 484, 487
 - – – tendon 447, 452, 487
 - – – – intermediate 456
 - – serrated 13
 - – serratus
 - – – anterior **196**, 204, **207 ff**, **264**, 290, 300, **384 f**, 410
 - – – – posterior
 - – – – – inferior 222, 403
 - – – – – superior 228, **235**, 238, 404 f
 - – – of shoulder 382 ff
 - – – of sole of foot 463 ff
 - – soleus 446, **457 f**, 487, 491
 - – – tendinous arch 457, 491
 - – sphincter s. also Sphincter; s. also Sphincter muscle
 - – – urethrae 349
 - – spinalis **221**, 223 f
 - – – thoracis 222, 225
 - – spinotransversal **221**
 - – splenius
 - – – capitis 70, 77, 179 f, 228, 234 ff, 383, **403 ff**
 - – – cervicis 228, 235 f, **403**, 405
 - – stapedius 127
 - – sternocleidomastoid 58, 60 f, 63, 68, **77 ff**, 81 f, 85, 152, 154, **156 f**, 174, 178, 206, 209, 234 ff, 264, 384 f, 403, 405 ff
 - – – clavicular head 175
 - – – sternal head 175
 - – – surface anatomy 401
 - – sternohyoid 60 f, **78**, 97, **151**, **156 f**, 174 f, 209, 264
 - – sternothyroid 151, **156**, 174 f, **206**, 265
 - – styloglossus 60, 71, **151**, **166**, 167
 - – stylohyoid **55**, 60, 68, 71, **78**, **150 ff**, **166 f**, 175
 - – stylopharyngeus 61, 67, **167**
 - – subclavius **156**, 207, 384 f
 - – subscapularis 196, **384**, **386 f**
 - – supinator 389, **391**, 393
 - – suprahyoid 60 f, **151**, **175**
 - – supraspinatus 15, **382 f**
 - – – tendon 378
 - – temporalis 19, 54, **55 ff**, 62 f, 79
 - – – insertion 56
 - – – tendon 60 f, 80, 82
 - – temporoparietalis 58, **77**
 - – tensor
 - – – fasciae latae 452 f, **455**, 480, 483
 - – – – surface anatomy 477
 - – – tympani **122 f**, 127
 - – – veli palatini **60 ff**, 147, 167
 - – teres
 - – – major **223**, 225, 234, **242**, 378, **382 f**, 387, 403 ff, 408 f
 - – – minor **382 f**, 403 ff, 408 f
 - – of thigh 452 ff
 - – thyro-arytenoid 160
 - – thyro-epiglottic 160
 - – thyrohyoideus 60 f, **151 f**, **156 f**, 160, **166 f**
 - – tibialis
 - – – anterior 459, **461 ff**, 495
 - – – – tendon 458, 461, 491, **498**
 - – – posterior 460 f, 491
 - – – – tendon 460
 - – transverse
 - – – of tongue 50, 62, **149**
 - – – of trachea 160
 - – transversospinal 221, 225
 - – transversus
 - – – abdominis **206**, 210 ff, **214**, 293
 - – – thoracis 206, 264
 - – trapezius 15, 77, 157, 225, 378, **382 f**, 408
 - – – ascending fibers 234, **382**, 403
 - – – descending fibers 234, **382**, 403
 - – – surface anatomy 402
 - – – transverse fibers 234, **382**, 403
 - – triceps
 - – – brachii 14, 387, 389
 - – – – lateral head 382, 401, 408 f
 - – – – long head **382 f**, 387, 403, 408 f
 - – – – – tendon 378 f
 - – – – medial head 382, 387, 401
 - – – – – surface anatomy 401
 - – – tendon 387
 - – surae, surface anatomy 476
 - – tricipital 13
 - – unipennate 13
 - – vastus
 - – – intermedius **452 f**, 455
 - – – lateralis 344, 448, **452 f**, 455, 480 f
 - – – medialis 448, **452 f**, 455, 458, 480 f
 - – vertical, of tongue 62, **86**, **149**
 - – vocalis 160 f
 - – zygomaticus
 - – – major 58, **77 ff**, 168
 - – – minor 58
- Muscle fibers, oblique, of stomach 295
- Muscular coat
 - of gallbladder 297
 - of stomach 295
- Myelencephalon 91

Page numbers in **bold** indicate main discussions.

Myocardium 256 ff, 259 f, 284
Myometrium 359, 367

N

Nasopharynx 62, **150**, 155

Neck **154 ff**, 403

– anatomical, of humerus 372 f

– anterior region **174 ff**, 406

– arteries 168 ff

– of bladder 338

– coronal section 195, 201

– cross section 157, 174, 176

– of femur 9, **438 f**

– of gallbladder 297

– horizontal section 203

– lateral region 178 ff

– lymph nodes 172 f

– lymph vessels 172 f

– of malleus 128

– MRI scan 157, 176, 195, 201

– muscles 203

– nerves 183, 414

– of radius 374

– posterior region **234 ff**, 403

– of scapula 371

– surgical, of humerus 372 f

– of talus 443

– veins **170 f**, 398

– vessels 183

Nerve(s) 147, **180**, 400, 415, 423, 477

– abducent 31, 64, 66, 69, **72 f**, 75, 93, 97 f, 111, 114, 136, 140

– accessory 31, 63 f, 66 f, 69, 71, **81**, 98, 111, **114 f**, 163 ff, 225, 235 f, 242, 403 ff, 407

– – intracranial portion 67

– alveolar

– – inferior 62, 68 f, 71, 80, **81 ff**, 150

– – superior

– – – middle 69

– – – posterior 68 f, **72**, **80**

– anococcygeal 351, 482

– of arm 414 ff

– auricular

– – great **63**, **77 ff**, 80 f, 174, 178 f, 229, 234, 236, 403 f

– – posterior **70**, **77**

– auriculotemporal 63, 68 f, 72, **77**, **79 ff**, 82 f, 85, 168

– – communicating branches to facial nerve 80

– axillary 383, **399**, 404, 408 f, **413 f**

– – cutaneous branch of arm 226, 409

– of back 226 ff

– buccal 63, 68 f, 72, **79 f**, 81 f

– cardiac, cervical

– – inferior 278 f

– – middle 162

– – superior 278

– carotid sinus 165

– cervical, transverse 63, **78 f**, 174, 178, 186, 242

– chorda tympani 62

– ciliary

– – long 141

– – short 68, **72 f**, 140

– cluneal

– – inferior **226**, 229, 351 f, **470**, 476, 482 ff

– – middle **226**, 229, 476, 482, 484

– – superior 223, **226 f**, 229, 476, 482

– cranial 18, **64 ff**, 98, **114 f**

– – base of skull 31

– – nuclei 114

– cutaneous 416

– – brachial, medial 186

– – dorsal

– – – intermediate, of foot 489, 498

– – – lateral, of foot 498

– – – medial, of foot 468, 489, 498

– – femoral

– – – lateral **214**, 218, **470 f**, 475 ff, 479

– – – posterior 226, 351 f, **470**, 476, 482, 484

– – – – perineal branch 482, 484

– – lateral

– – – of forearm 399 f, 415 ff, **420**, 424

– – – lower, of arm 399 f, 409

– – – upper, of arm 226, **400**, 403, **408 f**

– – medial

– – – of arm 399, 409 f

– – – of forearm 399 f, **408 ff**, 413, 415 ff

– – perforating 483

– – posterior

– – – of arm **399 f**, 403

– – – of forearm 399 f, 409, **420**, 424

– – of region of knee 486

– – sural

– – – lateral **470**, 479, 484, 486, 488 f

– – – medial 484, 487 ff

– digital

– – dorsal

– – – of foot 493, 498 f

– – – of hand 399 f

– – palmar 427

– – – common 399, 423, **427**

– – – proper 423, **428**

– – – supplied regions 424

– – – of thumb 400

– – plantar

– – – common 501

– – – proper 501 f

– dorsal

– – of clitoris 364

– – of penis 217, **341**, 352, 471

– erigentes 349, **472**

– ethmoidal, anterior 31, 141, **146**

– – external nasal branch 68

– – internal nasal branches 147

– facial 31, 64, 66 f, 69, **70**, **77 ff**, 81, 98, 111, 114 f, 146, 165, 168

– – buccal branches **70**, **77**, 178

– – cervical branch **70**, **77 ff**, 174, 177 f, 186

– – communicating branches to auriculotemporal nerve 80

– – marginal mandibular branch **70**, **77**, 79, 152, 178

– – temporal branch 70, 77

– – zygomatic branch 70, 77

– femoral 214, 293, 340, 367, 444 f, 467, **470 ff**, **475**, **477**, **479 ff**

– – cutaneous branch 486

– – – anterior 467, 479

– – muscular branch 480 f

– of forearm 419 ff

– frontal 69, 73

– – lateral branch 140

– genitofemoral 216, **330**, 333, 359, **470**, 472, **475**

– – femoral branch 216, **340**, **470**, 479

– – genital branch 216 f, **340**, **470**, 479

– glossopharyngeal 31, 64, 66 f, 69, 71, 98, 111, **114 f**, 151, 162 f, 165

– – carotid sinus branch 71

– – lingual branch 71

– gluteal

– – inferior 483 f

– – superior 483

– hypogastric 349

– hypoglossal 31, 33, 63 f, 66, 69, **78**, 81, 97 f, **114 f**, 151 f, 162, 164 ff, 183

– – intracranial portion 67

– – lingual branch 71, 183

– – omohyoid branch 183

– – thyroid branch 183

– iliocostalis 230

– iliohypogastric 212 f, 216, 329 f, 444 f, **470 ff**, **475 ff**

– – cutaneous branch

– – – anterior 470

– – – lateral 470

– ilio-inguinal 212, 214, 216 ff, 331, 333, **340**, 359, 362, **470 ff**, **475**

– infra-orbital 68 f, **72**, 79, 82, 136, 142

– – terminal branches 68

– infratrochlear 69

– intercostal 206 f, **214**, 216, 279, **474**

– – collateral branch 474

– – cutaneous branches

– – – anterior 207, **209**, 211, **214**, 229, 385, 400, 411, **470**

– – – lateral **196**, 207, **209**, **214**, 229, 385, 408 ff, 412, **470**

– – mammarian branches, medial 290

– – perforating branches, anterior **208**

– intercostobrachial 186, 196, 207, **290**, 410, 412, 414 f

– – terminal branches 400

Page numbers in **bold** indicate main discussions.

- Nerve(s)
- interosseous
 - – anterior, of forearm 399
 - – posterior, of forearm 421, 424
 - labial, posterior 364 f
 - lacrimal 68 f, **72 f**, 140 f
 - laryngeal
 - – inferior 160, 163
 - – recurrent 177, 185
 - – – inferior laryngeal branch 162
 - – left **162**, 255, 266, 269 ff, 272 ff, 276, 279, **335**
 - – – right **162**, 276, **335**
 - – superior **162**, 165 f
 - – – external branch 162
 - – – internal branch 151, 163, 173
 - lingual 62 f, 68 f, 71, 81, 146, **151 f**
 - mandibular 31, 53, 68 f, **72**, **83**
 - – inferior 63
 - – meningeal branch 31
 - masseteric 63, 72, **79 f**
 - maxillary 31, 68 f, 72, 136, **147**
 - medial 417
 - median 168, **186**, 207, 387 f, 391, 396, 399, **413 ff**, 419, 423, 425
 - – axillary region 410, 412
 - – cubital region 416 ff
 - – palmar branch 399 f, 423, **427**
 - – – digital 400
 - – – – common 423, **428**
 - – roots 399, **411**, 415
 - meningeal, recurrent 31
 - mental 68 f, **79**
 - musculocutaneous 399, 410, **413 f**
 - mylohyoid 68 f, **77 f**, 80, 152
 - nasociliary 72 f, 141
 - nasopalatine 146 f
 - obturator 333, **346 f**, 366, 467, **470 f**, 475 ff, 481
 - occipital 85
 - – greater 63, 70, **77**, **81**, 85, 223, 226, 229 f, **234 ff**, 238 ff, 403 f
 - – lesser **77**, 81, 178, **179**, 226, 229, 234 ff, 237 f, 403 ff
 - – third 226, 234 ff, 237, 404 f
 - – – cutaneous branch 403
 - oculomotor 31, 64 ff, 68 f, **72 ff**, 97 f, **114 ff**, 136 f, 140, **148**
 - – inferior branch 69, **71 f**, 136
 - – superior branch 141
 - olfactory 31, 64, **147**
 - ophthalmic 31, 68 f, **72 ff**, 136
 - optic 31, 62, 64 ff, 68 f, **72 f**, 75, 84, 98, 114 f, 121, **132 ff**, **135 ff**, **138**, 146, 148
 - – destruction 139
 - – dural sheath **133**, 138, 148
 - – extracranial part 135, 140
 - – intracranial part 135, 140
 - of the orbit 72 f
 - – palatine 146
 - – – greater 146 f
 - – – lesser 146
 - – parapharyngeal 164 ff
 - – parasympathetic 334
 - – pectoral
 - – – lateral 207, 407, **412**, 415
 - – – medial 177, 207, **214**, 407, 415
 - – perineal 471
 - – peroneal
 - – – common 455, 457, **467**, **470**, 476 f, 484, 489, 491, 495
 - – – deep 470, 477, **479**, 492 f, 495, 499
 - – – superficial 470, 477, **479**, 484, 489, 493, 495, 498
 - – – – dorsal cutaneous branch
 - – – – – intermediate 479
 - – – – – lateral 492 f
 - – – – – medial 479, 492 f
 - – petrosal
 - – – deep 147
 - – – greater 31, 77, 123, 127, **147**
 - – – lesser 31, 127
 - – phrenic 170, 177, 185 f, 266 f, **269 ff**, 274 ff, **280 f**, 396, 413
 - – – accessory 185
 - – plantar
 - – – lateral 470, 499, 501 f
 - – – superficial branch 501 f
 - – – medial 470, 499, 501 f
 - – – of great toe 502
 - – of pterygoid canal 146
 - – pterygopalatine 68, 72
 - – pudendal 346, **351 f**, 364, **470**, 471, 483
 - – – inferior rectal branches 484
 - – – perineal branch 352
 - – radial **399**, 404, 408, **413 ff**
 - – – axillary region 410
 - – – cubital region 416
 - – – deep branch 391, **399**, 414, 417 ff, 420 f
 - – – dorsal digital branch 400, **420**, 424
 - – – main branches 399
 - – – posterior interosseous branch 421
 - – – superficial branch 399 f, **414 f**, 418 ff, 424, 427
 - – – superficial palmar branch 427
 - – rectal, inferior 351 f, 364 f, **471**, 483
 - – recurrent 160
 - – saphenous 467 f, **470**, 476 f, 479 f, 486, 492, 498
 - – – entering the adductor canal 452
 - – – infrapatellar branch 467, **470**, 479, 486, 492
 - – scapular, dorsal 235, 237, 404
 - – sciatic 344, 351, 367, 444 f, 455, **470**, **483 f**, 496
 - – – branches 484
 - – scrotal
 - – – anterior 470
 - – – posterior 351 f, **471**
 - – spinal 18, **98**, **226 ff**, 229, 234
 - – – cervical 66, 154, 183
 - – – – dorsal root 157
 - – – – ventral rami 18
 - – – ventral root 157
 - – – – cutaneous branch 224
 - – – – lateral 226
 - – – – medial 226, 234
 - – – dorsal branches 403
 - – – dorsal root 71, 214, 230, **240**
 - – – lateral branches of dorsal rami 223, 226, 228 ff
 - – – – lumbar, ventral rami 18
 - – – medial branches of dorsal rami 223, 226, 228 f
 - – – – meningeal covering 231
 - – – ramus
 - – – – dorsal 214, 231, 240
 - – – – cutaneous branch 400
 - – – – lateral branches 408
 - – – – medial branches 408
 - – – – ventral 18, 230
 - – – root filaments 472 f
 - – – – anterior 474
 - – – – posterior 474
 - – – sacral 231
 - – – – ventral rami 18
 - – – thoracic 229
 - – – – dorsal root 231
 - – – – ventral root 214
 - – splanchnic
 - – – greater 279 f, 327, **335**
 - – – lesser 327, **335**
 - – lumbar 335
 - – – pelvic 349, **472**
 - – sacral 335
 - – – subcostal 329, **470**, **475**
 - – suboccipital 229, 238, **241**
 - – supraclavicular 63, **77**, 81, 207, 209, 242, 274
 - – – anterior 81, 180
 - – – intermediate 270, 400
 - – – lateral **174**, 178, **383**
 - – – medial **174 f**, 178, **214**, 400
 - – – middle **174 ff**, 178 ff, 406
 - – – posterior **179 ff**, 400, **403**, 408
 - – supra-orbital 63, 68, 72, **77**, 81, **136**
 - – – lateral branch 69, **73**, 85, 141
 - – – medial branch 69, **73**, 79, 85, 141
 - – suprascapular 170, 186, 378, 404, **414**
 - – supratrochlear **73**, 82
 - – sural 476, **479**, 489, 493
 - – – cutaneous branch 492
 - – – lateral calcaneal branches 493
- – sympathetic 334
- – temporal, deep 72, **82**
- – thoracic, long 186, 196, **207**, **214**, 407, 412 f
- – thoraco-abdominal 212, **214**, 216
- – thoracodorsal 186, 196, 207, **407**, 412, 415
- – tibial 446 f, **455**, 457, 467 f, **470**, 484, 491

Page numbers in **bold** indicate main discussions.

- trigeminal 31, 64, 66, **68 f**, 71 ff, 98, **114 ff**, 146
 - – main branches 69
 - – motor root 146
- trochlear 31, 64 ff, 67 ff, 71, **72 ff**, 98, 114 f, 136
 - – intracranial part 140
 - – intra-orbital part 140
- ulnar **186**, 207, 396, 399, 403, **413 ff**, 419, 420, 423 f, 427
 - – axillary region 410 f
 - – cubital region 416 ff
 - – deep branch 399, **427**
 - – dorsal branch 399 f, 421, 427
 - – palmar branch 423
 - – palmar cutaneous branch 400
 - – palmar digital branch 400
 - – – common 423, **428**
 - – – proper 423 f
 - – superficial branch 399, 423, **427**
- vagus 18, 31, 64, 66 f, 69, 71, 98, 111, **114 f**, 146, 154, 162 f, 165, 169, 244, 255, 264, 266, 274 f, 278, **280**, **335**
 - – cardiac branch 165, 185
 - – – cervical
 - – – – inferior 274, 276, **280**
 - – – – superior 274, 276
 - – – esophageal branches 278
 - – vestibulocochlear 31, 64, 66 f, 69, 98, 111, 114 f, **122 f**, 131
 - – – cochlear part 123
 - – zygomatic 68 f, **72**
- Nervous system 18
 - autonomic **18**, **334 f**
 - cranial part 18
- Network
 - capillary, of finger 427
 - venous
 - – of dorsum
 - – – of foot 477
 - – – of hand 398, 420
 - – around knee 486
 - – of lateral malleolus 498
 - – of medial malleolus 498
- Nipple **204**, 290, 410 f
- Node
 - atrioventricular 261
 - sinu-atrial 260 f
- Nodule of vermis 102
- Nostril 49
- Notch
 - acetabular 433, **436**
 - angular, of stomach 294 f
 - cardiac, of left lung 248, **268**
 - cardial, of stomach 294 f
 - clavicular 192
 - ethmoidal, of frontal bone 28
 - frontal 42, 45
 - interarytenoid 161
 - intercondylar 9
 - intertragic 124
 - jugular 192
 - mandibular **52**, 54, 79
 - mastoid 27, 29, **33**
 - parietal, of temporal bone 27
 - pterygoid 25
 - radial, of ulna 374
 - scapular 371 f
 - sciatic
 - – greater 433, **437**, 438
 - – lesser 433, **437**
 - sphenopalatine 39 f, 42
 - supra-orbital 22, 28
 - tentorial 73 ff
 - thyroid, superior 159
 - trochlear, of ulna 374
 - vertebral
 - – inferior 191, 197
 - – superior 191
- Nucleus(-i)
 - abducent 114
 - ambiguus 114
 - of Burdach 116
 - caudate 62, 92, 104 ff, **111**, **114**, 118 f
 - cochlear
 - – dorsal 131
 - – ventral 131
 - of cranial nerve 114
 - cuneate 116
 - dentate 103, 116
 - dorsomedial, of hypothalamus 108
 - emboliform 116
 - facial 70, **114**
 - of Goll 116
 - gracilis 116
 - hypoglossal **114**, 116
 - hypothalamic 108
 - lentiform **109**, **111**, **114 f**, 119
 - – motor
 - – – of oculomotor nerve 114
 - – – of trigeminal nerve 114
 - oculomotor 116
 - olivary, inferior 116
 - paraventricular 108
 - posterior, of hypothalamus 108
 - pre-optic 108
 - pulposus **198 f**, 232
 - red 99, **103**, 107, 116
 - salivatory 114
 - – sensory, of trigeminal nerve 114
 - solitarius 116
 - spinal, of accessory nerve 114
 - subcortical, of brain 105, **109 ff**
 - supra-optic 108
 - trochlear 114
 - ventromedial, of hypothalamus 108
 - vestibular **114**, 116
 - visceral
 - – of glossopharyngeal nerve 114
 - – of vagus nerve 114

O

- Obex 131
- Occlusion, centric 50
- Olecranon **374**, 379, 387, 392
 - fossa 373
 - surface anatomy 401
- Olfactory system 107
- Olive, inferior 66, 103, **111**, 114 f, 131
- Omentum
 - greater 292, 298, **302**, 306, 312, 318
 - – midsagittal section 322
 - lesser 311 f
 - – midsagittal section 322
- Opening
 - abdominal, of uterine tube 357
 - pharyngeal, of auditory tube 86, 246
 - saphenous 210, 217 f, 358, **468**, 479
- Operculum
 - frontal 109
 - frontoparietal 109
 - temporal 109
- Ora serrata 133
- Orbit 7, 31, **46 f**, **132**, 140 f
 - bones 132
 - horizontal section 148
 - nerves 72 f
- Organs
 - abdominal s. Abdominal organs
 - genital s. Genital organs
 - inner, position 2
 - mediastinal 274 ff
 - of neck 154
 - of posterior mediastinum 278 f
 - respiratory 247
 - retroperitoneal 323 ff
 - – vessels 305
 - thoracic 243 ff
 - – position 243 ff
 - – regional anatomy 264 ff
 - urinary, position 323 f
- Orifice
 - internal, of uterus 359
 - ureteric 336 f, 355
 - urethral
 - – external 336, 355, 361 f
 - – internal 336, **338 f**, 345, **355**
 - vaginal 356, 360, **361 f**, 364
- Oropharynx **150**, 155, 246
- Ossicles, auditory 20, 22, **122**, 125, **128**
 - movements 128
- Ossification, bones of limb 9
- Ossification center 9
- Outlet, pelvic 434

Page numbers in **bold** indicate main discussions.

Ovary 354, **356 ff**, 359 ff, 366 f
– position 323

P

Palate

– hard 50, 53, 143 f, **146 ff**, **150**, 164
– soft 53, 62, **88 f**, 143 f, 150, 163, 165

Palm of hand 368

Pancreas 279, 292, 294, **296 f**, 300, 302, 304, **316 f**

– Head's area 205
– horizontal section 324

Papilla(-ae)

– circumvallate 149
– duodenal
– – greater **296 f**, 300, 317, 320
– – lesser **296 f**, 300, 317
– filiform 149
– foliate 149
– fungiform 149
– renal 326 f
– sublingual 153

Patella 7, 432, **441**, 446, 452, 486, 492

– articular surface 448
– surface anatomy 477

Pecten pubis 433, **435**

Pedicle 191, 197

– of axis 200

Peduncle

– cerebellar
– – inferior **102 f**, 115
– – middle **102 f**, 111, **114 f**, 131
– – superior **102 f**, 111, 115
– cerebral 65, 71, **103**, 108, 114 ff, 131

Pelvic girdle 434

– organization 432
– skeleton 432

Pelvis 7, 188 f, 194 f

– aperture, inferior 437
– axial section 496
– female **359**, 435 ff
– – diameters 434, 438
– – inclination 438
– ligaments 444
– male **344 ff**, 435 ff
– renal **326 f**, 336
– – horizontal section 324
– skeleton 435 ff

Penis 336 ff

Perforated substance, anterior 66

Pericardium 170, 244 f, 255, 257, 265, **266 ff**, 269 f, **272 f**, 280 f

– diaphragmatic part 272
– reflection 255, **273**

Pericranium 85

Periorbita **72**, 132

Periosteum

– of skull 85
– of vertebral canal 232
Peritoneum 210, 213
– of posterior abdominal wall 310
– reflections from organs 318

Pes

– anserinus 452
– hippocampi 105 f
Phalanx(-ges) 368
– distal
– – of fingers 375 ff, **425**, 427
– – of great toe 442, 495
– – of thumb 376 f
– – of toe 443
– of foot 7, 432
– of hand 7
– middle
– – of fingers 375 ff, **425**, 427
– – of toe 443
– of newborn 9
– proximal
– – of fingers 375 ff, **425**, 427
– – of great toe 442, 495
– – of thumb 376 f, **425**
– – of toe 443

Pharynx 67, 86, 143, 154, 161, **164 ff**

– muscles 166 f
– oral part 90, 165

Pia mater 84 f, **89**, **92**, 100, 118

– spinal 98, 231, **232**

Pivot joint 10, **11**

Placenta 289, 359

Plane

– axial 4
– of the body 4 f
– coronal 5
– frontal 5
– horizontal 4
– median 5
– midsagittal 5
– nuchal **27**, **33**
– sagittal 4
– transpyloric 217
– transtuberular 217
– transverse 4

Plate

– cribriform, of ethmoidal bone **30 f**, 34, **38**, 49
– horizontal, of palatine bone **39 ff**, 42, 44 f, 49, **144**
– orbital
– – of ethmoidal bone **38**, 40 ff, 44 f, 46 f, 132
– – of frontal bone 28
– perpendicular **38 ff**, 41 f, 44, 47, 49
– pterygoid
– – lateral 21, 25 f, **33**, 36 ff, 41, 44 ff, 60 f, 125, 164
– – medial 25 f, **33**, 36 f, 41, 45, 144, **146**, 164

– tarsal

– – inferior 132

– – superior 132, 148

– tympanic 21

Platysma muscle 50, **55 ff**, **58 f**, 62, **77**, 149, 174, 290, 385

Pleura

– costal 264 ff
– surface projection of the thorax wall 248

Plexus

– alveolar, superior 72
– aorticorenal 335
– autonomic 323
– brachial 18, 77, 97, 154, 168, 170, 177, **186**, 206, 264, 269, 281, 335, 396, **399**, **412 ff**
– – lateral cord 170, **399**, **413**, 415
– – medial cord **399**, **413**, 415
– – middle trunk 396
– – posterior cord **399**, **413**, 415
– – roots 404, **413**
– carotid, internal 146
– celiac 279, **327**
– cervical 18, 97, 154, 177, **186**, **413**
– – cutaneous branches 174, **178**, 186, 207, 226, 234
– choroid 71, **112 f**
– – of fourth ventricle 115
– – of lateral ventricle **104 f**, 113, 115
– – of third ventricle 86, 105
– dental
– – inferior 68
– – superior 68
– esophageal 275 ff, 278 ff, 335
– gastric 335
– – anterior 279
– hepatic 279
– hypogastric
– – inferior **347**, 359, 472
– – superior 308, 331, **335**
– lumbar 470
– lumbosacral **18**, **470 f**
– nervous, of autonomic system 18
– pelvic 349
– pharyngeal 165
– prostatic 345
– pudendal 470
– sacral 349, **470 ff**
– solar 18
– splenic 279
– venous
– – extradural 232
– – pampiniform 218, 340, **343**, 347 f
– – prostatic 347, 349, 351
– – thyroid, inferior 184
– – uterine 367
– – vesicoprostatic 341, 346
– – vesico-uterine 355
Plica circularis of duodenum 297
Points, palpable, ventral 2

Page numbers in **bold** indicate main discussions.

- Polarity 1
 - Pons 66, 68, 86, 103, **114**
 - cross section 121
 - median section 90 f, 233
 - MRI scan 203
 - in neonate 233
 - Porta hepatis 299
 - Pouch 358
 - of Douglas **354**, 357 f f, 366 f
 - recto-uterine 322, **354**, 357 ff, 366 f
 - rectovesical 337 f
 - vesico-uterine 322, **354**, 356, 358 f, 366
 - Premaxilla 33
 - Premolar
 - first 50
 - second 50
 - Prepuce
 - of clitoris 361 f, 364 f
 - of penis 336, 341
 - Process(es)
 - alveolar
 - of mandible 22, **52**, 90
 - of maxilla 22, 37, 39 ff, 42, 44 ff, **52**, 90
 - articular
 - of cervical vertebra 157
 - inferior
 - of axis 200
 - of vertebra 191, 197
 - superior
 - of sacrum 433 ff, **437**
 - of vertebra 191, 197
 - ciliary 133
 - clinoid
 - anterior 25 f, **30**, 34, 36, **38**, 75
 - posterior 25 f, **30**, 34, **38**
 - cochleariform 126 f
 - condylar, of mandible 20 f, 36, **50**, **52**, 54, 56
 - coracoid 188 f, **369 ff**, 372, 378, 411
 - coronoid
 - of mandible 20 f, **52**, 54, 56, 79
 - of ulna **374**, 379
 - costal 191, 195, **198**
 - ethmoidal, of inferior nasal concha 48
 - frontal
 - of maxilla 22, 28, 37, **39 ff**, 42, 45, 47, 132, **144**
 - of zygomatic bone 45, 52
 - intrajugular 39
 - jugular 25, 39
 - lacrimal, of inferior nasal concha 48
 - lateral, of malleus 128
 - lenticular 126, 128
 - mamillary, of vertebra 191
 - mastoid 20 f, 27 ff, **33**, 53, 56, 122
 - maxillary
 - of inferior nasal concha 42, **48**
 - of palatine bone 40
 - muscular
 - of arytenoid cartilage 158
 - of vertebra 191
 - odontoid, of axis 86
 - orbital, of palatine bone 39 f, 42, 44, 132
 - palatine, of maxilla 33, 41 ff, **48**, **144**
 - perpendicular 49, **144**
 - pterygoid 21, 36, 127
 - of newborn 33
 - pyramidal 39 f, 42, 45
 - sphenoidal, of palatine bone 39 f, 42
 - spinous 3, 191 f, 194, **197**
 - of axis 53, **200**, 202, 222 f, 225, **237**
 - of cervical vertebra 157, 177, **191**, 193 f, **201**
 - of lumbar vertebra **191**, 193 f
 - of seventh cervical vertebra 222 f, 235 f
 - of thoracic vertebra **191**, 193
 - styloid
 - of radius 374, **376 f**, 380 f
 - of temporal bone 27 f, 33, 53, **54**, 60 ff, 71, 126, **151**, 164, 166
 - of ulna 374, **376 f**, 381
 - talar, posterior 443
 - transverse
 - of atlas 200 ff
 - of axis 200
 - of cervical vertebrae 177
 - of thoracic vertebrae 225
 - of vertebra 191, 197
 - uncinata
 - of ethmoidal bone 37, 46
 - of pancreas 297
 - vaginal 219
 - remnant 218
 - vocal, of arytenoid cartilage 158
 - xiphoid 189, 192, 196, 206, 264, 306, **369**
 - zygomatic
 - of frontal bone 28, **44 f**
 - of maxilla 22, 39 ff, 42, 44 f
 - of temporal bone 21, 27 f, 125
 - Prominence
 - saccular 128
 - utricular 128
 - Promontory
 - sacral 188 f, 310, 330, **337**, **346 f**, 354 f, **434 f**, 438, 471
 - midsagittal section 322
 - of tympanic cavity 125 ff
 - Pronation 368 f, **391**
 - Prosencephalon 91
 - Prostate 336 ff, 341, **344**
 - coronal section 345
 - Protuberance
 - mental 23, **52**
 - occipital
 - external 21, 25, 27, 29, **33**, 223
 - internal 25, 27, **30**, 39, 42
 - Pubis 7, **433**, 438, 496
 - symphyseal surface 433, 438
 - Pulvinar of thalamus 110, 115, 137
 - Punctum nervosum 63, **77**, 242
 - Purkinje fibers 261
 - Putamen 92, 105, **110**, 116, 120
 - Pylorus **295 f**, 298, 311, 318
 - Pyramid 66, 127
 - of vermis 102
- ## R
- Radiation 120
 - acoustic 131
 - of Gratiolet **109**, 119 f, **137 f**
 - optic **109**, 119 f, **137 f**
 - Radius 7, 10, **368**, **374**, 376 f, 379 ff, 425, 427
 - anterior surface 374 f
 - articular surface 374
 - axial section 419, 431
 - of newborn 9
 - posterior surface 374 f
 - Ramus
 - communicans, of sympathetic trunk 279 f
 - of ischium 437 f
 - of mandible 22 f, **52**, 54, 150
 - pubic, inferior 342
 - Raphe
 - fibrous, of pharynx 167
 - mylohyoid 156
 - pterygomandibular 61, **166 f**
 - Recess
 - costodiaphragmatic 248, **265**, 282
 - duodenal
 - inferior 318
 - superior 310, 318
 - elliptical 129
 - epitympanic 125, 128
 - hypotympanic 125, 128
 - ileocecal 318
 - inferior, of tympanic cavity 127
 - infundibular 112
 - intersigmoid 318
 - lateral, of fourth ventricle **112**, 116
 - optic **112**, 116
 - paracolic 318
 - peritoneal 318
 - pharyngeal 144, 147
 - pineal 112
 - piriform 161, 163
 - retrocecal 318
 - of Rosenmüller 145
 - sphenothmoidal 145
 - spherical 129
 - splenic, of lesser sac 318
 - superior, of lesser sac 318
 - suprapineal 112
 - Rectum 291, 310, 366 f

Page numbers in **bold** indicate main discussions.

- Region(s)
- anal 352
 - anterior, of neck **174 ff**, 406
 - axillary 407 f, **409 ff**
 - cervical 155
 - – anterior 155, **174 ff**
 - – lateral 155, **178 ff**
 - – posterior 155
 - crural 489 ff
 - – anterior 492, 494
 - – posterior 489 ff
 - cubital 416 ff
 - epigastric 217
 - facial, deep 82
 - femoral
 - – in the male 219
 - gluteal 482 ff
 - hypochondriac 217
 - hypogastric 217
 - iliac 217
 - infraclavicular 407
 - inguinal
 - – in the female 220
 - – in the male 219
 - of knee 486 f
 - lateral
 - – of head 76 ff
 - – of neck 178 ff
 - lumbar 217
 - malleolar, medial 468
 - nuchal 234 ff
 - parapharyngeal 31, 83, **151**
 - pharyngeal 81
 - popliteal 458
 - posterior, of neck **234 ff**, 403
 - retromandibular 81 f
 - retroperitoneal
 - – horizontal section 325
 - – lymph nodes 332
 - – lymph vessels 332
 - – nerves 333
 - – vessels 333
 - retropharyngeal 83
 - scapular 409
 - sublingual 151
 - submandibular 183
 - superficial, of the face 76
 - of trunk 217
 - umbilical 217
 - urogenital
 - – in the female 363
 - – in the male 352
- Respiration, changes of the position of diaphragm 282
- Respiratory system 246 ff
- Retina 133 f
- Retinaculum
- extensor
 - – of hand **392 ff**, 420 f, **424**
 - – – tunnels 392
 - – inferior, of foot **459**, 493, 495, 498 f
 - – superior, of foot **459**, 462, 498
 - flexor
 - – of foot **458 f**, 461, 491
 - – of hand 14, **388**, 390 f, 395, 423, **427 f**
- Rhombencephalon 91
- cross section 117
- Rib(s) 7, **190**, **369**
- false 369
 - first 159, 185, 188 f, **192 ff**, 206, 372
 - floating 194, **369 f**
 - true 194, **369**
 - twelfth 188 f, 193, 453
- Ridge, supracondylar
- lateral 373
 - medial 373
- Rima glottidis 161
- Ring
- ciliary 133
 - inguinal
 - – crus, lateral 217
 - – deep 212, **218**, 293, 337, **347**
 - – superficial 211, 217 f, **220**, **340**, **362**, 479
 - tendinous, common 135, 141
 - tympanic 125
 - umbilical 209, 213
- Riolan's anastomosis 304
- Roof of orbit 72
- Root(s)
- aortic 254
 - of brachial plexus 404, **413**
 - dorsal, of cervical spinal nerve 157
 - inferior, of ansa cervicalis 184
 - of median nerve 399, 411, 415
 - of mesentery 306, **318**
 - of meso-appendix 318
 - of mesosigmoid 318
 - motor, of trigeminal nerve 146
 - of penis 293, 342
 - superior, of ansa cervicalis 69, 71, **82 f**, 152, 179
 - of tongue 149 f, 161
 - of transverse mesocolon 312, **318**
 - ventral, of cervical spinal nerve 157
- Root filaments, posterior 98
- Rostrum, sphenoidal 25 f
- S**
- Sac
- endolymphatic 129
 - lacrimal 142
 - lesser 292, **311 ff**
 - – horizontal section 324
 - – isthmus 318
 - – midsagittal section 322
 - – splenic recess 318
 - – superior recess 318
 - pericardial 273
 - – upper margin 269
- Sacrum 3, 7, 188 f, **190 f**, 193, 195, **432 ff**, 472, 482
- lateral part 191
 - pelvic surface 433
 - shape 437
 - surface anatomy 476
- Saddle joint 11, 377
- Scapula 7, 15, 188, 223, **368 ff**, 378
- anterior surface 371
 - costal surface 371
 - of newborn 9
 - posterior surface 370, 372
- Scarring of ovary 357
- Sclera 132 ff
- Segmentation 1
- Segment(s)
- bronchopulmonary 246, **250 f**
 - of kidney 326
 - of liver 299
 - of spinal cord 475
- Sella turcica 25 f, **30**, 34, 36, 38, 46, 49, 53
- of newborn 35
- Semicanal of auditory tube 130
- Septum(-a)
- intermuscular
 - – lateral, of arm **387**, 392
 - – medial, of arm **387 f**, 416 ff, 423
 - interventricular 256, 258 f, 261
 - lingual 62, 149
 - nasal 22, **49**, 53, **144**, 146
 - – posterior border 48
 - pectiniforme 342
 - pellucidum 86, **94**, 103 ff, 116, 118 ff
 - of penis 339
 - of testis 343
- Shaft
- of femur 9, **438 f**
 - of fibula 440
 - of radius 374
 - of rib 191 f
 - of tibia 440
- Sheath(s) (s. also Synovial sheath) 394, 427
- fibrous
 - – digital, of tendons of flexor digitorum muscle 389
 - – of flexor tendons of hand 391, 394, **427 f**
 - of rectus abdominis muscle 204
 - – anterior layer **187**, 196, **208 ff**, 212, 214, **264 f**, 480
 - – posterior layer 206, **212 ff**, 293
 - of round ligament 220
 - synovial s. Synovial sheath
- Shoulder 403 ff
- collateral circulation 404
 - joints 378

Page numbers in **bold** indicate main discussions.

- ligaments 378
- muscles 382 ff
- region
 - – anterior 406 ff
 - – posterior 403 ff
- Shoulder girdle 7, **368**
- organization 368
- skeleton 369 ff
- Shoulder joint 10, **15, 368, 378, 382 ff**
- coronal section 11, 378
- frontal section 15
- horizontal section 430
- MRI scan 11, 15, 378, 430
- of newborn 9
- X-ray 15
- Shunt in fetal circulatory system 288
- Sinus(es) 258
- aortic 261
- carotid 63, **396**
- cavernous 31, 62, **87, 97, 124**
- coronary 257 f, 261, 273, 284
- ethmoidal 121, **148**
- frontal 37, **46, 48, 53, 73, 84, 86, 88 f, 143 ff**
- – opening 144
- intercavernous 87
- lactiferous 290
- of larynx 86
- maxillary 37, 46, 132, **144**
- – innervation of mucous membrane 72
- oblique, of pericardium 272 f
- paranasal 144 f
- – openings 144 f
- pericardial, transverse 269, 272 f
- petrosal, superior 87
- of pulmonary trunk 252
- renal 326
- sagittal
 - – inferior **85, 87, 112**
 - – superior 75, **85 ff, 112, 241**
- sigmoid 87
- sphenoidal 36 f, **48 f, 53, 62, 86, 88 f, 121, 144, 148**
- – opening 25
- straight 67, 75, **85 ff, 112, 121**
- tarsal 443
- transverse 67, 121, 241
- venous, dural 86 f
- Skeleton 6 ff
- appendicular 7
- of arm 10
- axial 7
- of a child 7
- cranial, of newborn 35
- facial 23
- – of newborn 35
- of a female adult 6
- of foot 442 f
- of hand 11
- of leg 440
- of pelvis 435 ff
- of thorax 192 ff
- of trunk **188 f, 221**
- visceral 22
- of wrist 11
- Skin
 - of scalp **89, 236**
 - of scrotum 218
- Skull 1
- anterior aspect 22
- base s. Base of skull
- bones 20 ff
- lateral aspect 20 f
- median section 36 f
- of newborn 33, **35**
- paramedian section 46
- periosteum 85
- Small intestine 3, 210, 291 f
- of fetus 289
- Head's area 205
- Snuffbox, anatomical 394, 428
- Solar plexus 323
- Spine of foot 461, **500 ff**
- Space
 - epidural, spinal 232
 - extradural, spinal 232
 - infratentorial 88
 - intercostal
 - – nerve s. Nerve, intercostal
 - – vessels s. Artery, intercostal; s. Vein, intercostal
 - intervaginal, of optic nerve 112
 - quadrangular, of axillary region 408 f
 - subarachnoid **85, 97, 133, 241**
 - – spinal **232, 472**
 - subdural 118
 - – spinal 232
 - triangular, of axillary region 408 f
- Sphincter
 - lower, of esophagus 278
 - middle, of esophagus 278
 - of Oddi 297
 - upper, of esophagus 278
- Sphincter muscle s. also Muscle, sphincter
 - anal
 - – external 342, 349, **350 ff, 354, 361**
 - – internal 361
 - pyloric 294 f
 - urethral 338
 - – external 336
 - – internal 336
- Spinal cord **18, 62, 84, 86, 89, 177, 214, 230 ff, 240 f, 473 ff**
- lumbar portion 230
- median section 91
- meningeal coverings 232
- MRI scan 203
- relation to vertebral column 475
- segments 475
- terminal filament 472
- terminal part 230 ff
- thoracic portion 231
- Spine 435
- frontal 42
- iliac
 - – inferior
 - – – anterior 433, 435 f
 - – – posterior 188, **433**
 - – superior
 - – – anterior 3, 189, **216, 433, 435 f, 438, 452 f, 480**
 - – – surface anatomy **204, 477**
 - – – posterior 188, **433, 435, 437, 482**
- ischial 188, **433, 435 f, 438**
- mental 36, **52**
- nasal 28
- – anterior 20, 36, 39, 45, 46 f
- – of frontal bone 47
- of scapula 3, 188, 234, **370 ff, 382 f, 408 f**
- of sphenoid 25, 126
- trochlear 22
- Spine-trochanter line 482
- Spine-tuber line 482
- Spleen 279, 291, 296, **300, 303 f, 311, 316 f, 329**
- border, anterior 300
- horizontal section 324
- margin, superior 300
- Splenium of corpus callosum 65, 99, **104 ff, 119 f**
- Squama
 - of occipital bone 20 f
 - of temporal bone 20 f
- Stapes 20, **122 f, 127, 128 f**
- Sternum 7, 187, 194, 206, **264, 368 f**
- Stomach 244, 279, 284, 291 f, **294 f, 303, 306, 311**
- cardiac part 294 f, 329
- circular muscle layer 295
- of fetus 289
- Head's area 205
- horizontal section 320
- longitudinal muscle layer 295
- midsagittal section 322
- muscular coat 295
- position 3, 294
- pyloric part 295, 316
- sagittal section 245
- Stria
 - acoustic, dorsal 131
 - longitudinal
 - – lateral 104 ff, **107, 113**
 - – medial 104 ff
 - medullaris of thalamus 99, 107, 115
 - olfactory
 - – lateral 103, **107, 137**
 - – medial 103, **107, 137**
 - terminalis 103 ff, **107, 115, 118**
- Substance, perforated
 - anterior 66, 99, 103, 137

Page numbers in **bold** indicate main discussions.

- Substance, perforated
 - posterior 103, 137
 - Substantia nigra 65, 99, **103**, 116
 - Sulcus
 - calcarine **99**, 103, 137
 - communication with parieto-occipital sulcus 99
 - carotid **30**, 38
 - central 89 f, 94, 100 f
 - of insula 72
 - chiasmatic 25, **30**
 - cingulate 99
 - circular, of insula 109
 - coronary 252, 257 f, 260 ff
 - of corpus callosum 99
 - frontal, superior 100
 - infra-orbital 132
 - intertubercular 373, 378
 - interventricular 268
 - anterior 252, 255, 257, 260, 262
 - posterior 252, 257, 262
 - lateral 89, 100
 - ascending ramus, anterior 100 f
 - horizontal ramus, anterior 100 f
 - posterior ramus 101
 - lunate 100
 - malleolar, of tibia 440
 - median, of tongue 149
 - mylohyoid 52
 - occipital, transverse 92
 - olfactory 66
 - orbital, of frontal lobe 66
 - parieto-occipital 99
 - postcentral 100 f
 - precentral **99 f**, 101
 - temporal, inferior 66
 - terminalis
 - cordis 256, 260 f
 - of tongue 149
 - Supination 368 f, **391**
 - Surface
 - articular
 - calcaneal
 - anterior, of talus 449
 - middle, of talus 449
 - posterior, of talus 449
 - inferior, of tibia 440
 - malleolar, of fibula 440
 - navicular, of talus 449
 - of navicular bone 449
 - of patella 441, 448
 - proximal, of tibia 447
 - superior
 - of axis 200
 - of tibia 440
 - talar
 - anterior, of calcaneus 449
 - middle, of calcaneus 449
 - posterior, of calcaneus 449
 - auricular, of sacrum 191, 433
 - bare
 - of ascending colon 318
 - of descending colon 318
 - costal 369
 - diaphragmatic
 - of liver 298
 - of lung 249
 - gluteal, of ilium 437
 - lunate, of acetabulum 433, **436**, 445
 - malleolar, lateral, of talus 443
 - patellar, of femur 439, **441**, 447
 - pelvic, of sacrum 433
 - popliteal, of femur 439, **441**
 - symphyseal, of pubis 433, 438
 - Surface anatomy 204 f, 401 f, 476 f
 - Sustentaculum tali **443**, 450 f
 - Suture
 - coronal 20 ff, **29**, **35**
 - ethmoidolacrimal 20
 - frontal 22 f, **35**
 - frontomaxillary 23
 - frontonasal 22
 - frontosphenoid 21
 - intermaxillary 22
 - internasal 22 f
 - lacrimomaxillary 20
 - lambdoid 20 f, **29**, **35**
 - nasomaxillary 20 ff, 23
 - of newborn 35
 - occipitomastoid 20 f, **29**
 - palatine
 - median 33, 45
 - transverse 45
 - palatomaxillary 33
 - parietomastoid 20
 - sagittal 29, 35
 - sphenofrontal 20, 23
 - sphenosquamosal 21
 - sphenozygomatic 23
 - squamomastoid 125
 - squamous 20 f
 - zygomaticomaxillary 22 f
 - Symmetry, bilateral 1
 - Symphysis, pubic 7, 188 f, 293, 354, 356, 432, **435 f**
 - midsagittal section 322
 - Synchondrosis, spheno-occipital 27, **38**
 - Syndesmosis, tibiofibular 443, 495
 - Synovial fluid 12
 - Synovial sheath
 - common
 - of extensor digitorum longus muscle 493
 - of flexor tendons of hand 390 f
 - digital
 - of flexor tendons of hand 390 f
 - of foot 501
 - of extensor tendons of hand 392
 - of flexor tendons
 - of foot 501
 - of hand 390
 - of hand 14
 - of tendon
 - of extensor hallucis longus muscle 493
 - of flexor pollicis longus muscle 390 f
 - of tibialis anterior muscle 493
- Systole 260
- ## T
- Taenia
 - coli 306
 - free, of colon 307 f, 310, 318
 - Tail
 - of caudate nucleus 115
 - of epididymis 343 f
 - of pancreas 297, 300, 316
 - Talus **443**, 449 ff
 - articular surface
 - calcaneal
 - anterior 449
 - middle 449
 - posterior 449
 - navicular 449
 - of newborn 9
 - Tectum 94, **108**, **114**
 - Telencephalon 91
 - Tendon 393, 415, 499
 - of abductor pollicis longus muscle 388, **390**, 392, 394, 401, **427**
 - annular, common 135, 141
 - of biceps femoris muscle 455 f, 484
 - surface anatomy 476 f
 - calcaneal 449, **457 ff**, 489, 491 ff
 - surface anatomy 476
 - central
 - of diaphragm **278**, 283, 298, 329
 - of perineum **353**, 361
 - of deep flexor muscles 458
 - of extensor carpi radialis brevis muscle 392 ff
 - of extensor carpi radialis longus muscle 392 ff
 - of extensor carpi ulnaris muscle 392, **424**
 - of extensor digiti minimi muscle 392
 - of extensor digitorum brevis muscle of foot 493
 - of extensor digitorum longus muscle of foot 459, 462, 491, 498 f
 - of extensor digitorum muscle of hand 392 ff, 401, **424**
 - of extensor hallucis longus muscle **458 f**, 491, 493, **498 f**
 - of extensor indicis muscle 392, 394, 401
 - of extensor muscles of hand 381
 - of extensor pollicis brevis muscle 388, 392, 394, **427**
 - of extensor pollicis longus muscle 392, 394, **424**

Page numbers in **bold** indicate main discussions.

- of flexor carpi radialis muscle 380 f, **389 f**, 394 f, **427 f**
- – surface anatomy 402
- of flexor carpi ulnaris muscle 380 f, 388, **390 f**, 394 f, **427 f**
- of flexor digitorum brevis muscle of leg 463 ff, 501 f
- of flexor digitorum longus muscle of leg 460, 463 ff, 501 f
- of flexor digitorum profundus muscle of hand **389 f**, 394 f, 425, **427**
- of flexor digitorum superficialis muscle of hand **389 f**, 394 f, 425, **427 f**
- of flexor hallucis longus muscle 449, **460 f**, 463, 465, 501 f
- of flexor pollicis longus muscle 388, **390**, 394 f
- of gracilis muscle 447, 452, **455**, 457
- of iliocostalis muscle 225
- intermediate
 - – of digastric muscle 150
 - – of omohyoid muscle 179
 - – of semitendinosus muscle 456
- of long head
 - – of biceps brachii muscle 378, **387**, 415 f, 419
 - – of triceps brachii muscle 378 f, 392
- of lumbrical muscle of hand 394
- of palmaris longus muscle 388, 402, 423, **428**
- of peroneus brevis muscle 491
- of peroneus longus muscle 462, **464**, 491
- of peroneus tertius muscle 462, 499
- of plantaris muscle 488
- of sartorius muscle 452
- of semimembranosus muscle 447
 - – surface anatomy 476
- of semitendinosus muscle 447, 452, 487
- sheath s. Sheath, fibrous; s. Synovial sheath
- of short head of biceps brachii muscle 387
- of stapedius muscle 126, 128
- of superior oblique muscle 135 f, 140
- of supraspinatus muscle 378
- of temporalis muscle 60 f, 80, 82
- of tensor veli palatini muscle 126
- of tibialis anterior muscle 458, 461, 493, 495, **498 f**
- of tibialis posterior muscle 460 f
- of triceps brachii muscle 409
- Tenon's space 132
- Tentorium cerebelli 67, 75, **87 ff**, 97, 121
- Testis 3, 218, 330, **336 f**, 339, 341, **343**, 351, 479
 - Head's area 205
 - longitudinal section 343
- Thalamus 90 f, 99, 103 ff, 107, 113, 116, 120
- Thenar muscles **390 f**, 395, **423**
 - axial section 431
- Thigh
 - anterior region 478 ff
 - arteries 480 f
 - axial section 496
 - muscles 480 f, 484 f
 - nerves, cutaneous 478 f, 484
 - posterior region 484 f
 - veins 478 f
- Thoracic cage, changes of position during respiration 282
- Thorax 1, 7, 188 f, **369 ff**
 - coronal section 253, **284 f**
 - horizontal section 286 f
 - MRI scan 253, **284 ff**
 - paramedian section 283
 - sagittal section 245, 263
 - skeleton 192 ff
- Thymus 155, 233, **265 ff**, 292
 - remaining parts 245
- Tibia 7, 12, 432, **440 ff**, 446
 - of newborn 9
 - upper end 440
- Tissue
 - adipose
 - – encasing round ligament 363
 - – perirenal 300, 324
 - cavernous, of female external genital organs 362
- Tongue 83, 84, 143
 - innervation 31
- Tonsil
 - cerebellar 66, **102**
 - lingual **149**, 161
 - palatine 83, 143, **147**, **149**, 153, 165
 - pharyngeal 144
- Tooth (teeth)
 - deciduous 51
 - lower 22, **50 ff**
 - molar 42, **50 f**
 - – permanent 51
 - – third 37
 - premolar 37, **50 f**
 - upper 22, 41 f, 44 f, **50 ff**
- Trabecula(-ae)
 - carneae 259
 - septomarginal 258
- Trachea 154, 243, 255, **274 ff**, 285
- Tract(s) 477
 - cerebellorubral 103
 - iliotibial 448, **452 f**, 455, **480**, 495
 - – surface anatomy 476 f
 - olfactory **65 f**, 69, **74 f**, 98 f, 103, **107**, **114 f**, 146
 - – lateral root 99
 - – medial root 99
 - olivocochlear 131
 - optic 66, 71, 107, **137 f**
 - pyramidal 109, 116
 - – course 111
 - – lateral 103
 - of Rasmussen 131
 - spiral, foraminous 123
 - Tractus solitarius 116
- Tragus **122**, 124
- Triad, portal 299
- Triangle(s)
 - carotid 155, 173, 178 f
 - deltopectoral 384, **407**
 - – surface anatomy 402
 - lumbar 223
 - lumbocostal 335
 - of neck 155
 - sternocostal 283
 - submandibular 155
 - suboccipital 237 f
 - supraclavicular 155
- Trigone
 - of bladder 336, 338 f, **355**
 - habenular 115
 - hypoglossal 115
 - olfactory 66, 115, 137
- Trochanter
 - greater 9, **438 f**, 482
 - lesser 438 f
 - third 439
- Trochlea
 - of humerus 373, 375, 379
 - peroneal, of calcaneus 443
 - of superior oblique muscle **72**, 135 f, **141**
 - of talus 443, 450 f
- Trunk 7, **187 ff**
 - brachiocephalic 162, **168 f**, 252 f, 256 f, 263, 267 f, 274 f, **396**, **414**
 - bronchomediastinal 332
 - celiac 279, 283, 300, 302, 316, **327 ff**, 330 f, 333, **335**
 - – branches **311**, **314 f**
 - costocervical 168
 - cross section 204
 - horizontal section 210 f
 - jugular 172 f
 - lumbar 332
 - lumbosacral 471
 - lymph vessels 17
 - median section 4, 233
 - – in neonate 233
 - midsagittal section 322, 354
 - neuro-vascular segments 187
 - parasagittal section 325
 - pulmonary **245**, **252 ff**, 260 ff, 266, 269, 271
 - – of fetus 288
 - – relation to bronchial tree 275
 - reference lines 217
 - regions 217
 - sagittal section 5
 - skeleto-motoric segments 187
 - skeleton 221
 - subclavian 184, 332
 - sympathetic 18, 67, 146, 162, 164 f, 168, 185, 266, **279 ff**, 327, 333, **334 f**, 471 f
 - – cervical part 174
 - – Ramus communicans 280 f

Page numbers in **bold** indicate main discussions.

- Trunk
- thyrocervical 162, **168 ff**, 177, 271, 396, 404
 - vagal 335
 - – anterior 327
 - – posterior 327
- Tube
- auditory 120, **122 ff**, 126 f, 143
 - – bony part 27
 - – opening 145, **147**
 - – pharyngeal opening 86, 144, 246
 - uterine **354 ff**, 359 f, 366 f
 - – position 323
- Tuber
- calcanei 451
 - cinereum 99
 - frontal 35
 - parietal 29, **35**
 - of vermis 102
- Tuber-trochanter line 482
- Tubercle
- anterior
 - – of atlas 191
 - – of transverse process 191
 - articular 21, 27 f, **50**, 54
 - conoid 369
 - corniculate 160
 - cuneiform 160
 - dorsal, of atlas 223
 - genial 36, **52**
 - greater, of humerus 372 f, 430
 - infraglenoid 370 ff
 - intercondylar
 - – lateral, of tibia 440
 - – medial, of tibia 448
 - – posterior, of tibia 440
 - jugular 25, 27, 39
 - lesser, of humerus 373, 430
 - olfactory 99
 - pharyngeal 25, 27, **33**, 164
 - posterior
 - – of atlas 191, 200
 - – of transverse process 191
 - pubic 433, **435**
 - of rib 191 f, **197**
 - supraglenoid 370 f
 - thyroid
 - – inferior 159
 - – superior 159
- Tuberculum sellae 38
- Tuberosity
- calcaneal 443, **450**, 457, 463, 491
 - deltoid 373
 - of distal phalanx 376 f
 - – of great toe 442
 - of fifth metatarsal bone 443
 - ischial 188, 344, **433**, **436 f**, 455 f, 472, 482
 - masseteric 52
 - maxillary 39 ff, 46
 - radial 374 f, 379
 - sacral 433
 - tibial **440 f**, 458 f
 - ulnar 374
- Tubules, seminiferous, convoluted 343
- Tunica
- albuginea
 - – of corpora cavernosa 339
 - – of corpus spongiosum 339
 - – of testis 341
 - vaginalis
 - – parietal layer 341, **343**
 - – testis 218, **343**
 - – visceral layer 341, **343**
- U**
- Ulna 7, 10, **368**, **374**, 376 f, 379 ff, 425
- anterior surface 375
 - axial section 419, 431
 - of newborn 9
 - posterior surface 374
- Umbilicus 3, 187, **209**
- Uncus
- hippocampi 99
 - of parahippocampal gyrus 106
- Urachus 289, 339, 354, 361
- Ureter 3, 210, 296, 300, **326 ff**, **330 ff**, **336 ff**, 359
- abdominal part **326 f**, 330, 336
 - Head's area 205
 - pelvic part 330, 336
 - position 323
- Urethra
- female 354 f
 - male 336 ff
 - membranous part 336 ff, 342, 344
 - prostatic part 336 ff, 344 f
 - spongy 337 ff
- Urinary bladder
- base 367
 - of the female 354 f, 357 ff, 361
 - of the fetus 289
 - frontal section 293
 - Head's area 205
 - horizontal section 324
 - of the male 336 ff
 - midsagittal section 322
 - mucous membrane 338 f
 - position 323
- Urinary organs, position 323 f
- Urinary system 330 f
- Urogenital system
- female 354 ff
 - male 336 ff
- Uterus **354 ff**, 358, **359 f**, 366 f
- position 323
- Utricle, prostatic 338
- Uvula 62, **86 f**, 144, 147, 163, 165
- of bladder 338
 - of vermis 102
- V**
- Vagina 322 f, 355, **356**, **358**, 360
- Vallecula of epiglottis 149
- Valve(s)
- aortic 253, **255 f**, 258 f, 261, 284
 - atrioventricular
 - – left **255 f**, 258 f
 - – right **255 f**, 258 ff, 287
 - bicuspid **255 f**, 258 f
 - of heart 255 ff
 - – position 255, **260**
 - ileocecal 310
 - – horizontal section 320
 - of inferior vena cava 288
 - mitral **255 f**, 258 f
 - pulmonary **255 f**, 259 f, 271, 286, 325
 - tricuspid **255 f**, 258 ff, 287
- Vasa recta of renal medulla 329
- Vein(s) 16, 468
- alveolar
 - – inferior 83
 - anastomotic
 - – inferior 92
 - – superior 89
 - angular 170
 - arcuate 329, 468
 - axillary 170, **186**, 196, **214**, 252, 264, 398, 411
 - azygos 244, 246, 276, **279 f**, 332
 - basilic 398, 402, 410, 419
 - brachial 398, 415
 - – surface anatomy 402
 - brachiocephalic 155, 170, **177**, 244, 252, 255, 265, 267, 271, 274, **396**, 398
 - – of fetus 288 f
 - cardiac
 - – great 258, 262
 - – middle 262
 - – minimal 262
 - – small 262, 270
 - cephalic **170 f**, 207, 209, 211, 265, 290, 398, **406**, 416
 - – accessory 401 f
 - – on forearm 398, 401 f, 419
 - – surface anatomy 402
 - cerebral 92
 - – great 90, 145
 - – inferior 89, **92**
 - – internal 86
 - – middle, superficial 92
 - – superior 89, **92**
 - of Cockett 468 f

Page numbers in **bold** indicate main discussions.

- coronary 262 f
- cubital, median 398, **402**, 416, 419
 - surface anatomy 402
- cutaneous
 - of leg 489
 - of popliteal fossa 486
 - of region of knee 486
 - of thigh 484
- digital
 - of foot 468
 - of hand 398
- dorsal
 - deep, of penis 217 f, **339 ff**, 342, 346
 - of penis 479
 - superficial, of penis 346
- epigastric
 - inferior 212, 219
 - superficial 210 f, 217, 468
 - superior 206, 208
- ethmoidal, anterior 31
- facial 77, **79**, 152, 170, 398
- femoral **214**, 293, 340, 367, 452, **467 f**, 480, 496
 - entering the adductor canal 452
- gastric, left 303
- gastro-omental 303
- hemiazygos 279
 - accessory 279, 287
- hepatic 283, 299, 303
- ileal 303
- ileocolic 303
- iliac
 - circumflex, superficial 210 f, 217, 468, **479**
 - common 359
 - external 293, **346**, 468
 - internal 279
 - intercostal 206, **210 f**
 - anterior 207
 - posterior 276, 279 ff
 - dorsal branches 408
 - superior 281
 - interlobar, of kidney 329
 - interlobular, of kidney 329
 - jejunal 303
 - jugular 154
 - anterior 170, 398
 - external **77**, 80, 170, **264 f**, 398
 - internal 80, 124, 127, 152, **157**, 165, **170 f**, 177, 179, 244, 252, **264 f**, 274 f, 398
 - of fetus 289
 - labial
 - inferior 170
 - superior 170
 - of labyrinth 31
 - lacrimal 140
 - lumbar 335
 - ascending 279
 - median, of forearm 402
 - meningeal, middle 87 f
 - mesenteric
 - inferior 300, 303, 308
 - superior 296, 300, **302 ff**, **309**, 316
 - metacarpal, dorsal 398
 - metatarsal, dorsal 468
 - nasal, superior, of retina 134
 - oblique, of left atrium of heart 262
 - obturator 366
 - occipital **85**, 170, 398
 - ophthalmic, superior 31
 - para-umbilical 303
 - perforating 468, 492
 - pericardiophrenic 272, 281
 - peroneal 468
 - plantar
 - lateral 499
 - medial 499
 - popliteal 446, **467**, 484, 486 ff
 - portal 16, 296, 299, **303 f**, 315, 317
 - of fetus 289
 - posterior, of left ventricle 262
 - of posterior abdominal wall 279
 - of posterior thoracic wall 279
 - pudendal, external 467 f, 479
 - superficial 210, 217
 - pulmonary 16, 252 f, 271
 - branches 246
 - of fetus 288 f
 - left 249, 262, 272 ff, 276, **281**
 - right 244, 249, 262, **272 ff**, 276, 283
 - radial 419
 - rectal
 - inferior 352
 - superior 303
 - renal **326 f**, 331
 - left 292, 327
 - right 329 f
 - retinal 134
 - central 133
 - retromandibular 77, 152
 - sacral, median 279
 - saphenous
 - great 210 ff, **214**, 217 f, 340, 344, **467 f**, 479, 480, 486, 489, 492
 - small 468, 484, **489**, 492 f
 - anastomoses with great saphenous vein 468, 489
 - scapular, circumflex 378, **408 f**
 - scrotal, posterior 351
 - sigmoid 303
 - spermatic 331
 - splenic 294, 303, 317
 - subclavian **170 f**, 184, 207, 244, 255
 - right 264 ff, 270
 - subcortical of kidney 329
 - submental 152, 170
 - superficial
 - on dorsum of foot 469
 - of forearm 420
 - of leg 469
 - of lower limb 468 f
 - supra-orbital 170
 - suprascapular 378
 - sural 487
 - temporal
 - inferior, of retina 134
 - superficial **77**, 79, 85, **168**, 170, 183, **398**
 - superior, of retina 134
 - testicular 341, 349
 - thoracic
 - internal **208**, **264 ff**, 398
 - lateral 196, 208, **290**, 398
 - thoraco-epigastric 207, 410 f
 - thymic 270
 - thyroid
 - inferior 170, 181, 269, 272
 - superior 170
 - tibial
 - anterior 468
 - posterior 468
 - ulnar 425
 - umbilical 289
 - vorticose 133, 140
- Velum medullary superior 102, 115
- Vena
 - cava
 - inferior 210, 252, 272, **283**, **285**, 303 f, 311, 320, 327, 329, 330 f, 359
 - of fetus 288 f
 - opening 258, 288
 - superior 169 f, 177, 244, **252 f**, 255, 260 ff, 270 f, 280, **282**, 284 f, 396
 - of fetus 288 f
 - vorticosa 133, 140
- Ventricle 269
 - fourth 71, 86, 91 f, 94, 102, **112**, 116
 - of larynx 161
 - lateral 71, **104 f**, 116
 - central part **112**, 118
 - left 16, 244 f, **252 f**, 255, 258, 262 f, **268 ff**, 271, 273, 285, 325
 - of fetus 288
 - right 16, 243 ff, **252 ff**, 255, 262 f, **268 ff**, 273, 325
 - of fetus 288 f
 - horizontal section 287
 - midsagittal section 322
 - third 86, 90 f, 99, 105, 107, **112**, 115 f, 119 f
 - inferior wall 73
- Ventricular system 112
- Vermis of cerebellum 66, 74 f, 94, **102 ff**, **105**, 107, 116, 240
- Vertebra 190
 - cervical 7, 53, 159, **190**, 192 f, 369 f
 - joints 195
 - seventh 188 f, 193, **370**
 - lumbar 7, 188, **190**, **199**
 - fifth 438

Page numbers in **bold** indicate main discussions.

- Vertebra
 - lumbar
 - – first 189, 211, **369 f**
 - – joints 195
 - – prominens 188, 193, 222 f, 235, **370**
 - thoracic 7, **190, 197**
 - – first 192, **369 f**
 - – joints 195
 - – twelfth 192, **369 f**
 - Vertebral column 84, 188 f, **193 ff, 369**
 - cervical 53, 193
 - joints connecting to the head 200 f
 - ligaments 197 f
 - lumbar part 472 f
 - – median section 473
 - – MRI scan 473
 - – paramedian section 473
 - – sagittal section 472
 - midsagittal section 322
 - relation to spinal cord 475
 - thoracic 193
 - Vertex of skull 84
 - Vesicle, seminal 336 ff, 341 f, **344 ff**
 - Vessels s. also Artery; s. also Vein
 - of arm 415 ff
 - gastro-omental 311 f
 - lymphatic s. Lymph vessels
 - retinal 134
 - Vestibular apparatus **122 ff, 129**
 - Vestibule
 - of larynx 149
 - of lesser sac 324
 - nasal 53, **144 f**
 - oral 50, 53, 83, **150**
 - of vagina 355, **361**
 - Vidian canal 25, **33, 45 f, 146, 164**
 - Vinculum(-a)
 - breve 394
 - of flexor tendon 394
 - Visual apparatus 132 ff
 - Visual pathway 137 f
 - injuries 139
 - Visual system, 3-D reconstruction 139
 - Vomer 20, 22 f, 33, 45, **47 ff**
 - Vortex, muscular, of right ventricle 257
- W**
- Wall
 - abdominal
 - – anterior 187, 293
 - – – arteries 208
 - – – muscles 205
 - – – superficial 209
 - – – segments **205, 214**
 - – – surface anatomy 204 f
 - – horizontal section 214
 - – nerves 214 ff
 - – posterior 316 ff
 - – – veins 279
 - – transverse section 213
 - – vessels 214 ff
 - thoracic 206 ff
 - – anterior 187, 206 ff
 - – – arteries 208
 - – – muscles 205
 - – – superficial 209
 - – – segments **205, 214**
 - – – surface anatomy 204 f
- White matter 118
- Window, round 125 f, 128
- Wing s. also Ala
 - greater, of sphenoidal bone 20, 22 f, **25 f, 34, 38, 40 f, 47, 132**
 - – cerebral surface **25, 52**
 - – maxillary surface 38
 - – of newborn 35
 - – orbital surface 25, **38, 40 ff, 45**
 - – temporal surface 25, 42, 44
 - lesser, of sphenoidal bone 22, 23, **25 f, 30, 34, 38, 40 ff, 44, 132**
- Wrist 368
 - coronal section 380
 - ligaments 380 f
 - MRI scan 380
 - skeleton 376 f
- Wrist joint **368, 375**
 - coronal section 425
- Z**
- Zona orbicularis 444 f

